

VASCULAR ANATOMY OF THE UPPER LIMB

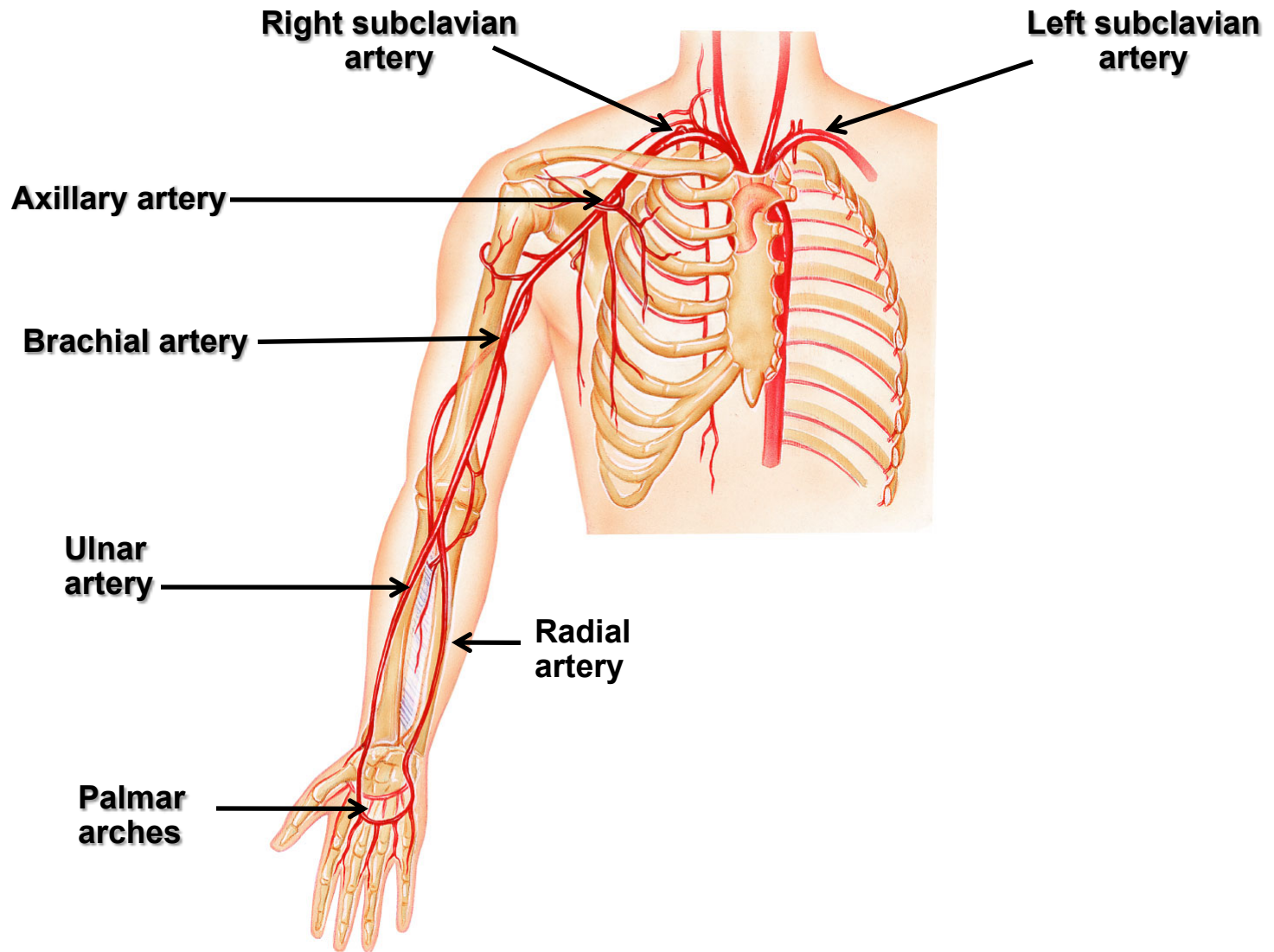
*Dr Jamila EL Medany & Dr. Essam Eldin
Salama*

Objectives

At the end of the lecture, the students should be able to:

- *Identify the origin of the vascular supply for the upper limb.*
- *Describe the main arteries and their branches of the arm, forearm & hand.*
- *Describe the vascular arches for the hand.*
- *Describe the superficial and deep veins of the upper limb*

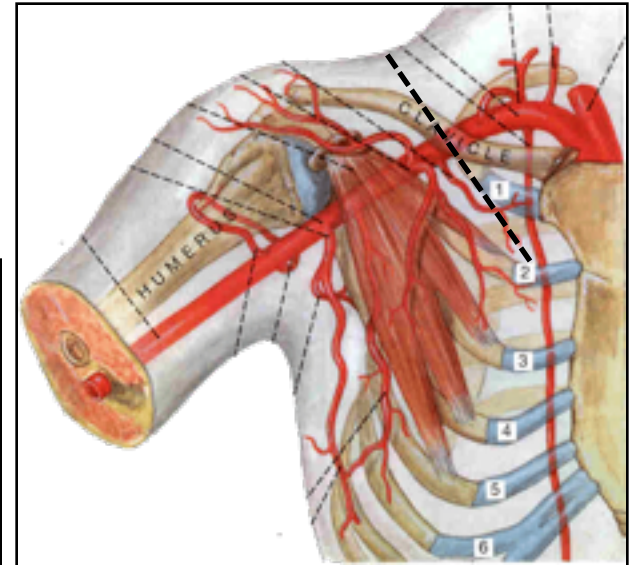
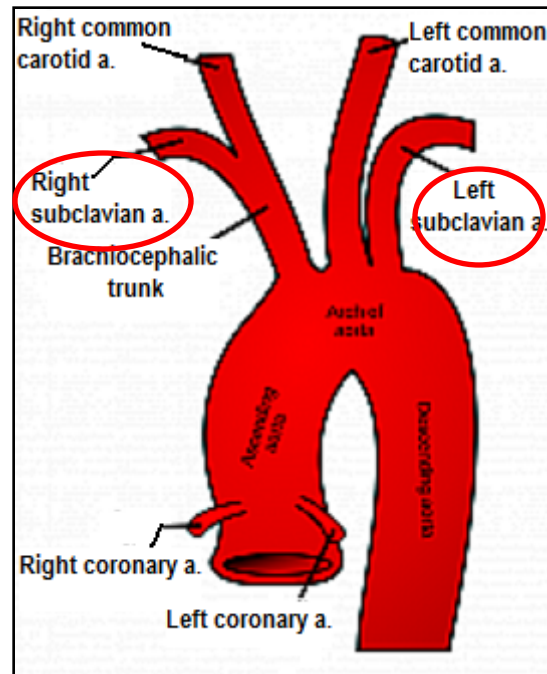
Arteries Of The Upper Limb



The Subclavian Artery

□ The **right** artery originates from the **brachiocephalic artery**.

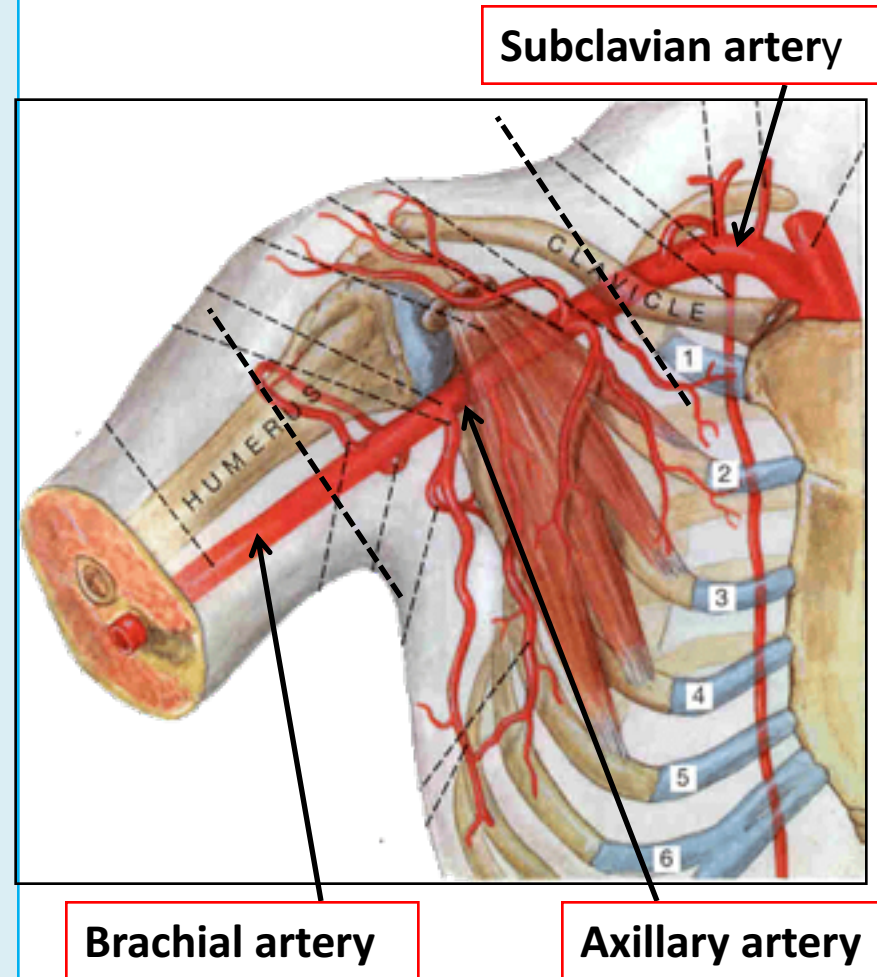
□ The **left** artery originates from the **arch of the aorta**.



Continues as **Axillary artery** at the lateral border of the 1st rib

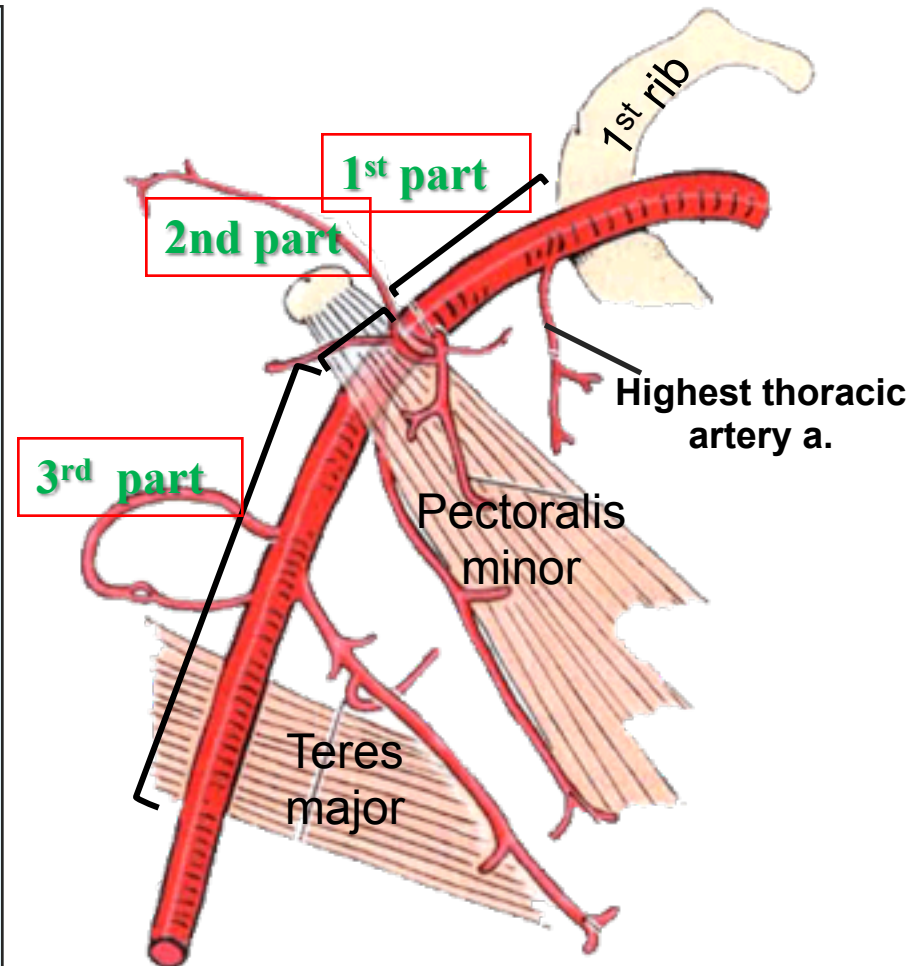
The Axillary Artery

- Begins at the lateral border of the 1st rib as continuation of the **subclavian artery**.
- Continues as **brachial artery** at lower border of **teres major** muscle.
- Is closely related to the cords of **brachial plexus** and their branches
- Is enclosed within the **axillary sheath**.
- Is crossed anteriorly by the **pectoralis minor** muscle, and is divided into three parts; **1st, 2nd & 3rd**.



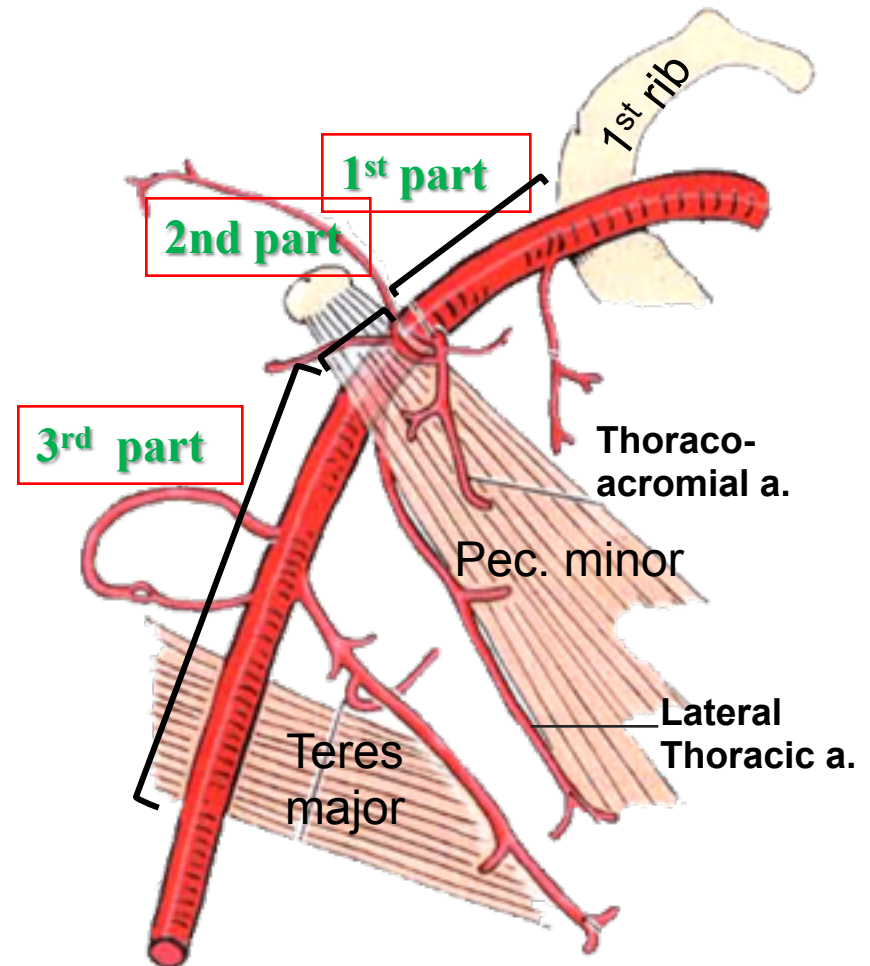
The 1st part of the axillary artery

- Extends from the **lateral border of 1st rib** to **upper border of the pectoralis minor muscle**.
- Related:
 - **Anteriorly**: to the pectoralis major muscle
 - **Laterally**: to the cords of the brachial plexus.
- It gives; **ONE branch**: **Highest thoracic artery**



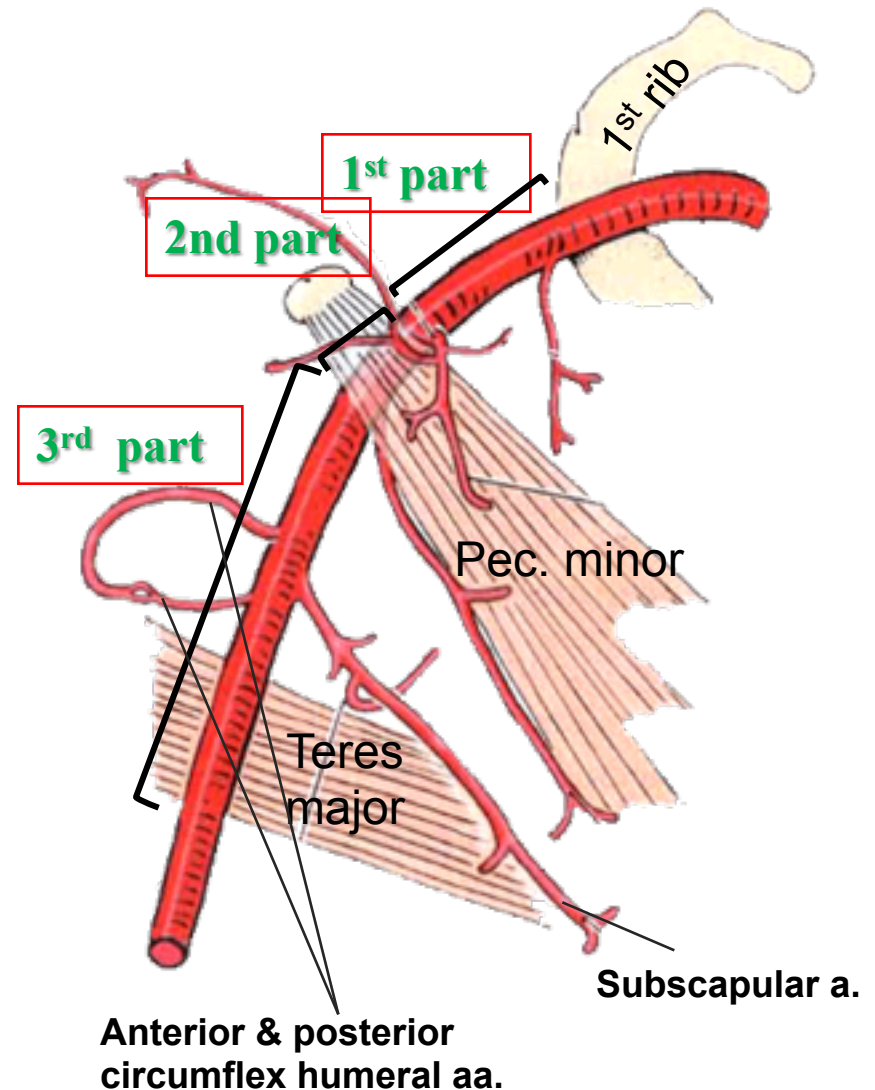
The 2nd part of the axillary artery

- Lies **behind the pectoralis minor muscle.**
- It is related medially, laterally, and posteriorly to the corresponding **cord** of the brachial plexus.
- It gives; **TWO branches:**
 - **Thoracoacromial .**
 - **Lateral thoracic.**



The 3rd part of the axillary artery

- Extends from the **lower border of pectoralis minor muscle** to the **lower border teres major muscle**.
- Related medially, laterally, and posteriorly, to the **branches** of the cords of the brachial plexus
- It gives; **THREE Branches**:
 - **Subscapular,**
 - **Anterior circumflex humeral**
 - **Posterior circumflex humeral.**



❑ Anastomosis occurs between branches of **Subclavian and Axillary arteries:**

▪ **Branches from**

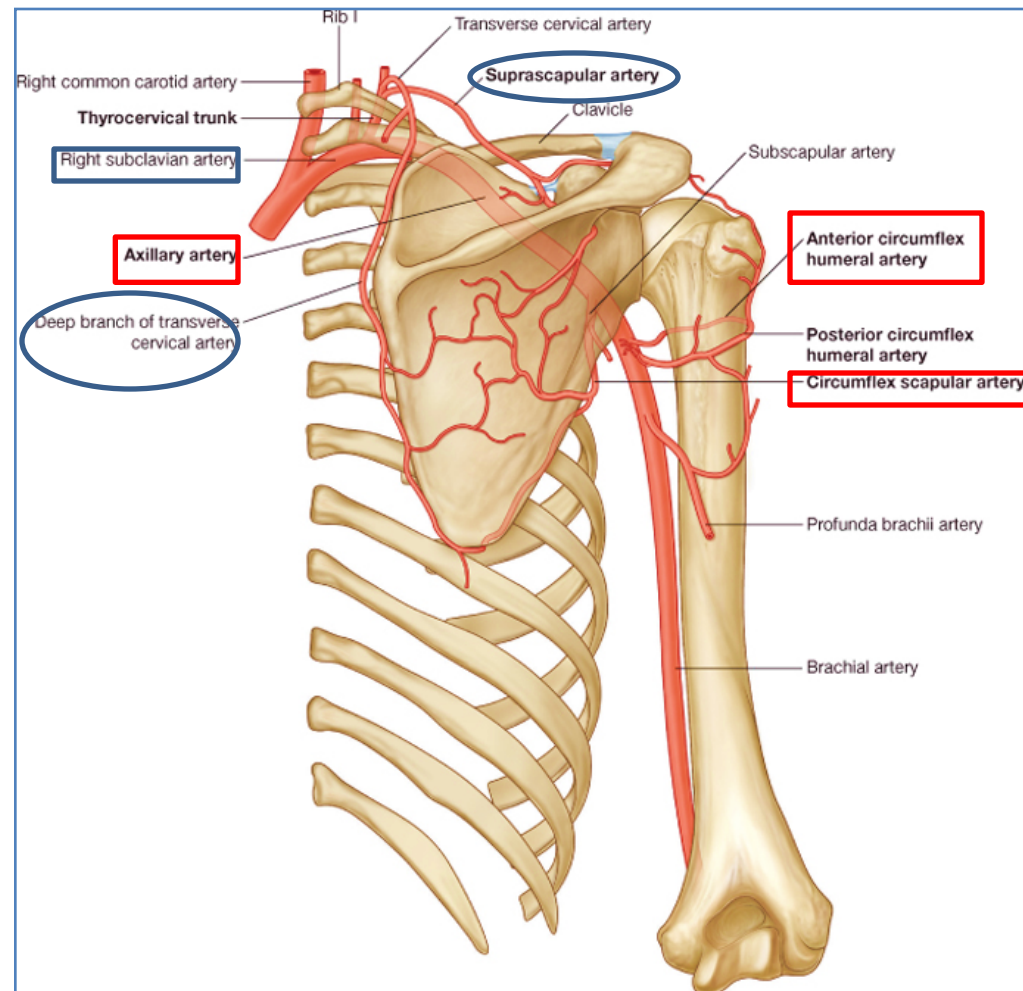
Subclavian Artery:

- Suprascapular artery
- Transverse cervical artery

▪ **Branches from Axillary Artery:**

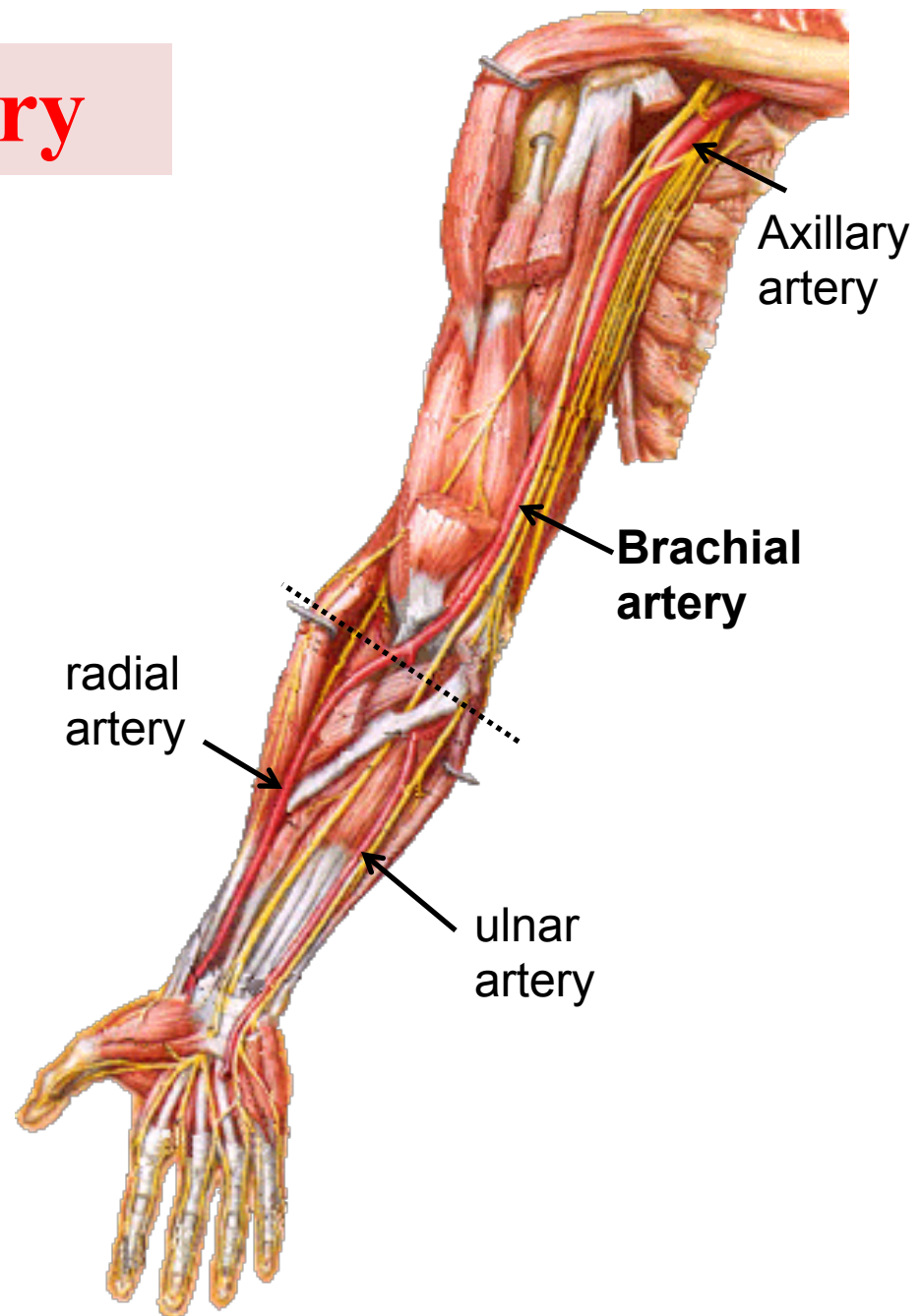
- Subscapular artery
- Anterior circumflex humeral artery
- Posterior circumflex humeral artery

Anastomosis around Shoulder joint (SCAPULA)



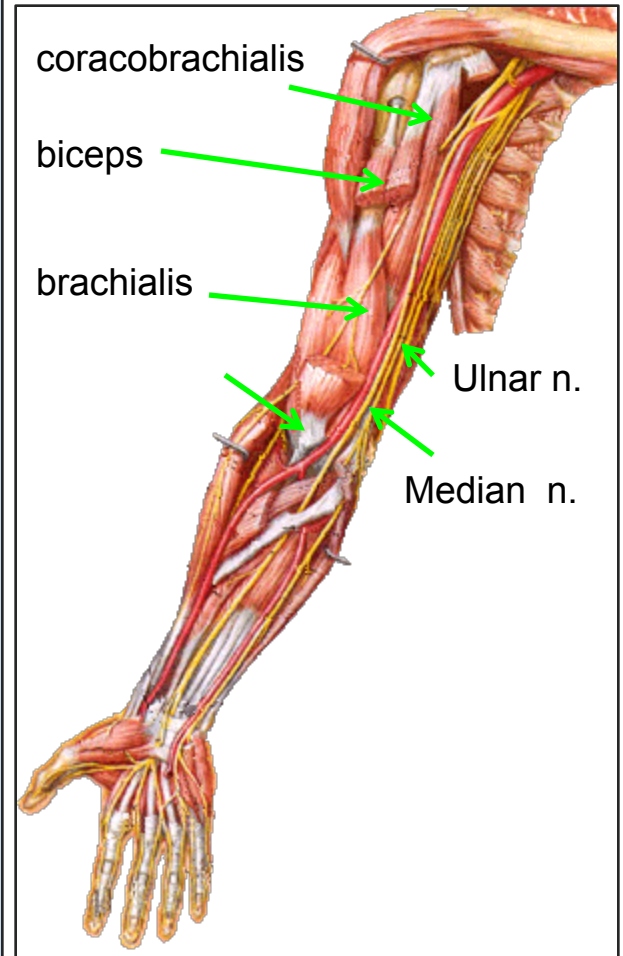
The Brachial Artery

- Is a continuation of the **axillary artery** at the lower border of teres major muscle.
- Provides main arterial supply to the arm.
- **Terminates** opposite **Neck of Radius** by dividing into **Radial** & **Ulnar** arteries.



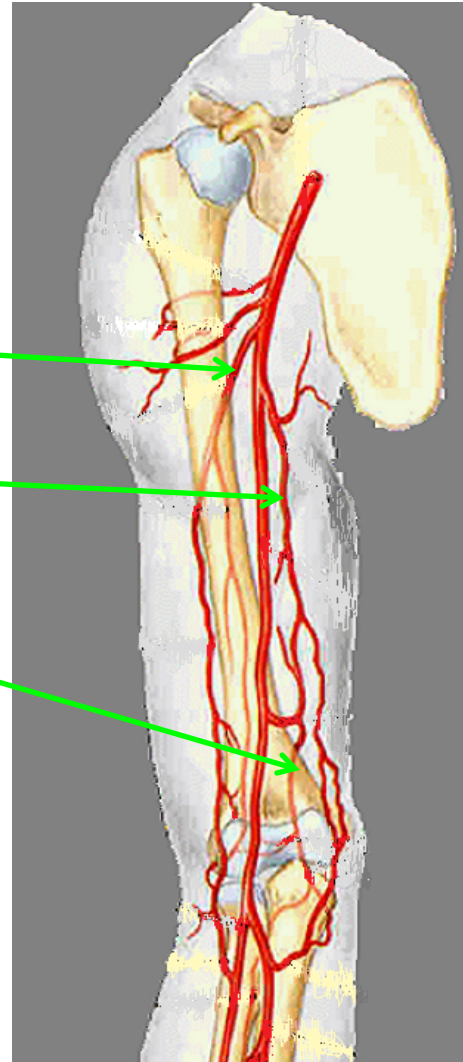
Relations of Brachial Artery

- **Anteriorly**: crossed from above downward by medial cutaneous nerve of the forearm, median nerve, and bicipital aponeurosis.
- **Posteriorly**: triceps, coracobrachialis and brachialis.
- **Medially**: basilic vein, ulnar and median nerves.
- **Laterally**: coracobrachialis and biceps muscles.



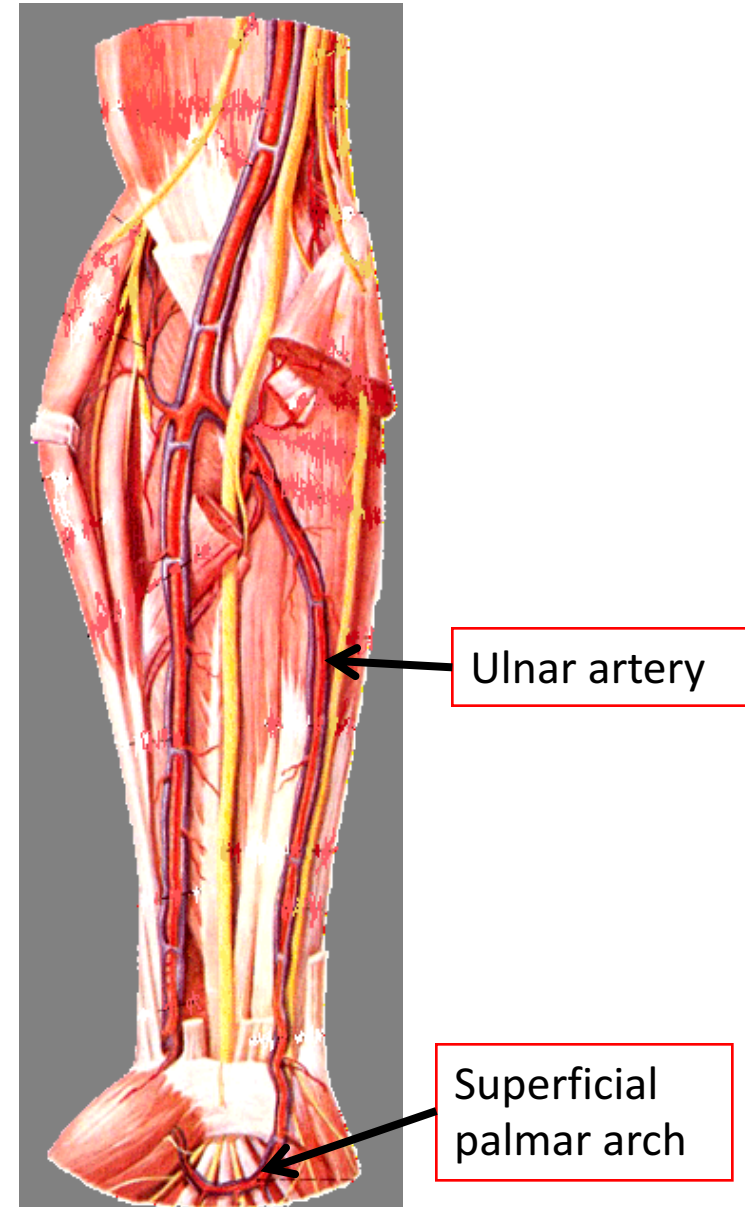
Branches of Brachial Artery

- Muscular.
- Nutrient to humerus.
- **Profunda brachii**
- **Superior ulnar collateral.**
- **Inferior ulnar collateral.**

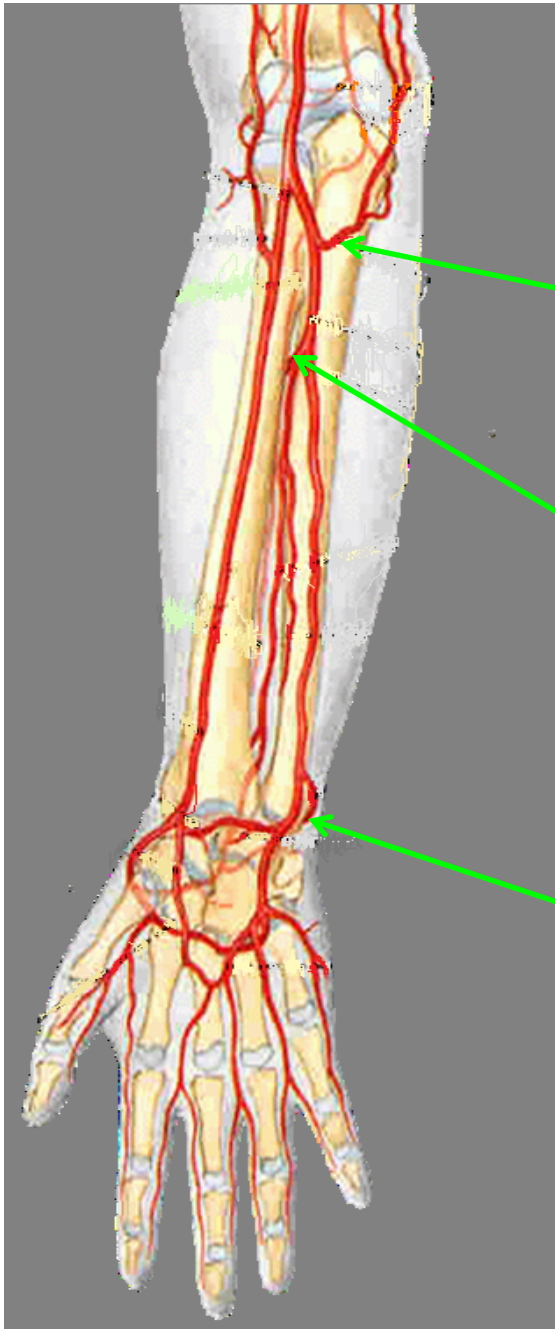

The Ulnar Artery

- The **larger** of the two terminal branches of the **brachial artery**.
- Begins in the cubital fossa at the level of **neck of radius**.
- Descends through the **anterior compartment** of the forearm.
- Enters the palm, **in front of the flexor retinaculum**, with the ulnar nerve.
- **Ends** by forming the **superficial palmar arch**, by anastomosing with superficial palmar branch of radial artery.



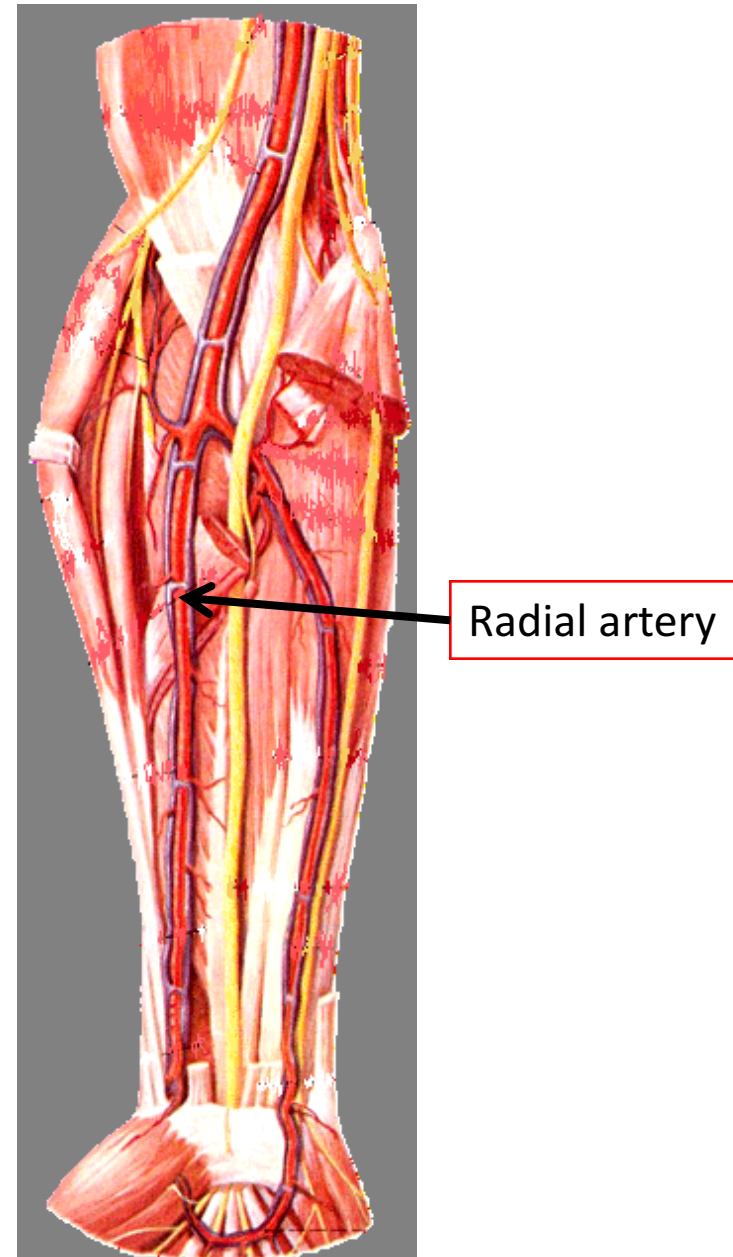
Branches of Ulnar Artery



- Muscular .
- **Recurrent branch** (for anastomosis around the elbow joint).
- **Common Interosseous** artery, which gives:
Anterior and Posterior Interosseous arteries.
- Branch to anastomoses around the wrist joint.

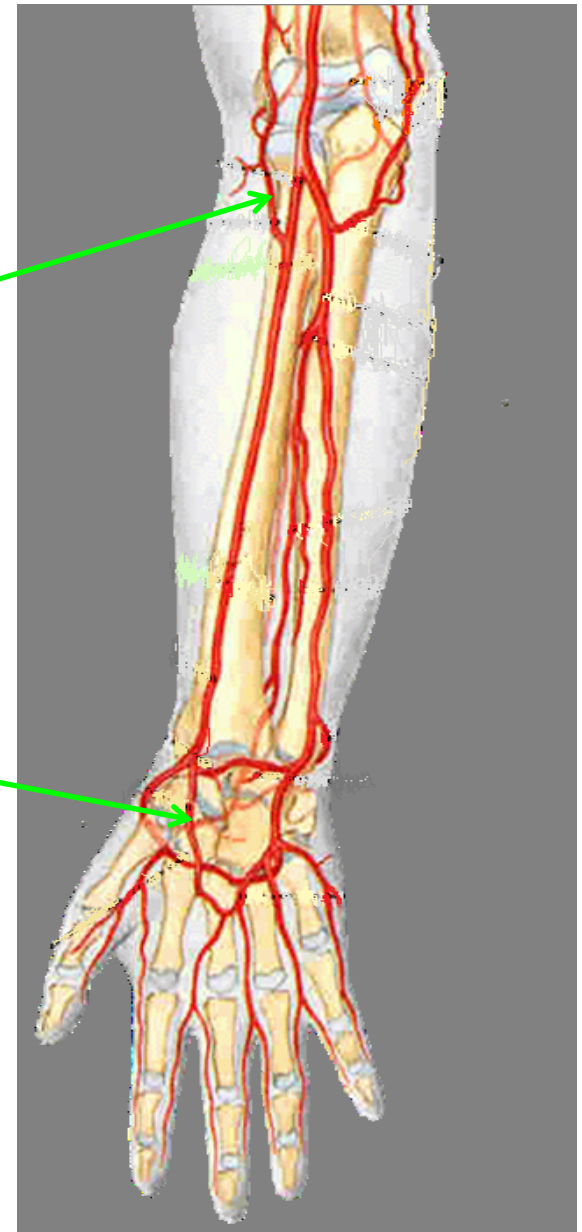
The Radial Artery

- The **smaller** of the two terminal branches of the **brachial artery**.
- Begins in the cubital fossa at the level of **neck of radius**.
- Descends downward and laterally.
- Leaves the forearm by **winding** around the lateral aspect of the wrist to reach the **dorsum** of the hand.



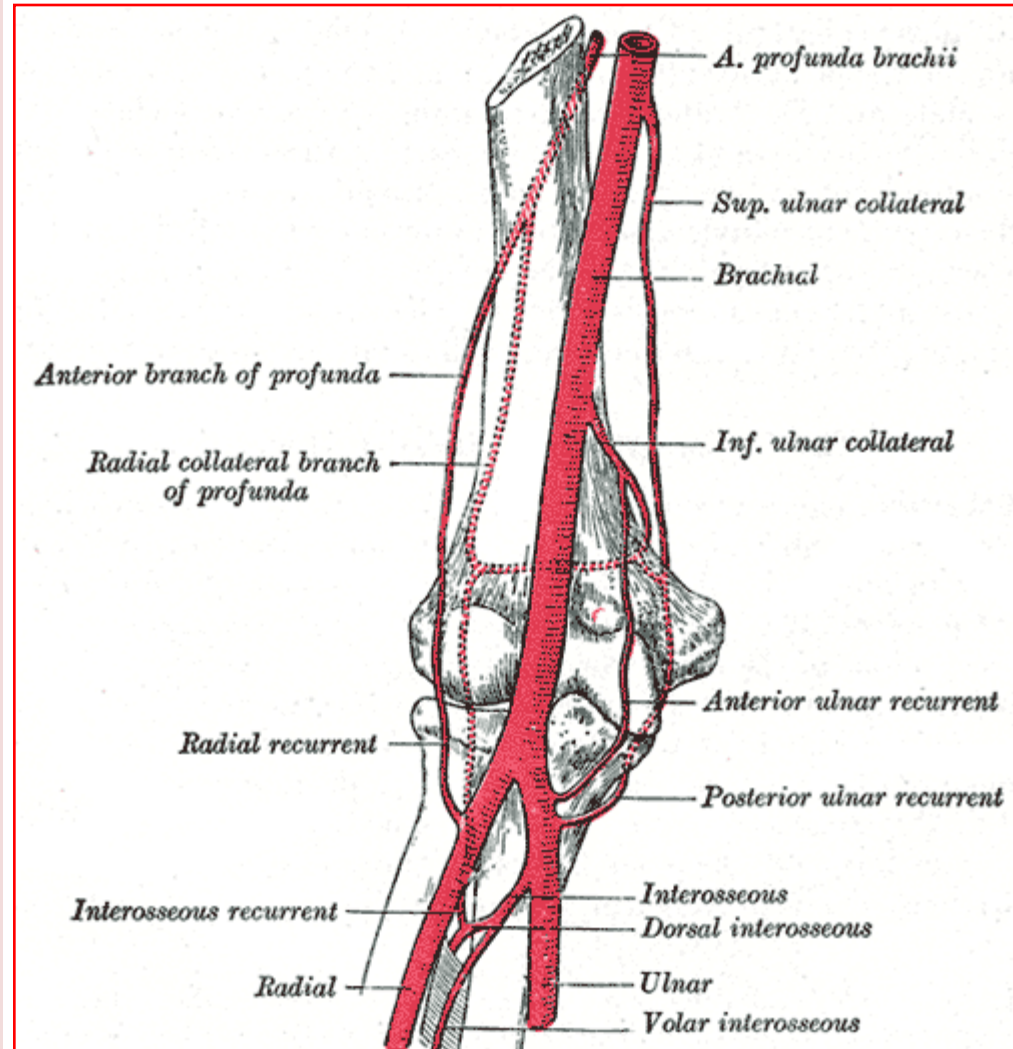
Branches of Radial Artery

- Muscular
- **Recurrent branch** (for anastomosis around the elbow joint).
- **Superficial palmar branch**, joins the ulnar artery to form the superficial palmar arch.



Anastomosis around Elbow Joint

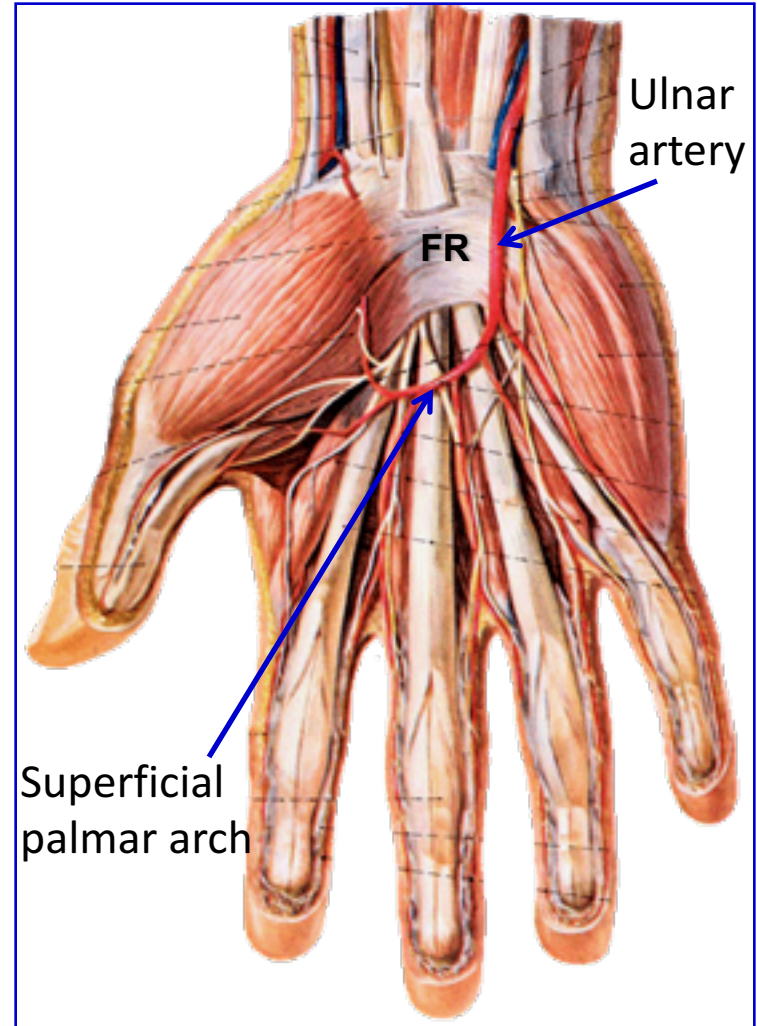
- ❑ Anastomosis occurs between branches of
- ❑ **Brachial, Radial and Ulnar arteries:**
 - Branches from Brachial Artery:
 - Profunda Brachii artery
 - Superior ulnar collateral artery
 - Inferior ulnar collateral artery
 - Branches from Ulnar and Radial Arteries:
 - Radial & ulnar recurrent arteries
 - Interosseous recurrent artery



Arteries of the Palm

➤ Ulnar artery:

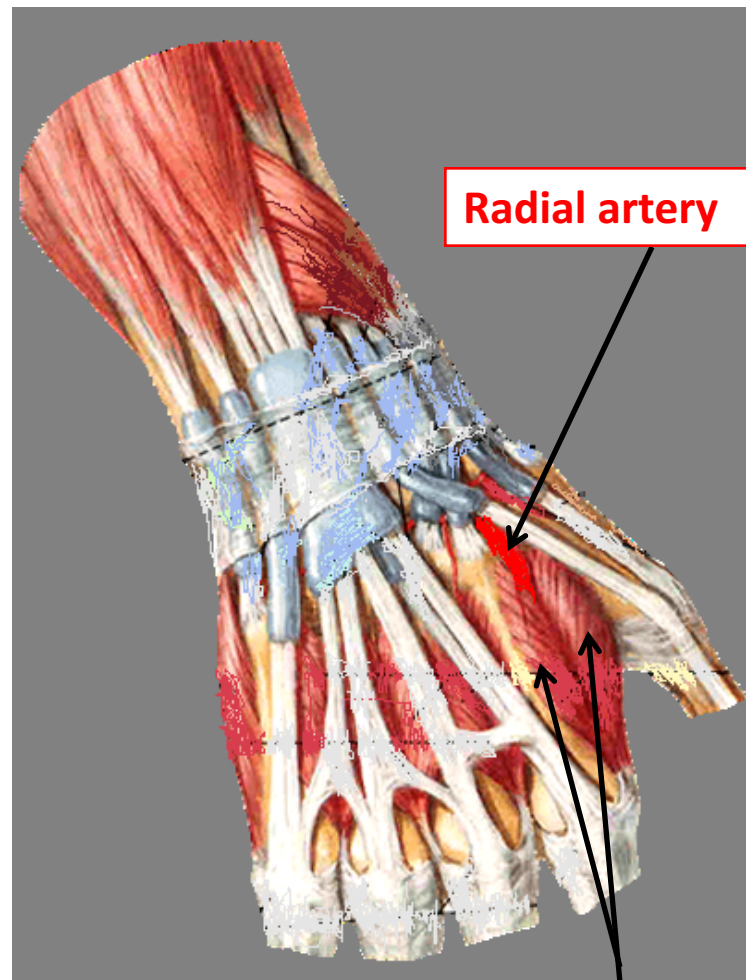
- Enters the hand:
 - anterior to the flexor retinaculum,
 - on the lateral side of the ulnar nerve and pisiform bone.
- Gives a **deep branch**.
- Continue as the **superficial palmar arch**.



Arteries of the Palm

➤ Radial artery;

- Leaves dorsum of the hand by **turning forward** between the proximal ends of the **1st and 2nd metacarpal** bones and **two heads of the 1st dorsal interosseous muscle**.
- On entering the palm it continues as **deep palmar arch**.
- It gives; arteria **radialis indicis** and arteria **princeps policis**.

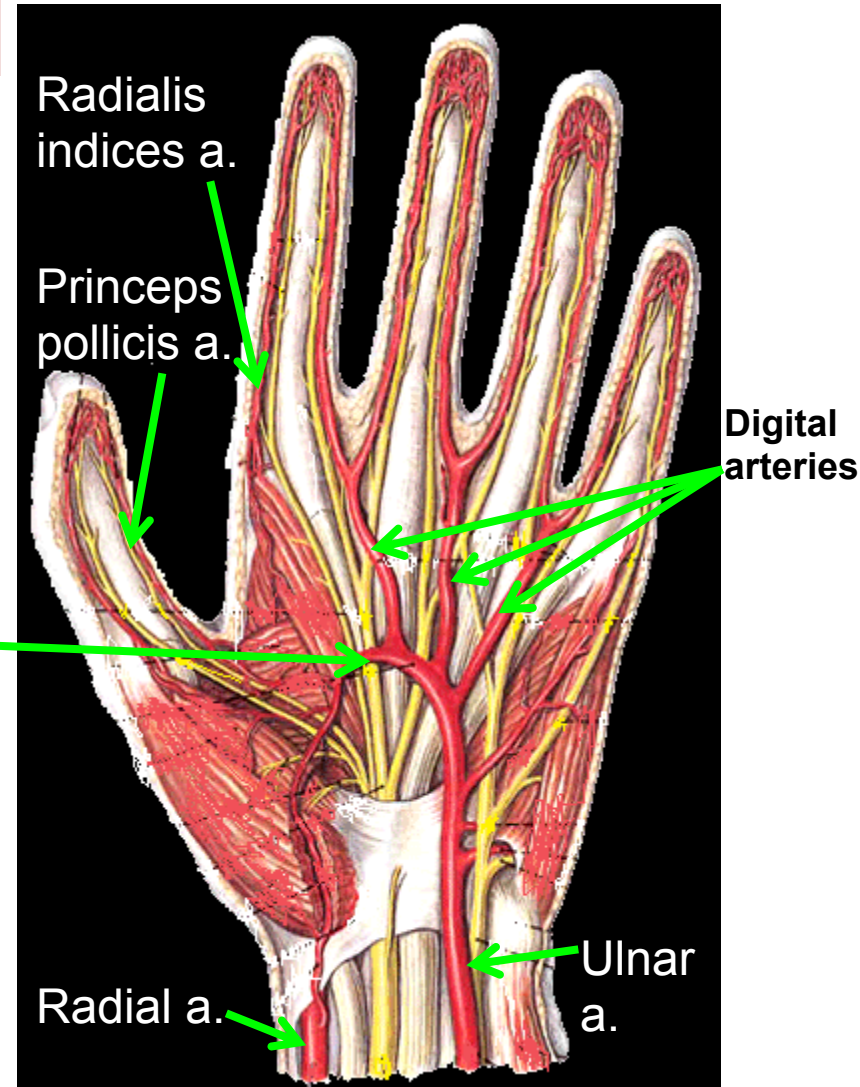


Radial artery

1st dorsal
interosseous muscle

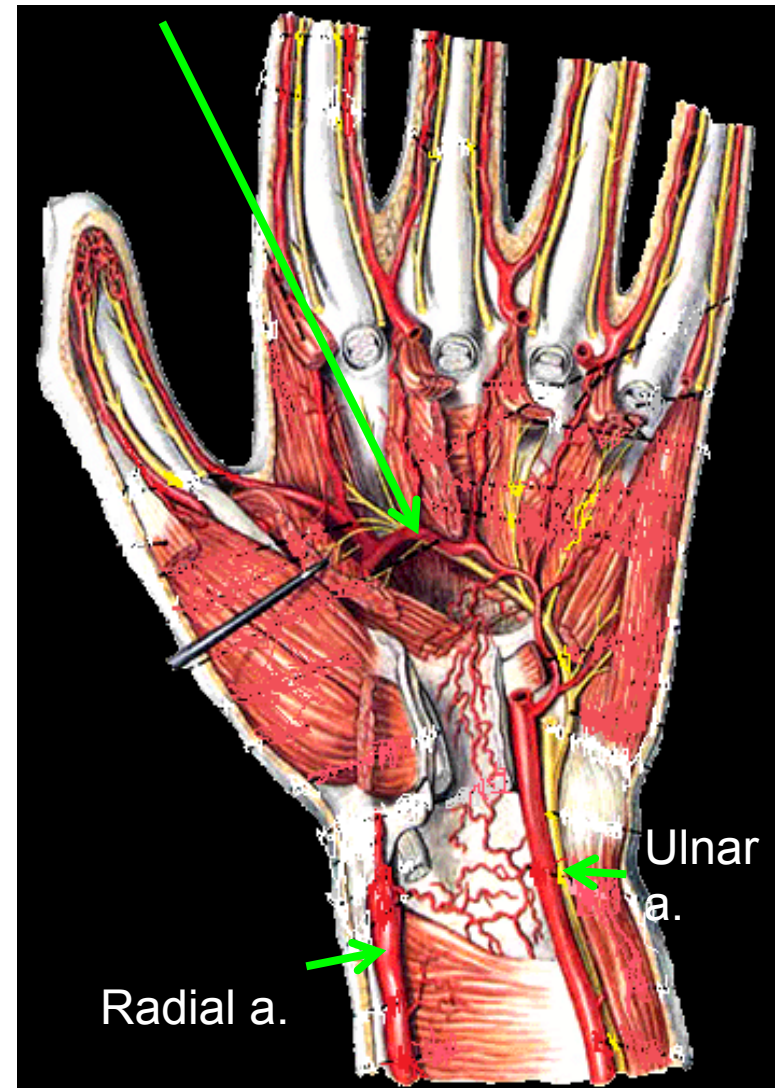
The Superficial Palmar Arch

- Is the direct continuation of the **ulnar artery**, as it curves laterally behind the palmar aponeurosis.
- Is completed by **branch from the radial artery**.
- Lies approximately at the level of the **Distal Border of the Extended Thumb**.
- Gives: **digital arteries** from its convexity to supply the fingers.

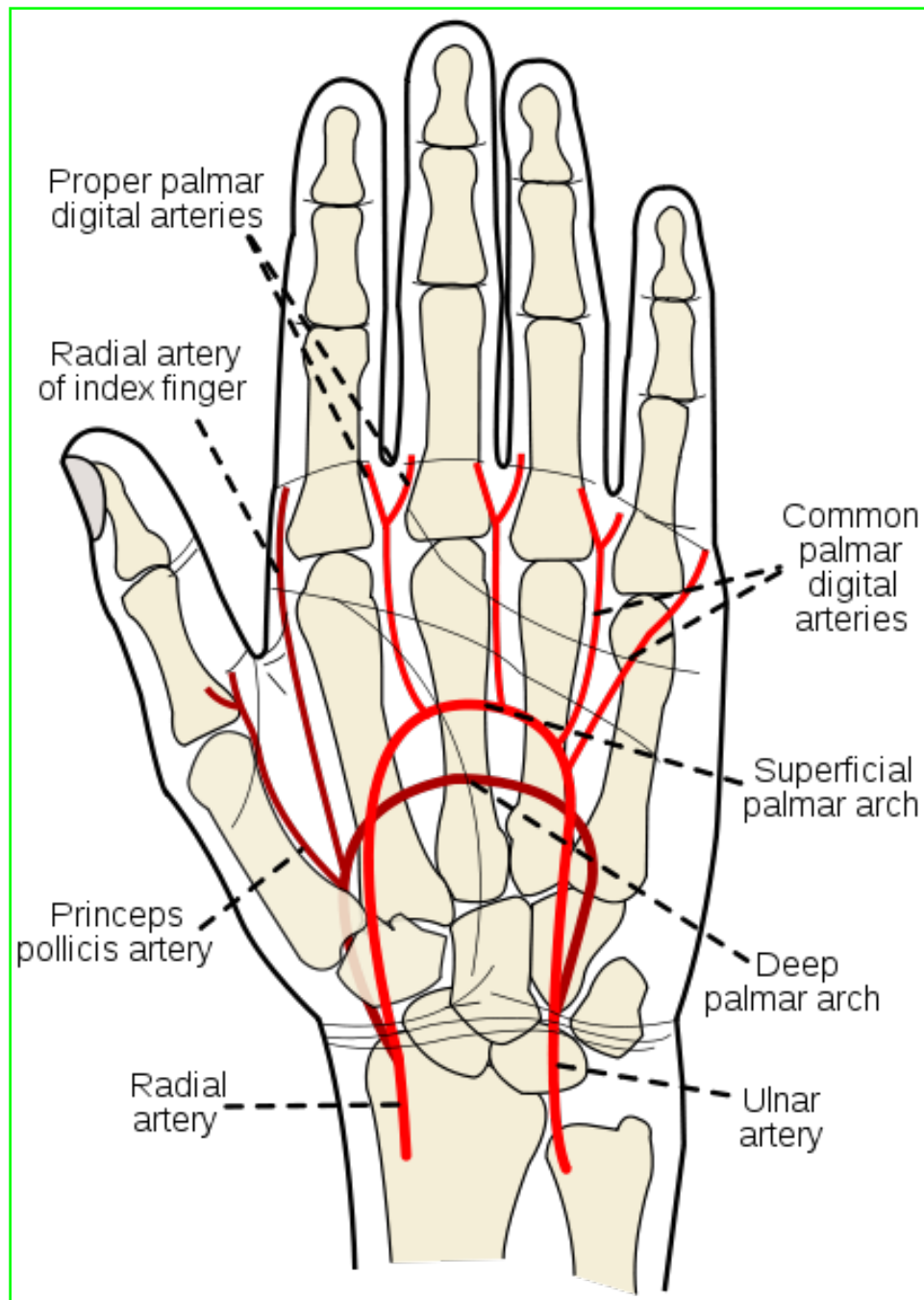


- Is a continuation of the **radial artery** as it curves medially beneath long flexor tendons , in front of the metacarpal bones and interosseous muscles.
- Is completed on the medial side by **deep branch of ulnar artery**.
- Lies at a level of the **Proximal Border of Extended thumb**.
- It sends branches:
 - **superiorly** to share in anastomosis around the wrist joint &
 - **inferiorly** to join branches of the superficial palmar arch.

The Deep Palmar Arch



The superficial palmar arch is more distal than the deep palmar arch.



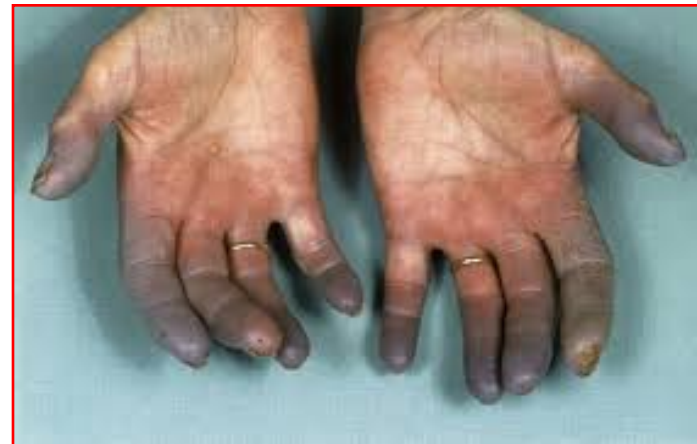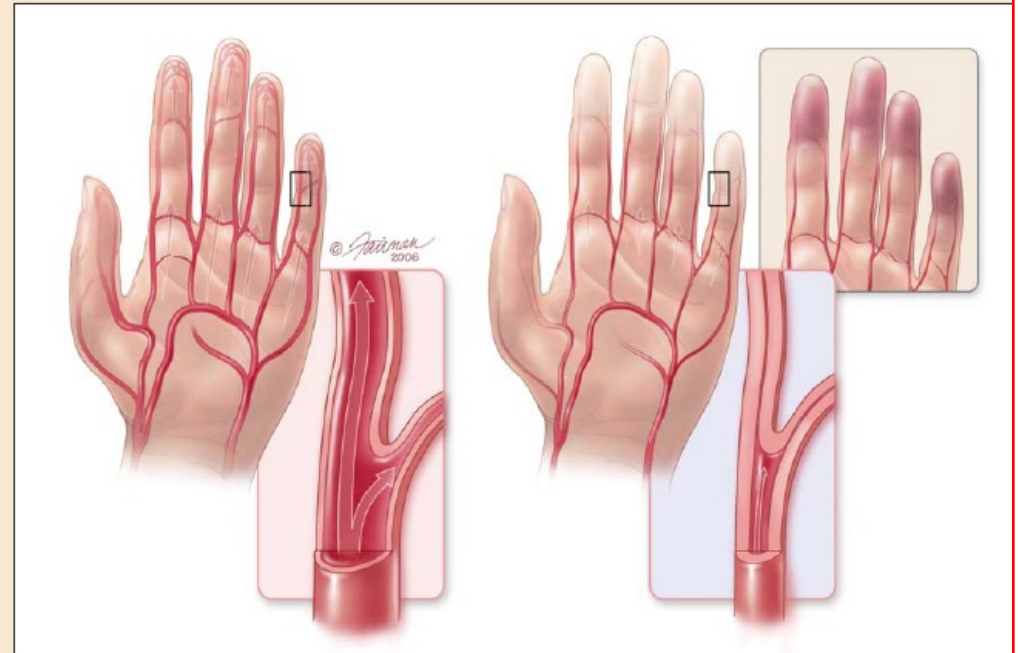
ARTERIAL INNERVATION AND RAYNAUD'S DISEASE

Raynaud's disease is a vasospastic disease involves digital arteries.

It may require cervicodorsal perganglionic sympathectomy to prevent **necrosis of the fingers**

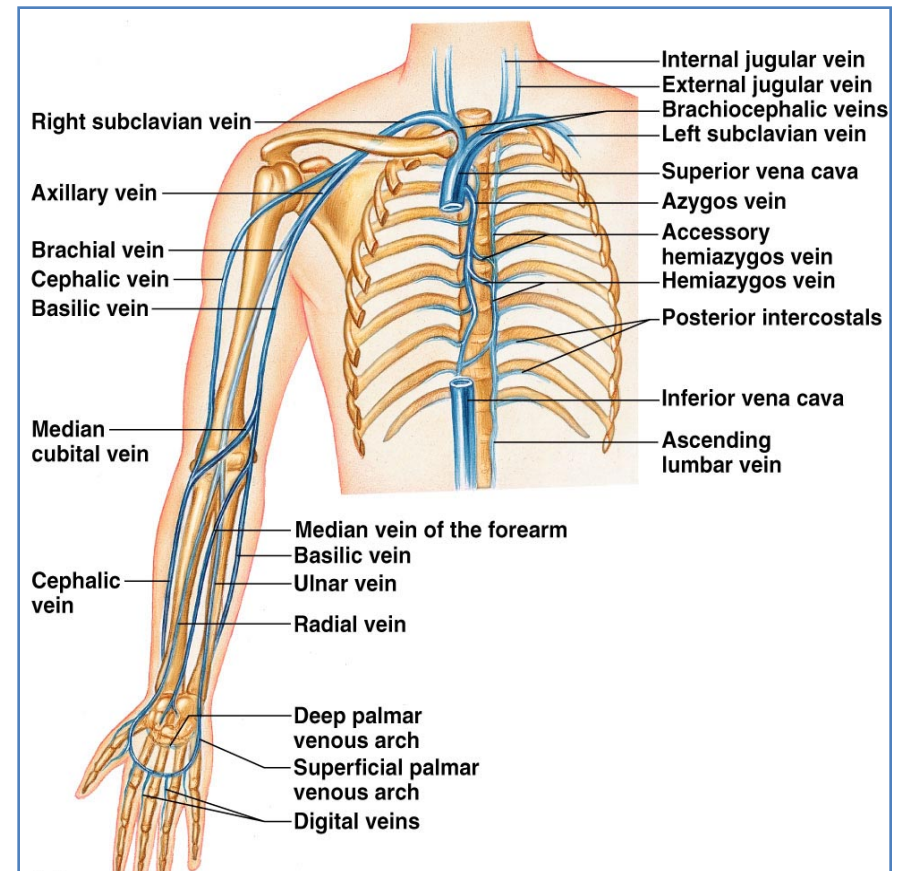
FIGURE 1

Vascular changes that occur during acute Raynaud's disease



Veins of the Upper Limb

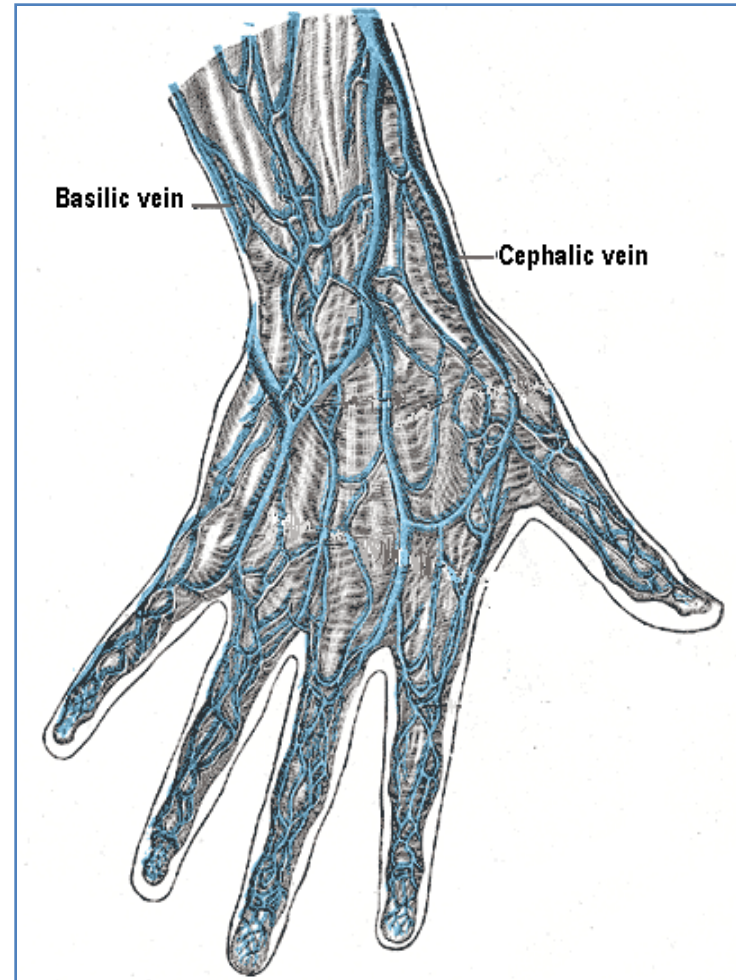
- The veins of the upper limb are divided into two sets: **Superficial** and **Deep**
- The two sets anastomose frequently with each other.
- The **superficial veins** are placed immediately beneath the skin, in the superficial fascia.
- The **deep veins** accompany the arteries, and constitute the **venæ comitantes** of those vessels



Superficial Veins of the Upper Limb

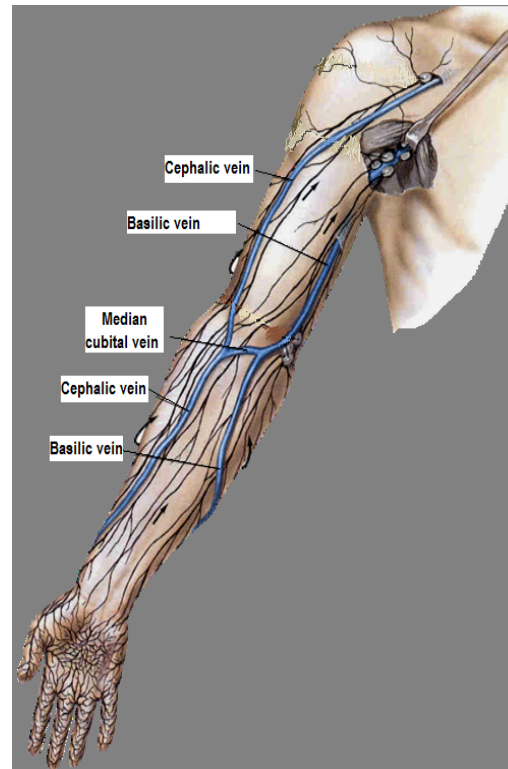
Dorsal Venous Arch (network)

- The dorsal digital veins drain into dorsal metacarpal veins, which unite to form a **dorsal venous arch or network**.
- Dorsal venous network lies on the dorsum of the hand, **in the subcutaneous tissue, proximal to the metacarpophalangeal joints**
- Drains into the **Cephalic** vein laterally, and **Basilic** vein medially



Cephalic Vein

- Arises from the **lateral end** of the dorsal venous arch of hand.
- Ascends on **radial side** of the forearm to the elbow and continues up the arm in the **deltopectoral groove**.
- Pierces **clavipectoral fascia** to drain into the **axillary vein**.



Basilic Vein

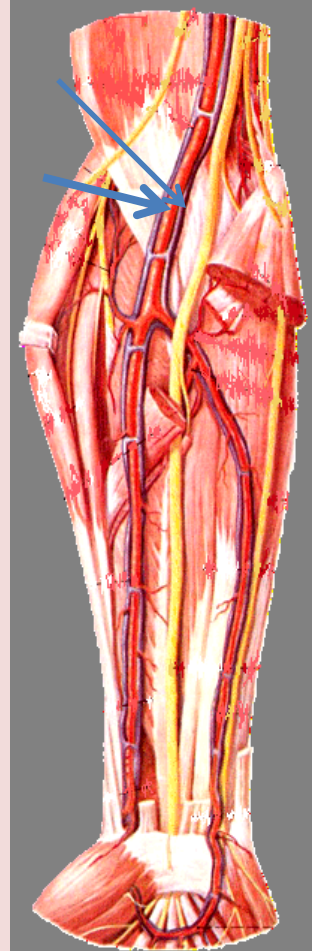
- Arises from the **medial side** of the dorsal venous arch of hand.
- Ascends on the **ulnar side** of forearm to the elbow ,
- in the middle of the arm, it pierces the **deep fascia** and joins the **brachial vein or axillary vein**.

Median Cubital Vein

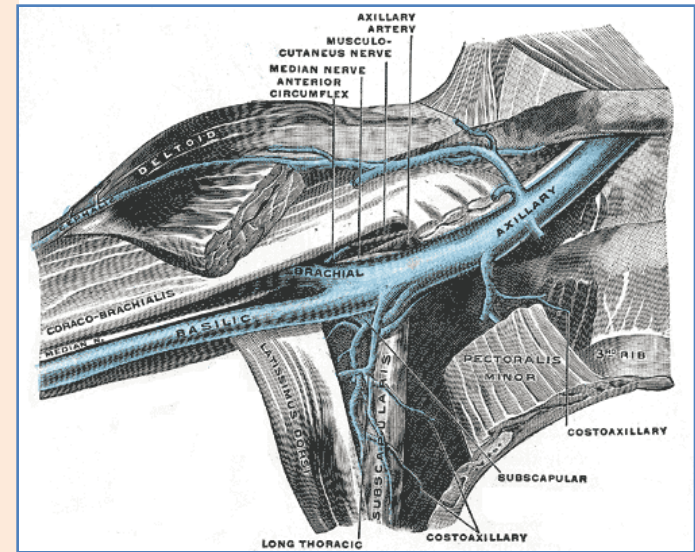
- Links cephalic vein and basilic vein in the cubital fossa.
- Is a frequent site for venipuncture.

Deep Veins of the Upper Limb

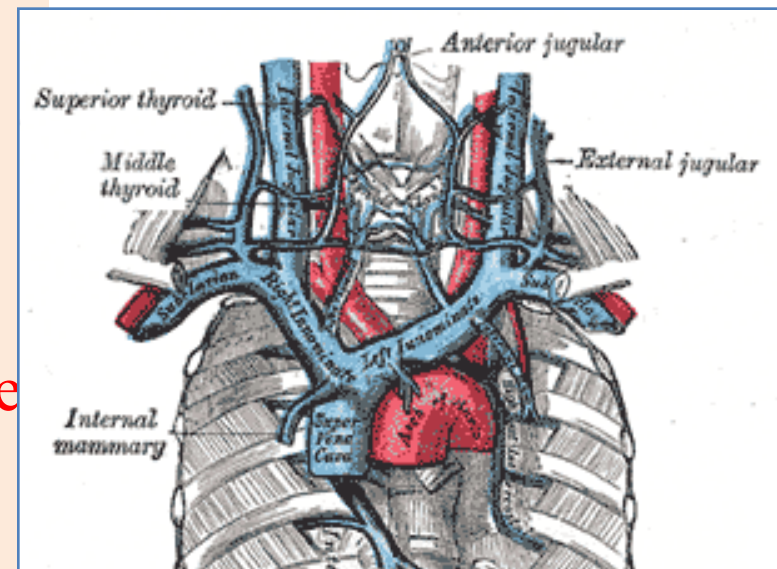
- Accompany the arteries of the same region and bear similar names.
- **Venae comitantes**: They are generally arranged in pairs, and are situated one on either side of the corresponding artery, and connected at intervals by short transverse branches.
- The superficial and deep palmar arterial arches are each accompanied by a pair of venæ comitantes which constitute the **superficial** and **deep palmar venous arches**, and receive the veins corresponding to the branches of the arterial arches.
- The **deep veins of the forearm** are the venæ comitantes of the radial and ulnar arteries.
- The **brachial veins** are placed one on either side of the brachial artery.



- The **Axillary vein**:
 - Begins at the **lower border of the Teres major**, as the continuation of the basilic vein.
 - Ends at the **outer border of the first rib** as the subclavian vein.
 - Receives the **brachial veins** and, close to its termination, the **cephalic vein**.



- The **Subclavian vein**:
 - Is the continuation of the axillary vein.
 - Extends from the **outer border of the first rib to the sternal end of the clavicle**, where it unites with the internal jugular to form the **Brachiocephalic (Innominate) vein**.



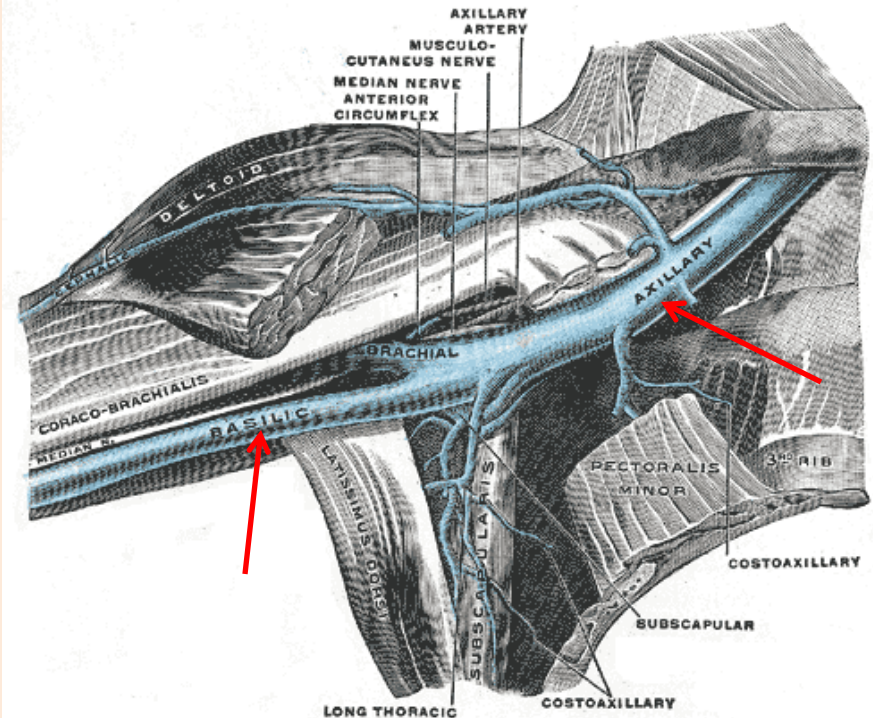
Vein Catheterization

The **Basilic vein** is the vein of choice for central venous catheterization,

Because:

from the cubital fossa until reaching the axillary vein it increases in diameter and lies in direct line with the axillary vein.

The **Cephalic vein** does not increase in size as it ascends in the arm, and frequently divides into small branches, And it joins the axillary vein at right angle ,so it is difficult to maneuver the catheter around this angle.



THANK YOU