

SHOULDER REGION

Dr Jamila EL Medany

OBJECTIVES

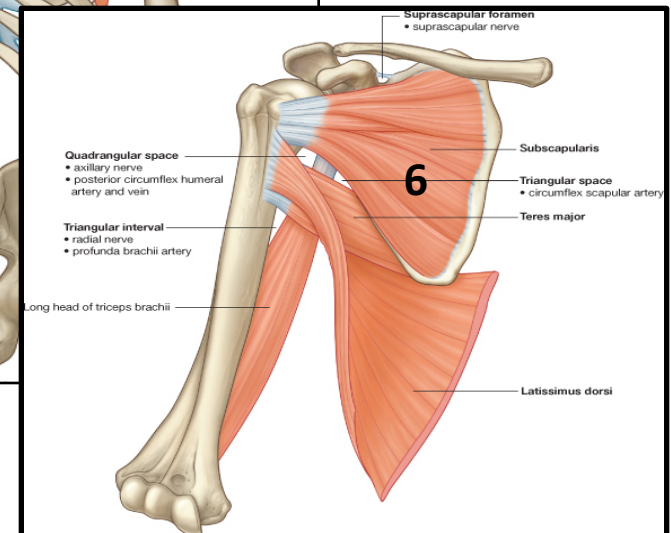
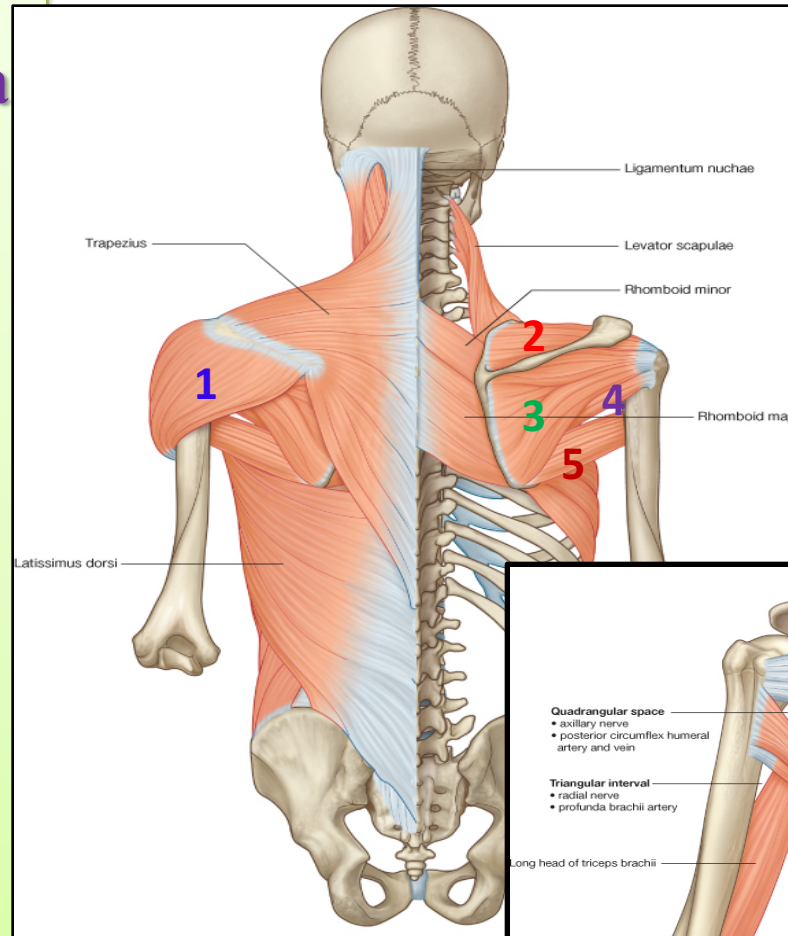
At the end of the lecture, students should:

- *List the name of muscles of the shoulder region.*
- *Describe the anatomy of muscles of shoulder region regarding: attachments of each of them to scapula & humerus, nerve supply and actions on shoulder joint*
- *List the muscles forming the rotator cuff and describe the relation of each of them to the shoulder joint.*
- *Describe the anatomy of shoulder joint regarding: type, articular surfaces, stability, relations & movements.*

MUSCLES OF SHOULDER REGION

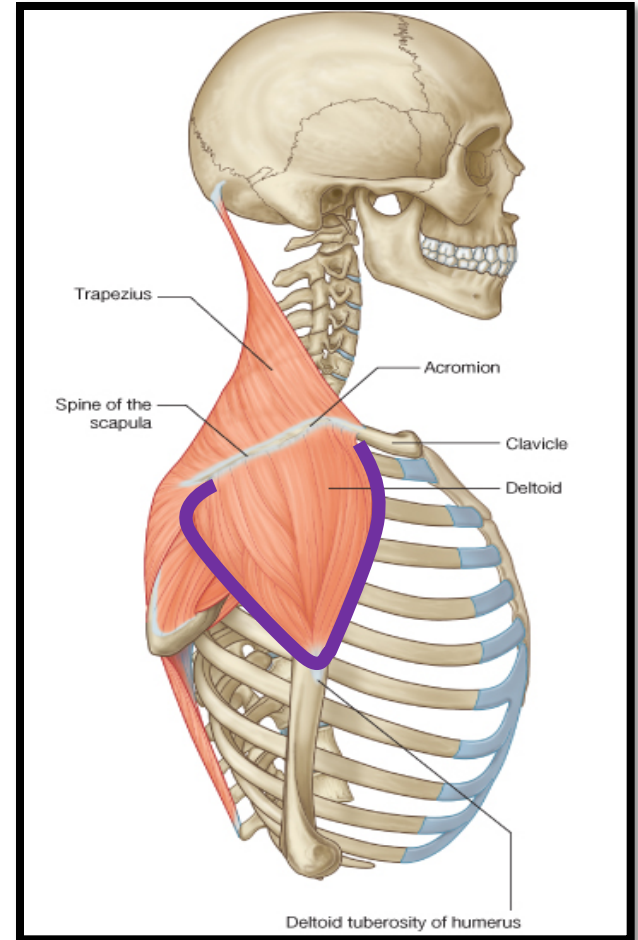
❑ These are muscles connecting scapula to humerus (move humerus through shoulder joint):

1. *Deltoid.*
2. *Supraspinatus.*
3. *Infraspinatus.*
4. *Teres minor.*
5. *Teres major.*
6. *Subscapularis.*



DELTOID

- ❑ A **triangular muscle** that forms the rounded contour of the shoulder.
- ❑ **Origin:** lateral 1/3 of clavicle, acromion and spine of scapula
- ❑ (= insertion of trapezius).
- ❑ **Insertion:** deltoid tuberosity of humerus.
- ❑ **Nerve supply:** axillary nerve.
- ❑ **Actions:**
 1. **Anterior fibers:** flexion & medial rotation of humerus (arm, shoulder joint).
 2. **Middle fibers:** abduction of humerus from **15° - 90°**.
 3. **Posterior fibers:** extension & lateral rotation of humerus.



SUPRASPINATUS & INFRASPINATUS

Origin:

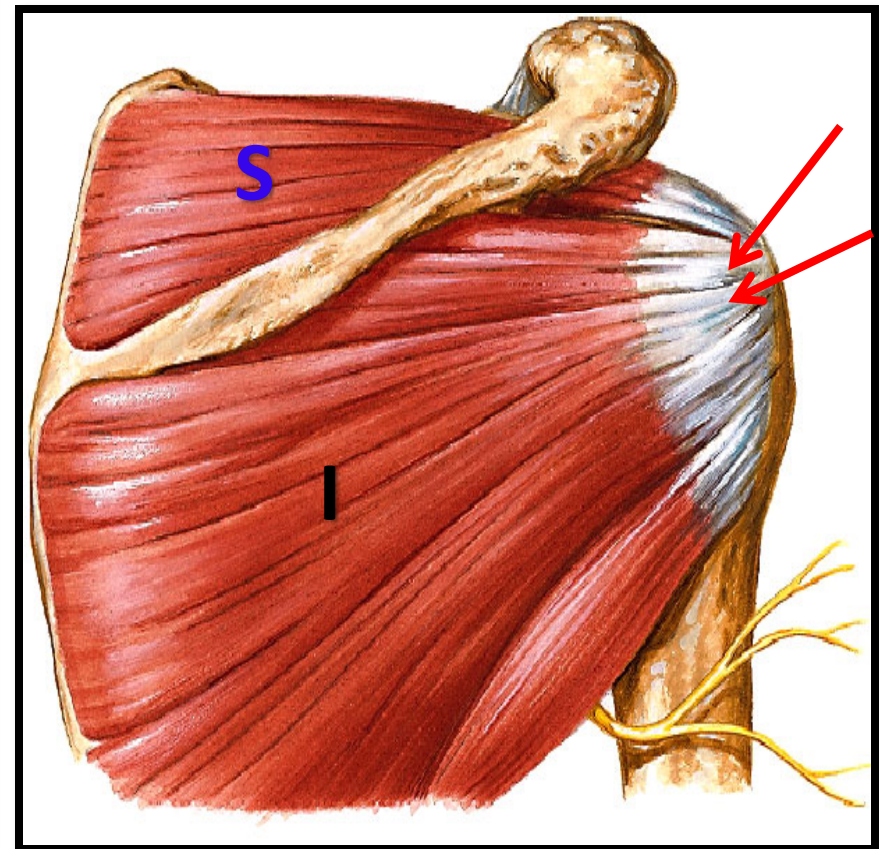
1. *Supraspinatus*: supraspinous fossa.
2. *Infraspinatus*: infraspinous fossa.

Insertion: greater tuberosity of humerus.

Nerve supply: Suprascapular nerve.

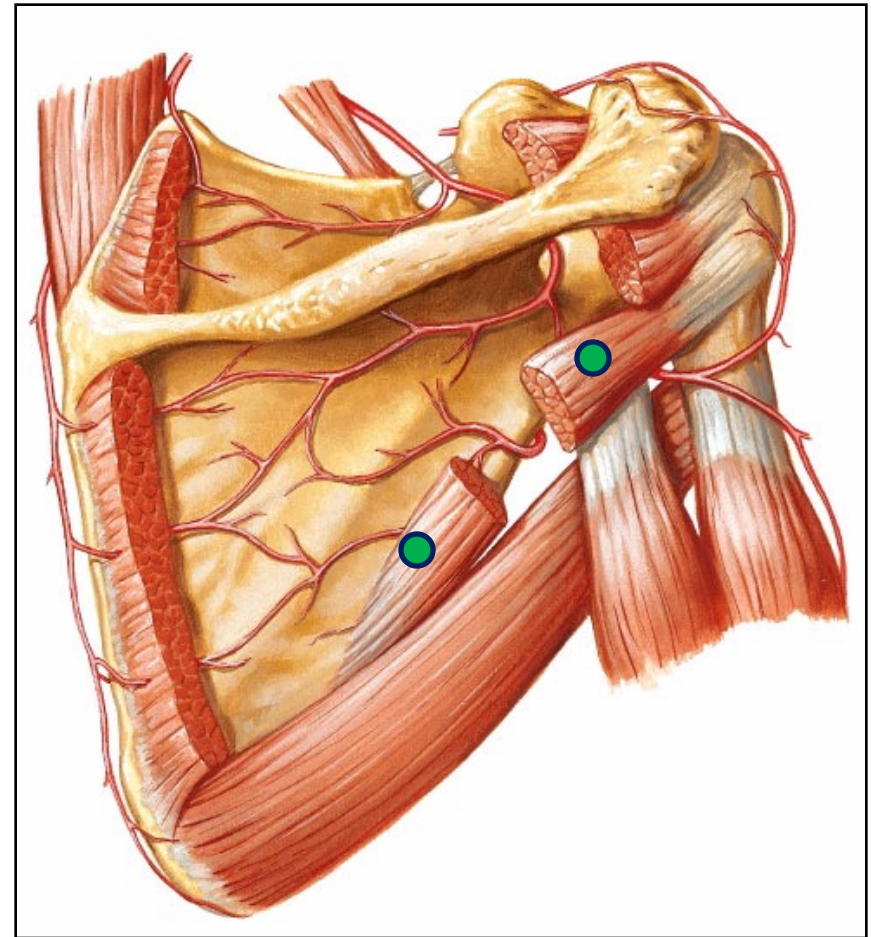
Action:

1. *Supraspinatus*: abduction of humerus from 0° - 15° .
2. *Infraspinatus*: lateral rotation of humerus.



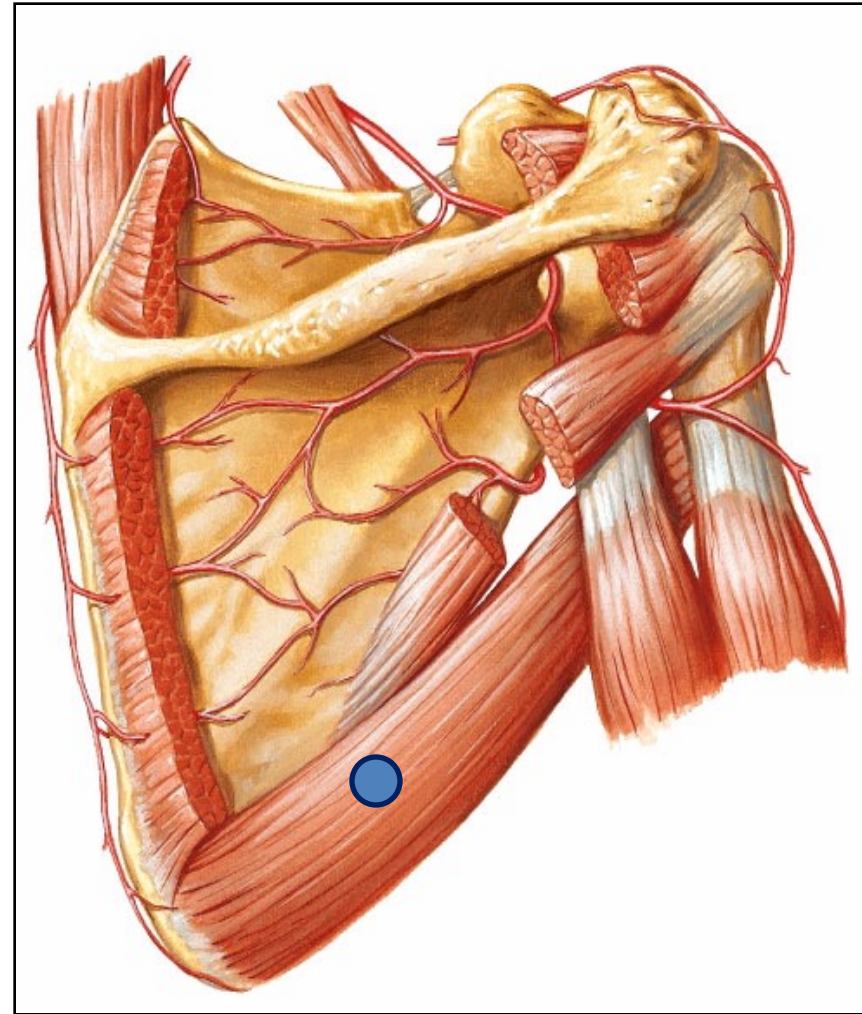
TERES MINOR

- ❑ **Origin:** lateral (Axillary) border of Scapula.
- ❑ **Insertion:** greater tuberosity of humerus.
- ❑ **Nerve supply:** axillary nerve.
- ❑ **Action:** lateral rotation of humerus.



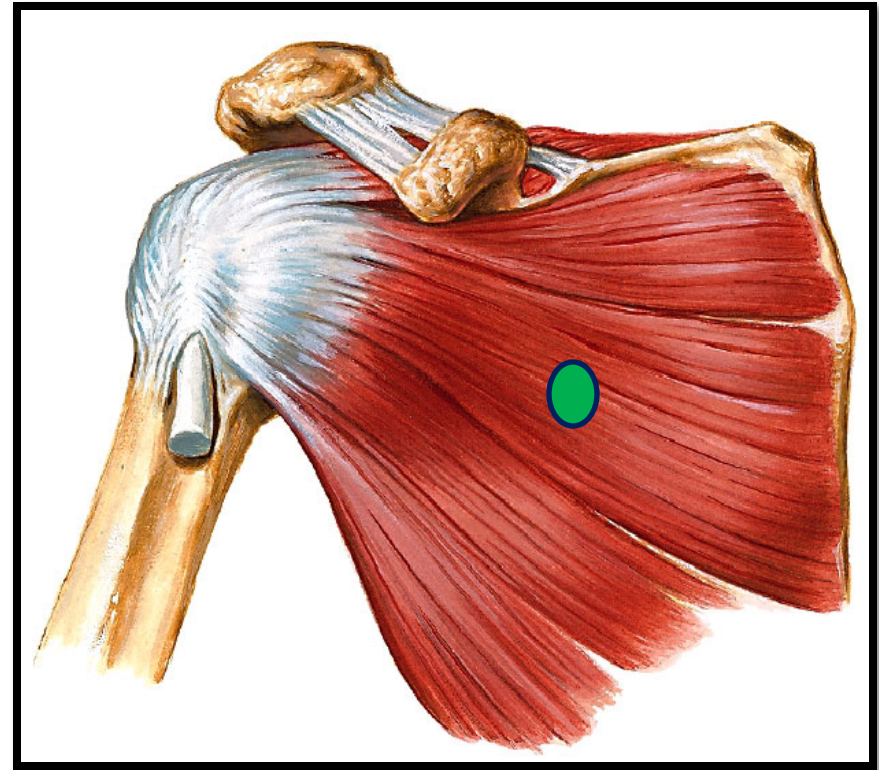
TERES MAJOR

- ❑ **Origin:** lateral border of scapula.
- ❑ **Insertion:** medial lip of bicipital groove of humerus (with *latissimus dorsi* & *pectoralis major*).
- ❑ **Nerve supply:** lower subscapular nerve.
- ❑ **Actions:** extension, adduction & medial rotation of humerus (as *action of latissimus dorsi*).



SUBSCAPULARIS

- ❑ **Origin:** subscapular fossa.
- ❑ **Insertion:** lesser tuberosity of humerus.
- ❑ **Nerve supply:** upper & lower subscapular nerves.
- ❑ **Action:** medial rotation of humerus.



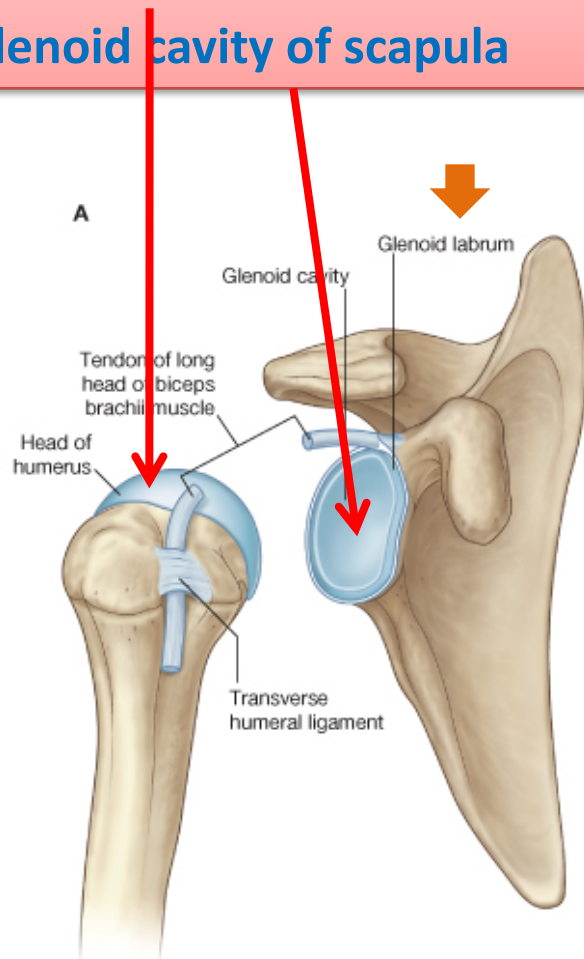
SHOULDER JOINT

□ TYPE:

Synovial, multiaxial (ball & socket)

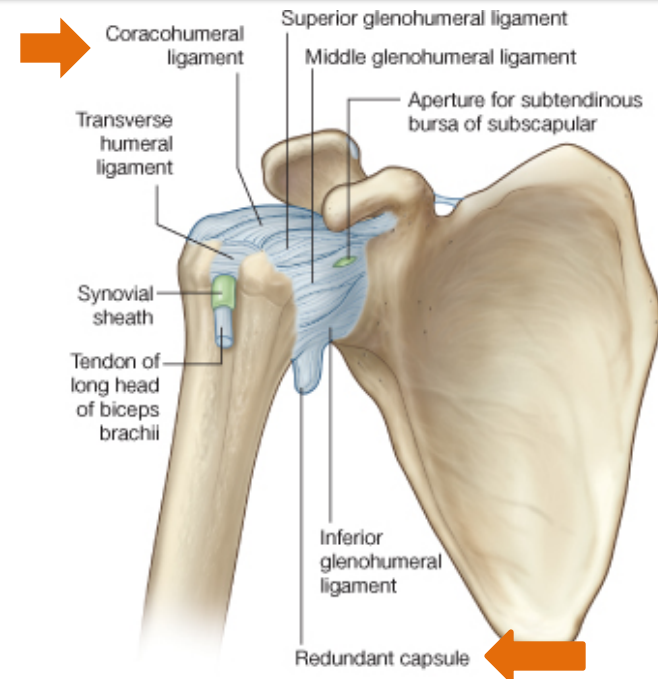
□ ARTICULAR SURFACES:

1. Head of humerus
2. Glenoid cavity of scapula



□ STABILITY: (NOT STABLE) ?

1. Head of humerus is 3 times larger than glenoid cavity
2. Capsule is redundant.
3. Few ligamentous support: glenoid labrum, coracohumeral
4. **Main Support:** muscles around the joint (**ROTATOR CUFF**)
5. Wide range of movement



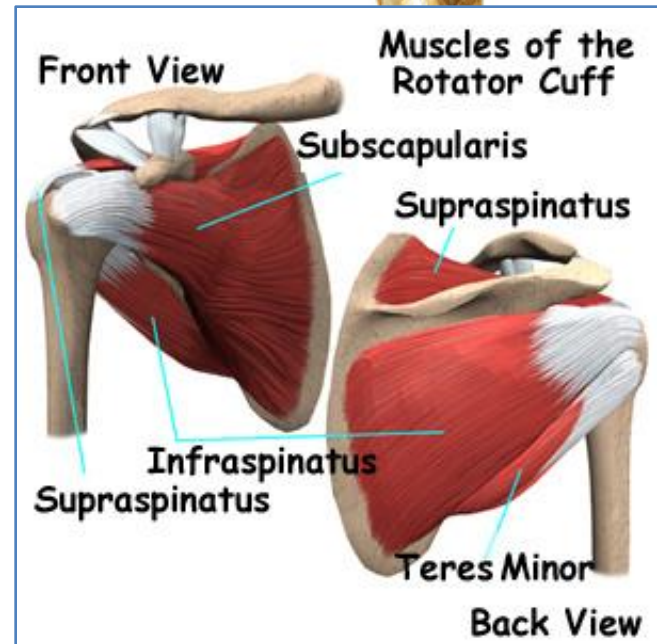
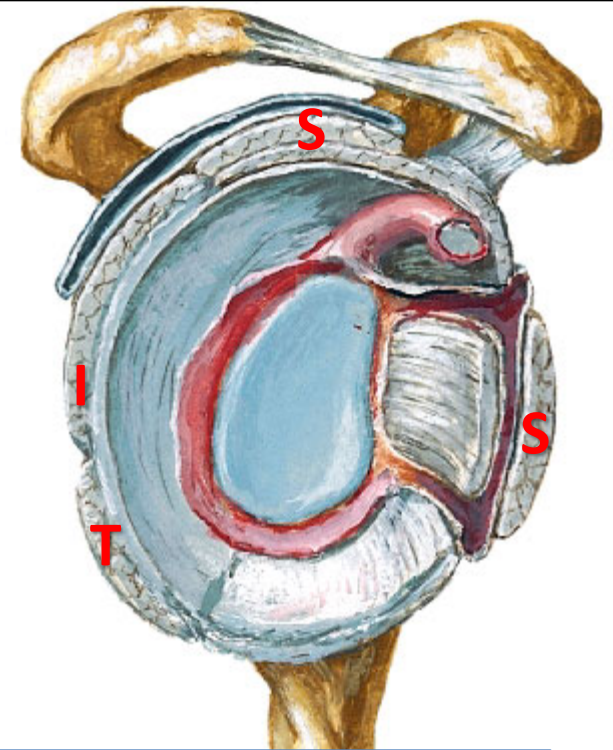
ROTATOR CUFF

❑ A **tendinous** cuff around the shoulder joint covering its **Anterior, Posterior and Superior** aspects.

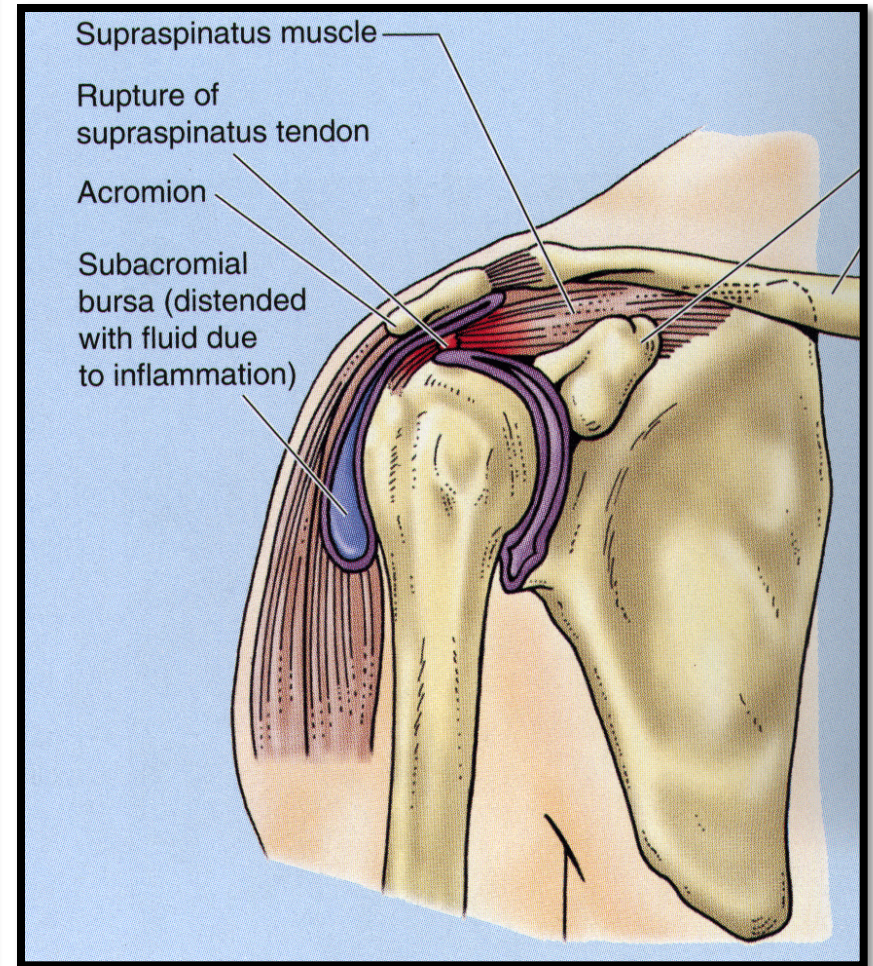
❑ The cuff is **deficient Inferiorly** and this is the site of potential weakness.

❑ It is formed of **4 muscles: *Supraspinatus, Infraspinatus, Teres minor & Subscapularis (SITS)***.

❑ The **tone of these muscles help in stabilizing the shoulder joint.**

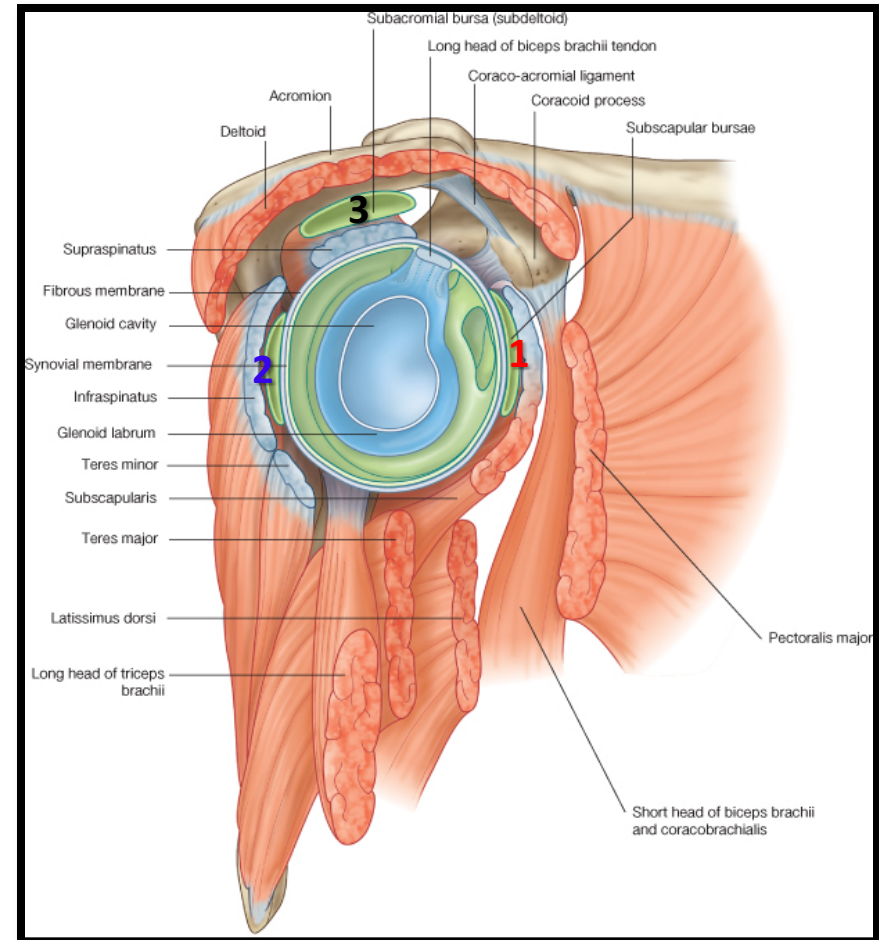


- ❑ Rotator cuff can be **damaged** due to **trauma** (during playing baseball) or **disease** (in older individuals).
- ❑ Trauma can tear or rupture one or more tendon (s) forming the cuff. Patients with rotator injury will present with **pain, shoulder instability, and limited range of motion.**
- ❑ Supraspinatus tendon is the most common site of rotator cuff injury.

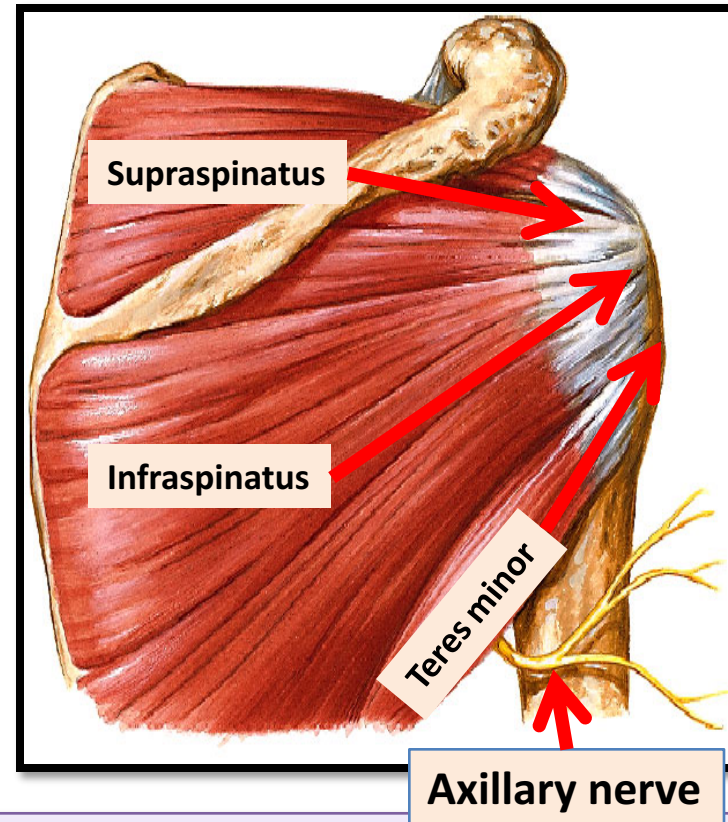
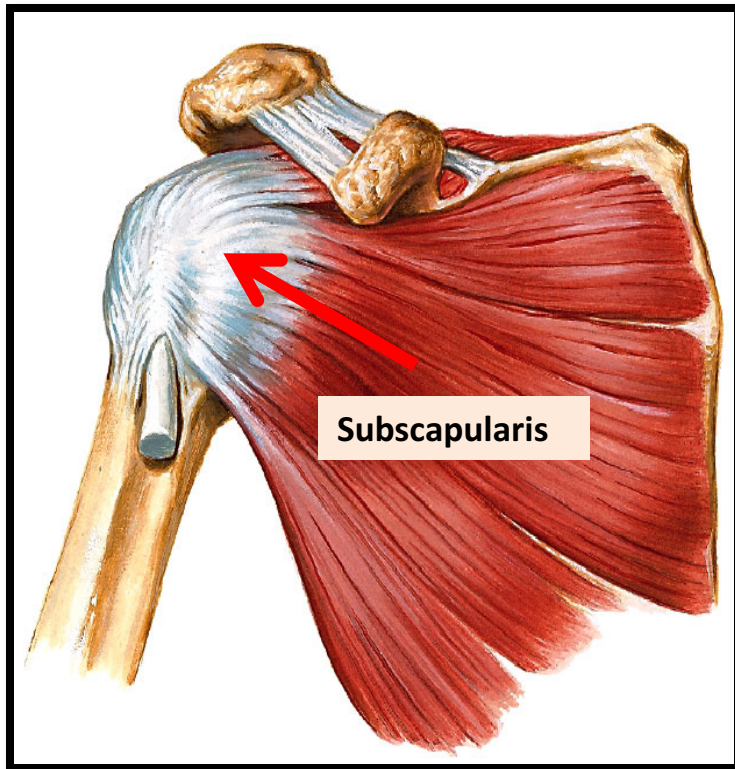


BURSAE IN RELATION TO SHOULDER JOINT

- ❑ They **reduce friction** between tendons, joint capsule & bone.
 - ❑ They are liable to be **inflamed** following injury of rotator cuff muscles.
1. **Subscapularis bursa:** between subscapularis tendon & capsule.
 2. **Infraspinatus bursa:** between infraspinatus tendon & capsule.
 3. **Subacromial bursa:** between deltoid, supraspinatus and capsule.

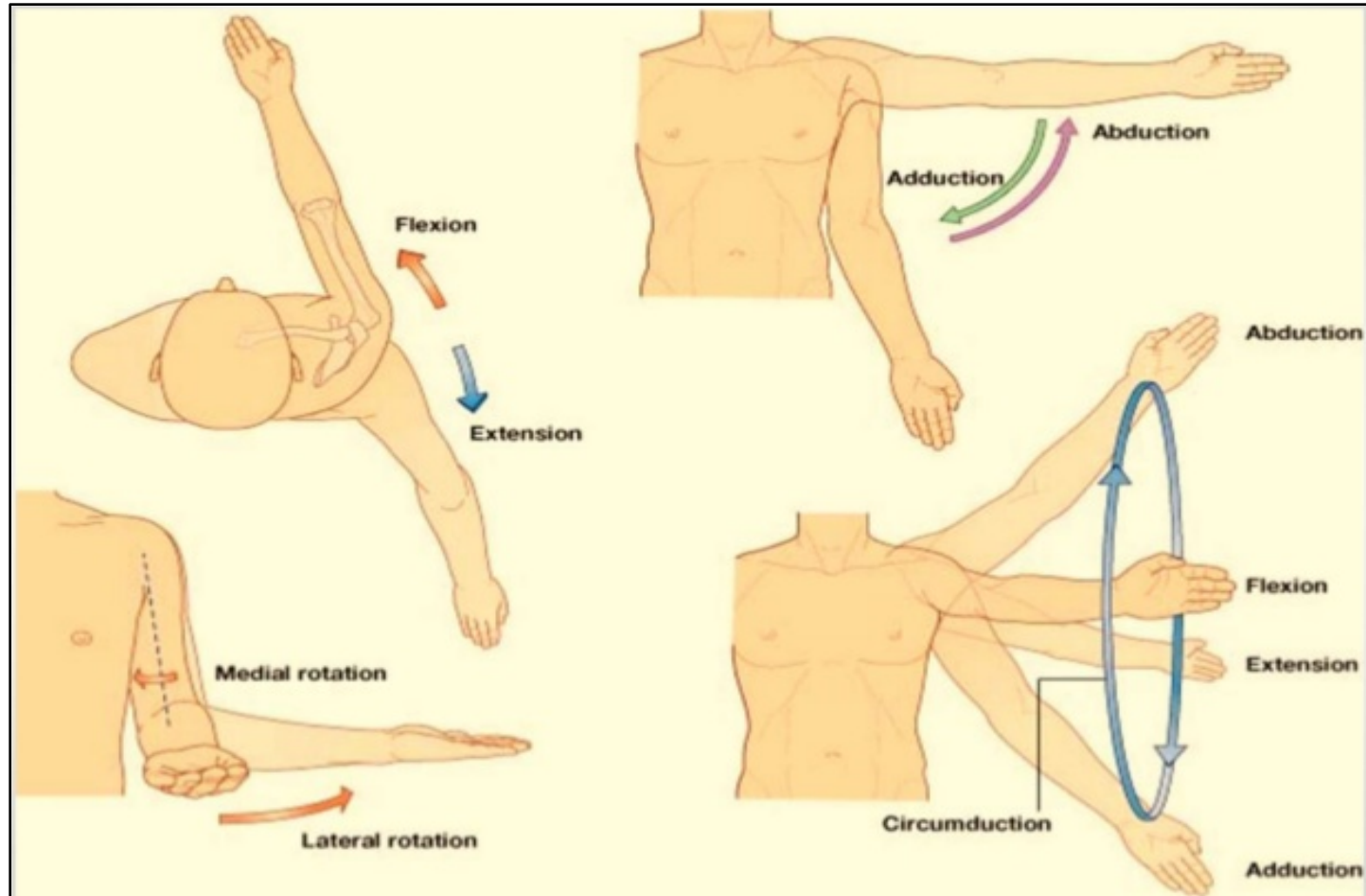


RELATIONS OF SHOULDER JOINT



- ❑ **ANTERIOR:** subscapularis
- ❑ **POSTERIOR:** infraspinatus, teres minor
- ❑ **SUPERIOR:** supraspinatus
- ❑ **INFERIOR:** axillary nerve

MOVEMENTS OF SHOULDER JOINT



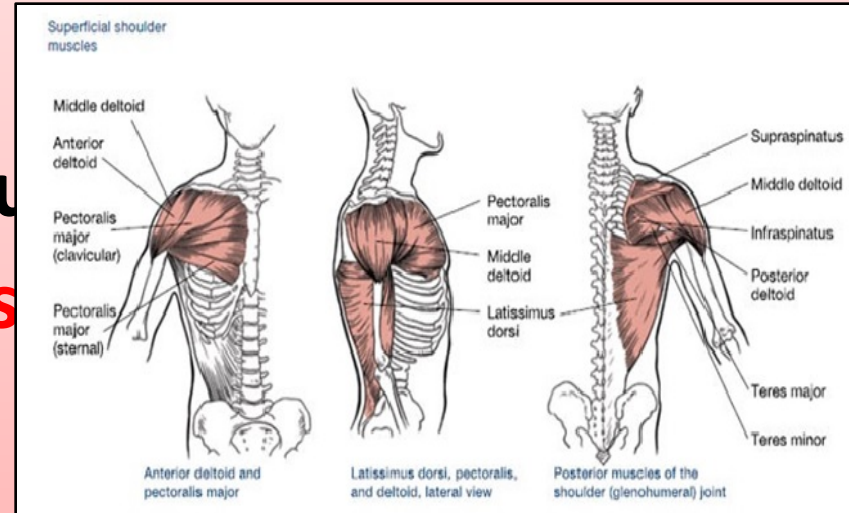
MOVEMENTS OF SHOULDER JOINT

□ FLEXION:

1. Anterior fibers of deltoid
2. Pectoralis major
3. Coracobrachialis (muscle)
4. Short head of biceps

□ EXTENSION:

1. Posterior fibers of deltoid
2. Latissimus dorsi
3. Teres major



MOVEMENTS OF SHOULDER JOINT

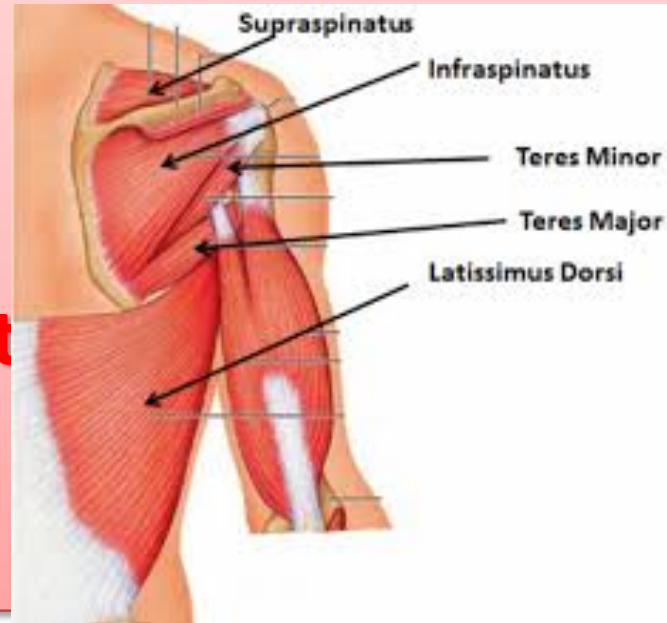ABDUCTION:

1. From 0° - 15°: Supraspinatus
2. From 15° - 90 °: Middle fibers of deltoid

ADDUCTION:

1. Pectoralis major
2. Latissimus dorsi
3. Teres major

← Insert



ve

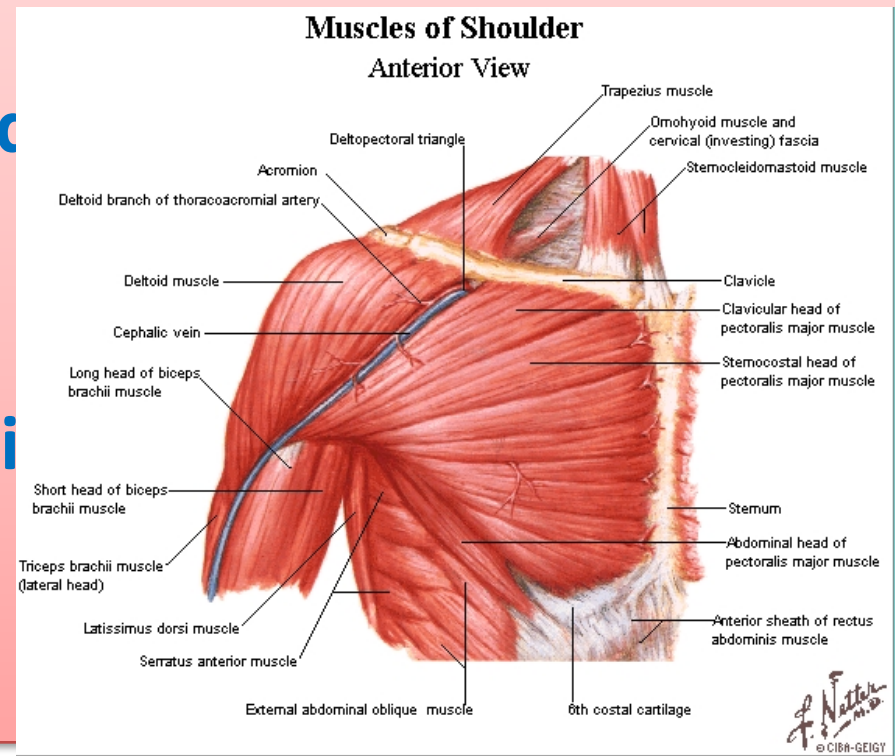
MOVEMENTS OF SHOULDER JOINT

MEDIAL ROTATION:

1. Pectoralis major
 2. Latissimus dorsi
 3. Teres major
 4. Anterior fibers of deltoid
 5. Subscapularis
- Inserted in bicipital groove

LATERAL ROTATION:

1. Posterior fibers of deltoid
2. Infraspinatus
3. Teres minor



SUMMARY

MUSCLES OF SHOULDER REGION:

1. Origin: scapula.
2. Insertion: humerus.
3. Action: move humerus (**SHOULDER JOINT**)
4. Nerve supply: anterior rami of spinal nerves through brachial plexus.

ROTATOR CUFF: 4 muscles in scapular region surround and help in stabilization of shoulder joint (*supraspinatus, infraspinatus, teres minor, subscapularis*).

SUMMARY

□ Shoulder joint:

1. **Type:** synovial, ball & socket
2. **Articular surfaces:** head of humerus & glenoid cavity of scapula
3. **Stability:** depends on rotator cuff
4. **Relations:** rotator cuff and axillary nerve
5. **Movements:** flexion, extension, abduction, adduction, medial & lateral rotation

QUESTION 1

Which one of the following muscles is inserted into the lesser tuberosity of the humerus?

1. Subscapularis




2. Deltoid

3. Teres major

4. Infraspinatus


QUESTION 2

Which one of the following muscles is part of the rotator cuff?

1. Subscapularis. 
2. Deltoid.
3. Teres major.
4. Rhomboid minor.

QUESTION 3

Regarding the shoulder joint, which one of the following statements is correct?

1. It is a stable joint.
2. It is a synovial joint of hinge variety.
3. Latissimus dorsi muscle adducts shoulder joint. 
4. Downward dislocation of shoulder joint may cause injury to the radial nerve.

THANK YOU