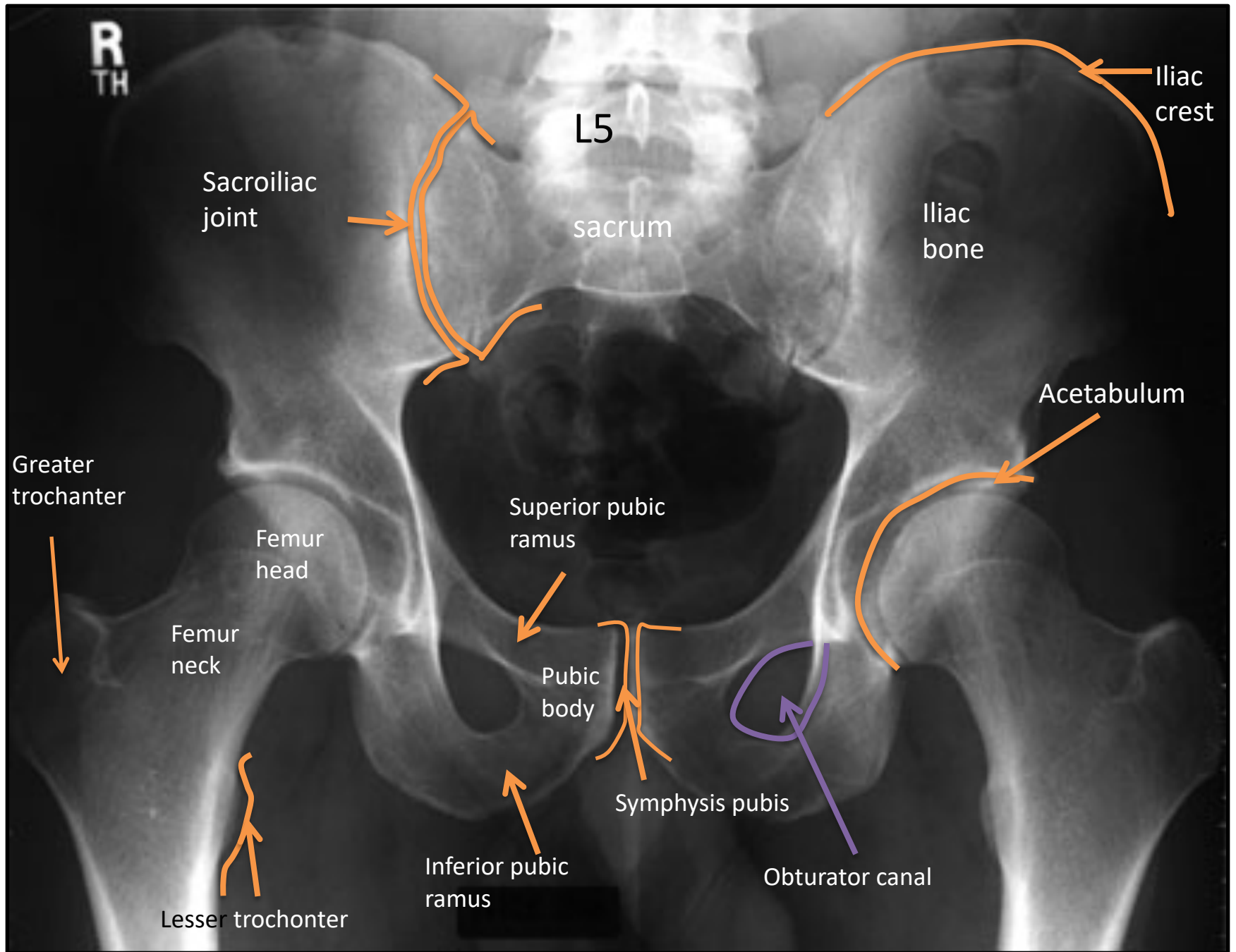


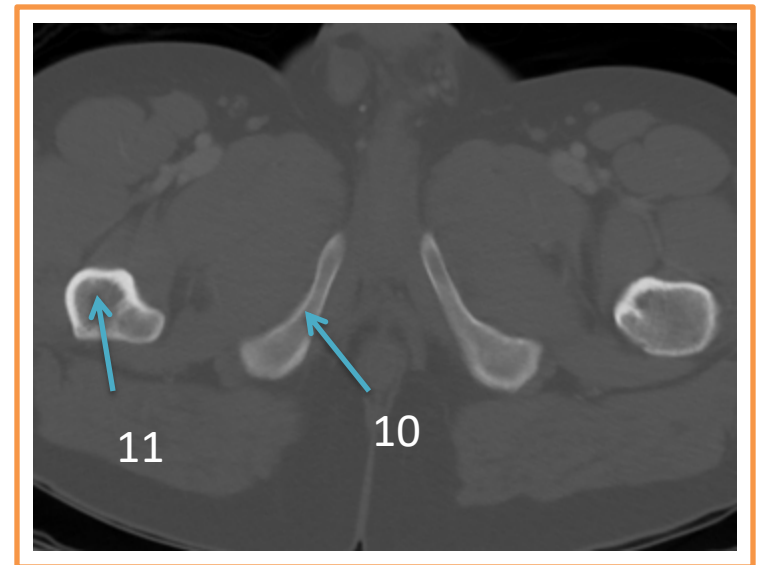
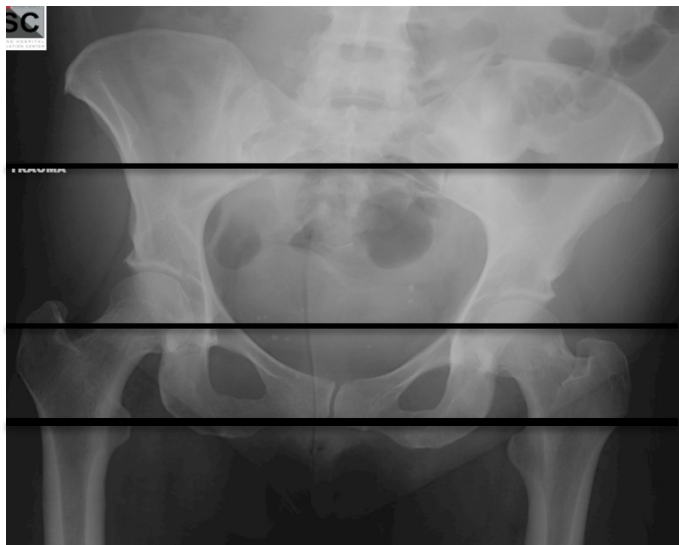
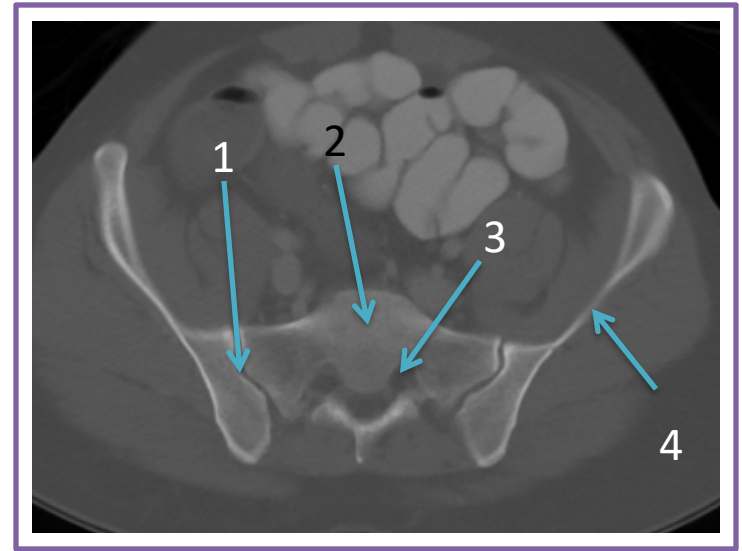
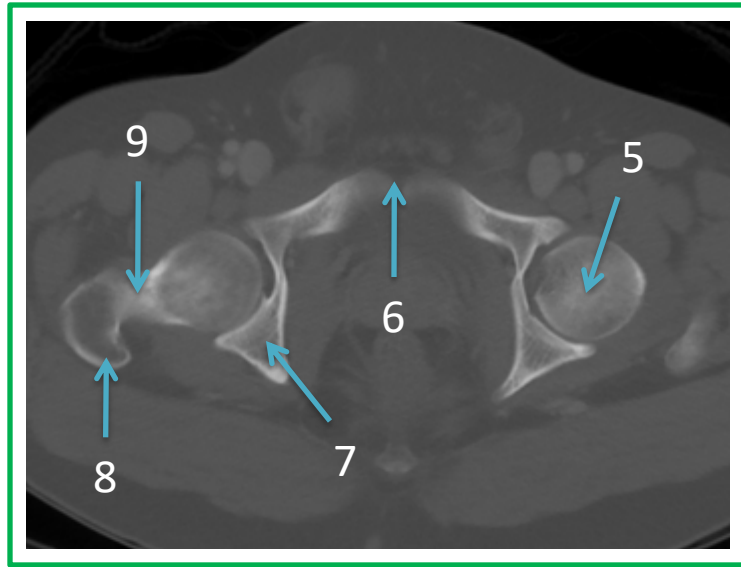
LOWER LIMB RADIOLOGY ANATOMY

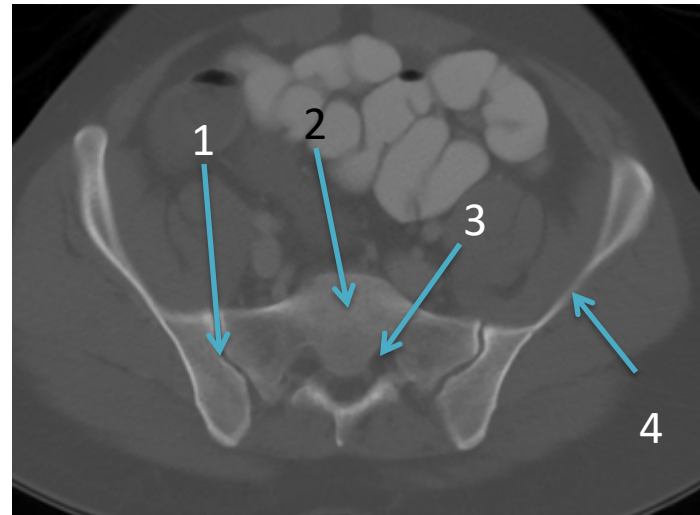
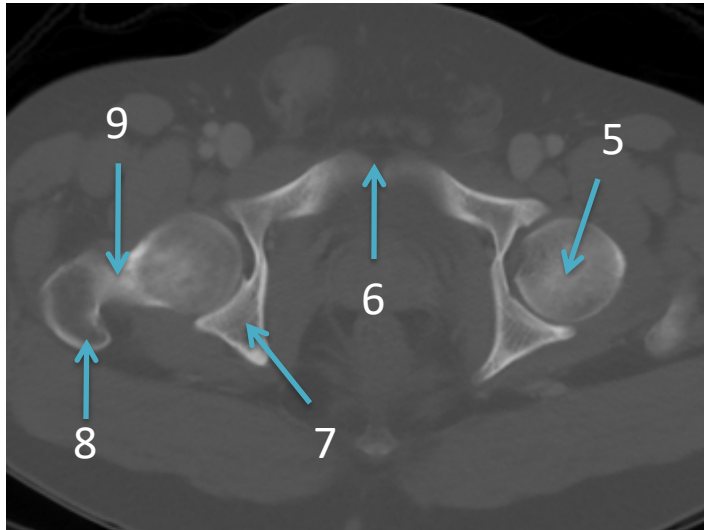
Practical (3)

Radiology

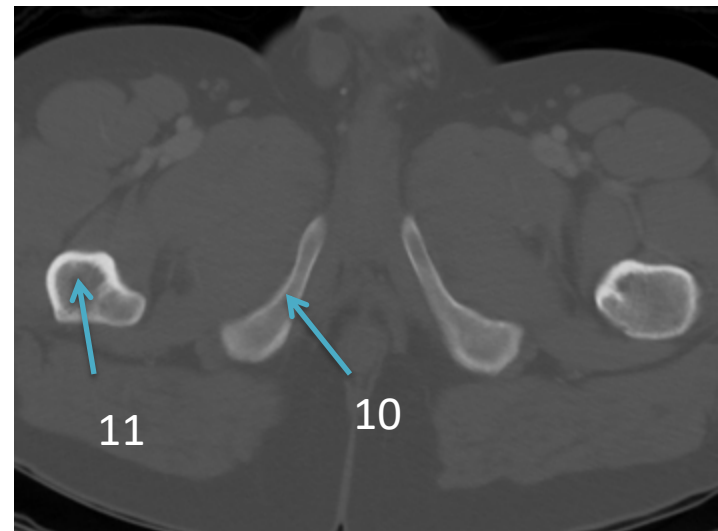
PELVIS

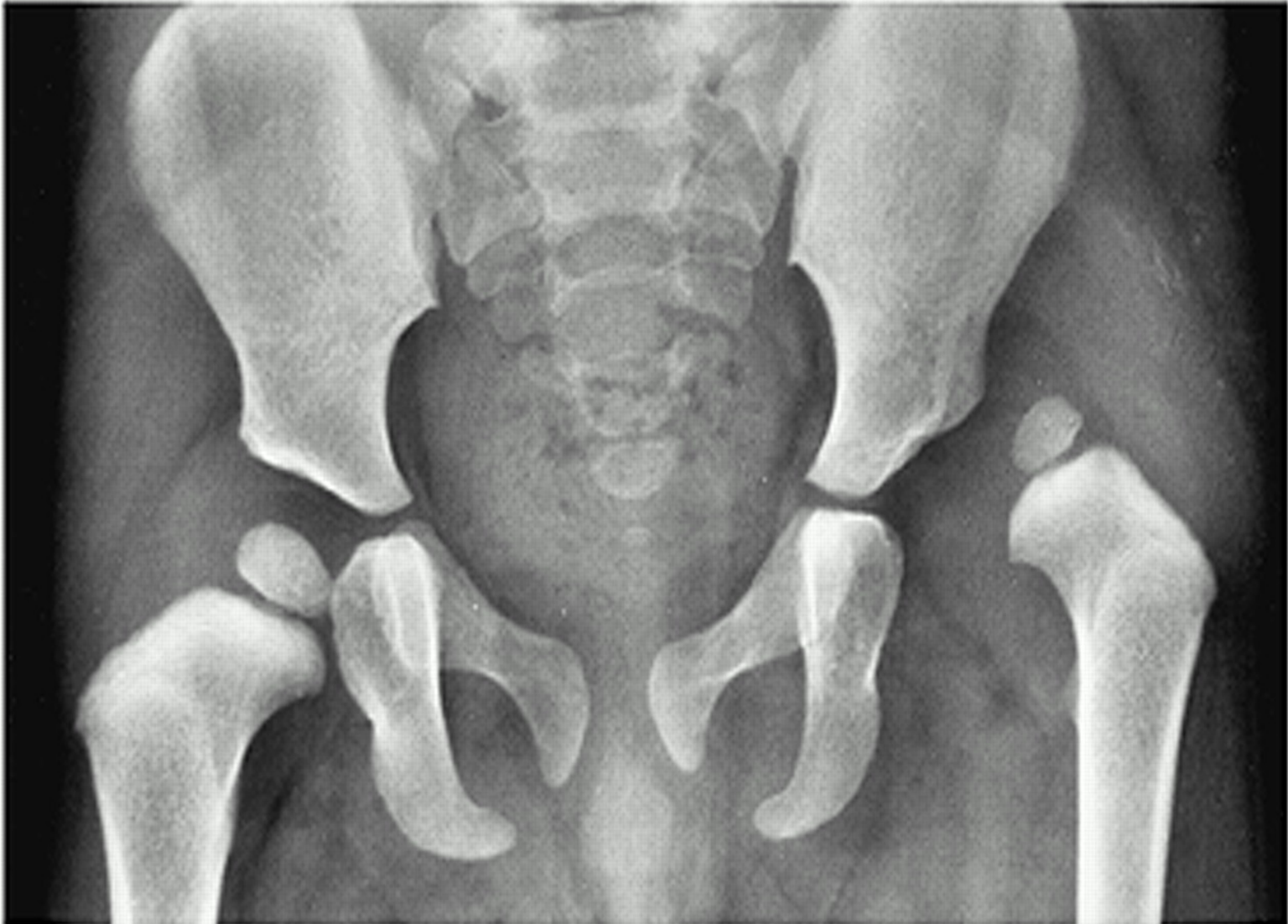





- 1- Sacroiliac joint
- 2- Sacrum
- 3- Sacral neural foramen
- 4- Iliac bone
- 5- Femur head
- 6- Symphysis pubis
- 7- Ischium
- 8- Greater trochanter
- 9- Femur neck
- 10- Pubic bone (inferior ramus)
- 11-Femur shaft

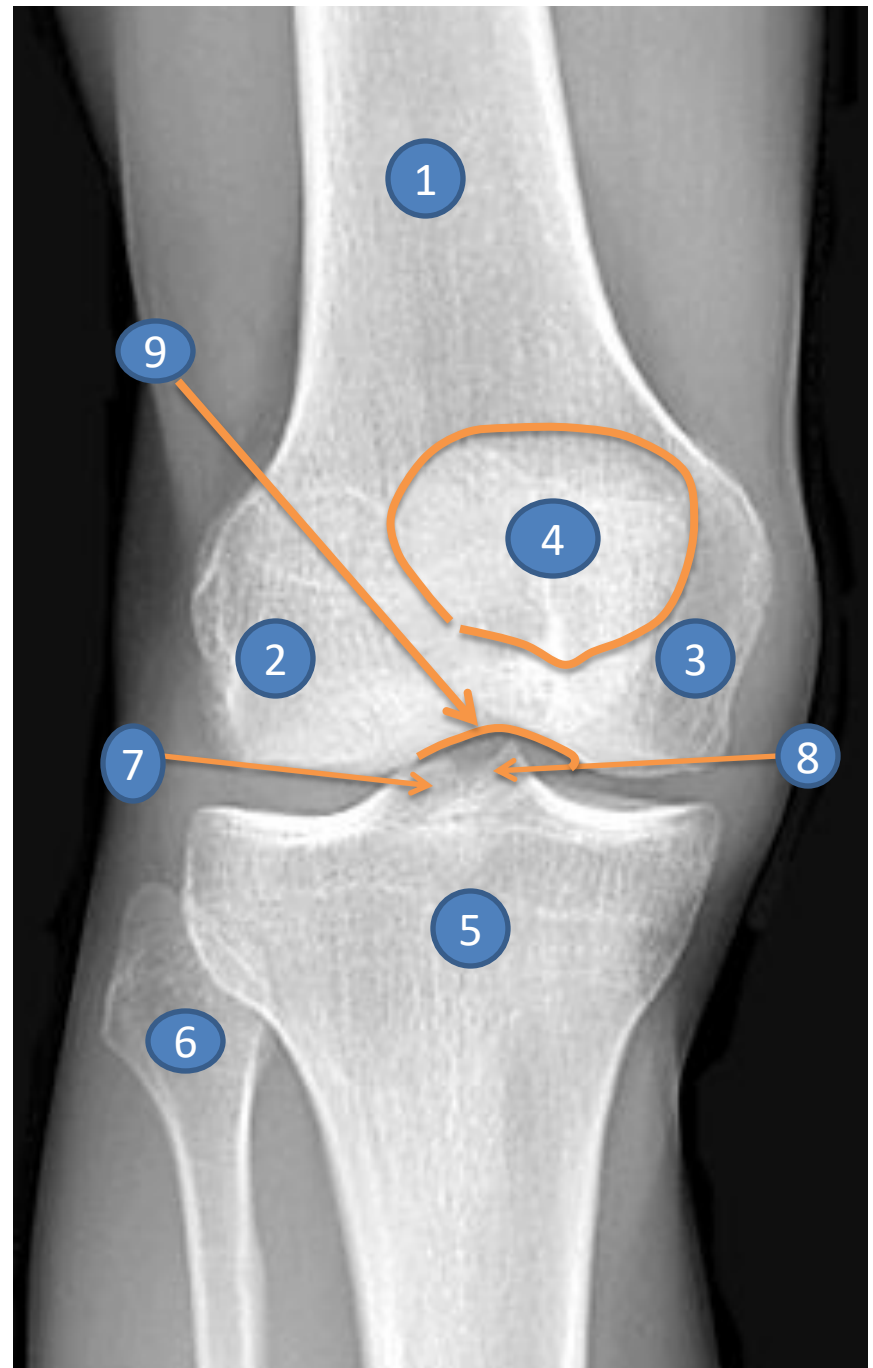




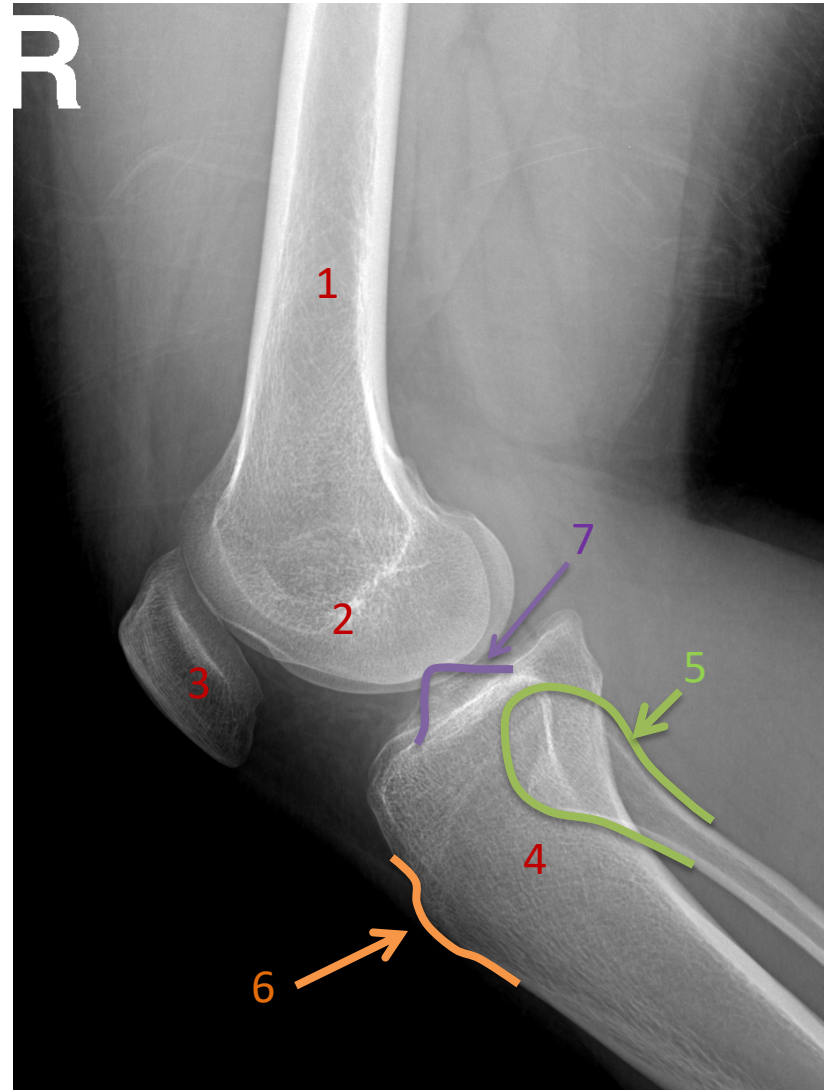
CONGENITAL HIP DISLOCATION

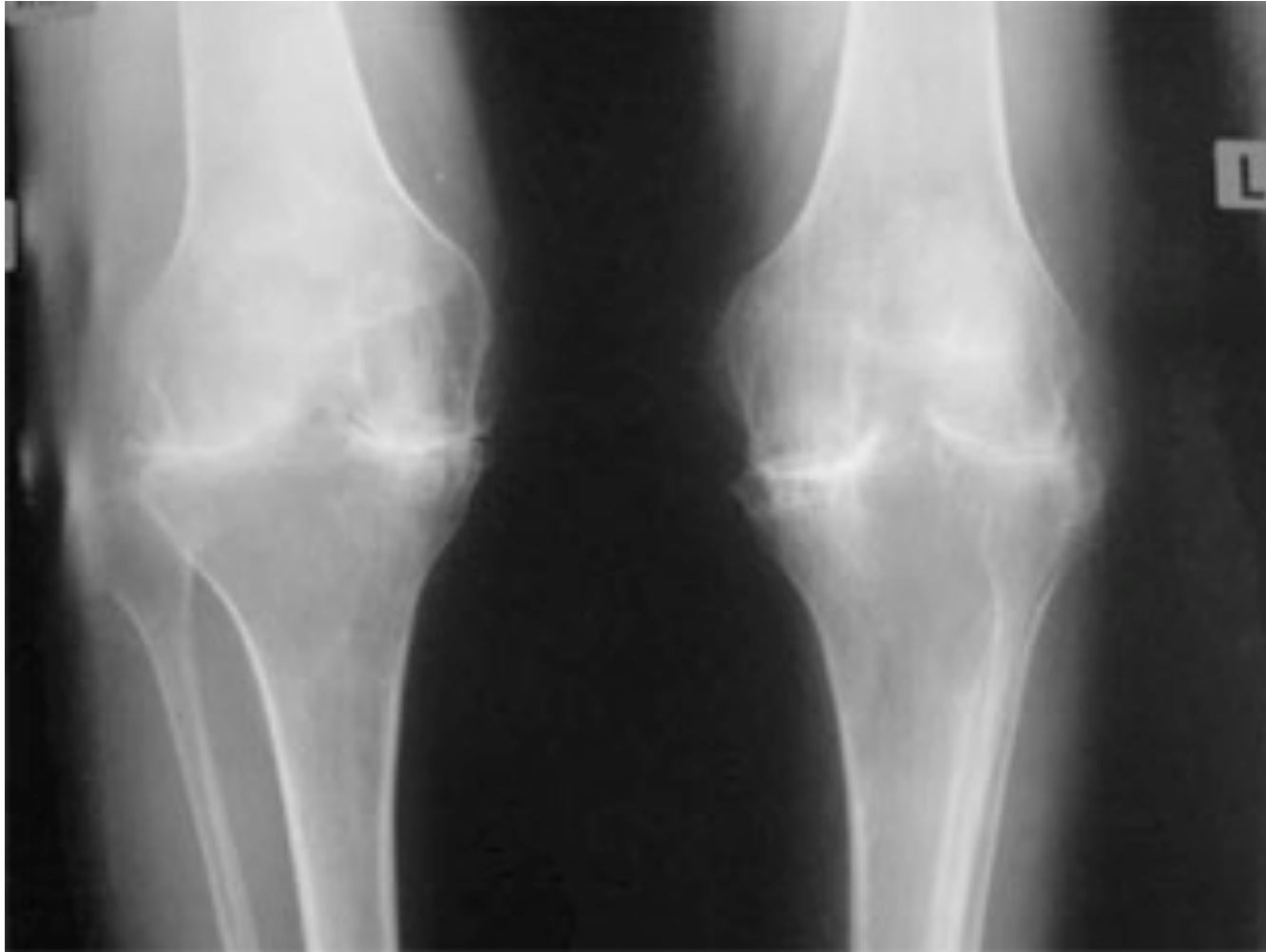
KNEE

- 1- Femur
- 2- Lateral condyle
- 3- Medial condyle
- 4- Patella
- 5- Tibia
- 6- Fibula
- 7- Lateral tibial spine
- 8- Medial tibial spine
- 9- Intercondyle notch



- 1-Femur
- 2- Femur condoyle
- 3- Patella
- 4- Tibia
- 5- Fibula
- 6- Tibial teberosity
- 7- Tibial spine

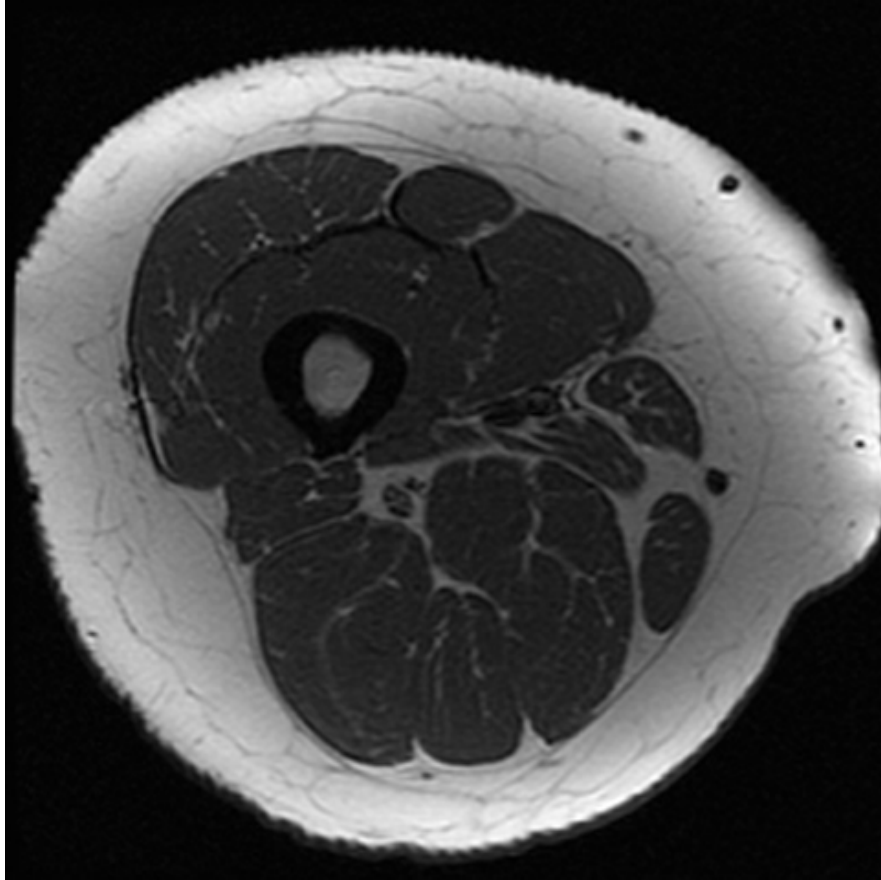




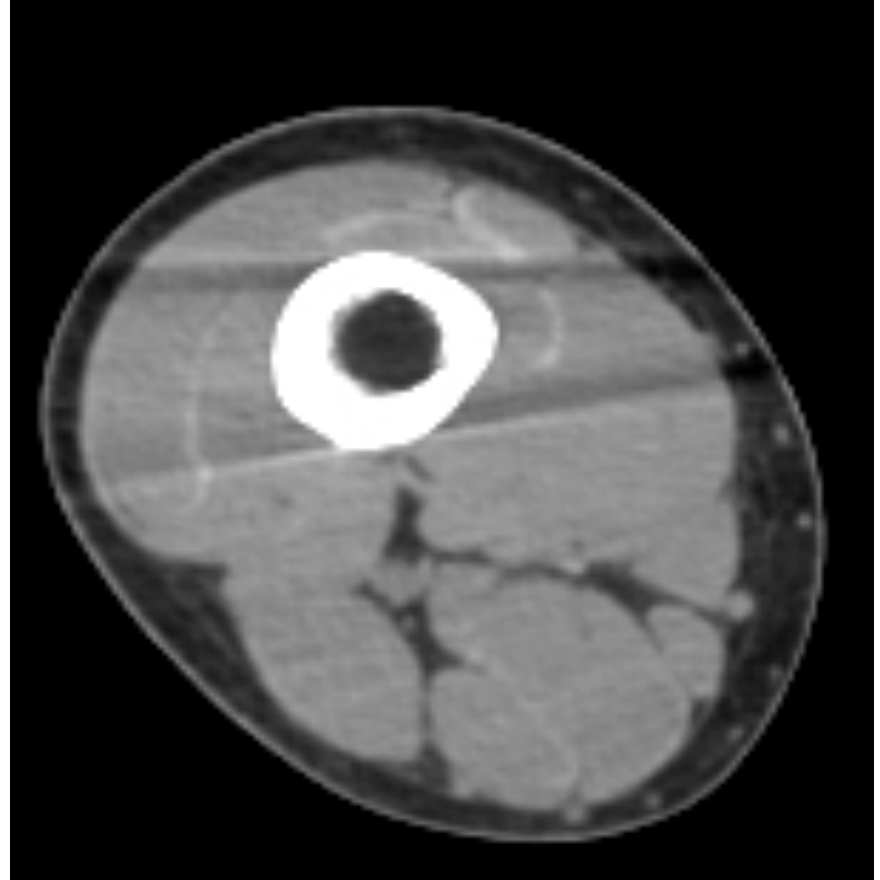SEVERE OSTEOARTHRITIS

THIGH

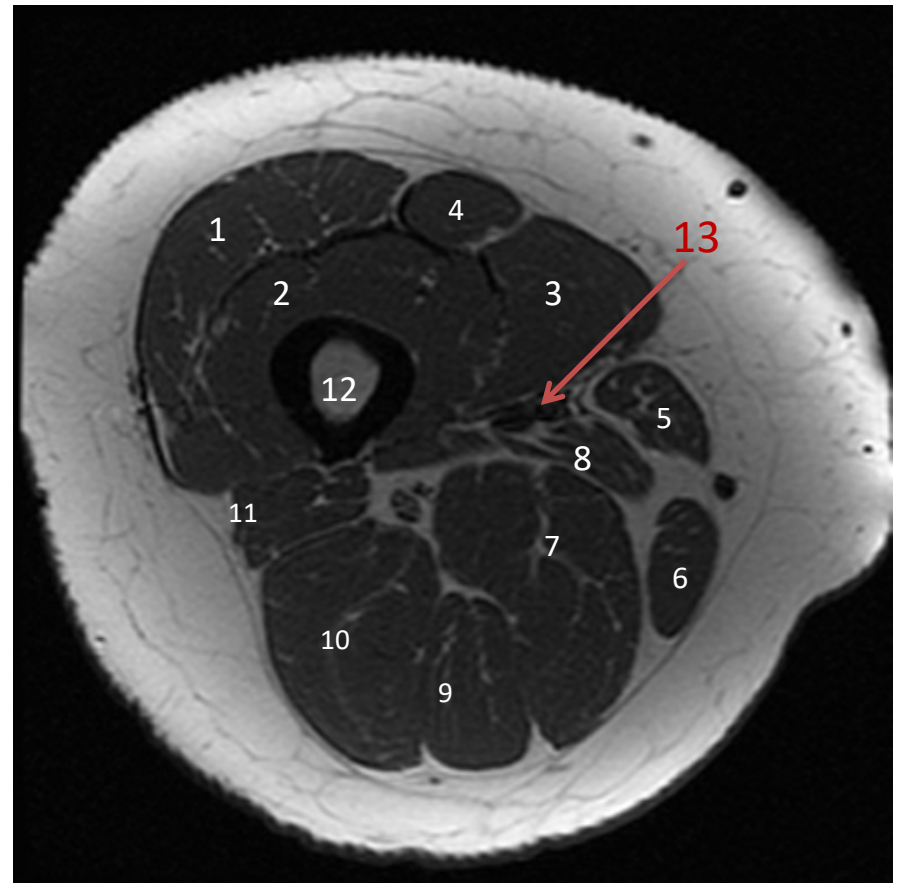
MRI



CT

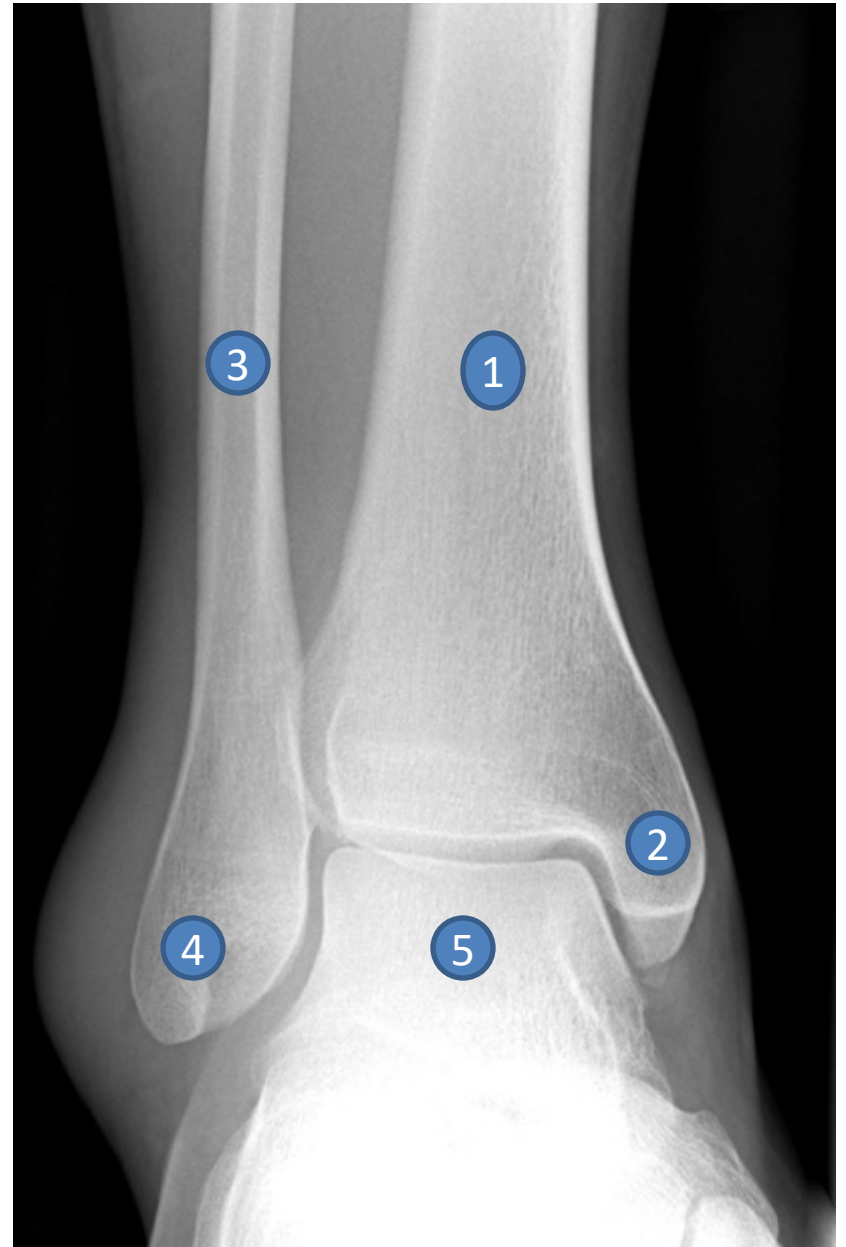


- 1- Vastus lateralis muscle
- 2- Vastus intermedius muscle
- 3- Vastus medialis muscle
- 4- Rectus femoris muscle
- 5- Sartorius muscle
- 6- Gracilis muscle
- 7- Adductor magnus muscle
- 8- Adductor longus muscle
- 9- Semimembranosus muscle
- 10- Semitendinosus Muscle
- 11- Biceps femoris muscle
- 12- Femur
- 13- Femoral artery

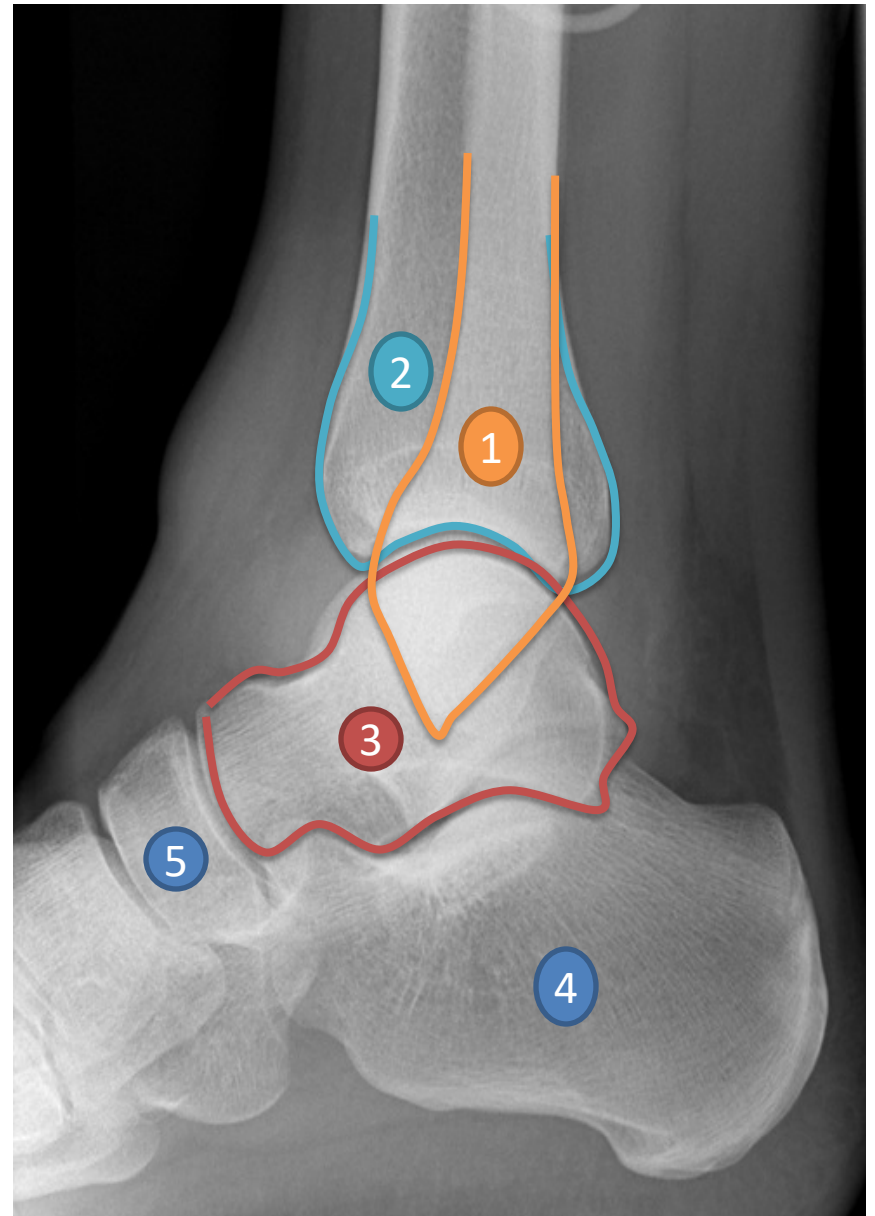


ANKLE

- 1- Tibia**
- 2- Medial malleolus**
- 3- Fibula**
- 4- Lateral malleolus**
- 5- Dome of talus**

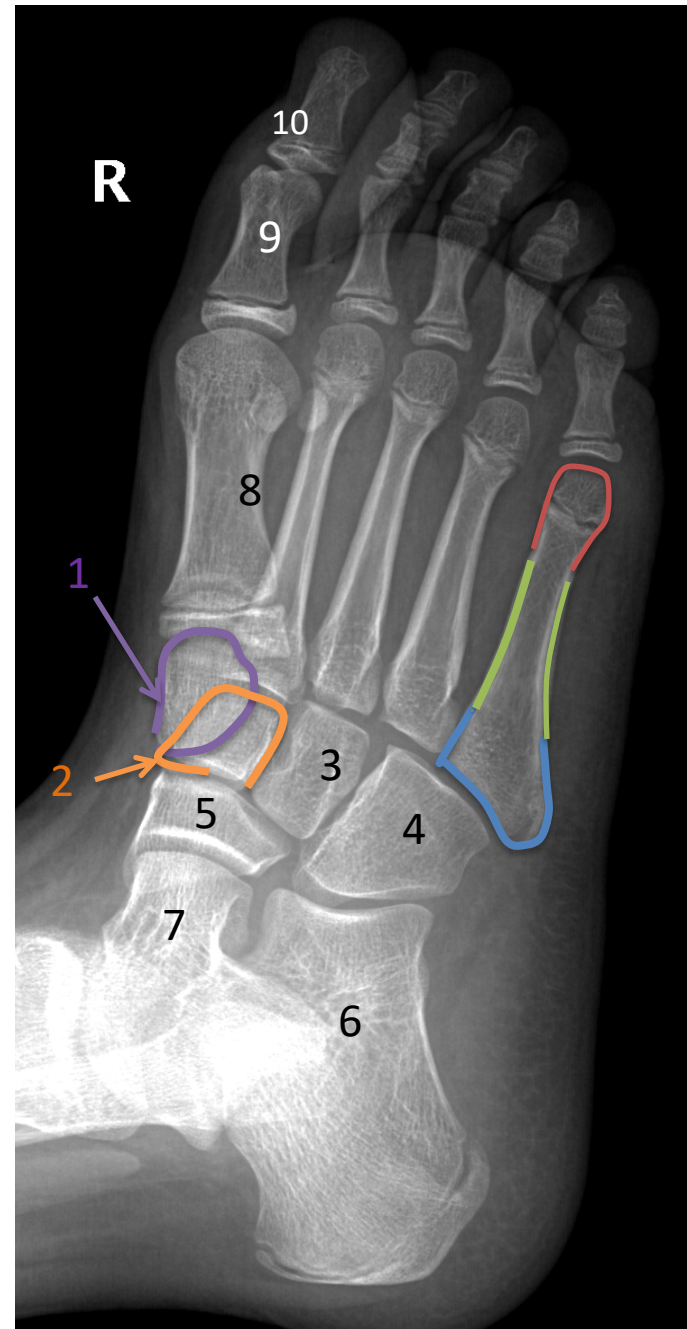


- 1- Fibula
- 2- Tibia
- 3- Talus
- 4- Calcaneus
- 5- Navicular

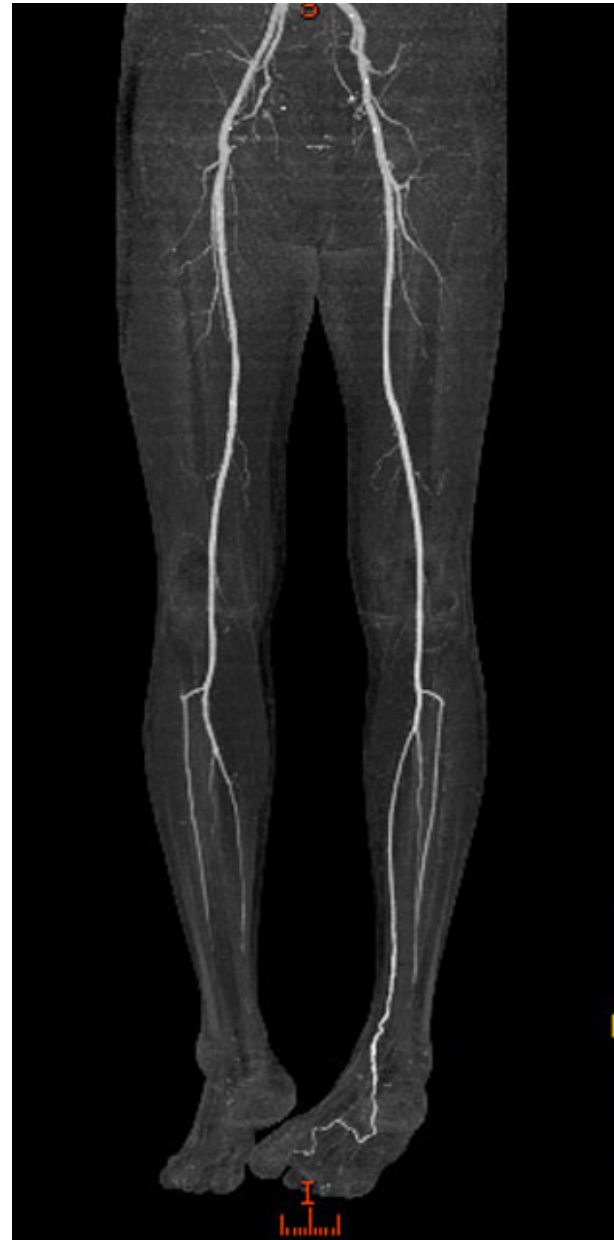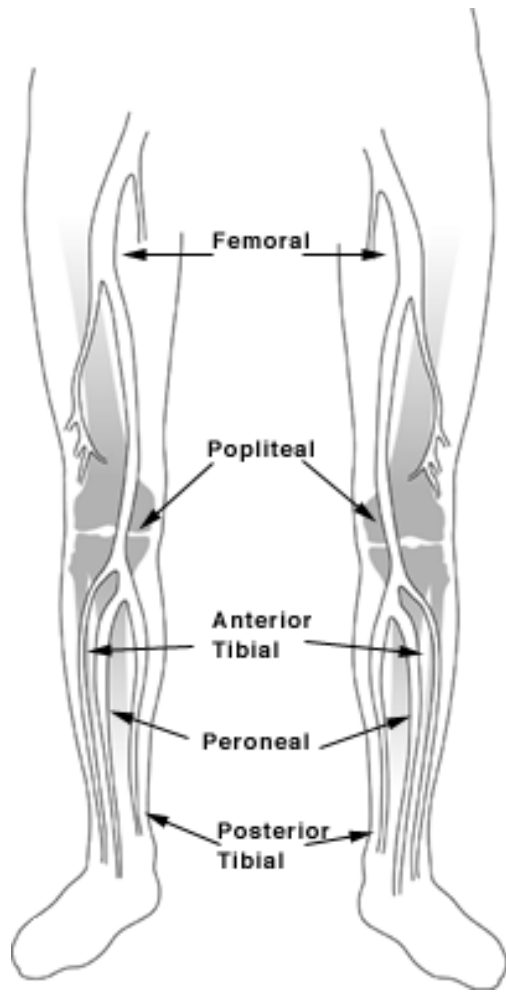


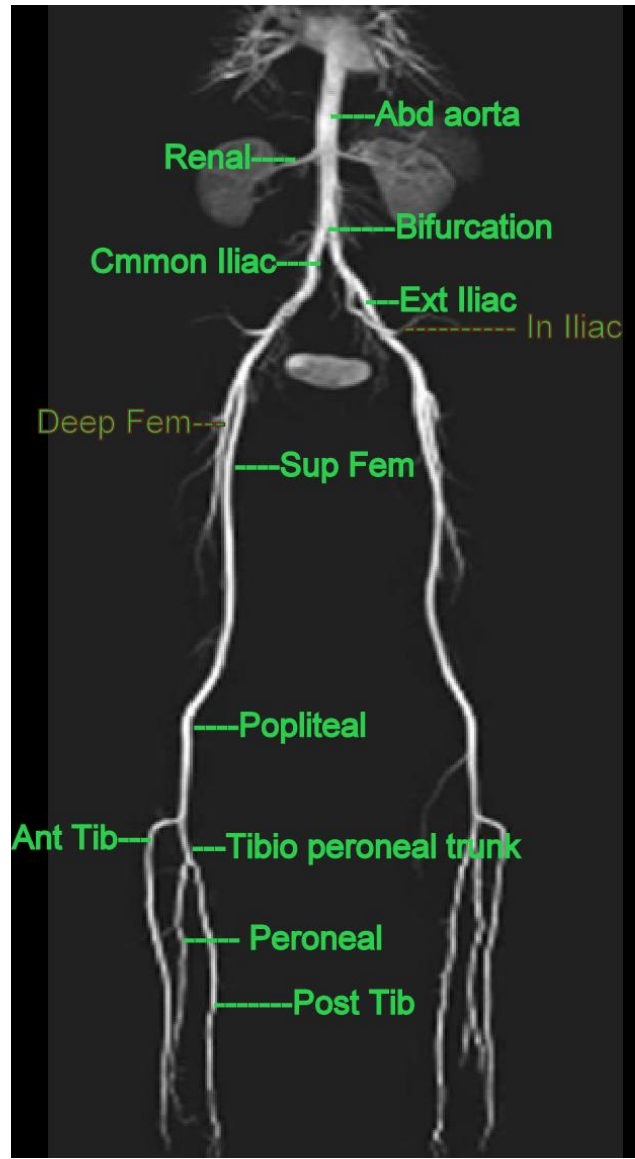
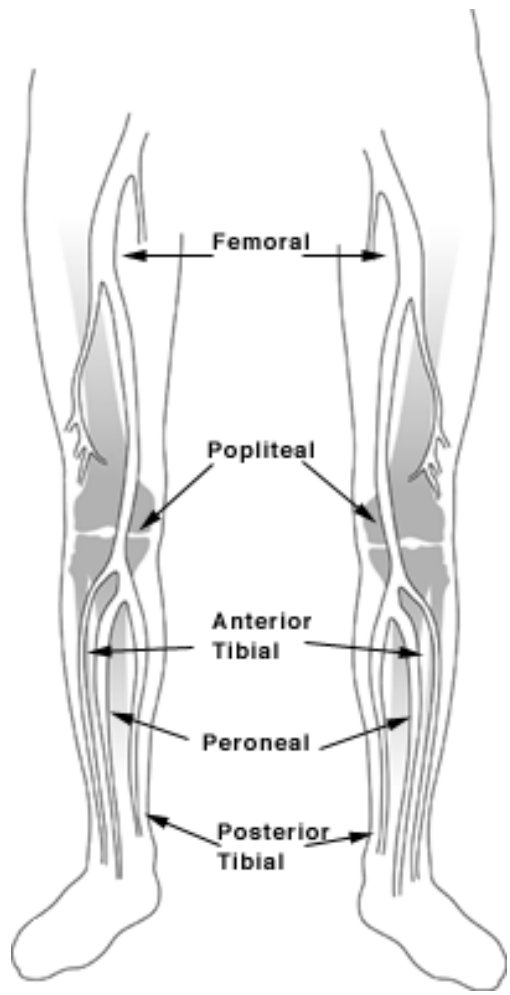
FOOT

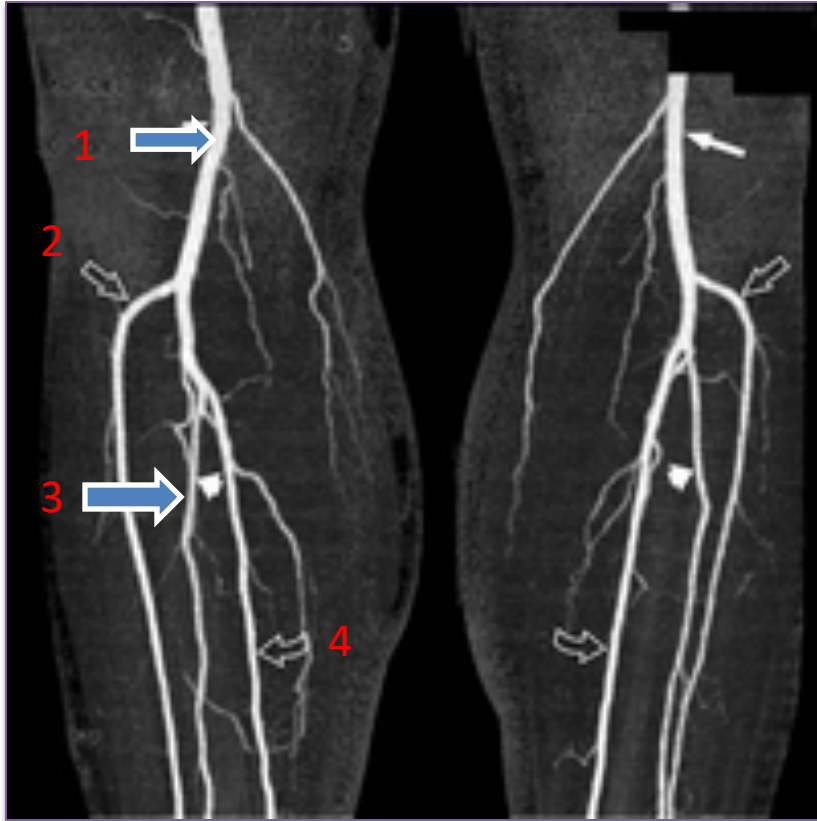
- 1- Medial cuneiform bone
- 2- Intermediate cuneiform bone
- 3- Lateral cuneiform bone
- 4- Cuboid bone
- 5- Navicular bone
- 6- Calcaneal bone
- 7- Talus
- 8- Metatarsal bone (1st toe)
- 9- Proximal phalanx (1st toe)
- 10- Distal phalanx (1st toe)



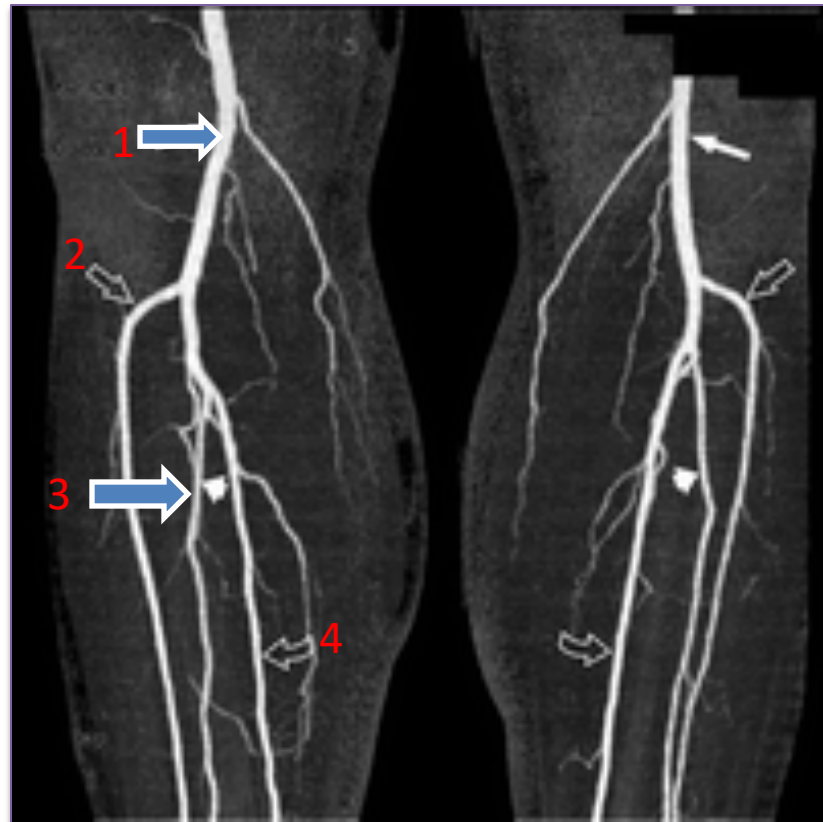LOWER LIMB ARTERIES







- 1- Popliteal artery**
- 2- Anterior tibial artery**
- 3- Peroneal artery**
- 4- Posterior tibial artery**



THE END