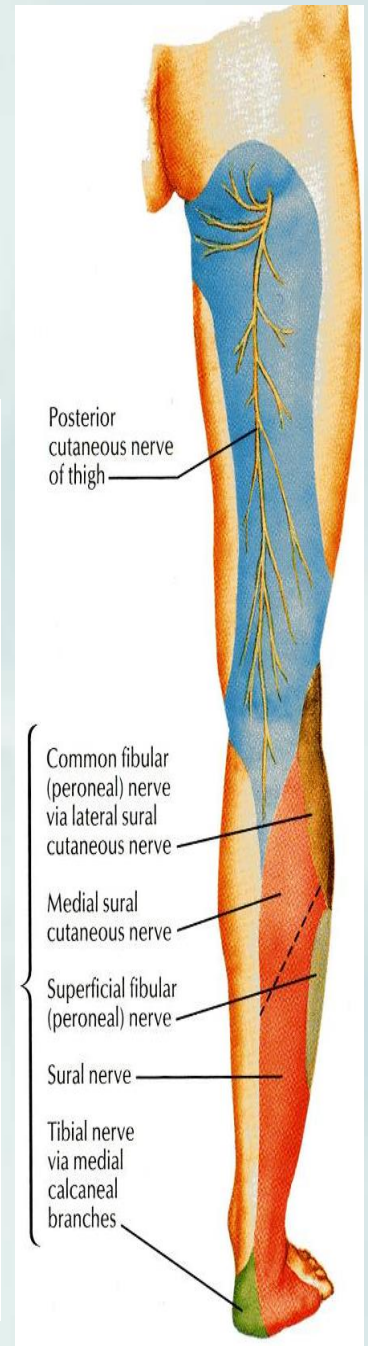
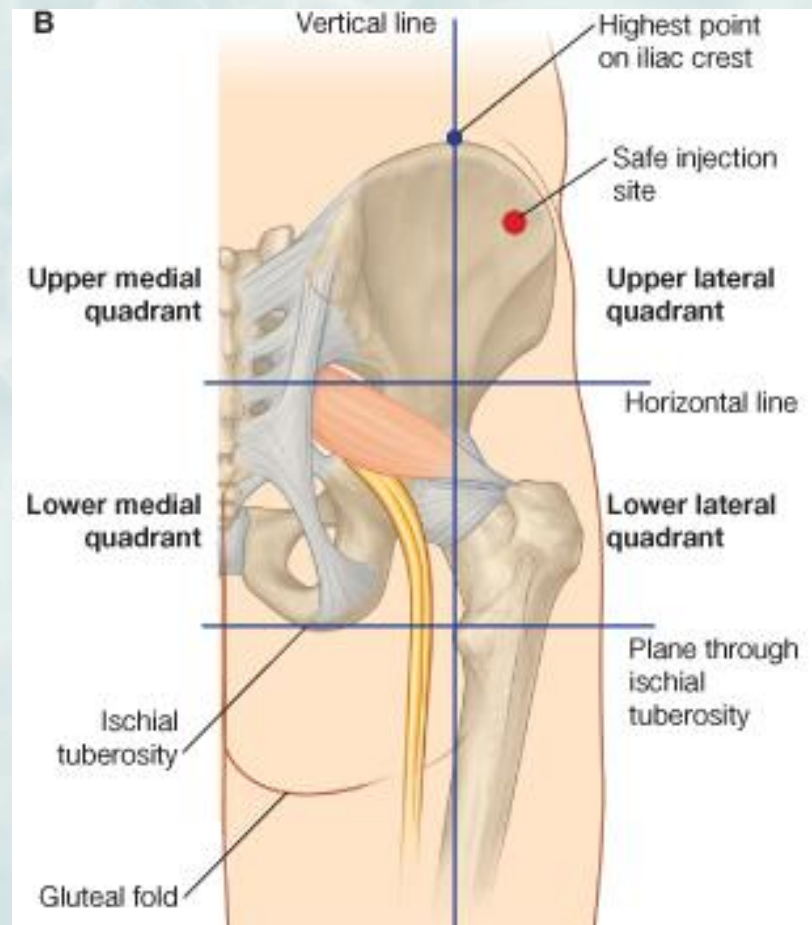


GLUTEAL REGION, BACK OF THIGH



OBJECTIVES

- ❖ By the end of this lecture, you should be able to identify:
- ❖ Contents of the gluteal region:
 - ❖ **3 Glutei muscles:** Gluteus maximus, medius and minimus.
 - ❖ **Other 5 Small muscles:** Piriformis, Obturator internus, Superior gemellus, Inferior gemellus and Quadratus femoris.
- **Nerves & vessels.**
- ❖ Foramina: 1-Greater Sciatic Foramen.
2-Lesser Sciatic Foramen.
- **Back of the thigh: Hamstring muscles.**

CONTENTS

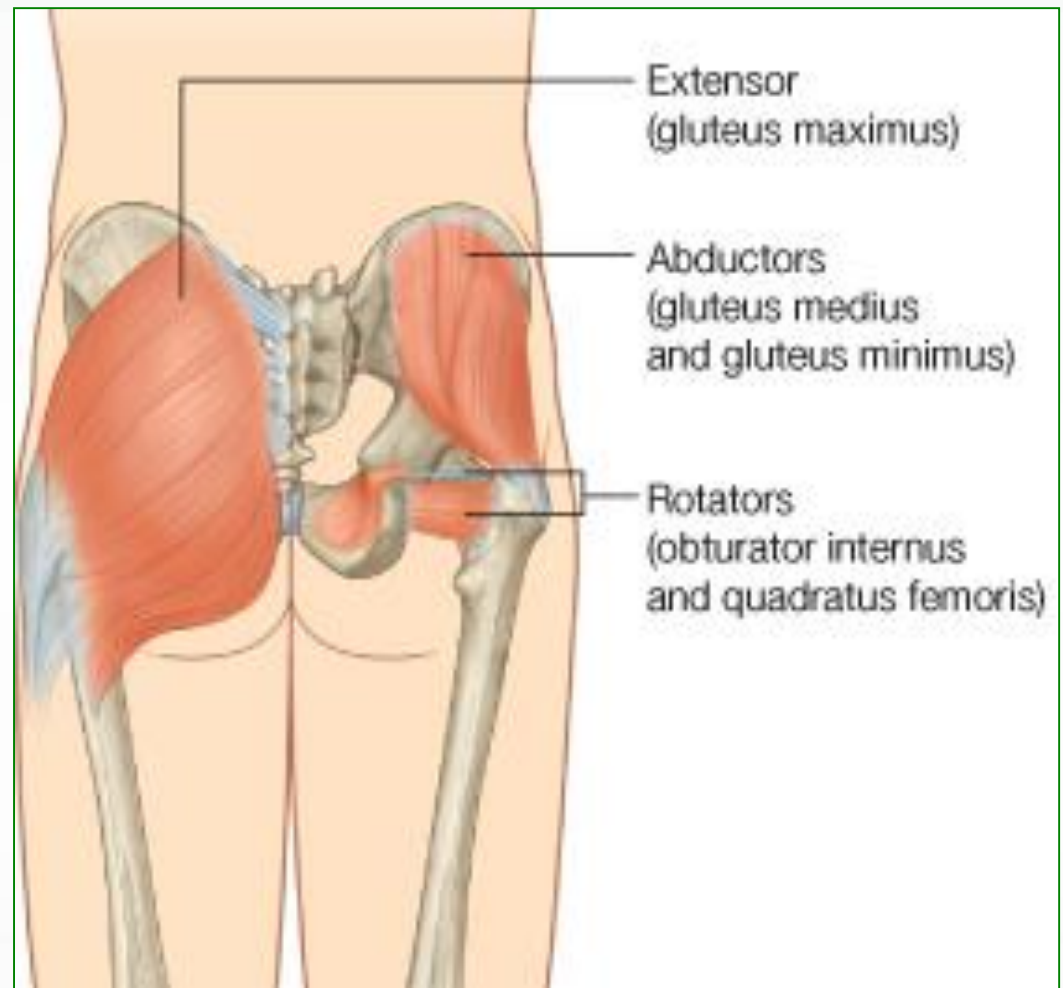
• I - Muscles:

A- GLUTEI:

1. Gluteus maximus.
2. Gluteus medius.
3. Gluteus minimus.

B- GROUP OF SMALL MUSCLES:

1. Piriformis.
2. Obturator internus.
3. Superior gemellus.
4. Inferior gemellus.
5. Quadratus femoris.

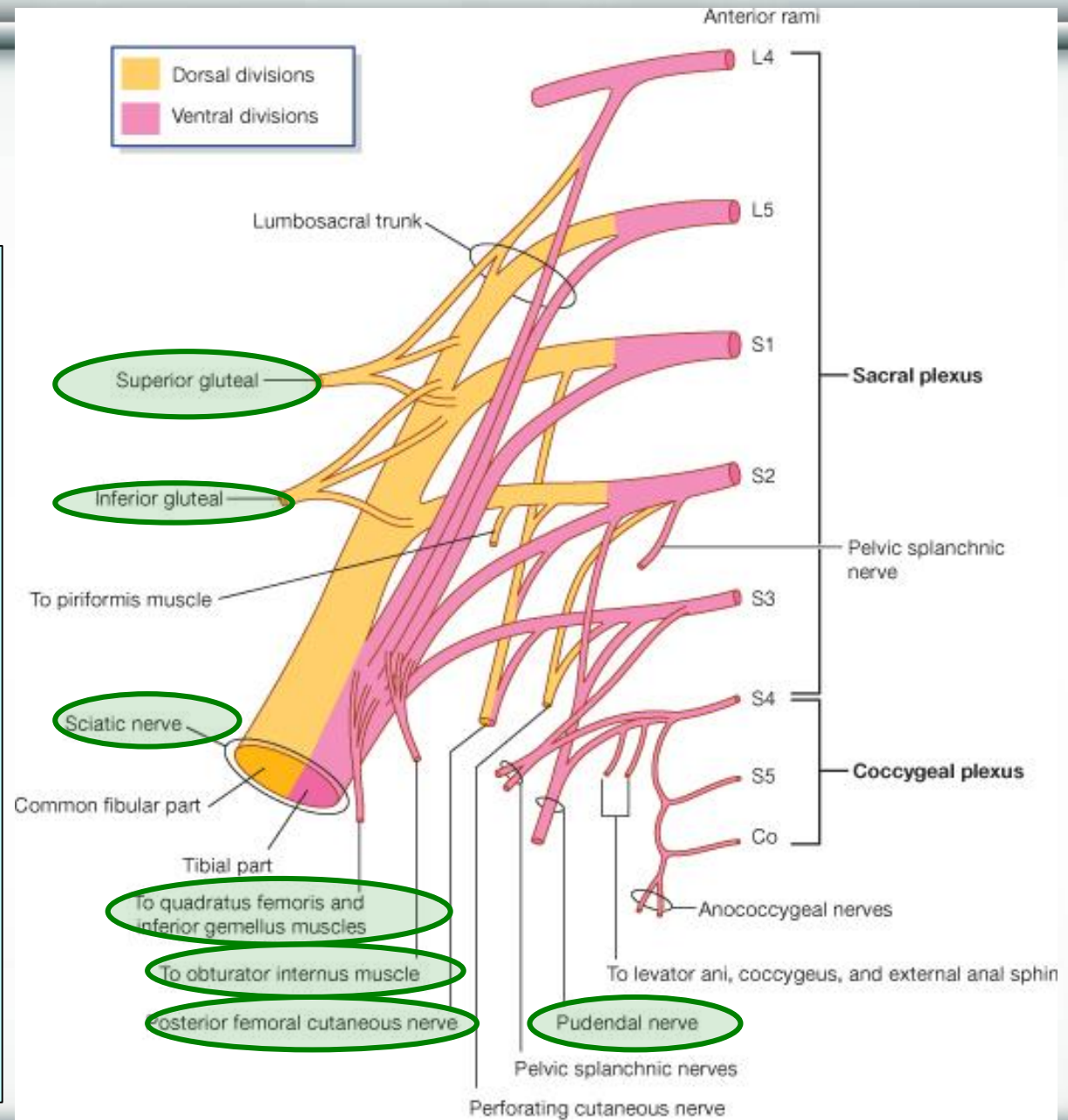


CONTENTS

II – NERVES:

(all from sacral plexus):

1. Sciatic nerve.
2. Superior gluteal n.
3. Inferior gluteal n.
4. Posterior cutaneous nerve of thigh.
5. Nerve to obturator internus.
6. Nerve to quadratus femoris.
7. Pudendal nerve.

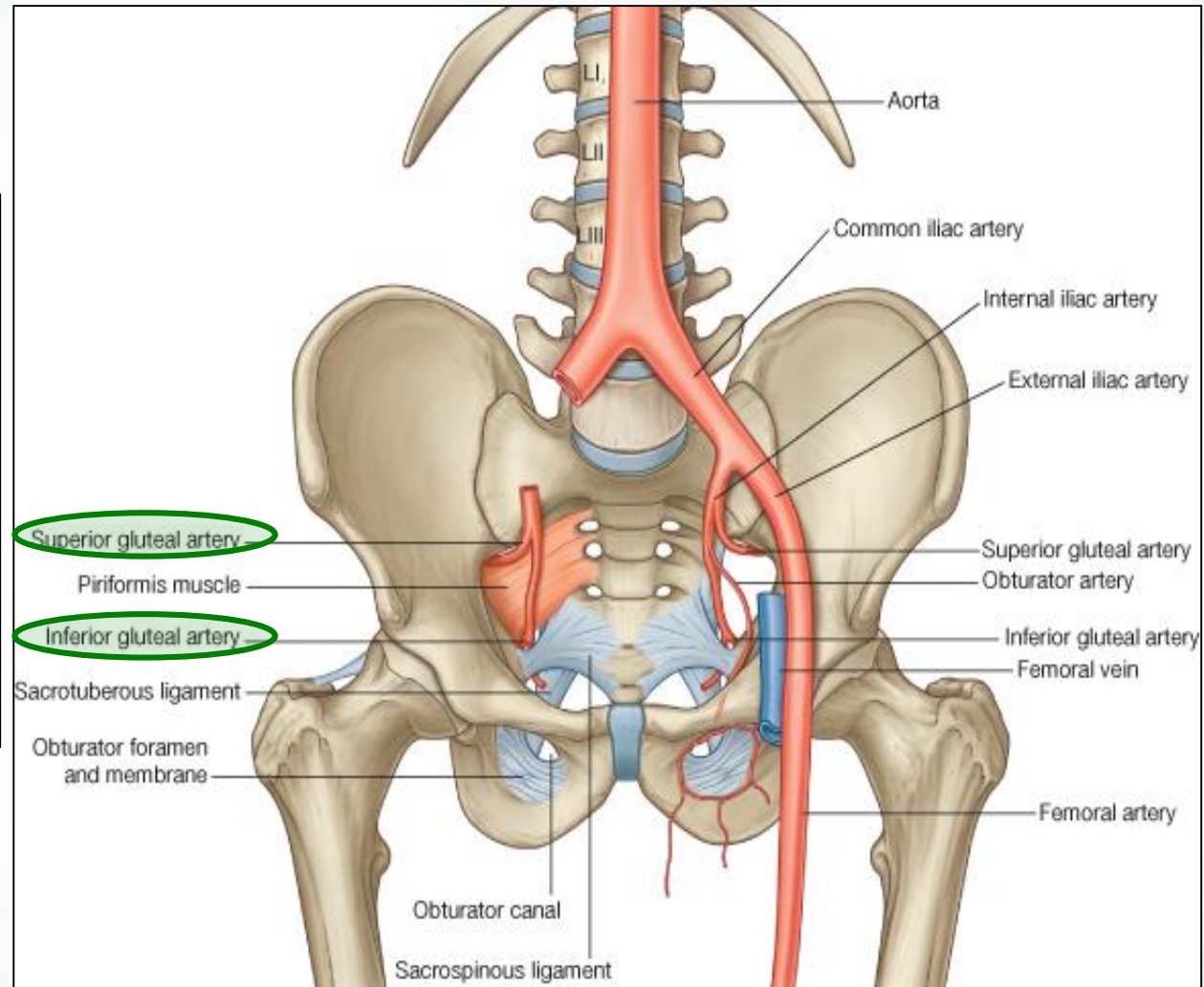


CONTENTS

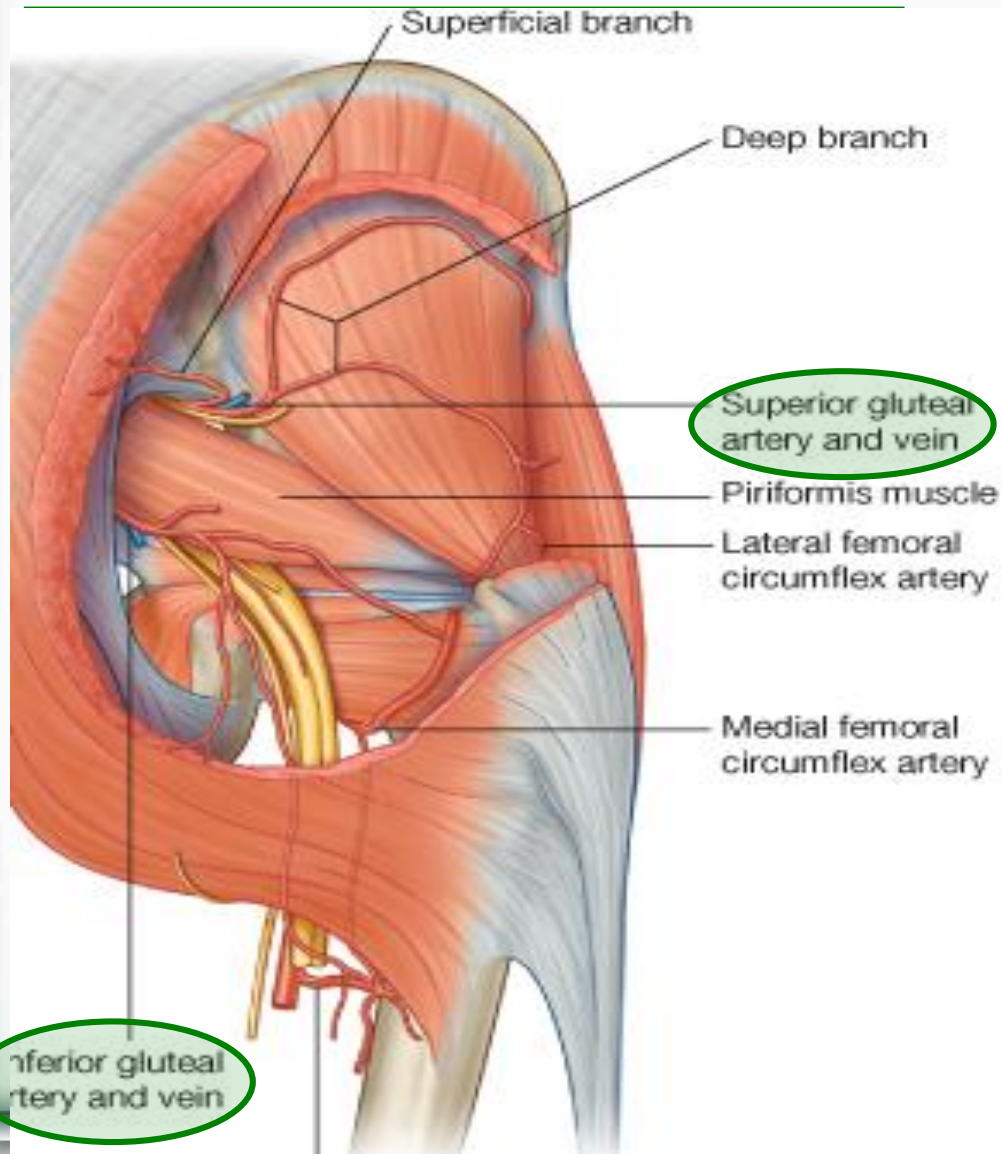
III - VESSELS:

(all from internal iliac vessels):

1. Superior gluteal V.
2. Inferior gluteal V.
3. Internal pudendal vessels.



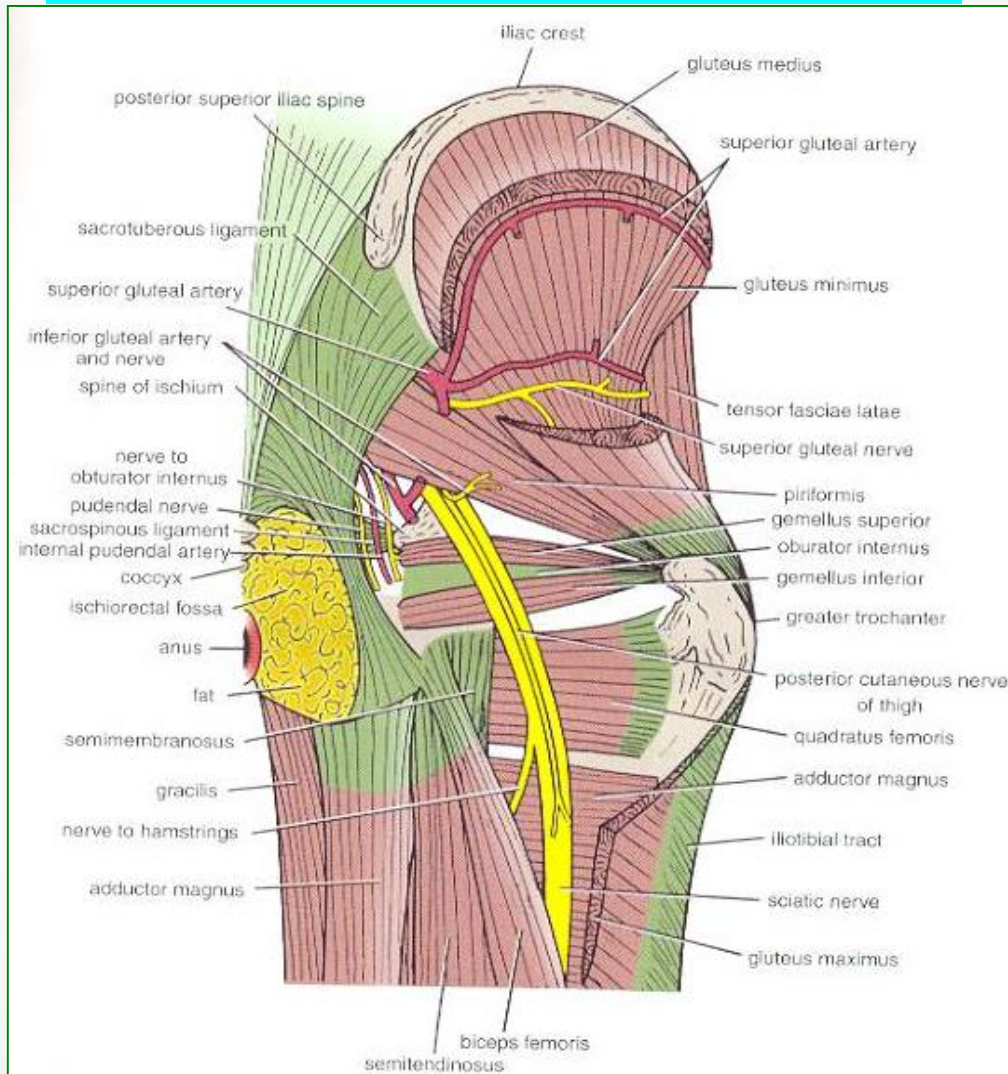
Greater sciatic foramen



➤ Greater sciatic notch of hip bone is transformed into foramen by sacrotuberous & sacrospinous ligaments.

- Structures passing through Greater sciatic foramen :
- Piriformis muscle.
- Above piriformis:
- Superior gluteal nerves & vessels.
- Below piriformis:
- Inferior gluteal nerves & vessels.
- Sciatic nerve.
- Posterior cutaneous nerve of thigh.
- Nerve to quadratus femoris.
- Nerve to obturator internus.
- Pudendal N.
- Internal pudendal vessels.

Lesser sciatic foramen



➤ Lesser sciatic notch of hip bone is transformed into foramen by Sacrotuberous & sacrospinous ligaments.

• *Structures passing through Lesser sciatic foramen :*

1. Tendon of obturator internus.
2. Nerve to obturator internus.
3. Pudendal nerve.
4. Internal pudendal vessels.

Glutei Muscles

- **ORIGINS:**

- **Gluteus minimus:**

- Anterior part of the gluteal surface of ilium

- **Gluteus medius:**

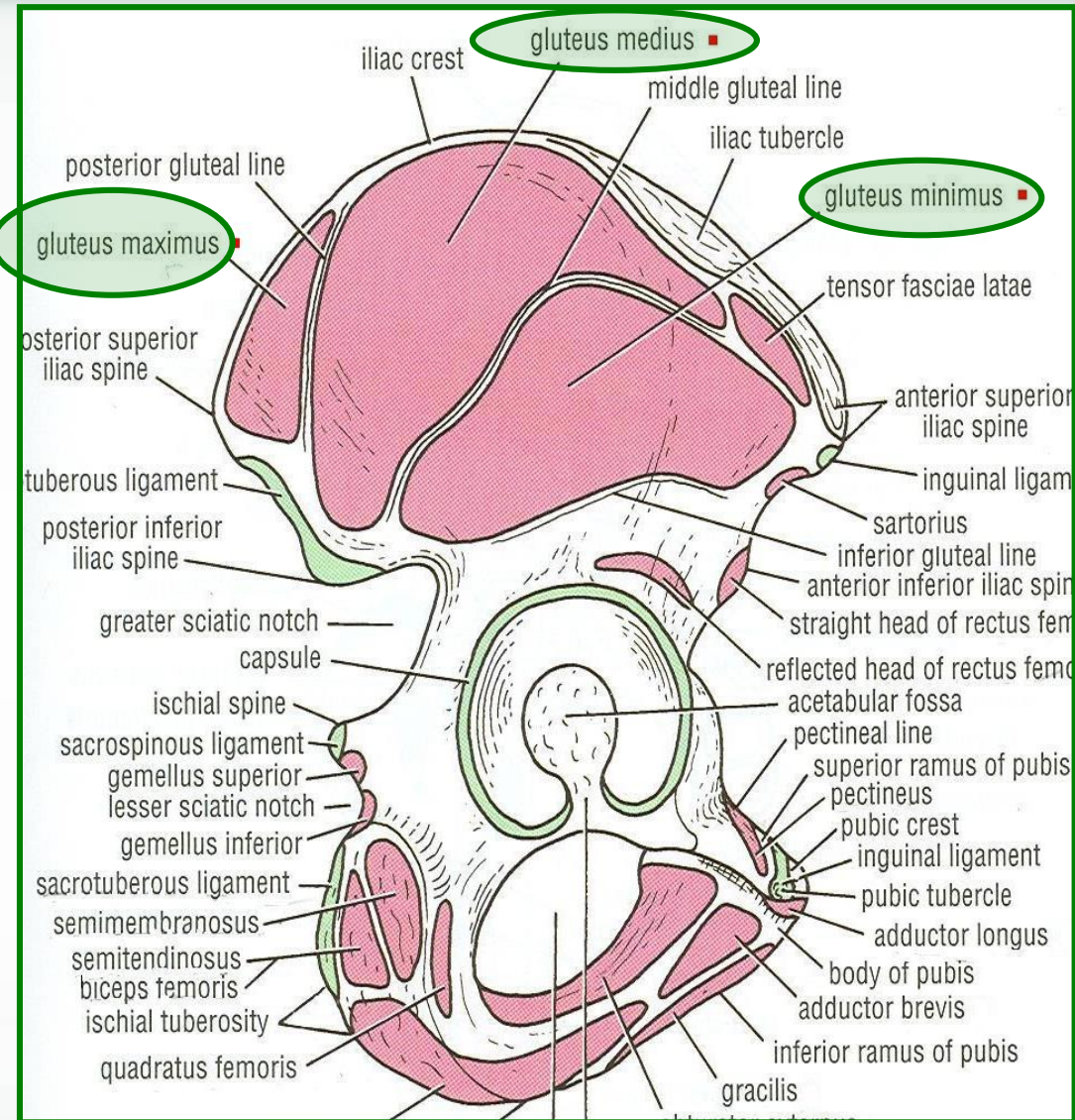
- Middle part of the gluteal surface of ilium.

- **Gluteus maximus:**

- Posterior part of the gluteal surface of ilium.

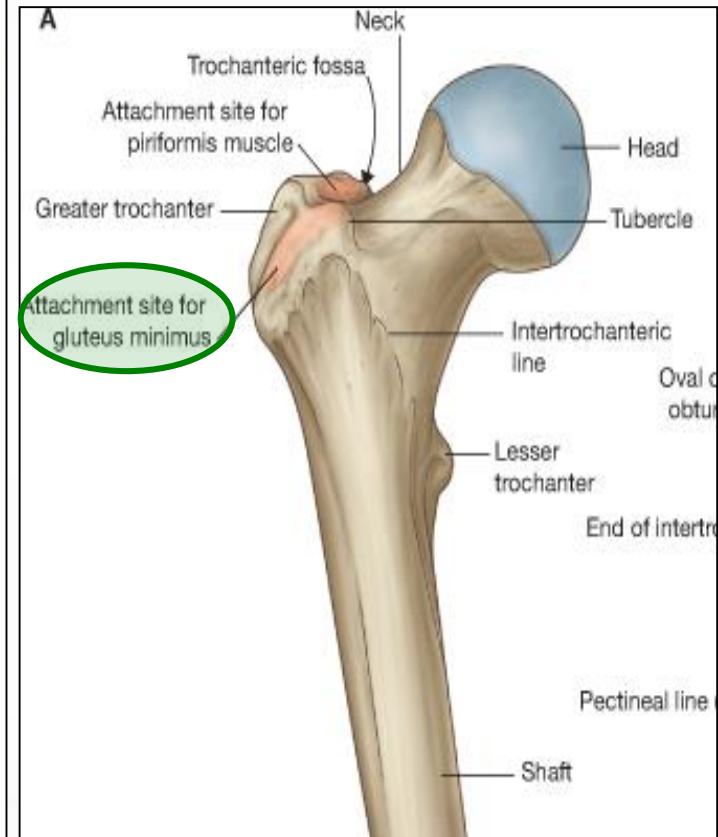
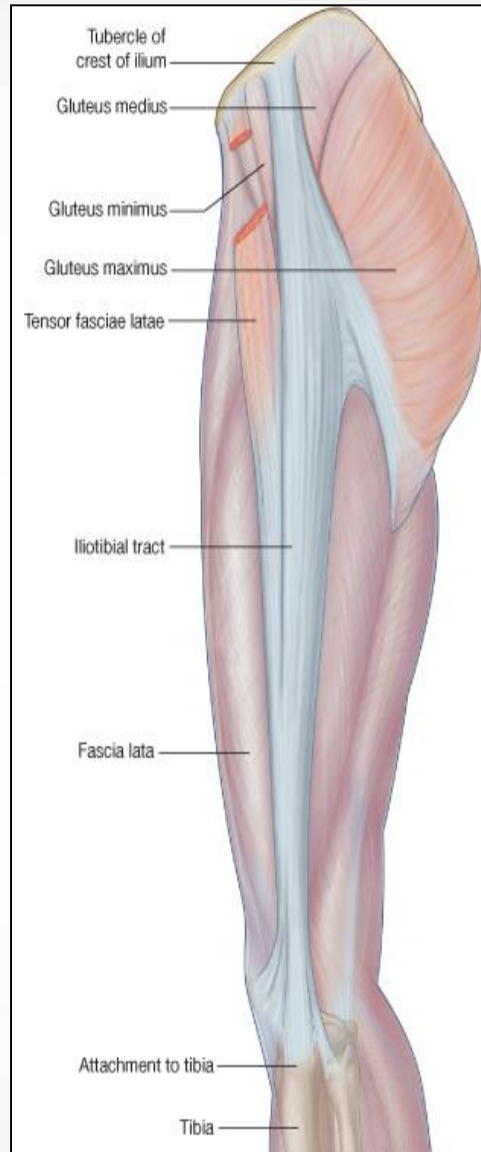
Main origin of gluteus maximus:

Back of sacrum & coccyx & back of Sacrotuberous ligament.



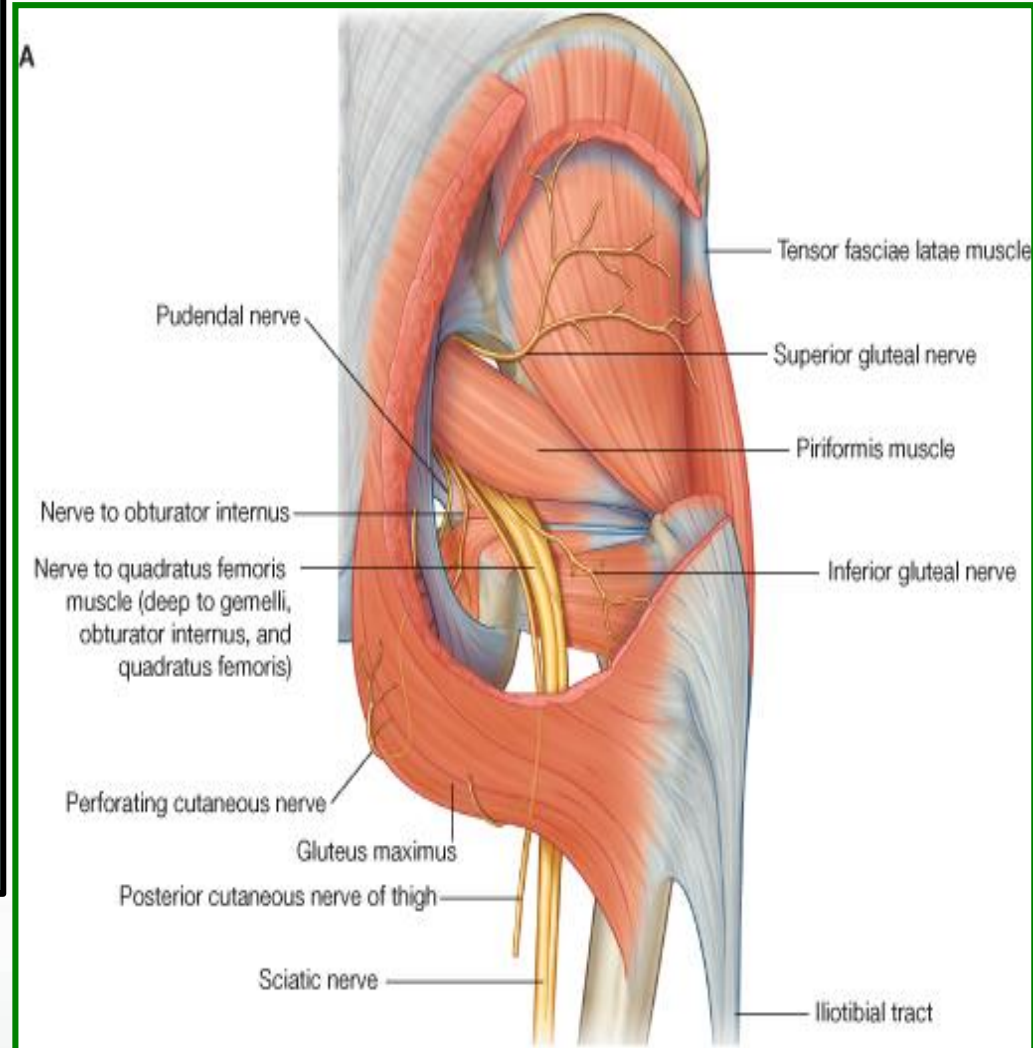
Glutei

- **Insertion:**
- **Gluteus minimus:** anterior surface of the greater trochanter
- **Gluteus medius:** lateral surface of the greater trochanter
- **Gluteus maximus:**
 1. **Main insertion:** iliotibial tract
 2. **Other insertion:** gluteal tuberosity of the femur.



NERVE SUPPLY & ACTION

- **Gluteus medius & minimus:**
- **Nerve supply:**
- Superior gluteal nerve.
- **Action:**
- Abduction & Medial rotation of hip joint.
- **Gluteus maximus:**
- **Nerve supply:**
- Inferior gluteal nerve.
- **Action:**
- Extension & lateral rotation of the hip joint.
- Through its attachment to iliotibial tract, it stabilizes the femur on the tibia during standing.



- **Obturator Internus:**

- **Origin:**

- Side wall of the pelvis.

- **Insertion:**

- Greater trochanter.

- **Nerve supply:**

- Nerve to obturator internus.

- **Superior & Inferior Gemelli:**

- **Origin:**

- Upper and lower part of lesser sciatic notch respectively.

- **Insertion:**

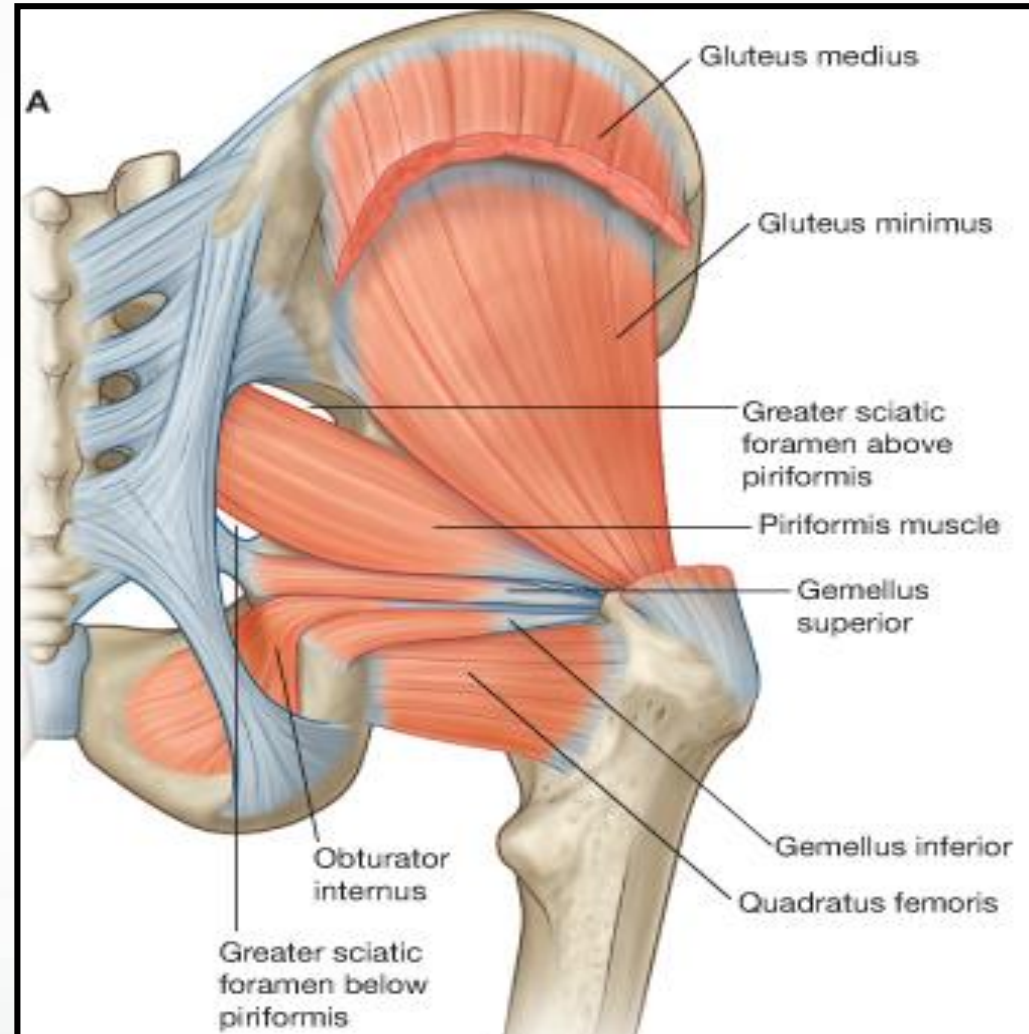
- Into **tendon of obturator internus.**

- **Nerve supply:**

- **Superior gemellus:** nerve to obturator internus.

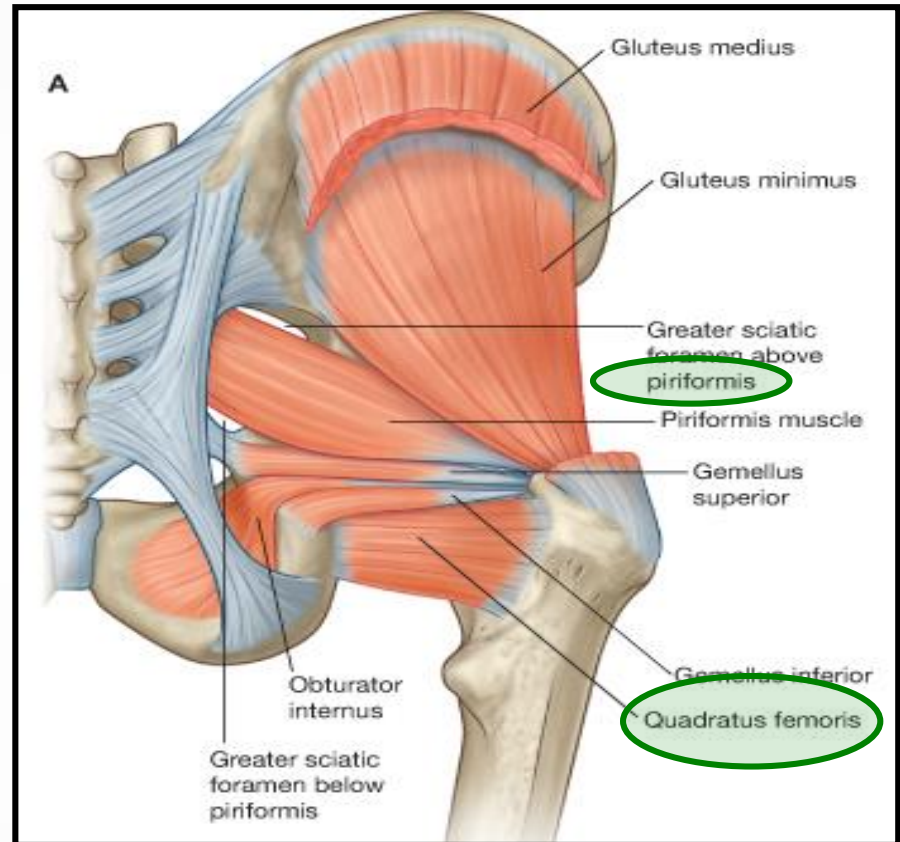
- **Inferior gemellus:** nerve to quadratus femoris.

Small muscles



- **Piriformis:**
- **Origin:**
- Pelvic surface of middle 3 sacral vertebrae.
- **Insertion:**
- Greater trochanter.
- **Nerve supply:**
- Anterior rami of S1,2.
- **Quadratus femoris:**
- **Origin:**
- Ischial tuberosity.
- **Insertion:**
- Quadratus tubercle.
- **Nerve supply:**
- Nerve to quadratus femoris.

Small muscles



Action: All have **SIMILAR ACTION:** Lateral rotation of the hip joint.
Control movement of the hip joint.

SUPERIOR GLUTEAL NERVE:

- **Course:**
- Passes through **GSF**, above piriformis.
- **Branches:**
- 1. Muscular to gluteus medius, minimus & tensor fasciae lata muscle.
- 2. Articular to hip joint.

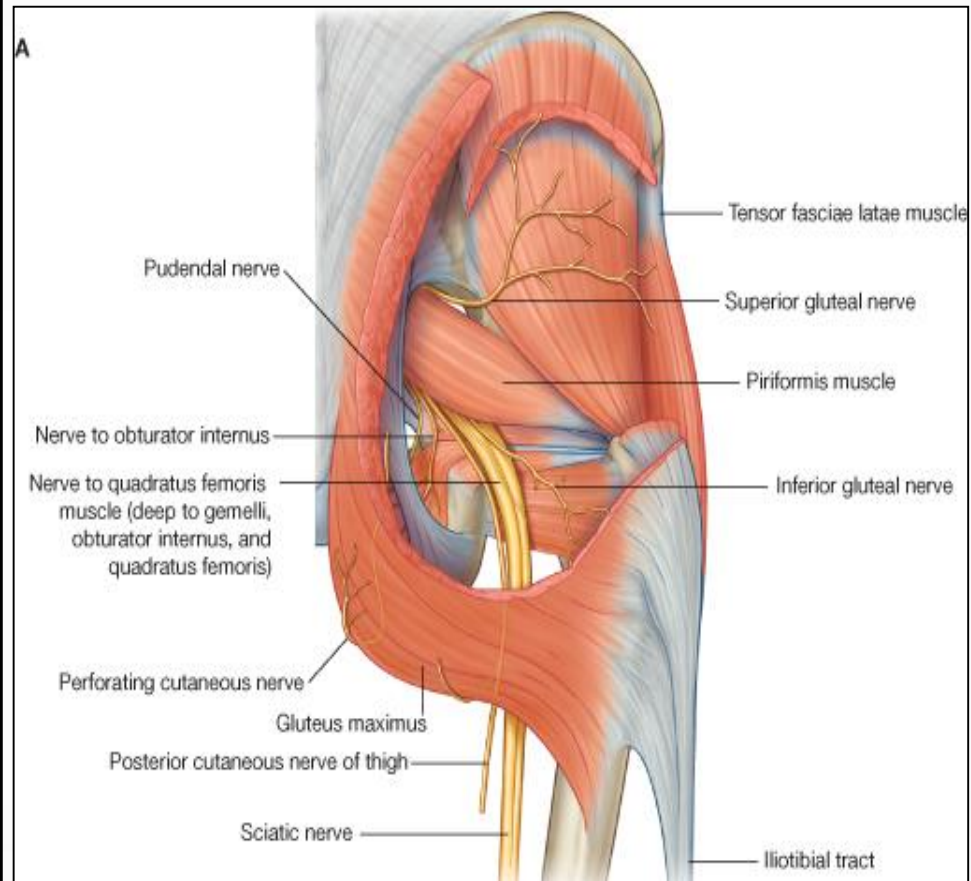
INFERIOR GLUTEAL NERVE:

- **Course:**
- passes through **GSF**, below piriformis.
- **Branches:** Gluteus maximus.

NERVE TO QUADRATUS FEMORIS:

- **Course:**
- passes through **GSF**, below piriformis.
- **Branches:**
- 1. Muscular to quadratus femoris & inferior gemellus.
- 2. Articular to hip joint.

NERVES



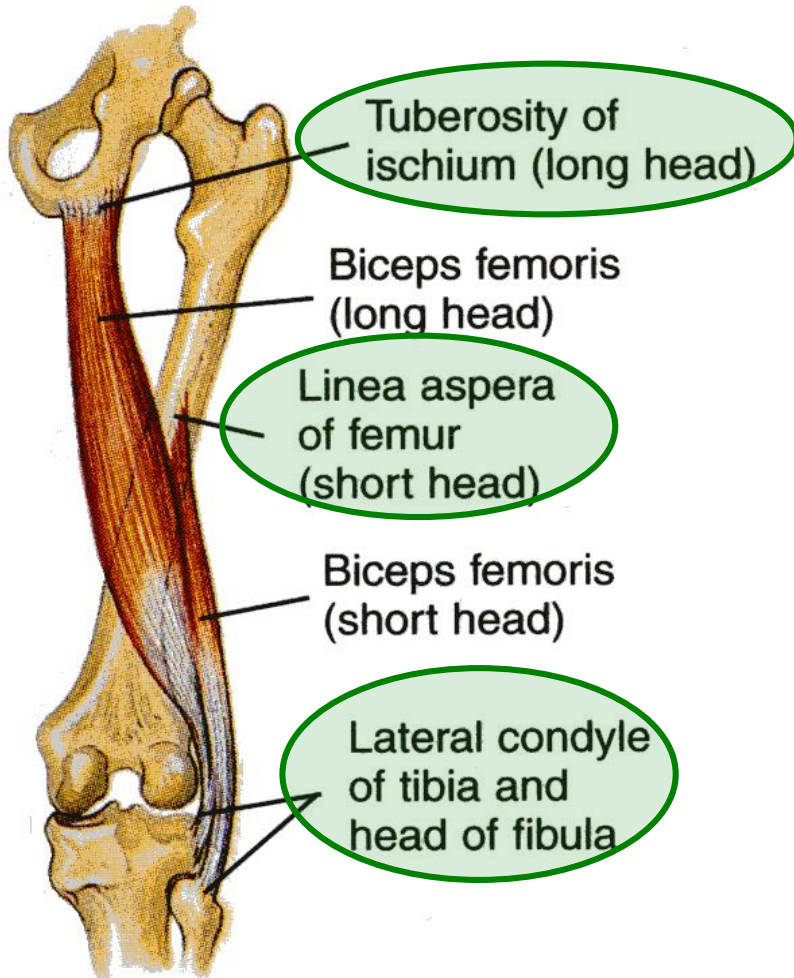
POSTERIOR COMPARTMENT OF THE THIGH

CONTENTS



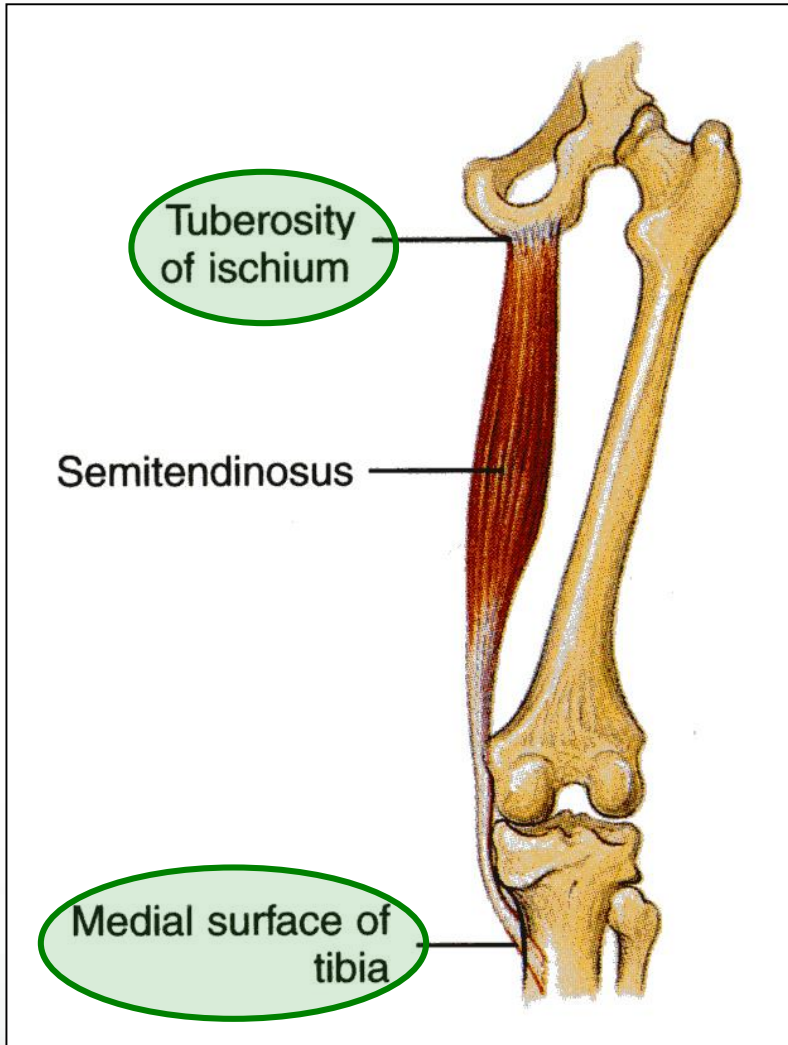
- **Muscles:**
- **Hamstring muscles:**
- Biceps femoris.
- Semitendinosus.
- Semimembranosus.
- Ischial part of adductor magnus.
- **Blood supply:**
- Branches of the profunda femoris artery.
- **Nerve supply:**
- Sciatic nerve.

MUSCLES



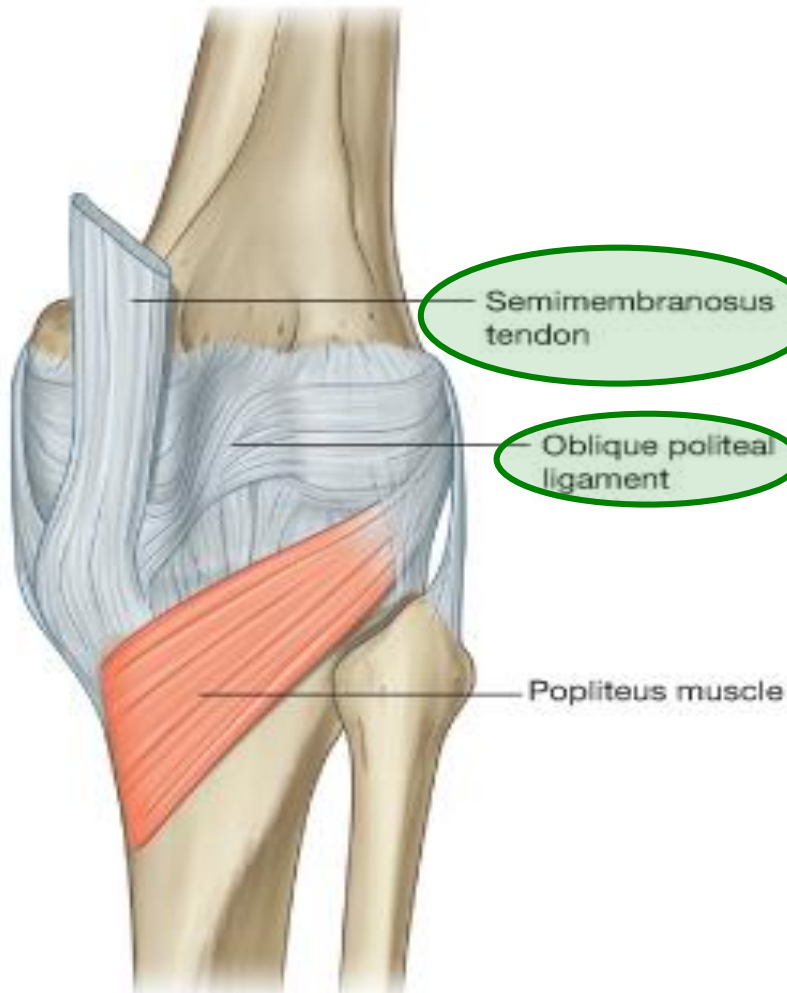
- Biceps Femoris,
 - **Origin:**
 - **Long head** from the *ischial tuberosity*.
 - **Short head** from *the linea aspera*
 - **Insertion:**
 - *Head of the fibula.*
 - Nerve supply:**
 - **Long head:** tibial part of the sciatic;
 - **Short head:** common peroneal part of the sciatic.
- Action**
- Flexion of knee.
 - Lateral rotation of flexed leg.
 - Long head: extends the hip.

SEMITENDINOSUS



- **Origin:**
 - Ischial tuberosity.
 - **Insertion:**
 - Upper part of the medial surface of the shaft of the tibia (**SGS**).
- Nerve supply:**
- Tibial portion of the sciatic.
- Action**
- Flexes and medially rotates the leg at the knee joint.
 - Extends the thigh at the hip joint.

SEMIMEMBRANOSUS



- **Origin:**
- Ischial tuberosity.
- **Insertion:**
- Posterior surface of the medial condyle of the tibia.
- It forms the **oblique popliteal ligament**, which reinforces the capsule on the back of the knee joint.

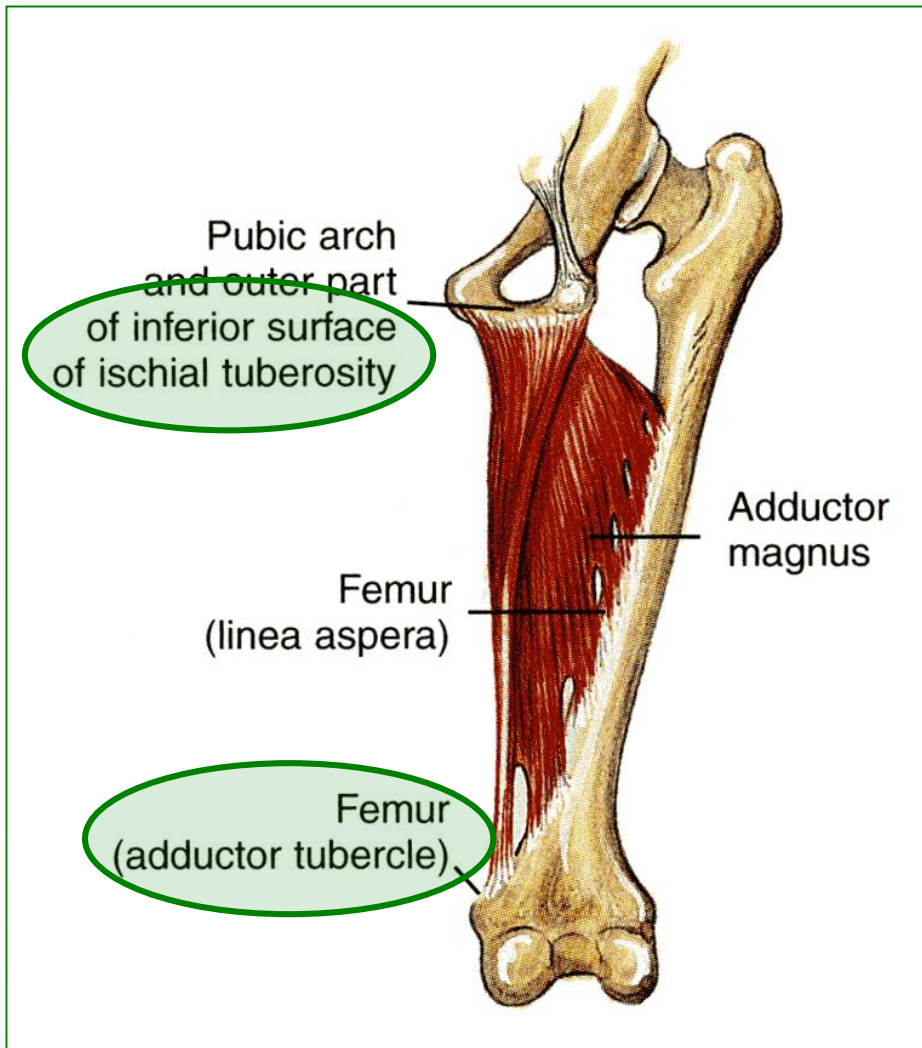
Nerve supply

- Tibial part of the sciatic nerve.

Action

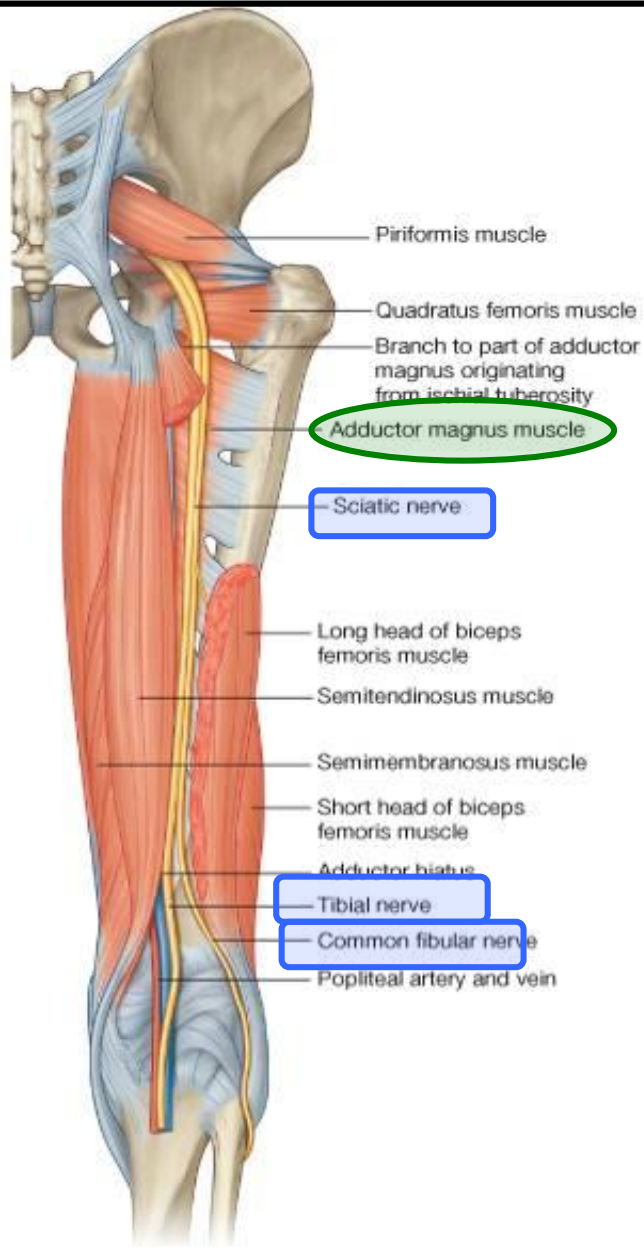- Flexes and medially rotates the leg at the knee joint;
- Extends the thigh at the hip.

ADDUCTOR MAGNUS (HAMSTRING PART)



- **Origin:**
- Ischial ramus and ischial tuberosity.
- **Insertion:**
- Adductor tubercle of the medial condyle of the femur.
- **Nerve supply:**
- Tibial portion of sciatic.
- **Action:**
- Extends the thigh at the hip joint.

NERVE SUPPLY



- **Sciatic Nerve**
- The **sciatic nerve**, is a branch of the sacral plexus (L4 and 5; S1, 2, and 3), leaves the gluteal region as it descends in the midline of the thigh.
- It lies on the posterior aspect of the adductor magnus.
- In the lower third of the thigh it ends by dividing into **tibial** and **common peroneal nerves**.