

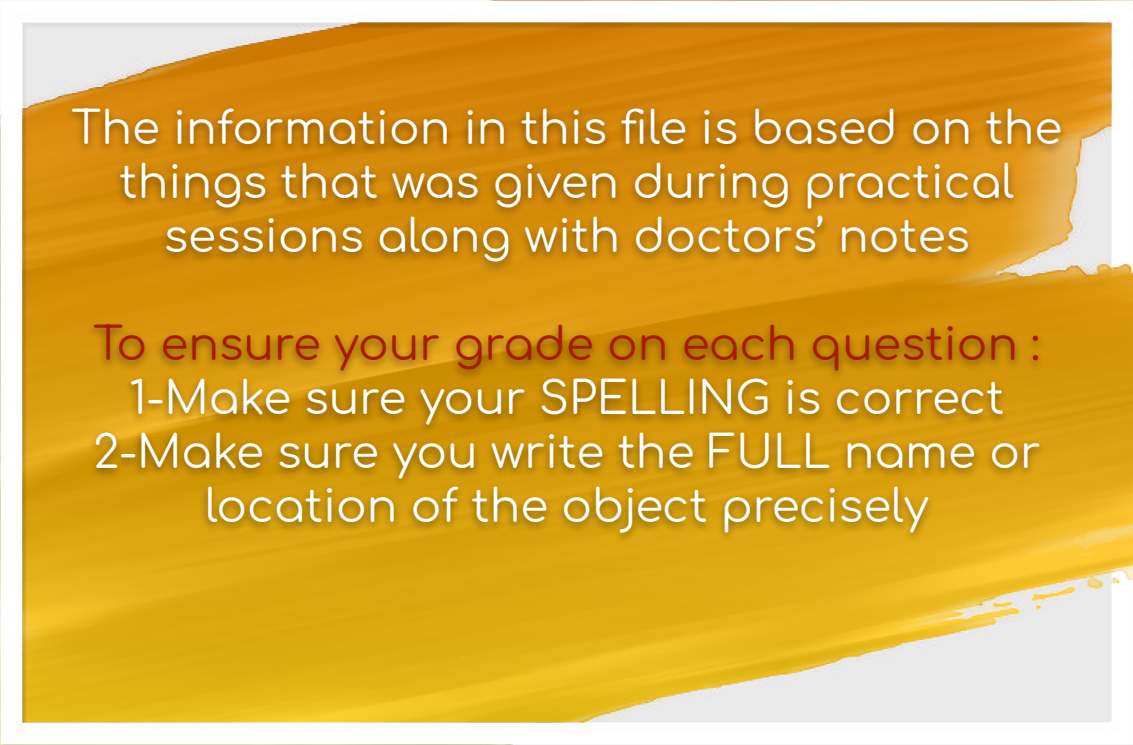


Appendicular skeleton

Musculoskeletal Block



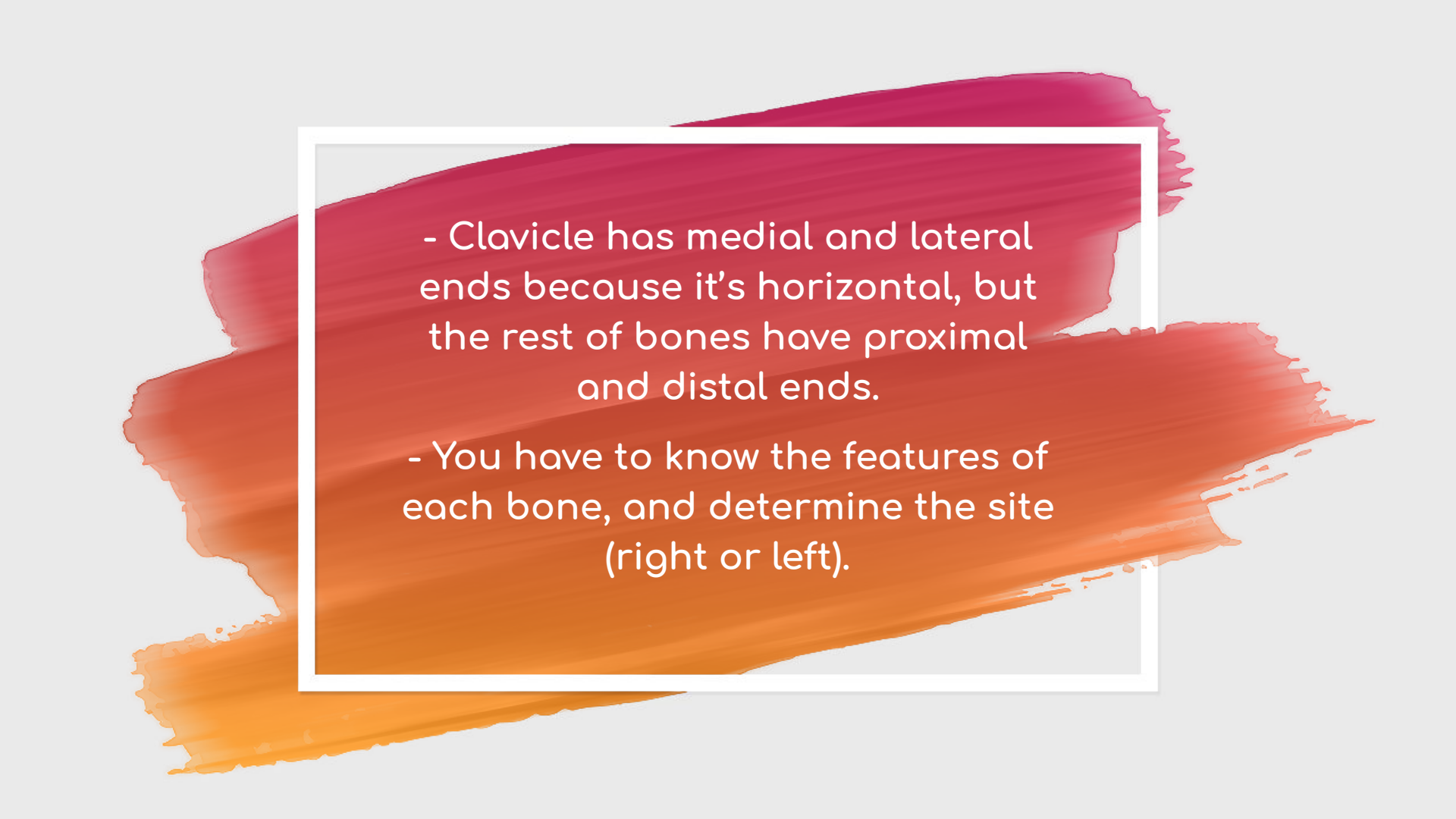
Anatomy Practical team - Med 439



The information in this file is based on the things that was given during practical sessions along with doctors' notes

To ensure your grade on each question :

- 1-Make sure your SPELLING is correct
- 2-Make sure you write the FULL name or location of the object precisely



- Clavicle has medial and lateral ends because it's horizontal, but the rest of bones have proximal and distal ends.

- You have to know the features of each bone, and determine the site (right or left).



Pectoral Girdle

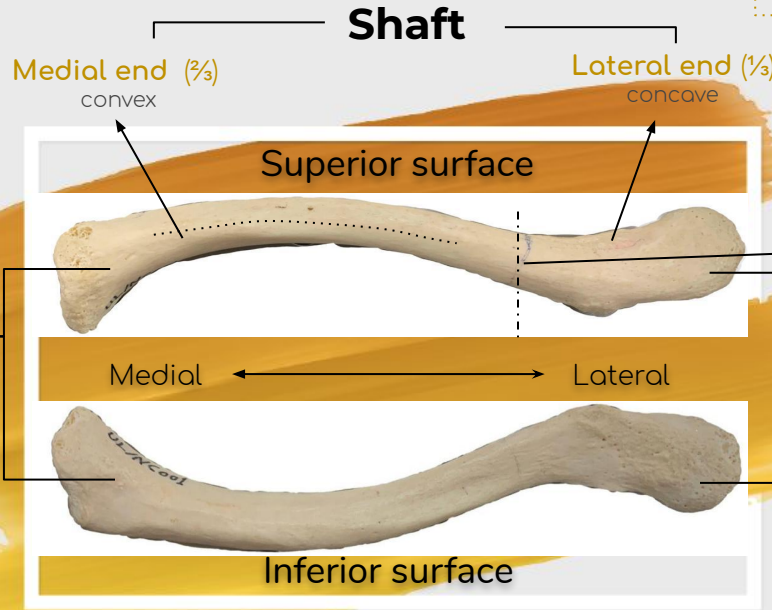
Pectoral Girdle

Clavicle "S" Shaped

- The only horizontal long bone in our bodies.
- Doubly curved.
- subcutaneous.



Click or Scan



Common site of injury

Lateral (Acromial) End

- Flattened
- has one joint with scapula (acromioclavicular joint)

Medial (Sternal) End

- Enlarged and triangular you could say
- has two joints with
- 1-1st Rib
- 2-Sternum (Sternoclavicular joint)

Surfaces:

- Superior Surface is smooth (due to skin attachment)
- Inferior Surface is rough (due to muscle attachment)

Site determination by:

- Sternal end (**medial**)
- The convex part of the shaft (**medial,anterior**)
- smooth surface (**superior**)

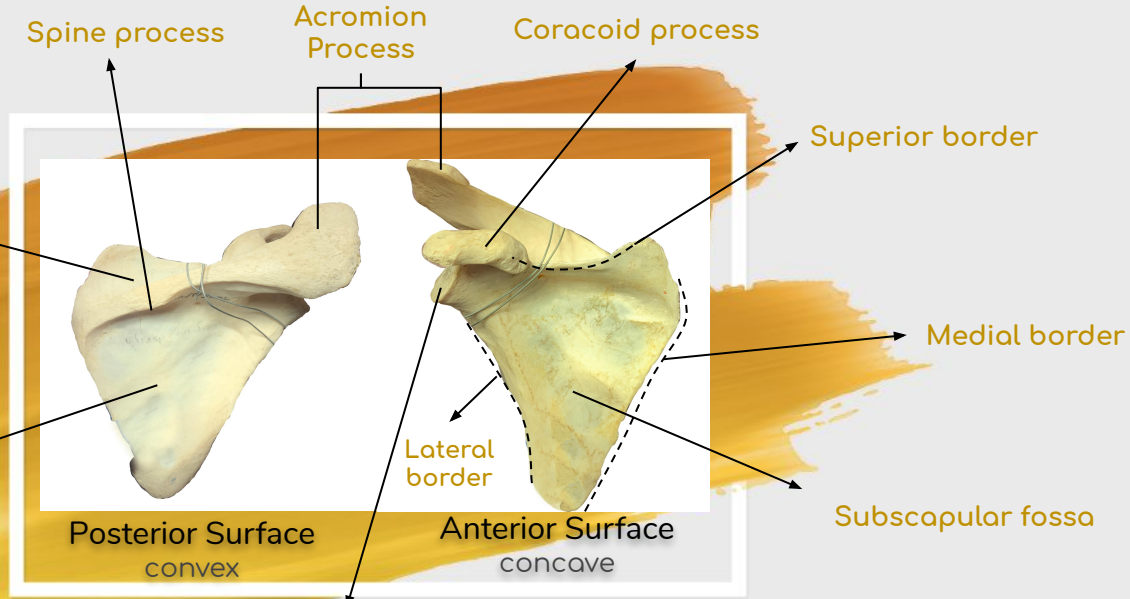


Click or Scan

Pectoral Girdle

Scapula

Flat bone in the posterior side of the thoracic, extends from the 2nd to the 7th rib.



There are:

- 3 Process
- 3 Borders
- 3 Fossa
- 1 Cavity

Supraspinous fossa
- Small
- Above the spine

Infraspinous fossa
- Large
- Under the spine

Glenoid cavity
lateral Cavity : "glenoid"
articulate with humerus to
make (shoulder joint)

- Site determination by :**
- Spine process (**posterior**)
 - Glenoid cavity (**lateral**)
 - Subscapular fossa (**toward the ribs**)



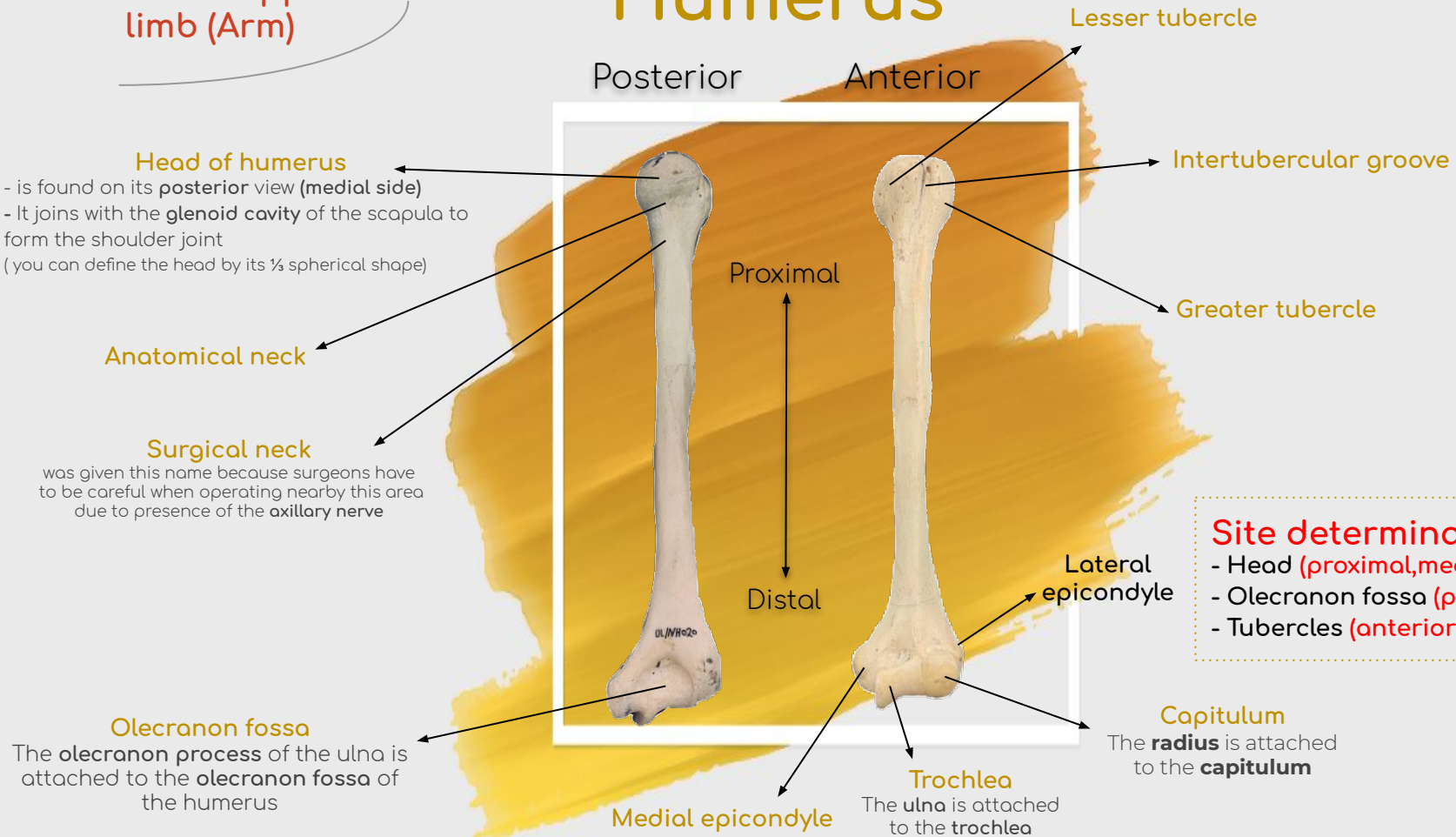
Bones of Upper Limb

Bones of upper limb (Arm)

Humerus



Click or Scan



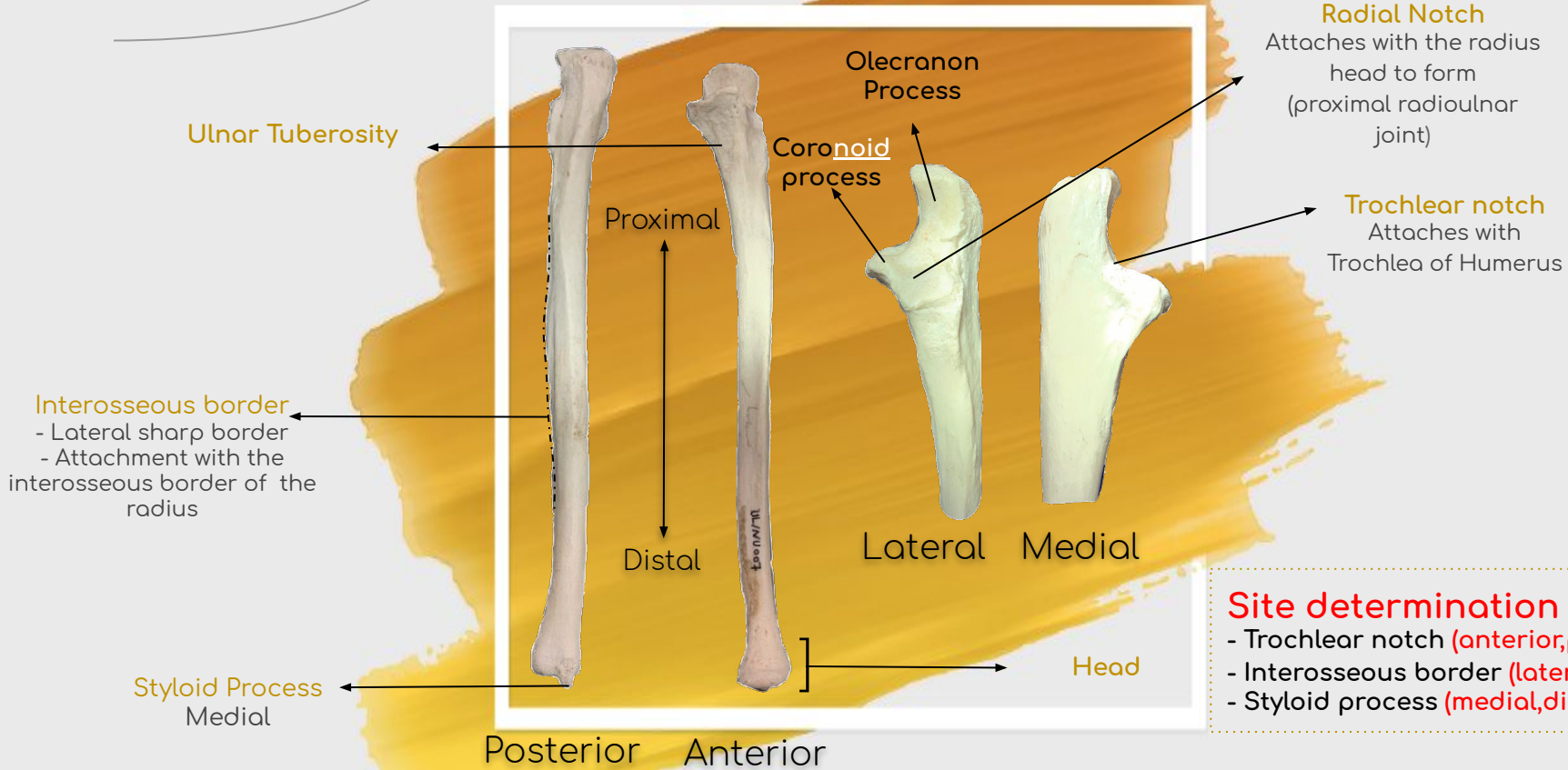
Bones of Upper Limb

Ulna

Medial bone of the forearm



Click or Scan



- Site determination by :**
- Trochlear notch (**anterior, proximal**)
 - Interosseous border (**lateral**)
 - Styloid process (**medial, distal**)

Bones of Upper Limb

Radius

The lateral bone of the forearm



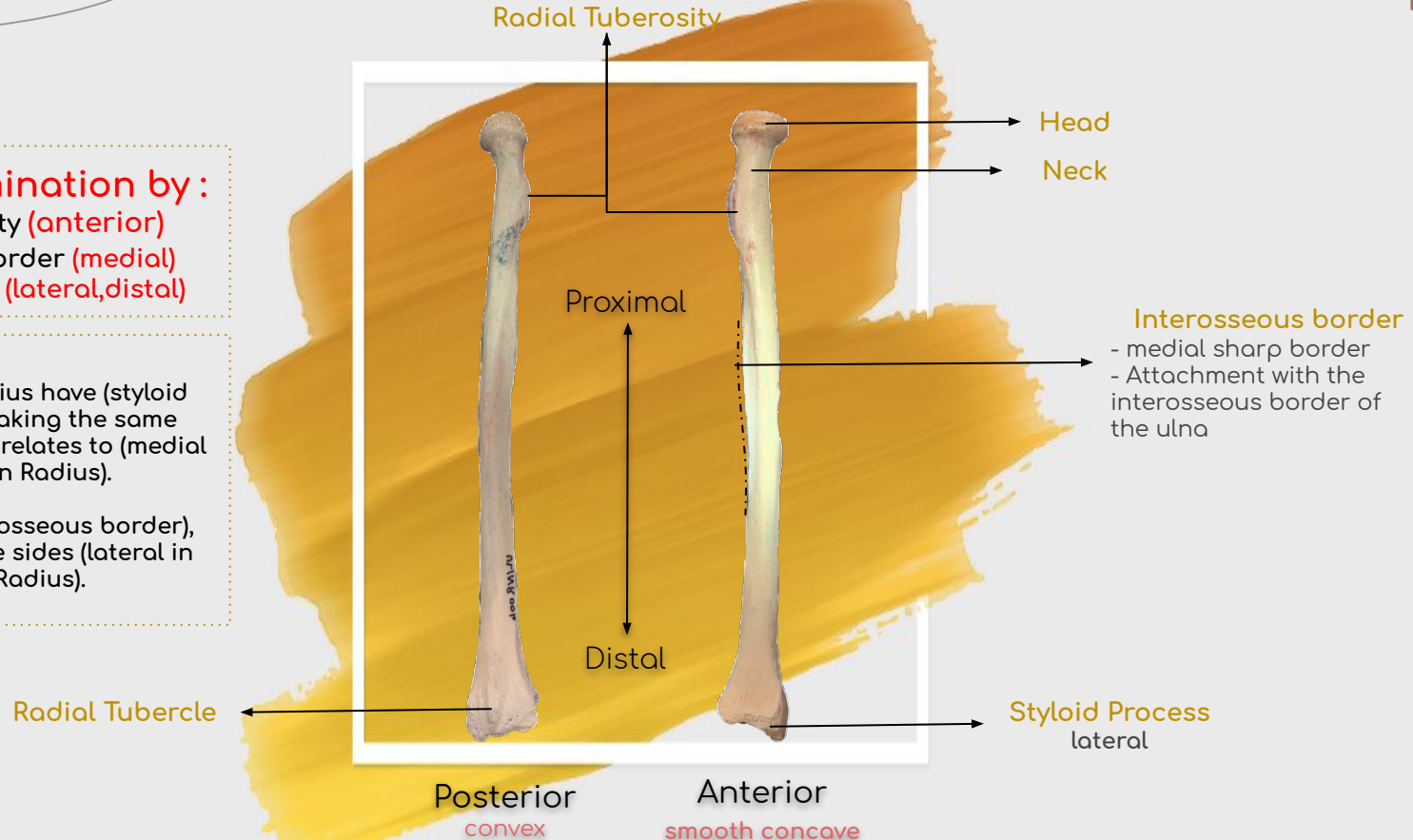
Click or Scan

Side determination by:

- Radial tuberosity (anterior)
- Interosseous border (medial)
- Styloid process (lateral, distal)

Note that:

- 1- Both Ulna & Radius have (styloid process) which is taking the same side of the bone it relates to (medial in Ulna) & (lateral in Radius).
- 2- Both have (interosseous border), but in the opposite sides (lateral in Ulna) & (medial in Radius).



Bones of Upper Limb

Hand



Click or Scan

Carpals (8 Bones)

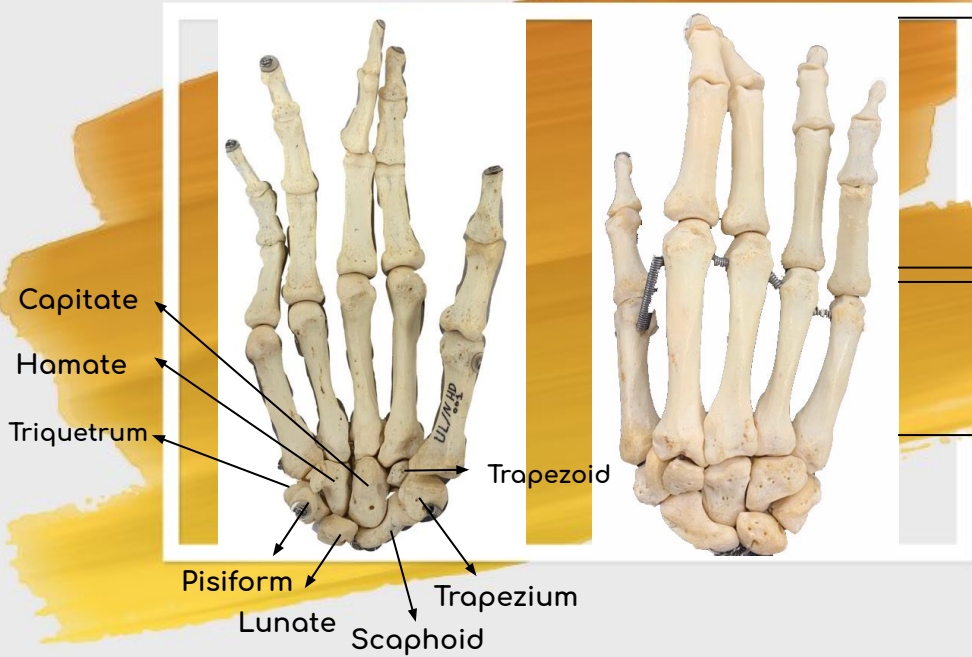
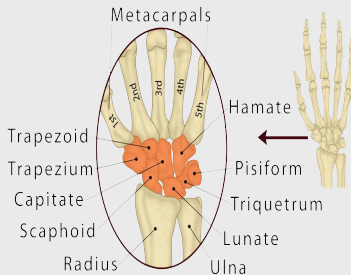
*From Lateral to medial (starting from thumb)

Proximal (first) row:

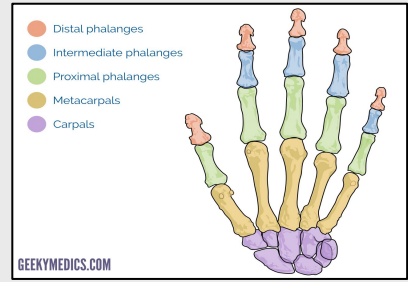
Scaphoid, Lunate, Triquetrum & pisiform.
(She Looks Too Pretty)

Distal (second) row:

Trapezium, Trapezoid, Capitate & Hamate.
(Try To Catch Her)



She Looks Too Pretty, Try To Catch Her



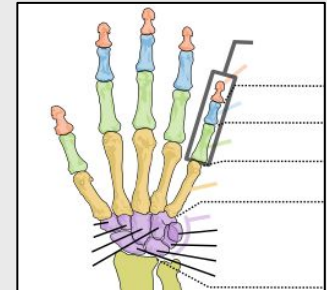
Phalanges (14 Bones)

Three for every finger except for the thumb which has 2 phalanges

Metacarpals (5 Bones)

*From Lateral to medial (starting from thumb)

- A long bone i.e each bone has a base, shaft and a head.
- Metacarpal 1, 2, 3, 4 & 5



Test yourself!



Bones of Lower Limb

Bones of Lower Limb

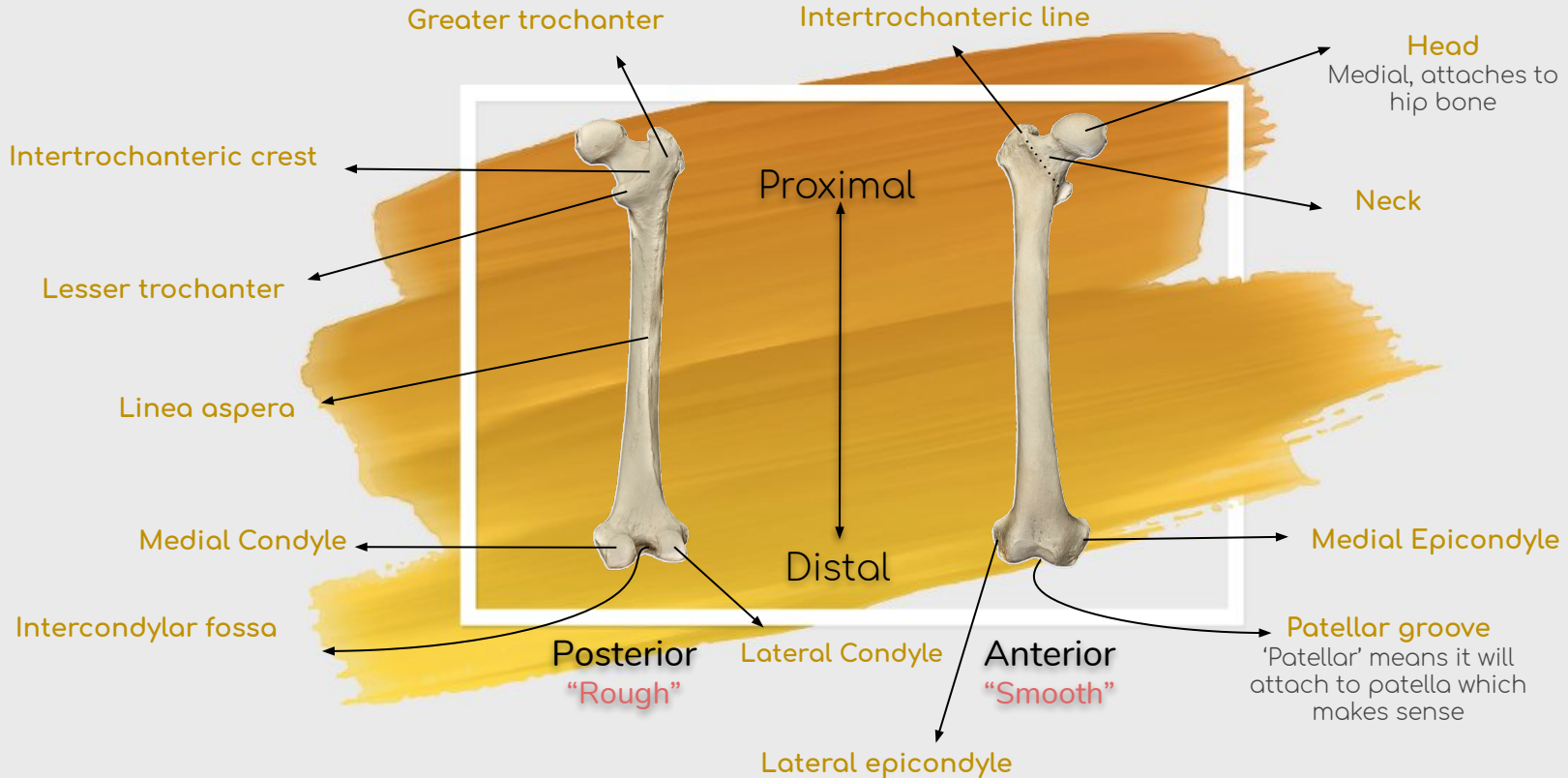
Femur

Site determination by :

- Head (proximal,medial)
- Epicondyles (anterior)
- Condyles (posterior)



Click or Scan



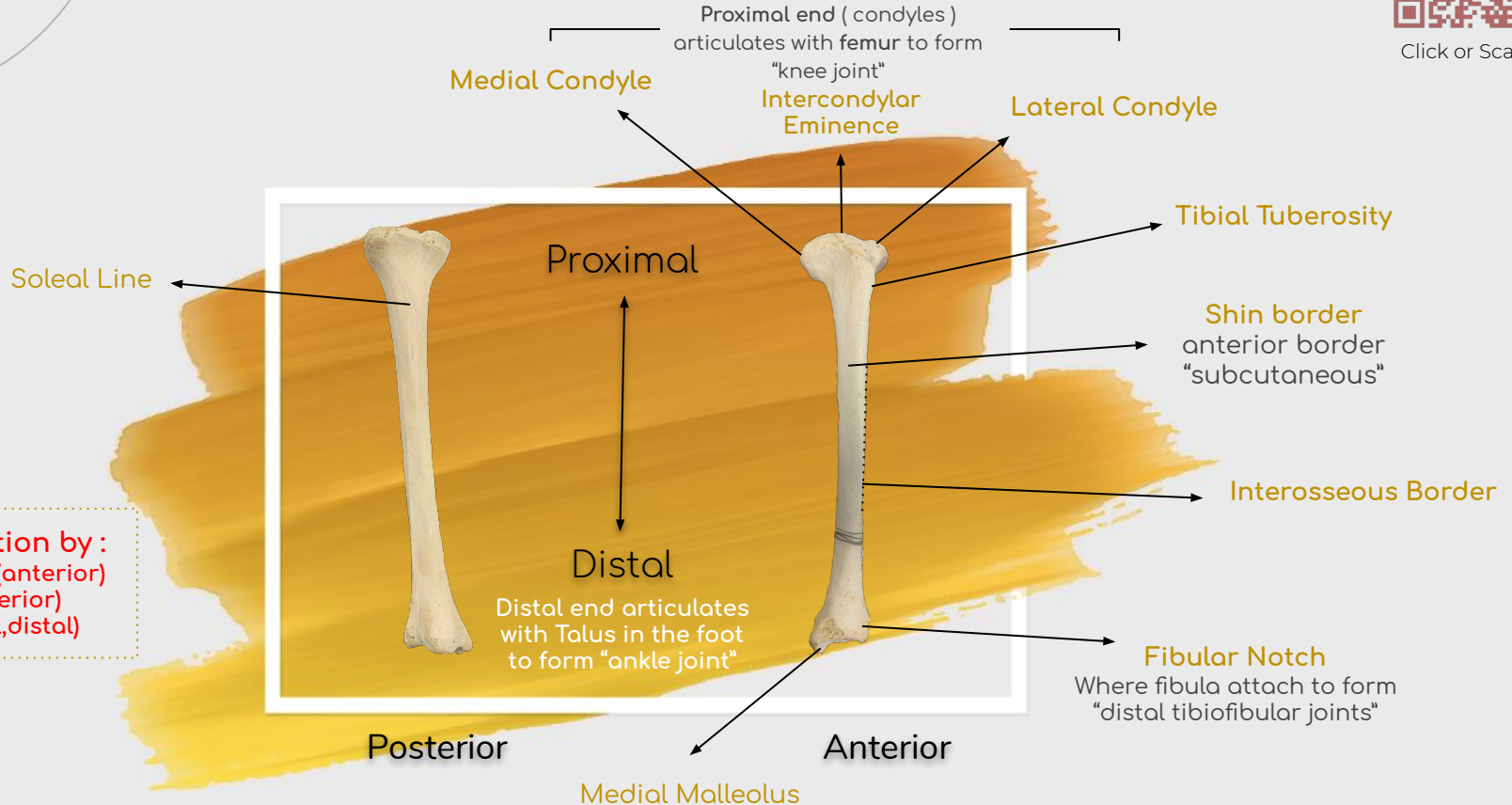
Bones of Lower Limb

Tibia

“Medial bone of the leg, and the most weight bearing bone.”



Click or Scan



Site determination by :

- Tibial tuberosity (anterior)
- Shin border (anterior)
- Malleolus (medial, distal)

Bones of Lower Limb

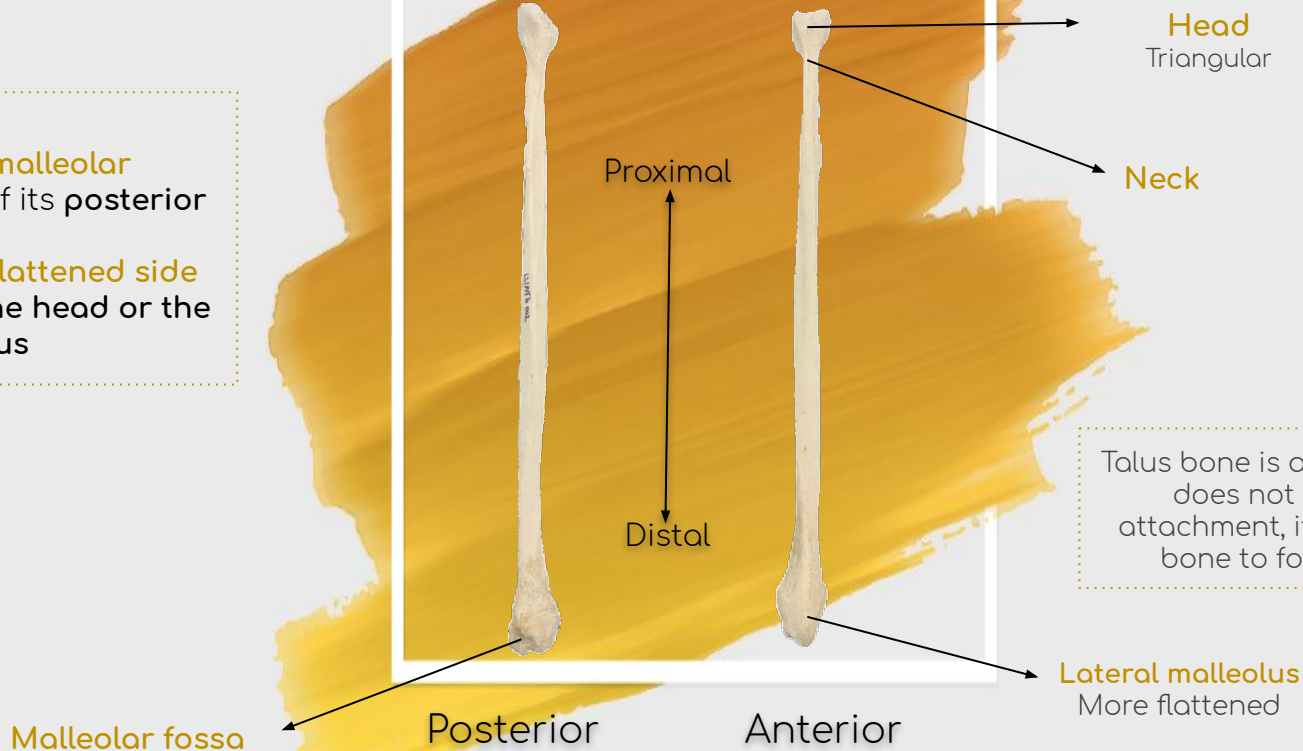
Fibula



Click or Scan

Identification:

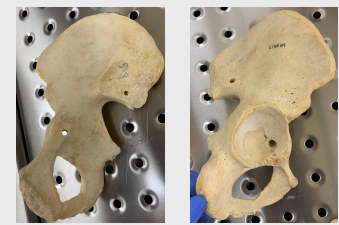
- Look for the **malleolar fossa** to know if its **posterior** or **anterior**
- Look for the **flattened side** to know if its **the head** or the **lateral malleolus**



Talus bone is a bone of the foot that does not have any muscle attachment, it joins with the fibula bone to form the ankle joint

Hip Bone

Bones of the lower limb

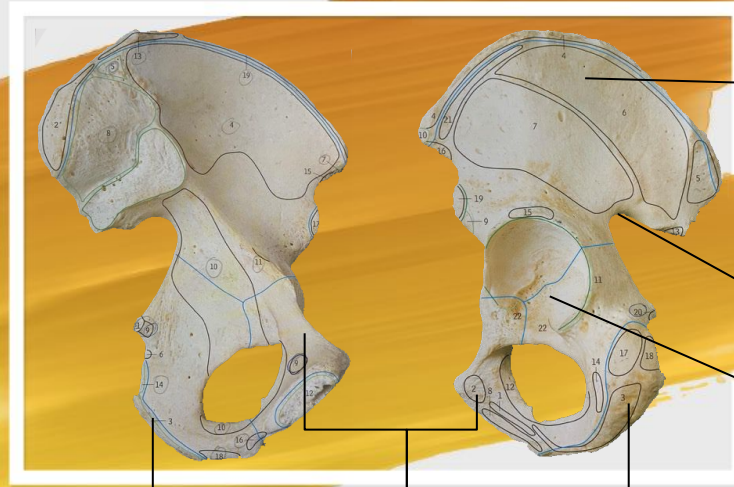

Site determination by:

- Ilium (superior)
- Acetabulum (lateral)
- Ischium (posterior)

Medial

Lateral



Ilium

ilium of the hip bone and the sacrum together form the Sacroiliac joint

Greater Sciatic Notch

Acetabulum

(lateral side of hip bone) articulates with femur to form hip joint

Pubis

The pubic symphysis is a joint formed between the pubic of each hip bone

Ischium



Click or Scan

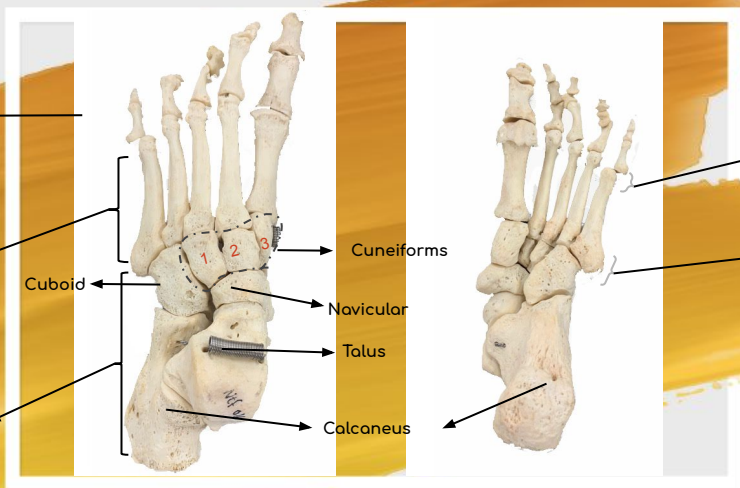
Bones of the lower limb

Foot



Click or Scan

Anterior view Posterior View

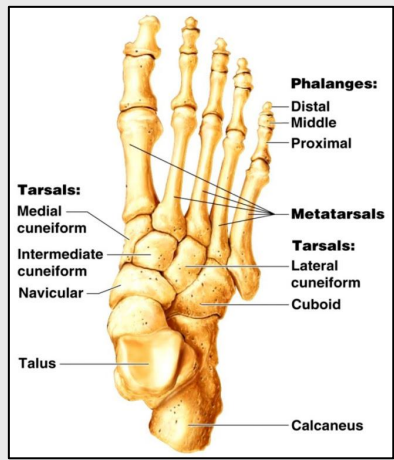
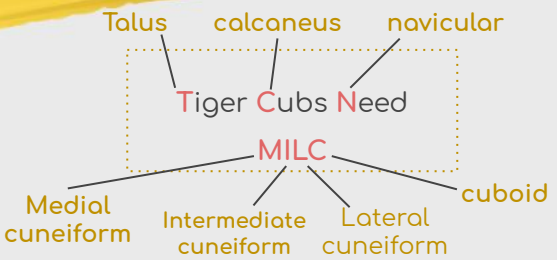

Phalanges (14 bones)
Each toe has three phalanges except the big toe which has two phalanges

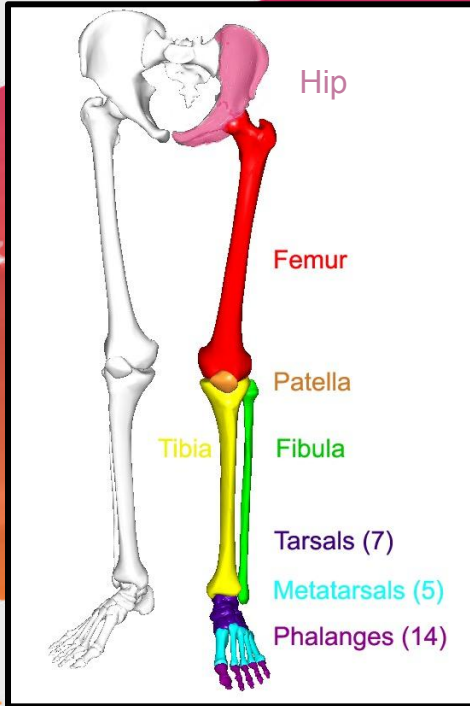
Metatarsals
5 bones

Tarsals (7 bones)
(medial to lateral)
- **Proximal row:** Calcaneus, Talus, navicular, cuboid
- **Distal row:** 3 cuneiforms
"medial, intermediate, lateral"

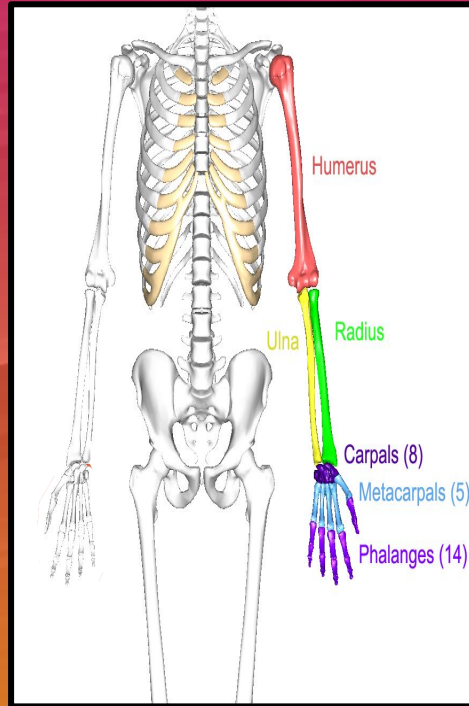
Head
Distal end
Base
Proximal end



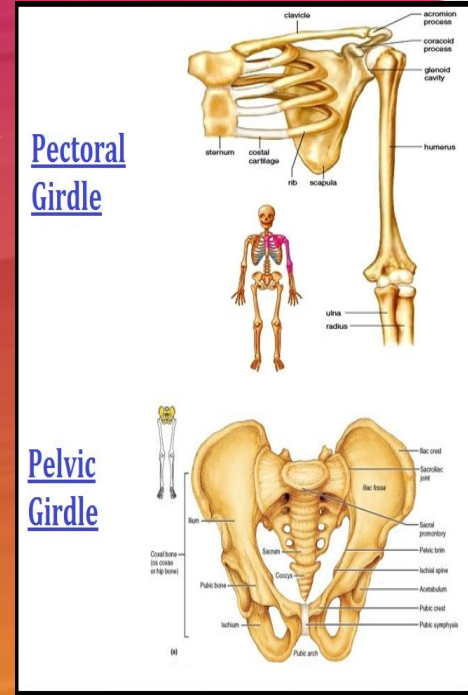
Summary



Bones of Lower limb



Bones of Upper Limb



Bones of two girdles (pectoral is upper, pelvic is lower)

QUIZ

Now, we suppose you are able to determine the site of each bone that was explained.

☆ Can you guess, what is the site of each previous bone? (right or left)

Answers:

Clavicle = right
Scapula = right
Humerus = right
Ulna = left

Radius = left
Femur = right
Tibia = left
Hip = left

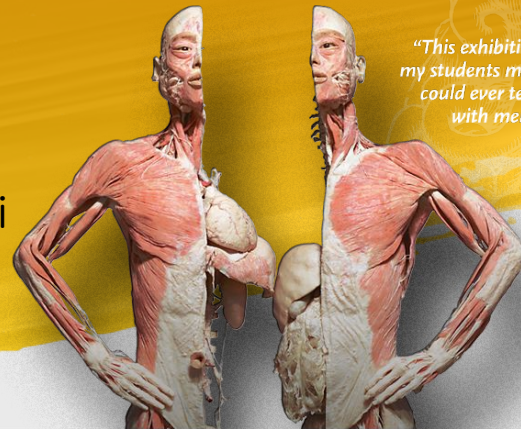
Don't stop until you are proud.

Team Members:

- Duaa Alhumoudi
- Mona Alomiriny
- Rania Almutiri
- Taif Almotiri
- Nourah Alklaib
- Arwa Alqahtani
- Norah Alasheikh
- Sara Alharbi
- Najd Alzahrani
- Mishal Althunayan
- Omar alhalabi
- Abdulaziz Alomar
- Khalid Alosaimii
- Hadi Alhemsii
- Nasser Alohalii
- Abdulrahman Alotaibi

Team Leaders:

- Renad Alhomaidi
- Bassam Alasmari



"This exhibition taught my students more than I could ever teach them with mere words."