

MUSCLES INVOLVED IN RESPIRATION

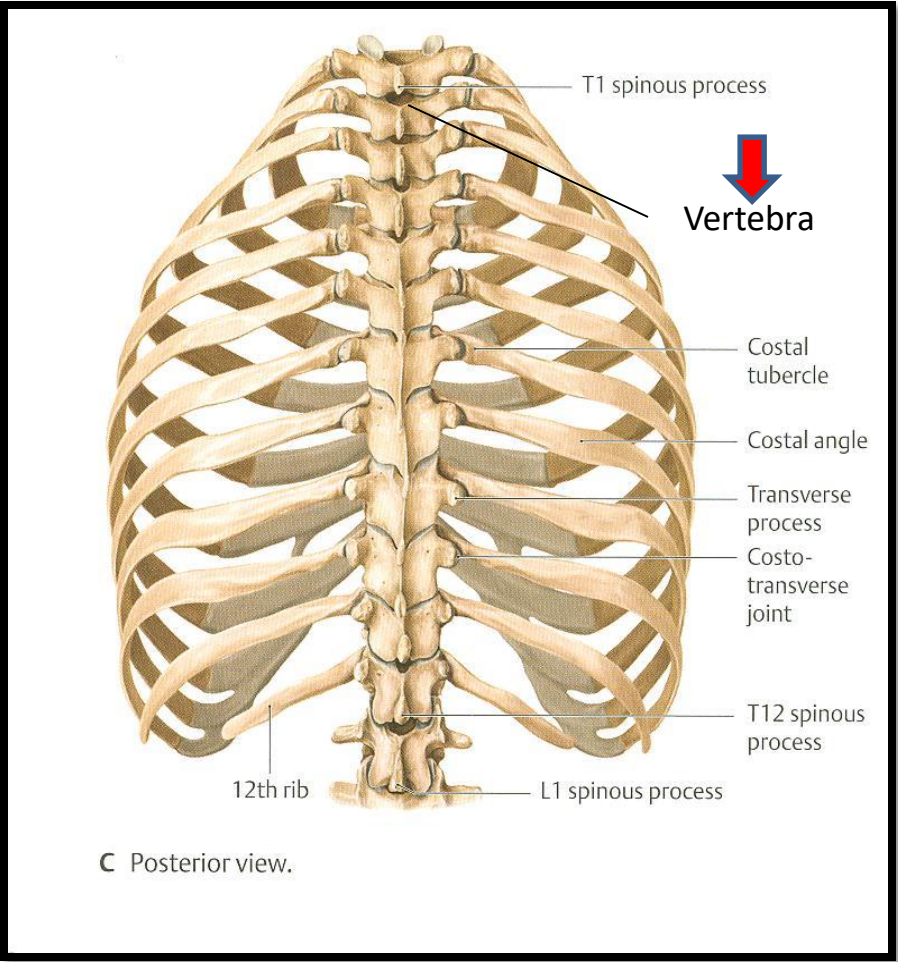
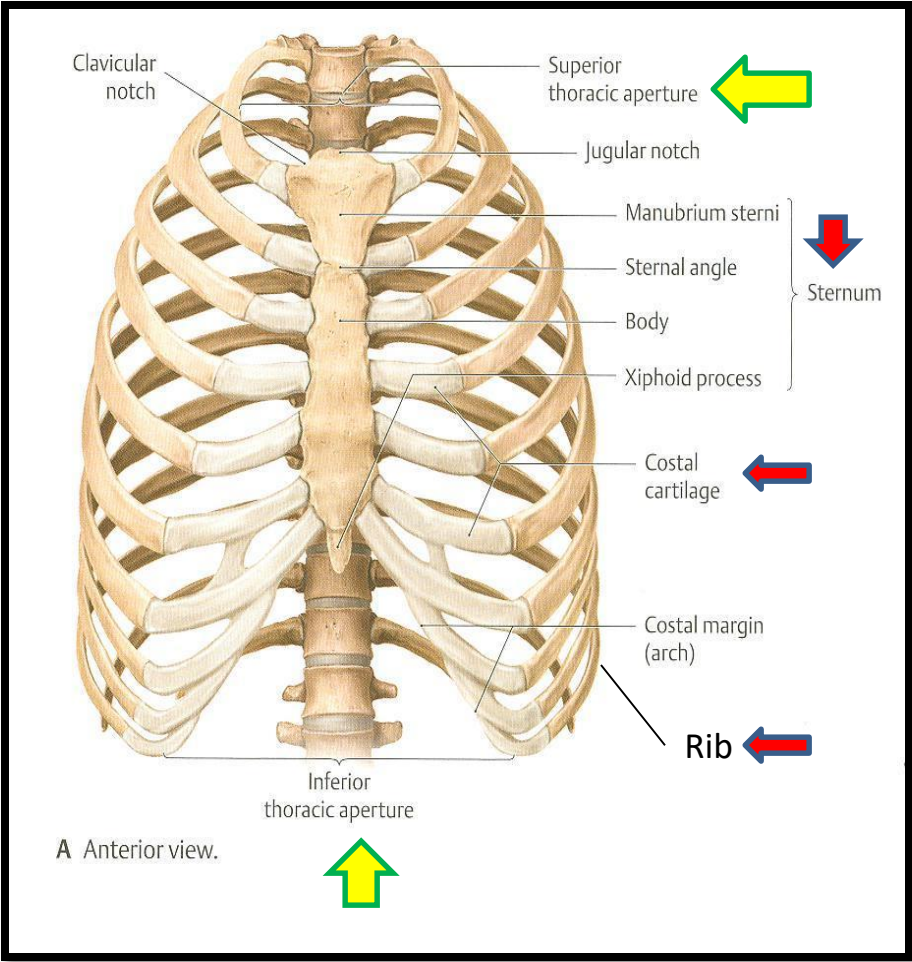
***Prof. Ahmed Fathalla Ibrahim
Professor of Anatomy
College of Medicine
King Saud University
E-mail: ahmedfathala@gmail.com***

OBJECTIVES

At the end of the lecture, students should:

- *Describe the components of the thoracic cage and their articulations.*
- *Describe in brief the respiratory movements.*
- *List the muscles involved in inspiration and in expiration.*
- *Describe the attachments of each muscle to the thoracic cage and its nerve supply.*
- *Describe the origin, insertion, nerve supply of diaphragm.*

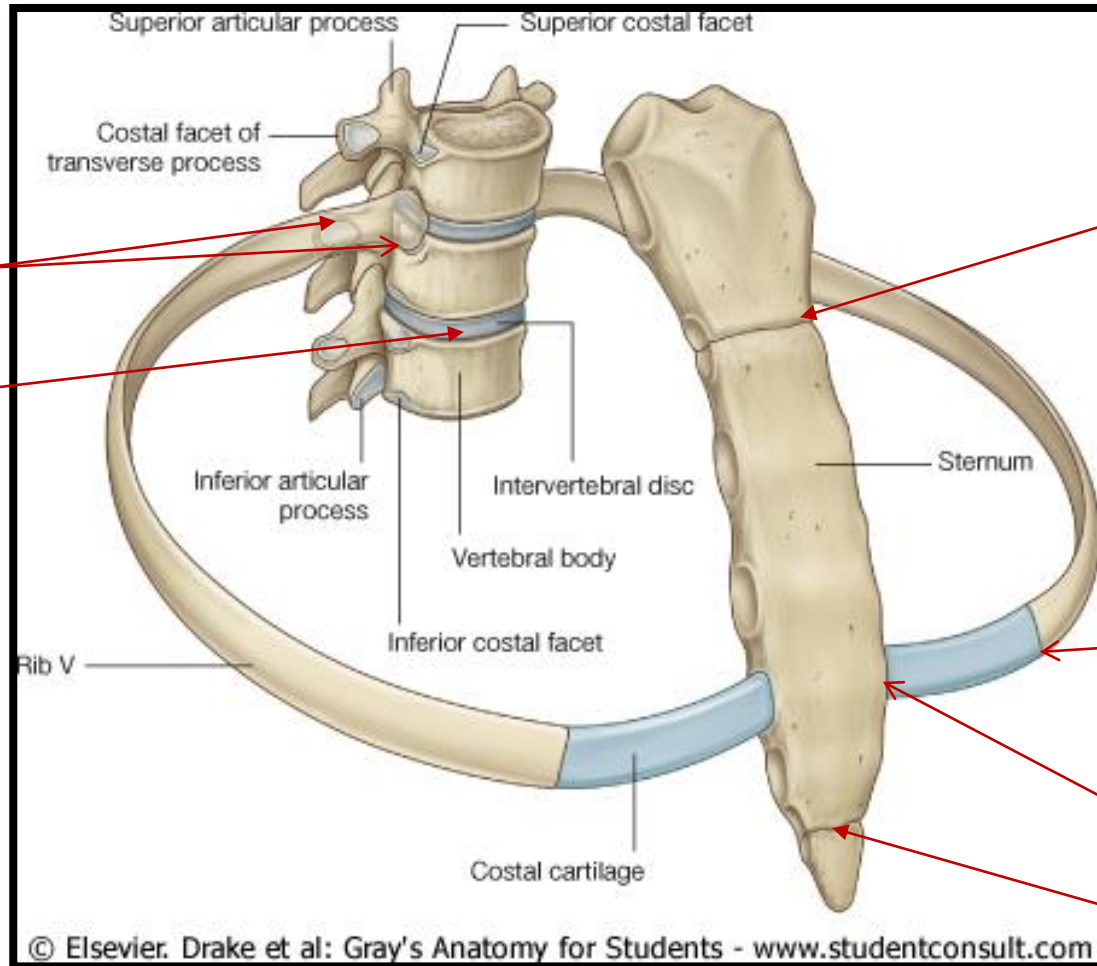
THORACIC CAGE



THORACIC CAGE

- **Conical** in shape
- **Has 2 apertures (openings):**
 1. **Superior (*thoracic outlet*):** narrow, open, continuous with neck
 2. **Inferior:** wide, closed by diaphragm
- **Formed of:**
 1. **Sternum & costal cartilages:** *anteriorly*
 2. **Twelve pairs of ribs:** *laterally*
 3. **Twelve thoracic vertebrae:** *posteriorly*

ARTICULATIONS



Costovertebral

**Intervertebral
disc**

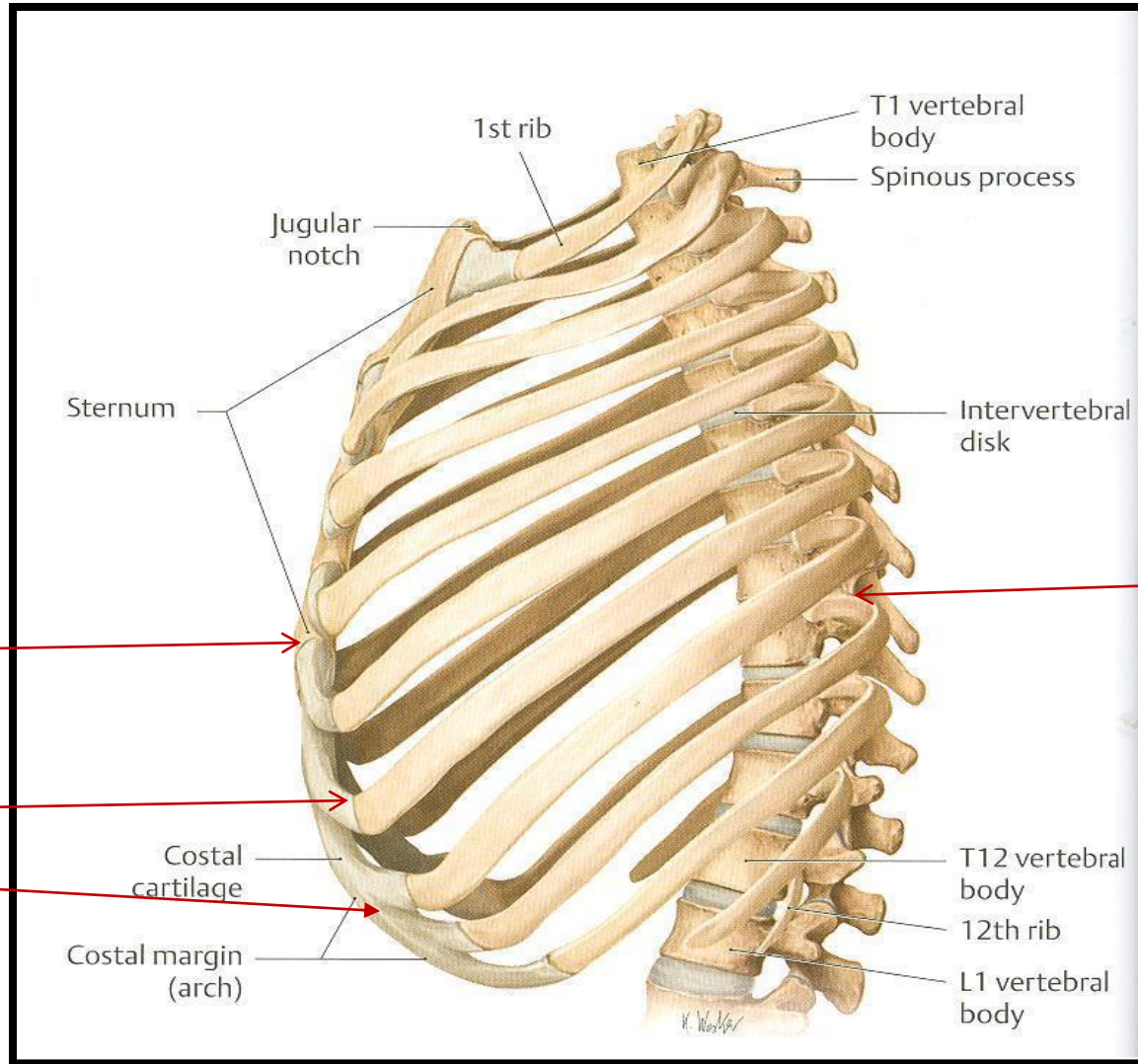
Manubriosternal

Costochondral

Sternocostal

Xiphisternal

ARTICULATIONS



Sternocostal

Costochondral

Interchondral

Costovertebral

ARTICULATIONS

- **Secondary cartilaginous:** Manubriosternal joint, Xiphisternal joint and Intervertebral discs.
- **Primary cartilaginous:** 1st Sternocostal joint, Costochondral joints and Interchondral joints.
- **Plane synovial joints:** Costovertebral joints and the rest of Sternocostal joints.

***Complete Respiration and
the 3D Diaphragm***

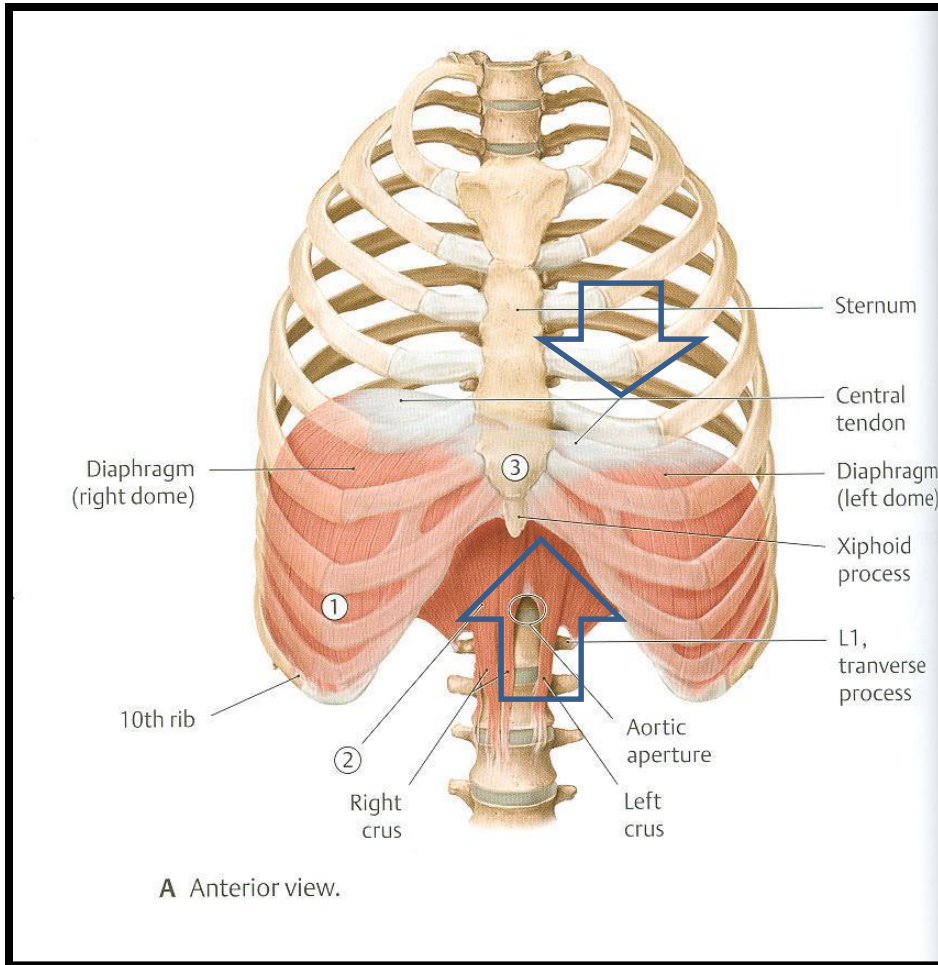
produced by
Three Treasures Studio

Copyright 2009 All Rights Reserved

visit www.3d-yoga.com for more information

RESPIRATORY MOVEMENTS

A- MOVEMENTS OF DIAPHRAGM



Inspiration

Contraction (descent)
of diaphragm



Increase of vertical diameter
of thoracic cavity

Relaxation (ascent)
of diaphragm)

Expiration

RESPIRATORY MOVEMENTS

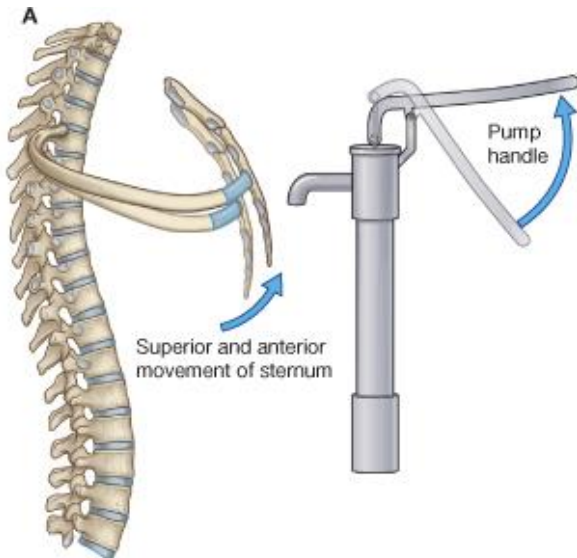
B- MOVEMENTS OF RIBS

PUMP HANDLE MOVEMENT

Elevation of ribs



Increase in antero-posterior diameter of thoracic cavity

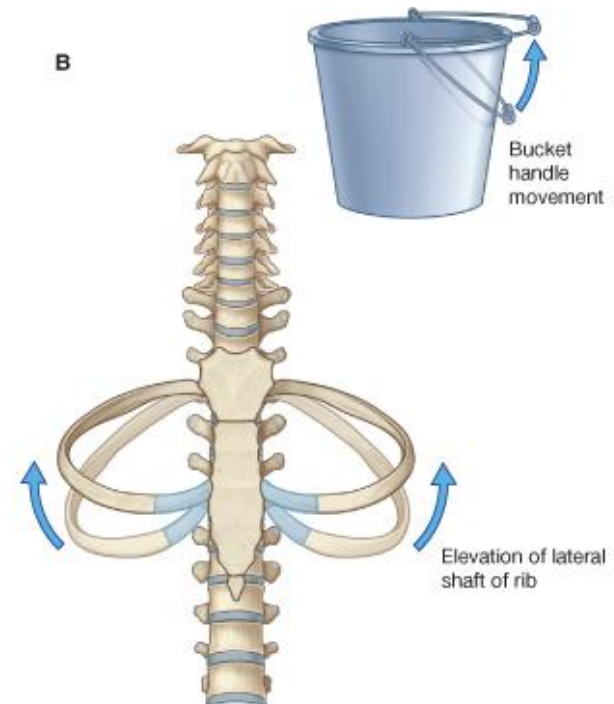


BUCKET HANDLE MOVEMENT

Elevation of ribs



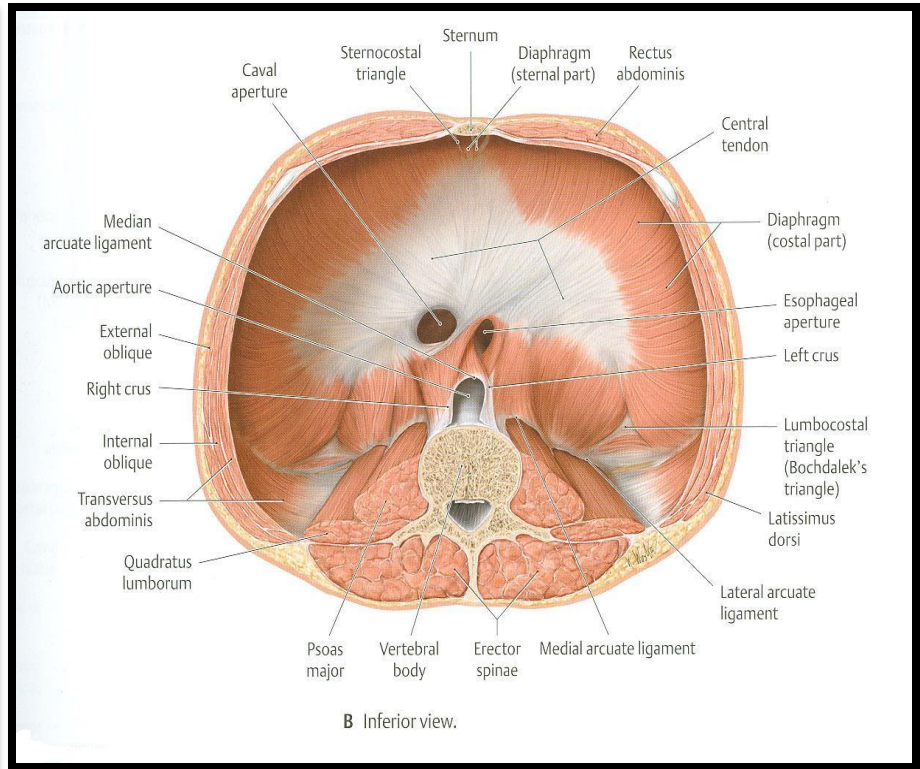
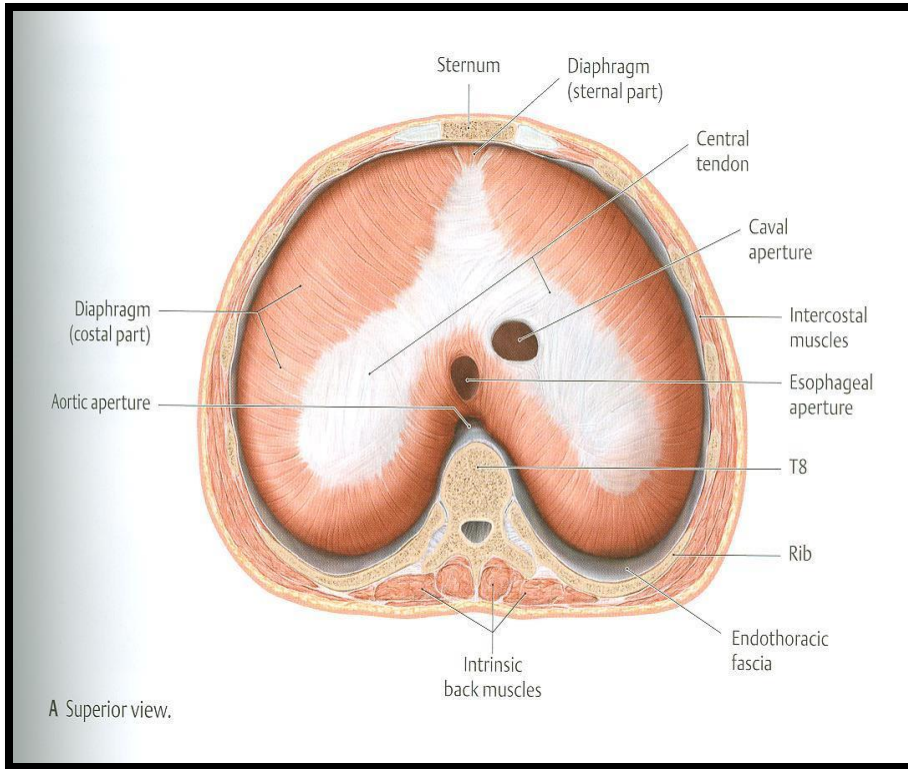
Increase in lateral diameter of thoracic cavity



INSPIRATORY MUSCLES

- ❑ **Diaphragm** (most important muscle)
- ❑ **Rib elevators: external intercostal muscles**
- ❑ **Accessory muscles** (only during forced inspiration), such as:
 1. **Muscles attaching cervical vertebrae to first & second rib: scalene muscles**
 2. **Muscles attaching thoracic cage to upper limb: pectoralis major, pectoralis minor, serratus anterior.**
 3. **Muscles attaching thoracic cage to skull: sternocleidomastoid.**

INSERTION OF DIAPHRAGM (CENTRAL TENDON)



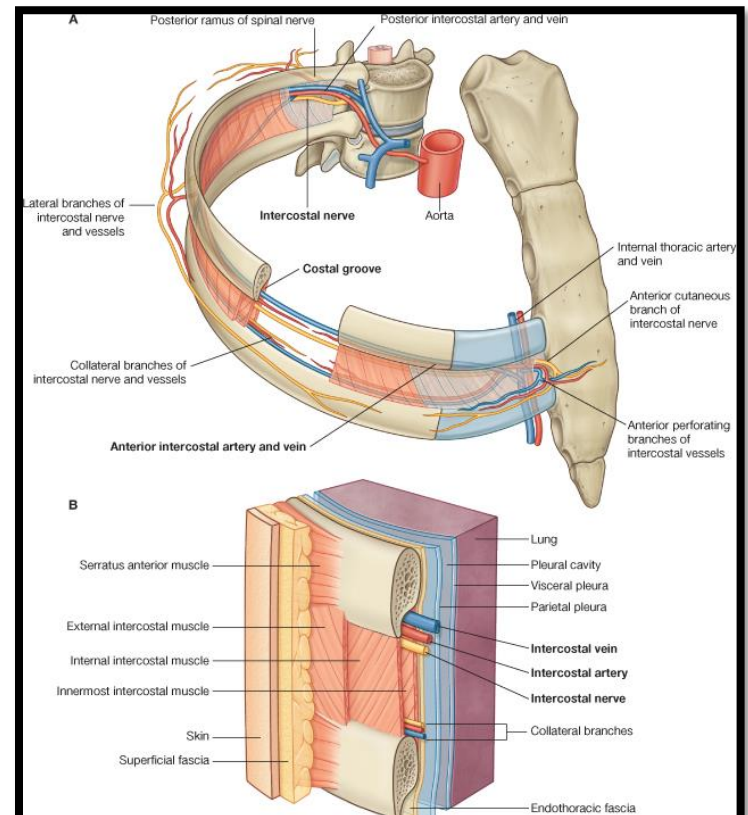
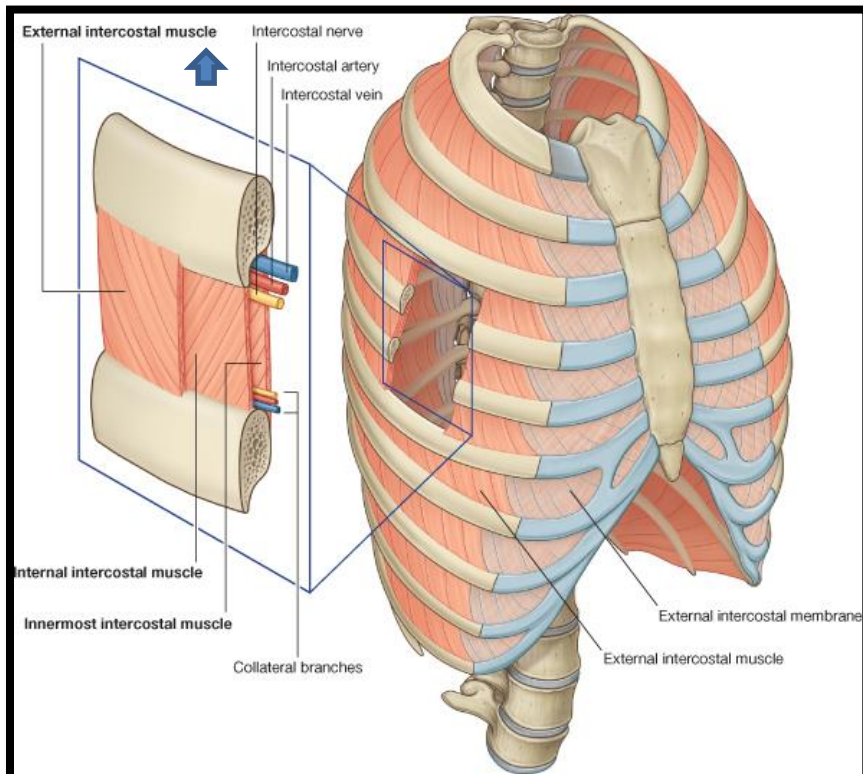
DIAPHRAGM

- **A musculotendinous partition** between thoracic & abdominal cavity.
- **Convex** toward thoracic & **concave** toward abdominal cavity.
- **Attached to:** sternum, costal cartilages, 12th rib & lumbar vertebrae.
- **Fibers converge to join the central tendon.**
- **Nerve supply:** **phrenic nerve (C3,4,5)**, penetrates diaphragm & innervates it from abdominal surface
- **Action:** contraction (descent) of diaphragm increase vertical diameter of thoracic cavity (**essential for normal breathing**).

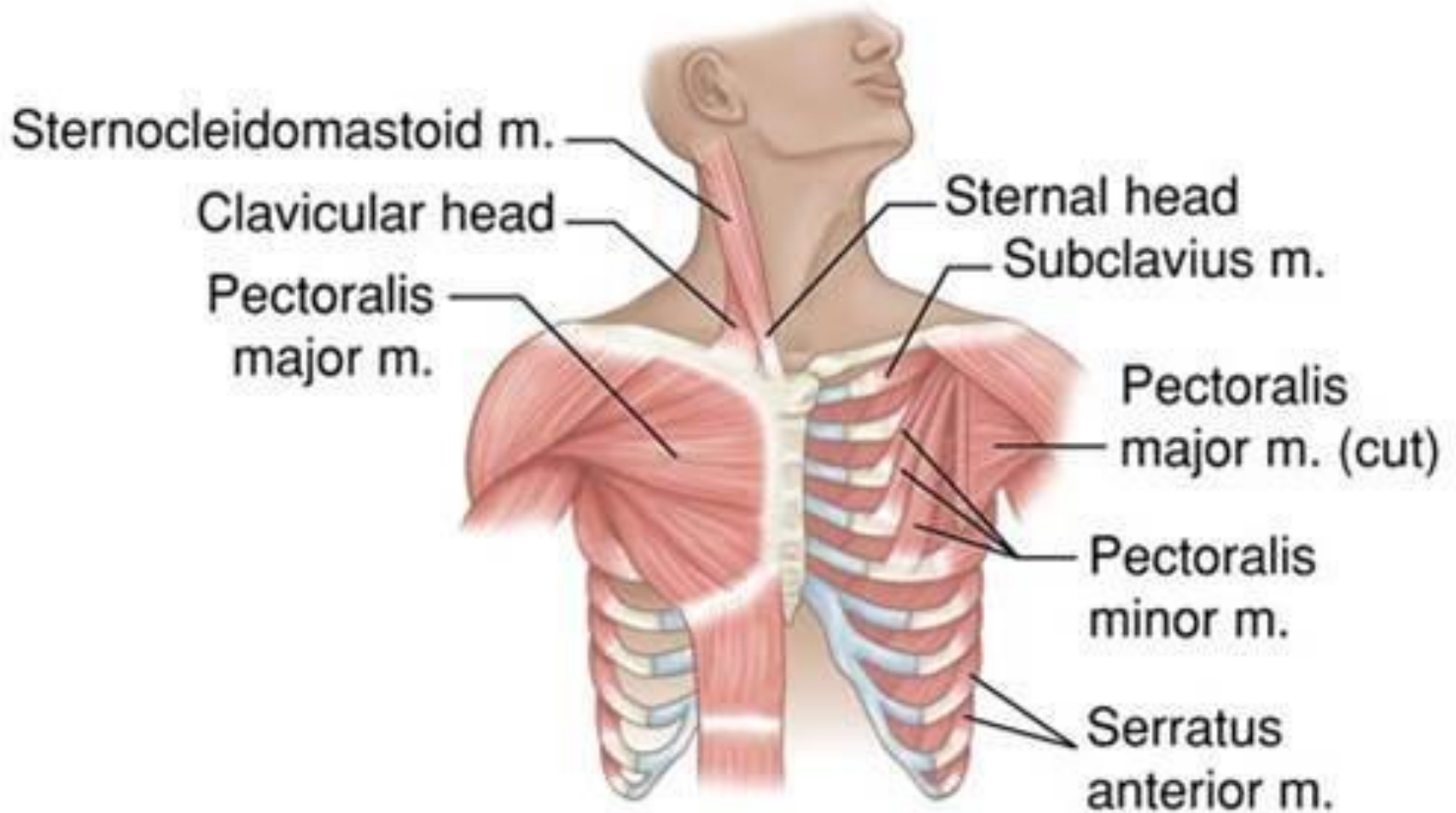
EXTERNAL INTERCOSTAL

- **Attachments:** from lower border of rib above to upper border of rib below
- **Direction of fibers:** downward & medially

- **Nerve supply:** intercostal nerves
- **Action:** rib elevators (inspiratory)

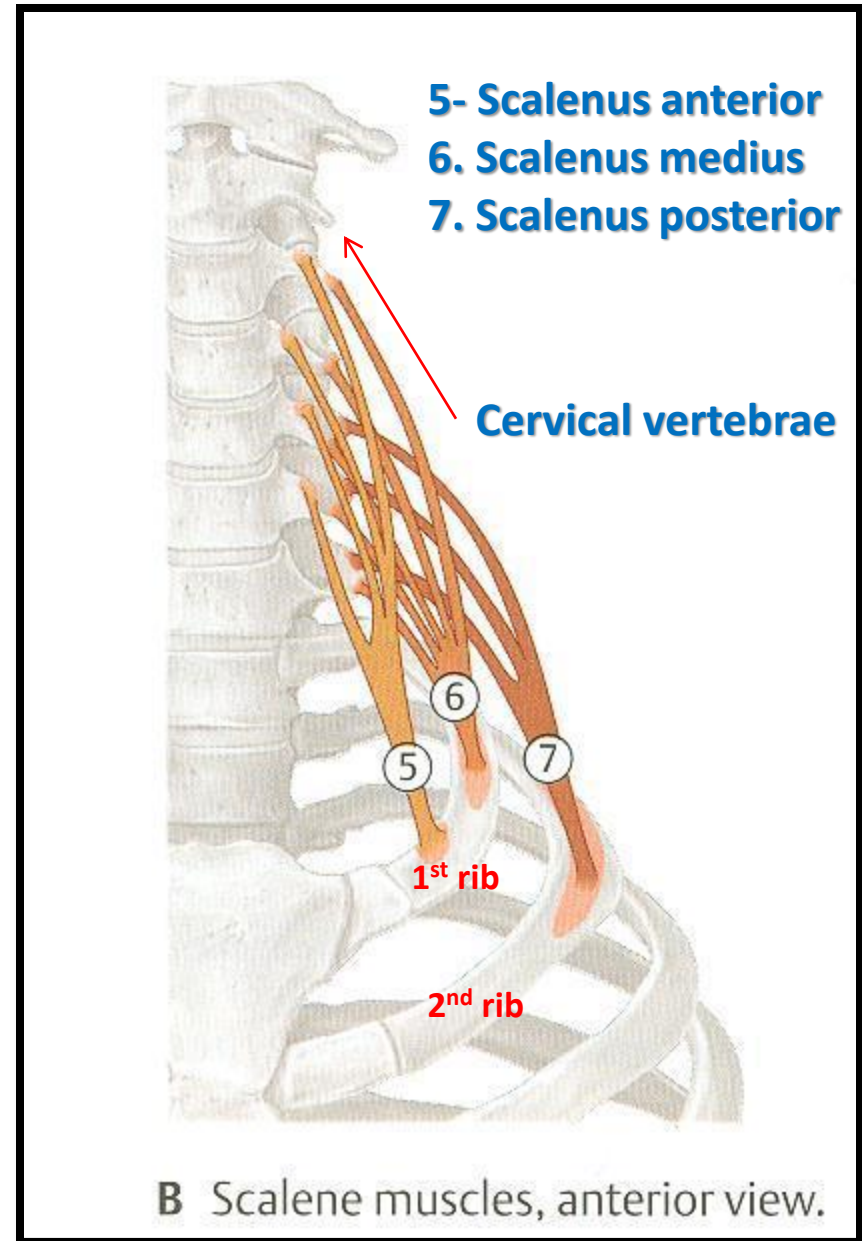


ACCESSORY MUSCLES OF INSPIRATION



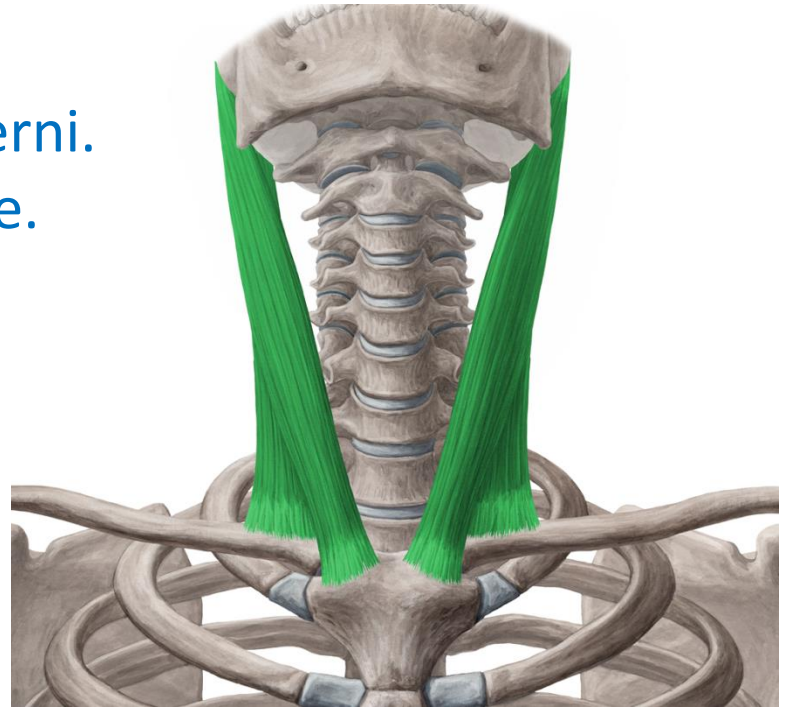
SCALENE MUSCLES

- **Origins:** cervical vertebrae
- **Insertions:** 1st rib (scalenus anterior and medius) & 2nd rib (scalenus posterior)
- **Action:** elevate 1st & 2nd ribs (inspiratory)



STERNOCLEIDOMASTOID

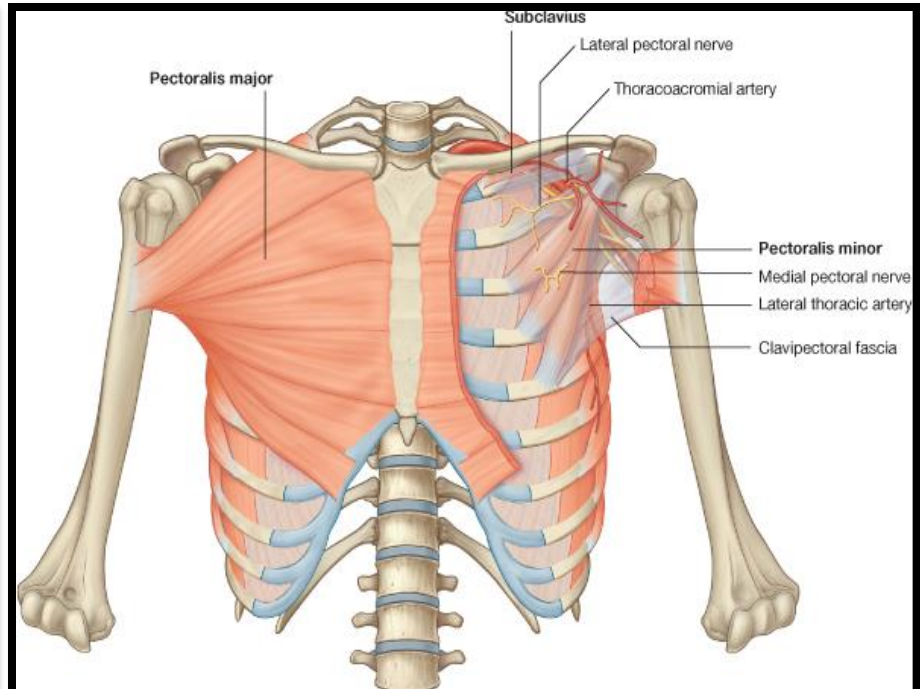
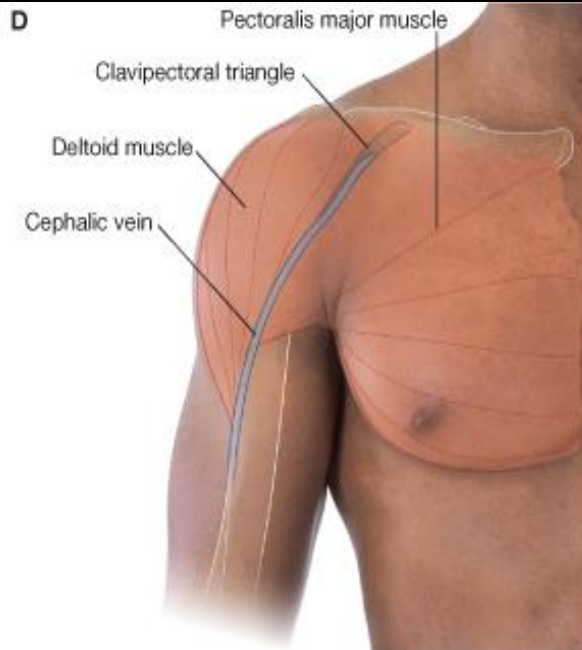
- **Origin:**
- **Sternal head:** front of manubrium sterni.
- **Clavicular head:** medial 1/3 of clavicle.
- **Insertion:** mastoid process.
- **Action:** elevates the manubrium.



PECTORALIS MAJOR

- **Origin:** clavicle + sternum + costal cartilages
- **Insertion:** humerus

- **Action:** increases antero-posterior diameter of thoracic cavity, when arm is fixed (inspiratory)



EXPIRATORY MUSCLES

□ Act only during forced expiration

- Rib depressors:

1. Internal intercostal
2. Innermost intercostal
3. Subcostals
4. Transversus thoracis

- Anterior abdominal wall muscles:

1. External oblique
2. Internal oblique
3. Transversus abdominis
4. Rectus abdominis

RIB DEPRESSORS: REST OF INTERCOSTAL MUSCLES

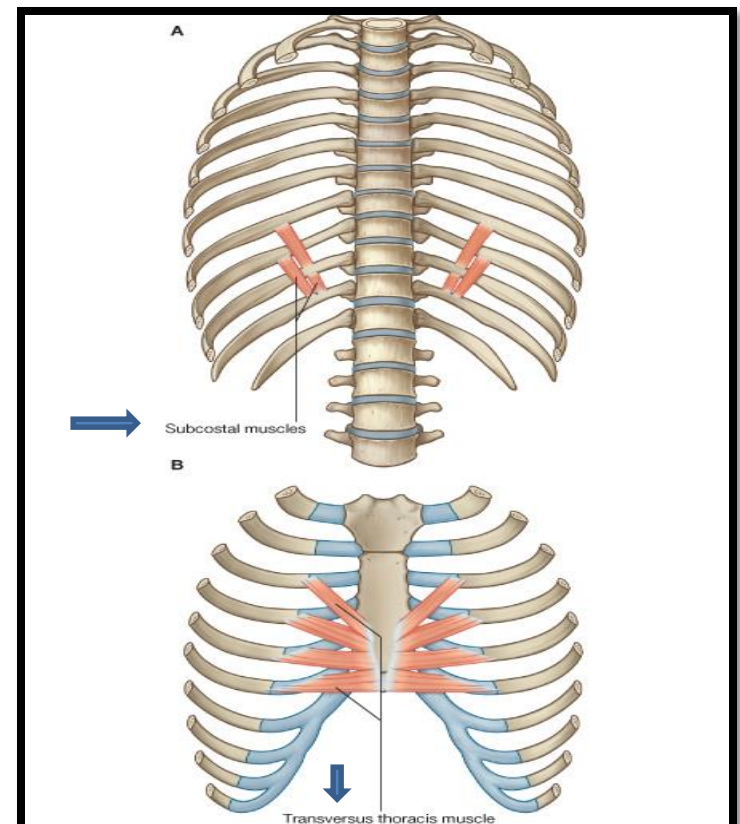
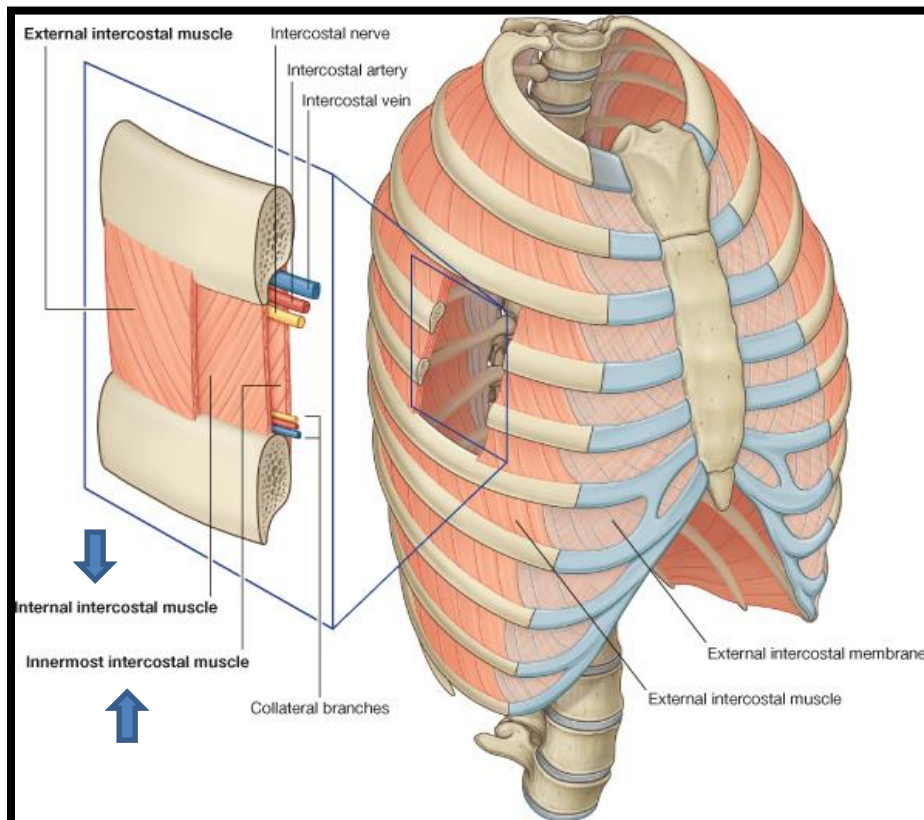
1. Internal intercostal
2. Innermost intercostal

Direction: backward & laterally

3. Subcostal

4. Transversus thoracis

Nerve supply: intercostal nerves (ventral rami of T1-T11)

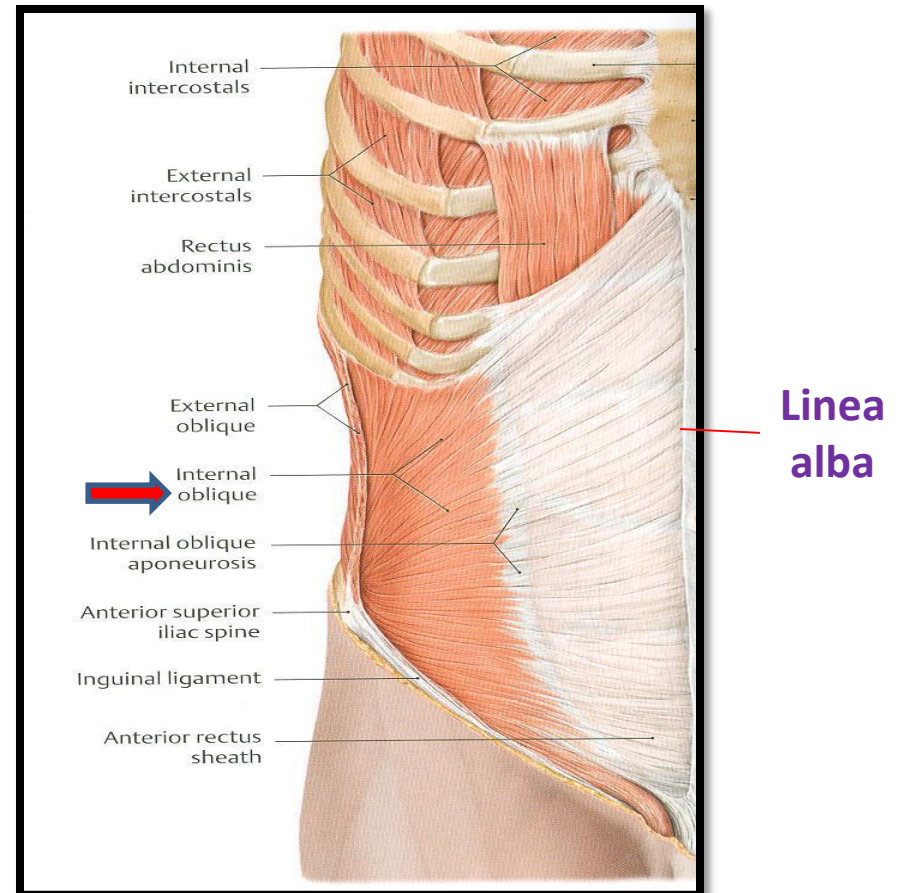
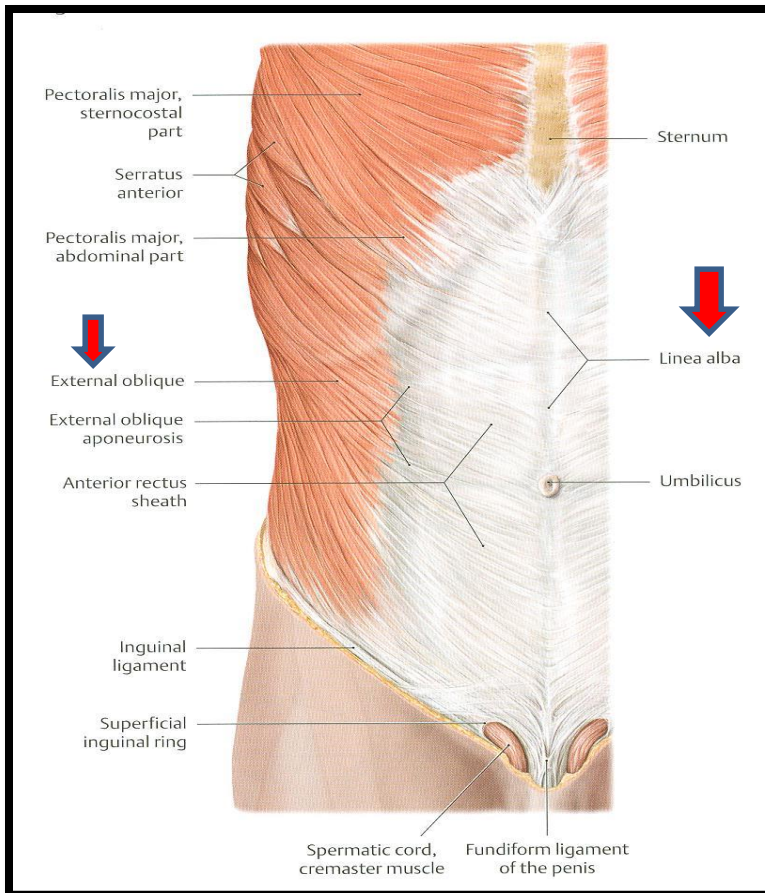


ANTERIOR ABDOMINAL WALL

External oblique (outer layer) Internal oblique (middle layer)

▪ **Direction:** downward & medially

▪ **Direction:** upward & medially



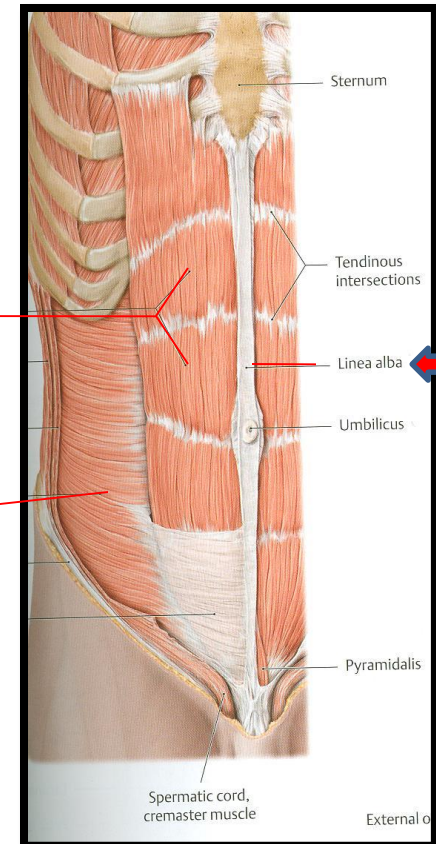
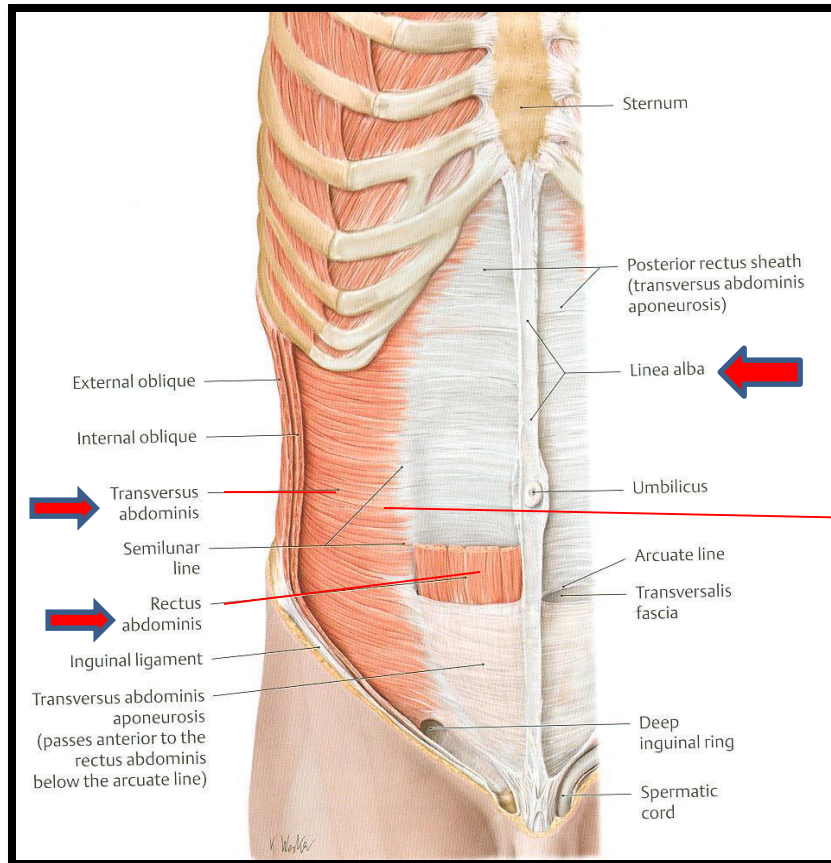
ANTERIOR ABDOMINAL WALL

Transversus abdominis (inner layer)

▪ **Direction:** transverse

Rectus abdominis

▪ **Direction:** vertical



Rectus abdominis

Transversus abdominis

Anterior abdominal wall

- ❑ Is formed of 3 layers of muscles of fibers running in different directions (to increase strength of anterior abdominal wall)
- ❑ The 3 muscles form a sheath in which a fourth muscle lies (rectus abdominis)
- ❑ Muscles are attached to: sternum, costal cartilages and ribs + hip bones
- ❑ The aponeurosis of the 3 muscles on both sides fuse in the midline to form linea alba
- ❑ **Action (during forced expiration):** Compression of abdominal viscera to help in ascent of diaphragm (during forced expiration)
- ❑ **Nerve supply:** lower 5 intercostal nerves (T7 – T11), subcostal nerve (T12) and first lumbar nerve.

SUMMARY OF RESPIRATORY MOVEMENTS

Inspiration

Expiration

▪ Quiet Inspiration (active)

Contraction (Descent) of diaphragm

Elevation of ribs (external intercostal)



Increase in **vertical** diameter

Increase in:
- **anteroposterior** diameter
- **lateral** diameter

▪ Forced Inspiration (active)

Accessory muscles of inspiration:

1. Pectoralis major
2. Scalene muscles

▪ Quiet Expiration (passive)

1. Elastic recoil of lung
2. Relaxation of diaphragm & external intercostal

▪ Forced Expiration (active):

Contraction of anterior abdominal wall muscles

Depression of ribs (rest of intercostal muscles)



Compression of abdominal viscera



Ascent of diaphragm

QUESTIONS

- **Are the following muscles have a respiratory role? If yes, what is it?**
 1. **Levatores costarum.**
 2. **Serratus posterior superior.**
 3. **Serratus posterior inferior.**
 4. **Pectoralis minor.**
 5. **Serratus anterior.**
 6. **Latissimus dorsi.**
 7. **Quadratus lumborum.**
- **Why diaphragm is supplied by cervical nerves?**
- **Why right crus of diaphragm is larger than left crus?**



THANK YOU