

اللهم لا سهل الا ما جعلته سهلا
واب لا يعجز احد الا ما سببته سهلا

Histology

OSPE



Males slides only

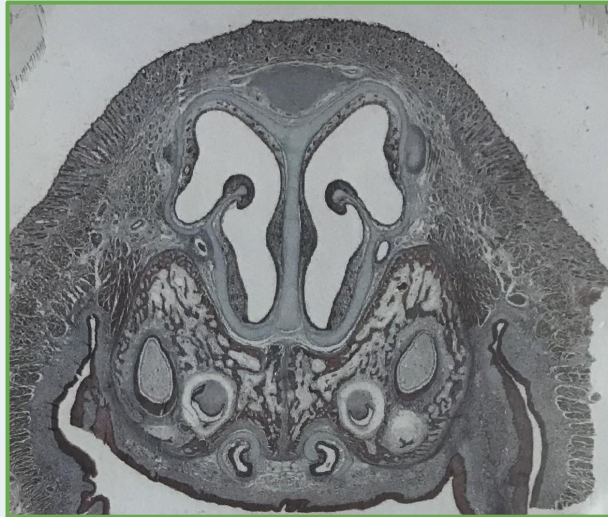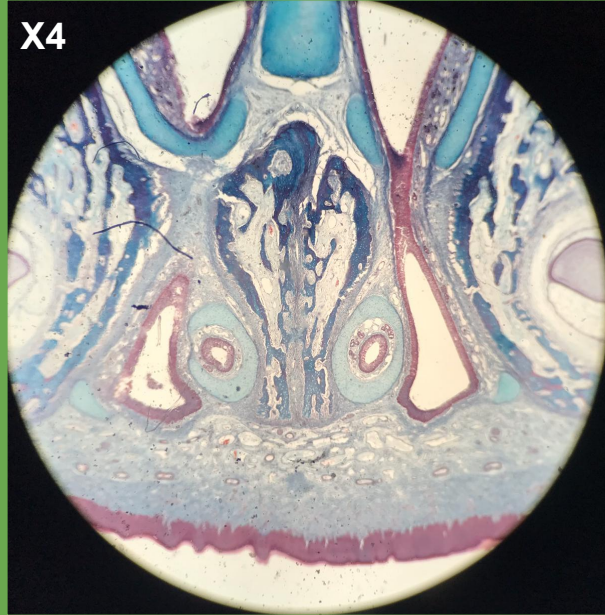


Important Notes

- There are multiple magnifications of the same slide.
- The corresponding magnification level of the slide is written in the upper-left corner of each picture.
- Some of the pictures have a **red** or **blue** colored frame which represents a certain area in the previous magnification level.

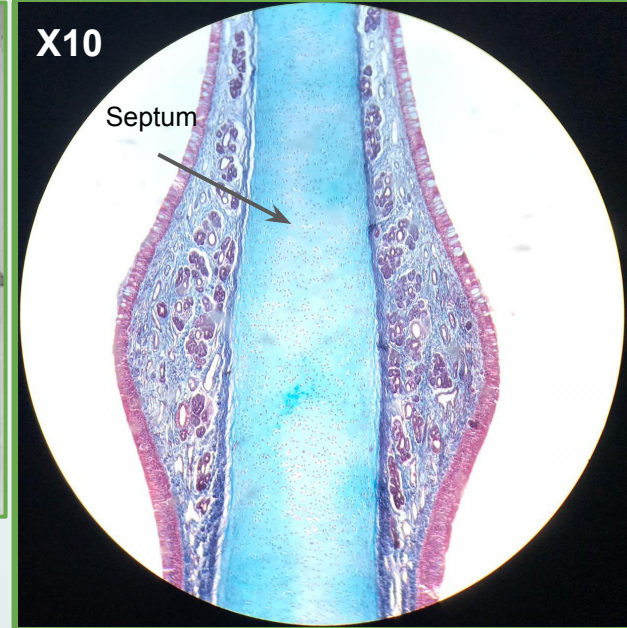
Nasal cavity and septum

X4

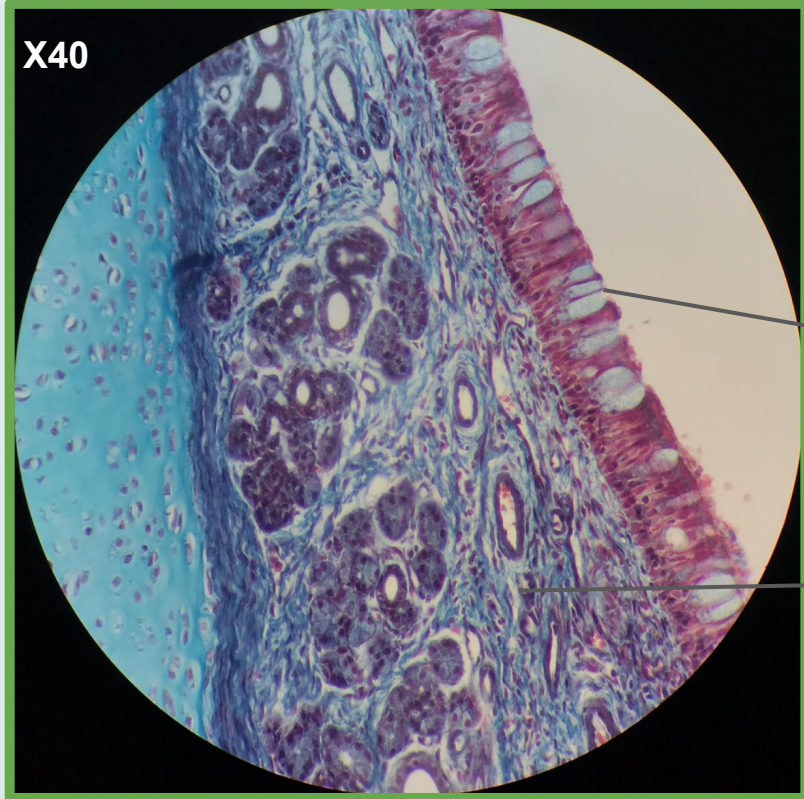


HINT: you can identify and see the picture above on the slide grossly (without the need of microscope)

X10



Nasal mucosa (Pseudo-stratified ciliated columnar epithelium with goblet cells & lamina propria) of the nasal cavity



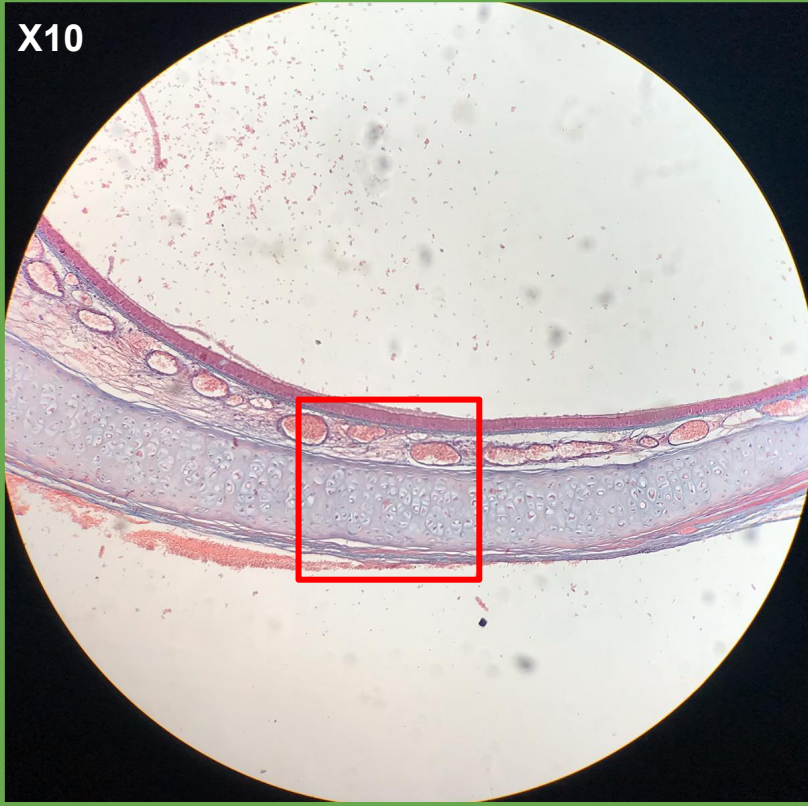
IMPORTANT NOTE: you **HAVE** to write the full name of the slide above, if the focus was on the epithelium

Respiratory Epithelium
(Pseudo-stratified ciliated columnar
epithelium with goblet cells & lamina
propria)

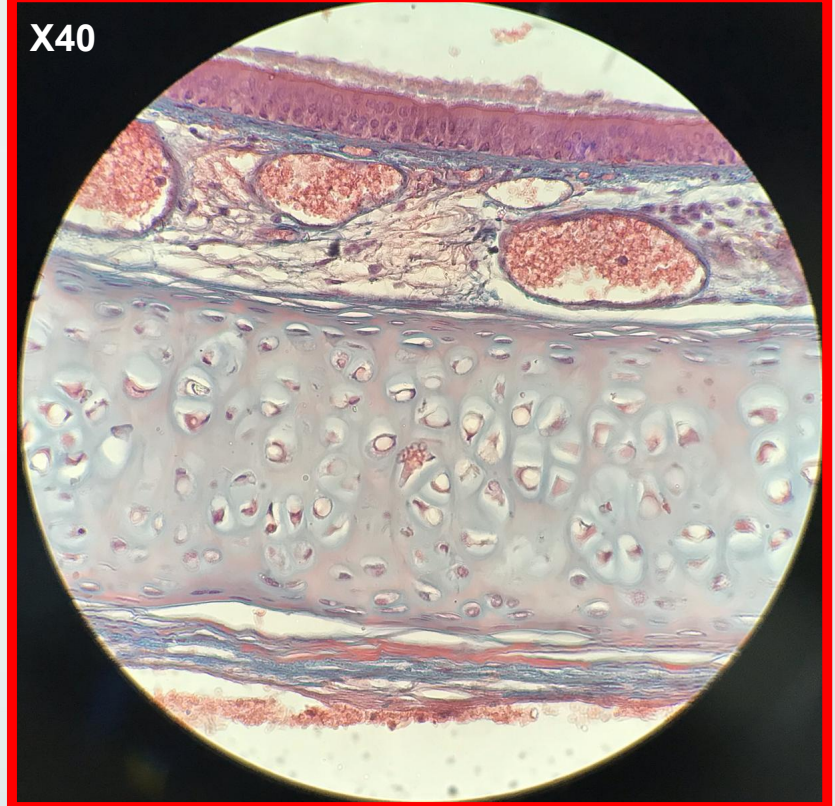
Lamina propria

Trachea

X10

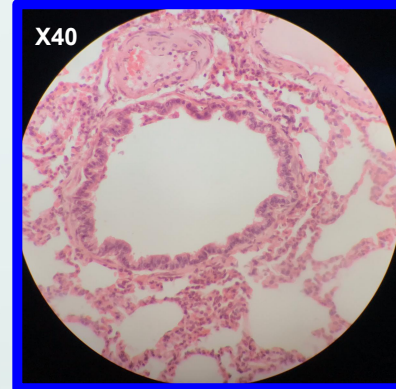
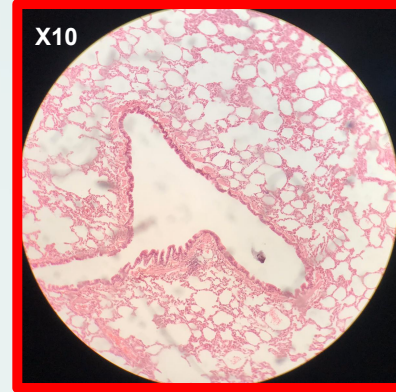
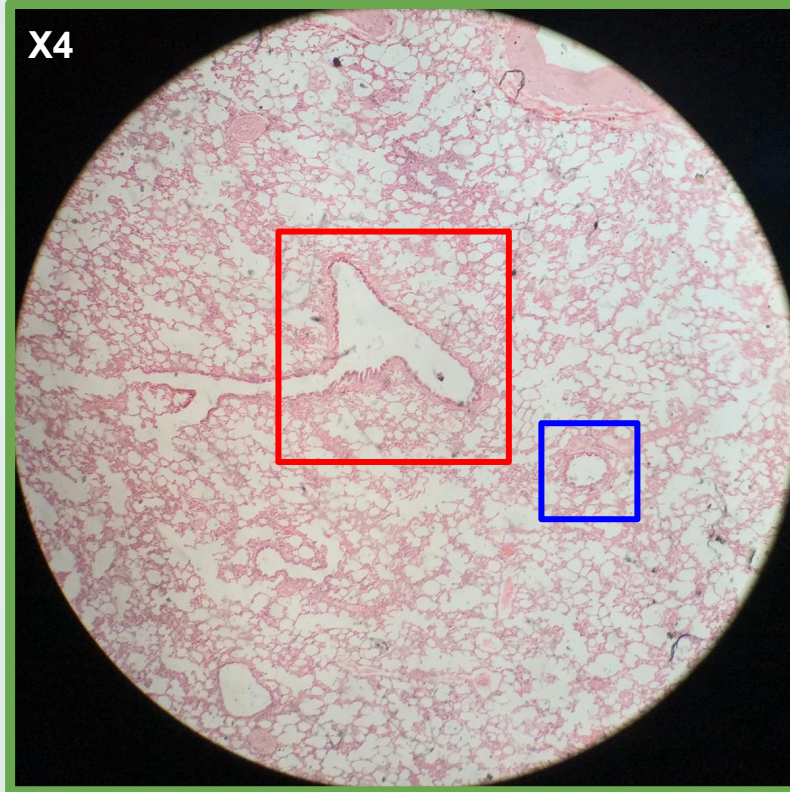


X40



Lung-Bronchiole

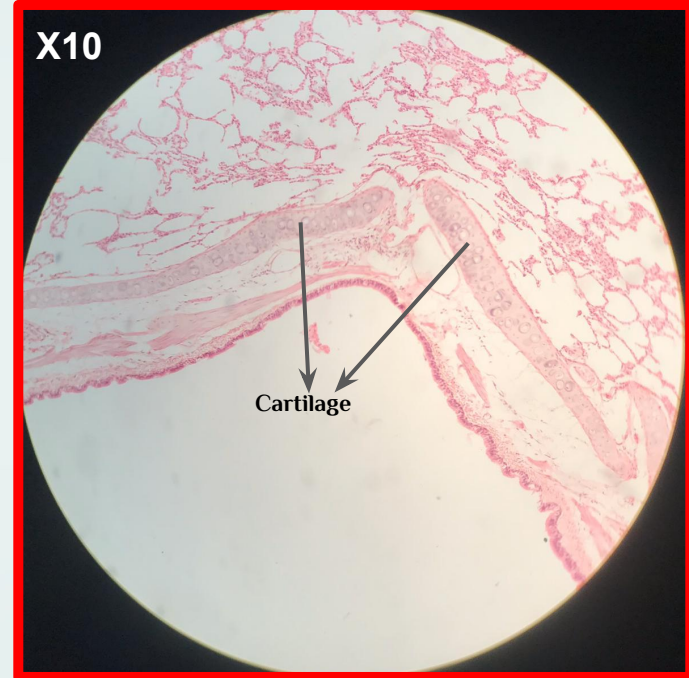
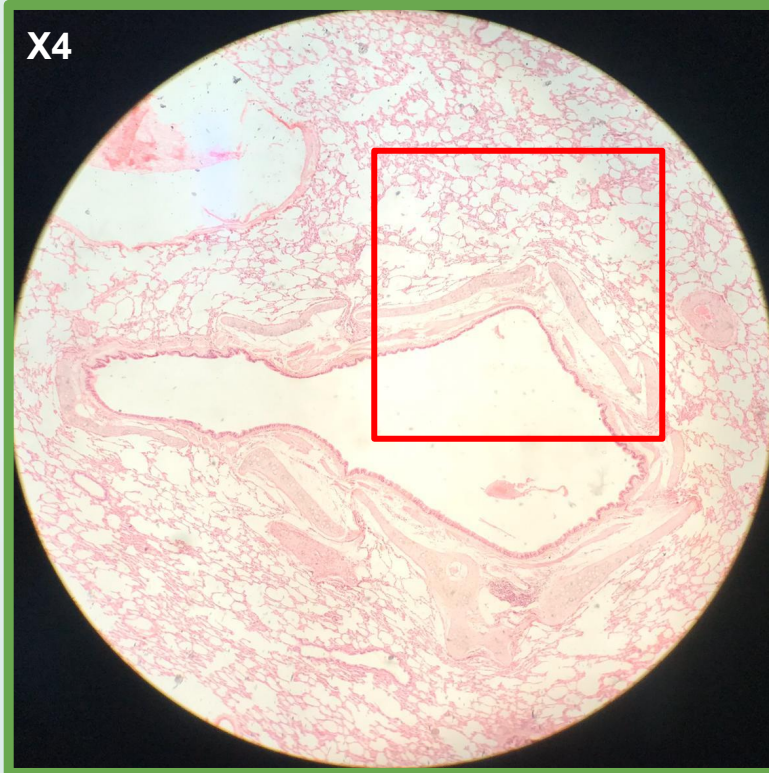
L.S. & T.S.



L.S.

T.S.

Lung-Intrapulmonary bronchus



IMPORTANT NOTE: You MUST differentiate between bronchi and bronchioles. Bronchi is surrounded by cartilage.

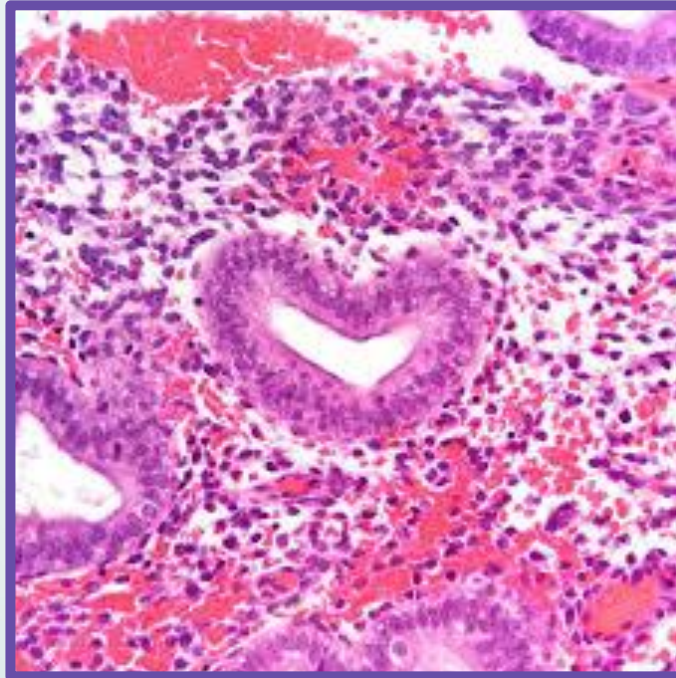
Quizzes!!

I bet you guys to answer the last question



Good luck and best wishes for all

See you next block





Team leaders

Fatimah Alhelal
 Albara Aldawoud



اللهم علما مايتفعا ، وانفعنا
بما علمتنا وزدنا علما يارب
العالمين



Any future corrections will be
in the editing file.
Click [Here](#)

Team members


Afnan AlMohsen
Nourah Alklaib
Sumo Abdulrahman
Mariam Alruhaimi
Joud Alarifi



Team members

Yazeed Alomar
Abdulmohsen Albeshar
Mohamed Albabtain
Mohammed Ben Hajji
 Abdullah Alburikan
 Nawaf Alshahrani
Mohamed Alquhidan



Contact us through :
 Histologyteam439@gmail.com