

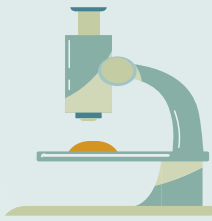
اللهم لا سهل الا ما جعلته سهلا  
وابد يجعل اجتناب السهلا

# Histology

## OSPE



**\*For Girls Only**




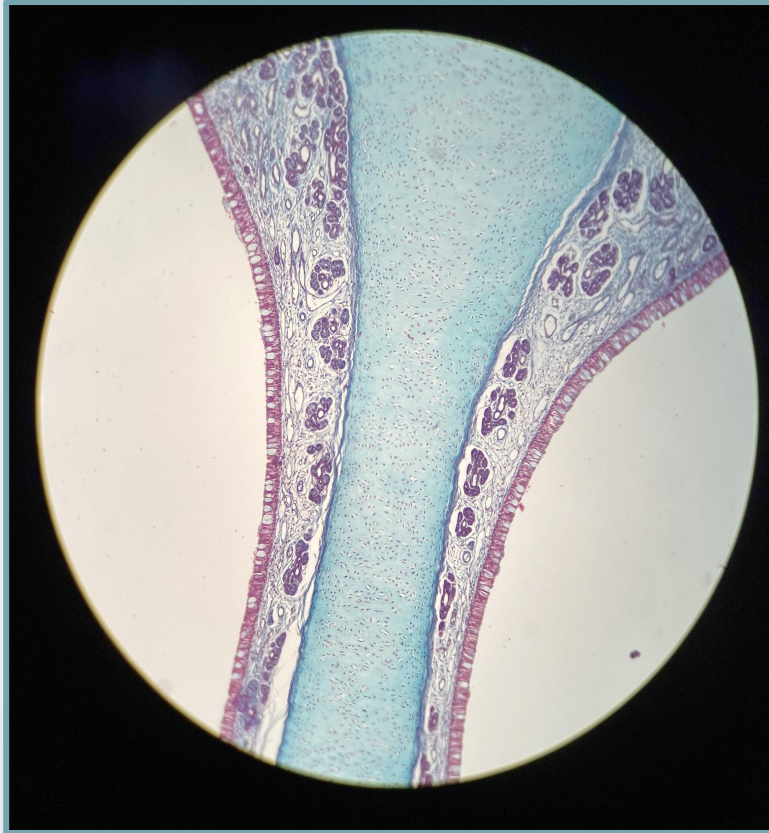
## **Note :**

- 1-Only one station for histology in this block
- 2-The question will be identifying the structure only
- 3-Make sure you write the full name with correct spelling for each section.

# Nasal septum

Q1- Identify the structure?

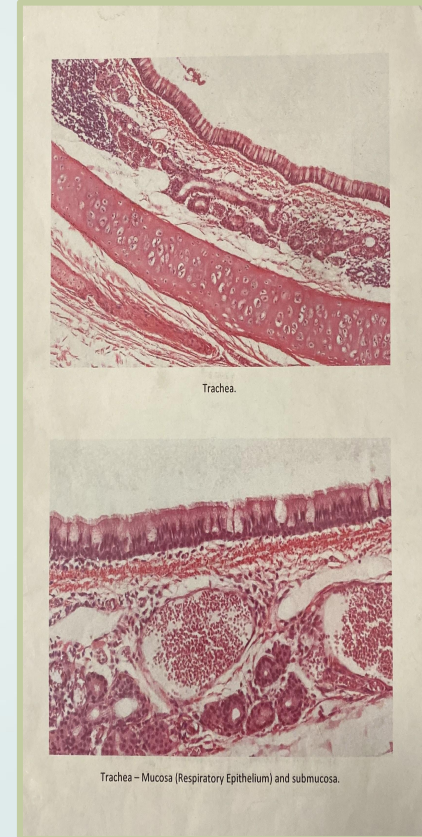
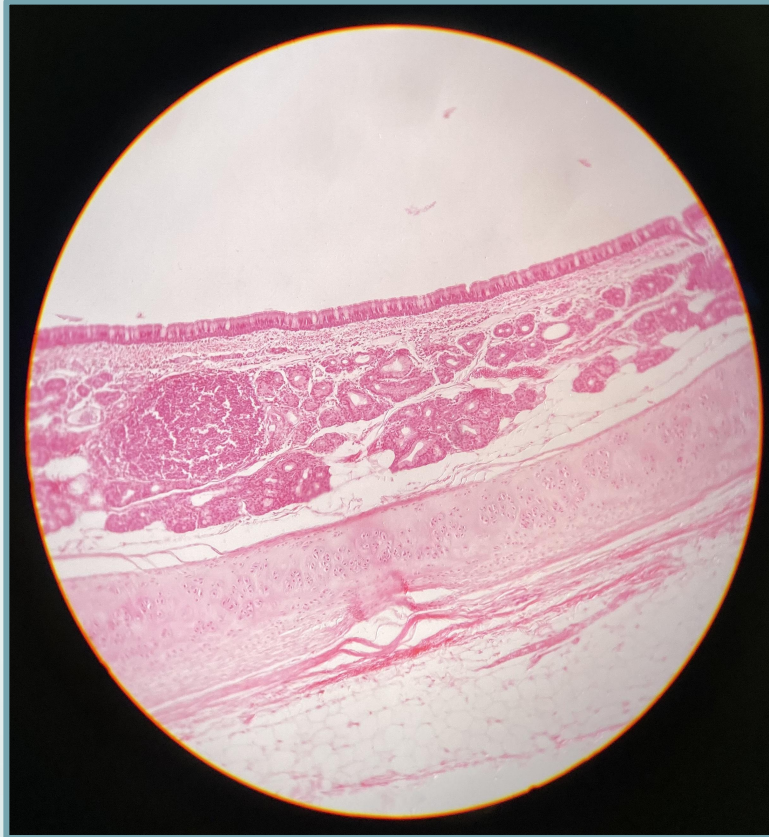
Nasal septum



# Trachea

Q1- Identify the structure?

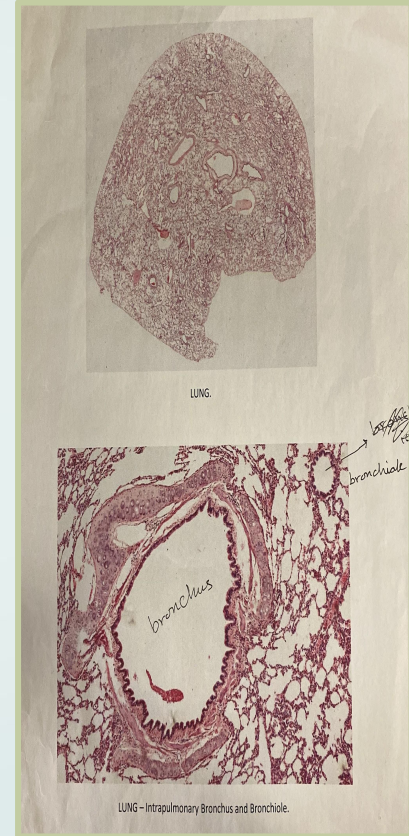
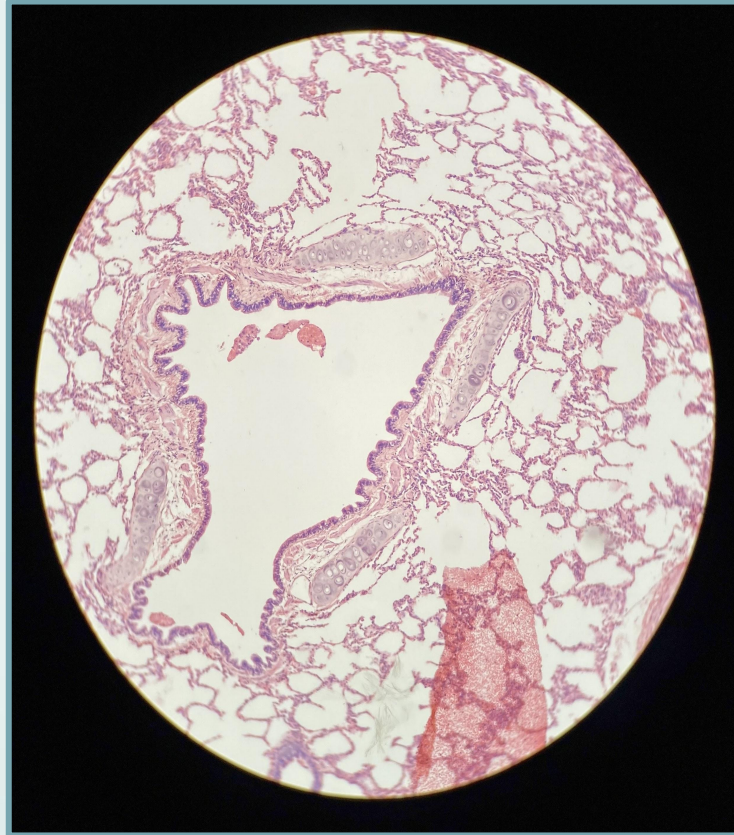
Trachea



# Lung-Intrapulmonary bronchus

Q1- Identify the structure?

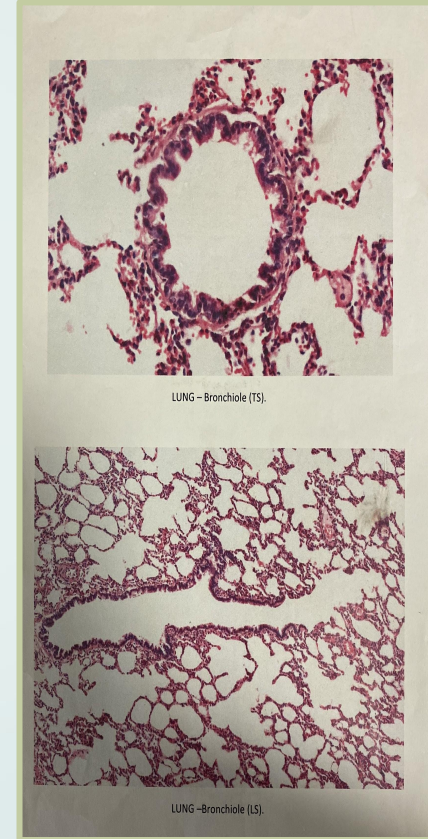
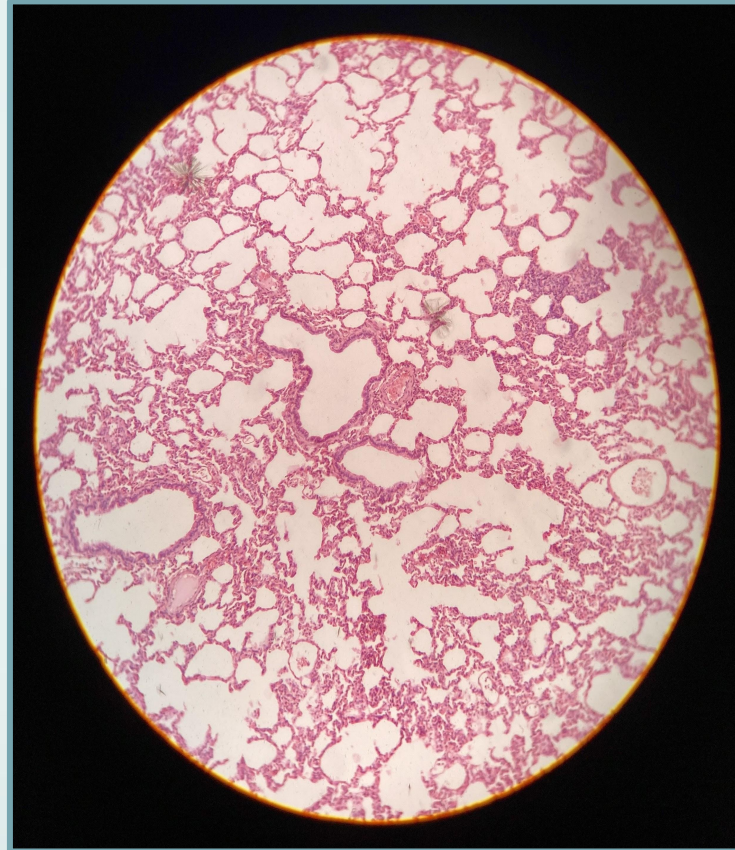
Lung-Intrapulmonary bronchus



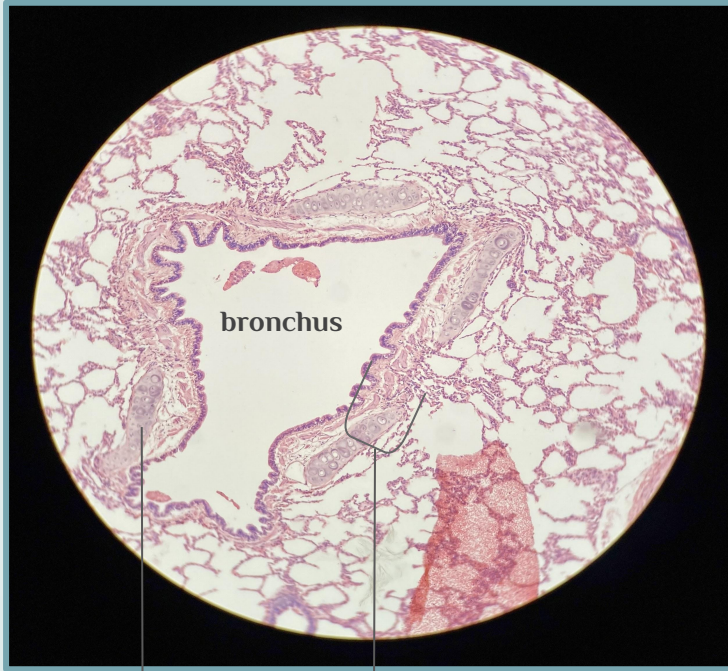
# Lung-Bronchiole

Q1- Identify the structure?

Lung-Bronchiole

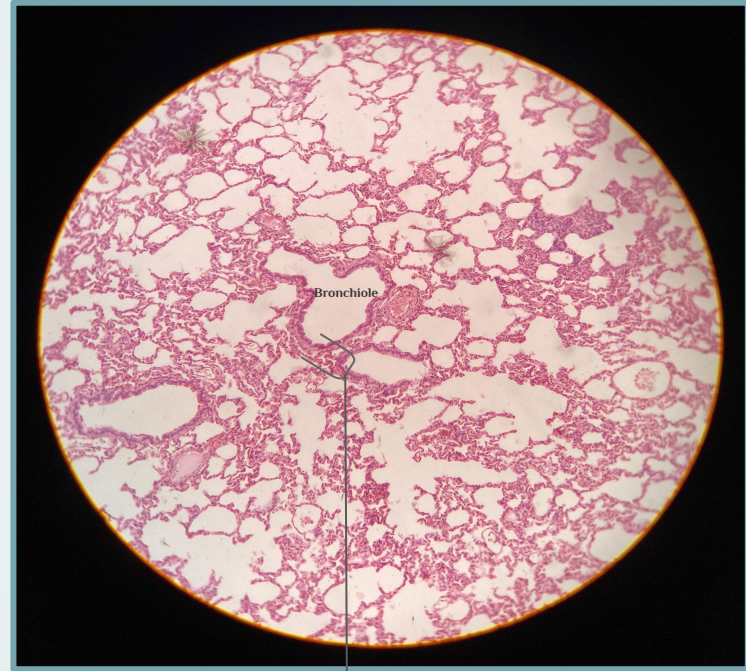


## How to differentiate between Intrapulmonary bronchus and bronchiole



Cartilage

Thick wall



Thin wall

No cartilage

Good luck!



## Team leaders

Fatimah Alhelal  
Albara Aldawoud



اللهم علما مايتفعا ، وانفعنا  
بما علمتنا وزدنا علما يارب  
العالمين

Any future corrections will be  
in the editing file.  
Click [Here](#)

## Team members

Afnan AlMohsen  
Nourah Alklaib  
Sumo Abdulrahman  
Mariam Alruhaimi  
Joud Alarifi



## Team members

Yazeed Alomar  
Abdulmohsen Albeshar  
Mohamed Albabtain  
Mohammed Ben Hajji  
Abdullah Alburikan  
Nawaf Alshahrani  
Mohamed Alquhidan



Contact us through :  
[Histologyteam439@gmail.com](mailto:Histologyteam439@gmail.com)

