

# ***CARDIOVASCULAR SYSTEM***

## ***Pathology Practical 1***

Prepared by:

- *Prof. Ammar Al Rikabi*
- *Dr. Sayed Al Esawy*

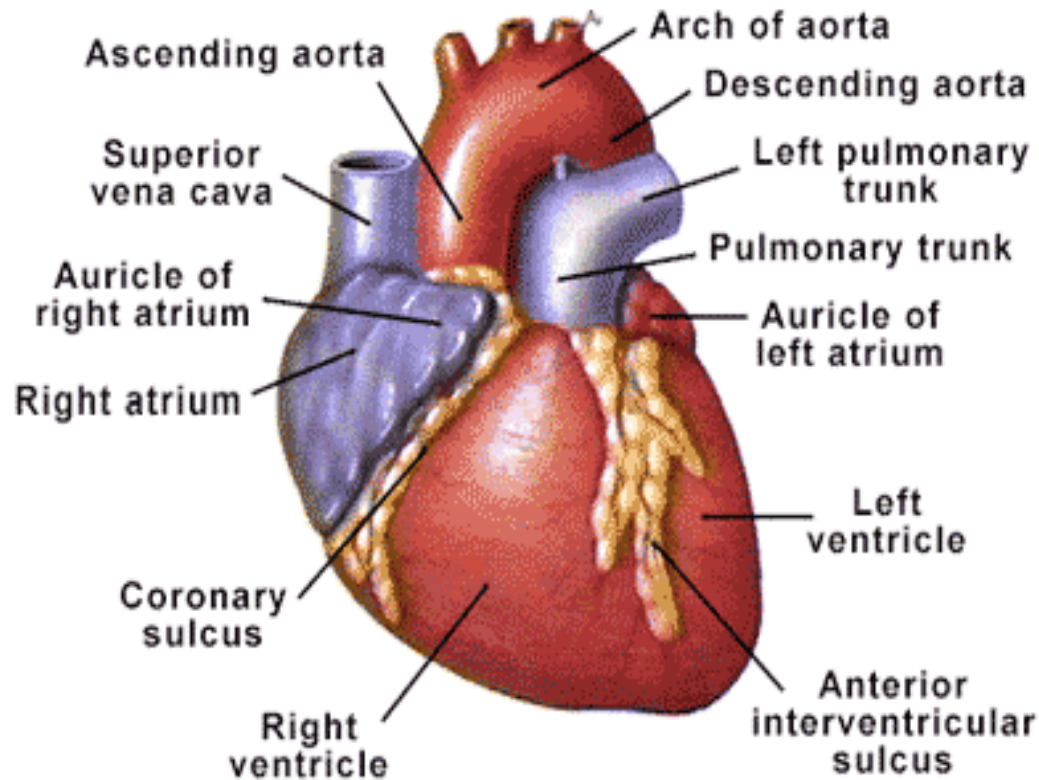
# ***NORMAL ANATOMY AND HISTOLOGY***

# Objectives:

**At the end of this P1 practical session of the cardiovascular block, the medical students will be able to:**

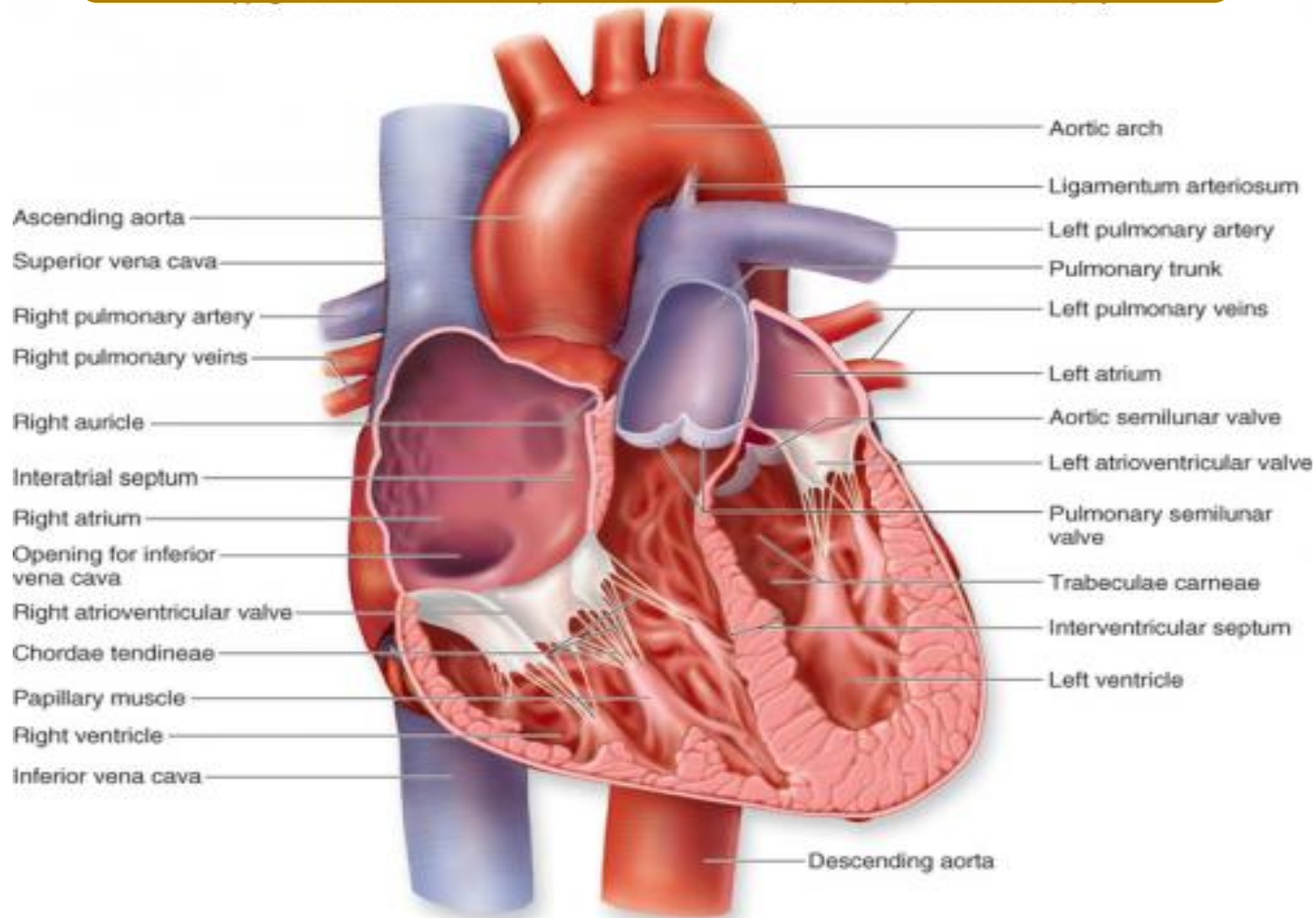
- Identify the morphologic **histopathological** features of:
  - Acute rheumatic myocarditis
  - Acute rheumatic valvulitis
  - Chronic rheumatic valvular heart disease
  - Aortic stenosis
  - Atheroma of aorta
  - Coronary atherosclerosis
  - Atheroma histology
  - Abdominal aortic aneurysm
  - Myocardial infarction

# Anatomy of the Heart



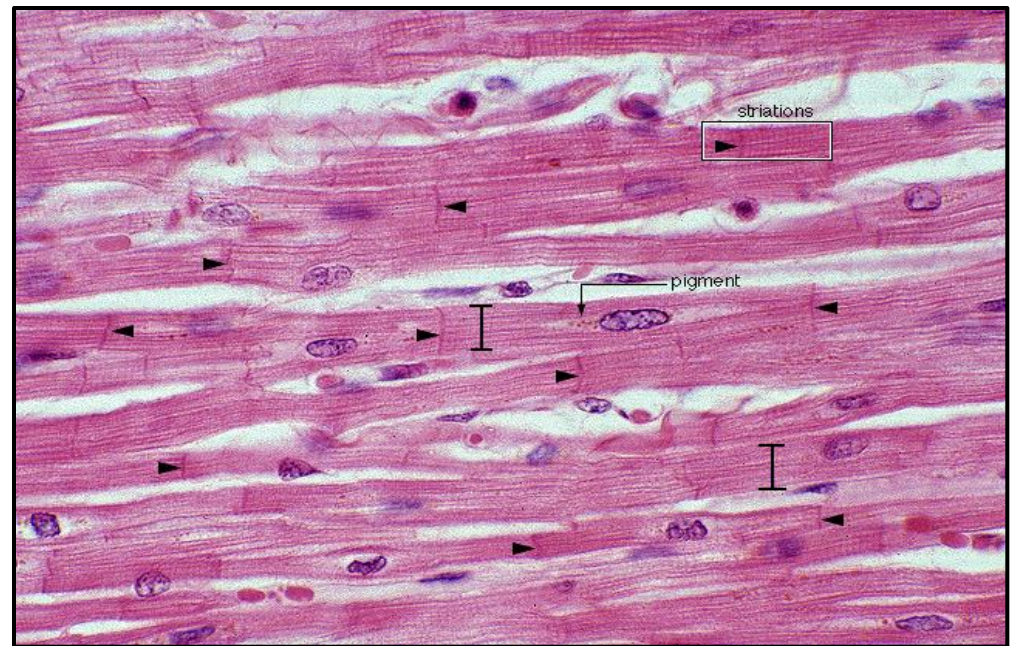
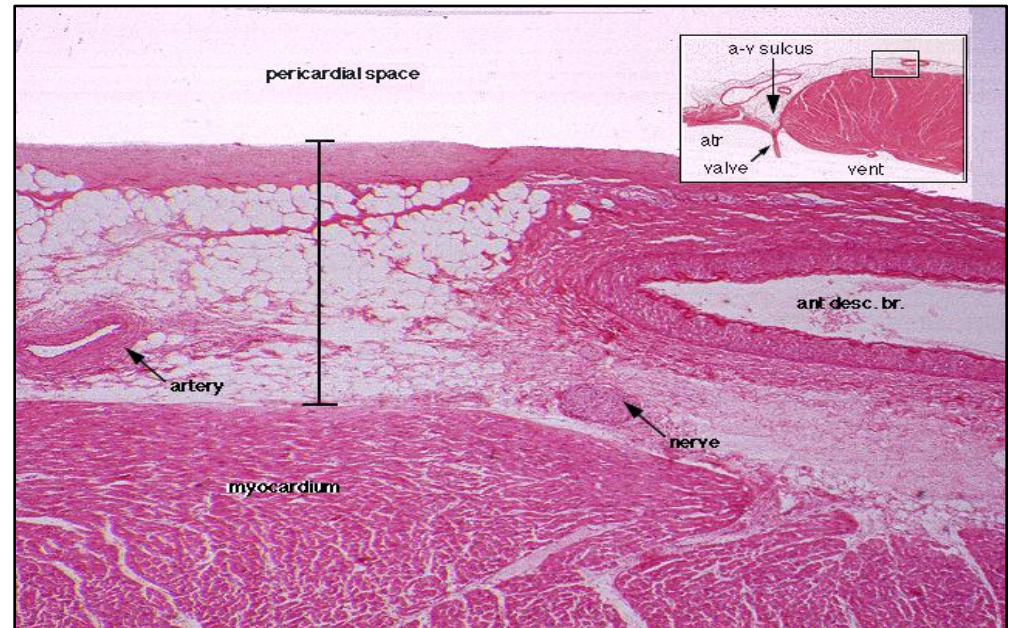
- The heart serves as a **mechanical pump** to supply the entire body with blood, both providing nutrients and removing waste products.
- The great vessels exit the base of the heart.
- Blood flow: body → sup & inf vena cava → right atrium → right ventricle → lungs → left atrium → left ventricle → Aorta → body

# Anatomy of the Heart – inside view



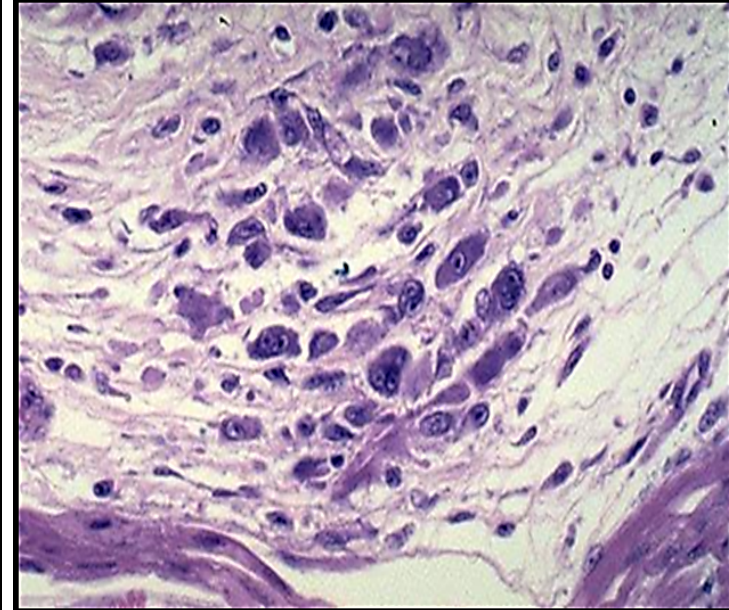
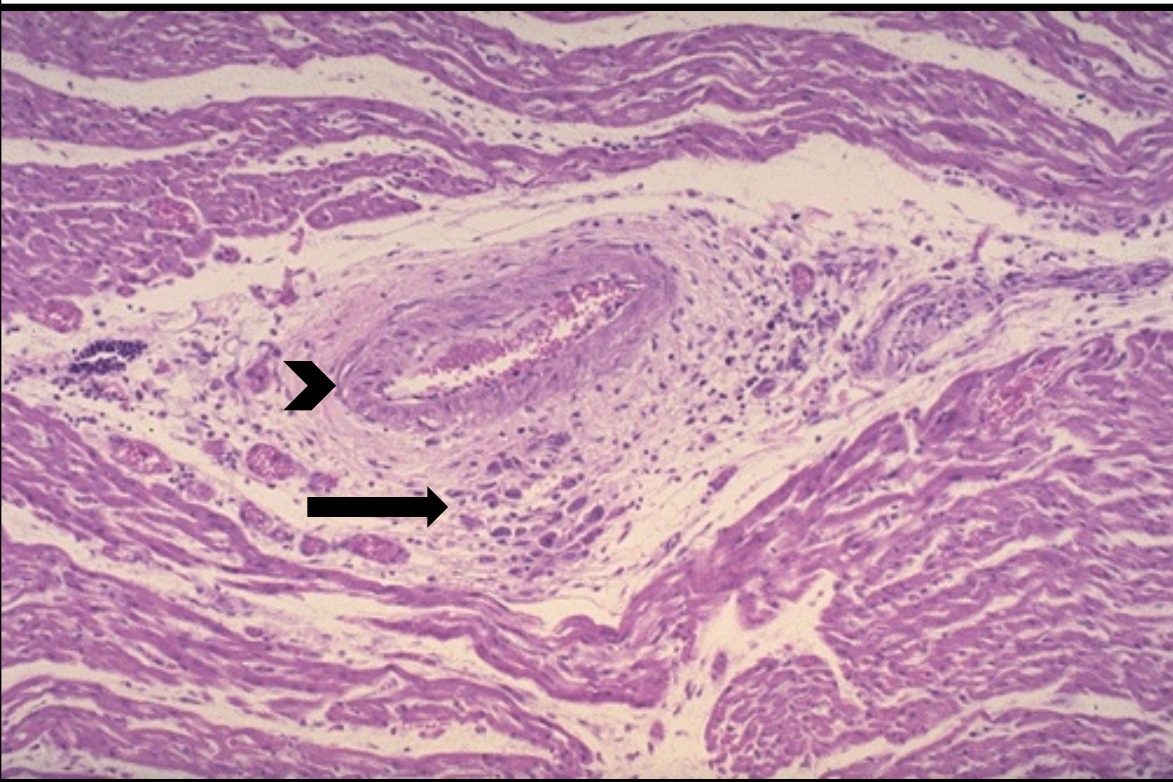
# Histology of the Heart

- The heart consists of 3 layers
  - the **Endocardium**,
  - the **Myocardium**, and
  - the **Pericardium**.
- The **Pericardium** consists of arteries, veins, nerves, connective tissue, and variable amounts of fat.
- The **Myocardium** contains **branching, striated muscle cells with centrally located nuclei**. They are connected by **intercalated disks** (arrowheads).



# Acute rheumatic myocarditis

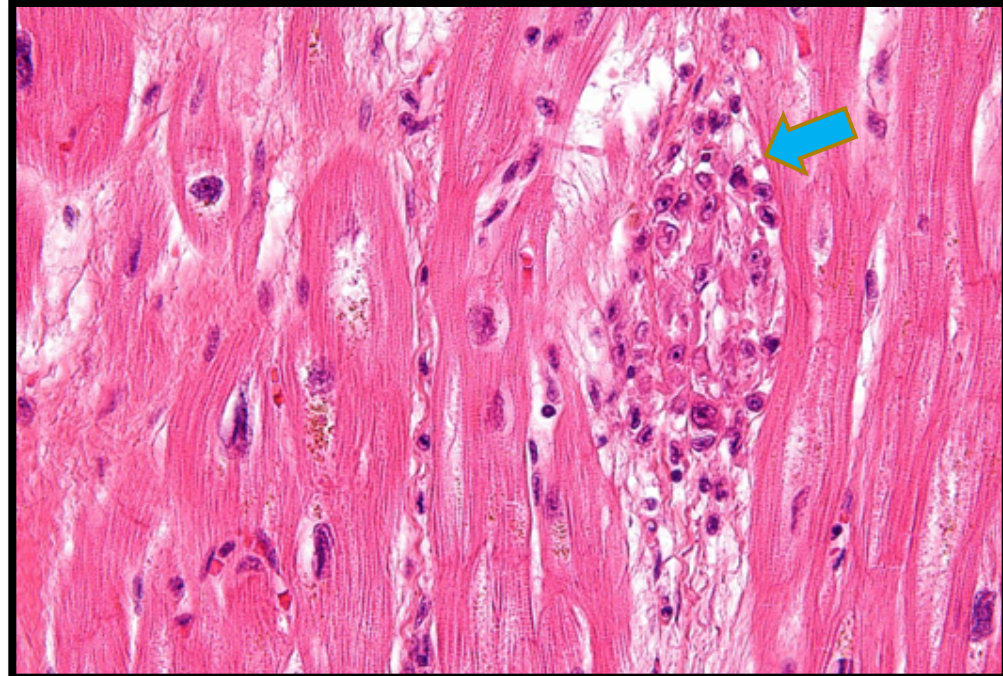
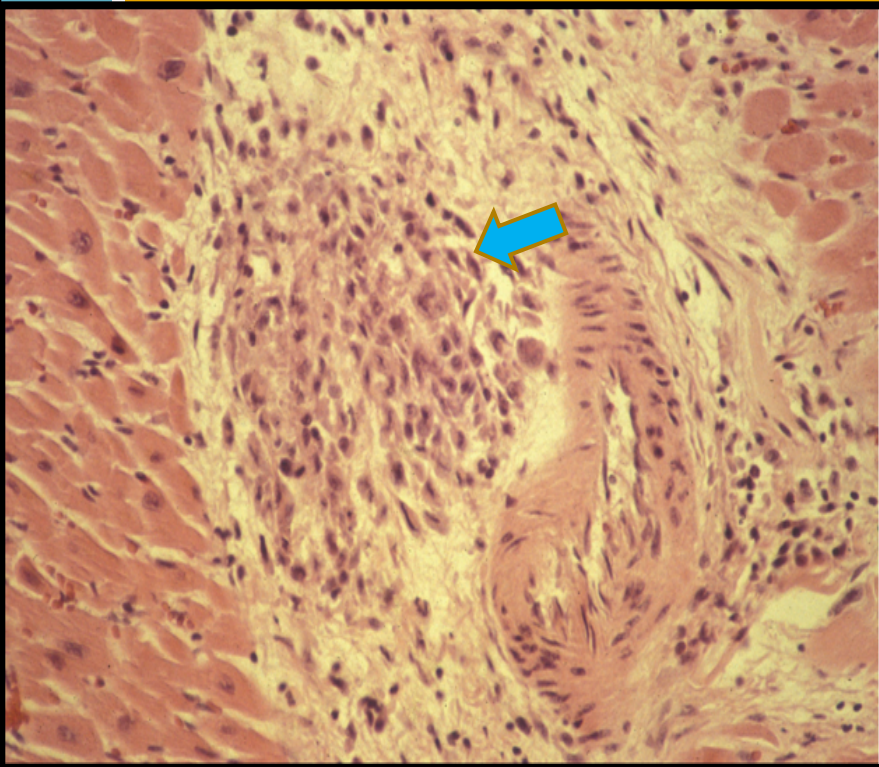
## Acute Rheumatic Carditis - HPF



**An Aschoff nodule/body (arrow) *seen* in the myocardium. They are usually seen near a blood vessel (arrowhead). It consists of a tiny focus of necrosis, few lymphocytes, macrophages and few giant cells called Aschoff giant cells.**

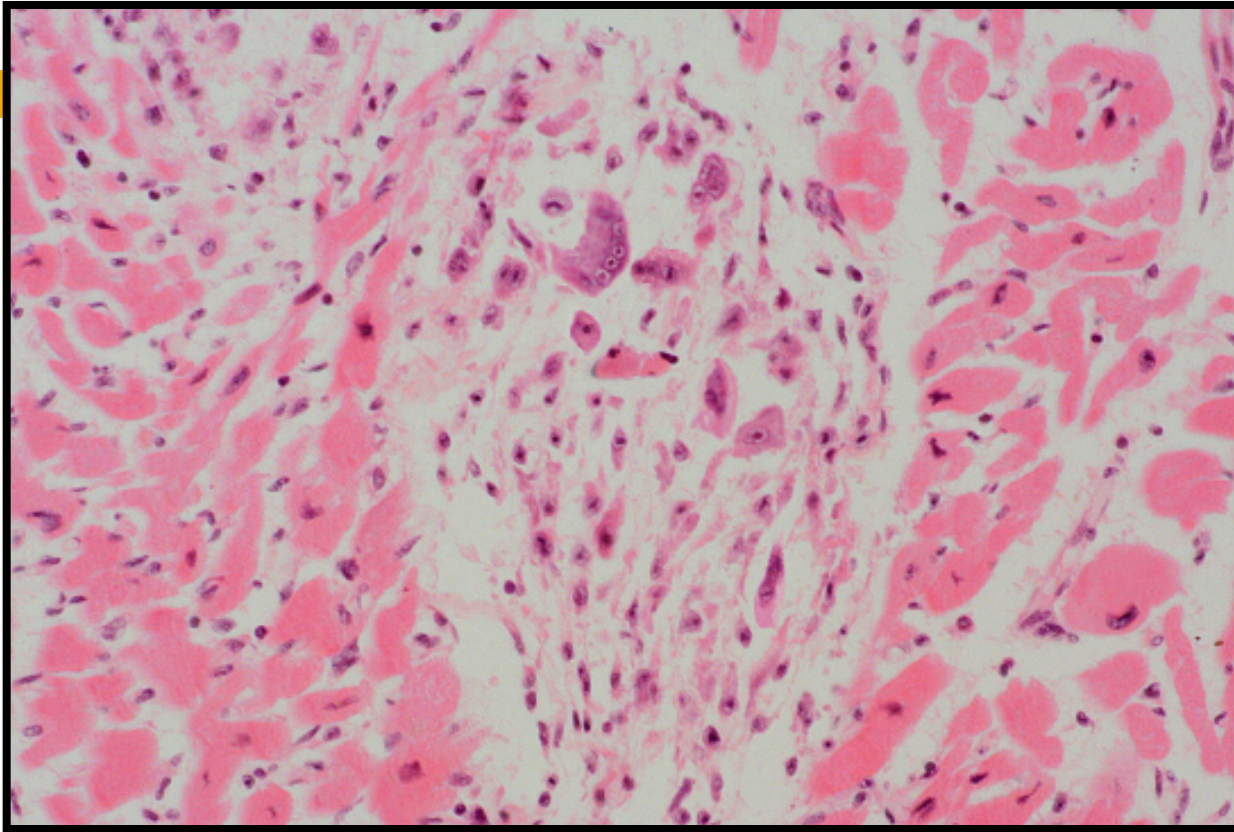


# RHEUMATIC MYOCARDIITIS (ASHOFF NODULE)



***Aschoff nodule*** consists of a focus of necrosis, few lymphocytes, macrophages and few small giant cells with one or several nuclei (***Aschoff giant cell***). Aschoff nodules are usually seen near a blood vessel

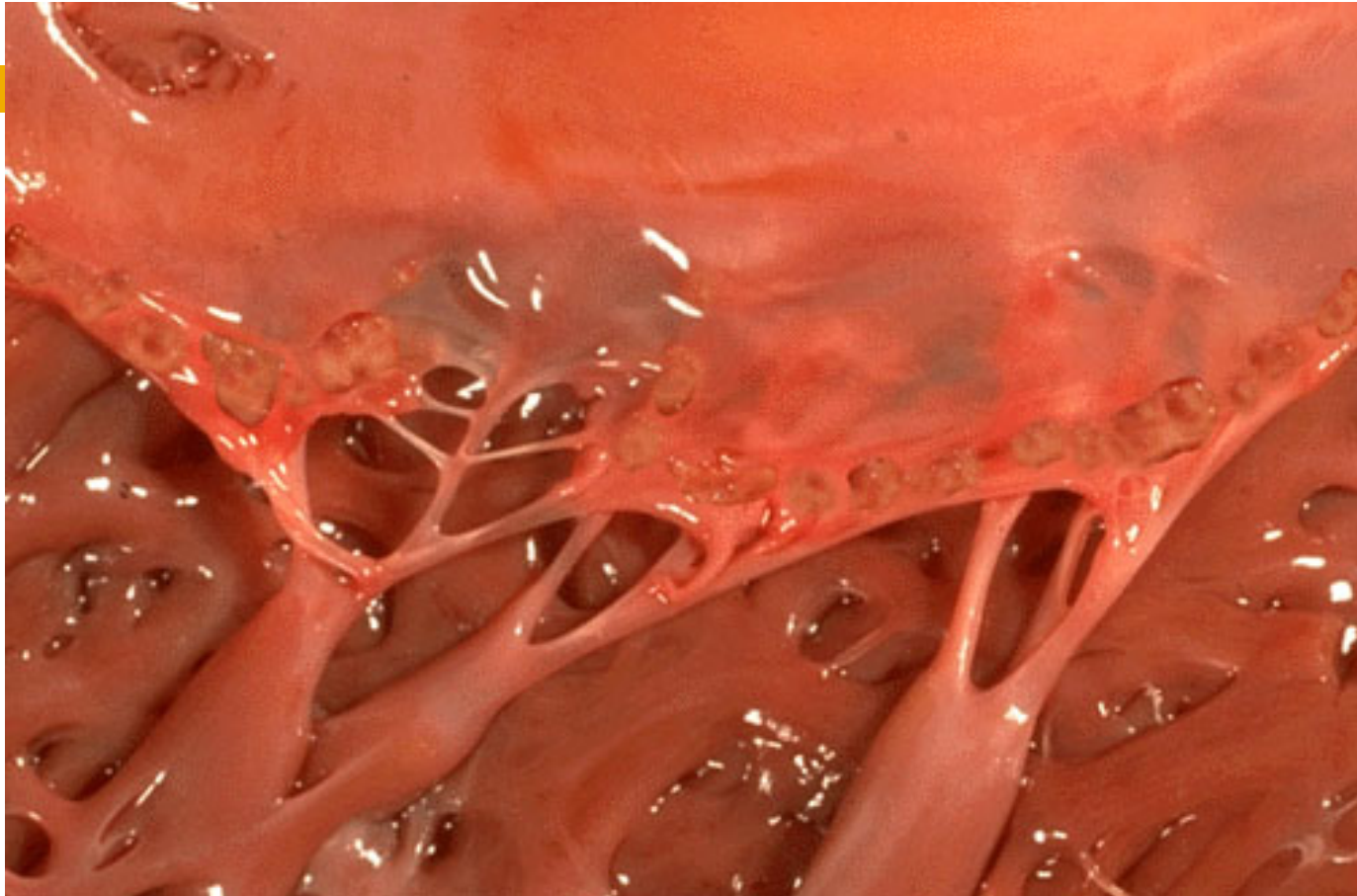
## **Acute Rheumatic Carditis - HPF**



***Acute rheumatic fever is an autoimmune process that can follow pharyngeal infection with Group A beta hemolytic Streptococcus. Microscopically, acute rheumatic myocarditis shows granulomatous inflammation called "Aschoff nodules" with giant cells called Aschoff giant cell.***

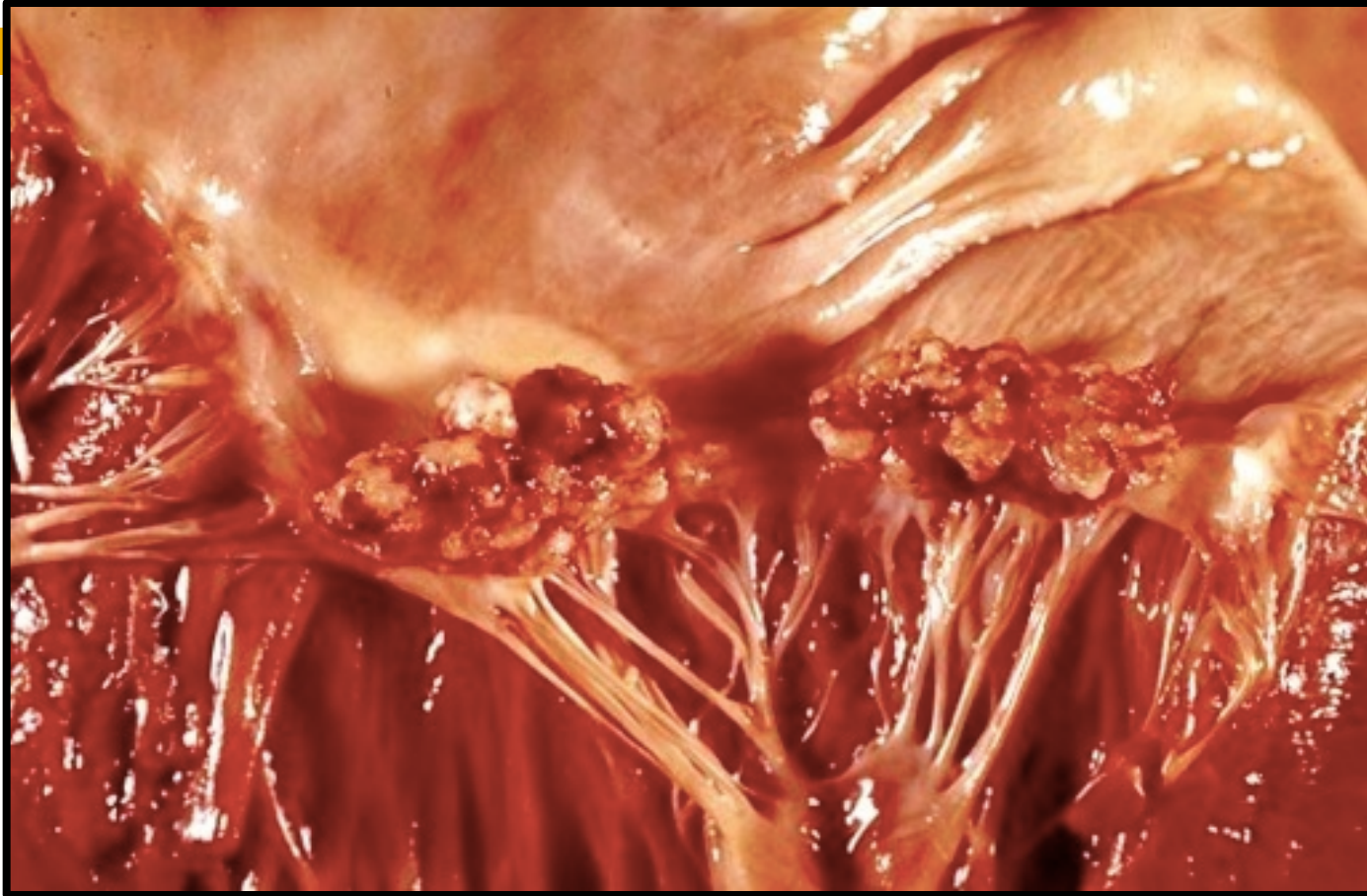
# Acute rheumatic valvulitis of the mitral valve

## **Acute Rheumatic Mitral Valvulitis - Gross**



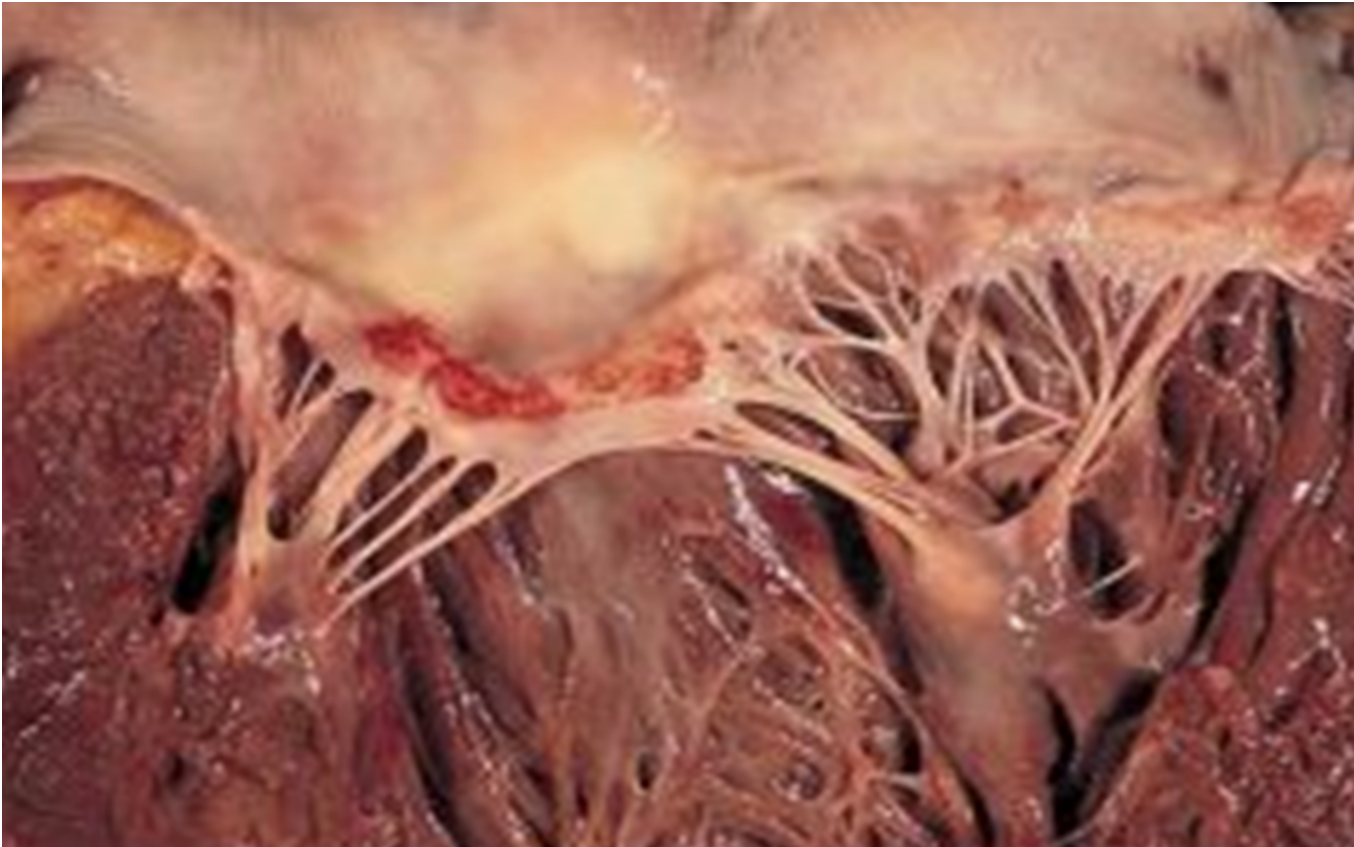***The small verrucous vegetations are associated with acute rheumatic fever. These warty vegetations are multiple, firm, adherent, small , 1-3 mm in- diameter and form along the line of valve closure over areas of endocardial inflammation. Affects mainly Aortic & Mitral valves***

## **Mitral Valvulitis seen in Acute Rheumatic heart disease - Gross**



***Picture shows large vegetations/hemorrhage along the free margins of the mitral valve in acute rheumatic valvulitis of the mitral valve.***

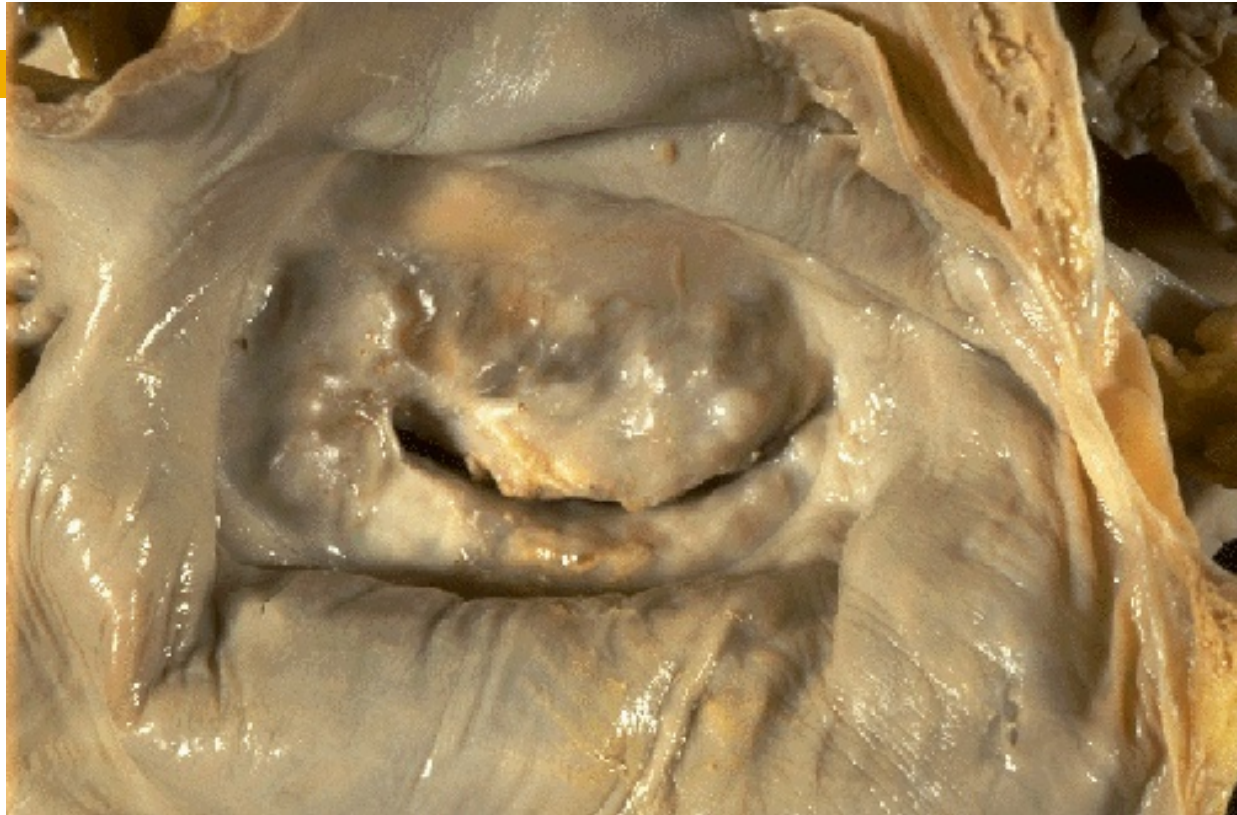## ***Acute Rheumatic Mitral Valvulitis - Gross***



**Close-up view of an opened-out rheumatic mitral valve showing vegetations growing of the valve surface. These cases can progress to chronic rheumatic heart disease with rigid and fibrosed and stenosed mitral valve → mitral stenosis.**

# Mitral stenosis (chronic rheumatic valvular heart disease)

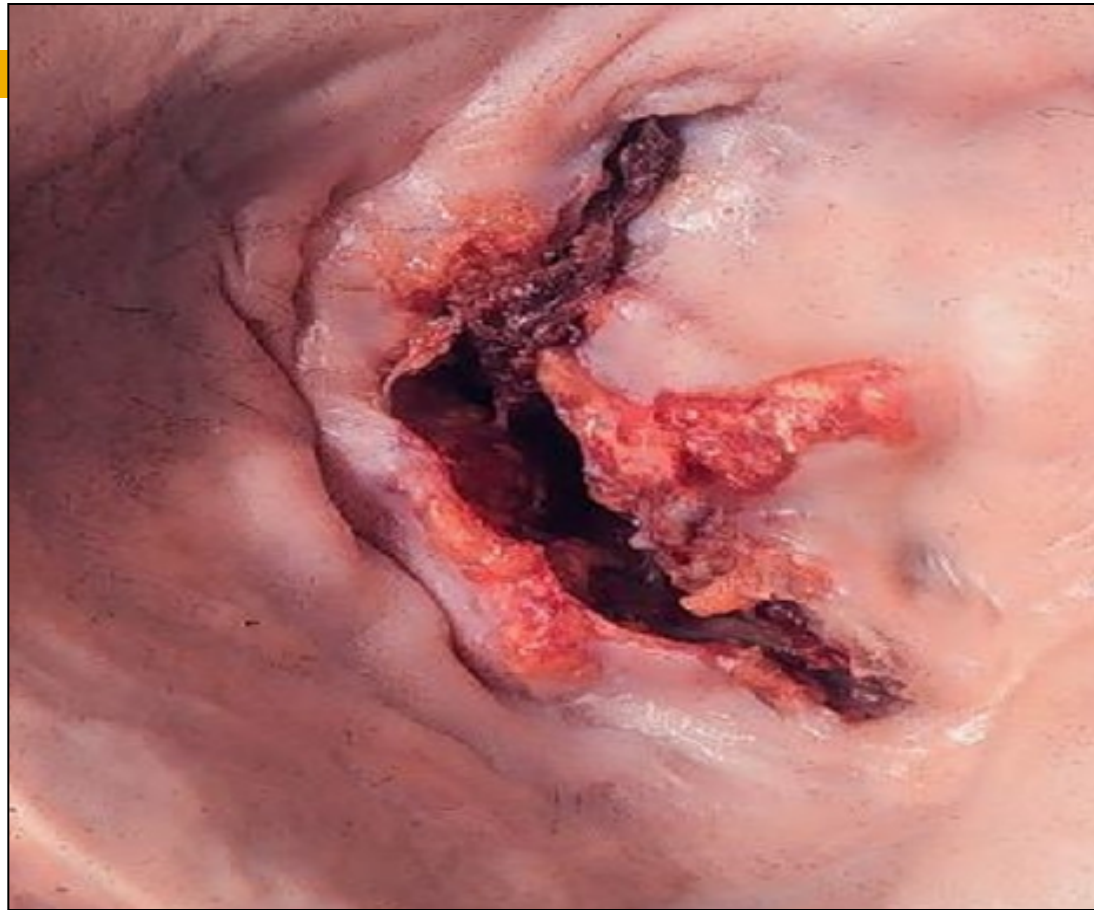
## **Chronic Rheumatic Heart disease: Mitral Stenosis - Gross**



***In with rheumatic heart disease mitral valve is most often affected, followed by mitral and aortic together. The vegetations on the mitral of acute rheumatic valvulitis undergo organization and the inflamed cusps heal by fibrosis. This results in stenotic mitral valve with "fish mouth" / "button hole" deformity. This picture shows stenotic mitral valve seen from above in the left atrium due to chronic rheumatic scarring. The mitral valve shows fusion of commissures, thickening and calcification of the cusps.***



## **Chronic Rheumatic Heart disease: Mitral Stenosis - Gross**

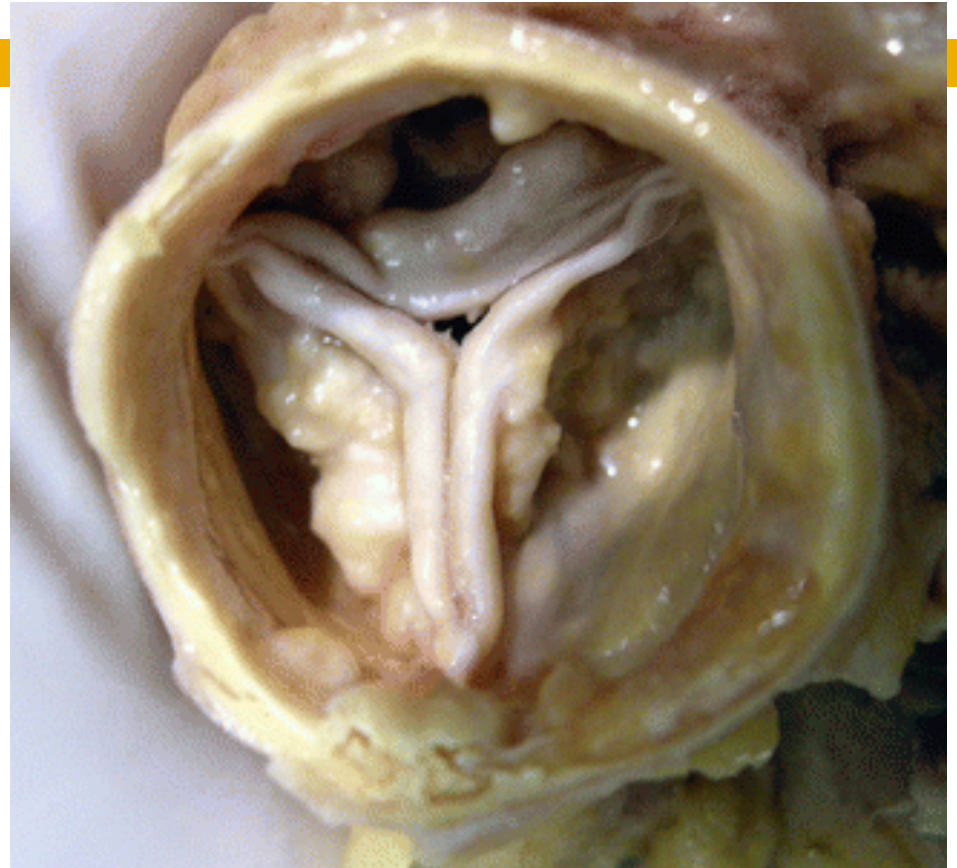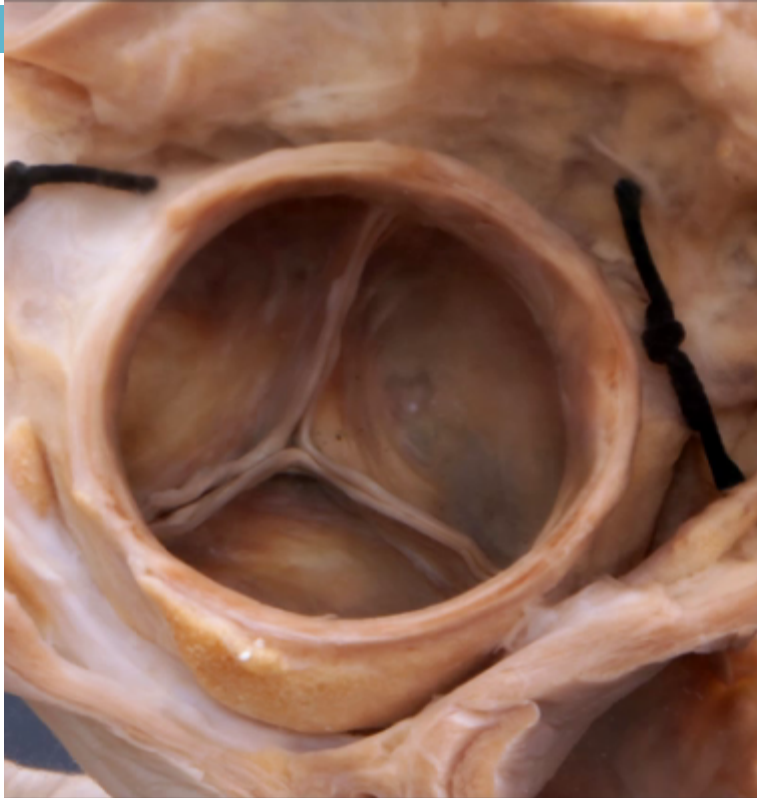


***Stenotic mitral valve seen from left atrium (Fish-Mouth) showing fusion of commissures, thickening and calcification of the cusps, The vegetations undergo organization and the inflamed cusps heal by fibrosis.***

# AORTIC STENOSIS

A decorative horizontal bar at the bottom of the slide, consisting of a teal segment on the left and a yellow segment on the right, separated by a thin white vertical line.

## Aortic stenosis - Gross



***Picture shows a normal aortic valve and a stenotic aortic valve***

***Aortic stenosis: Aorta show thickened, fused calcified aortic valve leaflets***

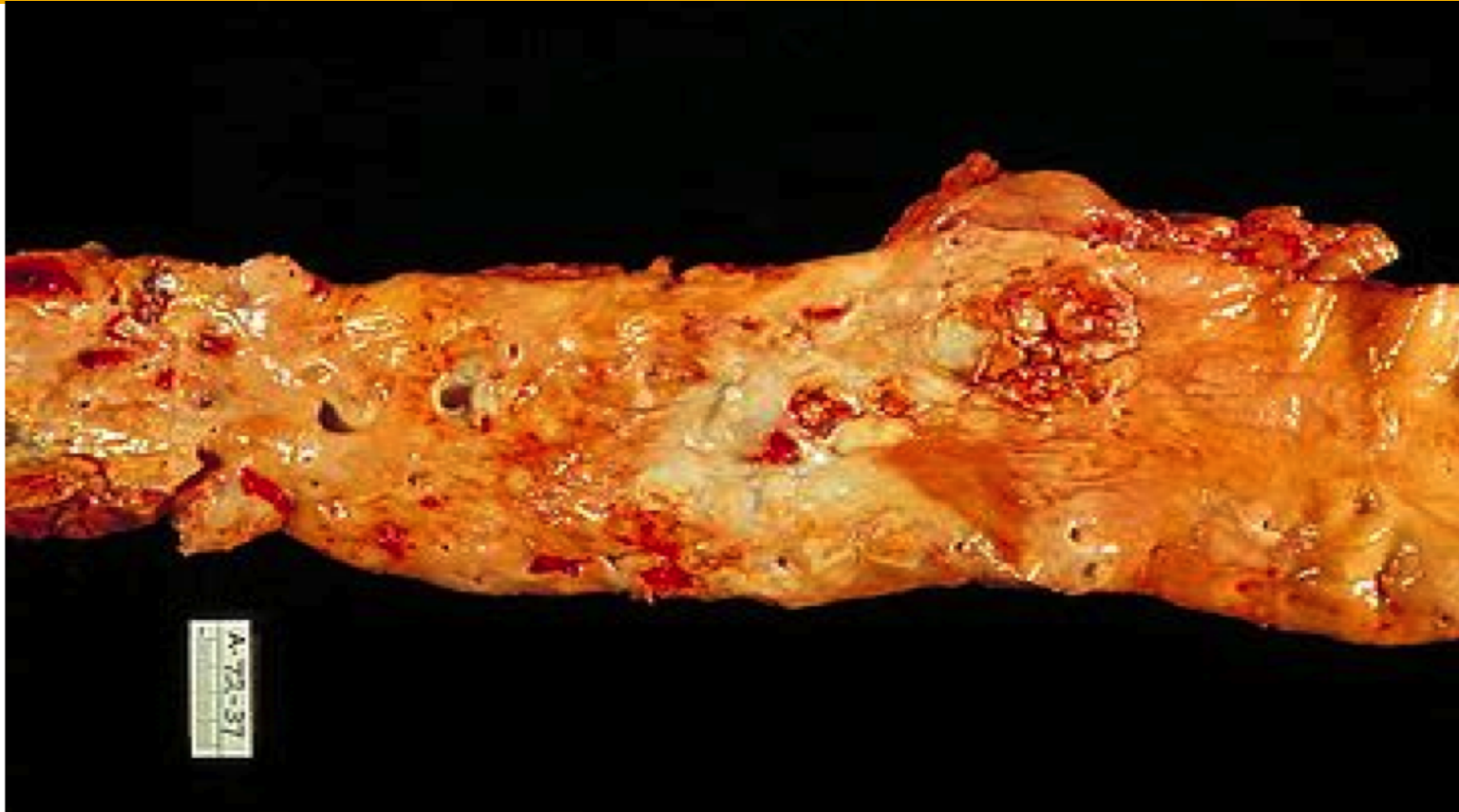***Causes of Aortic stenosis: rheumatic heart disease, calcification of aortic valve in old age***

# ***ATHEROMA OF THE AORTA***

- **An atheroma** is a swelling in arterial walls and accumulation made up of:
  - (mostly) macrophages
  - debris
  - lipids (cholesterol and fatty acids)
  - calcium
  - variable amount of fibrous connective tissue.
  
- **The major risk factors are:**

<b>Nonmodifiable (Constitutional)</b>
Genetic abnormalities
Family history
Increasing age
Male gender
<b>Modifiable</b>
Hyperlipidemia
Hypertension
Cigarette smoking
Diabetes
Inflammation

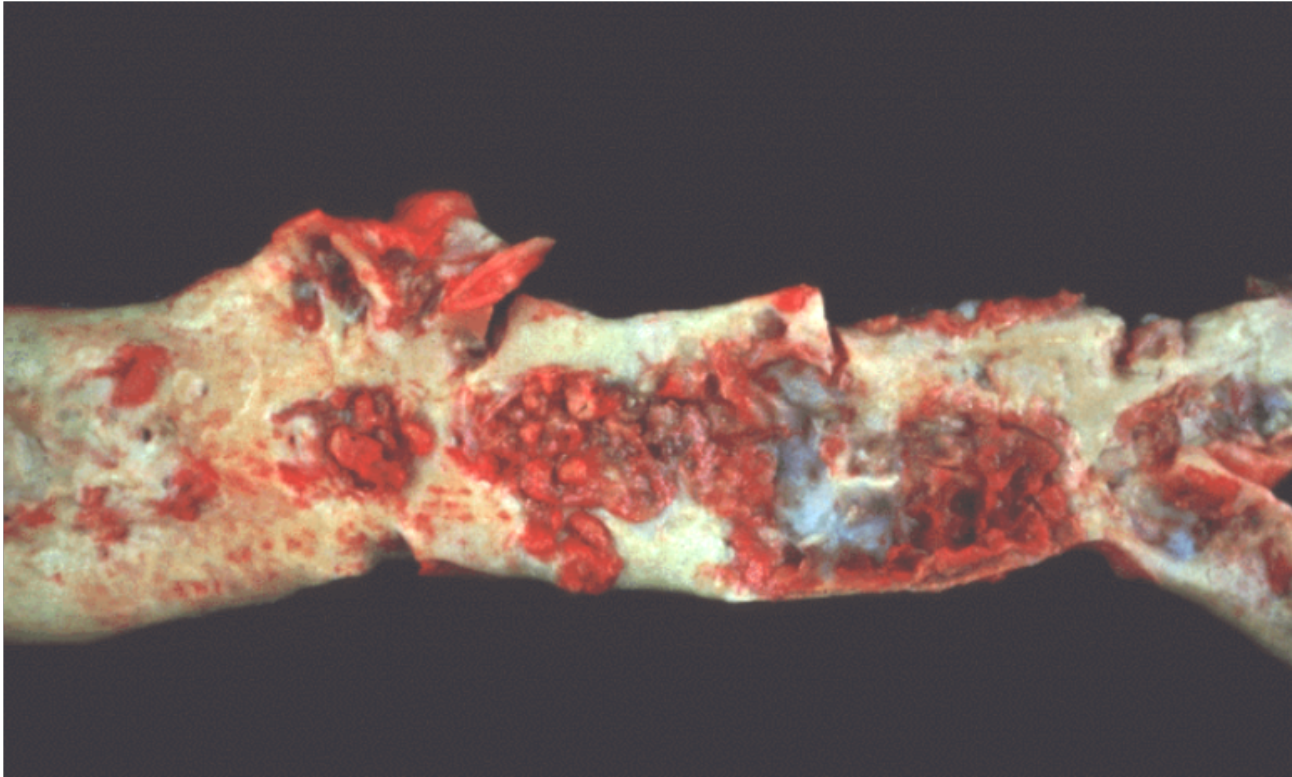
## *Atheroma of the Aorta - Gross*



### **Advanced atherosclerosis in abdominal aorta:**

The atheromatous plaques have undergone **ulceration** along with formation of overlying mural **thrombus**.

## ***Atheroma of the Aorta - Gross***



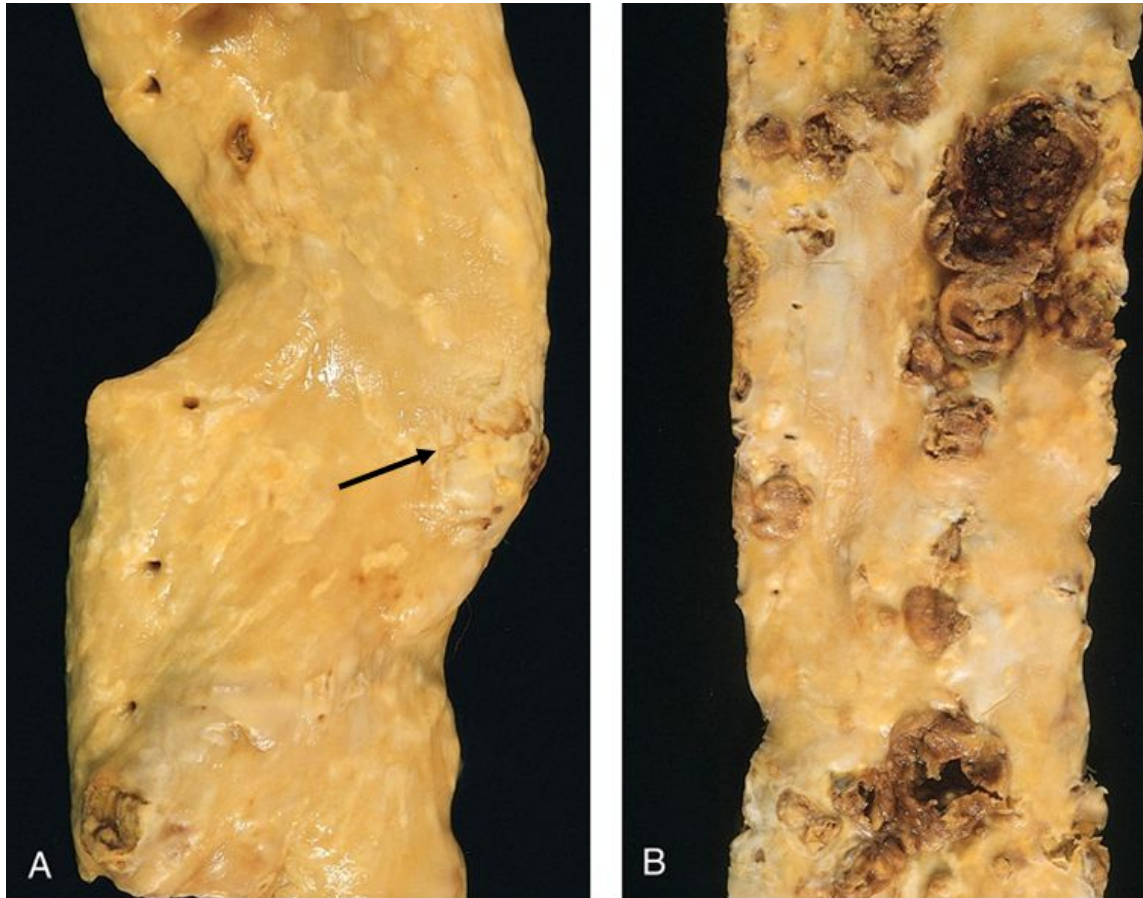
**Severe atherosclerosis of the aorta** : the atheromatous plaques have undergone ulceration along with formation of overlying mural thrombus. Complications are thrombosis , hemorrhage , calcifications and aneurysmal dilatation with the distal ischemic events .

## ***Atheroma of the Aorta - Gross***



**Severe atherosclerosis of the aorta** : the atheromatous plaques have undergone ulceration along with formation of overlying mural thrombus. Complications are thrombosis , hemorrhage , calcifications and aneurysmal dilatation with the distal ischemic events .

## ***Atheroma of the Aorta - Gross***

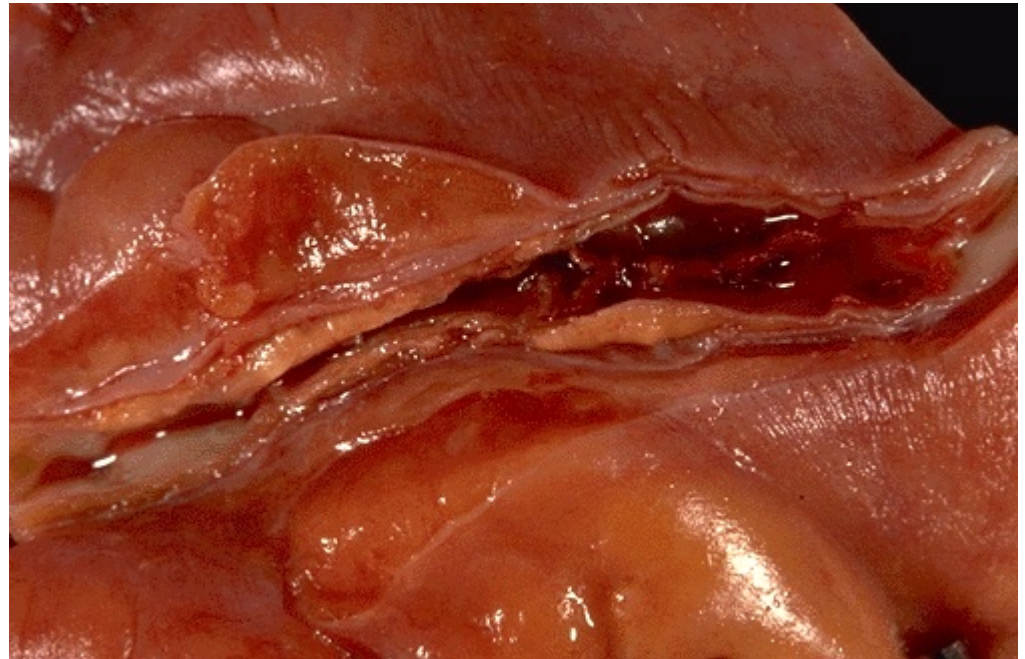
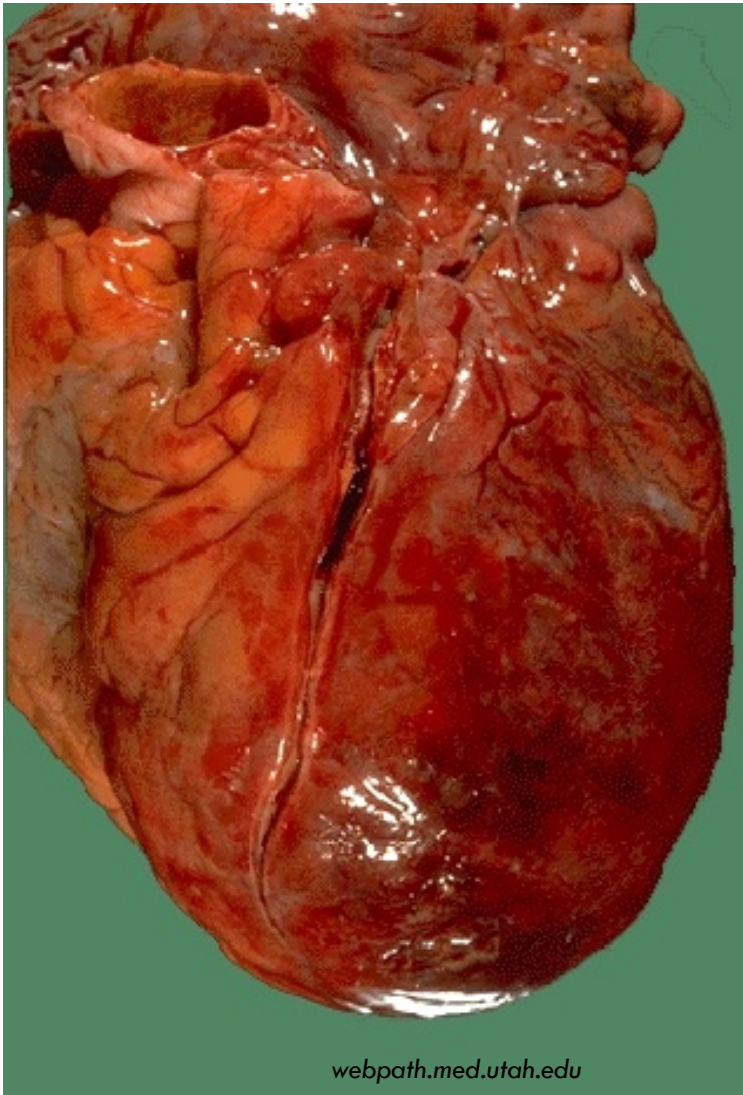


***These 2 aortas demonstrate mild and severe atherosclerosis. “A” shows mild atherosclerosis few scattered atheromatous lipid plaques. “B” shows many more larger plaques with disruption and ulceration in the plaques.***



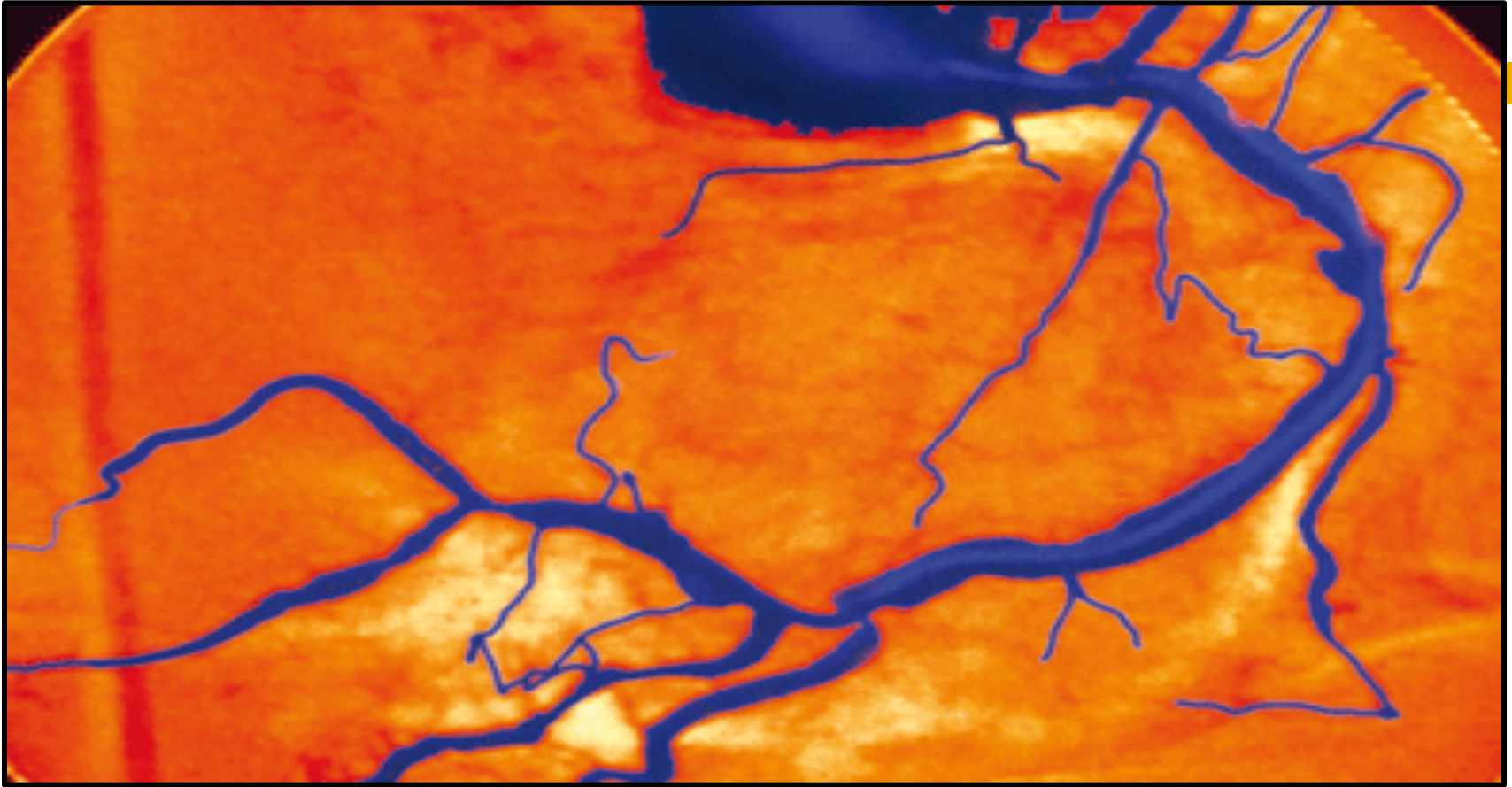
# CORONARY ATHEROSCLEROSIS

## ***Coronary Atherosclerosis - Gross***



**The surface of the heart demonstrates an opened interventricular left anterior descending coronary artery. Within the lumen of the coronary, there is a dark red recent coronary thrombosis. The hemorrhagic area seen at the lower right of the thrombus is the area of myocardial infarction. At high magnification, the dark red thrombus is apparent in the lumen of the coronary. The yellow tan plaques of atheroma narrow this coronary significantly, and the thrombus occludes it completely.**

## ***Coronary Atherosclerosis - Gross***

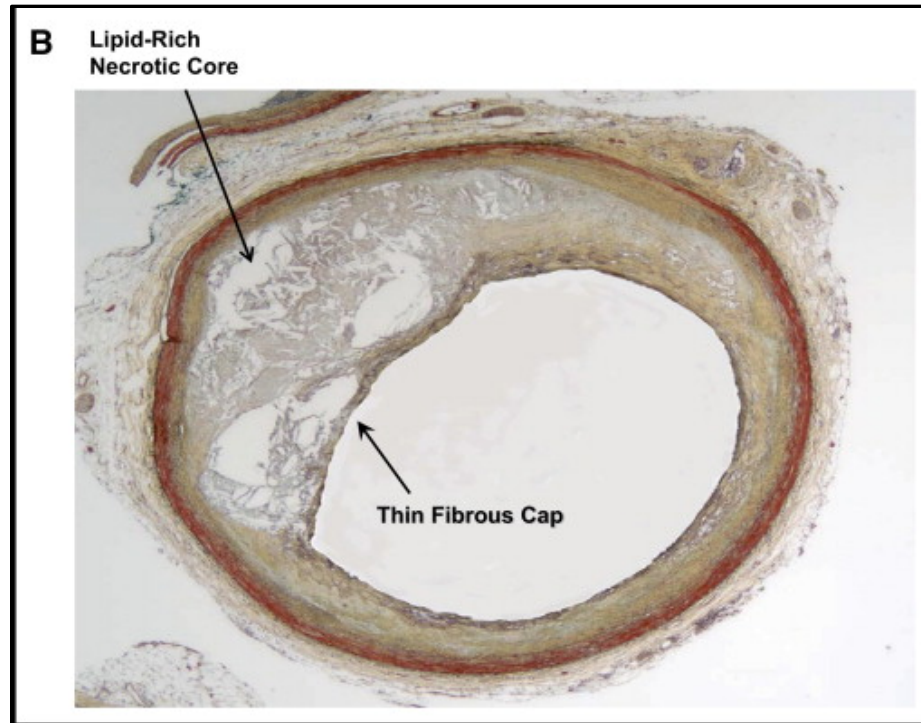
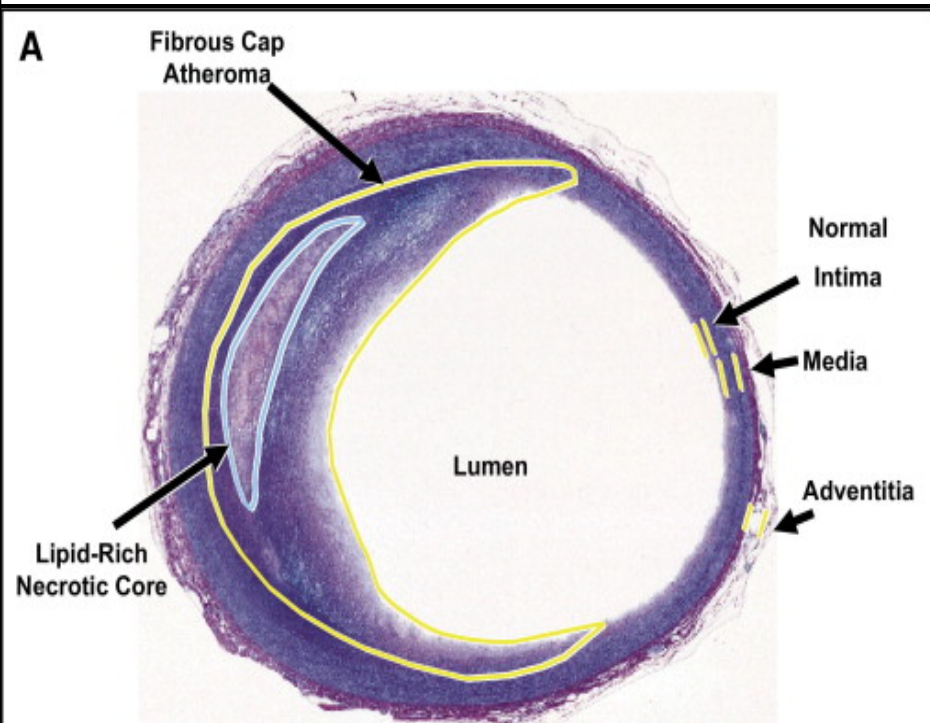


**Coronary atherosclerosis.** Coloured angiogram (X- ray) showing atherosclerosis in a coronary artery. The atherosclerosis is seen as the pinching in the blue- coloured artery at bottom centre

# ATHEROMA HISTOLOGY



# Coronary atherosclerosis - LPF

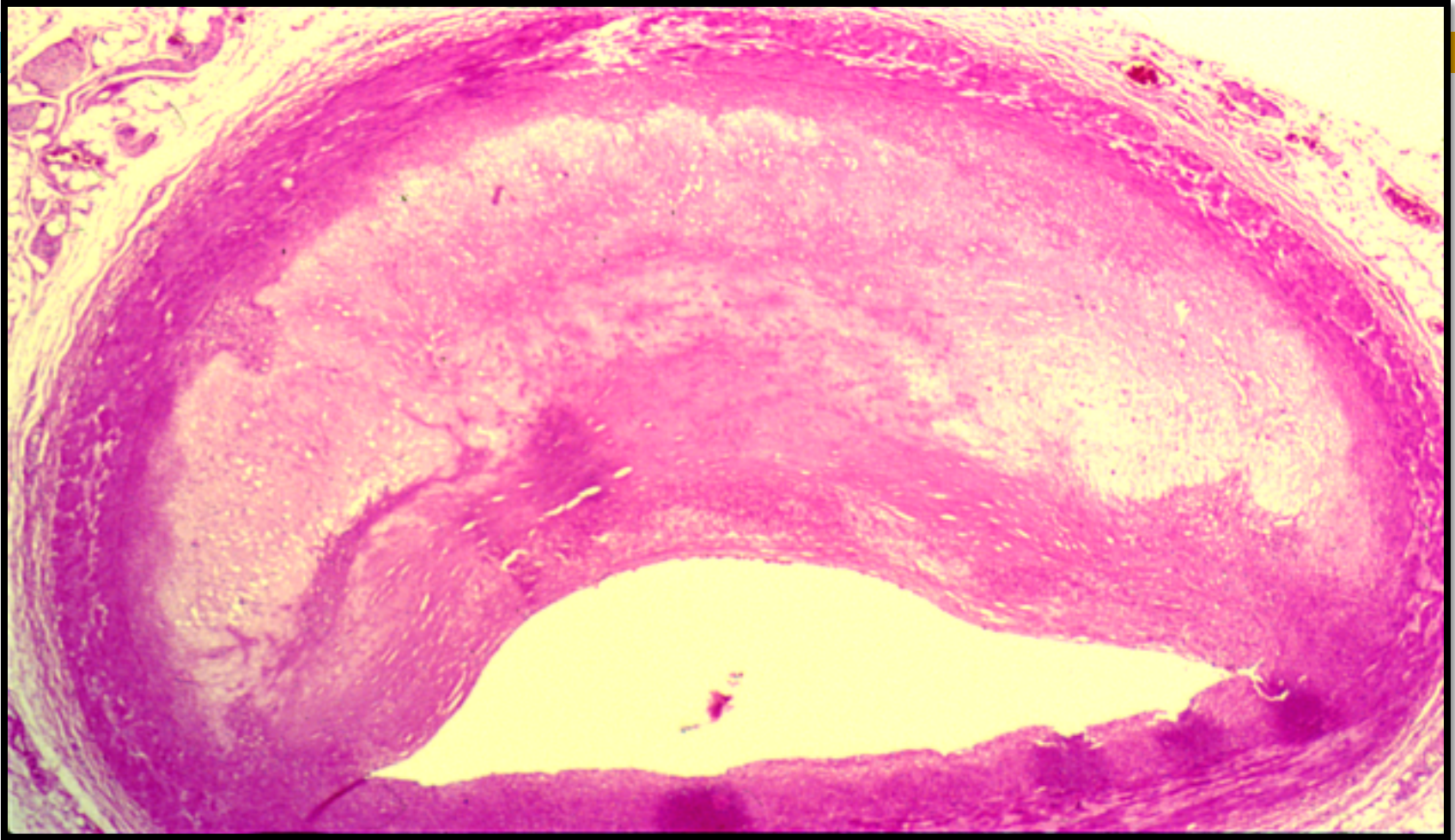


<https://doi.org/10.1016/j.amjmed.2008.10.013>

The American Journal of Medicine, Vol 122, No 1A, January 2009

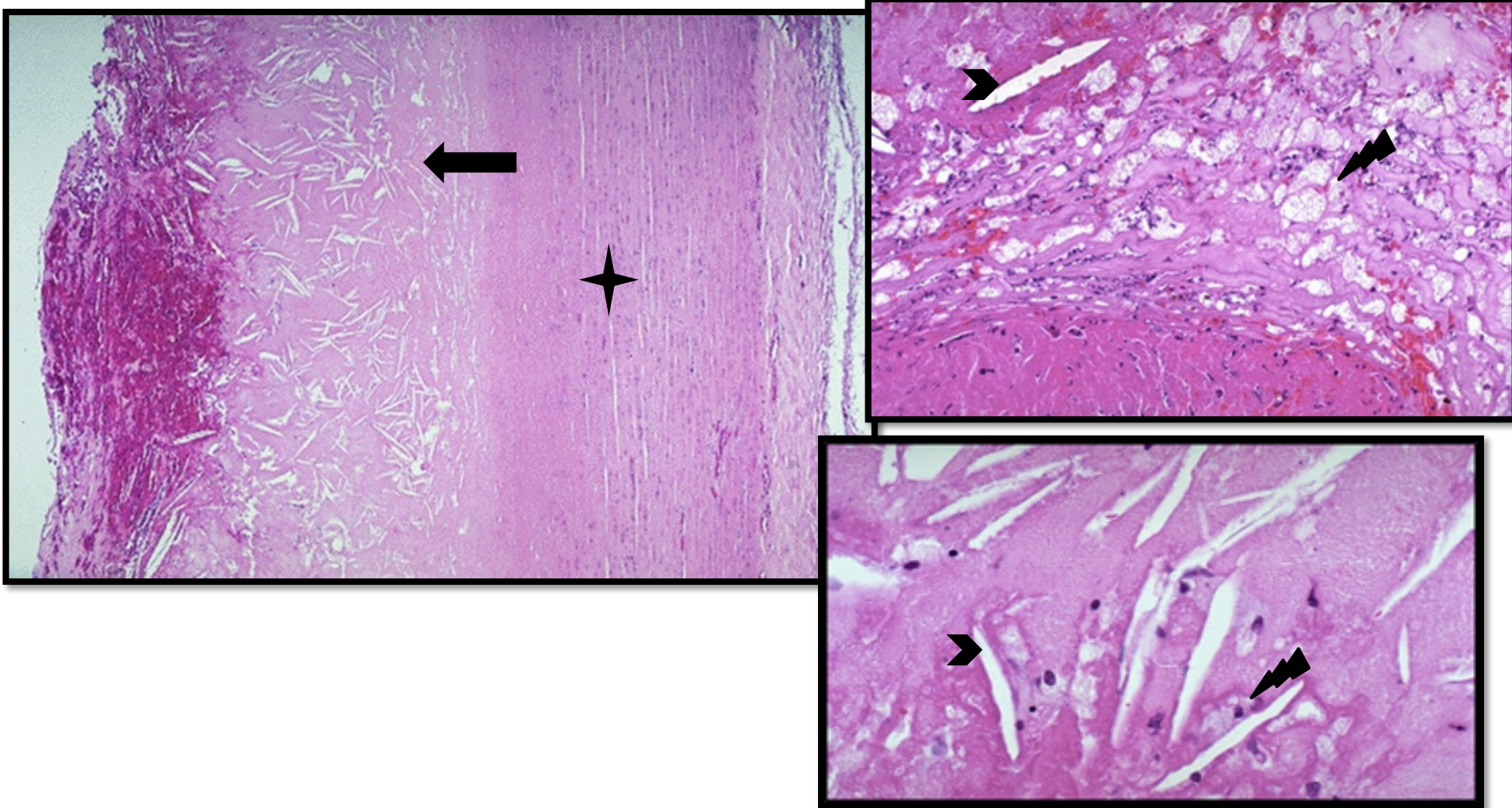
**Coronary artery with atherosclerosis (fibro-lipid or fibro-fatty plaque). The atheromatous fibro-fatty plaque is characterized by the accumulation of lipids in the intima of the arteries, narrowing the lumen. Beneath the endothelium it has a "fibrous cap" covering the atheromatous "core" of the plaque, which consists in cholesterol crystals, cholesterol esters, fibrin, macrophages and smooth muscle cells, proteoglycans, collagen, elastin and cellular debris.**

## ***Coronary atherosclerosis - MPF***



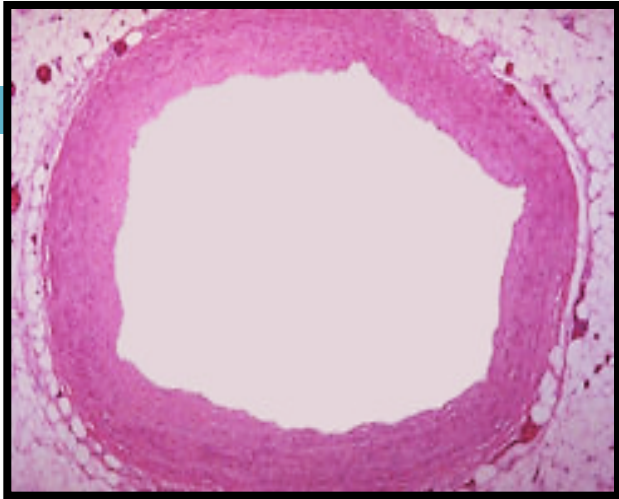
**Severe coronary atherosclerosis with 70% narrowing  
of the lumen**

# Atheroma

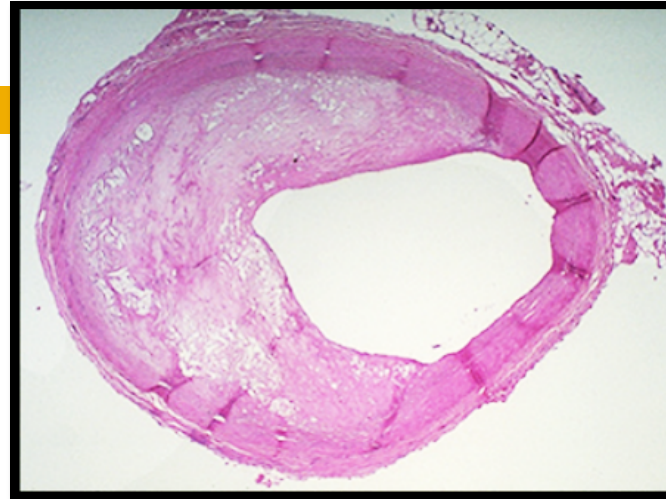


***This microscopic cross section of aorta shows the wall of the aorta (star) and an atheroma (arrow). The atheroma shows numerous cholesterol clefts, surface ulceration and hemorrhage. The higher magnification pictures show cholesterol clefts (arrow head) and foam cells (lightning arrow).***

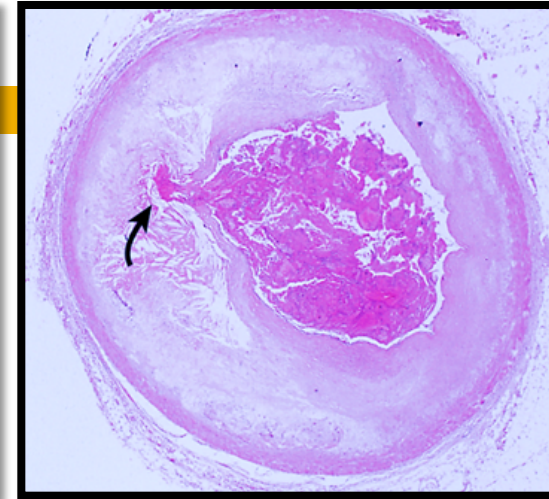
# Coronary atherosclerosis



**A normal coronary artery with no atherosclerosis** and a widely patent lumen that can carry as much blood as the myocardium requires.



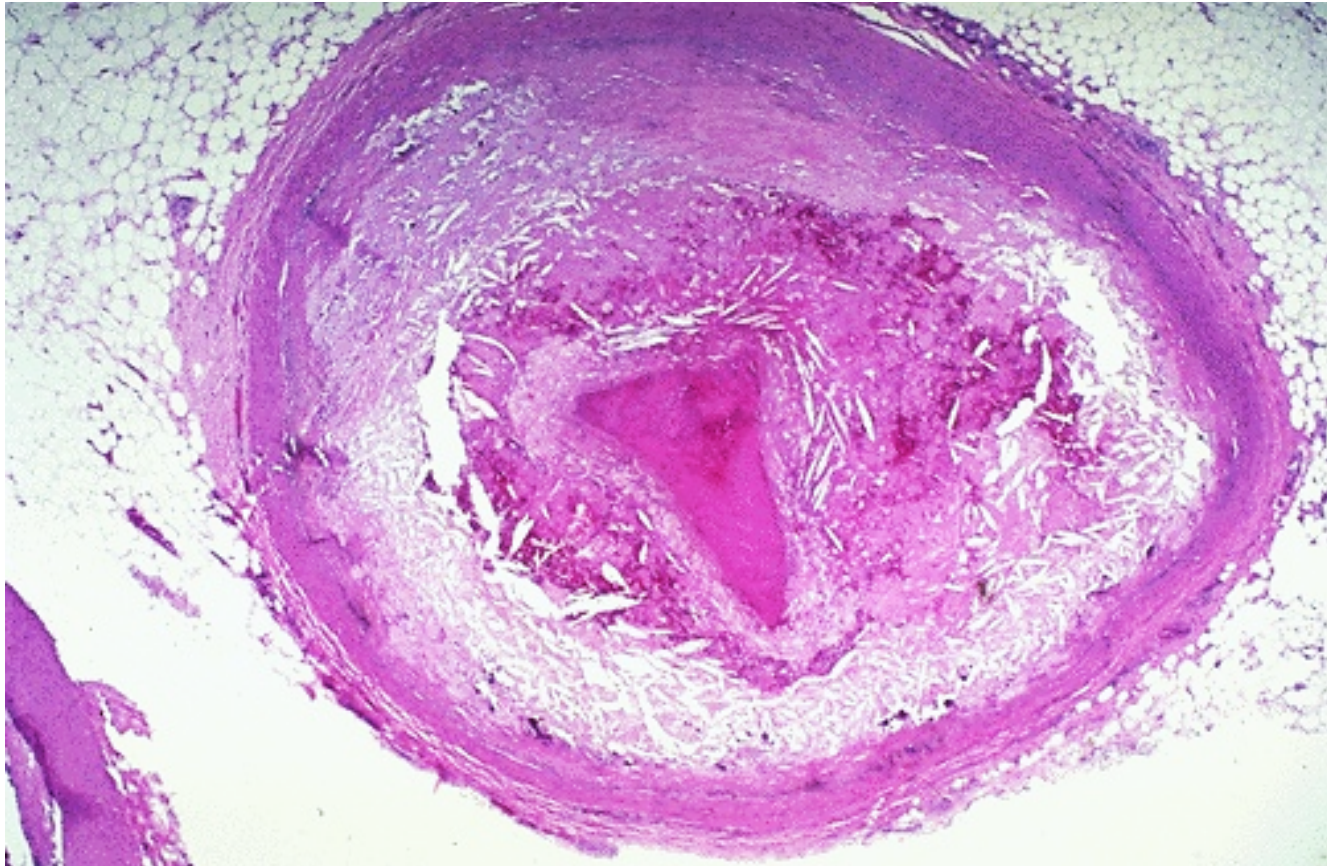
**Coronary atherosclerosis.** The coronary artery is narrowed by 50%.



**Acute coronary thrombosis superimposed on an atherosclerotic plaque** with focal disruption of the fibrous cap, triggering a myocardial infarction



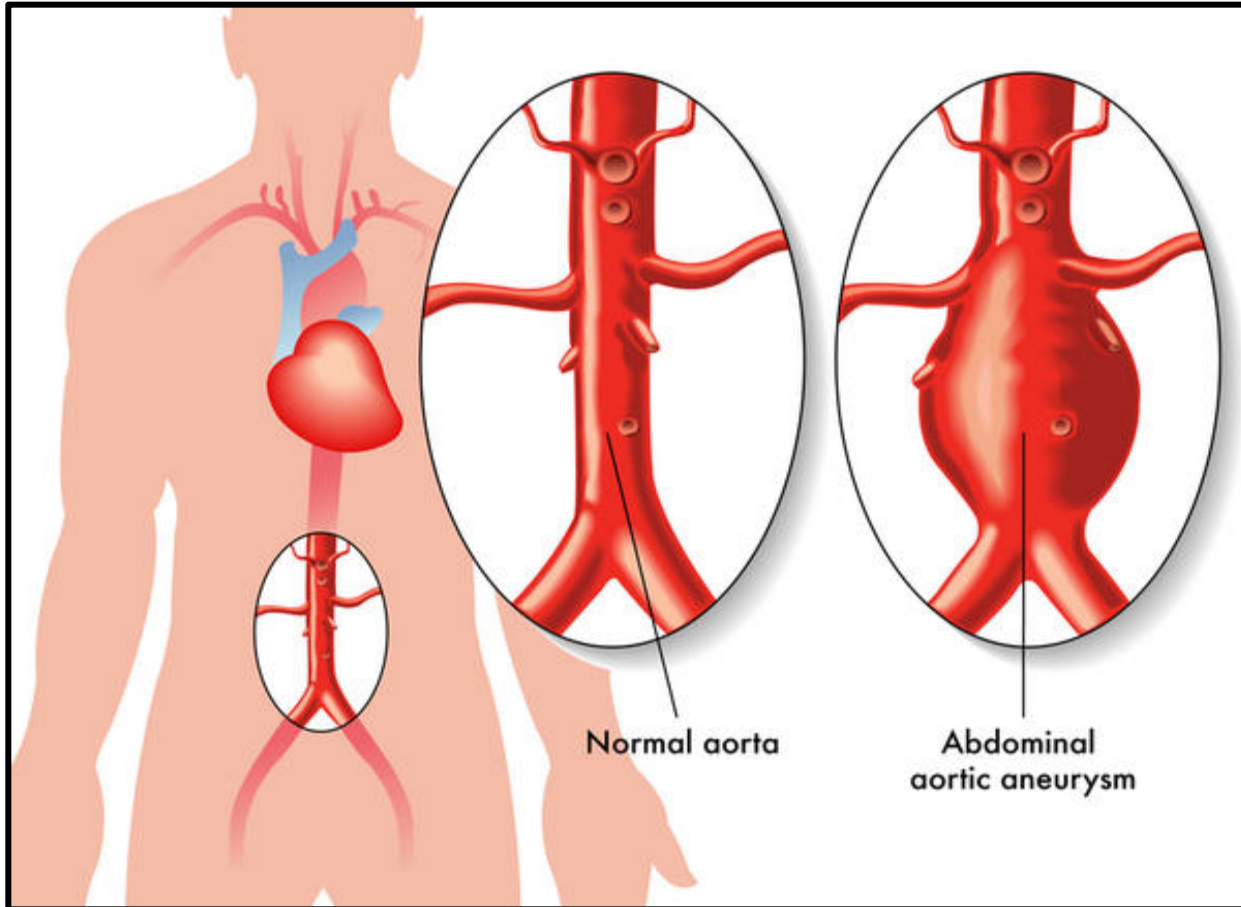
# *Atheroma*



**Artery showing atheroma with a totally occlusive thrombus → infarction in the organ being supplied by this artery.**

# ANEURYSM OF ABDOMINAL AORTA

# *Abdominal Aortic Aneurysm*

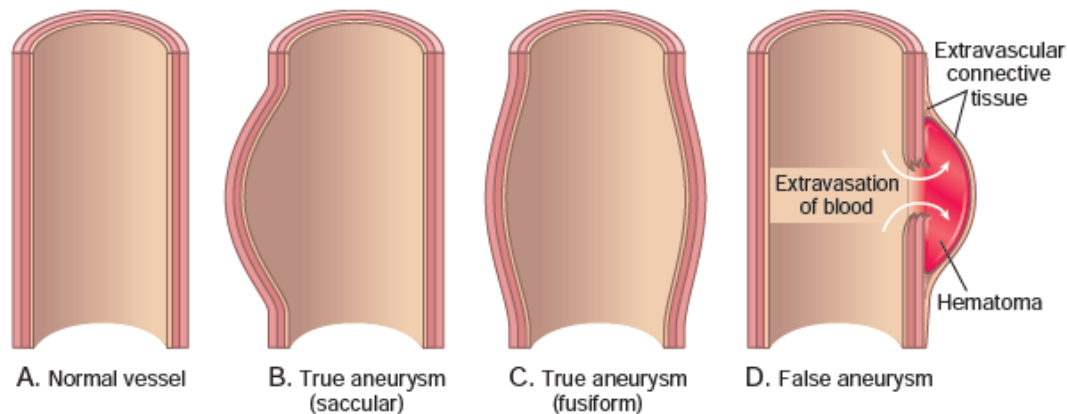


Normal aorta

Abdominal  
aortic aneurysm

# Aneurysm

- **Definition:**
  - ▣ An aneurysm is a localized abnormal dilation of a blood vessel
- It may be **congenital or acquired**
- **It is divided into:**
  - ▣ True aneurysm
  - ▣ False aneurysm “pulsating hematoma”



# *Abdominal Aortic Aneurysm (AAA)*

- Is aneurysms occurring as a consequence of atherosclerosis form most commonly in the abdominal aorta and common iliac arteries.
- AAAs occur more frequently in MEN and in SMOKERS, rarely developing before age 50.
- **Atherosclerosis** is a major cause of AAA.
- Risk of rupture: is directly related to the size of the aneurysm:
  - ▣ < 4 cm: low risk of rupture
  - ▣ >4 cm: high risk of rupture

# *Abdominal Aortic Aneurysm (AAA)*

## □ **Clinical Features:**

- Most cases of AAA are asymptomatic.
  
- The other clinical manifestations of AAA include:
  - **Rupture** into the peritoneal cavity or retroperitoneal tissues with massive, potentially fatal hemorrhage.
  - **Obstruction** of a vessel branching off from the aorta, resulting in ischemic injury to the supplied tissue.
  - **Embolism** from atheroma or mural thrombus.
  - **Compression** of the ureter.

# *Types of Aneurysms*



Saccular Aneurysm



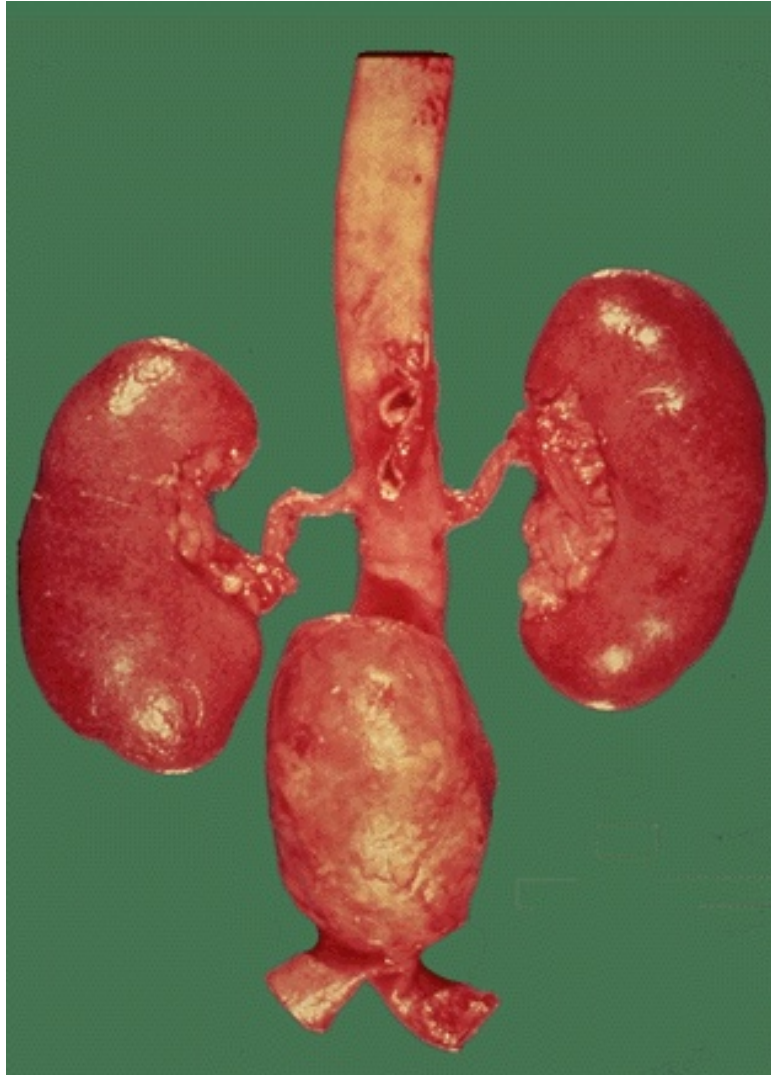
Fusiform Aneurysm



Ruptured Aneurysm

***The most likely causes of aneurysms are atherosclerosis , mycotic, syphilitic and congenital***

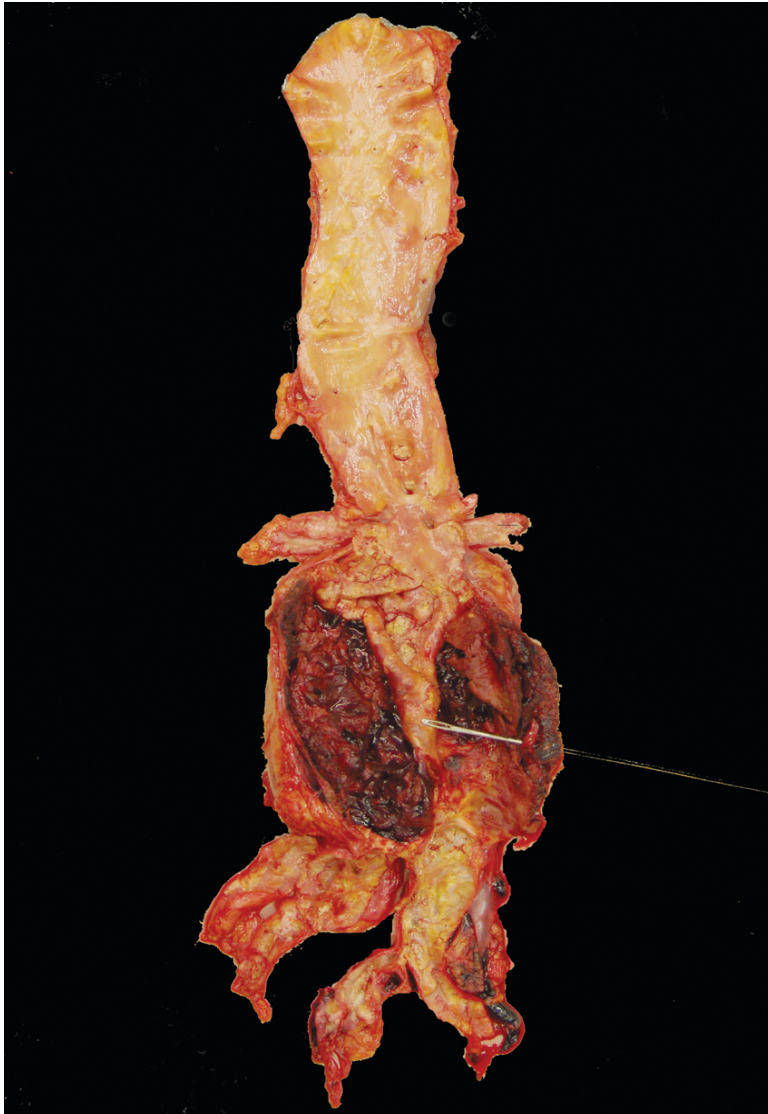
# ***Abdominal Aortic Aneurysm***



***An example of an atherosclerotic aneurysm of the aorta in which a large "bulge" appears just above the aortic bifurcation.***



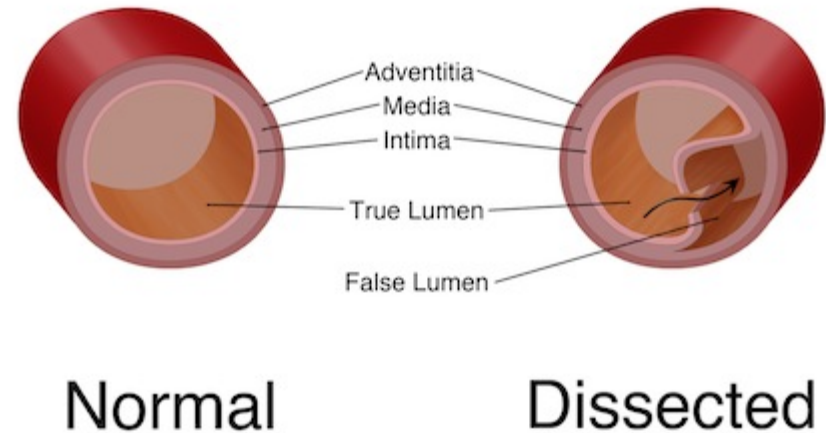
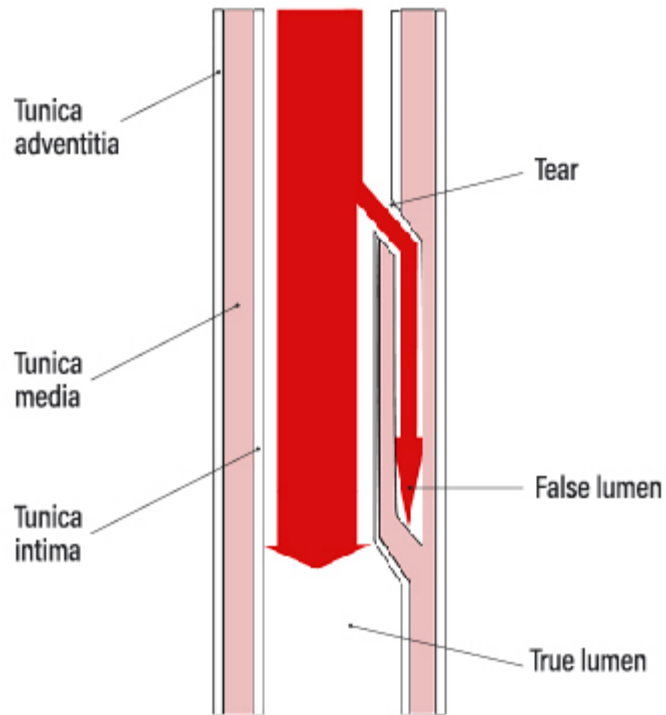
# ***Abdominal Aortic Aneurysm***



***Aneurysmal dilatation of the abdominal aorta with rupture , intraluminal thrombus and extensive aortic atherosclerosis .***

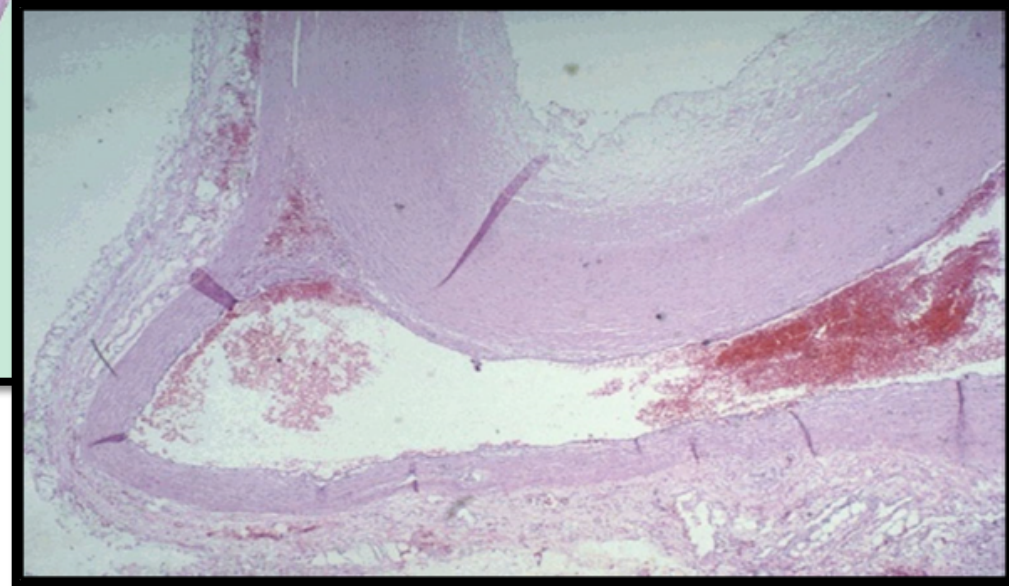
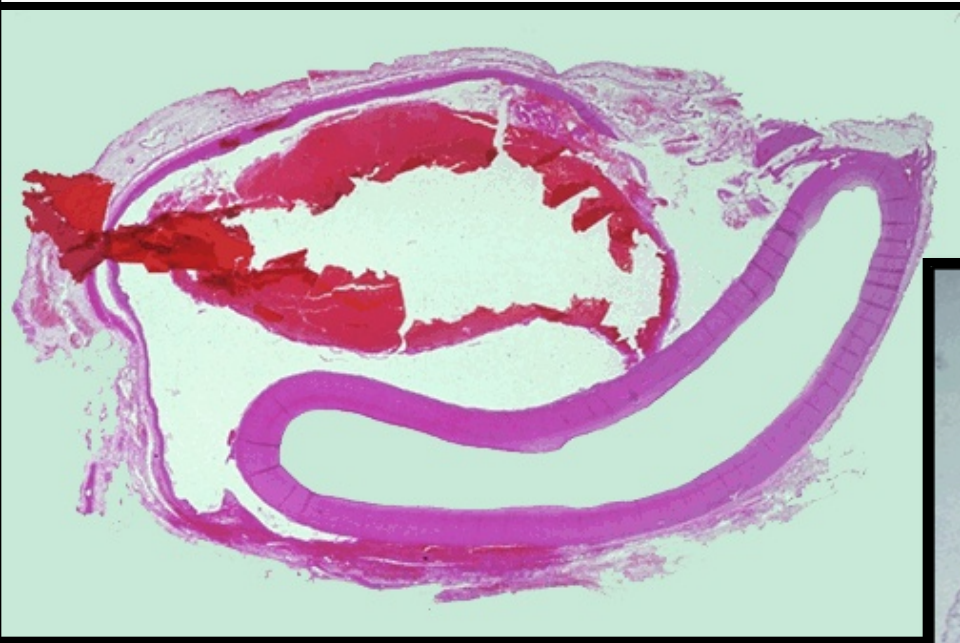
***The patient had suddenly developed severe abdominal pain, shocked and collapsed***

# *Dissecting aortic aneurysm*



***In aortic dissection there is a tear in the wall of the aorta and the blood enters into the wall through the defect, thereby dissecting the wall of the aorta. An aortic dissection is an extreme emergency and can lead to death in a matter of minutes. The blood can dissect up or down the aorta.***

# *Dissecting aortic aneurysm*



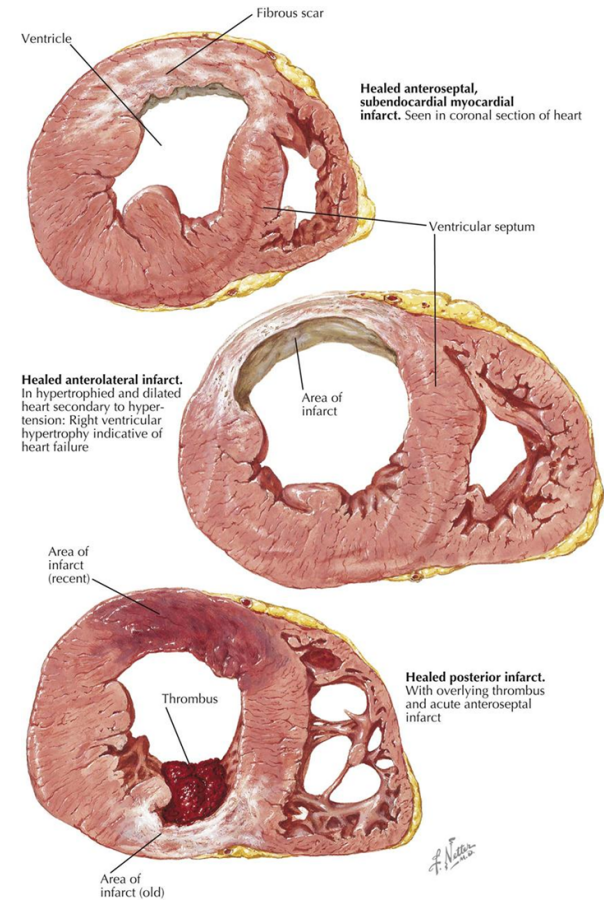
***This is a microscopic cross section of a dissecting aortic aneurysm showing a red blood clot compressing the aortic lumen. It is usually associated with atherosclerosis, inflammation, and degeneration of the connective tissue of the tunica media of the blood vessel.***

# ***MYOCARDIAL INFARCTION***

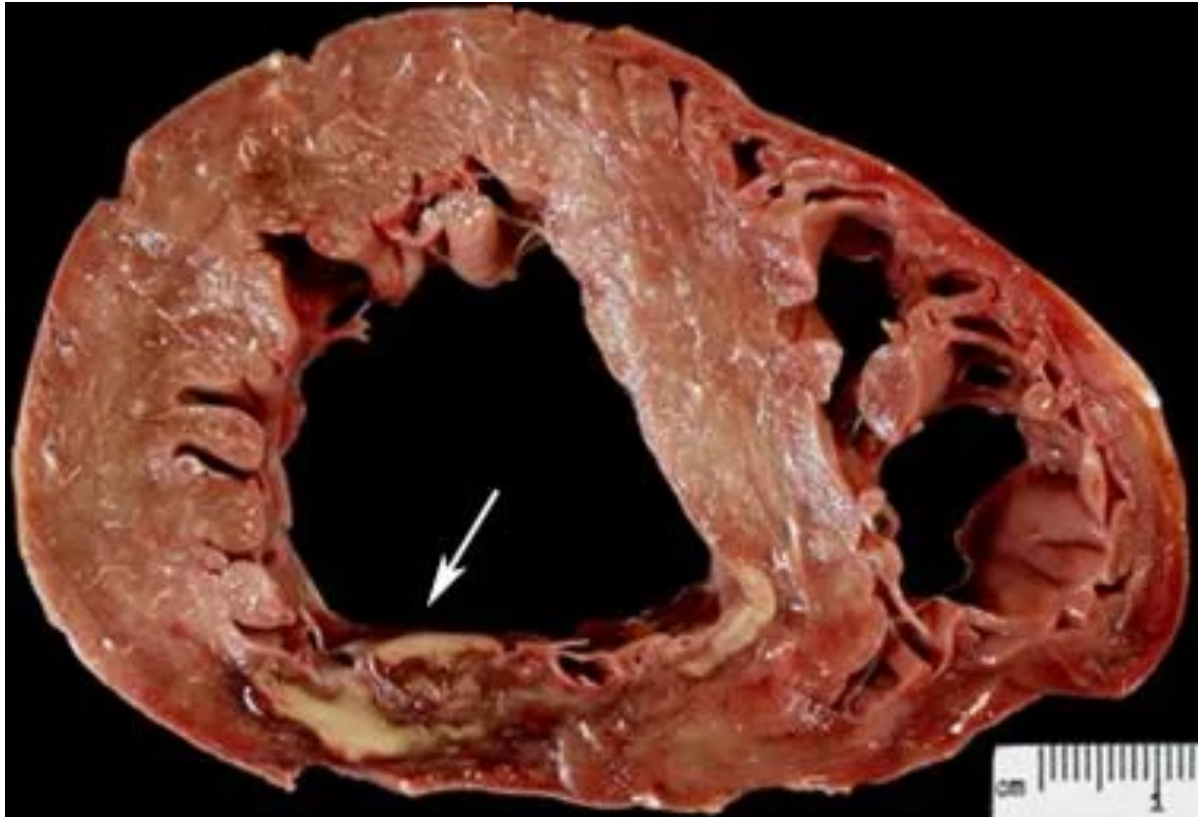
# Background information

## Changes in myocardial Infarction

Time	Gross changes	Microscopic changes
0-4 hours	None	None
4-12 hours	Mild Mottling (hemorrhagic look)	Coagulation necrosis
12-24 hours	Dark Mottling	More coagulation necrosis; neutrophils come in
1-7 days	Yellow infarct center with surrounding red borders	Neutrophils die, macrophages come to eat dead cells
1-2 weeks	Yellow infarct center with red gray borders	Granulation tissue
2-8 weeks	Scar	Collagen and fibrosis

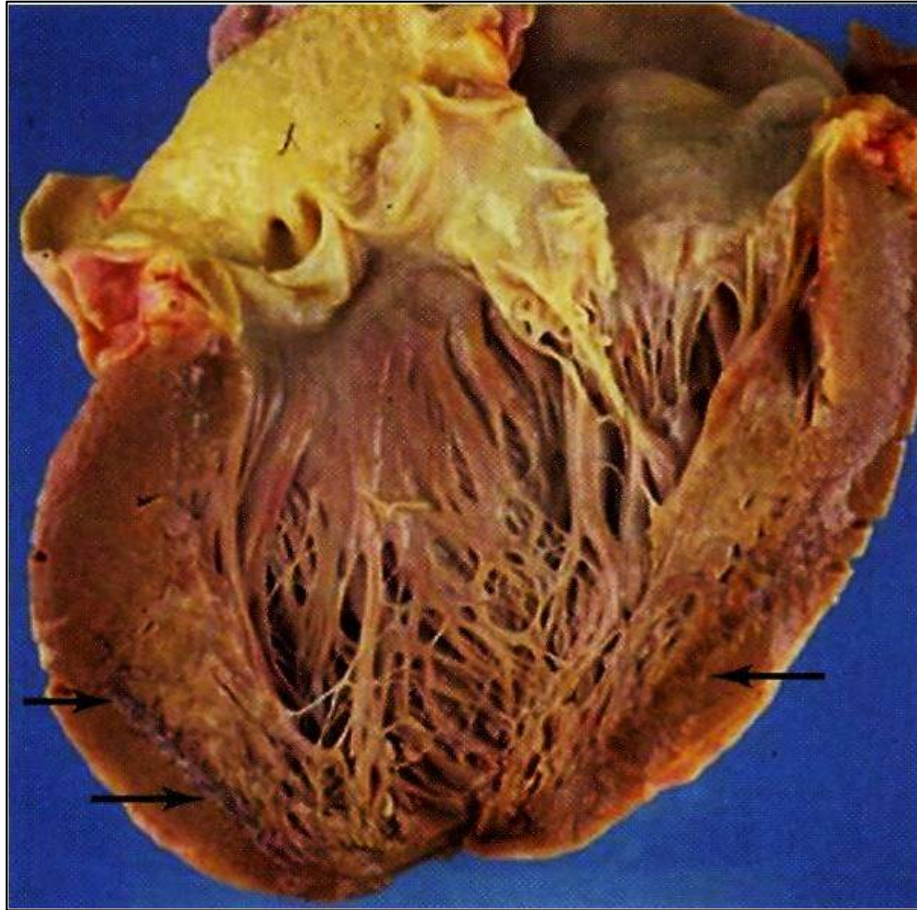


# *Myocardial Infarction - CS*



This is a cross section through the heart shows the larger left ventricular chamber and the small right ventricle. There is a transmural **myocardial infarction in the wall of the left ventricle (arrow)**. The center is tan with surrounding hyperemia. This infarction is "transmural" because it extends through the full thickness of the ventricular wall

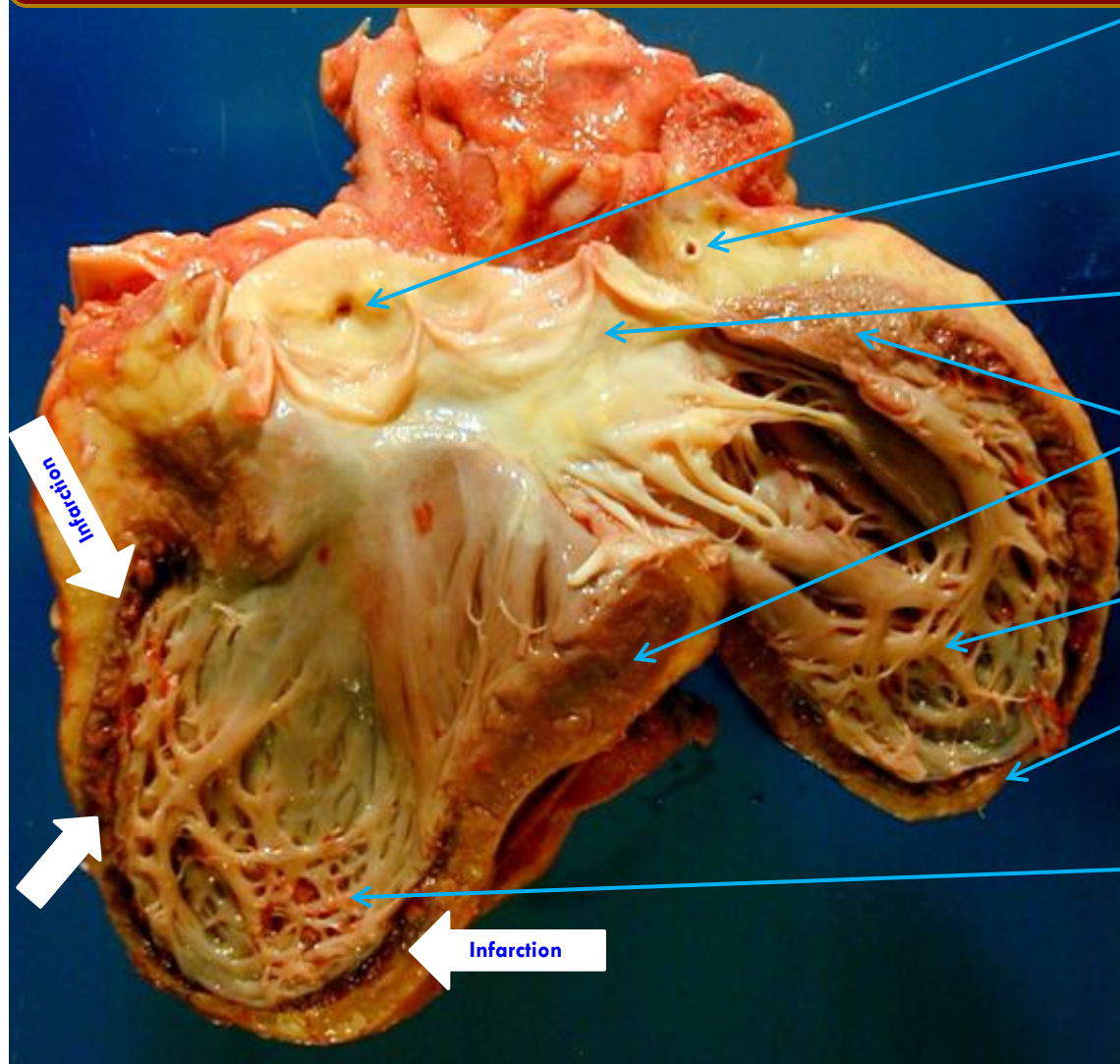
# *Myocardial Infarction - CS*



***This is a longitudinal section through the left ventricular chamber show transmural myocardial infarction (arrow) in the wall of the left ventricle and also involving the apex of the heart. The infarct is hyperemic.***

***Complications of MI: arrhythmias, ventricular aneurysm, rupture of myocardium, cardiac tamponade etc.***

# Myocardial Infarction



Right coronary ostium,  
patent

Left circumflex artery,  
patent

Aortic valve

Residual normal  
myocardium

Free wall of left ventricle

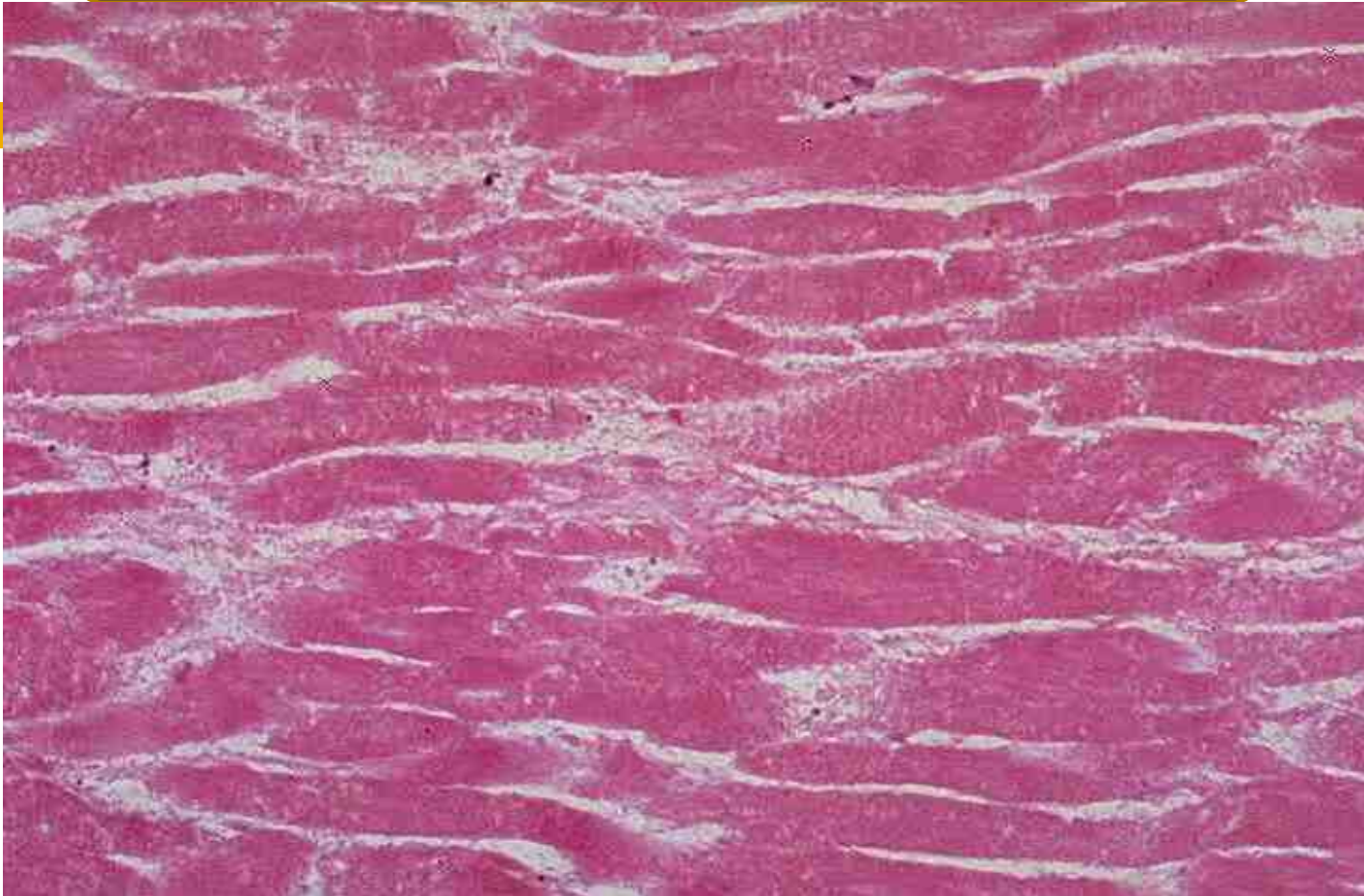
Markedly thinned left  
ventricular apex

Septal wall

The heart is opened showing the left ventricle. There is a **Massive Transmural Infarction** extending around the entire wall between the white arrows.

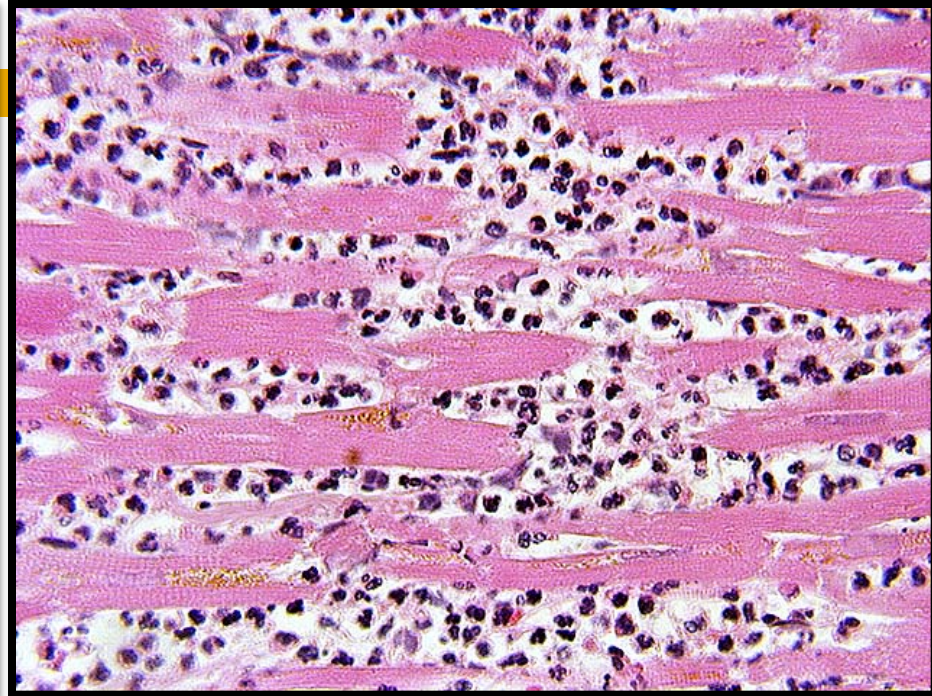
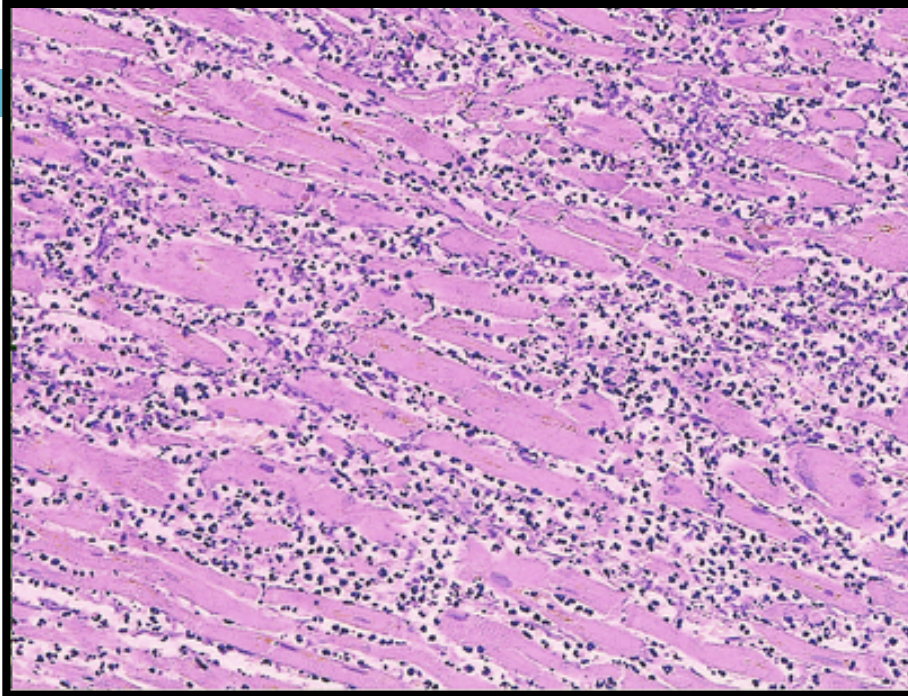


# *Recent Myocardial Infarction*



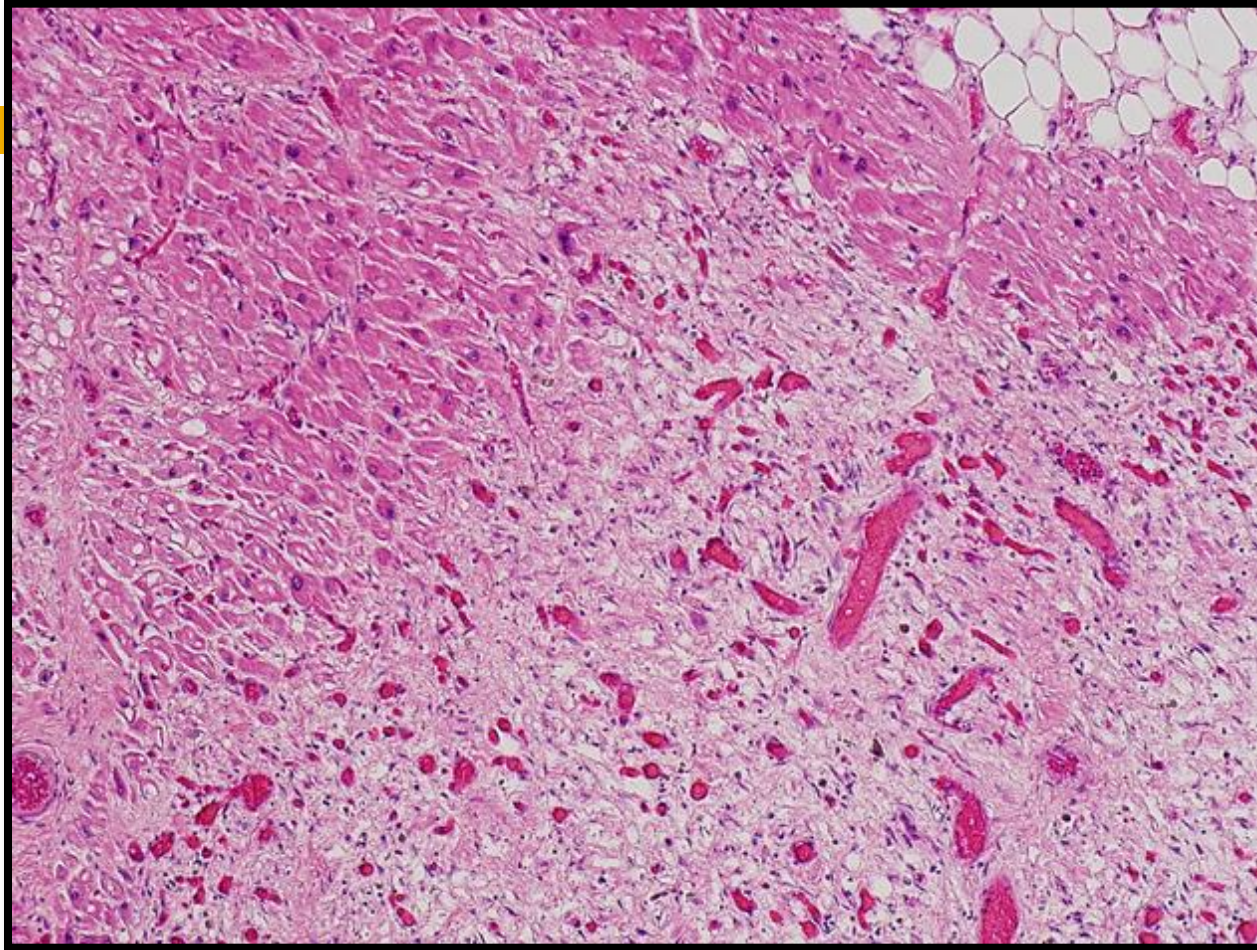
***Recent myocardial infarct (day 1): myocardial fibers are still well delineated (ghost outline), with intense eosinophilic (pink) cytoplasm, but lost their cross striations and the nucleus.***

# *Myocardial Infarction*



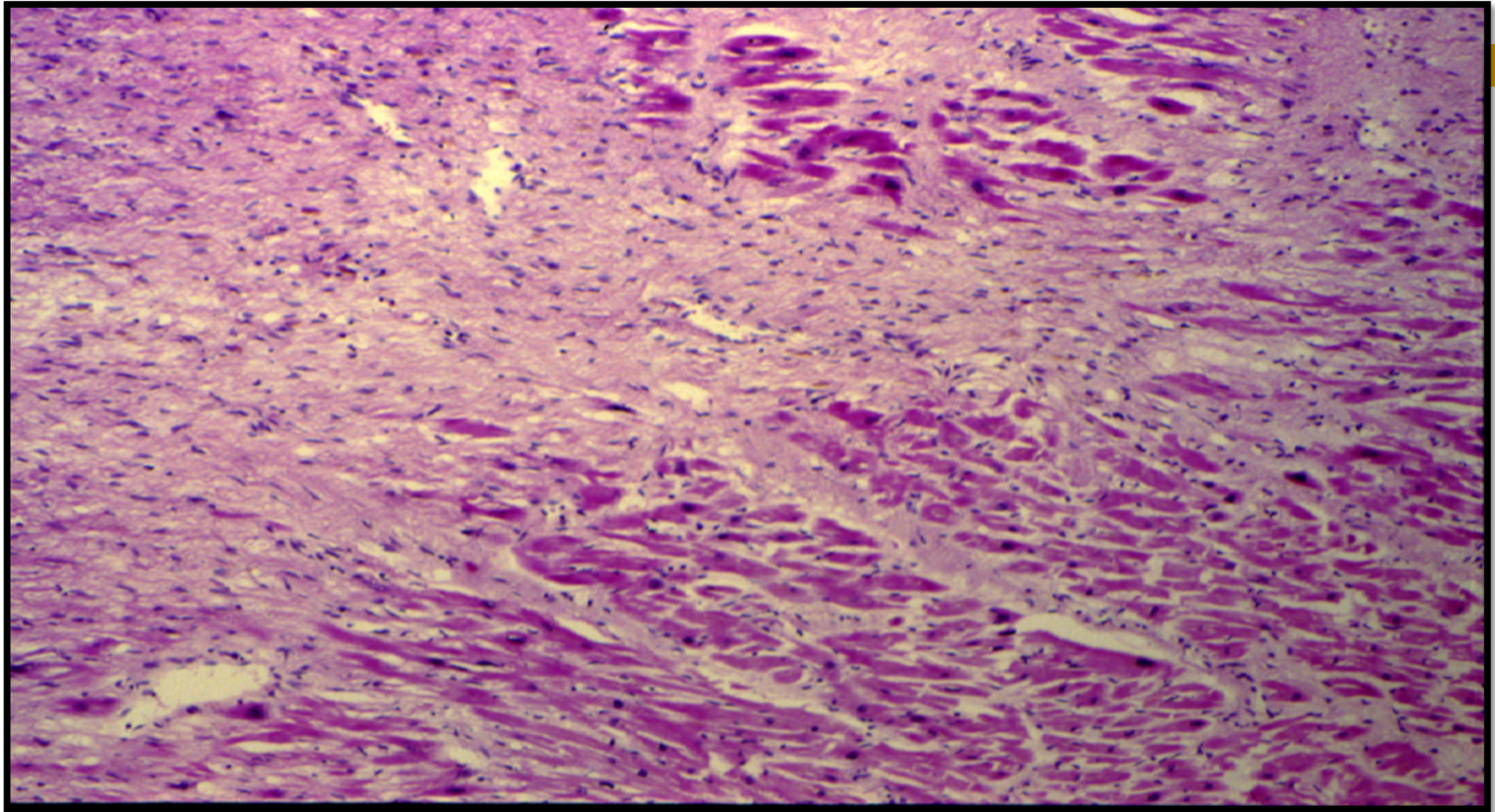
***Myocardial infarct (day 3-4) coagulative necrosis of myocardial cells and infiltration by many polymorphnuclear leukocytes (neutrophils).***

# *Myocardial Infarction*



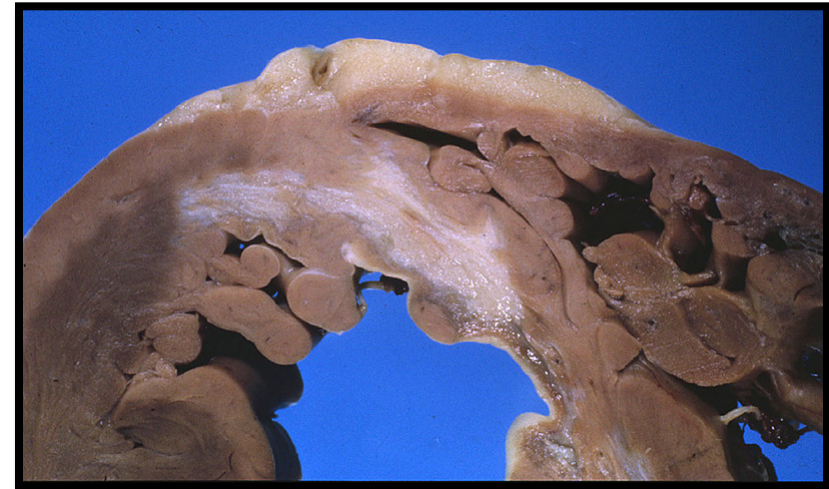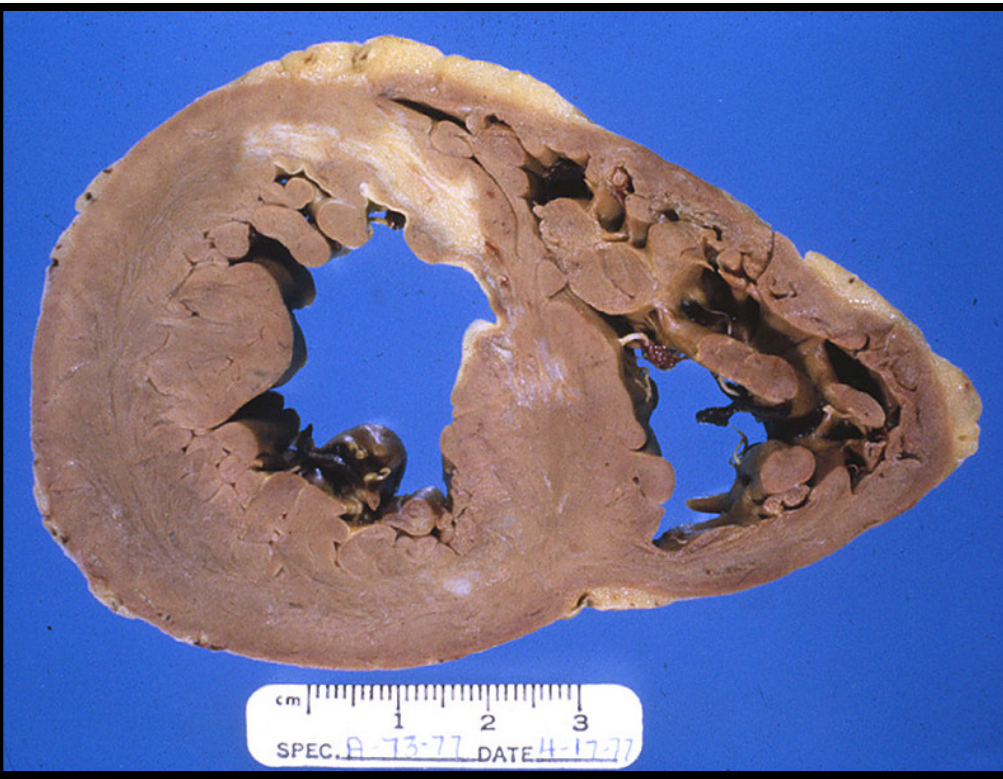***Myocardial infarct (week 1 to week 2) shows granulation tissue (new blood vessels, fibroblasts and chronic inflammatory cells)***

# *Myocardial Infarction - HPF*



**Scar of myocardial infarct (> 8 weeks) shows dense collagenous scar (fibrosis)**

# *Scar of an old Myocardial Infarction*



**Cross section of the left and right ventricles shows a pale and irregular focal fibrosis in the left ventricular wall with increased thickness . There is a collagenous scar in the wall of the left ventricle extending into the interventricular septum. Also, there is left ventricular hypertrophy.**

# ***CARDIOVASCULAR SYSTEM***

## ***Pathology Practical 2***

Prepared by:

- *Prof. Ammar Al Rikabi*
- *Dr. Sayed Al Esawy*

# ***NORMAL ANATOMY AND HISTOLOGY***

# Objectives:

**At the end of the 2<sup>nd</sup> P2 practical sessions of the cardiovascular block, the medical students will be able to:**

- Identify the morphologic **histopathological** features of:
  - chronic venous congestion of the liver
  - chronic venous congestion of the lung
  - Hypertensive changes in blood vessels
  - Myocardial hypertrophy
  - Thromboangitis obliterans
  - Giant cell arteritis
  - Leukocytoclastic vasculitis.



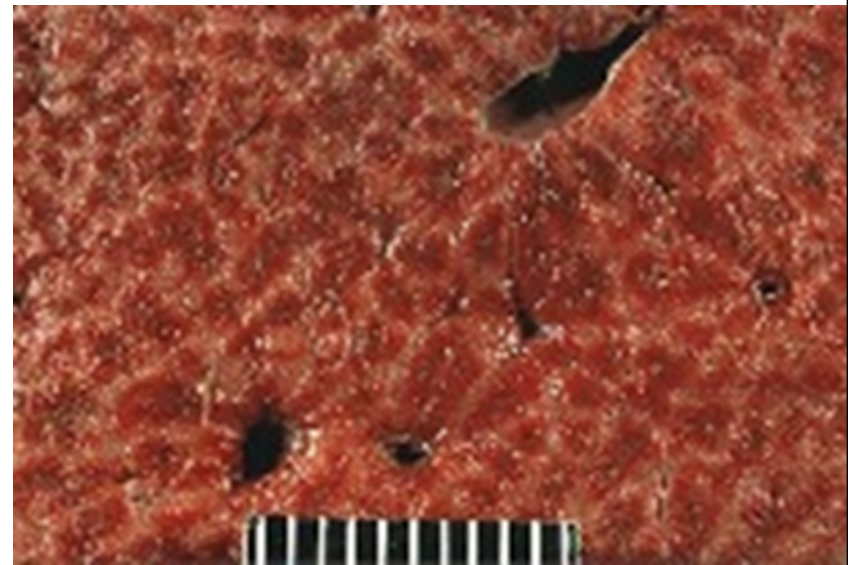
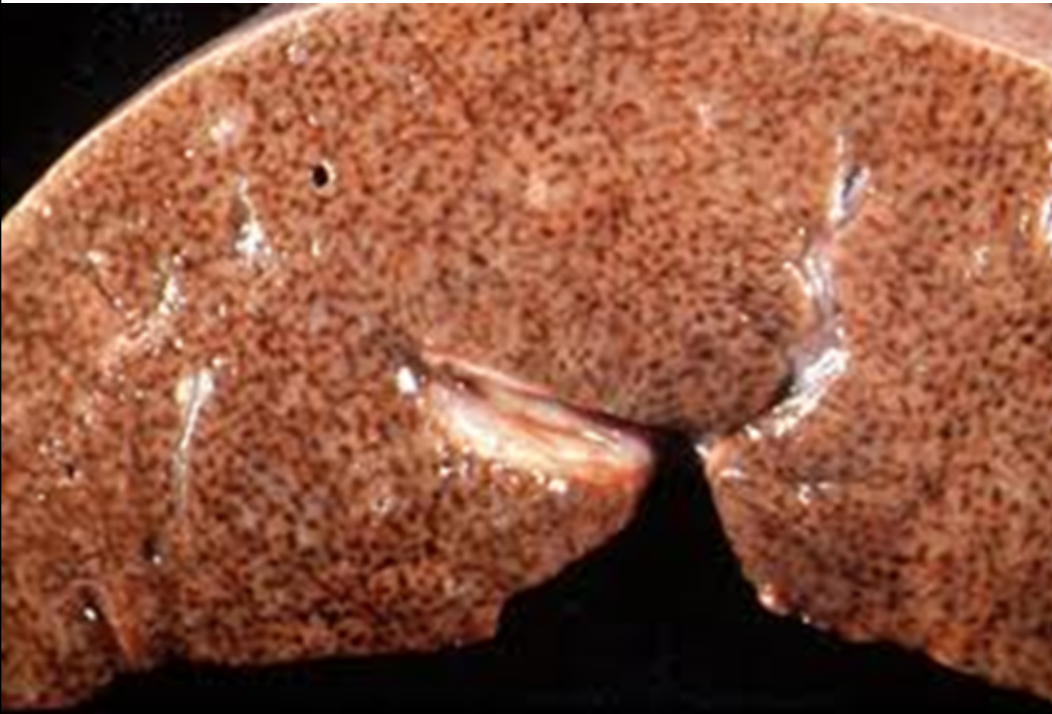
# **Chronic venous congestion of the liver (seen in right sided heart failure)**

# Additional information

## Hyperemia & Congestion

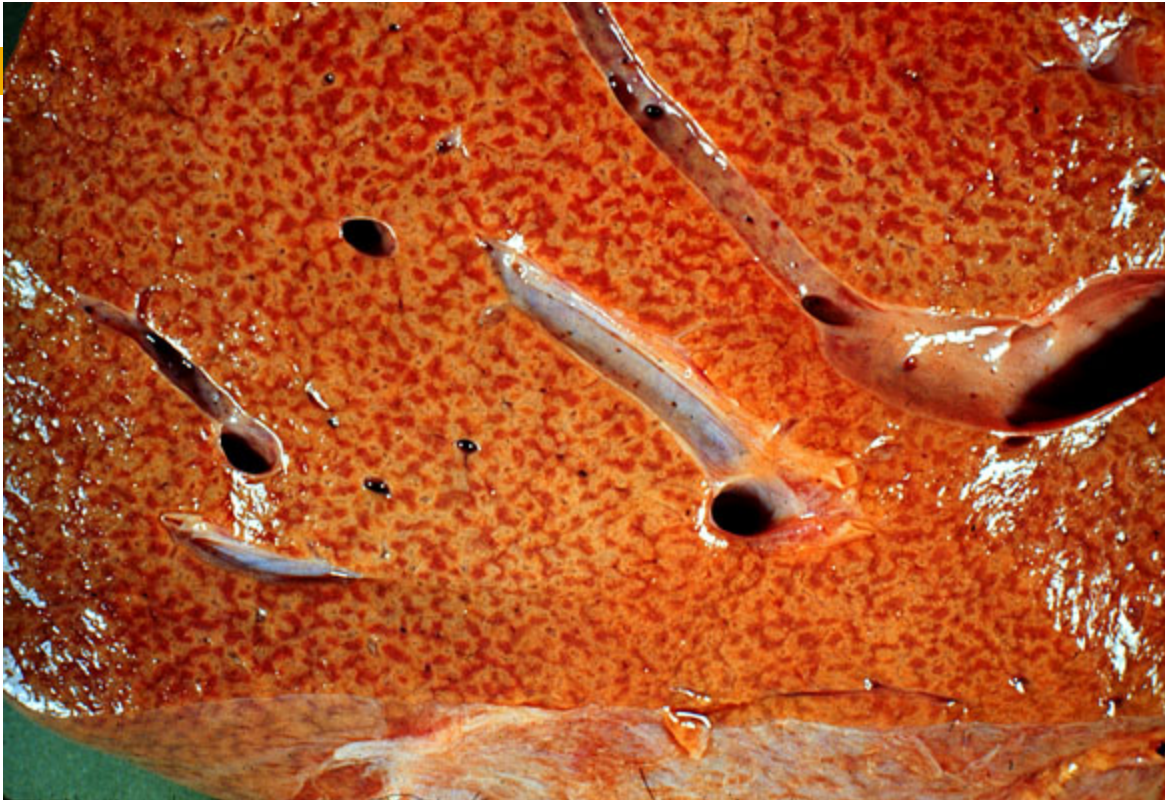
- **Hyperemia** is an *active process* resulting from tissue inflow because of arteriolar dilation, e.g. skeletal muscle during exercise or at sites of inflammation. The affected tissue is redder because of the engorgement of vessels with oxygenated blood.
- **Congestion** is a *passive process* resulting from impaired outflow from a tissue. It may be systemic e.g. cardiac failure, or local e.g. an isolated venous obstruction. The tissue has a blue-red color (*cyanosis*), due to accumulation of deoxygenated hemoglobin in the affected tissues.

## ***Chronic Congestion of the Liver - HPF***



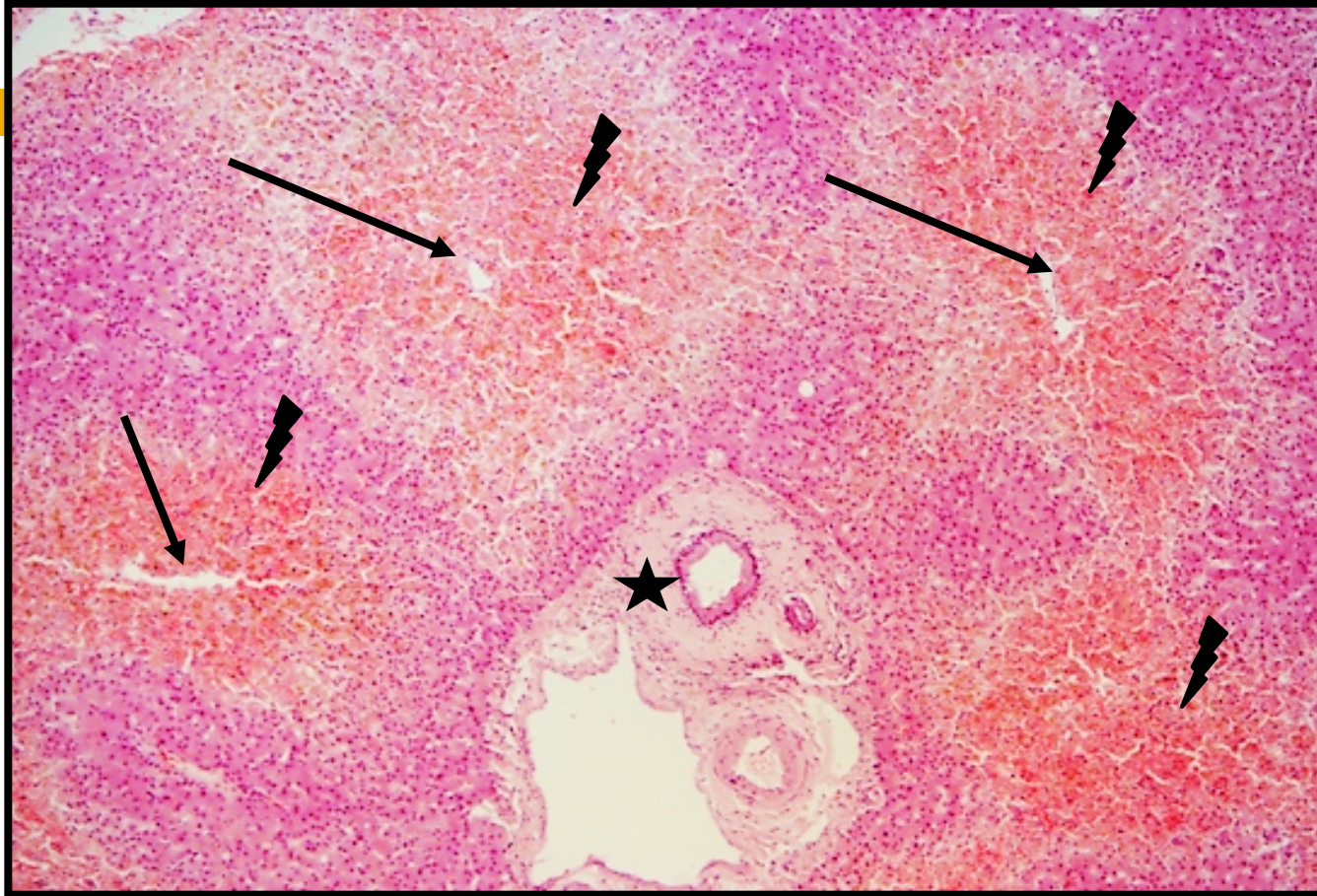
***In chronic passive congestion of the liver: on cut surface of liver shows red dots. These red dots represent venous congestion with accumulation of RBC's in centrilobular regions. And they are surrounded by grey/ tan /pale zones of uncongested normal liver. This appearance is described as nutmeg liver. The most common cause is passive congestion secondary to right sided heart failure.***

# *Chronic Congestion of the Liver - CS*



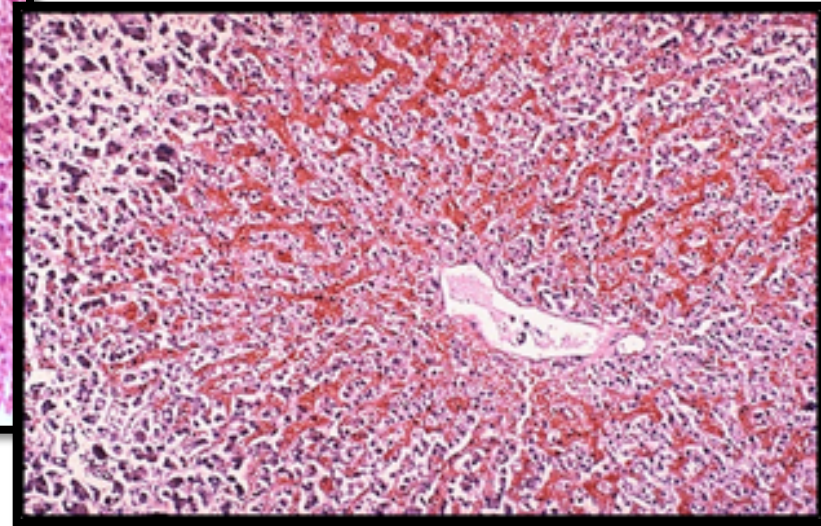
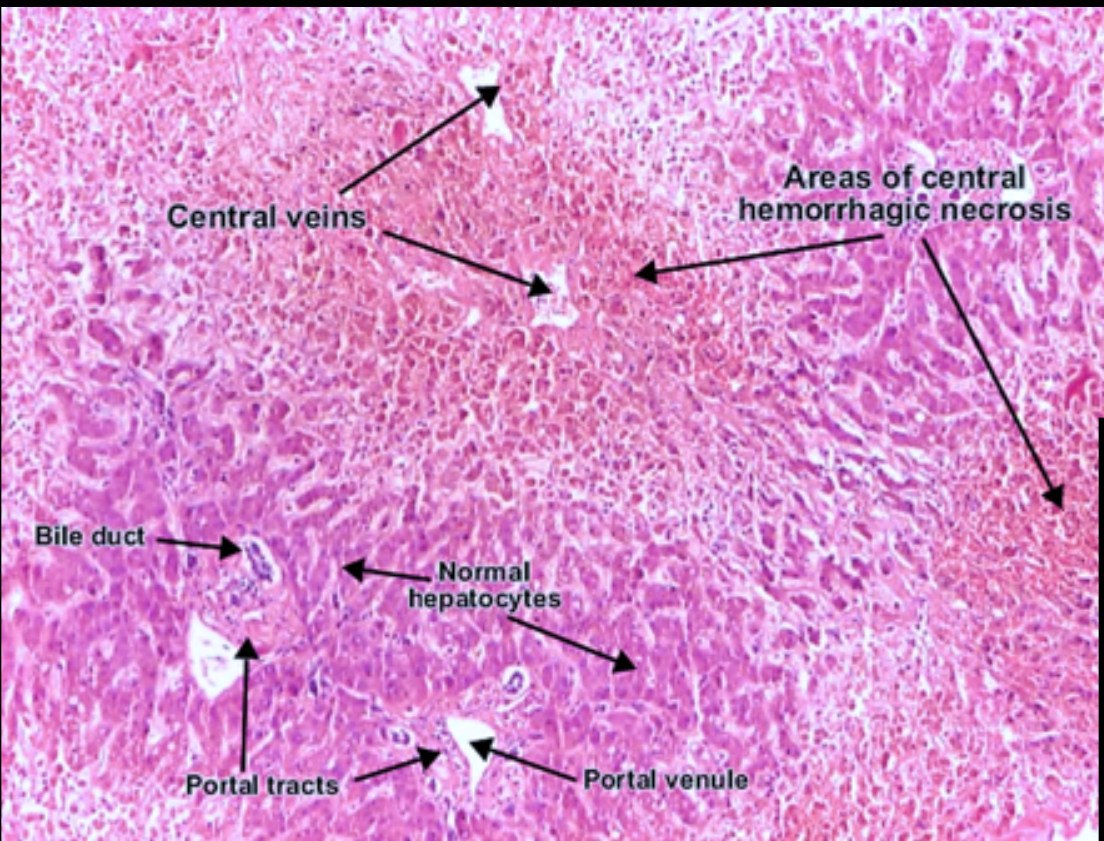
***A gross view of nutmeg appearance of liver characteristic of centrilobular necrosis or passive congestion of the liver.***

## ***Chronic Congestion of the Liver - CS***



***Microscopically, there is passive congestion in the central portion of each liver lobule. The central veins (which are present in the center of each liver lobule) become congested and dilated (arrows) → leads to congestion in the surrounding sinusoids → which ultimately leads to necrosis of the hepatocytes around the central vein called centrilobular necrosis (lightning arrows). The portal tracts (star) are unaffected.***

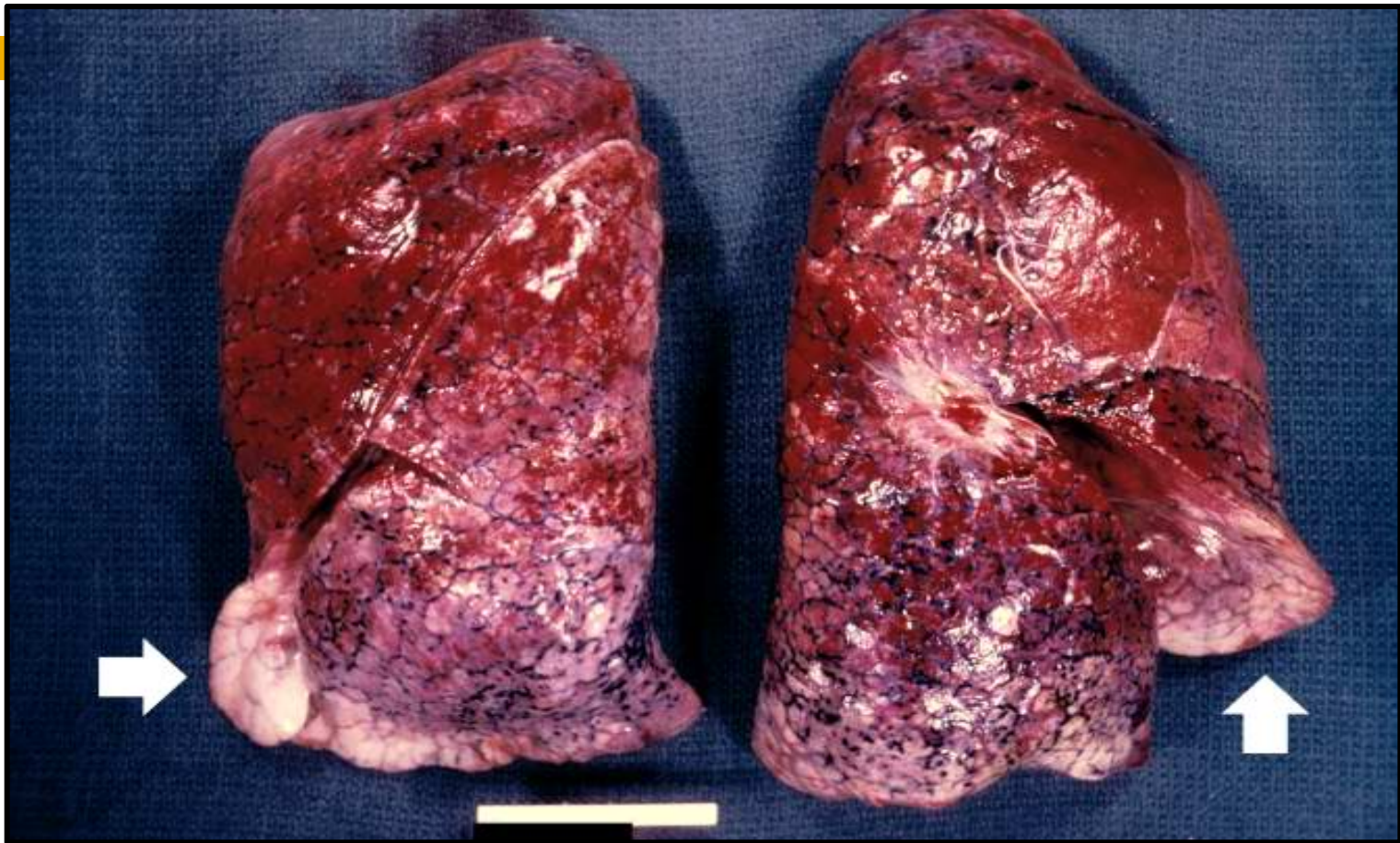
# Chronic Congestion of the Liver - LPF



***Central veins are dilated and congested surrounded by necrotic hepatocytes (called centrilobular necrosis) with associated hemorrhage and hemosiderin-laden macrophages. In long-standing cases these areas are replaced by fibrosis. This type of fibrosis is called hepatic fibrosis or cardiac cirrhosis.***

# **Chronic venous congestion of the lung (seen in left sided heart failure)**

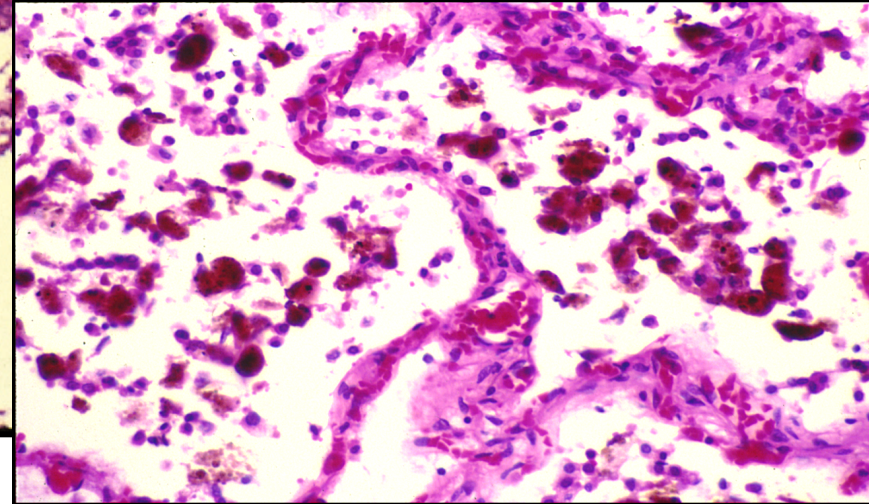
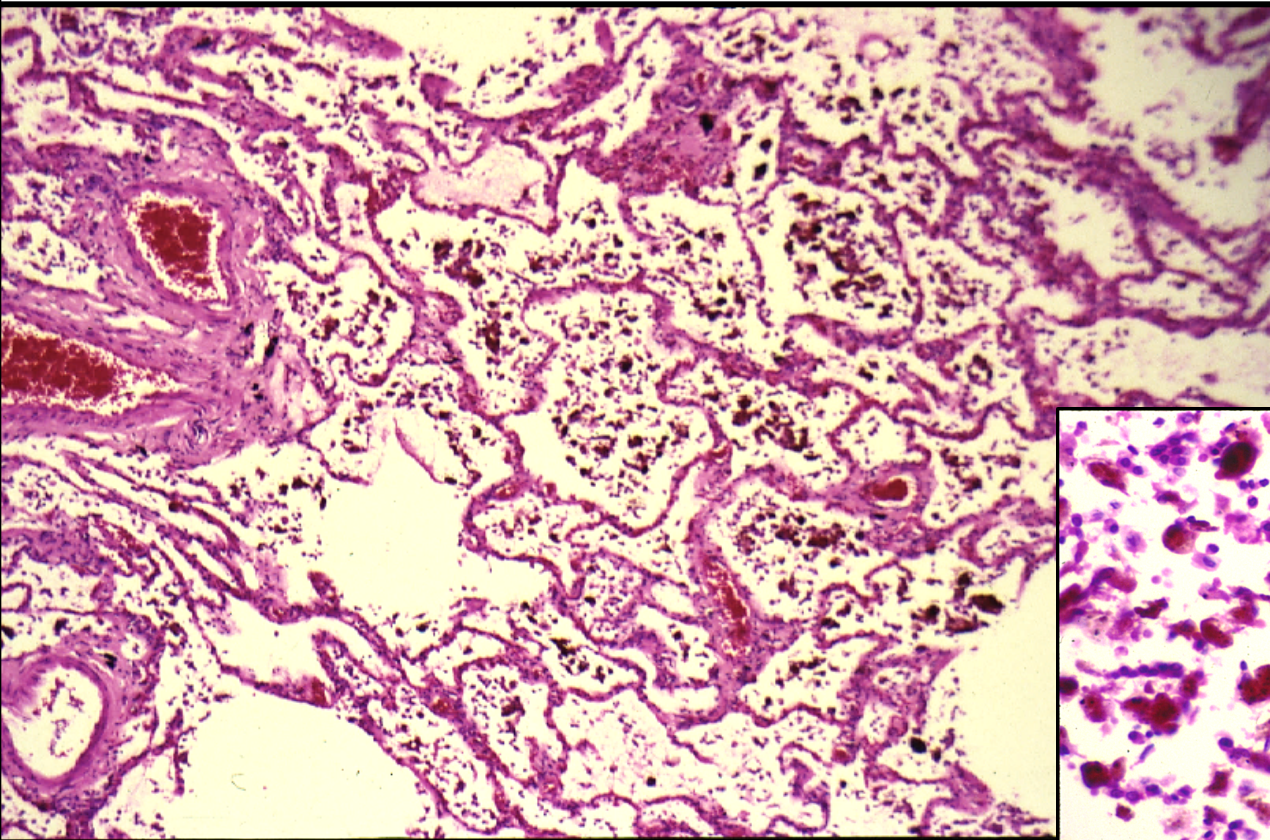
## ***Chronic venous congestion of the lung - Gross***



***The lungs are enlarged, heavy, distended and red. The reddish coloration of the tissue is due to congestion. Some normal pink lung tissue is seen at the edges of the lungs (arrows) The cut surface is hemorrhagic and wet and frothy blood oozes on squeezing.***

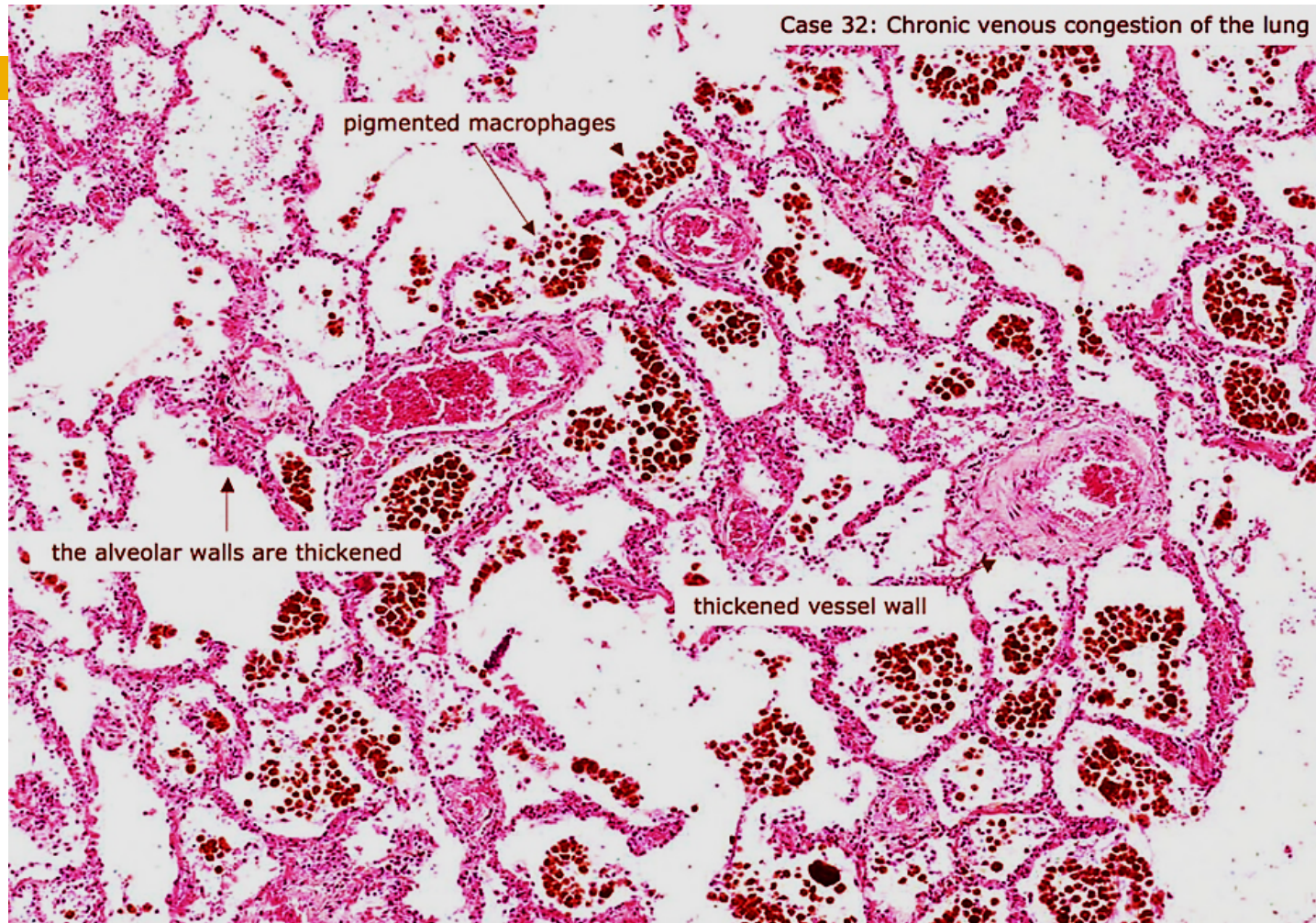


# Chronic venous congestion of the lung - LPF

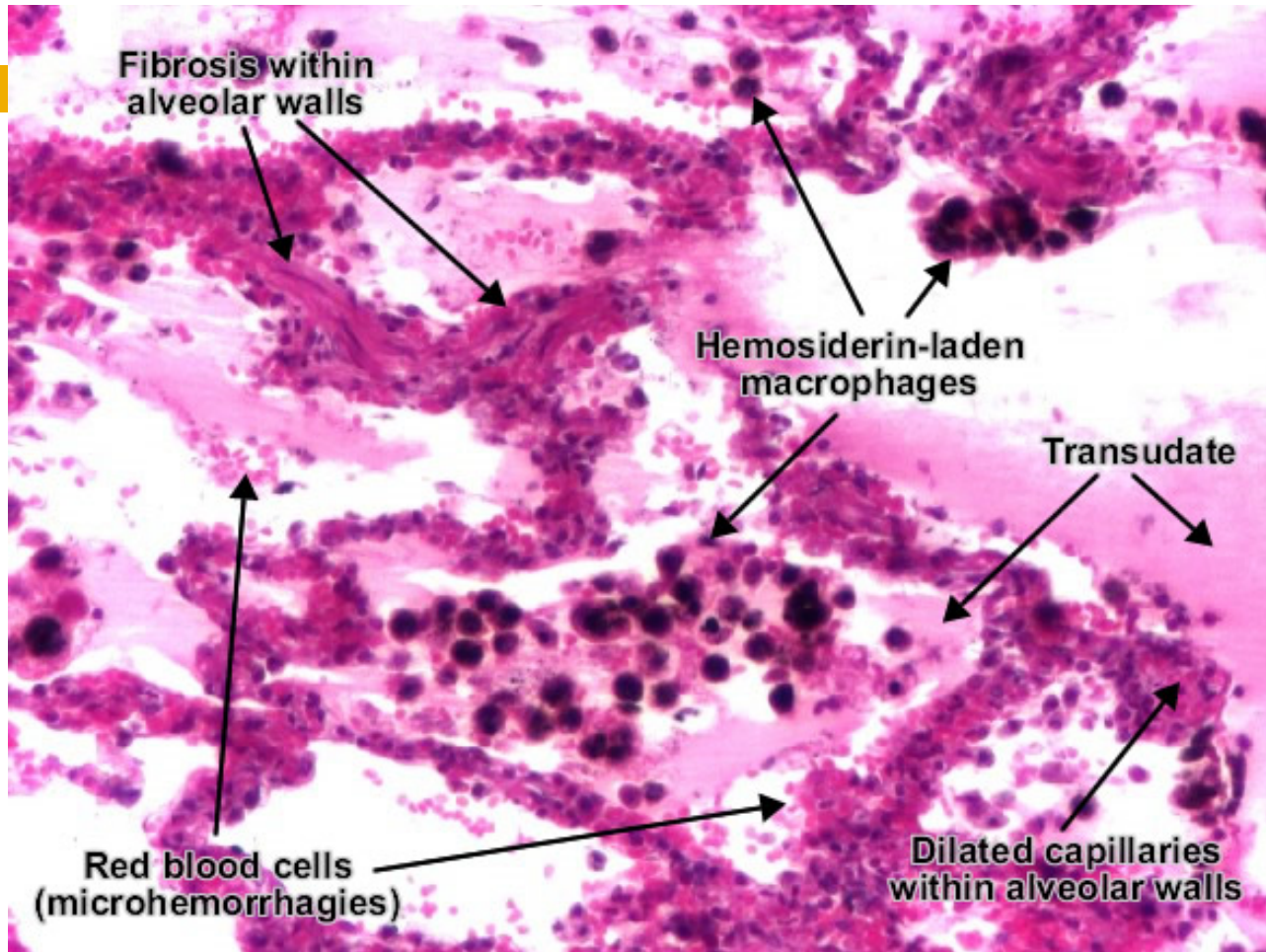


***The alveolar walls are thickened by dilated and engorged capillaries and edema fluid. The alveoli are filled with edematous fluid, red blood cells and many alveolar macrophages which are filled with hemosiderin pigment derived from red cells breakdown. These alveolar macrophages are called heart failure cells. With time the alveolar septa become fibrosed.***

# Chronic venous congestion of the lung - LPF



# ***Chronic venous congestion of the lung - HPF***



***The alveoli contain edematous fluid, red blood cells and large alveolar macrophages (heart failure cells), which are filled with haemosiderin pigment derived from red cells breakdown.***

# BLOOD VESSELS IN HYPERTENSION





Normal

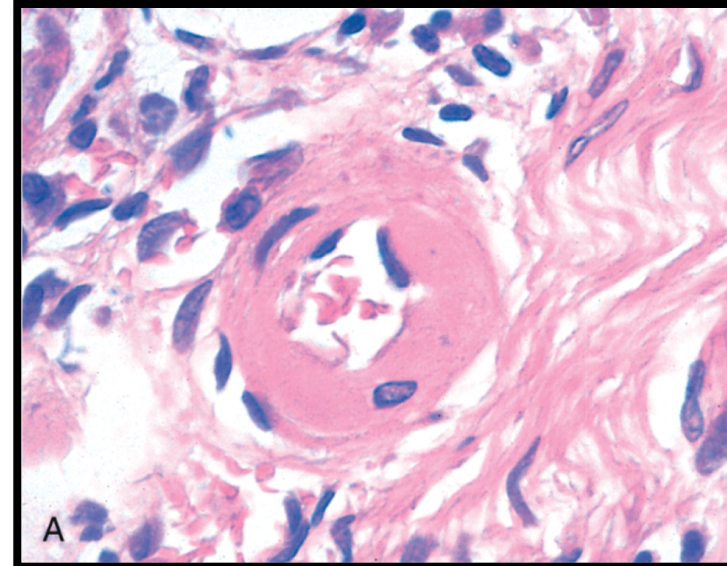
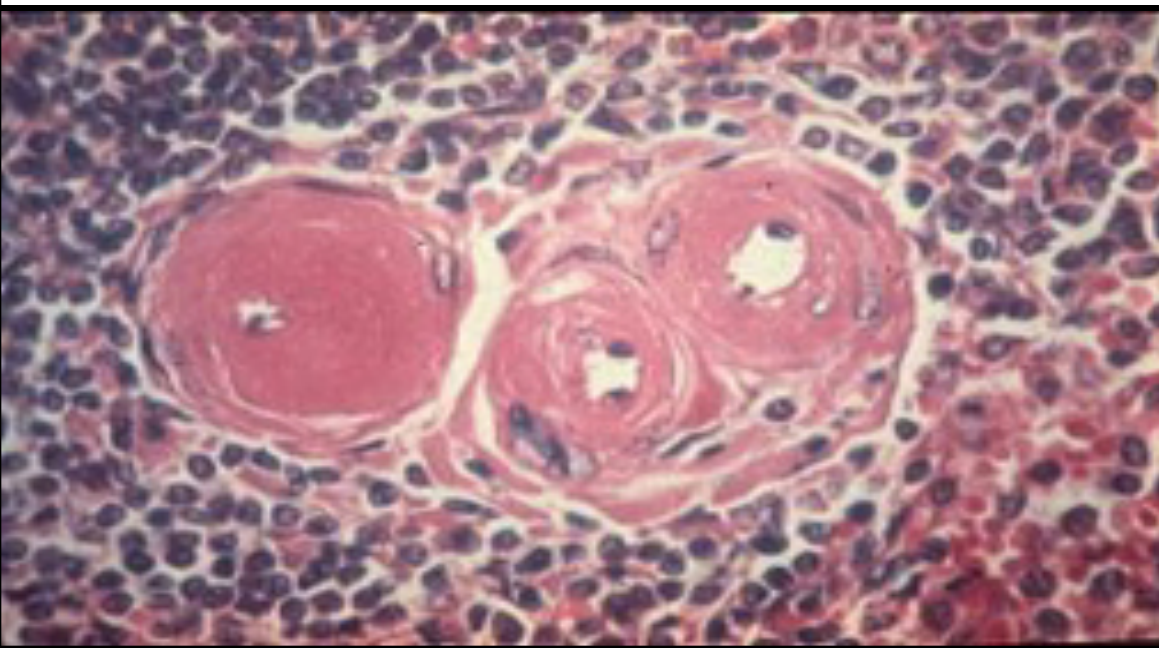


Hyaline arteriosclerosis



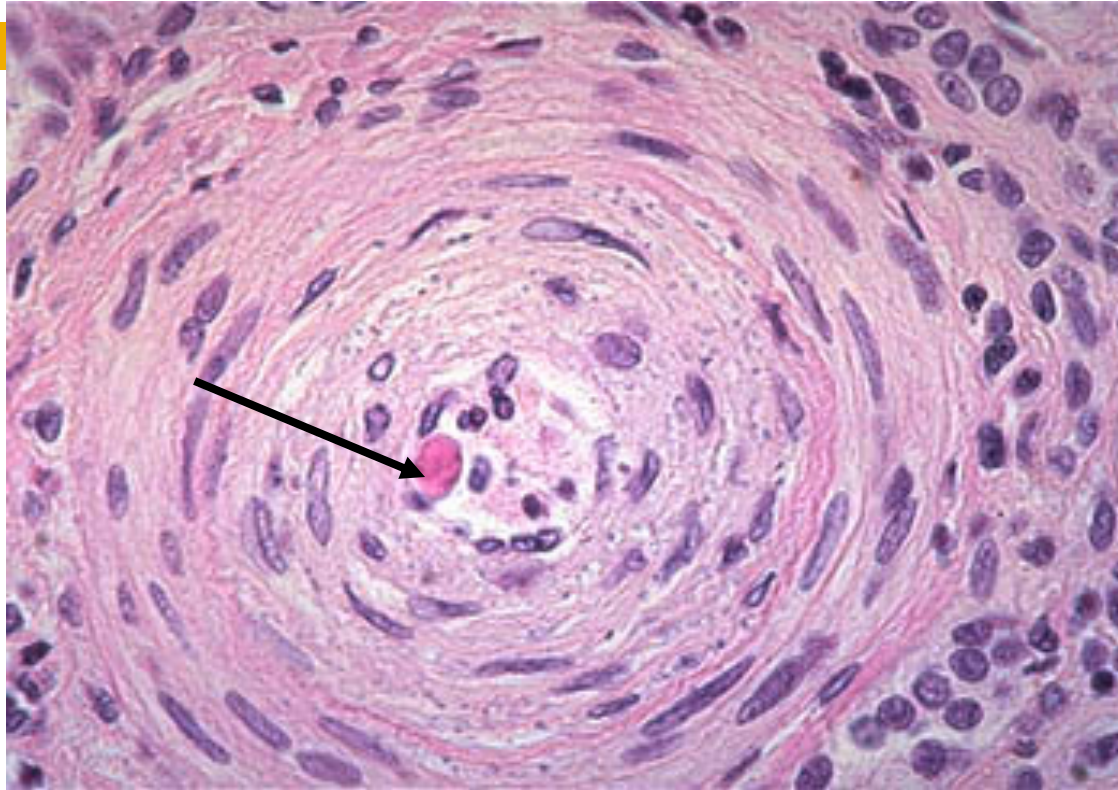
Hyperplastic arteriosclerosis

## *Hyaline arteriosclerosis - HPF*



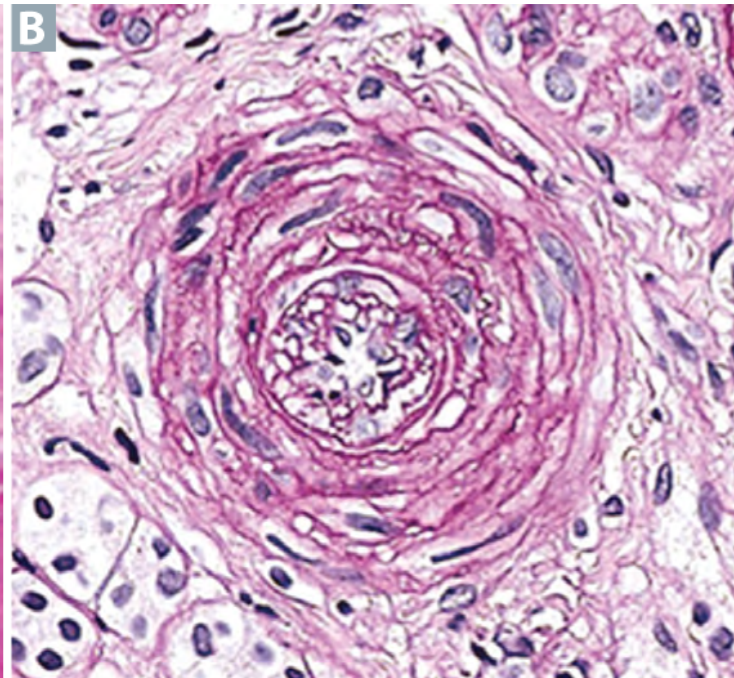
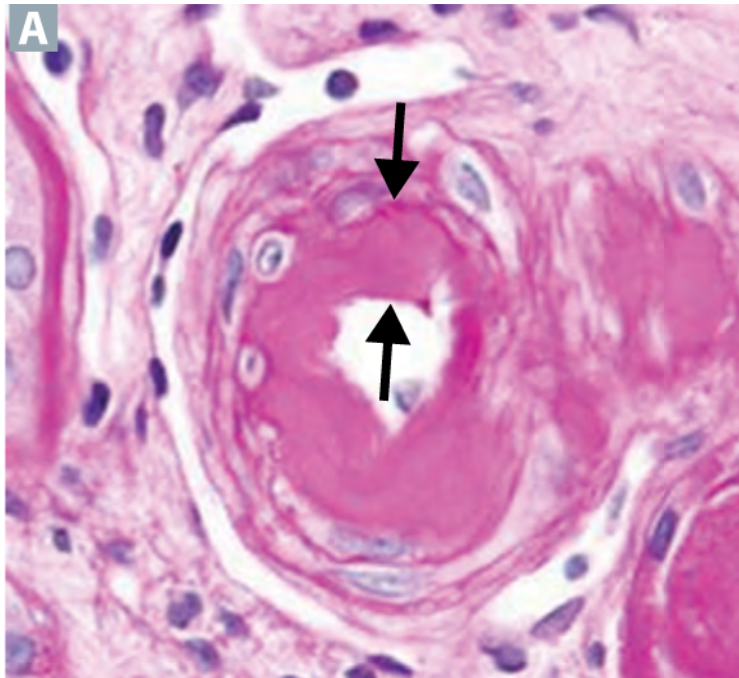
***Hyaline arteriosclerosis (arterial hyalinosis or arteriolar hyalinosis):*** it is the thickening of the walls of arterioles by the deposits that appear as homogeneous pink hyaline material. It is commonly found in diabetics, hypertensives and elderly.

# *Hyperplastic arteriolosclerosis - HPF*



**Hyperplastic arteriolosclerosis:** It is characterized by thickening of the arteriolar wall due to the concentric proliferation of smooth muscle cells, giving the arterioles an “onion skin” appearance. These changes represent an adaptive response of arterioles to severe (“malignant”) hypertension. The onion-skinning causing luminal obliteration of the arteriole (arrow). May be associated with necrotizing arteriolitis and fibrinoid necrosis of the blood vessel.

# *Hyaline arteriolosclerosis - HPF*



**A. Hyaline arteriolosclerosis**  
**Arteriosclerosis (hardening of the arteries) involves both small and large vessels. It is commonly found in diabetics, hypertensives and elderly.**

**B. Hyperplastic arteriolosclerosis:** *is a type of small vessel arteriosclerosis, it is characteristic of malignant hypertension. The “onionskinning” is causing luminal obliteration. Hyperplastic arteriolosclerosis is often accompanied by fibrinoid necrosis of the arterial intima and media (most prominent in the kidney and can lead to acute kidney failure).*



***LEFT  
VENTRICULAR  
HYPERTROPHY***

# Causes of ventricular hypertrophy

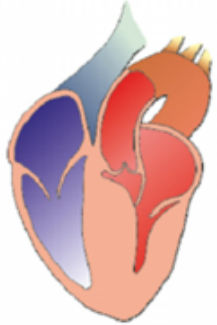
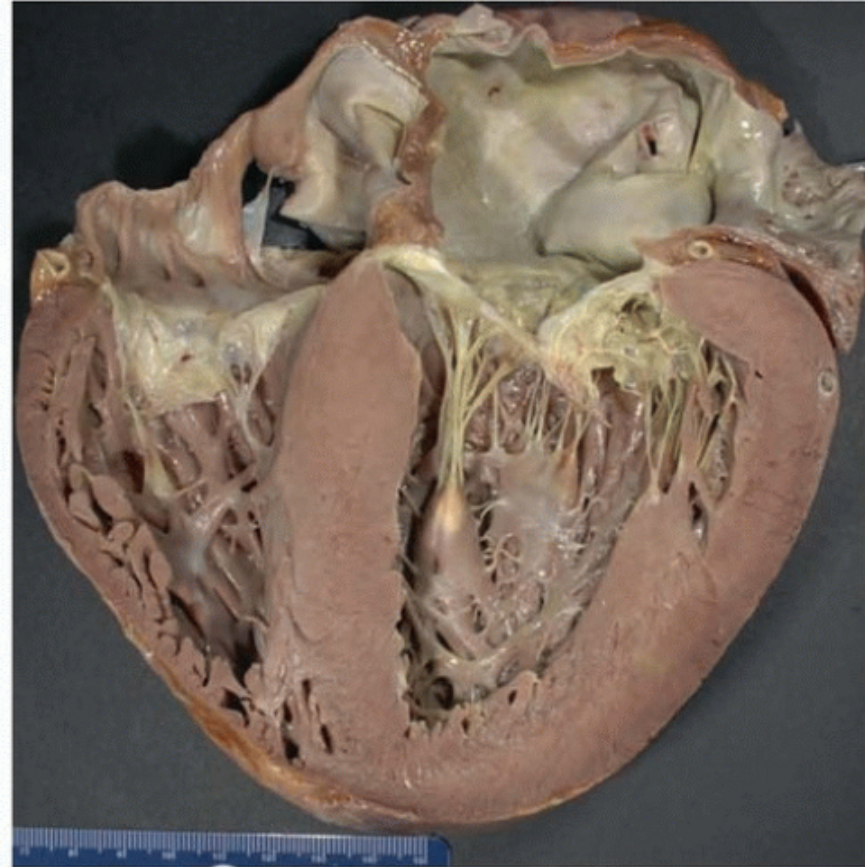
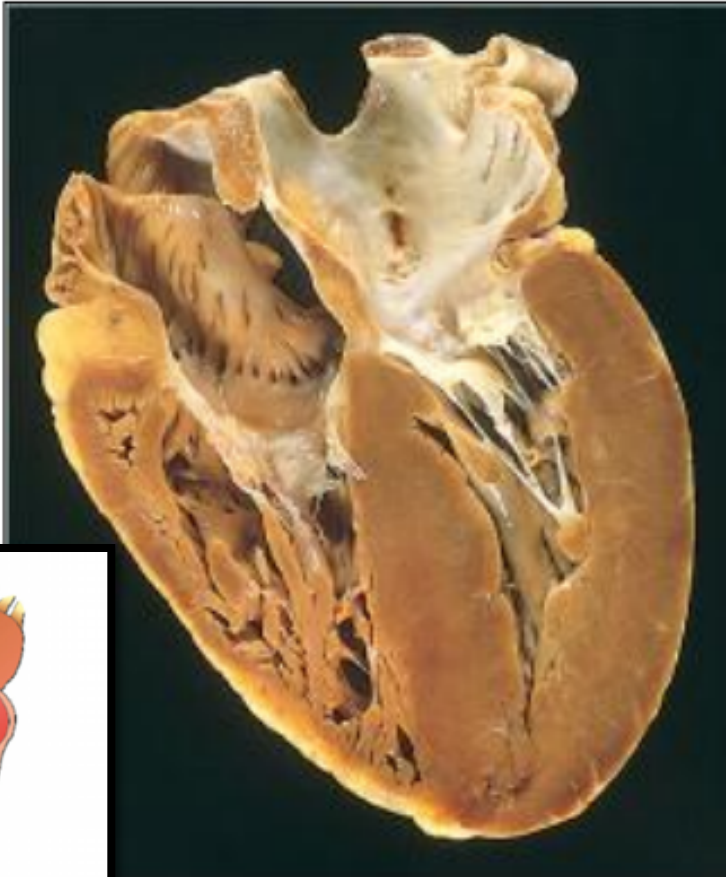## Left ventricular hypertrophy :

- Systemic hypertension
- Ischaemic heart disease
- Aortic valve stenosis
- Primary diseases of the myocardium or cardiomyopathy

## Right ventricular hypertrophy:

- Pulmonary hypertension
  - asthma, COPD
  - pulmonary thromboembolic disease
  - primary pulmonary hypertension
- Pulmonary valve stenosis
- Left-to-right shunts (volume overload)

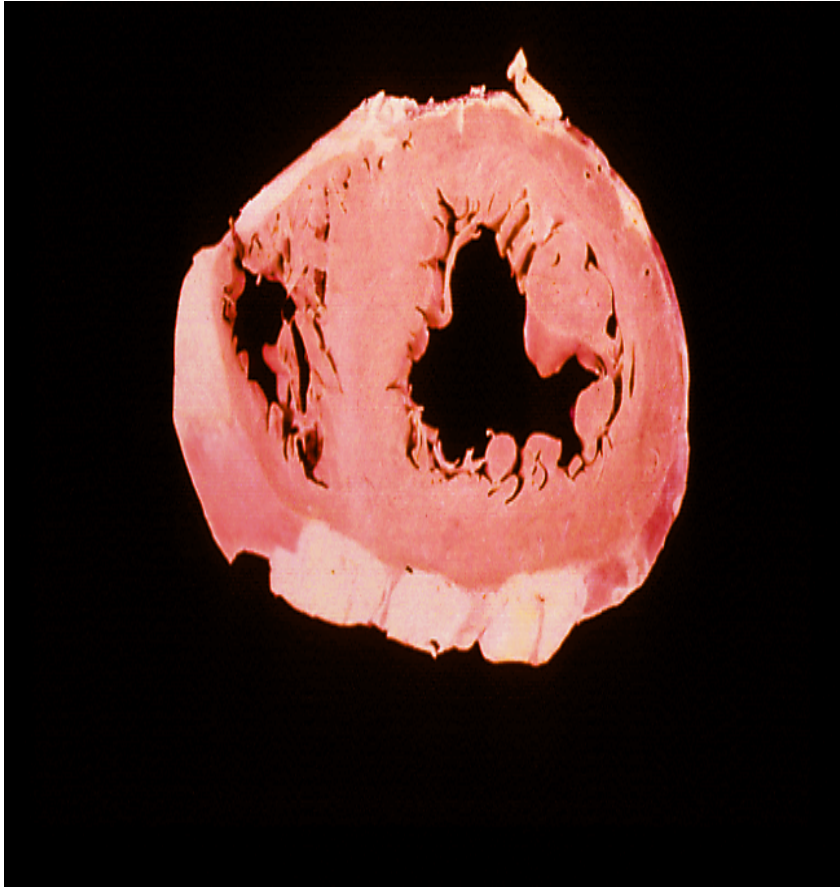
# Left ventricular hypertrophy - Gross



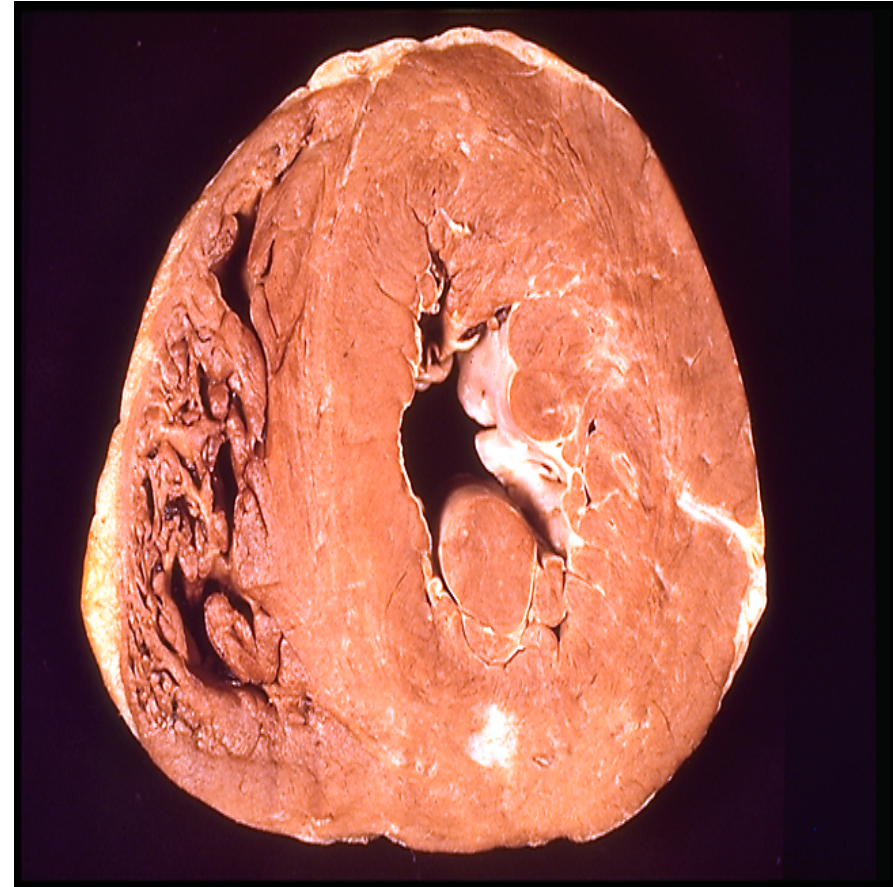Heart with  
left ventricular hypertrophy

***Heart from a hypertensive patient. The left ventricle wall is very thick. However the rest of the heart is fairly normal in size as is typical for hypertensive heart disease. The hypertension creates a greater pressure load on the left side of the heart to induce the hypertrophy***

# Normal and hypertrophied left ventricle – cross section

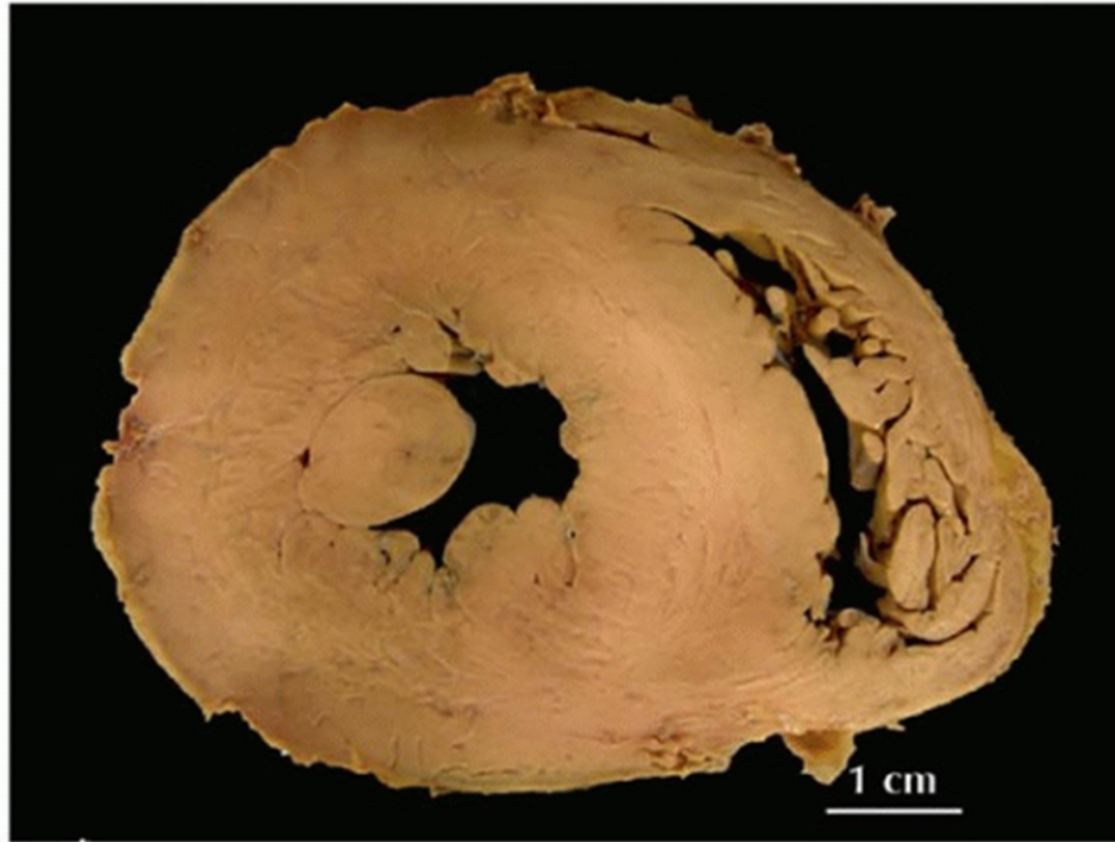


**Normal ventricles**



**Left ventricular  
hypertrophy**

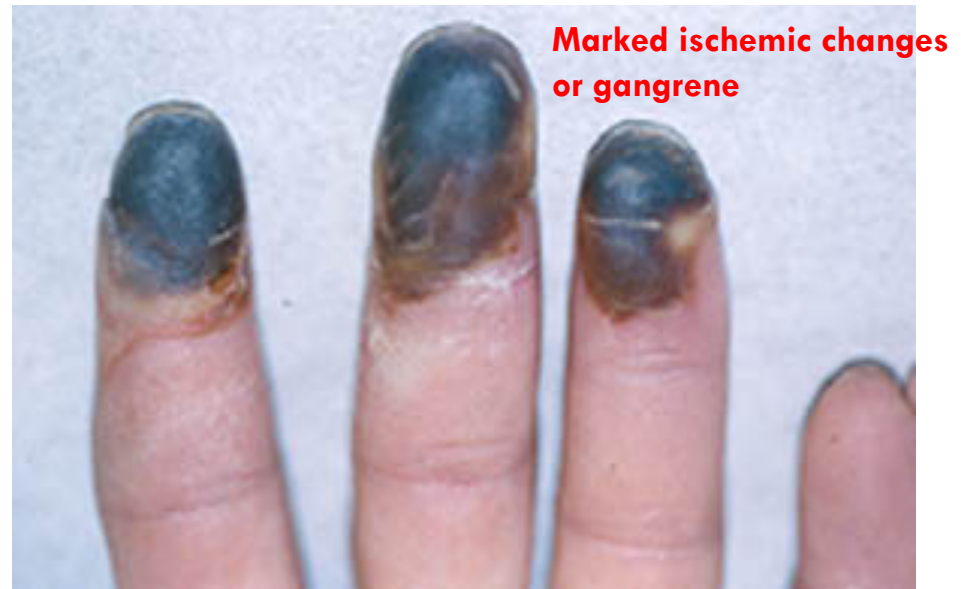
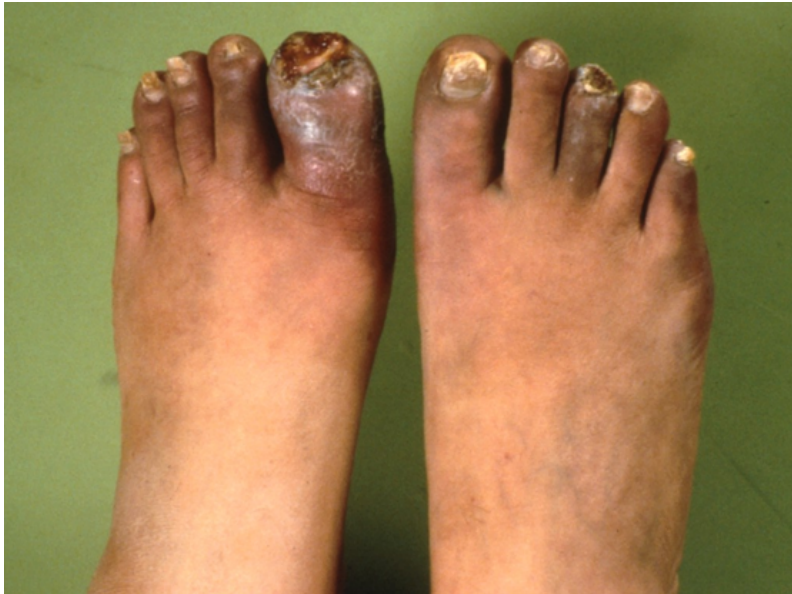## Left ventricular hypertrophy - Gross



*This cross section view of the heart shows the left ventricle in the left of the picture. The heart is from a severe hypertensive. The left ventricle is grossly thickened. The myocardial fibers have undergone hypertrophy.*

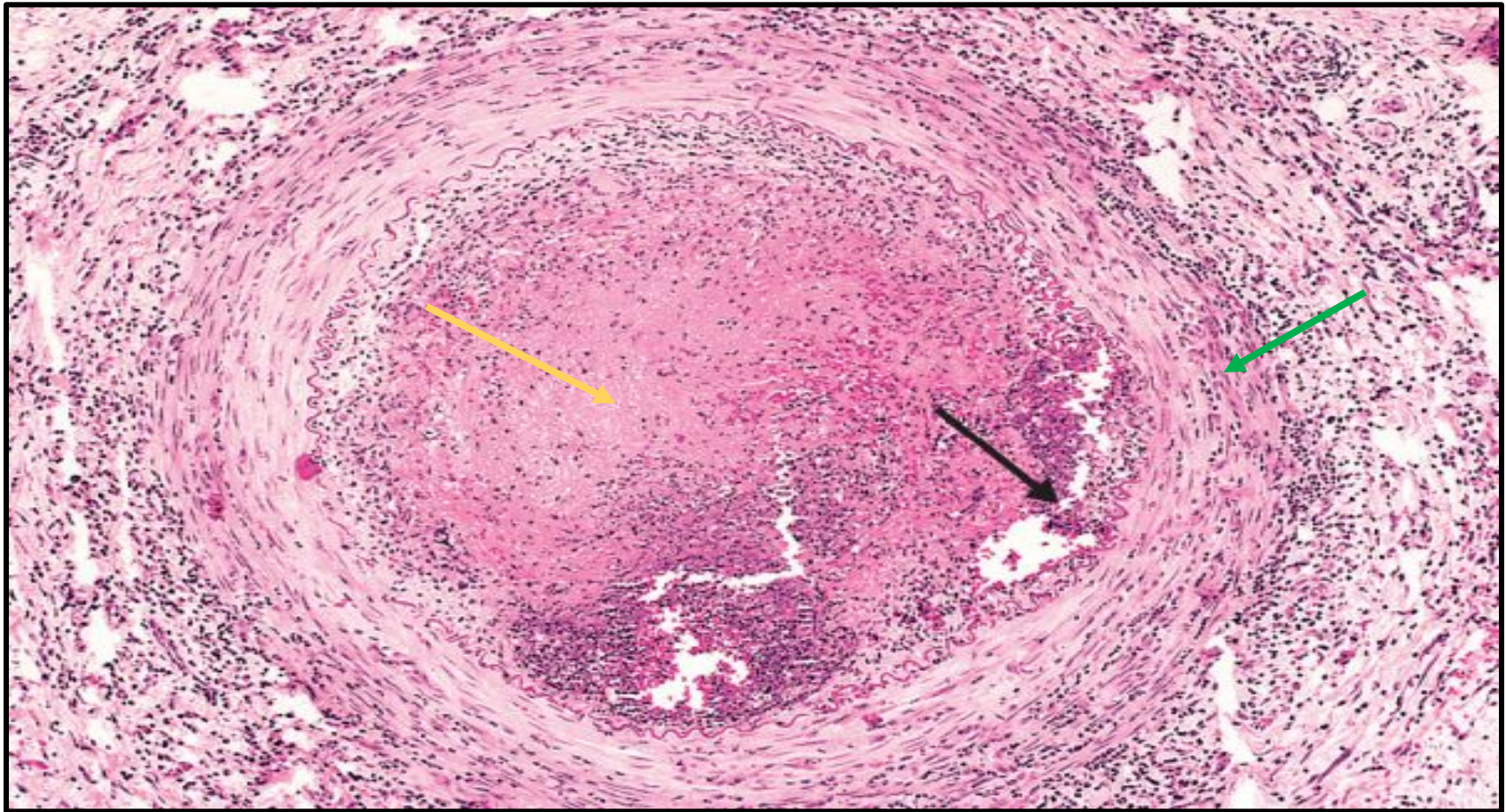
***Thromboangitis obliterans  
(Buerger's disease)***

# *Thromboangitis obliterans (Buerger's disease)*



***Thromboangiitis obliterans TAO (Buerger's disease) is a non atherosclerotic, segmental, inflammatory, vaso-occlusive (thrombotic) disease that affects the small- and medium-sized arteries and veins of the upper and lower extremities.***

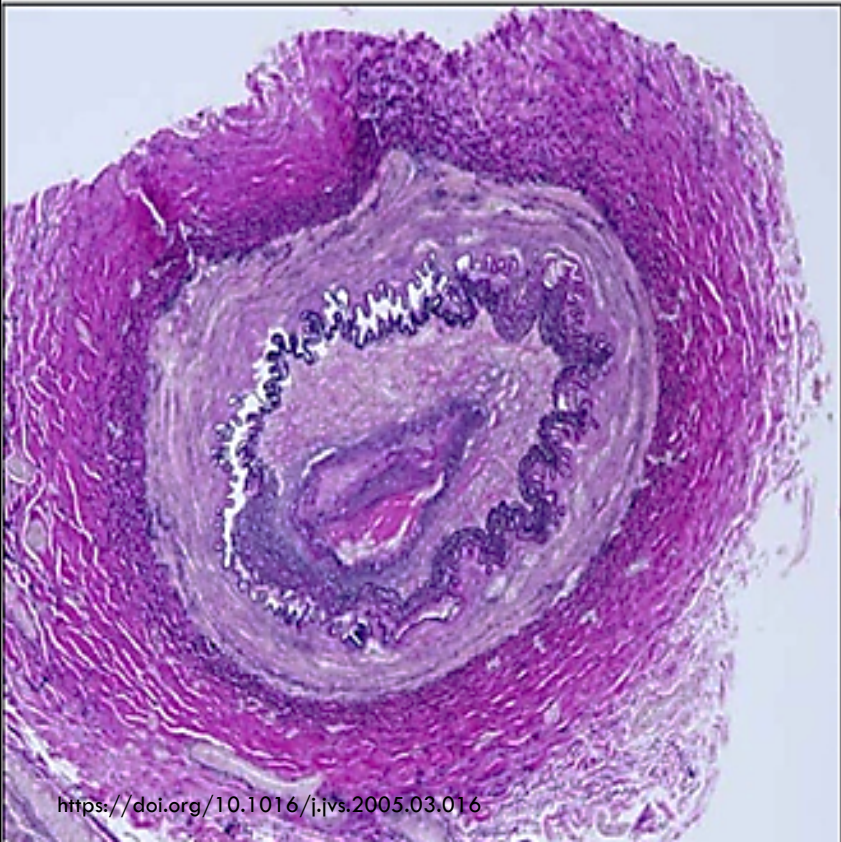## ACTIVE STAGE OF THROMBOANGITIS OBLITERANS (BUERGER'S DISEASE)



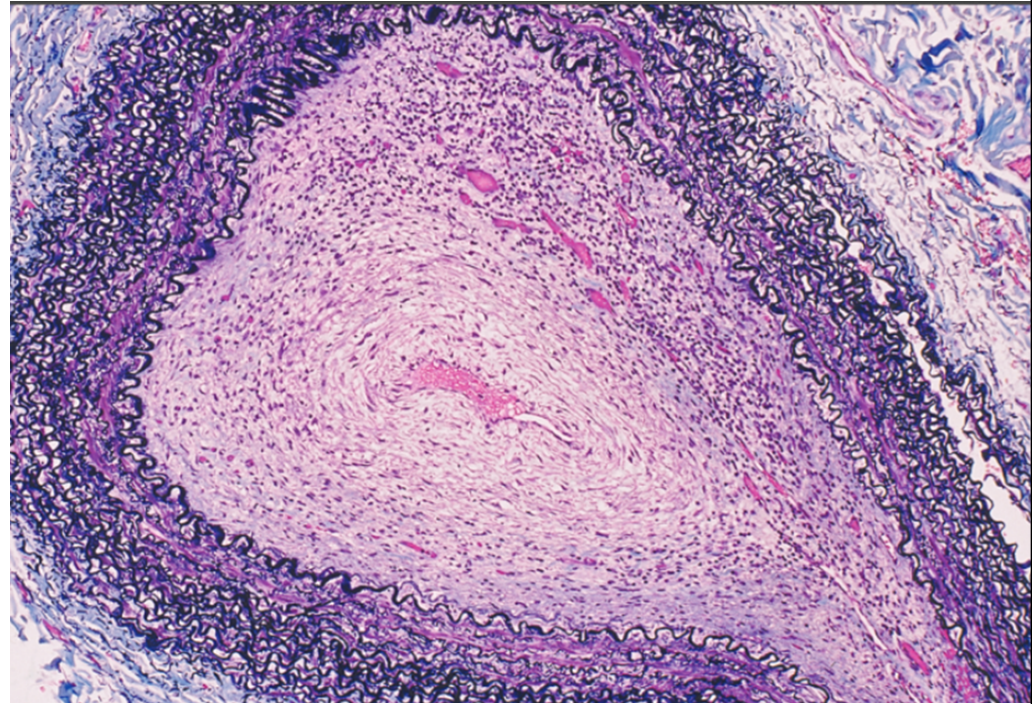
**Thromboangitis obliterans TAO (Buerger disease). The lumen is occluded by a **thrombus** containing Neutrophils with abscess formation, and the **vessel wall is infiltrated with neutrophils.****



# CHRONIC STAGE THROMBOANGITIS OBLITERANS (BUERGER'S DISEASE)

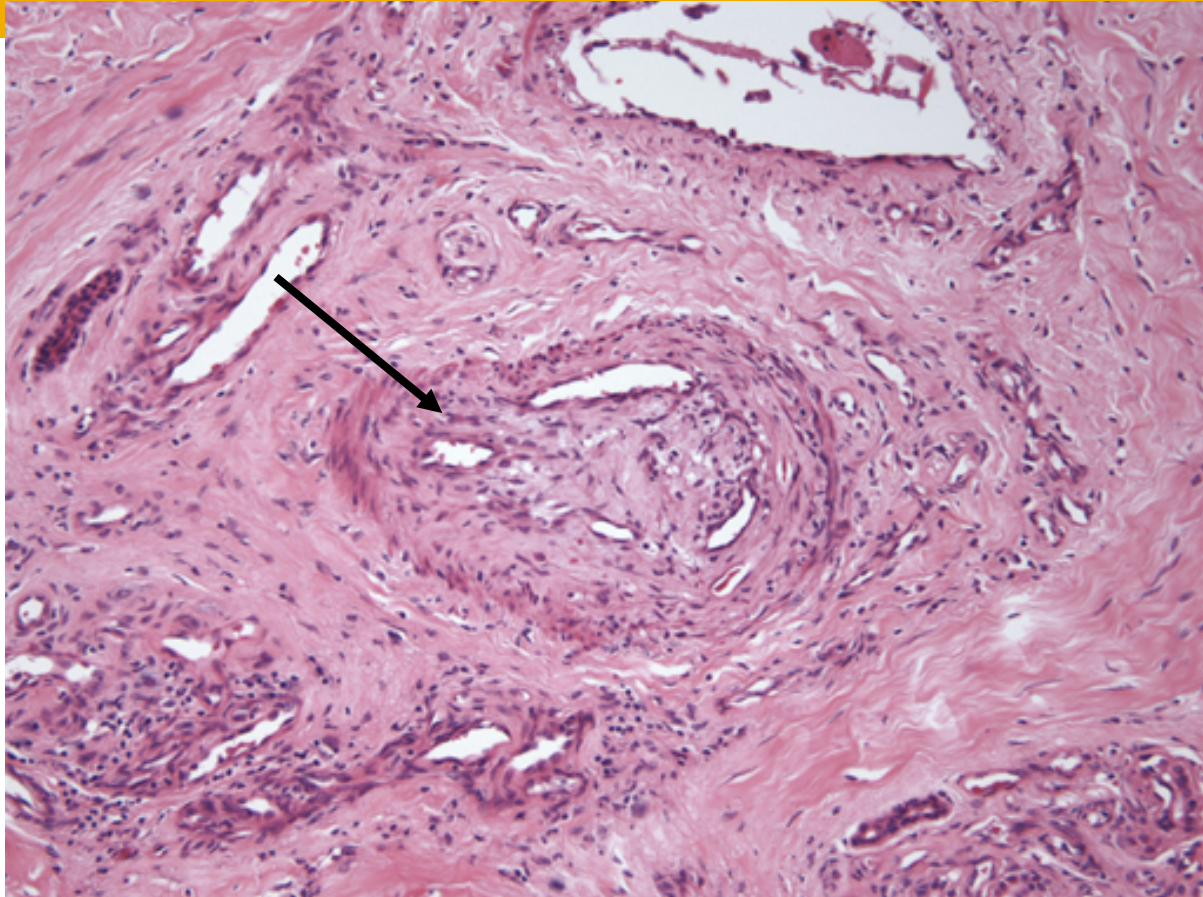


<https://doi.org/10.1016/j.jvs.2005.03.016>



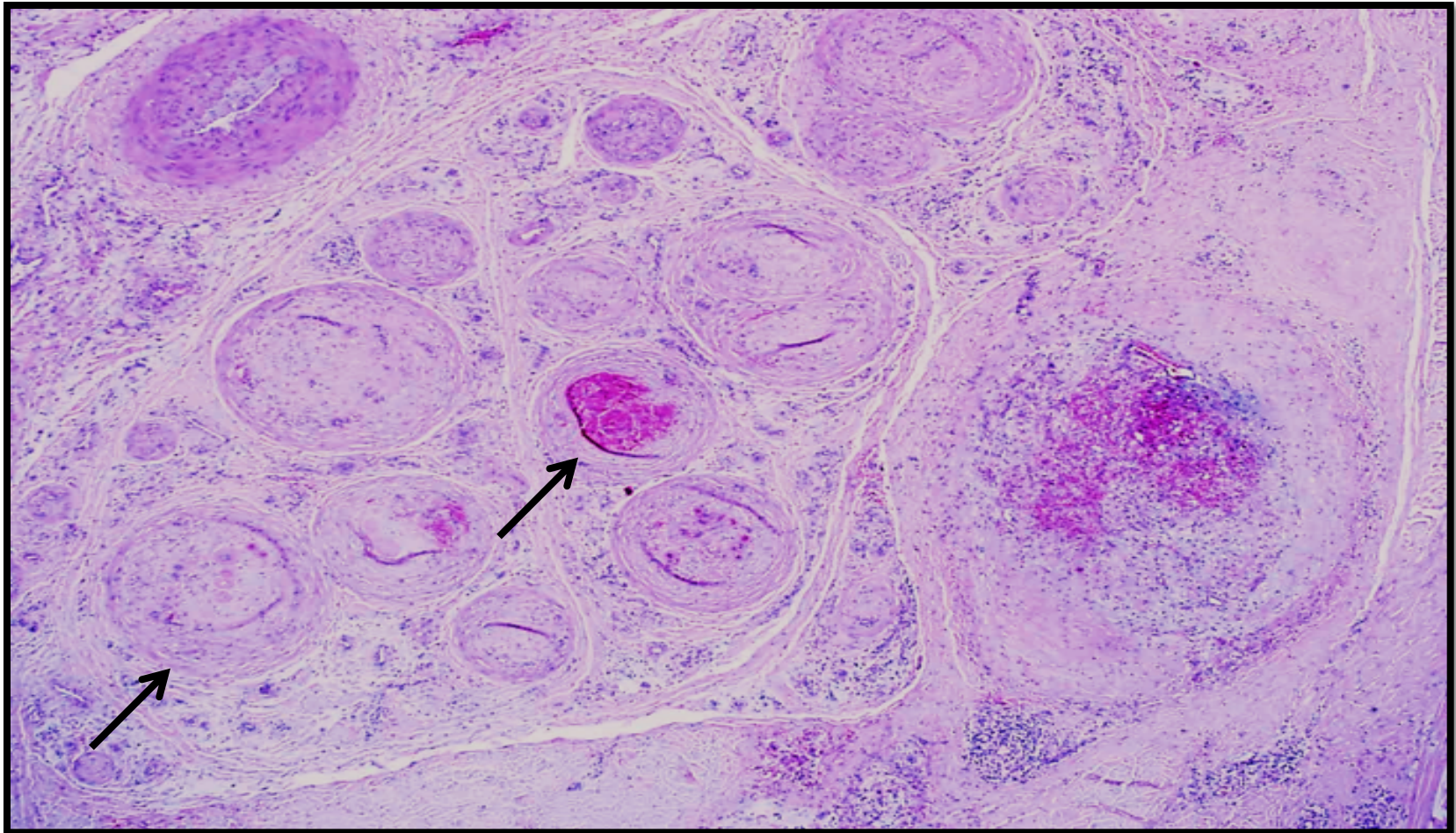
***Thromboangiitis obliterans TAO (Buerger's disease) is a non atherosclerotic, segmental, inflammatory, vaso-occlusive disease that affects the small- and medium-sized arteries and veins of the upper and lower extremities. Both pictures show cut-section of artery with near total occlusion of the lumen by a fibrotic thrombus. There are inflammatory cells in the fibrotic occlusive thrombus in the picture on the right (PAS stain & trichrome elastic stain).***

# CHRONIC STAGE THROMBOANGITIS OBLITERANS (BUERGER'S DISEASE)



***Blood vessel shows chronic stage of TAO with occlusive organized thrombi (arrow) with recanalization and fibrosis around the blood vessel.***

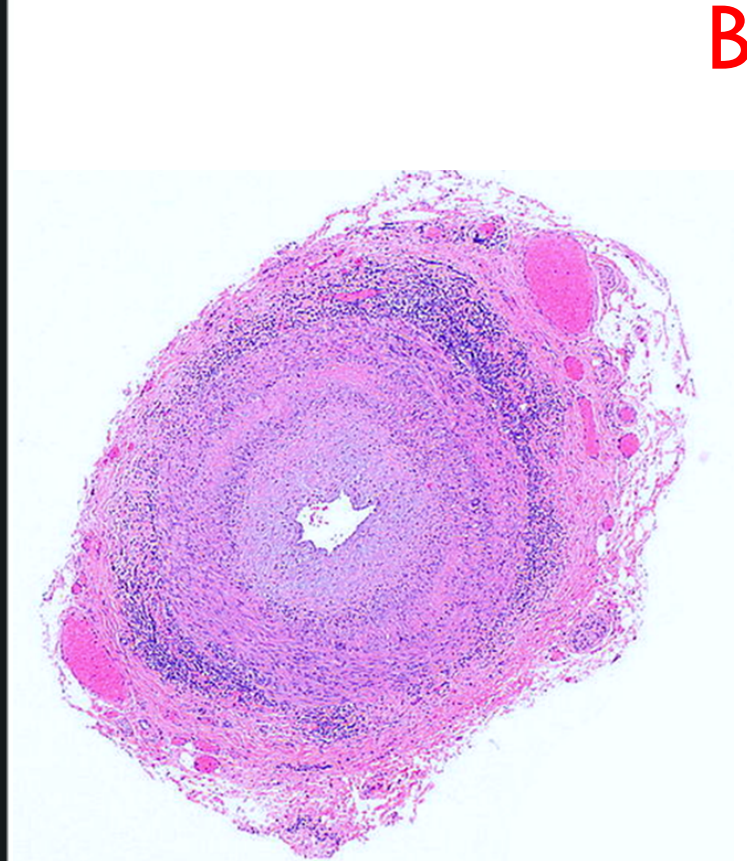
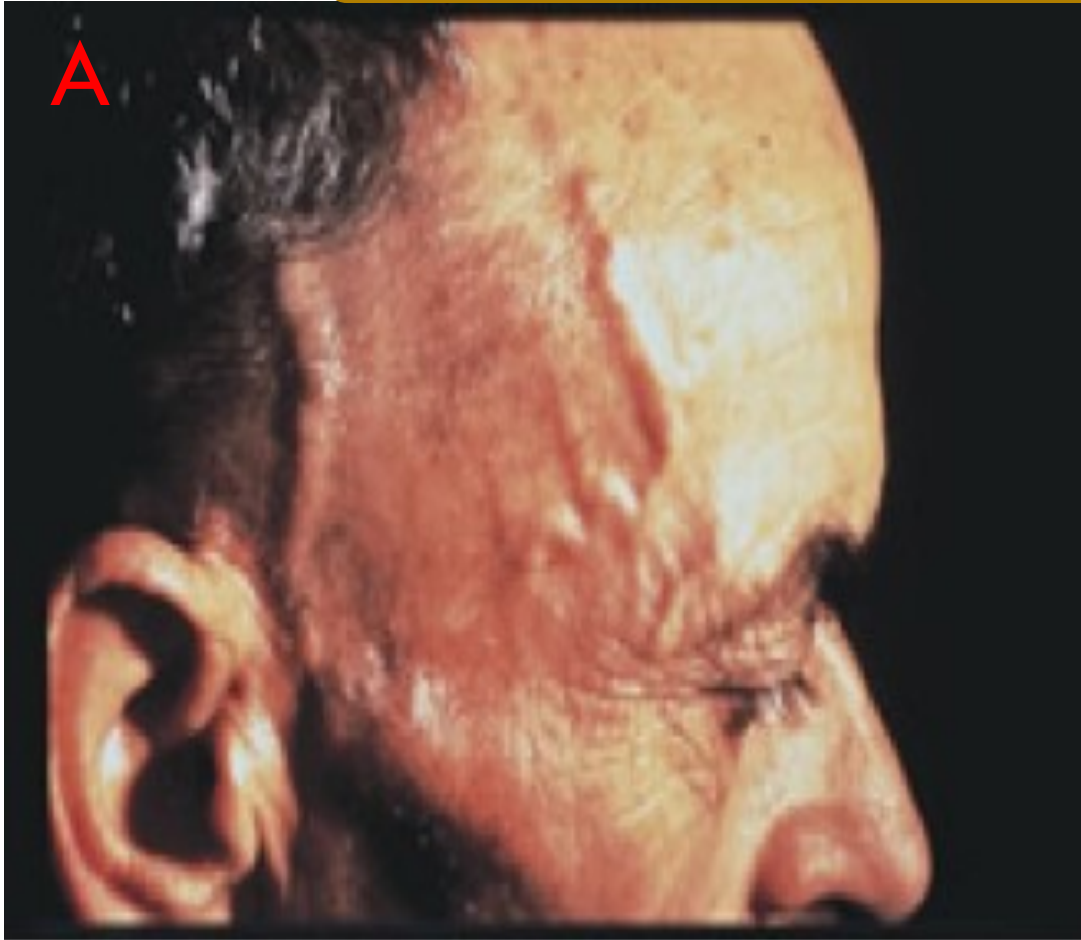## THROMBOANGITIS OBLITERANS (BUERGER'S DISEASE)



**Several blood vessels showing occlusive organized thrombi (arrow). Some vessels show chronic inflammatory cell infiltration in their wall. There is fibrosis in the surrounding tissue.**

# ***GIANT CELL (TEMPORAL) ARTERITIS***

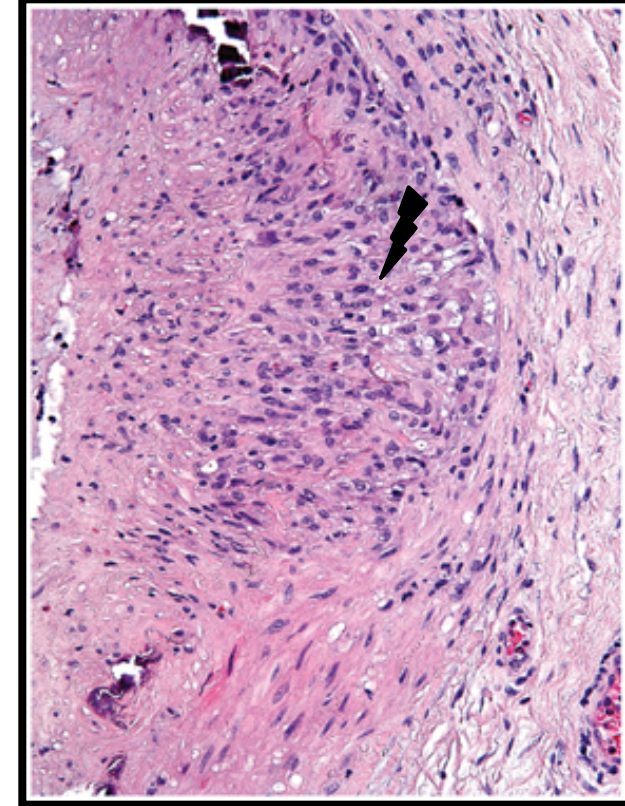
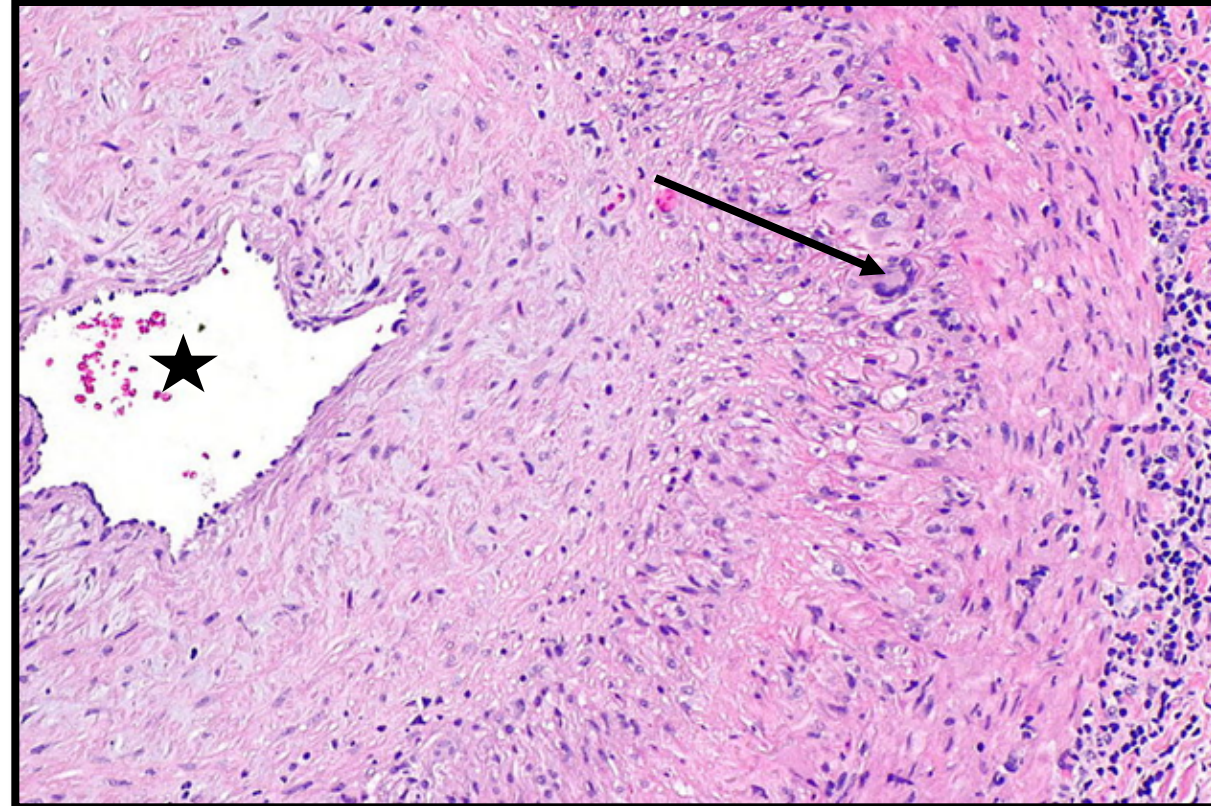
# GIANT CELL / TEMPORAL ARTERITIS



**A. Tender and thickened scalp vessels**

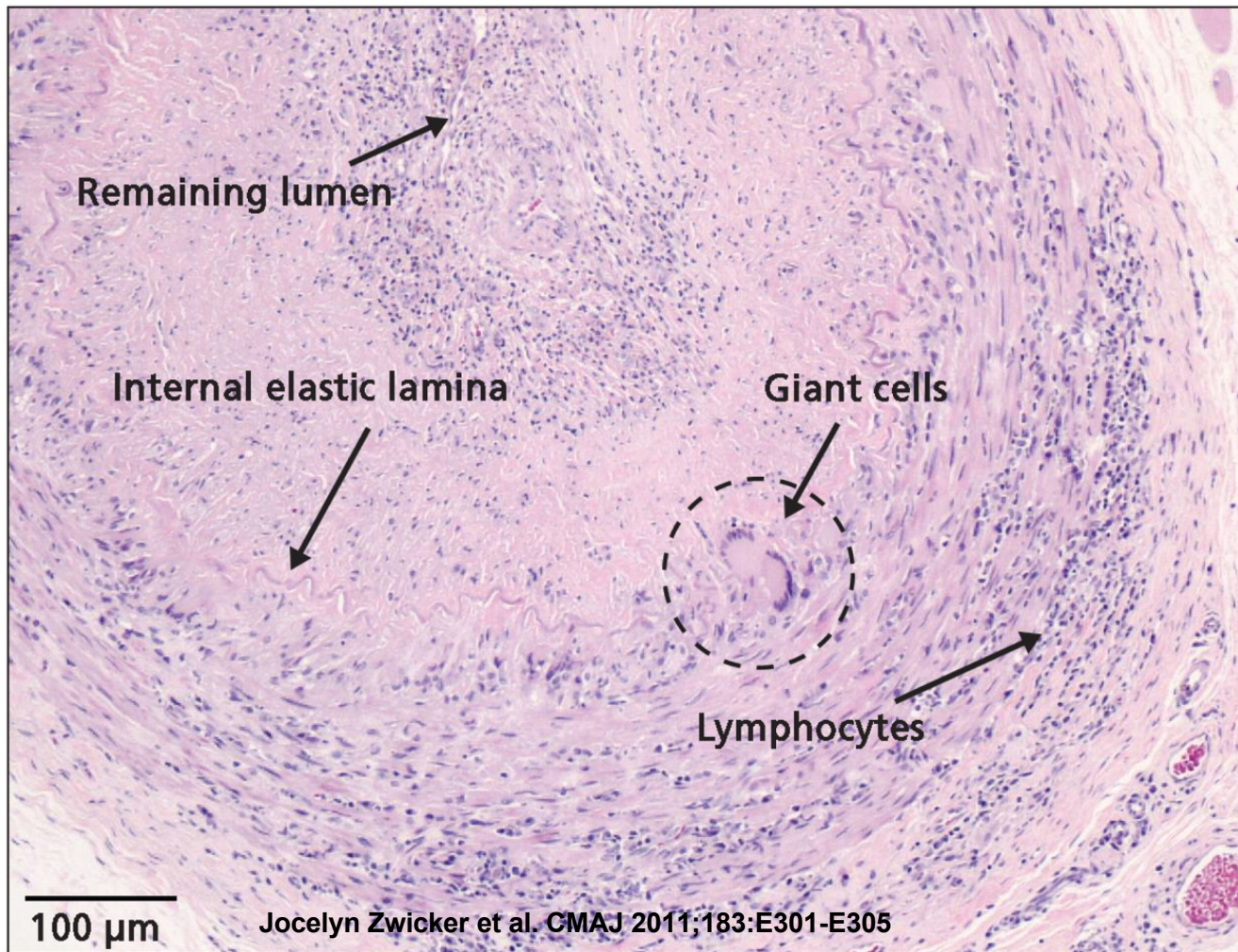
**B. Cut section of temporal artery showing circumferential chronic lymphocytic inflammation/ arteritis**

# GIANT CELL (TEMPORAL) ARTERITIS - HPF



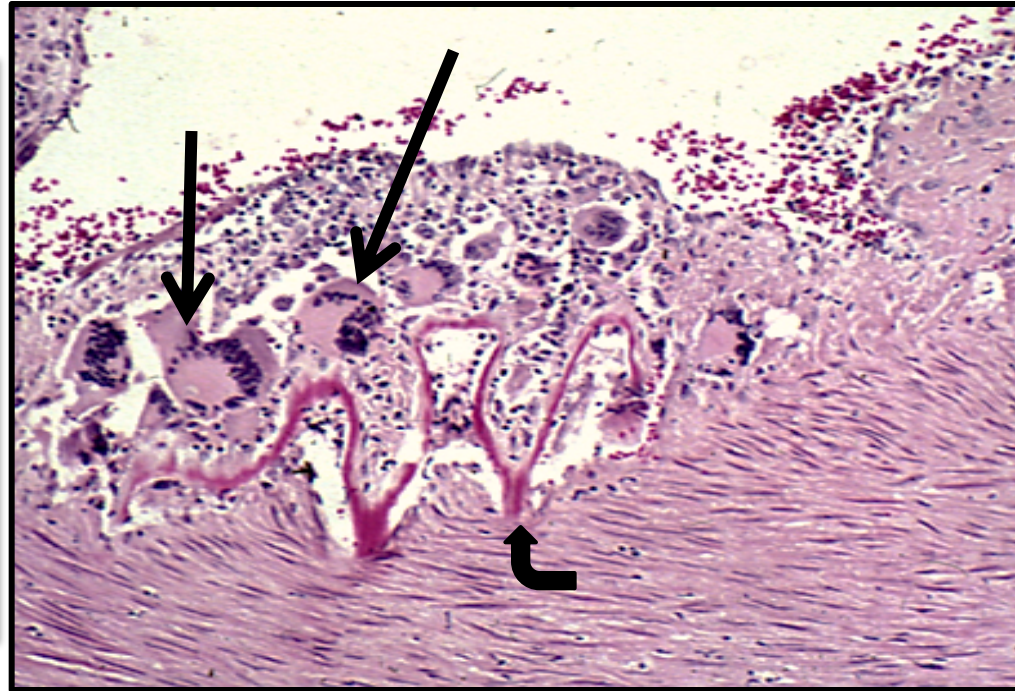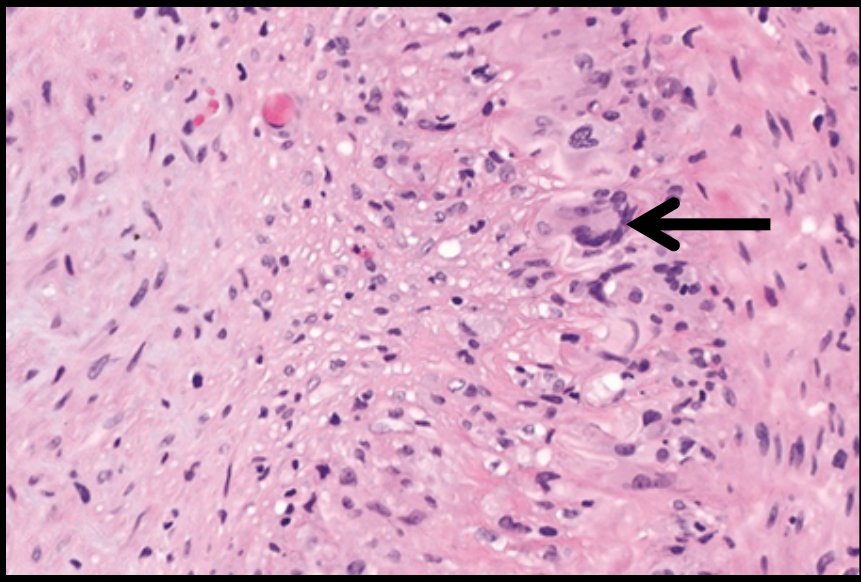
***Temporal artery showing lymphocytic inflammation, granuloma (lightning arrow) and multinucleated giant cells (arrow). The lumen (star) of the artery shows narrowing because reactive intimal fibrosis.***

# GIANT CELL (TEMPORAL) ARTERITIS



***Inflammation of temporal artery showing multinucleated giant cells, fragmentation of the internal elastic lamina and chronic lymphocytic infiltrate consistent with giant cell arteritis. The lumen of the artery is narrowed by intimal fibrosis.***

# GIANT CELL (TEMPORAL) ARTERITIS - HPF



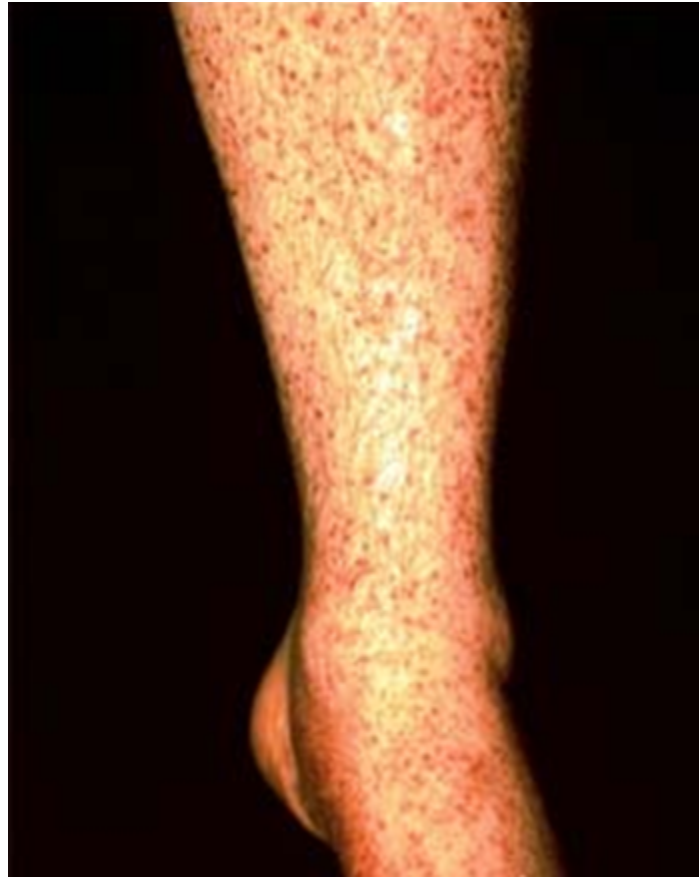**Disruptions of the elastic lamina with inflammation and giant cells.**

*Segmental inflammatory lesions with intimal thickening , medial granulomatous inflammation with giant cells (arrows) and chronic inflammatory cells and there is fragmentation of the(pink) internal elastic lamina (curved arrow)*



***LEUKOCYTOCLASTIC /  
HYPERSENSITIVITY  
VASCULITIS  
( MICROSCOPIC POLYANGITIS )***

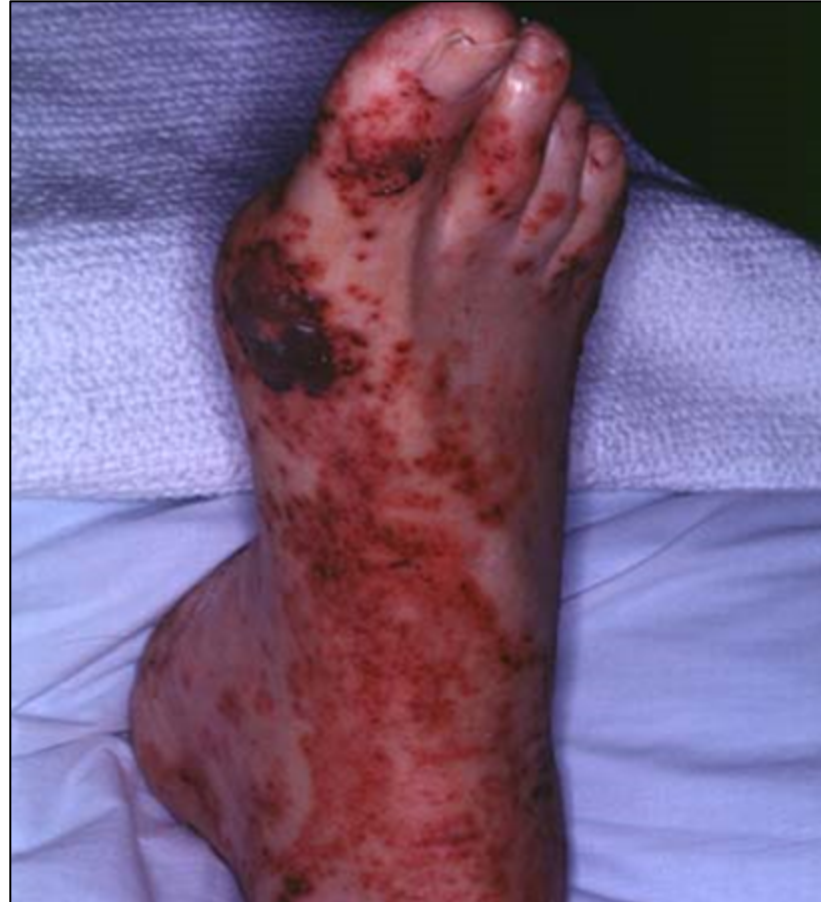## *Hypersensitivity vasculitis – Clinical sign*



***Hypersensitivity vasculitis might be complicated with glomerulonephritis and hemoptysis due to pulmonary capillaritis***

# *Leukocytoclastic vasculitis - Clinical sign*

Can be a feature of a number of immune disorders, such as *Henoch-Schönlein purpura*.

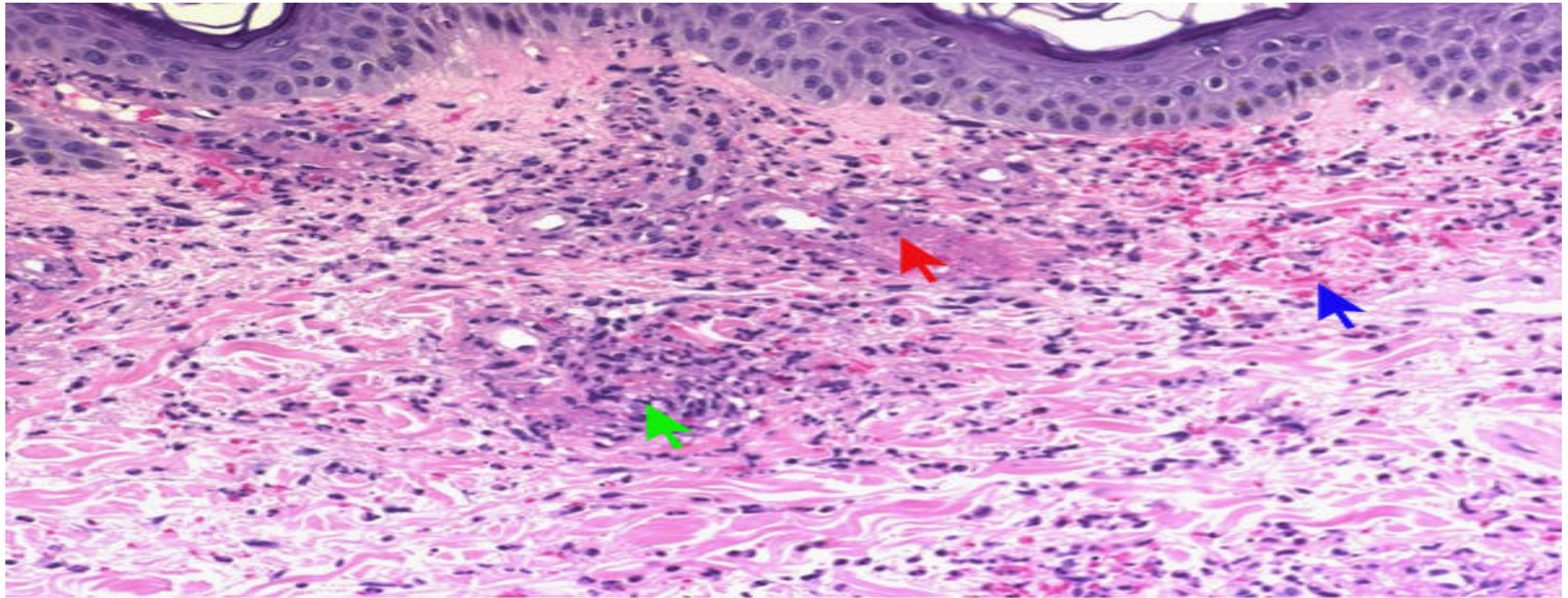





Erythematous and purpuric rash with areas of haemorrhage

## *Leukocytoclastic vasculitis*

*The purpuric eruption (Subcutaneous bleeding patches) of the foot tends to be most pronounced on dependent areas.*

# *Leukocytoclastic vasculitis - HPF*

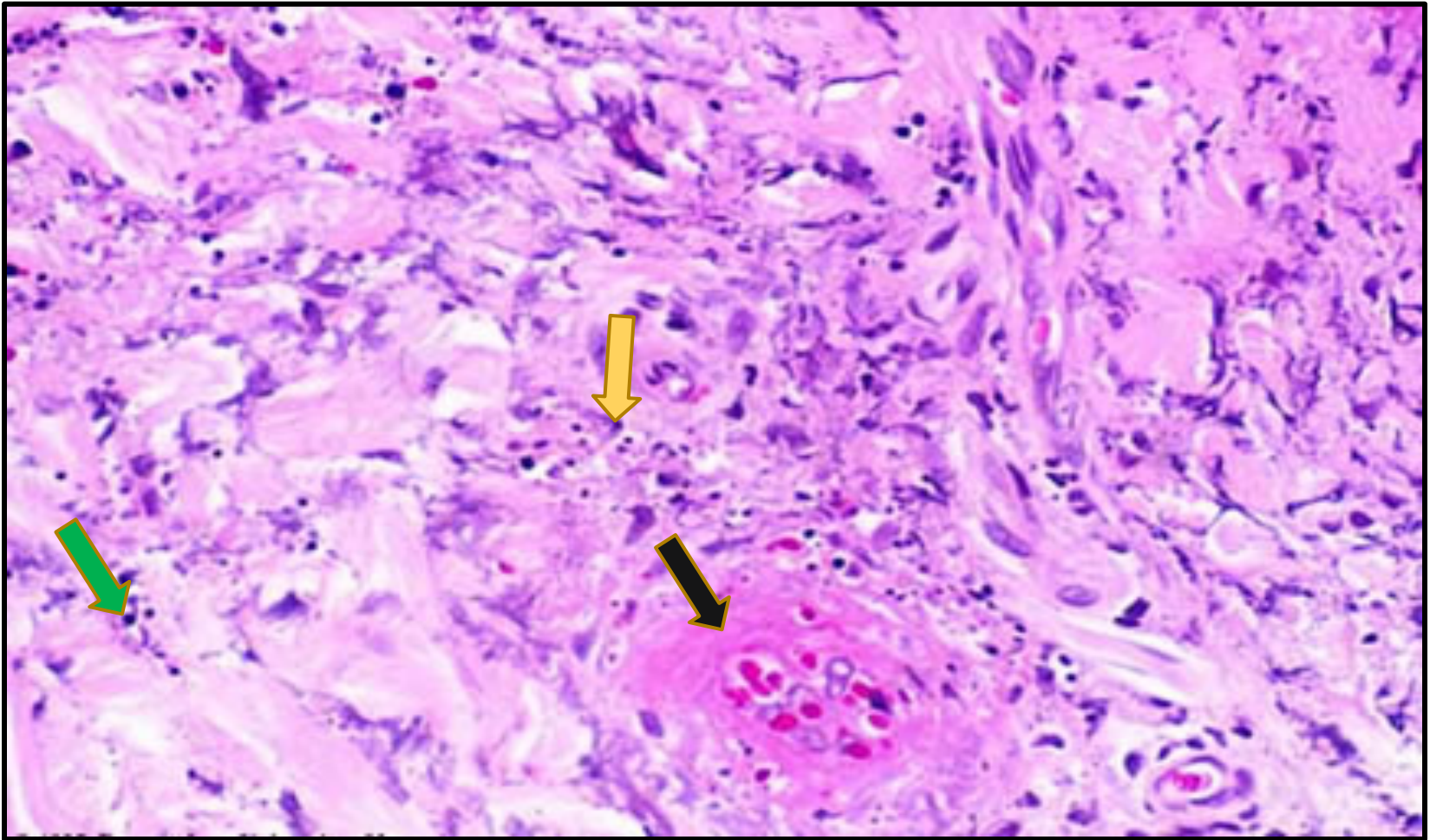


-  **Fibrinoid type necrosis**
-  **Red cell extravasation**
-  **Inflammation**

## **Vasculitis, leukocytoclasia ( high power)**

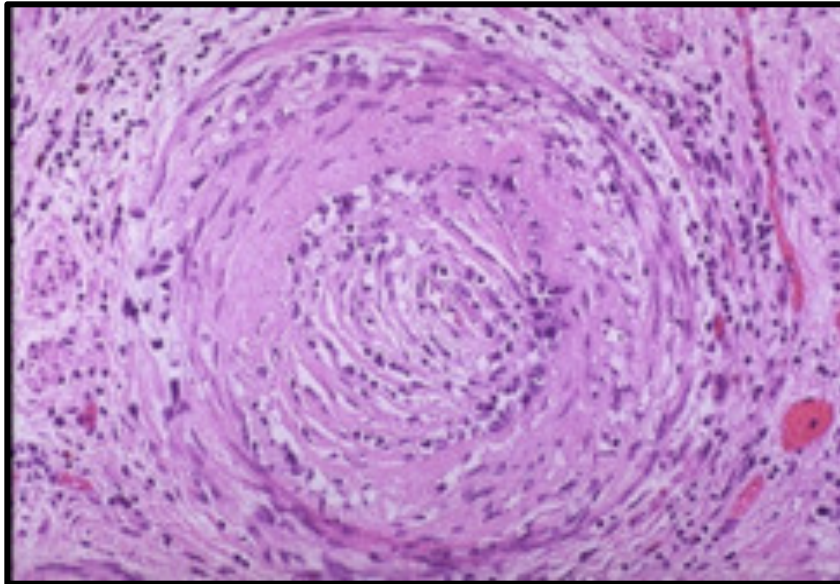
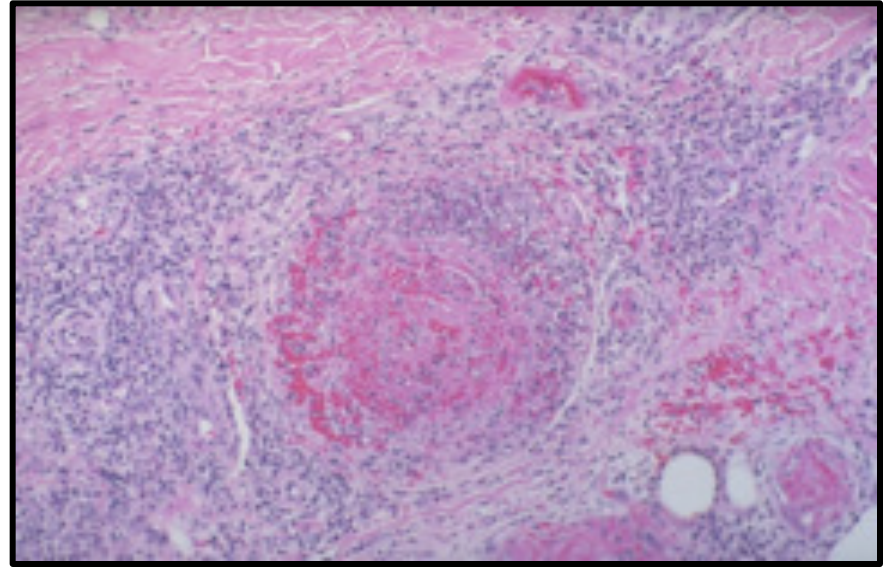
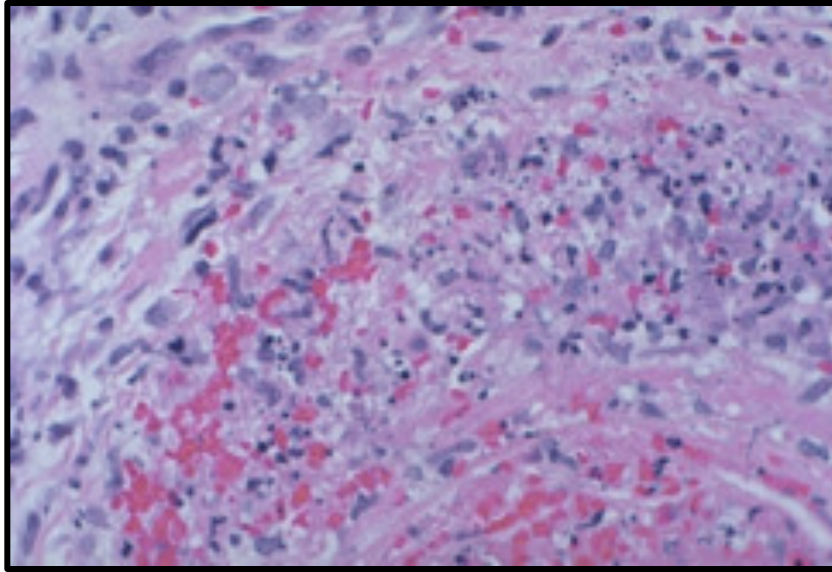
**Section of the skin shows fibrinoid necrosis of blood vessels with extravasation of RBCs , neutrophilic infiltration with debris (leukocytoclasia /nuclear dust)**

## *Leukocytoclastic vasculitis - HPF*



***Fibrinoid necrosis of the blood vessels, Apoptotic bodies and Neutrophils.***

## *Severe vasculitis – Microscopic views*



**This muscular artery shows a more **severe vasculitis** with acute and chronic inflammatory cell infiltrates, along with necrosis of the vascular wall**

A photograph of a wave tunnel, showing the water curving around to form a natural archway. The water is a deep blue color, and the sky is visible through the opening. The text "THE END" is overlaid in the center of the image.

**THE END**