

NEOPLASIA – PRACTICAL SESSION 1

Dr. Maria A. Arafah

Associate Professor – Department of Pathology

<http://fac.ksu.edu.sa/mariaarafah/courses>

Contents

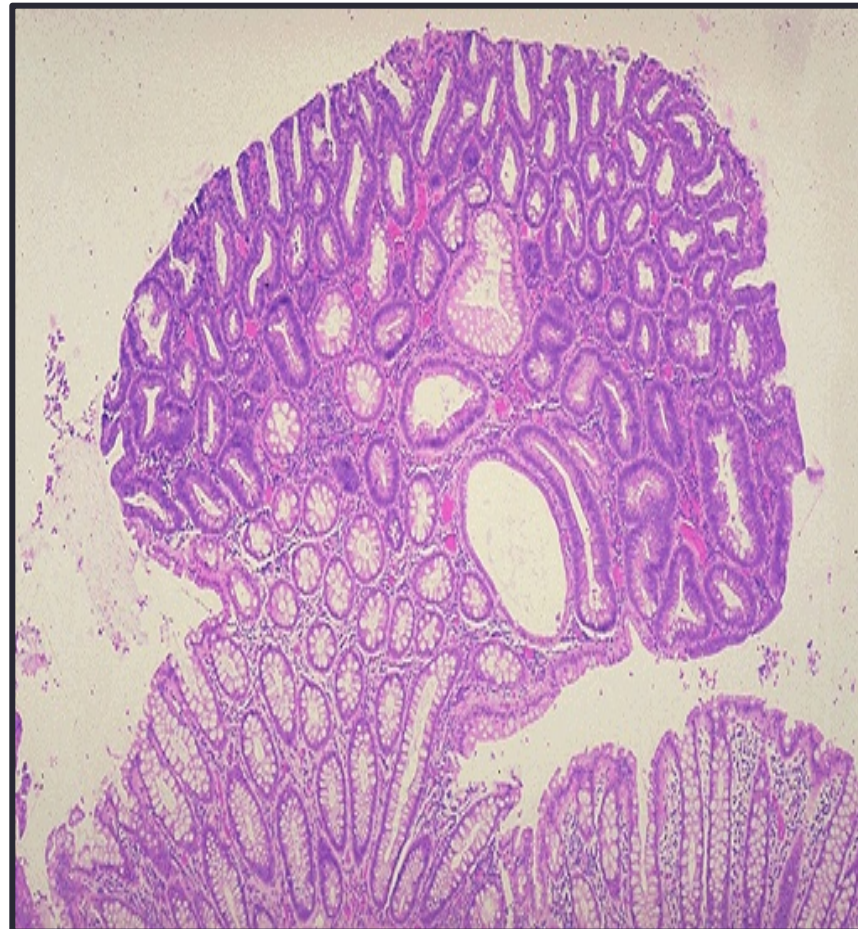
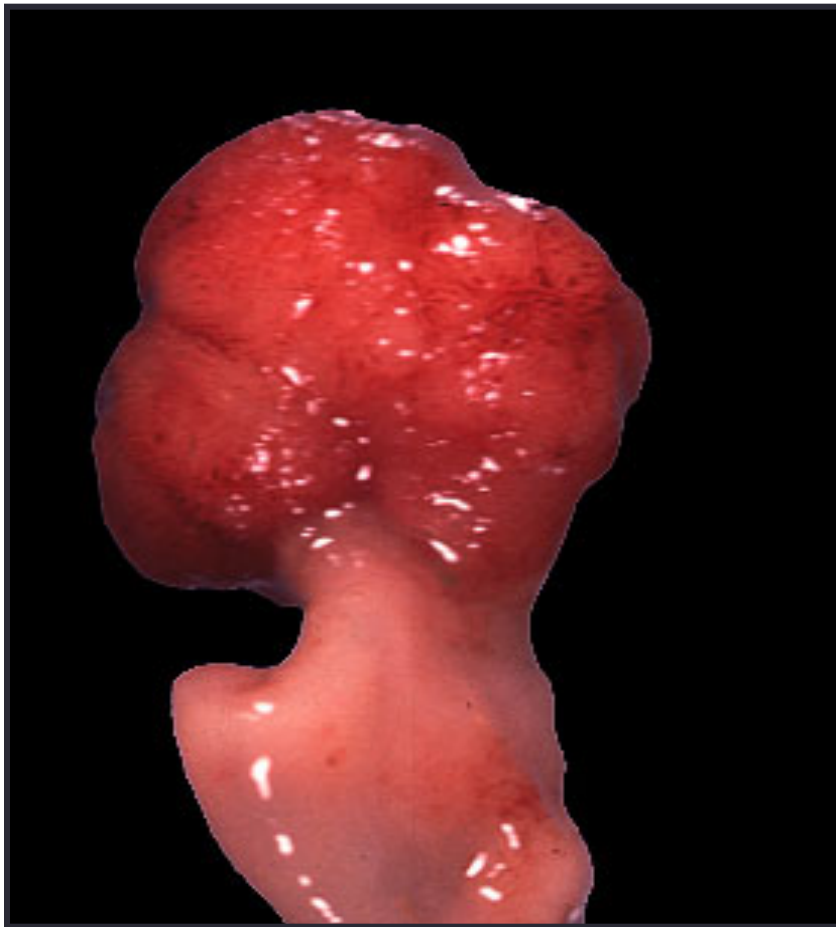- Adenomatous polyp of rectum/colon.
- Lipoma.
- Intradermal nevus.
- Multiple uterine leiomyomata.
- Chondroma.
- Hemangioma.
- Teratoma (Dermoid cyst of the ovary).

CASE 1

Adenomatous polyp of colon/rectum

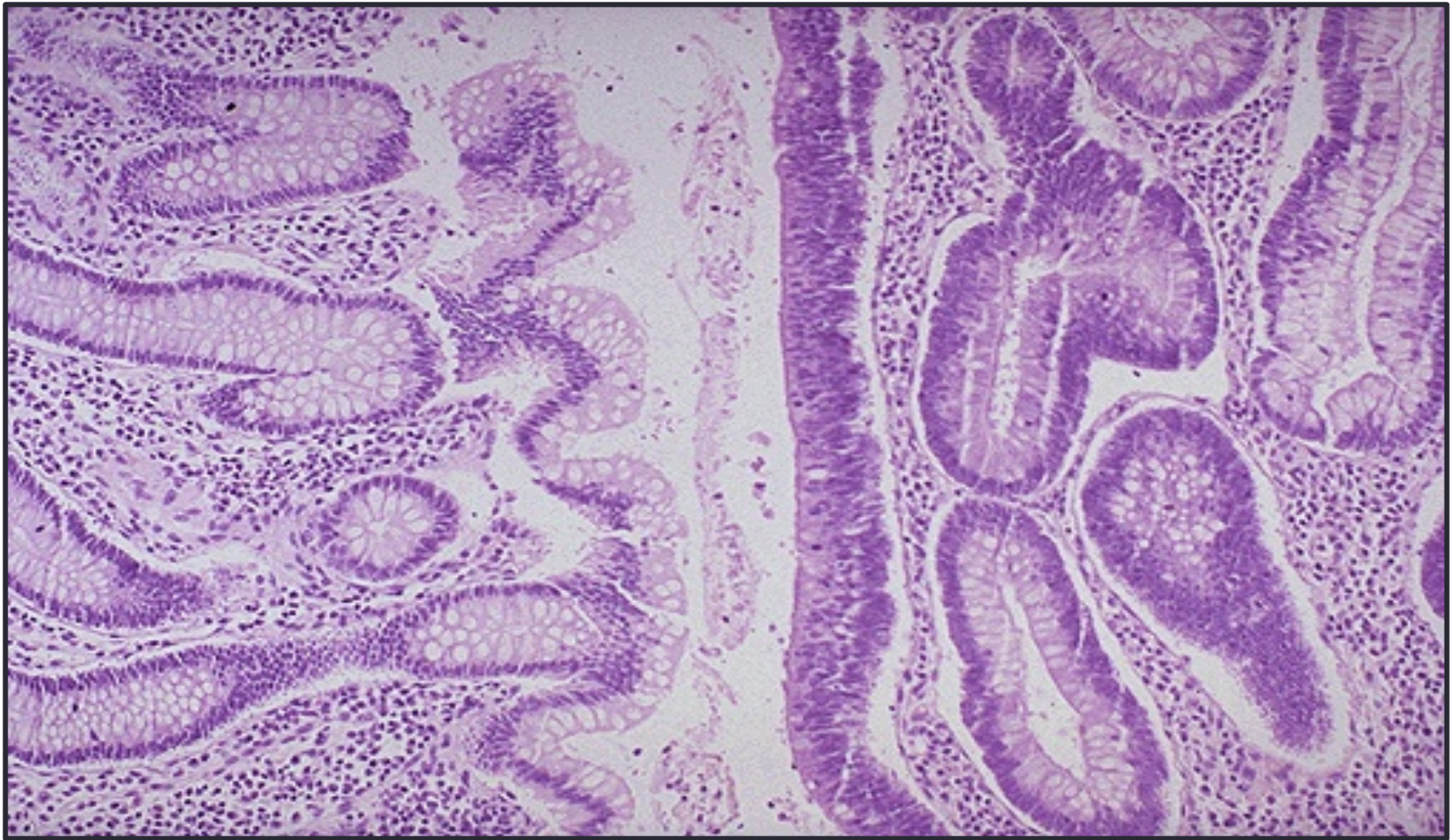


This adenomatous polyp has a hemorrhagic surface (which is why they may first be detected with a stool occult blood screening) and a long narrow stalk. The size of this polyp (above 2 cm) makes the possibility of malignancy more likely, but this polyp was proved to be benign



This small adenomatous polyp (tubular adenoma) on a small stalk is seen microscopically to have more crowded, disorganized glands than the normal underlying colonic mucosa. Goblet cells are less numerous and the cells lining the glands of the polyp have hyperchromatic nuclei

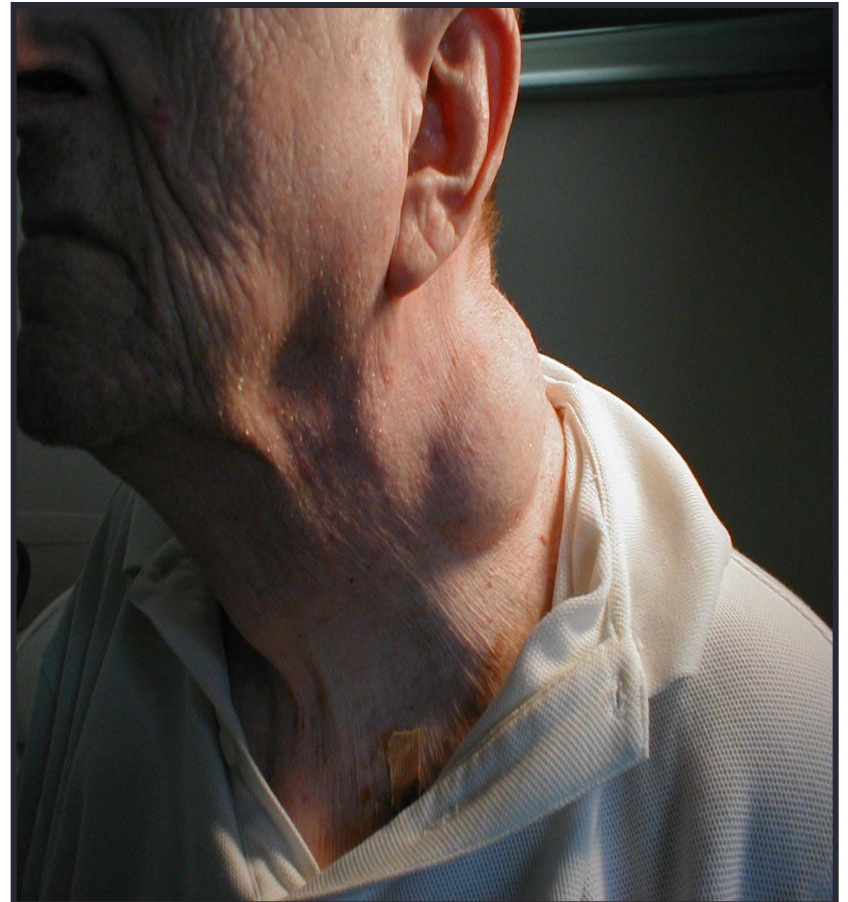
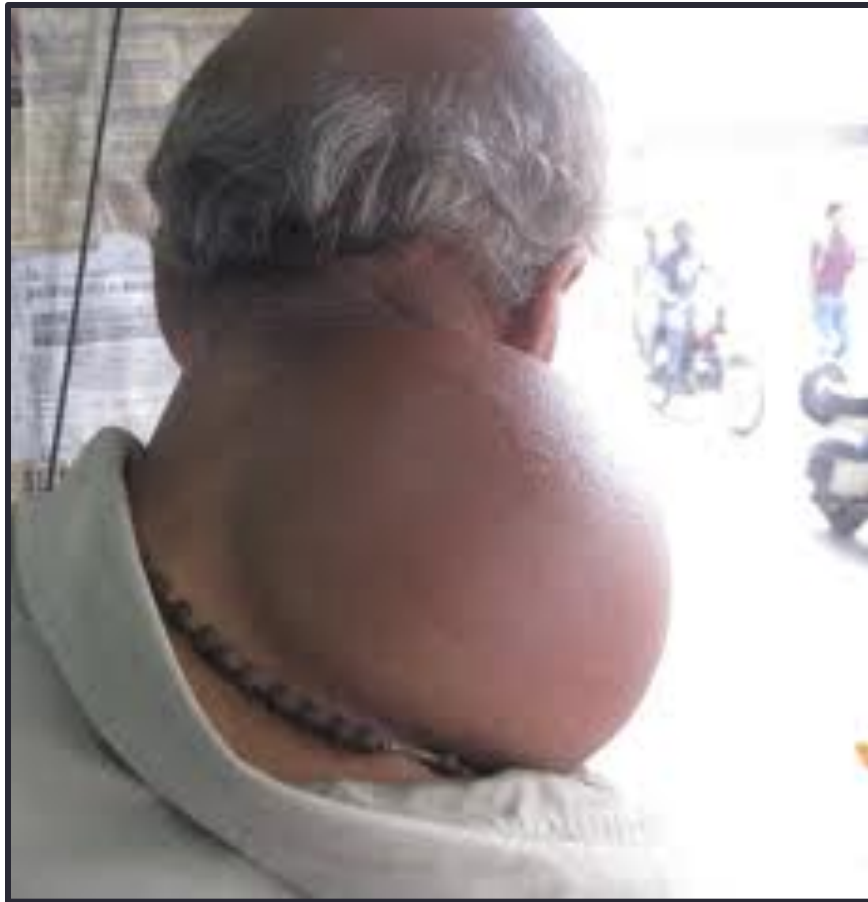Right



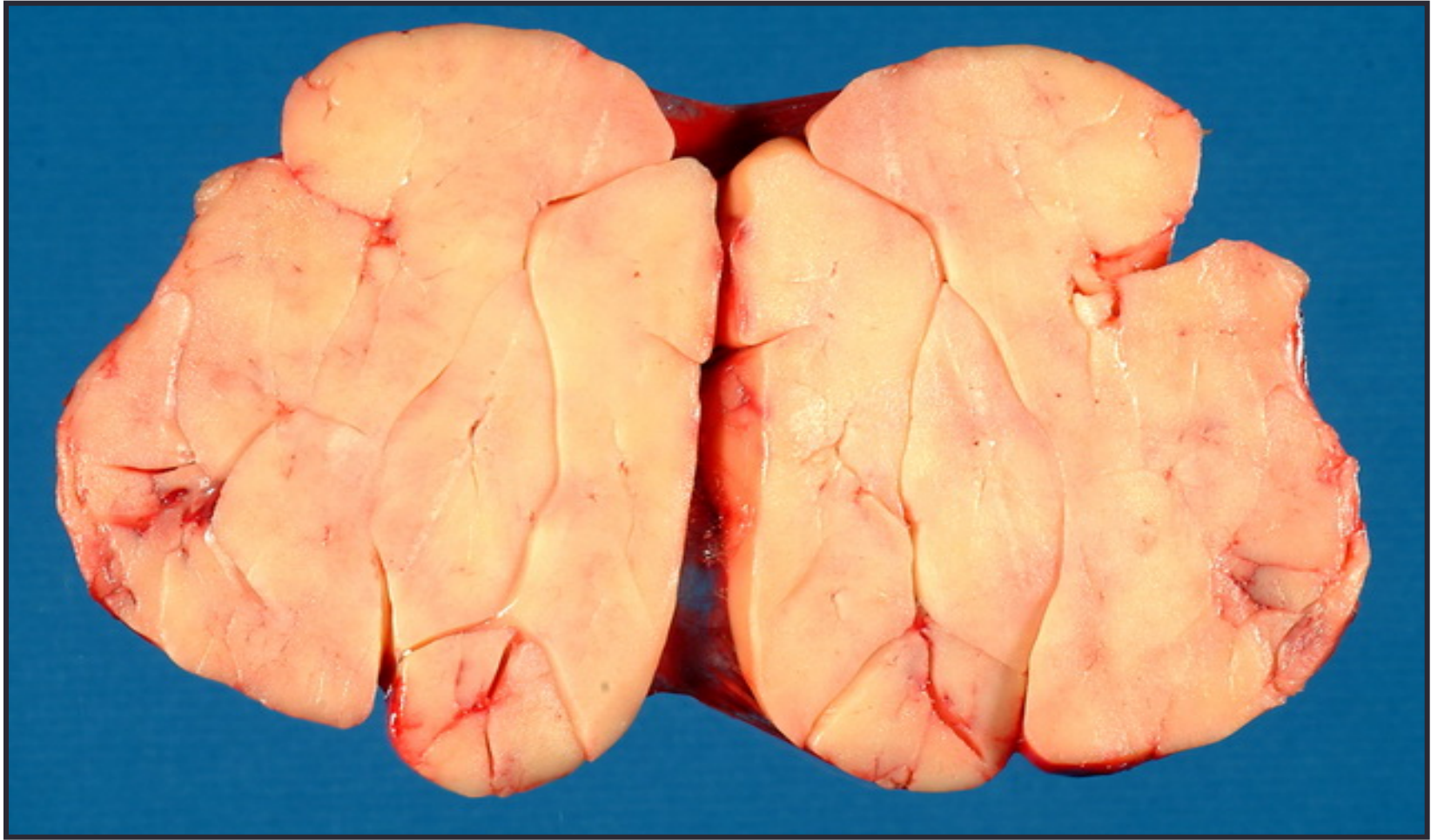
A microscopic comparison of normal colonic mucosa on the right and that of an adenomatous polyp (tubular adenoma) on the left is seen here. The neoplastic glands are more irregular with darker (hyperchromatic) and more crowded nuclei

CASE 2

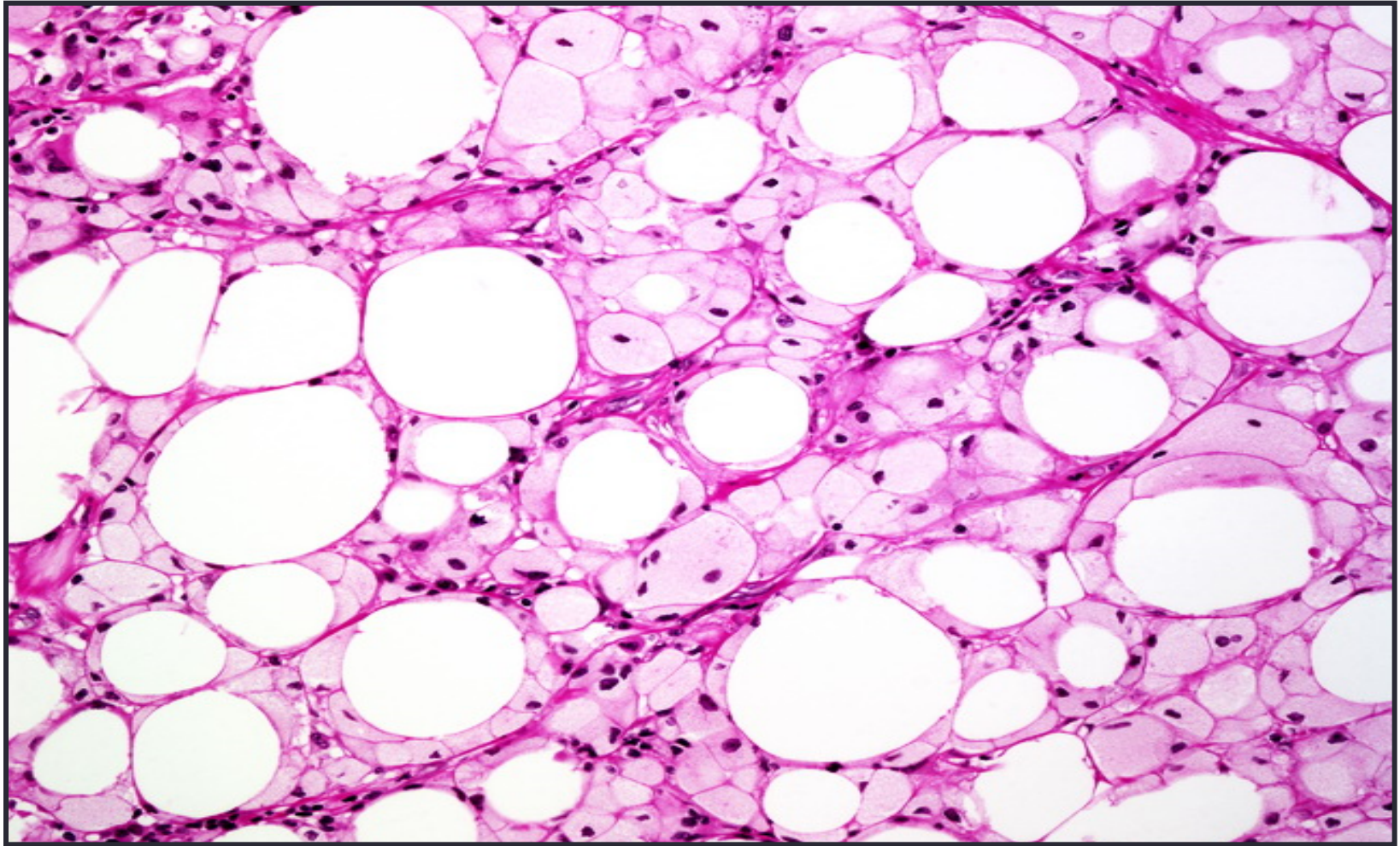
Lipoma



Lipoma: Benign, slow growing, subcutaneous skin growth. In this case, the lipoma is rather large and located in the neck region. On palpation, these are soft, non tender, and mobile if it is small size.



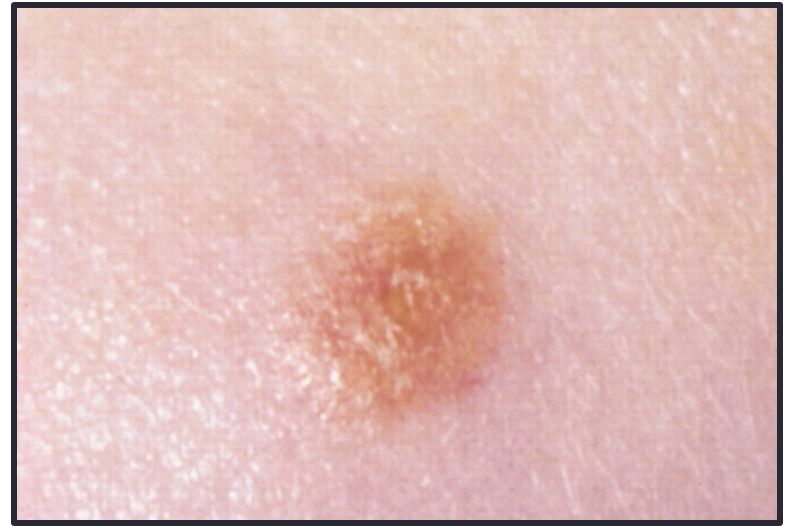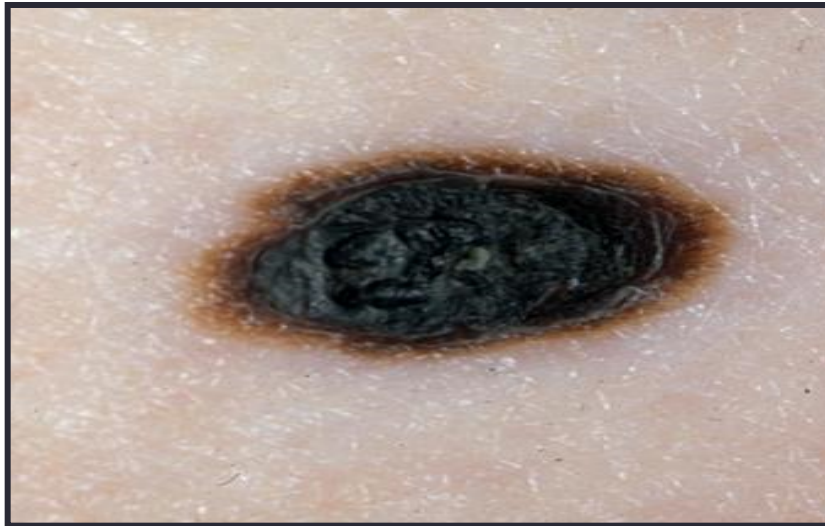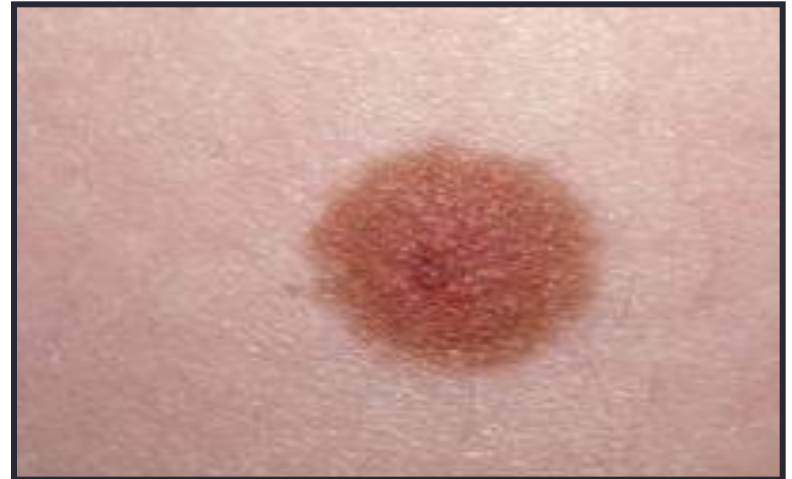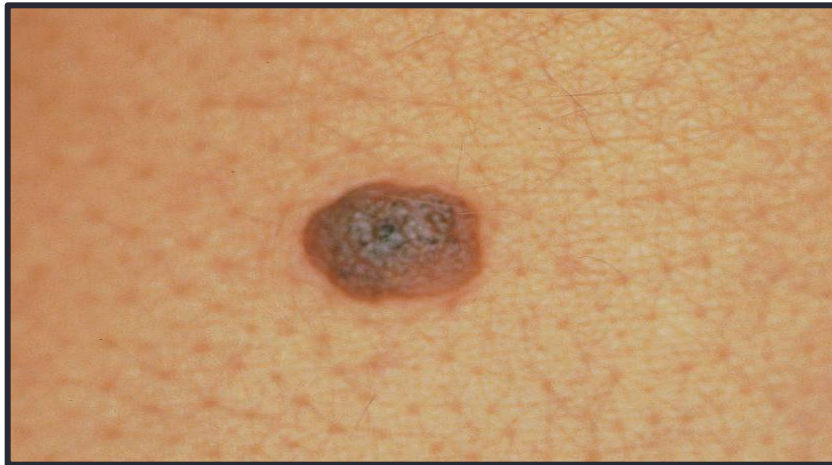Lipoma cut section: It is a benign tumor composed of mature adipose tissue. Most of them are superficially located in the upper part of the body, although they can arise anywhere. Grossly, they appear bright yellow and lobulated.



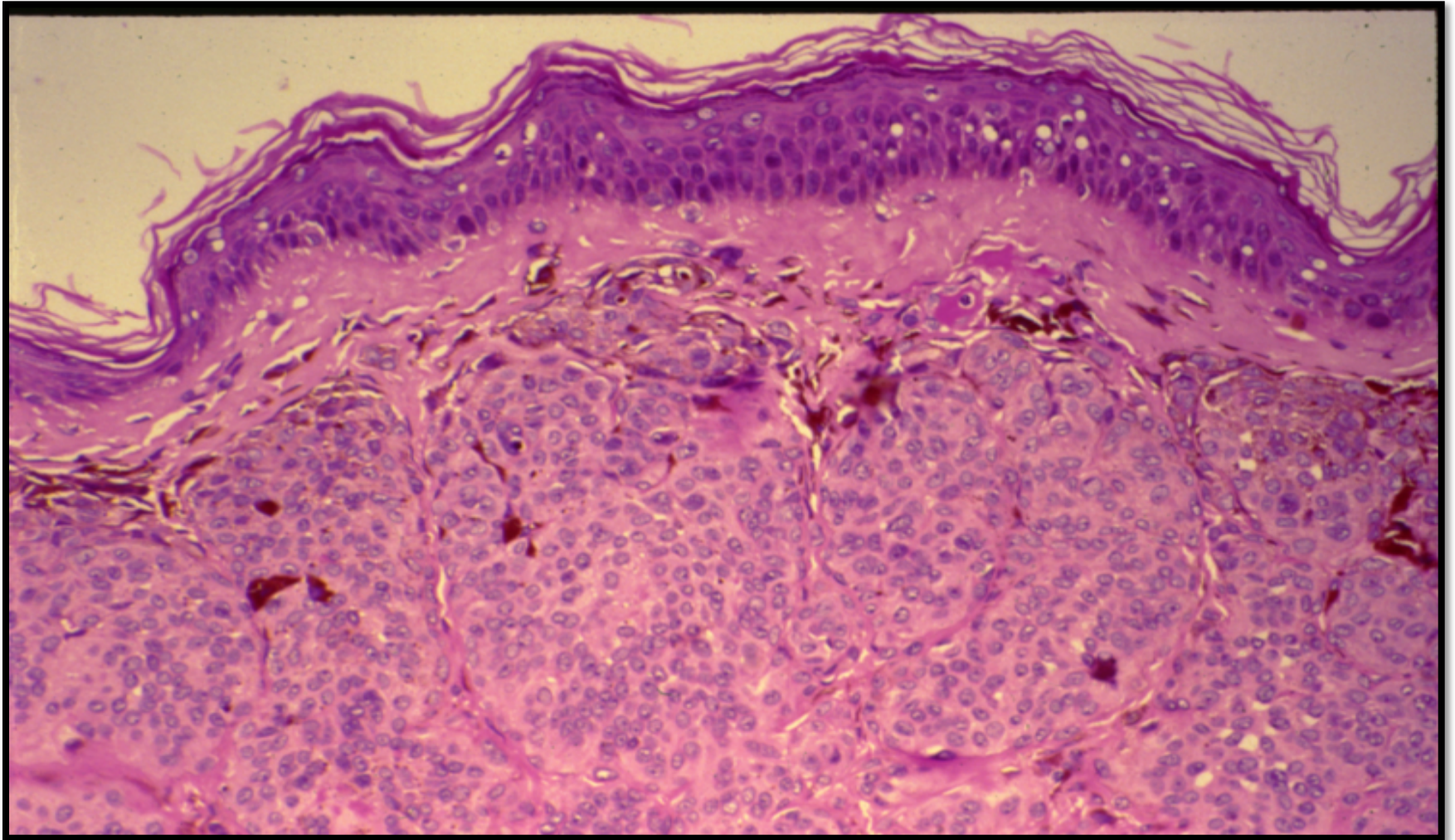
Lipoma with fat necrosis: This picture shows an area of fat necrosis within a lipoma. The masses are comprised primarily of mature adipocytes. Histiocytes present within these areas should not be mistaken for lipoblasts.

CASE 3

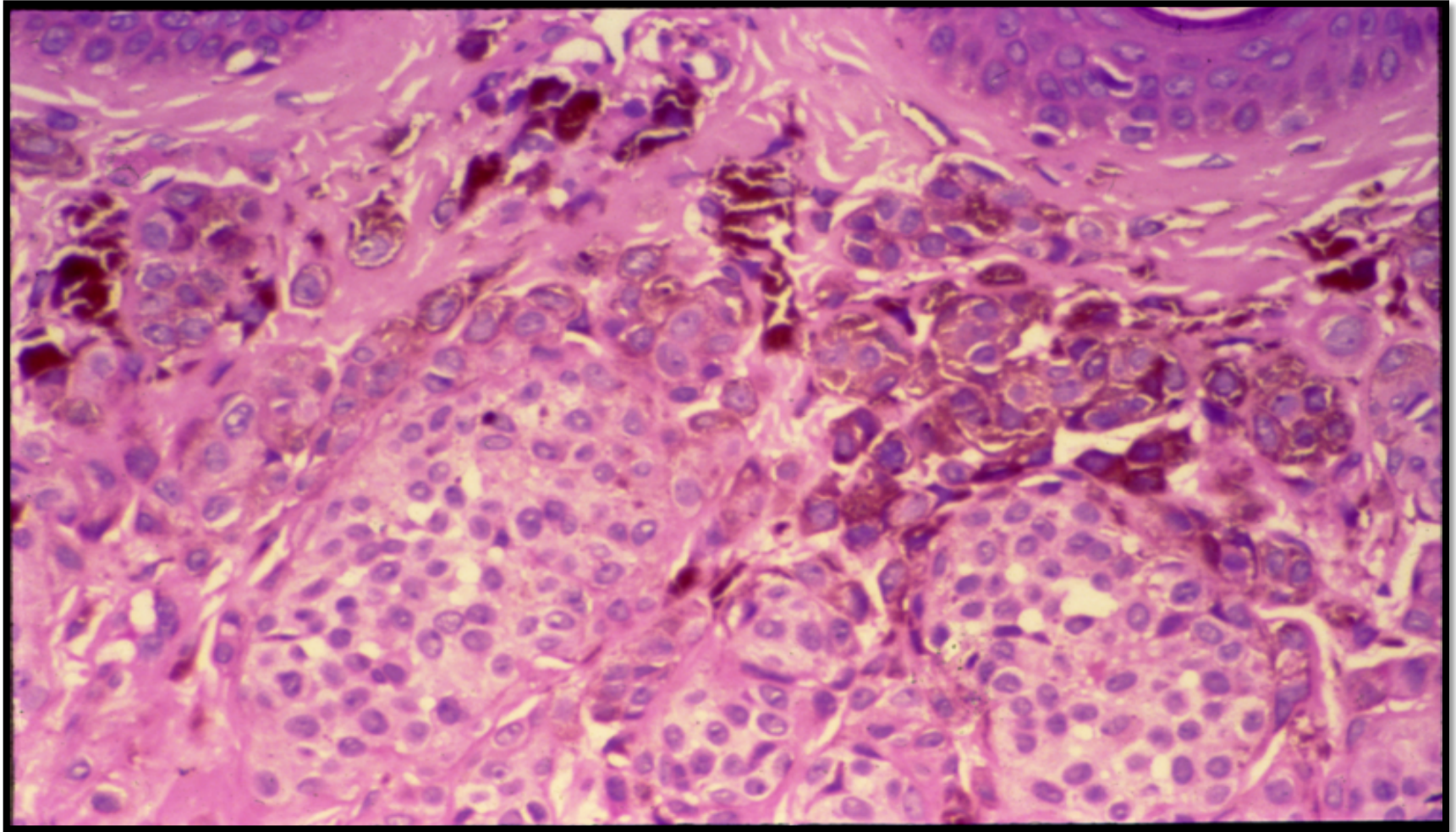
Intradermal nevus



A intradermal nevus: The lesion is small, symmetrical, and has uniform different colors (pink – tan – brown, etc)



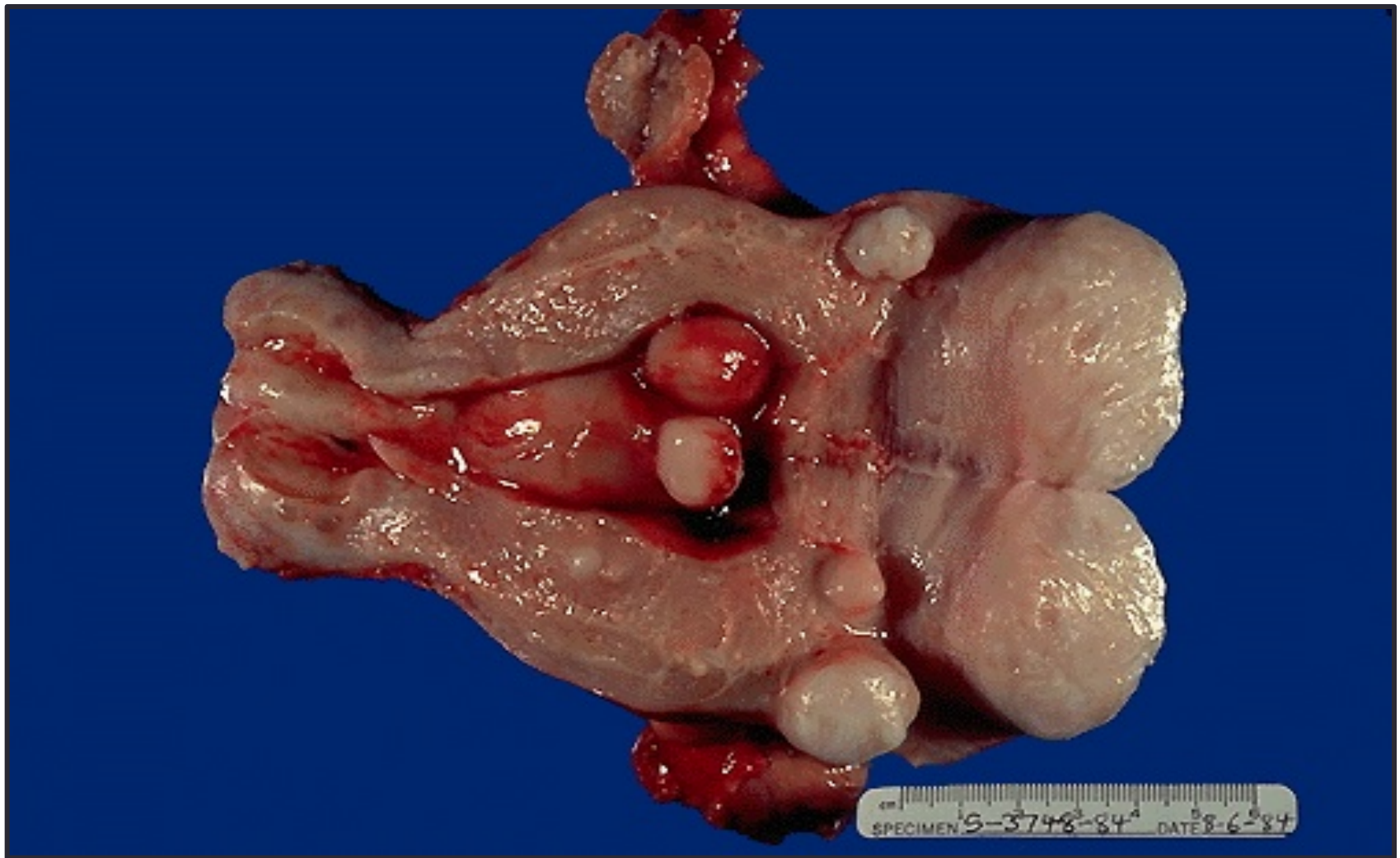
Intradermal nevus in a low power field: Nests and clusters of small round or spindle shaped nevus cells with few melanophages in the upper dermis.



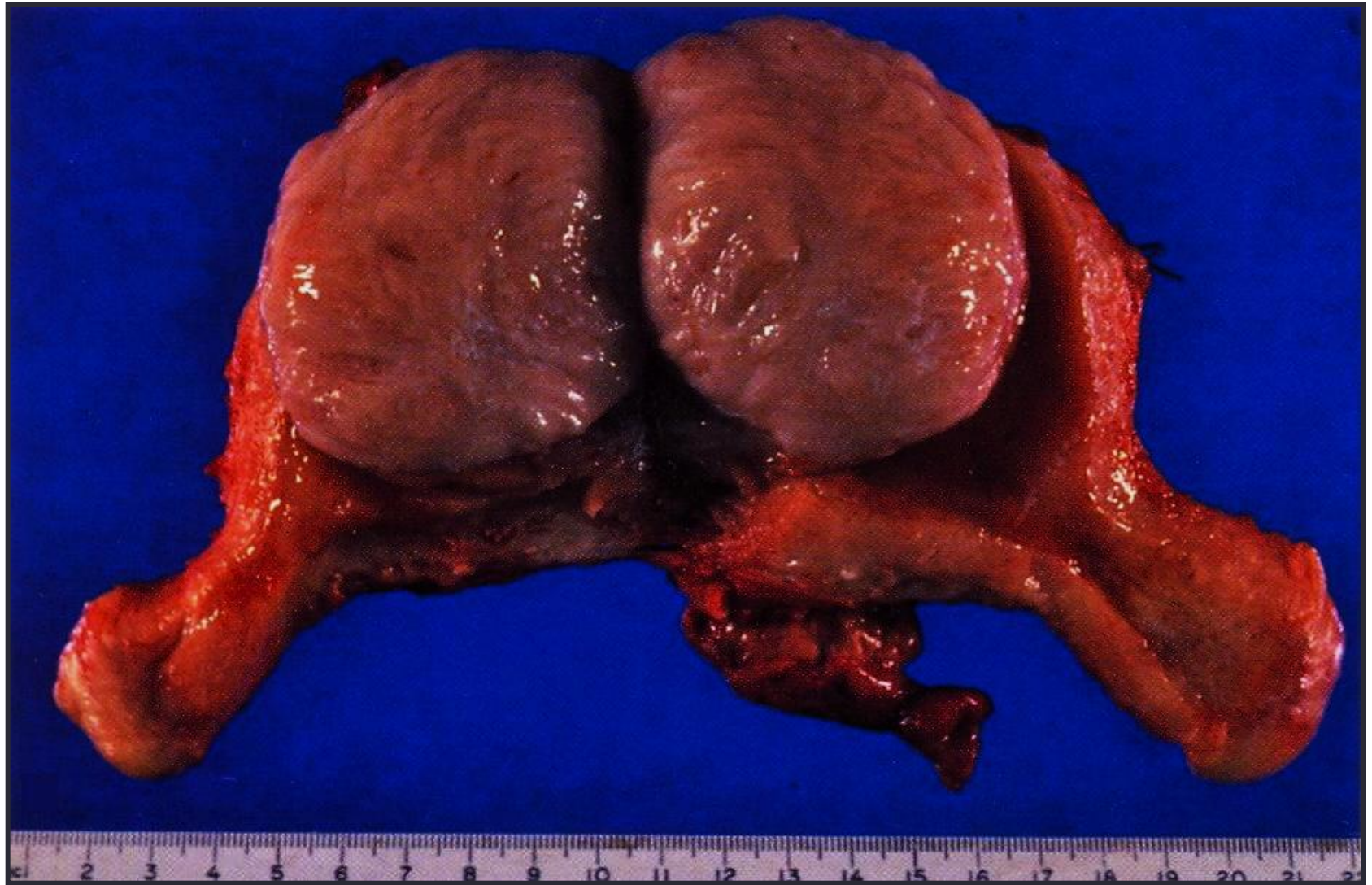
Intradermal nevus in a high power field: The cells contain varying amounts of brown melanin pigment. No junctional activity is noted.

CASE 4

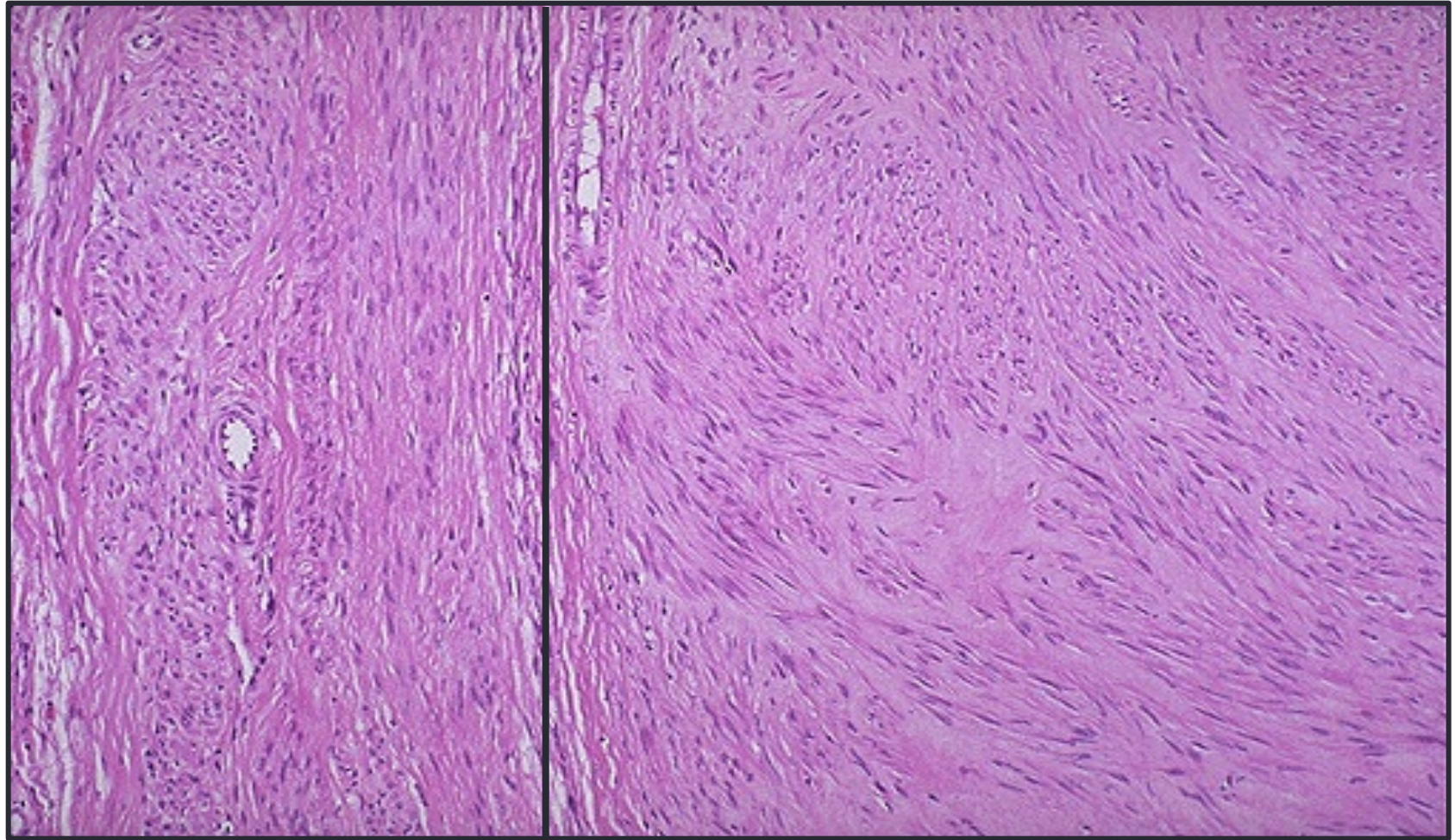
Uterine leiomyomata



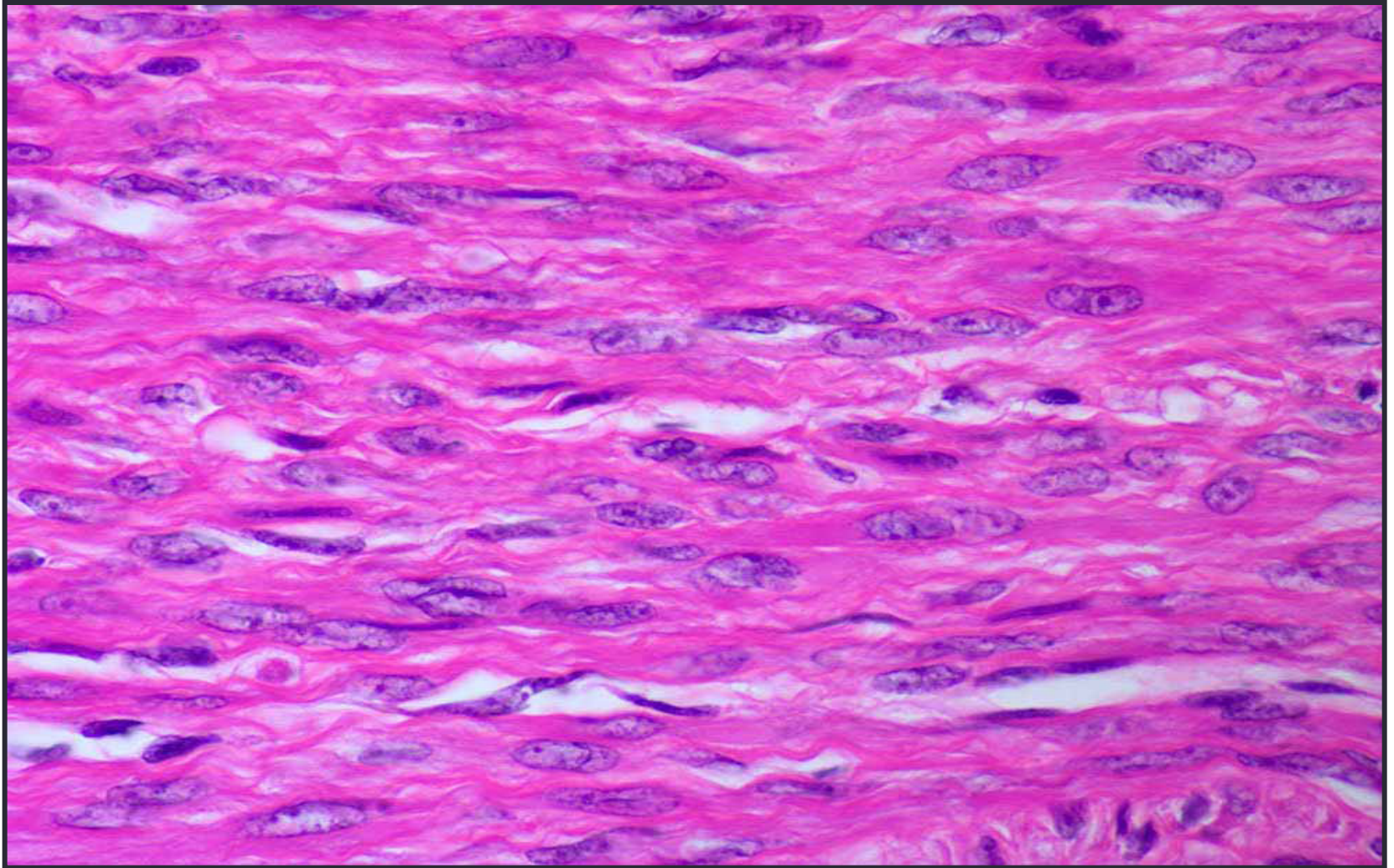
Multiple uterine leiomyomata – gross appearance: Smooth muscle tumors of the uterus are often multiple. They are submucosal, intramural, and subserosal leiomyomata in this picture.



Uterine leiomyoma – gross appearance: A well demarcated tumour mass in the muscle coat of the uterus without a definite capsule.



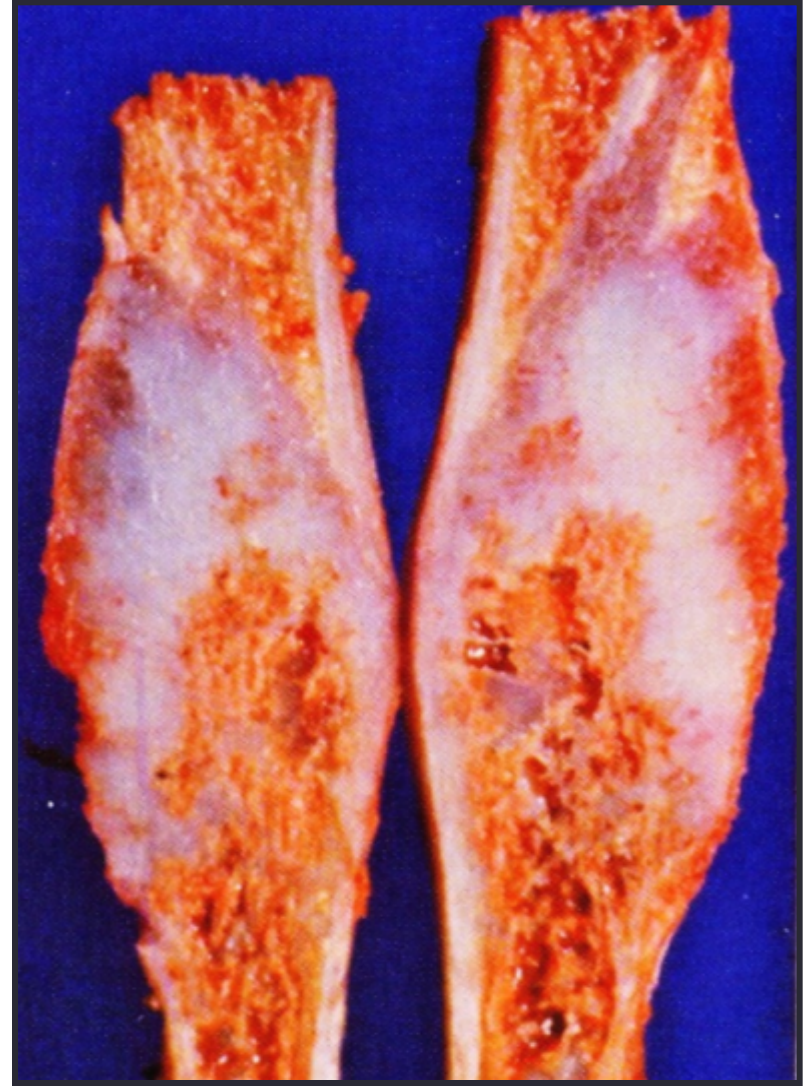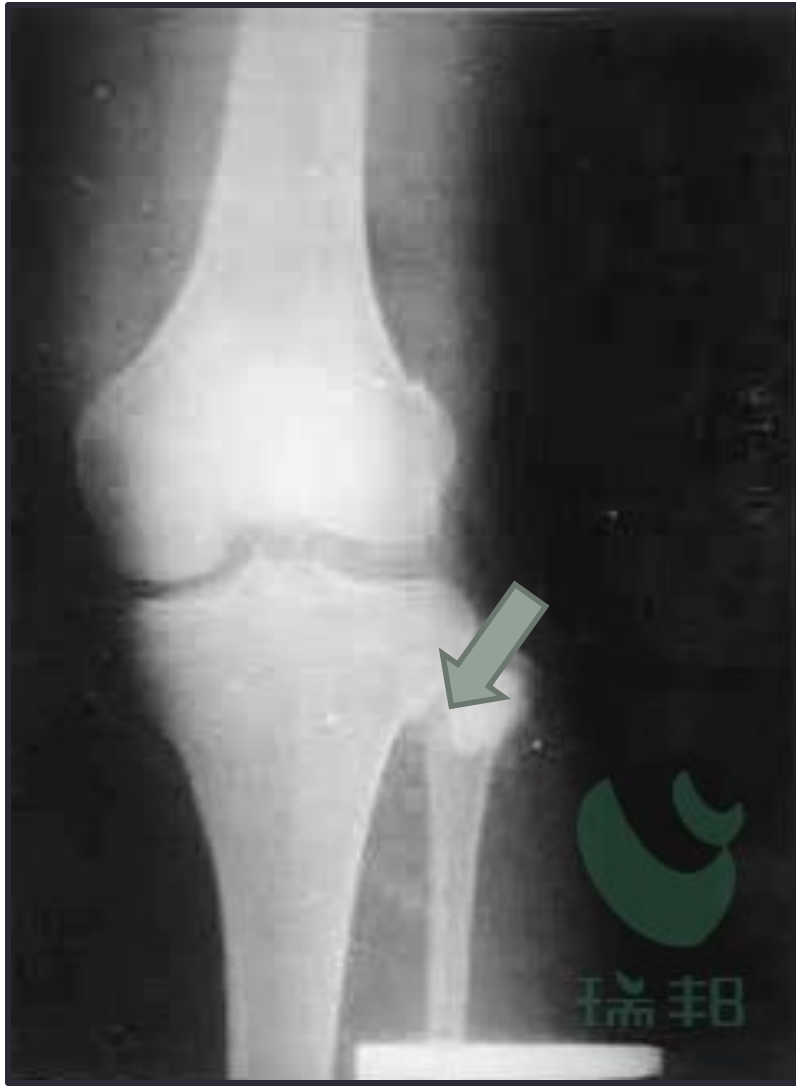Uterine leiomyoma in a low power field: Normal myometrium is on the left, and the neoplasm is well-differentiated so that the leiomyoma on the right hardly appears different. Bundles of smooth muscle are interlacing in the tumor mass.



Uterine leiomyoma in a high power field: The muscle cells are spindle shaped with elongated nuclei and eosinophilic cytoplasm.

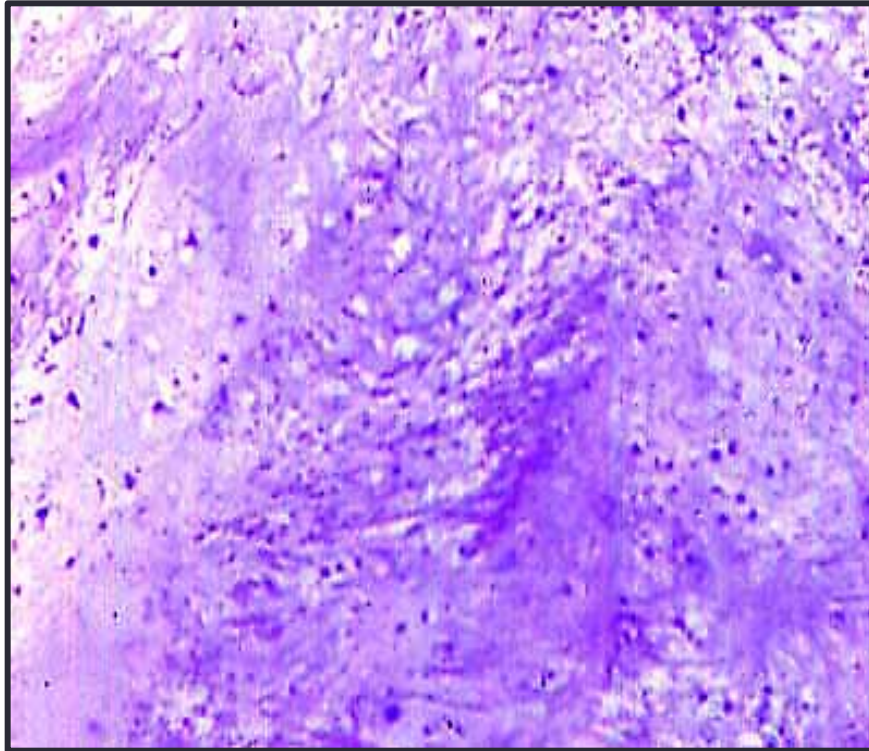
CASE 5

Chondroma

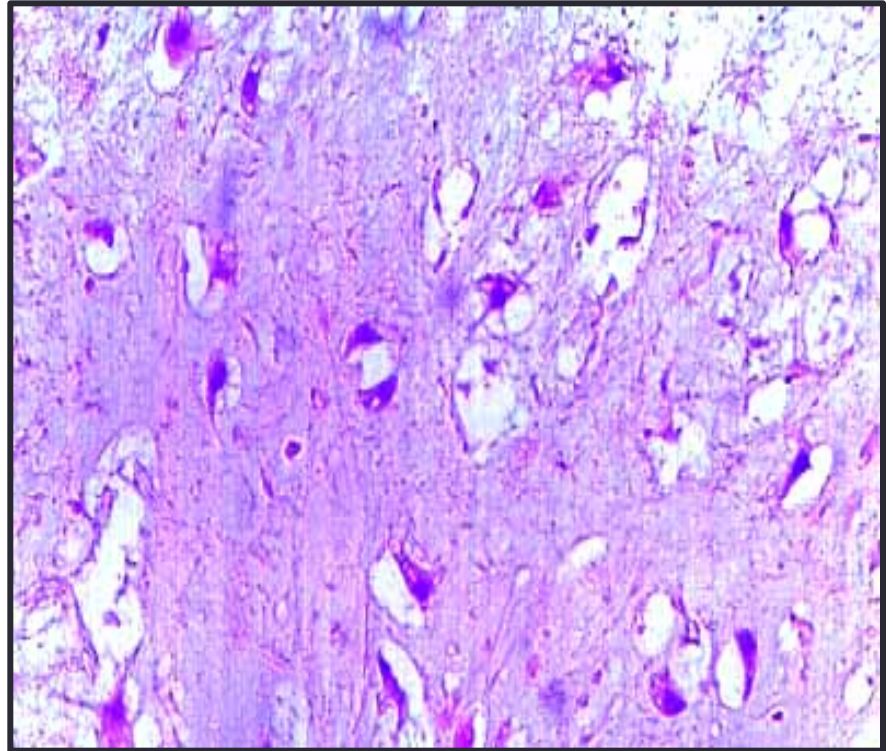


Enchondroma of the fibula: The picture shows an intramedullary bone expansion, a chondromyxoid material & a thin bone cortex.

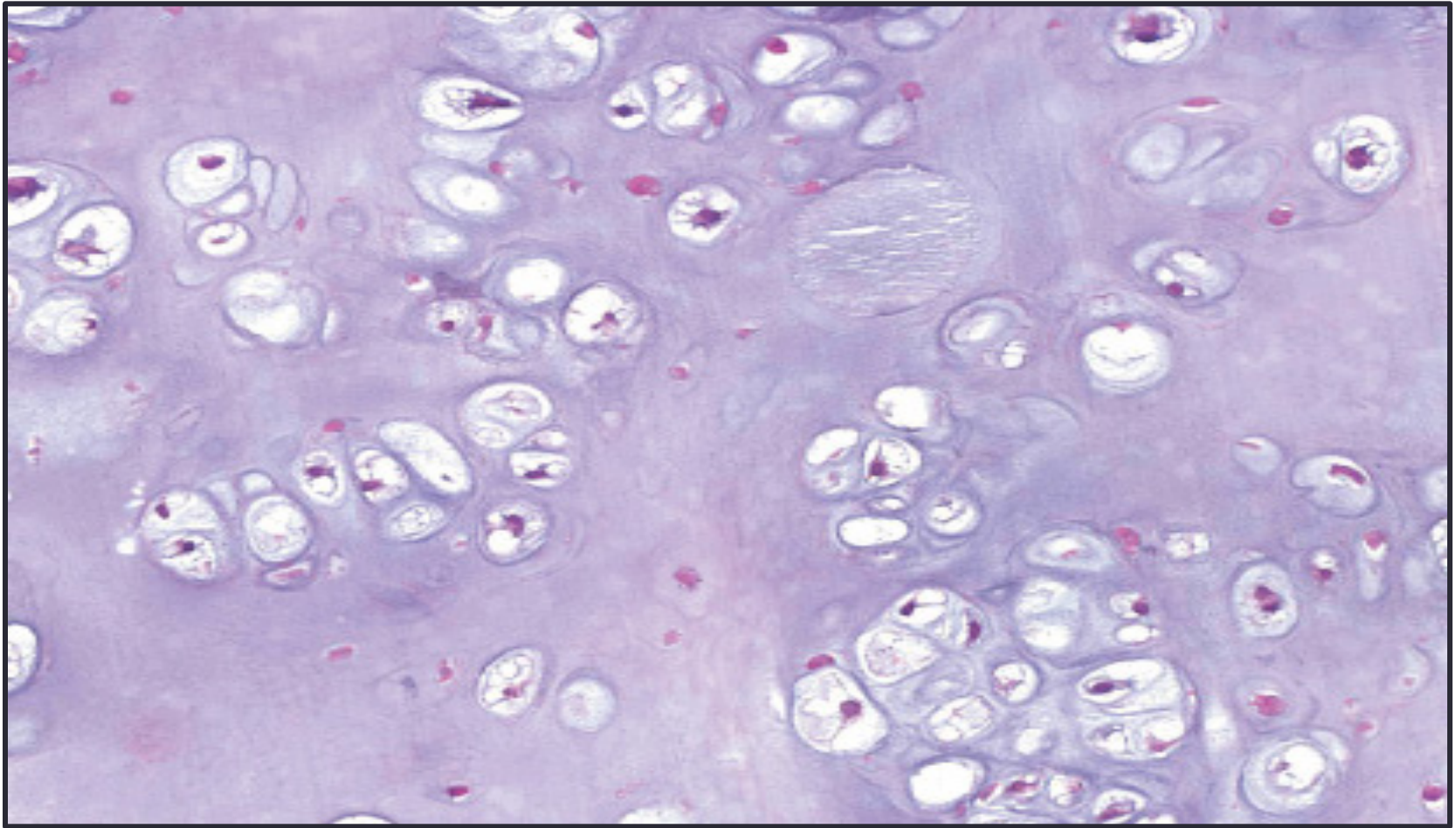
Low power field



High power field



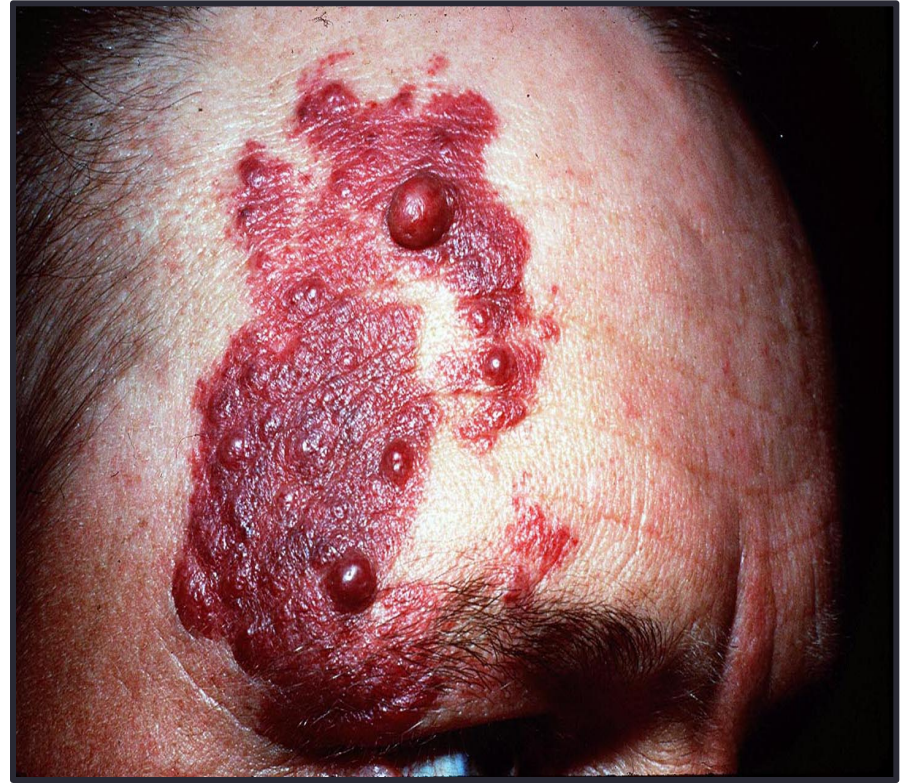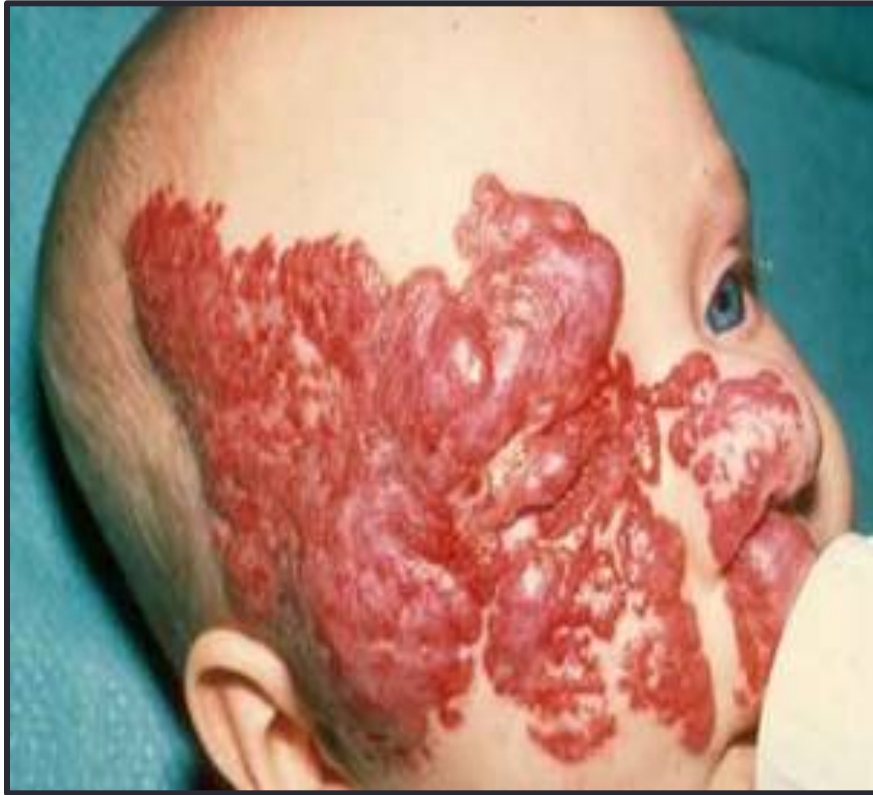Enchondroma of the fibula – Microscopic: Lobules consist of mature cartilage cells irregularly distributed through a pale blue homogenous matrix and are contained within the lacunar spaces singly, in pairs or in tetrads. Few bony trabeculae are included in the tumour.



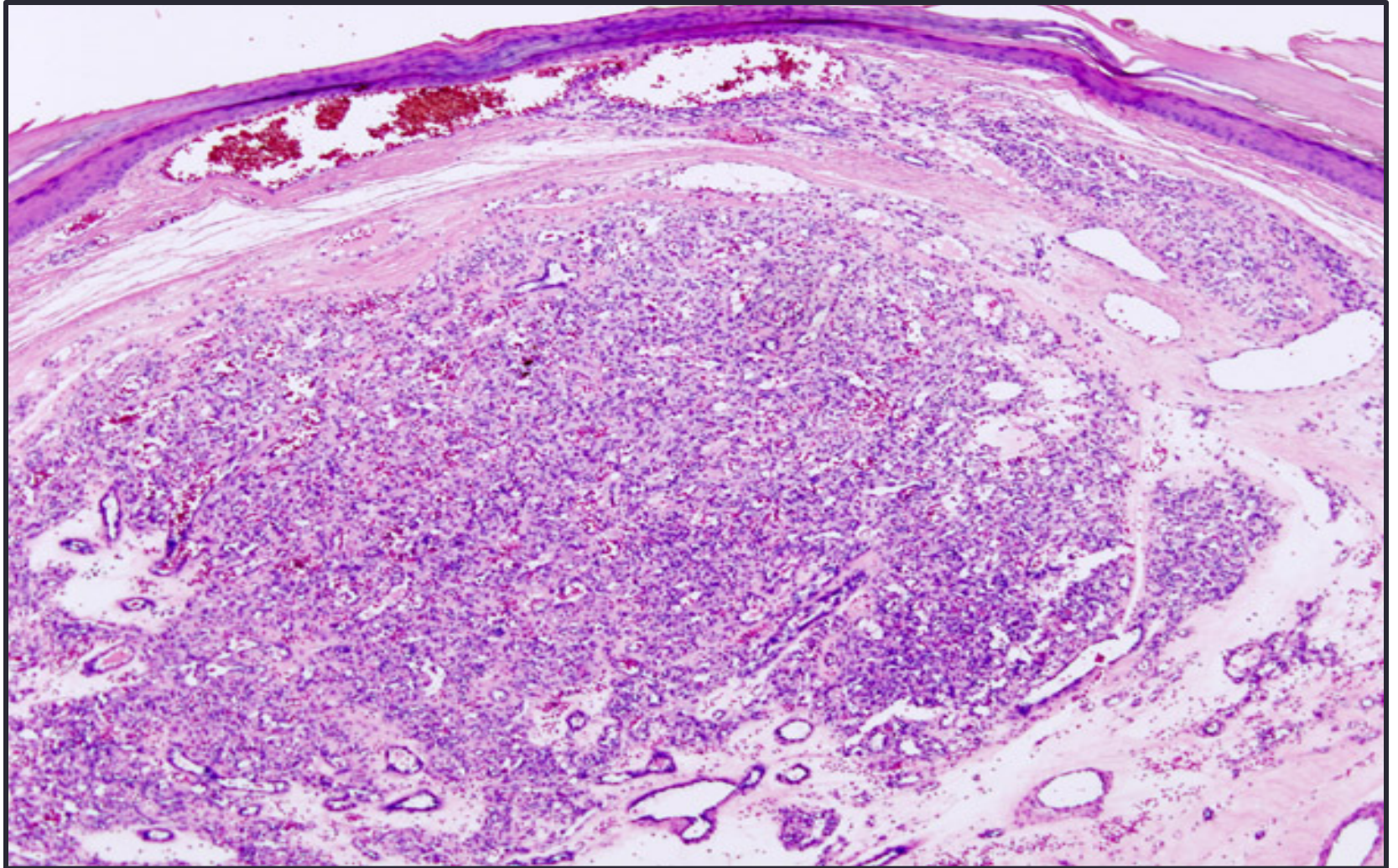
Enchondroma of the fibula – high power field: Cartilage shows hypo- to moderate cellularity and contains chondrocytes of variable sizes. The nuclei tend to be small, round and hyperchromatic. Scattered binucleated cells may be found. Irregular purple granules within the matrix represent calcifications.

CASE 6

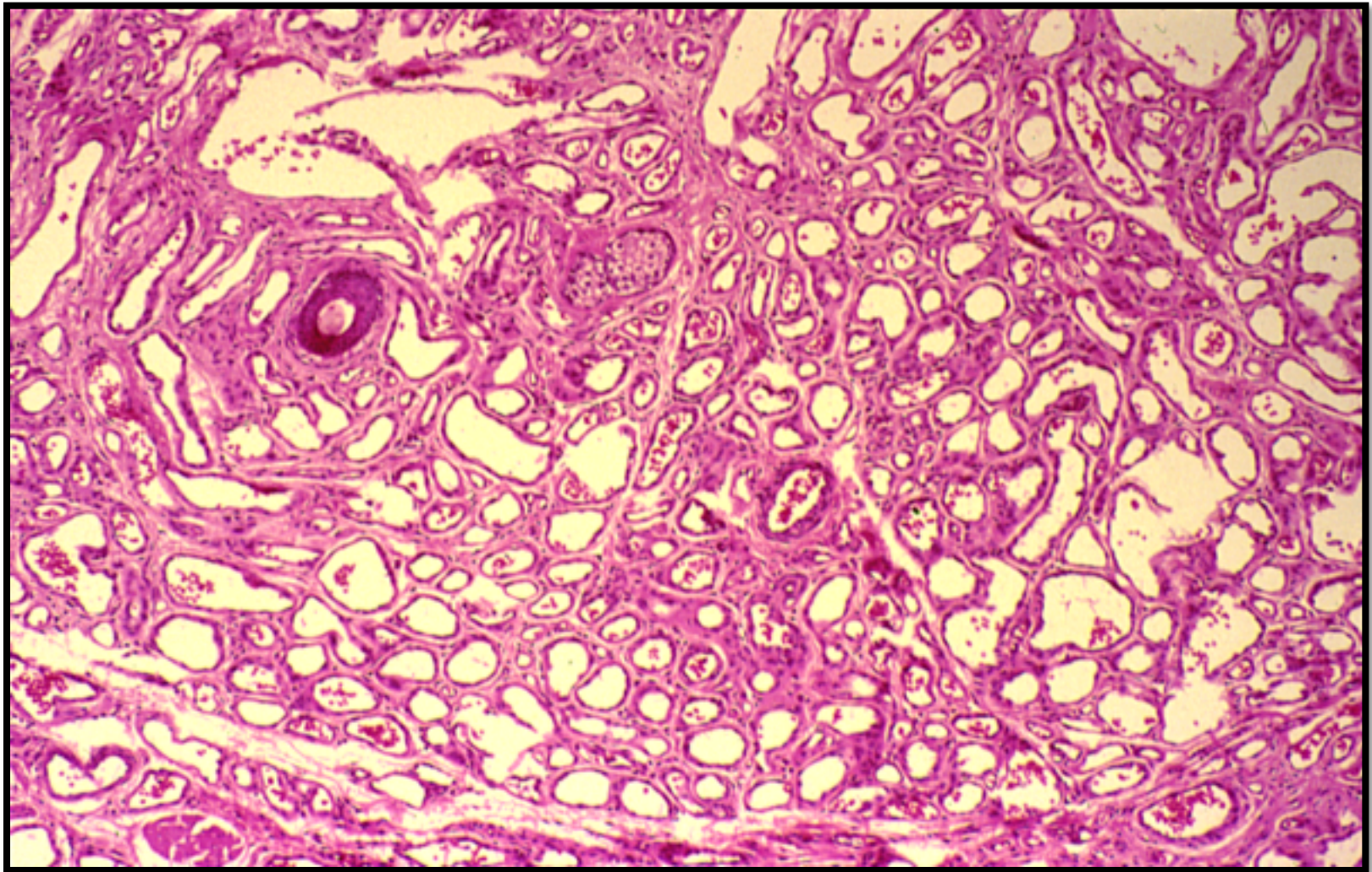
Hemangioma



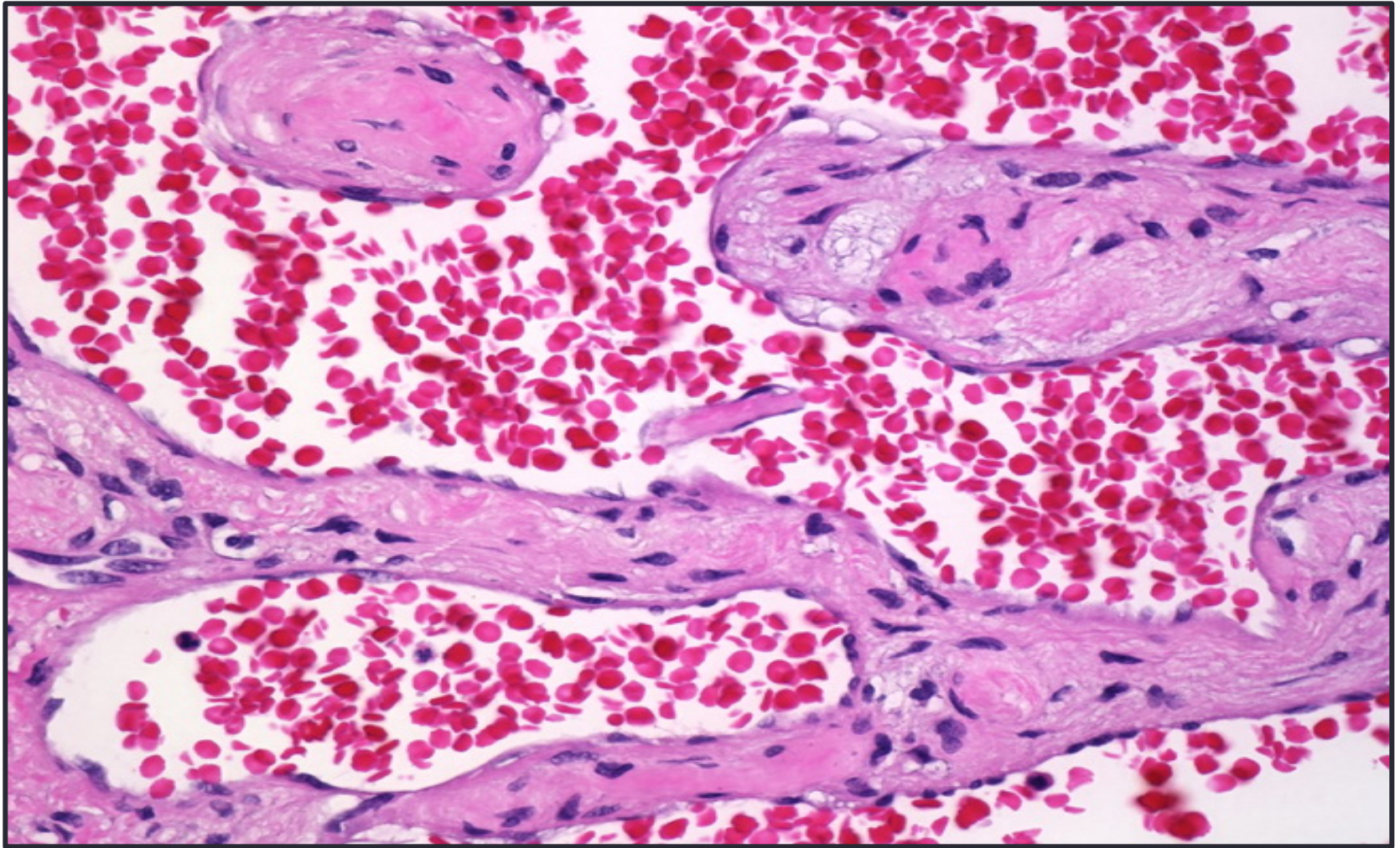
Hemangioma of the skin: A tumour mass in the dermis which consists of a large number of vascular spaces of varying shapes and sizes separated by a connective tissue stroma.



Capillary hemangioma of the skin – low power field: Histopathology of a cutaneous capillary hemangioma (skin biopsy, H&E stain).



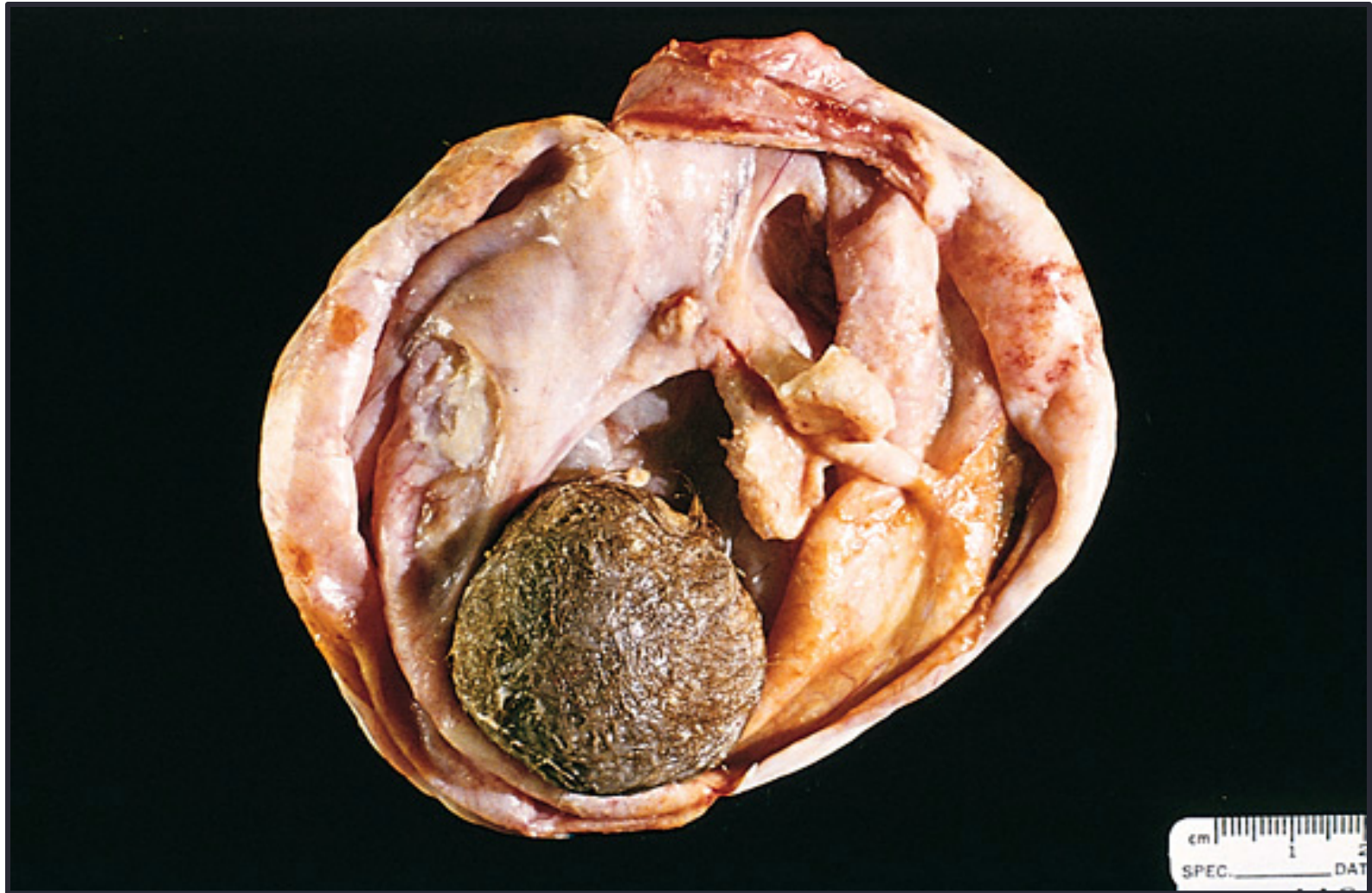
Capillary hemangioma of the skin – low power field: Vascular spaces are lined by flattened endothelial cells and some contain blood. Delicate connective tissue stroma separate the capillary vascular spaces.



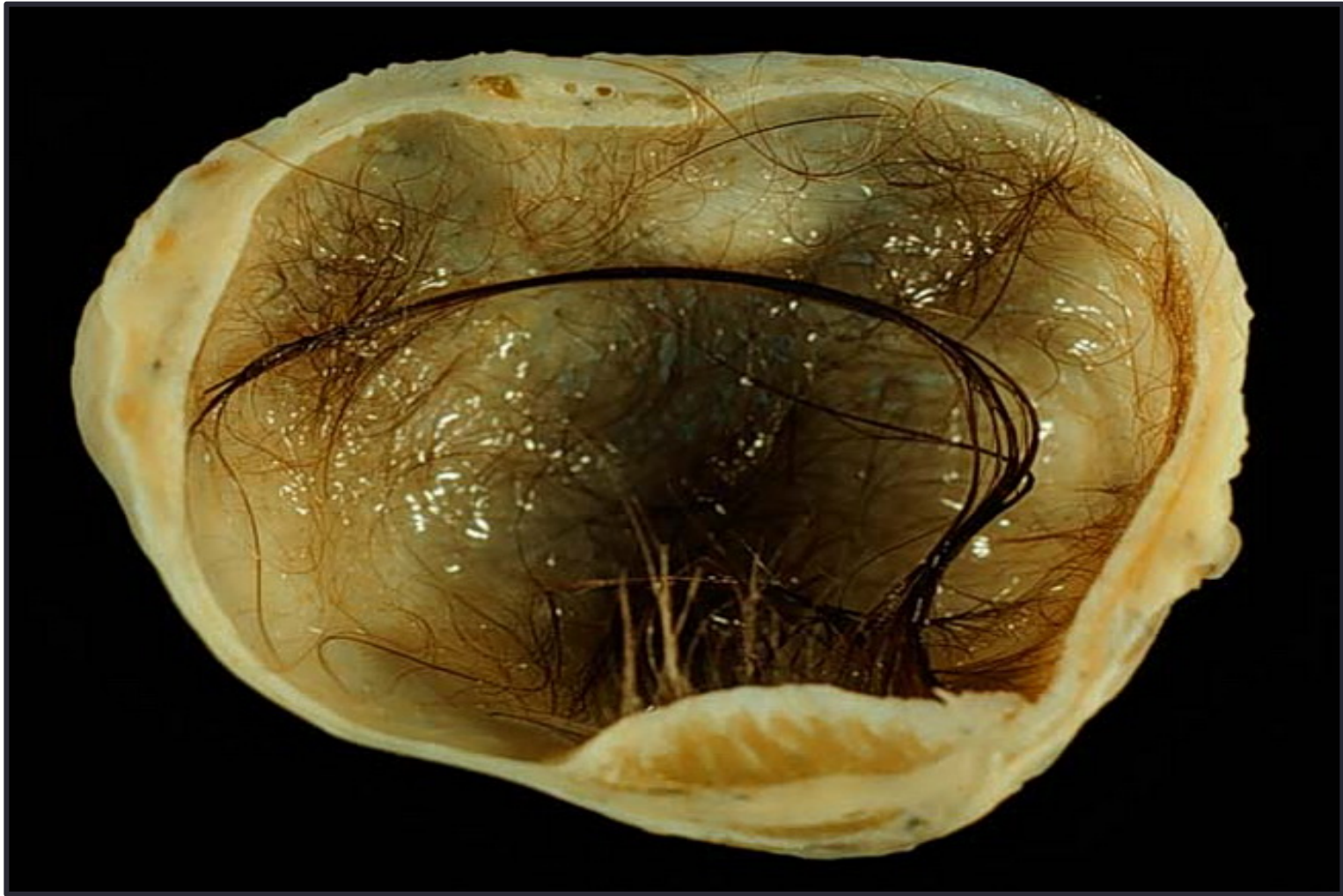Cavernous hemangioma of skin – high power field: Large cavernous hemangioma, usually on an extremity, complicated by thrombocytopenic purpura. Blue rubber bleb nevus syndrome comprises cavernous hemangiomas of the skin and gastrointestinal tract.

CASE 7

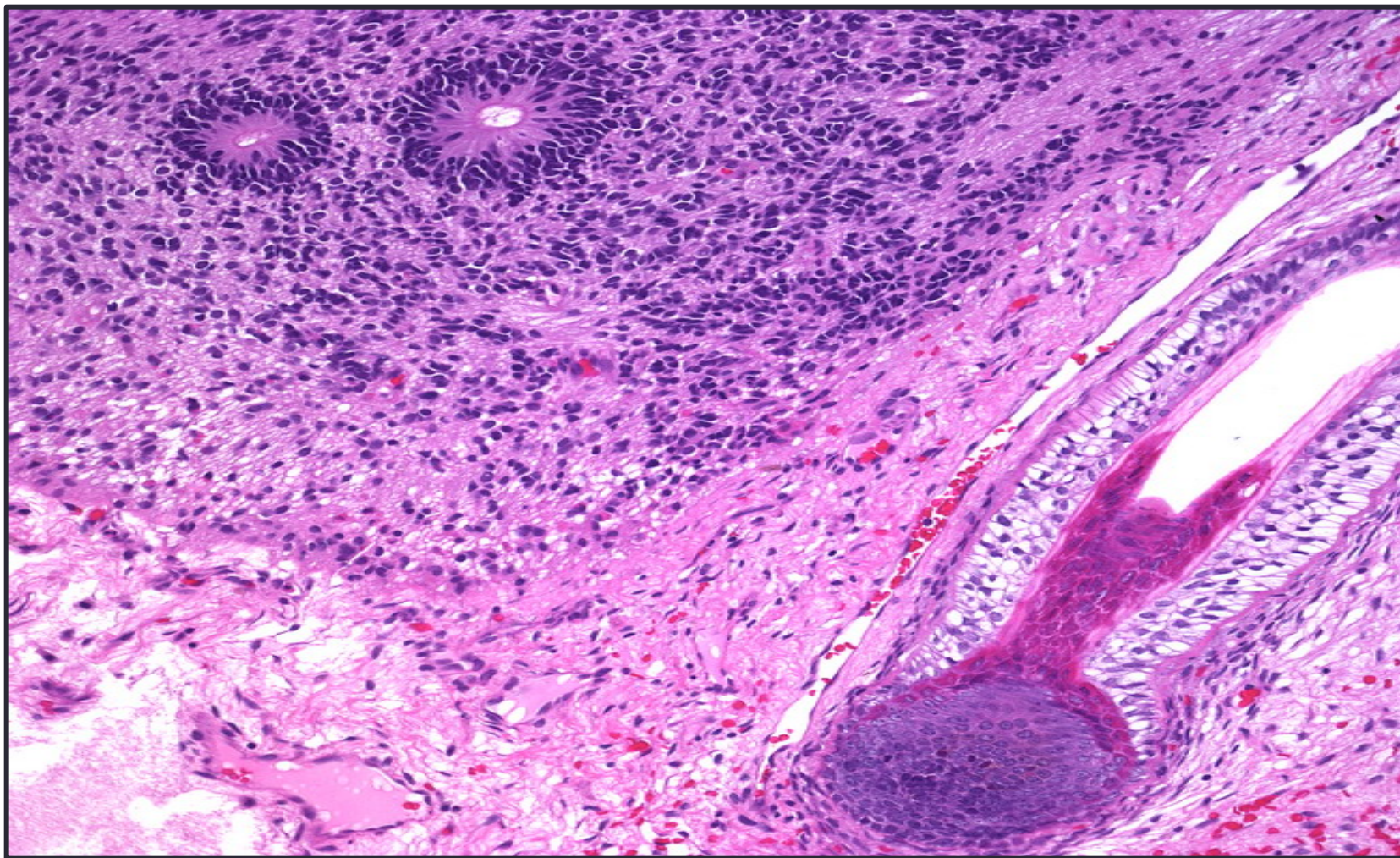
Teratoma (Dermoid cyst) of the ovary



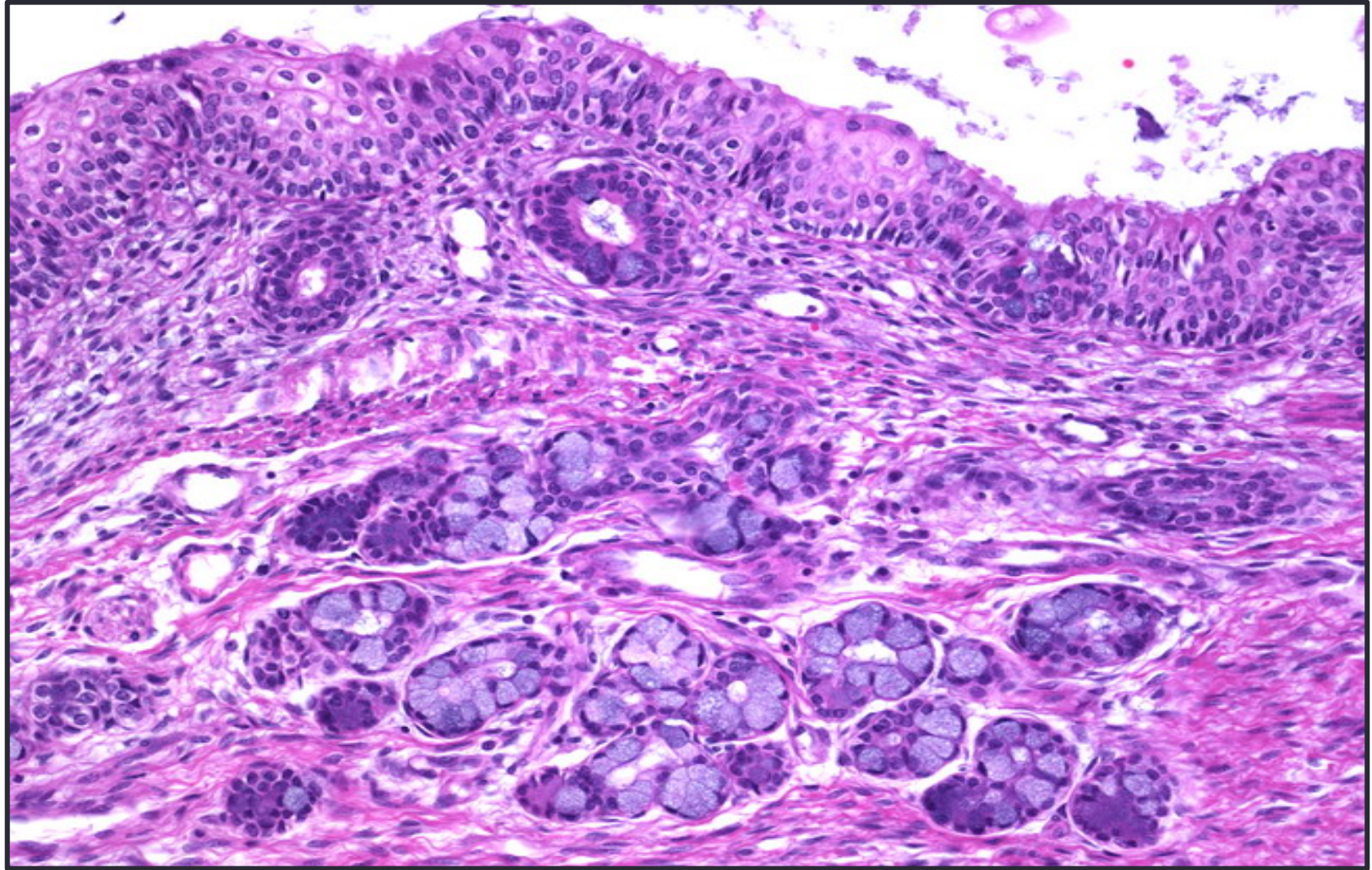
Mature cystic teratoma of the ovary: An opened mature cystic teratoma (dermoid cyst) shows hair (bottom) and a mixture of tissues .



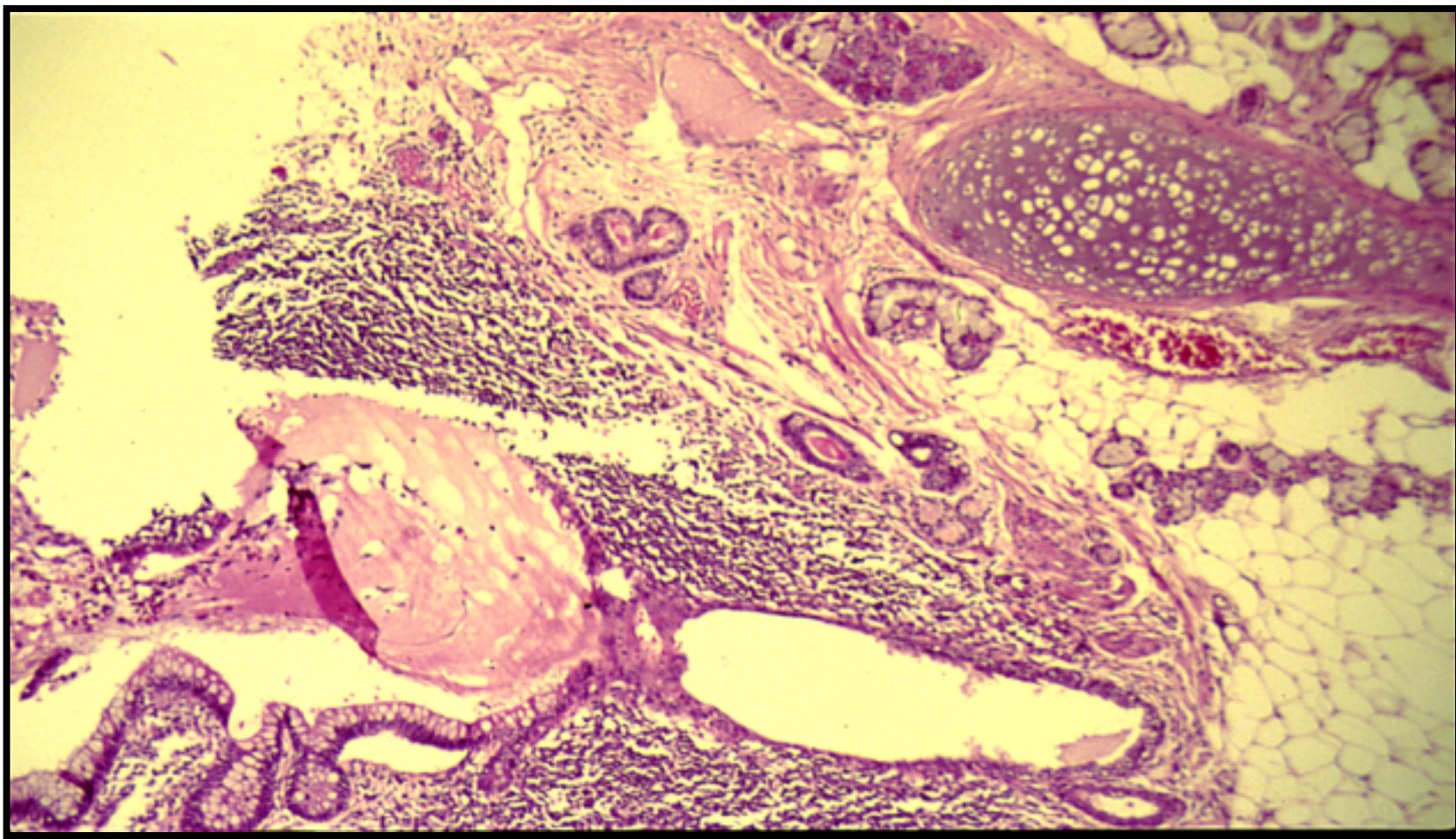
Mature cystic teratoma of the ovary: This 4.0 cm dermoid cyst is filled with a greasy material (keratin and sebaceous secretions) and shows tufts of hair. The rounded solid area at the bottom is called Rokitansky's protruberance. Microscopically, it also showed foci of neural tissue.



Mature cystic teratoma of the ovary: An ovarian teratoma showing neuroepithelial tubules and rosettes (immature component) adjacent to a hair follicle (mature component). They consist of epidermis, hair follicles, sweat and sebaceous glands and neuroectodermal derivatives.



Mature cystic teratoma of the ovary: This image shows skin and mucinous glands in a solid mature teratoma of the ovary.



Mature cystic teratoma of the ovary: Stratified squamous epithelium with underlying sweat glands, sebaceous glands, hair follicles, columnar ciliated epithelium, mucous and serous glands and structures from other germ layers such as bone and cartilage, lymphoid tissue, smooth muscle and brain tissue containing neurons and glial cells.

END OF SESSION 1

Thank You