

Radial & Ulnar Nerves

Department of Anatomy

King Saud University



Dr. Sameerah Shaheen
Assistant Professor Anatomy

sshahee@ksu.edu.sa

Objectives

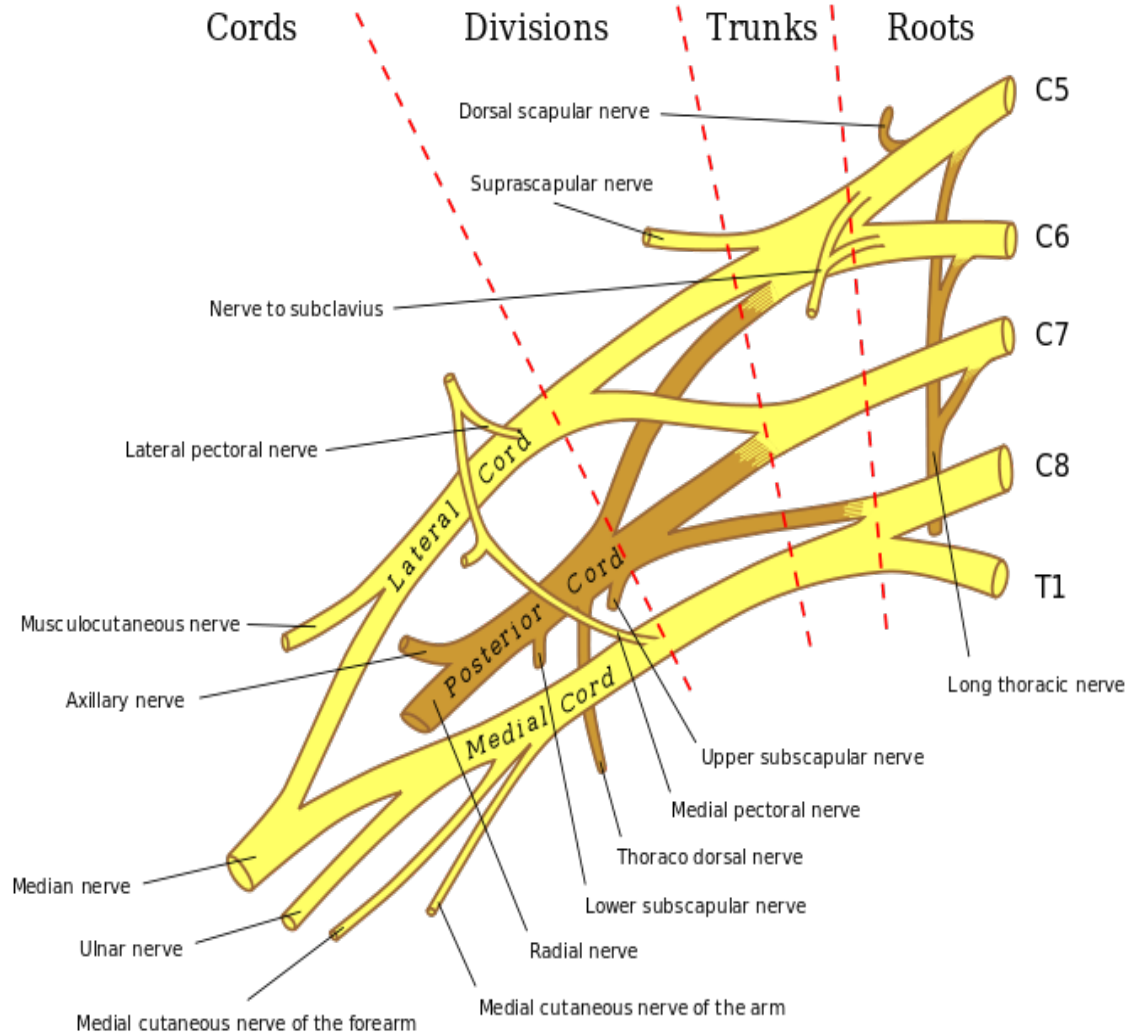
By the end of this session we should be able to:

- Describe the anatomy of the radial & ulnar nerves regarding:
 - Origin,
 - Course &
 - Distribution.
- List the branches of the nerves.
- Describe the causes and manifestations of nerve injury.

Radial Nerve

The radial nerve arises from the posterior cord of the brachial plexus.

The radial nerve receives branches from each nerve root from C5-T1.



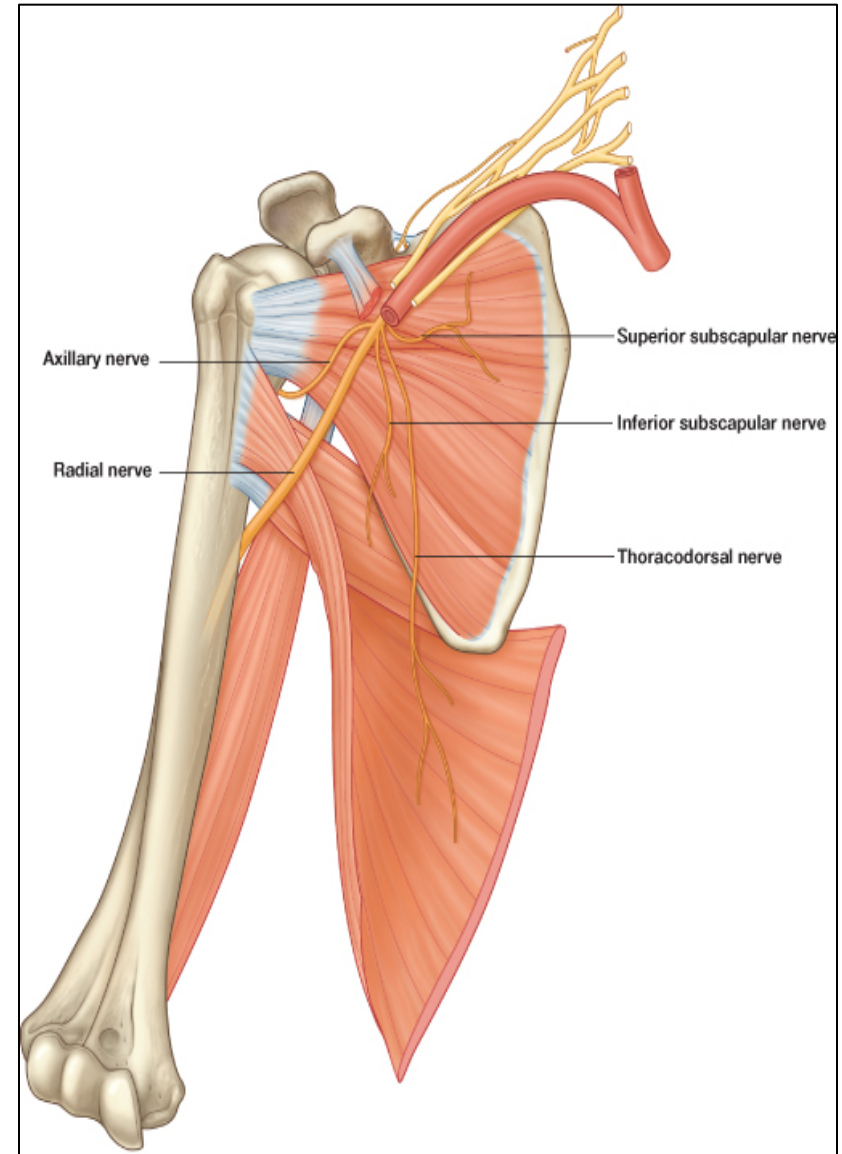
Radial Nerve

Origin:

- *One of the five branches of the Posterior cord of the brachial plexus*
- *Begins in the axilla*
- *the largest branch*

Supplies:

- *Nerve of the extensor compartment*
- *Muscles of the posterior compartment of the arm & the forearm*



Radial Nerve

In the Axilla

- The radial nerve lies posterior to the axillary artery
- The radial nerve continuous into the posterior compartment of the arm
- Then gives three branches in the axilla:

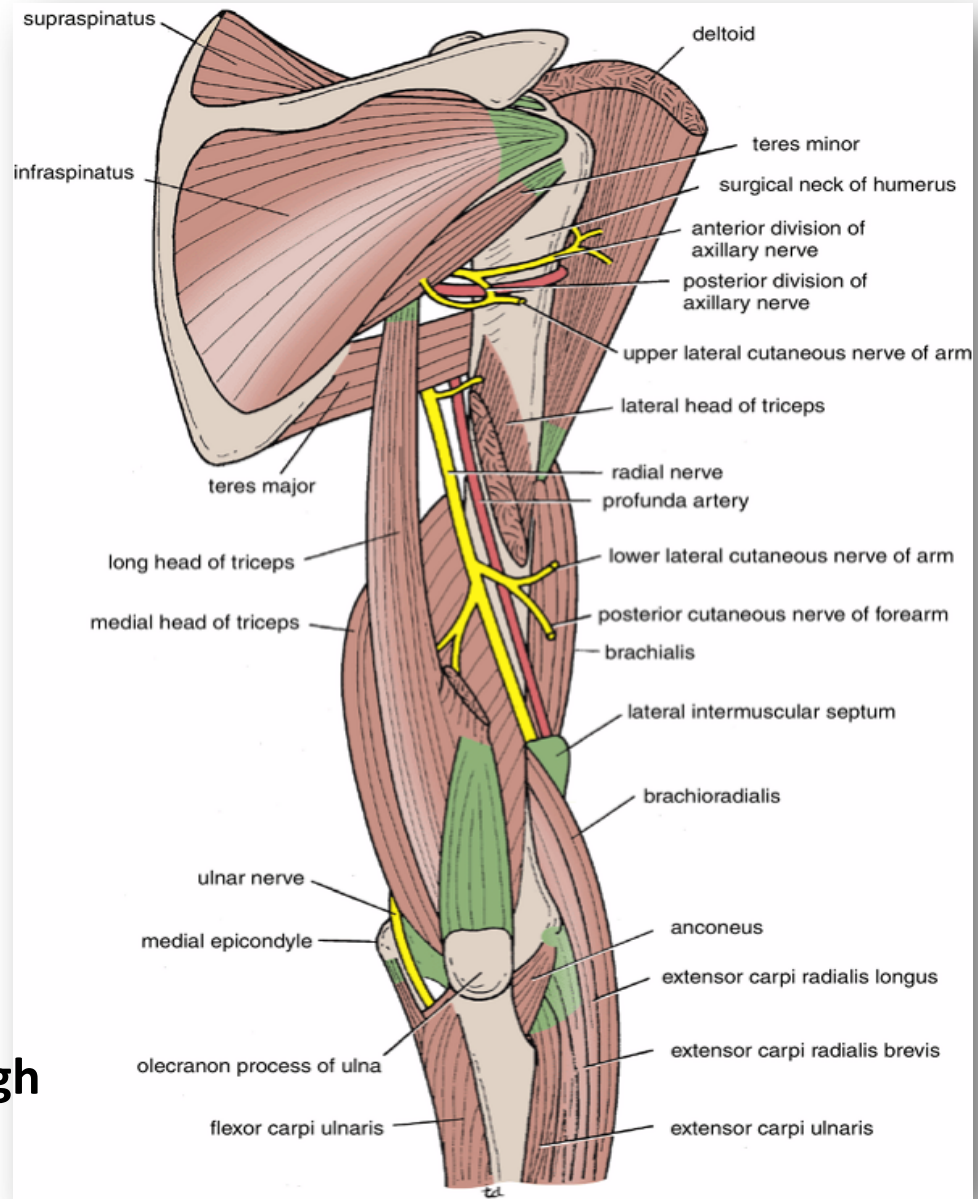
Cutaneous:

Posterior cutaneous nerve of arm.

Muscular:

Long & Medial Heads of Triceps.

- The radial nerve next travels through the triangular interval with the profunda brachi artery posteriorly



Radial Nerve

In the Arm

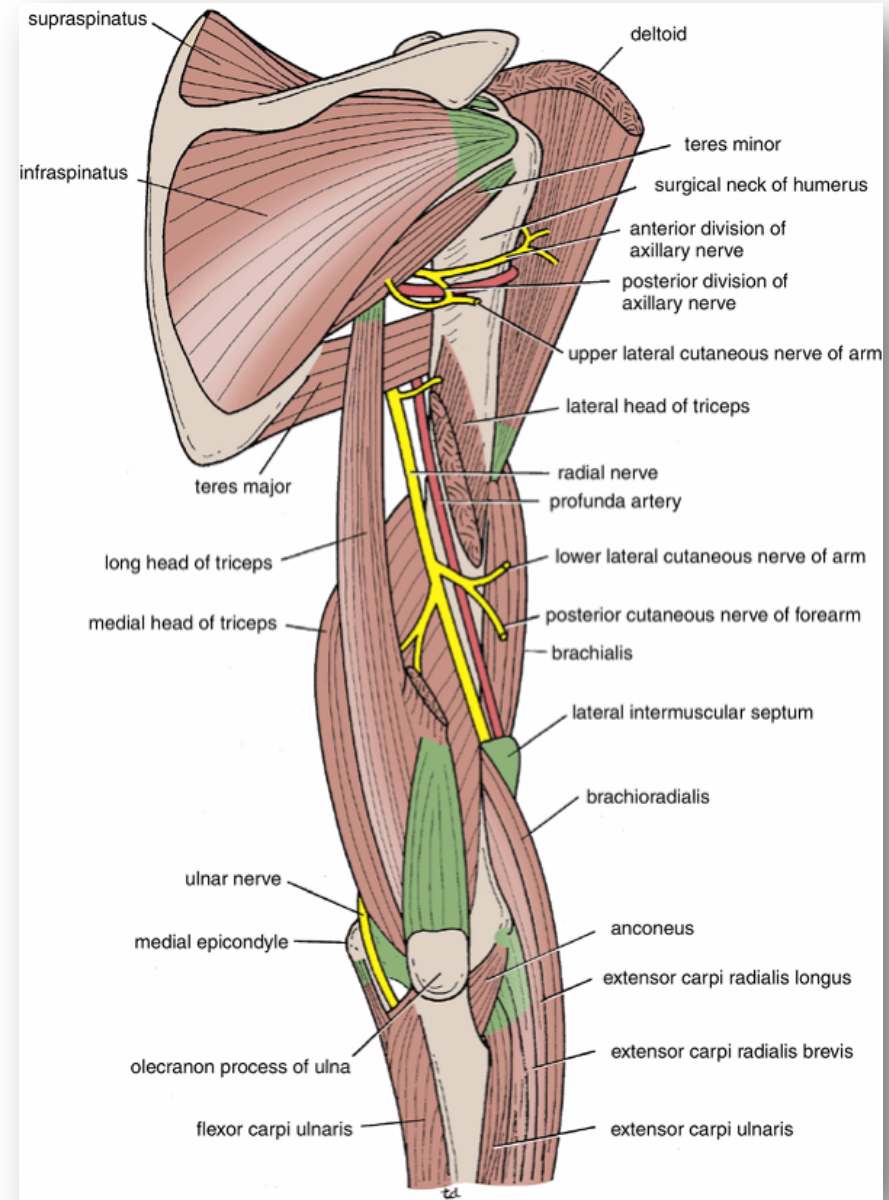
- *It winds around the back of the arm in the Spiral Groove on the back of the humerus between the heads of the triceps.*
- *In the spiral groove, the nerve is accompanied **by the Profunda Vessels**, and it lies directly **in contact with the shaft of the humerus (a Dangerous Position)**.*

Cutaneous:

1. *Lower lateral cutaneous nerve of arm.*
2. *Posterior cutaneous nerve of forearm.*

Muscular:

3. *Lateral & Medial heads of triceps.*
4. *Anconeus.*



Radial Nerve

In the Forearm

- *It pierces the Lateral Intermuscular septum & enters the ant. compartment of the arm (7.5 cm) above elbow joint.*
- *Descends in front of the Lateral Epicondyle.*
- *Passes forward into the Cubital Fossa*

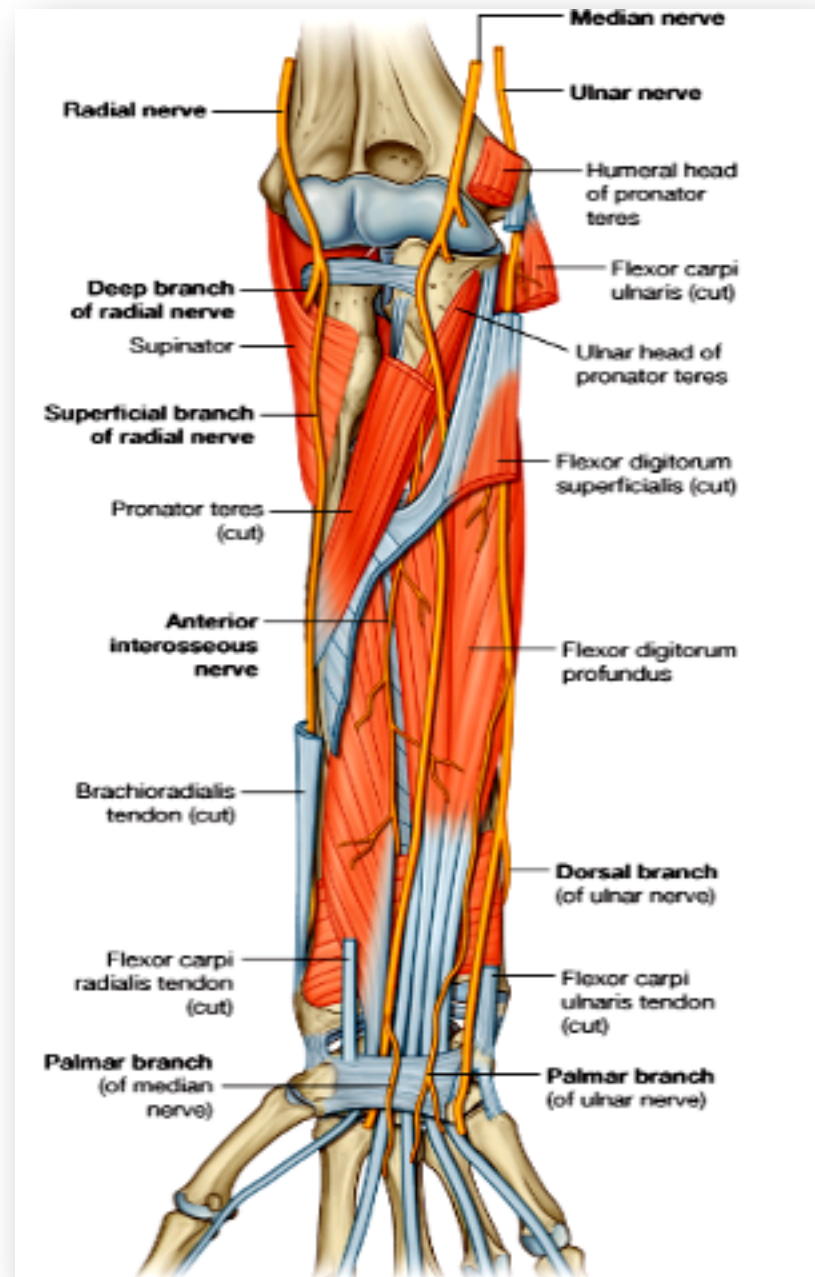
Divides into

1. Superficial branch

Conti. of the radial nerve

Purely cutaneous

2. Deep branch (Post. interosseous)



Radial Nerve

Branches

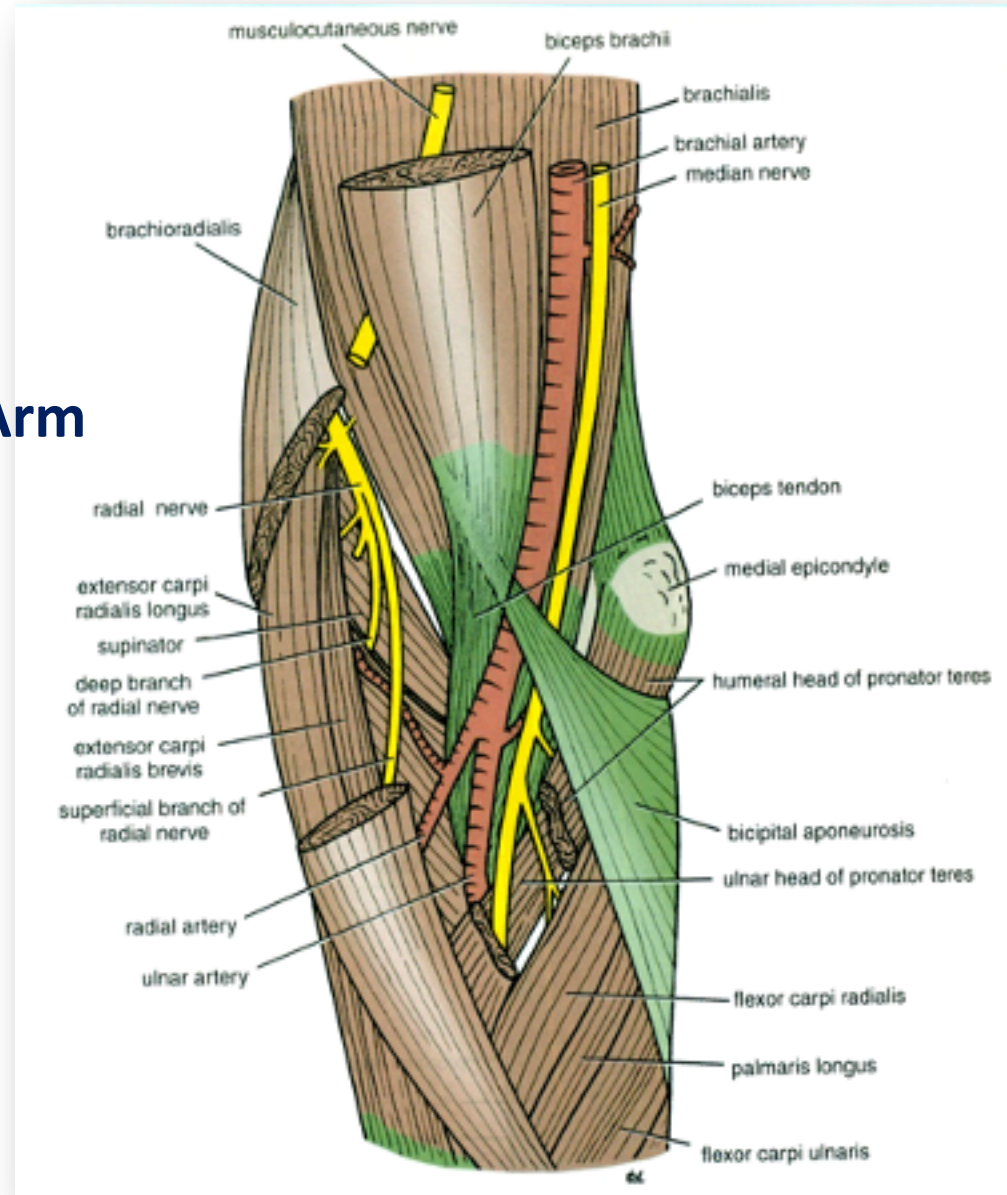
Close to Lateral Epicondyle:
In the flexor compartment of Arm

Muscular:

1. *Brachialis.*
2. *Brachioradialis.*
3. *Extensor carpi radialis longus.*

Articular

- *to the elbow joint*



Radial Nerve

Terminal Branches

Superficial Branch

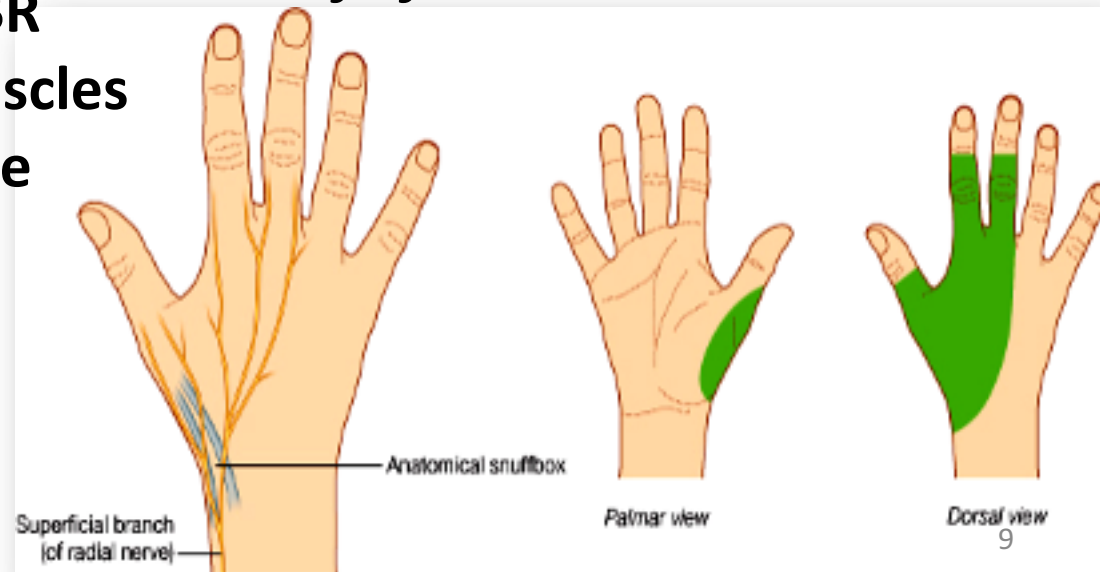
- Conti. of the radial nerve
- Purely cutaneous
- Runs down the flexor comp of the forearm
- Winds around the lower end of the radius deep to BR
- Crosses the pollicis muscles to reach the back of the hand

- Supplies:

The superficial radial nerve is a sensory nerve supplying the majority of the dorsum of the hand

-The skin on the lateral (radial) two and half digits or three and a half of proximal phalanges

-The skin of the corresponding half of the hand



Radial Nerve

Terminal Branches

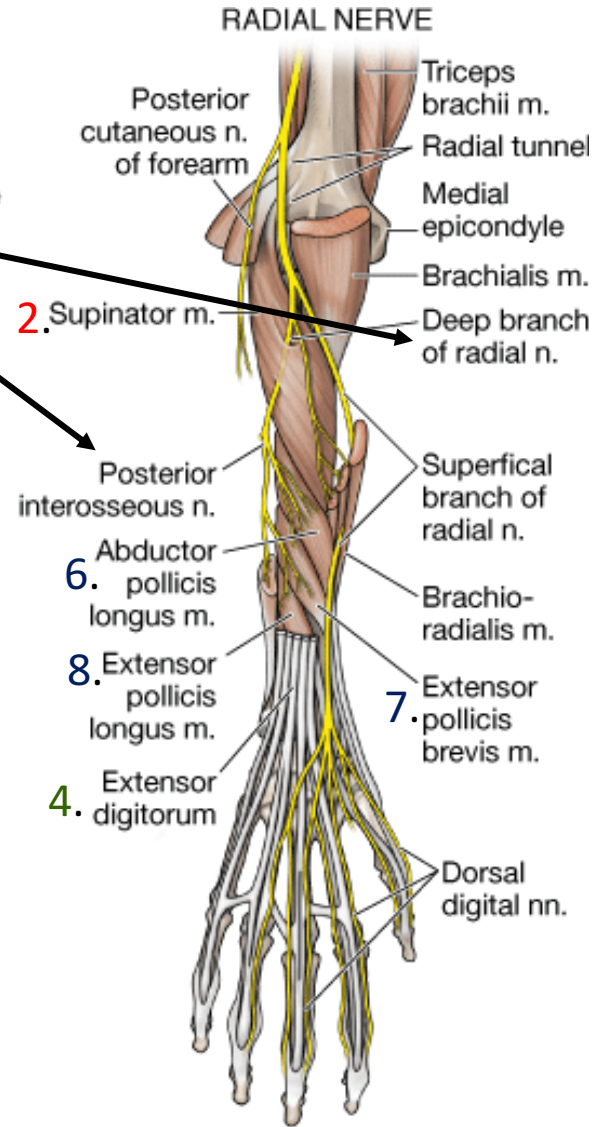
Deep Branch (Post. interosseous)

Course

It winds around the neck of the radius, within the supinator muscle, and enters the posterior compartment of the forearm.

Muscular:

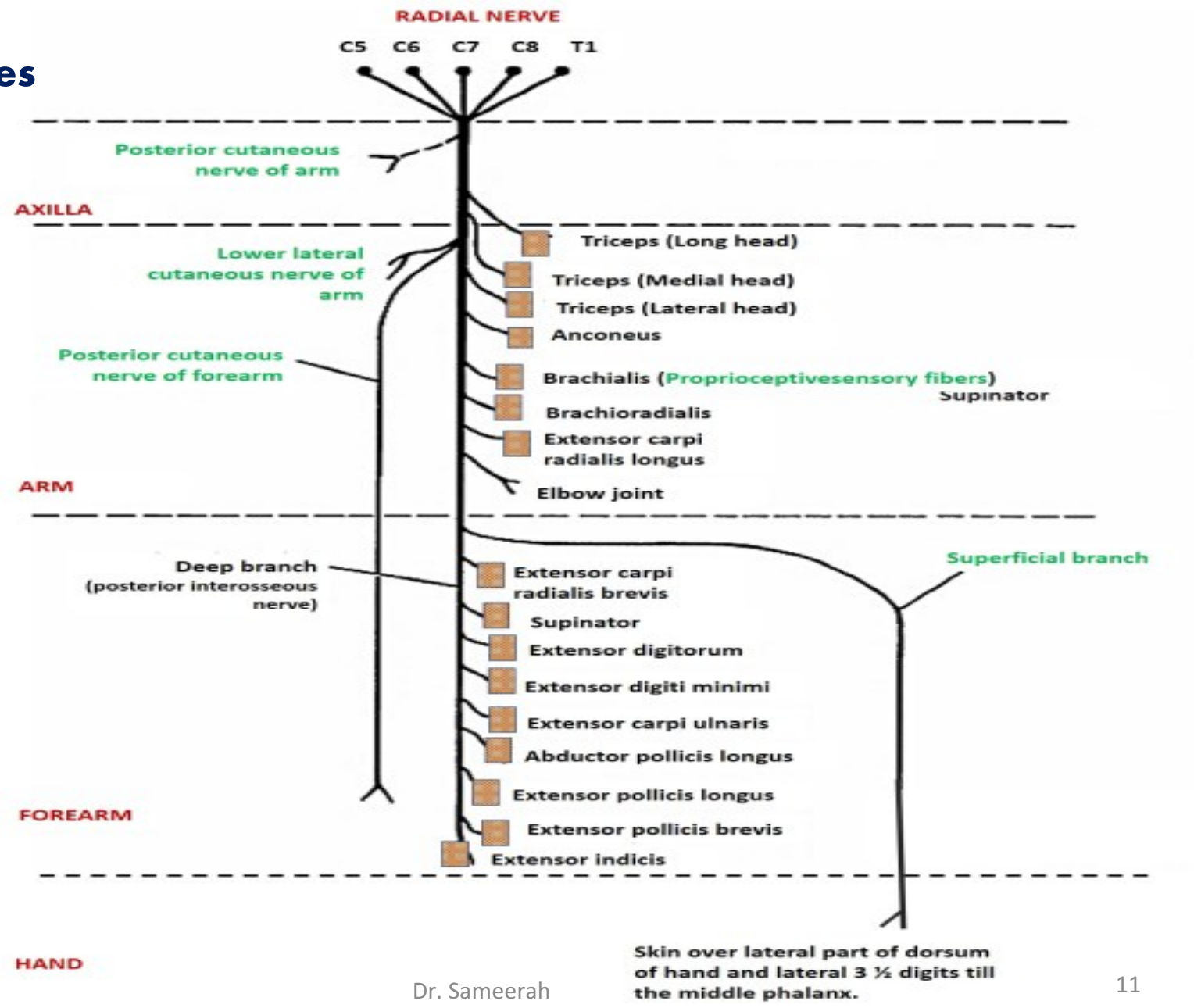
1. **Extensor carpi radialis brevis.**
2. **Supinator.**
3. **Extensor carpi ulnaris.**
4. **Extensor digitorum**
5. **Extensor digiti mini**
6. **Abductor pollicis longus.**
7. **Extensor pollicis brevis.**
8. **Extensor pollicis longus.**
9. **Extensor indicis.**



C

Radial Nerve

Summary of main branches



Radial Nerve

Applied Anatomy

Transient paralysis

1. **Improper use of crutch (pressing the nerve in the axilla)**
2. **Saturday night palsy (draping the arm over the chair in a state of diminished consciousness)**

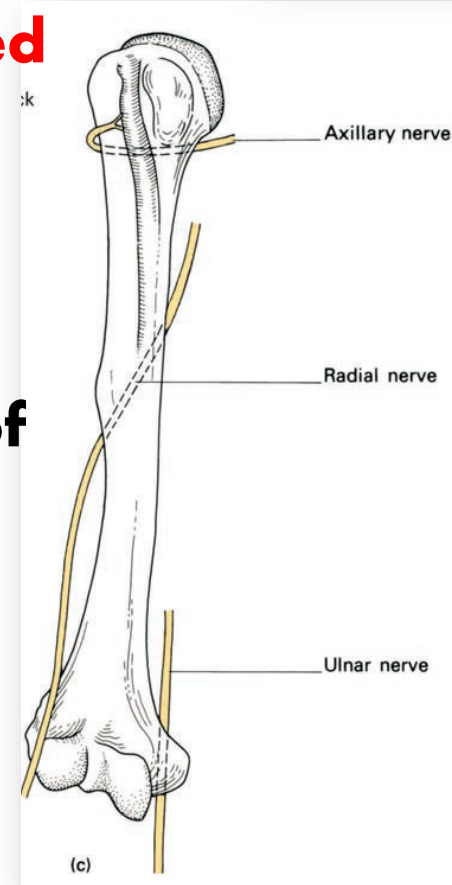
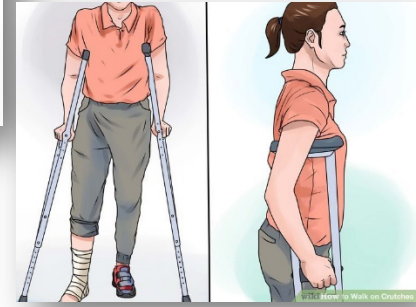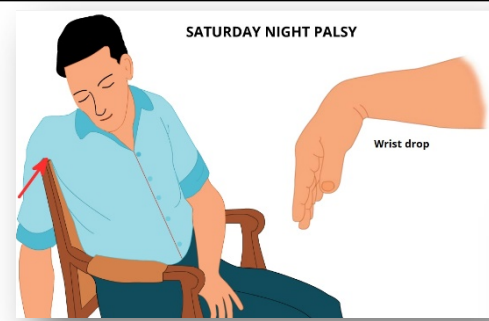Test. Extension of elbow. Result ?

Injury of the radial nerve

Most common-fracture of the shaft of the humerus

The characteristic lesion is "WRIST DROP"

Inability to extend WRIST and metacarpophalangeal joint



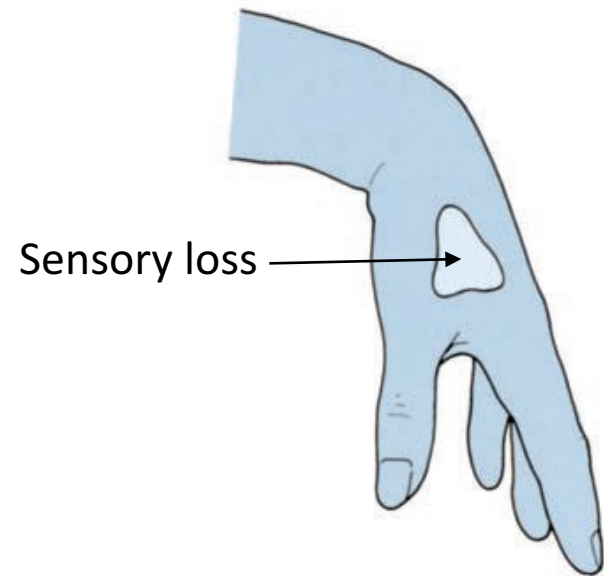
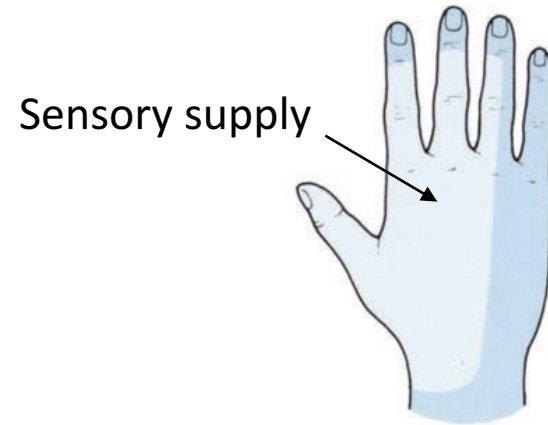
Radial Nerve

Applied Anatomy

Injury of the radial nerve

**Sensory loss –MINIMAL –
WHY??**

**Overlapping by the median
and ulnar nerves**



Radial Nerve

Applied Anatomy

Injury of the Deep Branch (Post. interosseous)

Causes:

- Fractures of the proximal end of the radius
- During dislocation of the radial head.
- the patient will experience weakness of finger extension.

“No wrist Drop” {Ref. snell p-539}

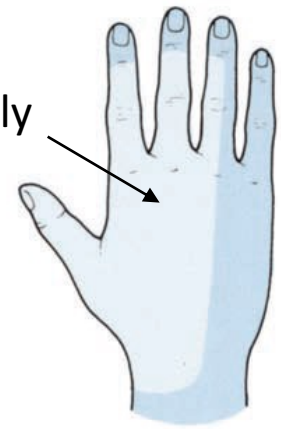
Why?

The nerve supply to the supinator and the ext. carpi radialis longus will be undamaged, and because the latter muscle is powerful, it will keep the wrist joint extended -----**No wrist Drop.**

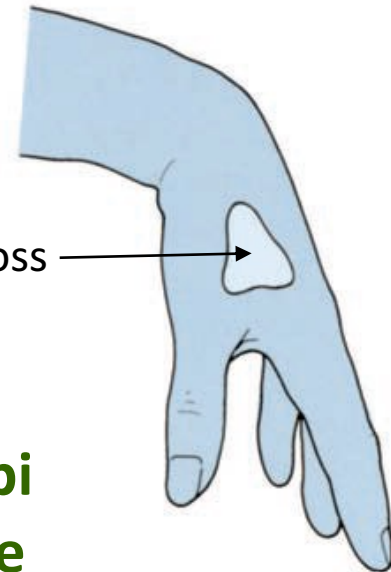
Sensory loss – Nothing

Overlapping by the median and ulnar nerves

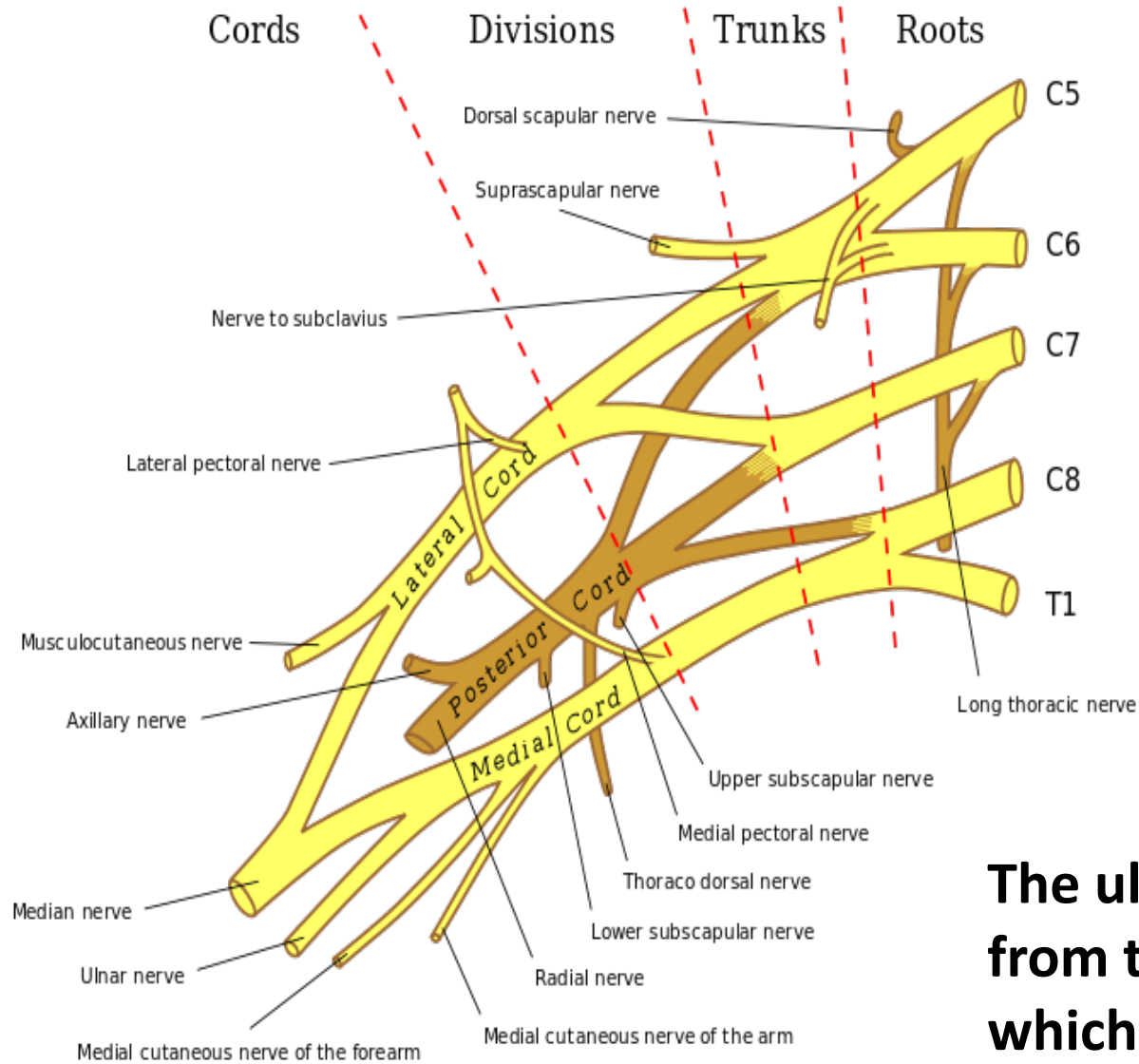
Sensory supply



Sensory loss



Ulnar Nerve



The ulnar nerve originates from the C8-T1 nerve roots which form the medial cord of the brachial plexus.

Ulnar Nerve

Origin:

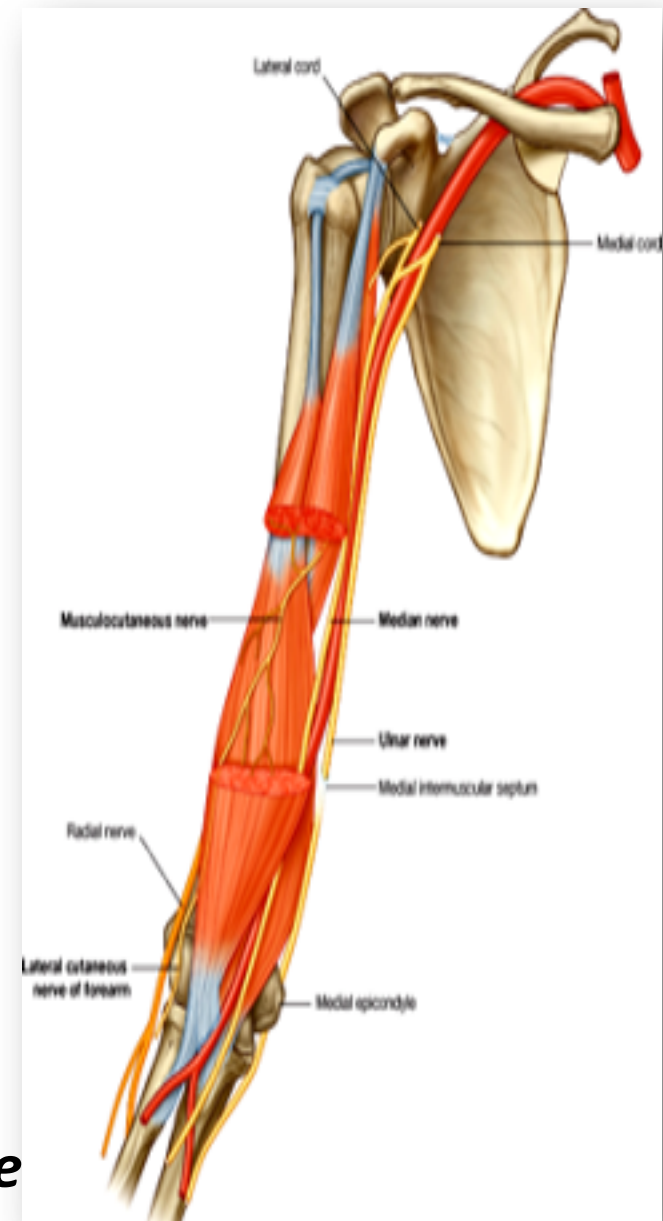
- *Begins in the axilla*
- *Continuation of the medial cord*

Supplies:

- *Some flexors muscles on ulnar side of the forearm*
- *Most of the intrinsic muscles of the hand*
- *Skin of the ulnar one and a half digits*

Course: In Arm

- *Descends along the medial side of the following arteries:*
 - *Axillary.*
 - *Brachial.*
- *Pierces the Medial Intermuscular Septum.*
- *Passes behind the Medial Epicondyle of the humerus at the elbow.*

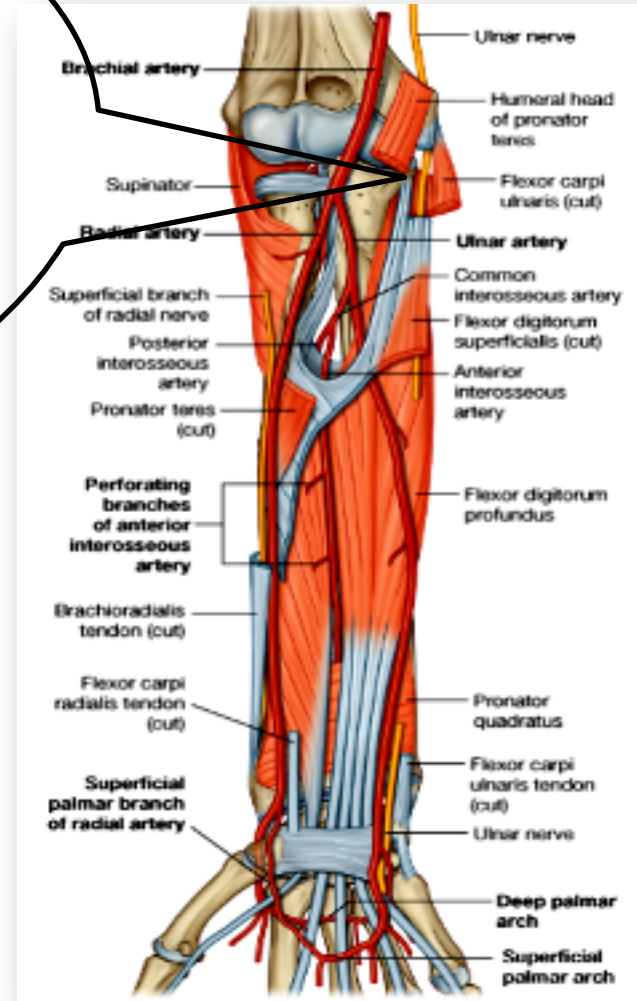


Ulnar Nerve

Course: In Forearm

Enters between the two heads of the Flexor Carpi Ulnaris muscle.

- Lies deep to the Flexor Carpi Ulnaris.
- It is medial to **Ulnar Artery**



Ulnar Nerve

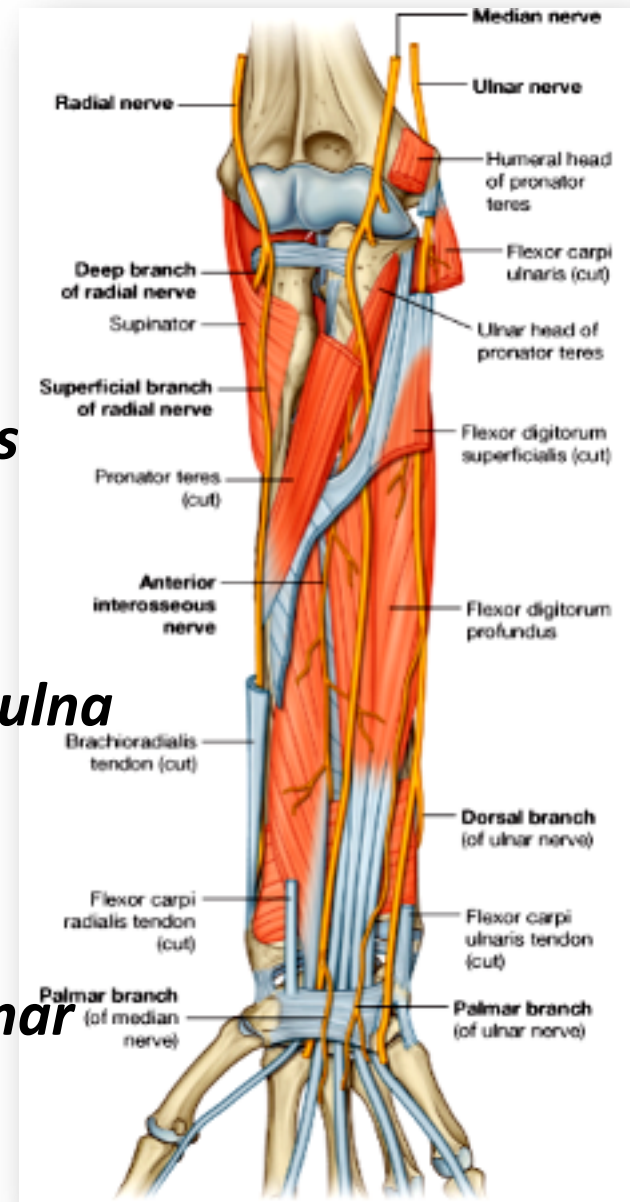
Branches: in the Forearm

Muscular to (1 & 1/2 muscles)

- 1. Flexor Carpi Ulnaris*
- 2. Medial 1/2 of Flexor Digitorum Profundus*

Articular to Elbow joint

- The ulnar nerve then travels alongside the ulna bone of the forearm into the wrist.*
- In the lower part of the forearm the ulnar nerve lies lateral to the FCU & medial to ulnar artery.*



Ulnar Nerve

Branches: in the Forearm

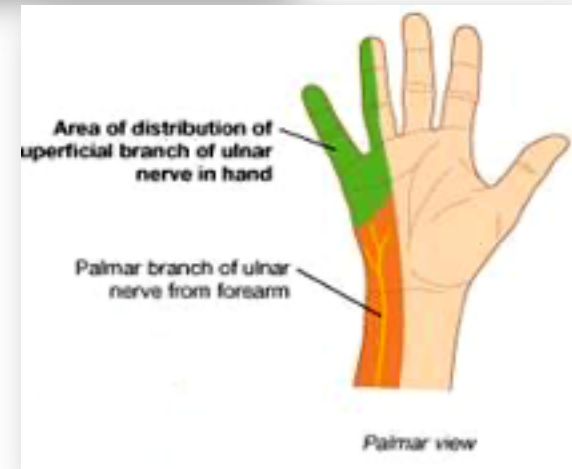
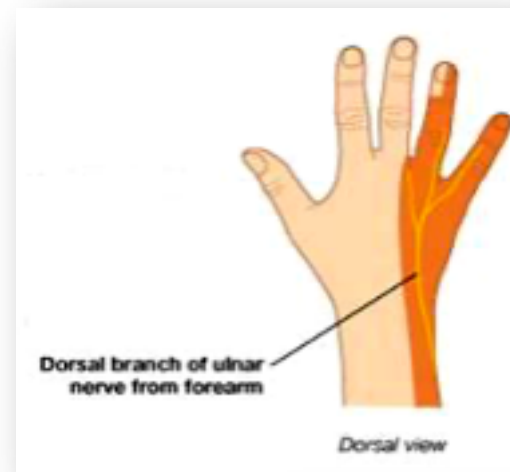
Cutaneous:

1. ***Dorsal (posterior) cutaneous:***

Supplies the skin over the back of Medial side of the hand & Medial 1+1/2 fingers

2. ***Palmar cutaneous:***

Supplies the skin over the Medial part of the palm.



Ulnar Nerve

The ulnar nerve enters the palm of the hand.

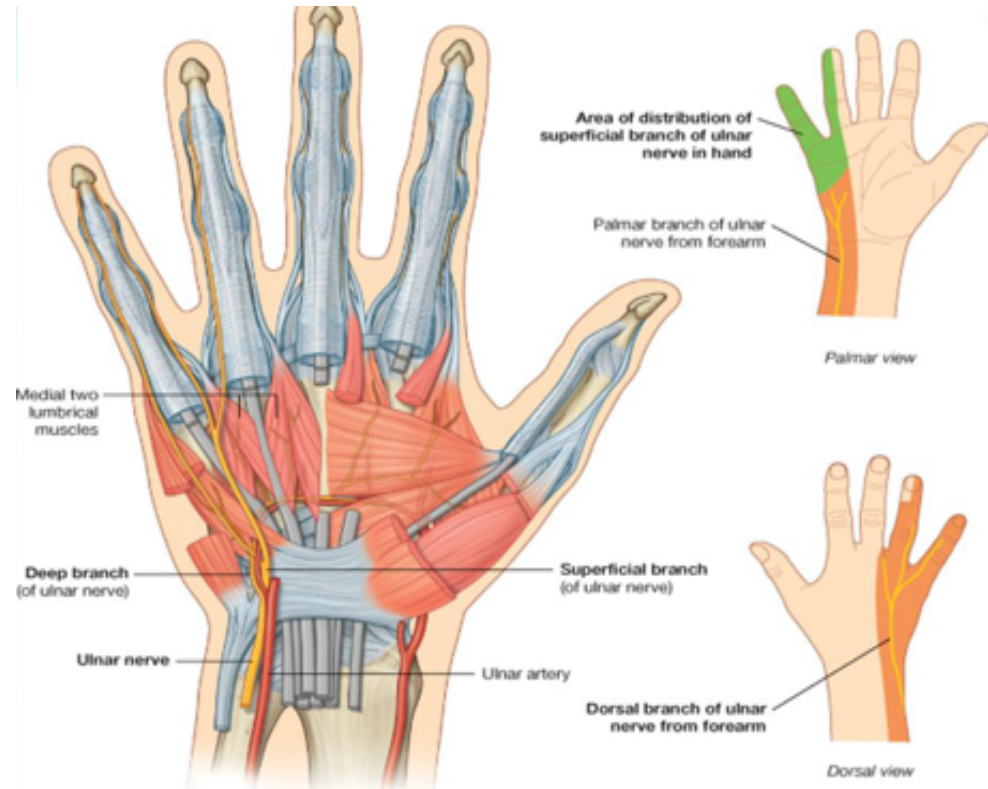
Course: At wrist

Passes:

- *Anterior to Flexor Retinaculum.*
- *Lateral to Pisiform bone.*
- *Medial to Ulnar artery.*

Divides into :

Superficial & Deep branches

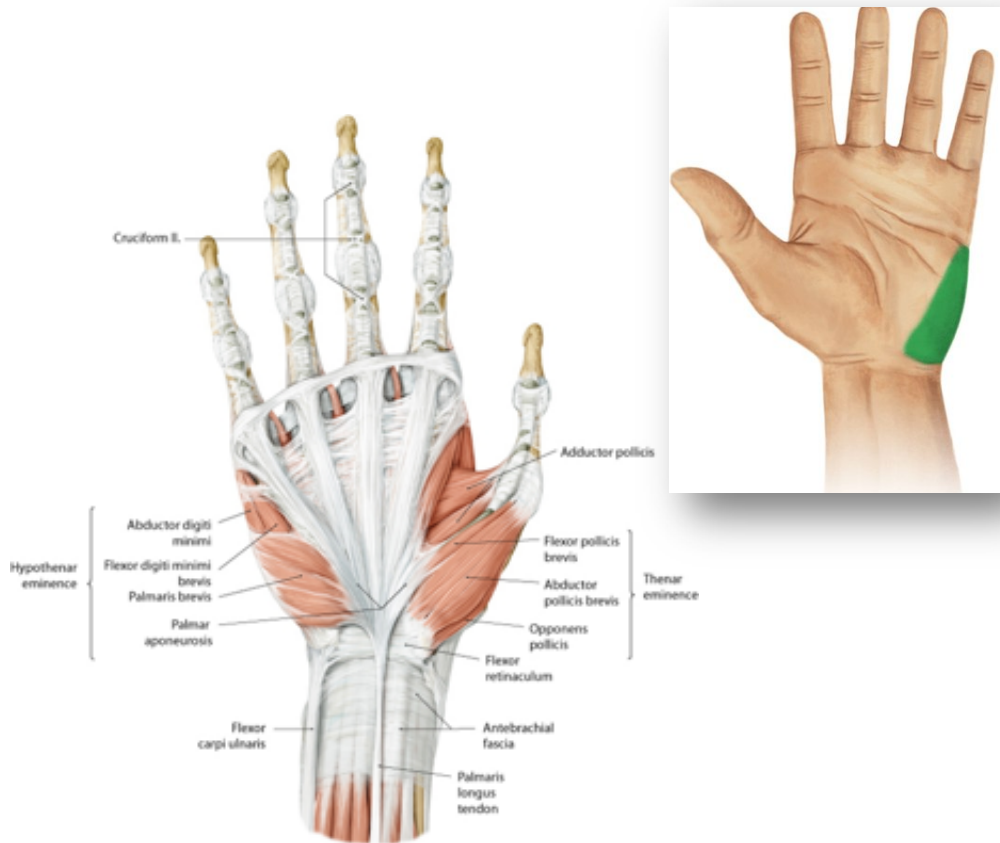
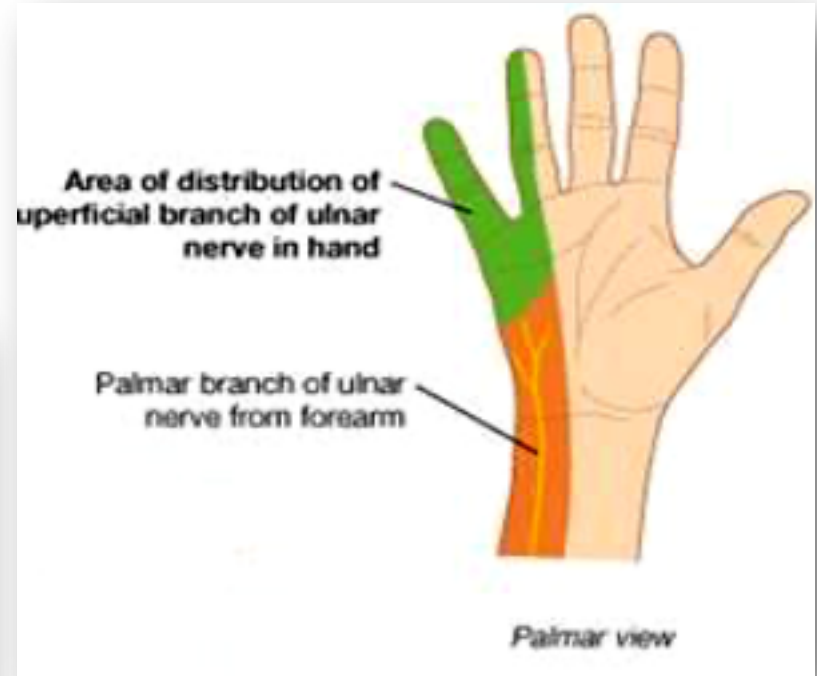


© Elsevier. Drake et al: Gray's Anatomy for Students - www.studentconsult.com

Ulnar Nerve

Terminal Branches: Superficial

Muscular to Palmaris Brevis.



Cutaneous:

Supplies the skin over the Palmar aspect of the medial 1+ ½ fingers (including nail beds).

Ulnar Nerve

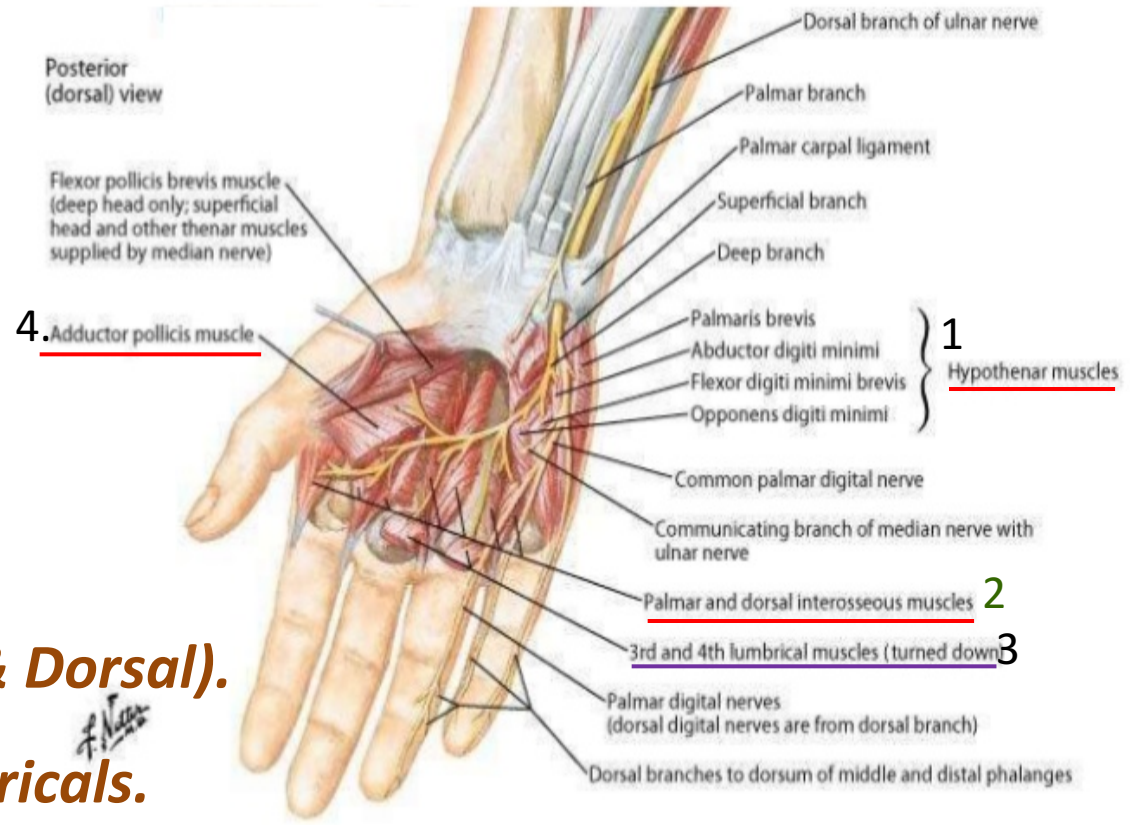
Terminal Branches:

Deep Branch

Muscular to:

1. *Hypothenar Eminence.*
2. *All Interossei (Palmar & Dorsal).*
3. *3rd & 4th (Radial) Lumbricals.*
4. *Adductor pollicis*
(ends by supplying it)

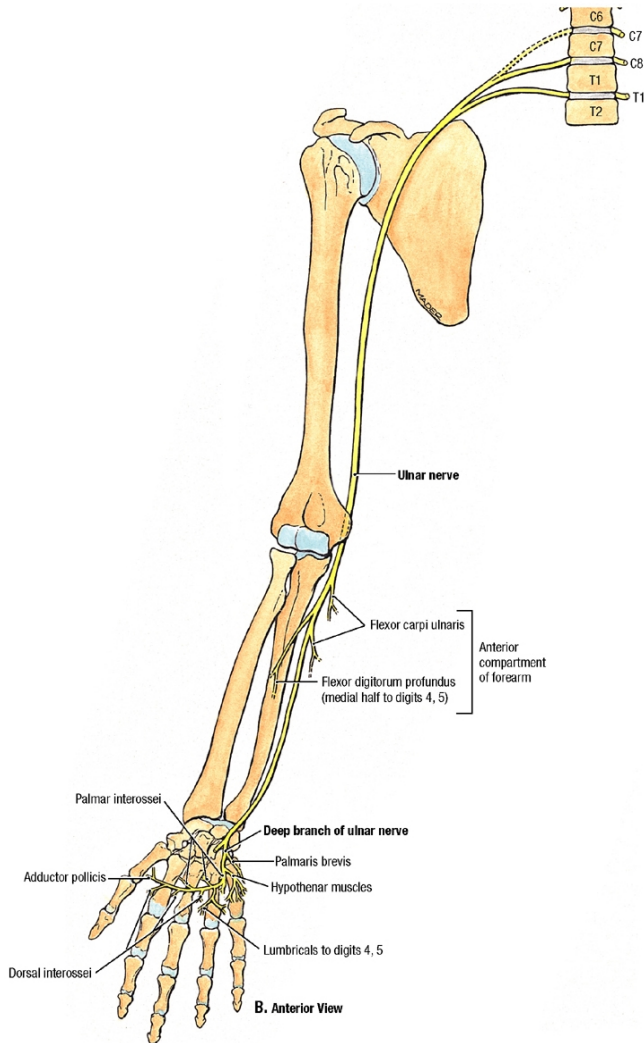
Articular to Carpal joints



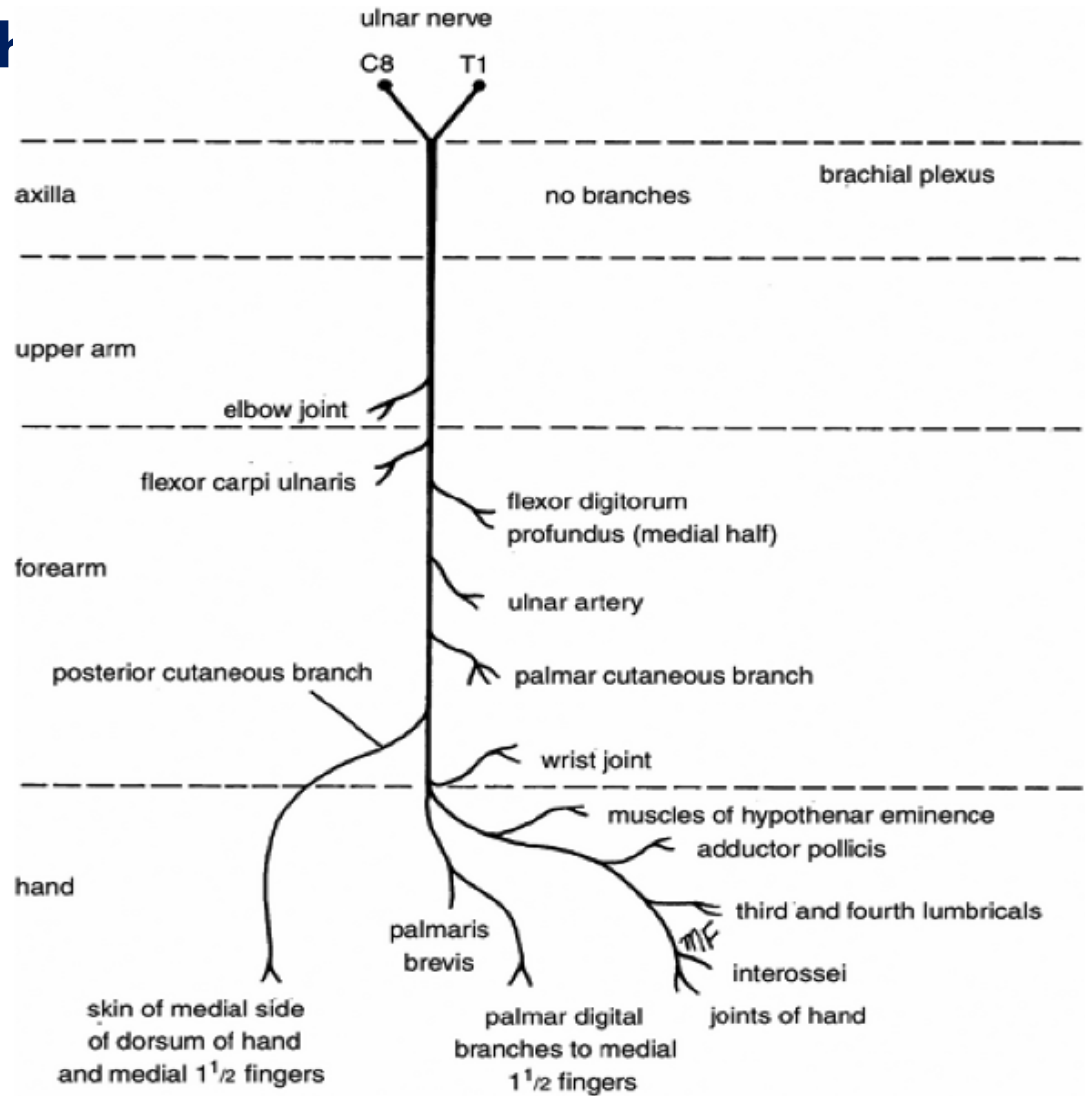
Copyright © 2011 Elsevier Inc. www.netterimages.com Netter's Atlas of Human Anatomy, 5e

Ulnar Nerve

Summary of main branch



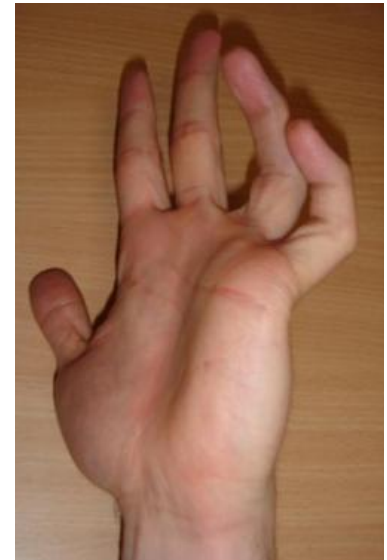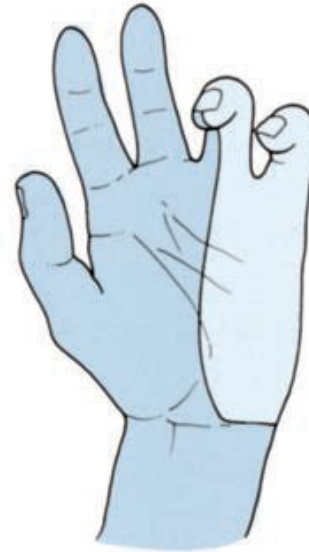
Copyright © 2009 Wolters Kluwer Health | Lippincott Williams & Wilkins



Ulnar Nerve

Applied Anatomy Most commonly injured

- Behind the elbow
- At wrist
- The classical sign of a low lesion “**CLAW HAND**”
 - Hyperextension of the MCP joints of ring and little fingers
 - Flexion of the IP joints



WHY?


- Paralysis of interossei & lumbricals
- Unopposed actions of extensors & FDP

Ulnar Nerve

Applied Anatomy

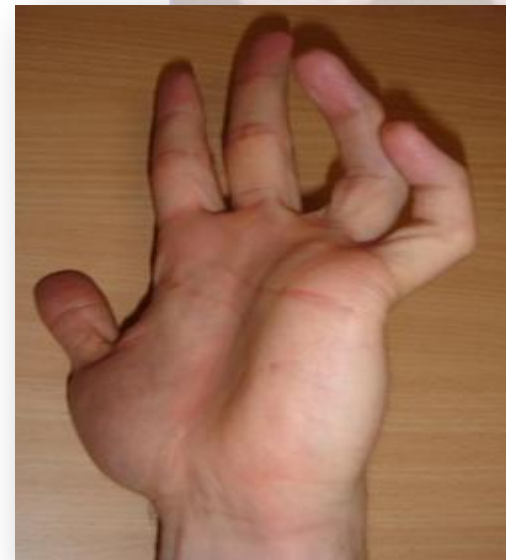Behind the elbow

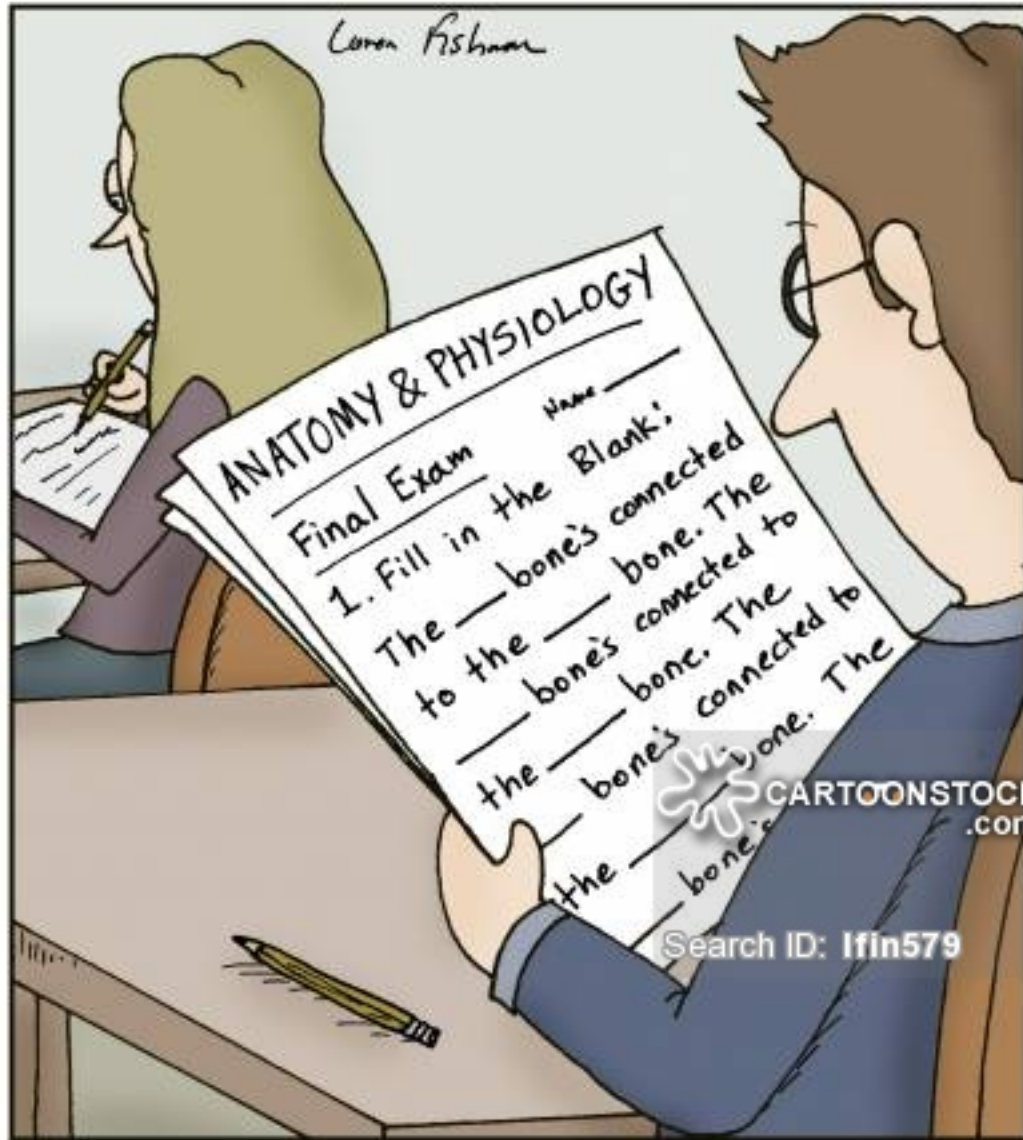
- *Atrophy of Ulnar side of forearm.*
- *Flexion of the wrist with Abduction.*
- *Wasting of Hypothenar Eminence*
- *Claw hand.*



At the elbow

- *Claw Hand.*
- *Wasting of Hypothenar Eminence.*





Thanks for Listening