

# *ARTERIES AND VEINS OF THE LOWER LIMB*

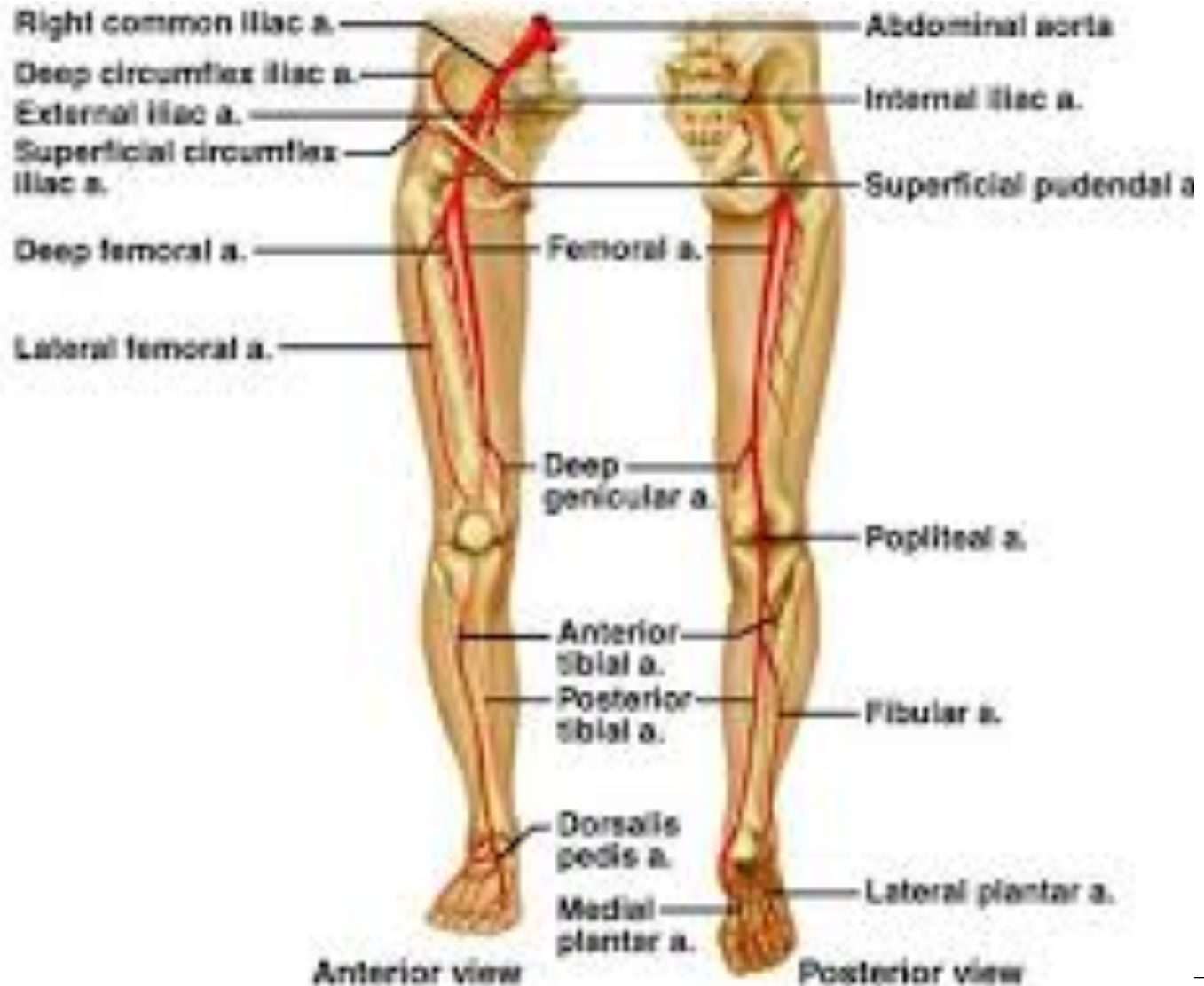*Dr. JAMILA ELMEDANY*

*Dr. ESSAM SALAMA*

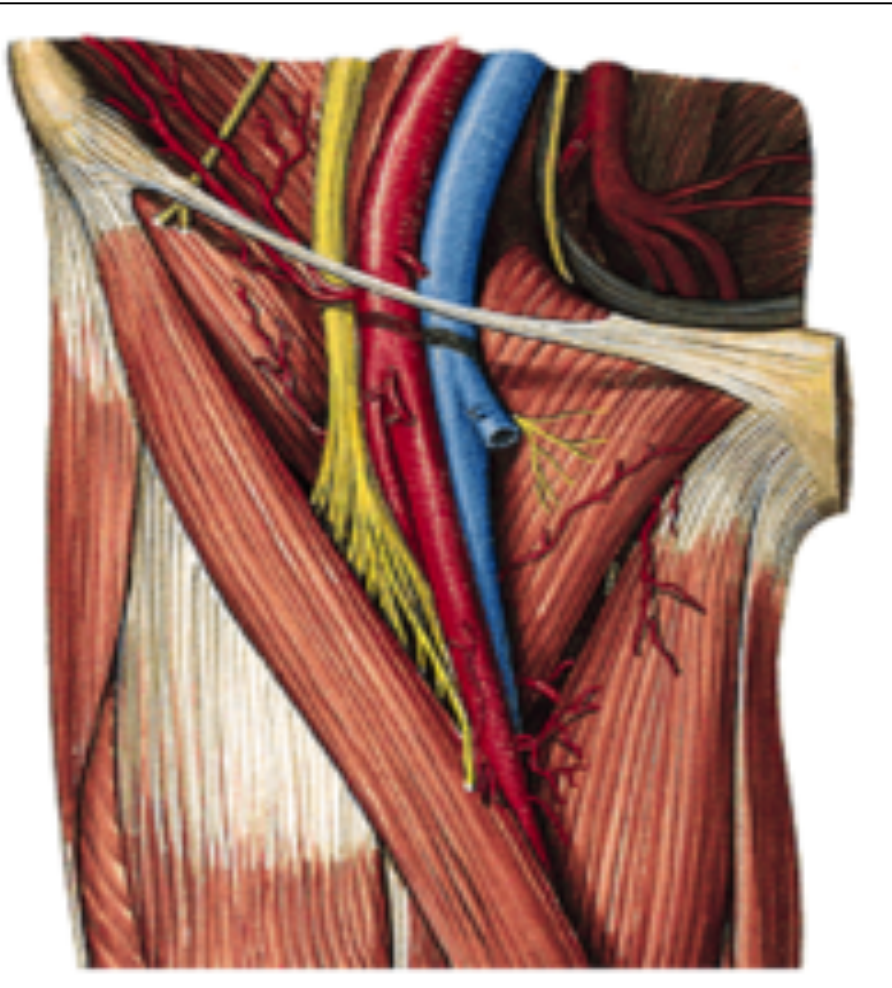
# Objectives

- **At the end of the lecture, students should be able to:**
- **List the main arteries of the lower limb.**
- **Describe their origin, course distribution & branches.**
- **List the main arterial anastomosis.**
- **List the sites where you feel the arterial pulse.**
- **Differentiate the veins of LL into superficial & deep**
- **Describe their origin, course & termination and tributaries**

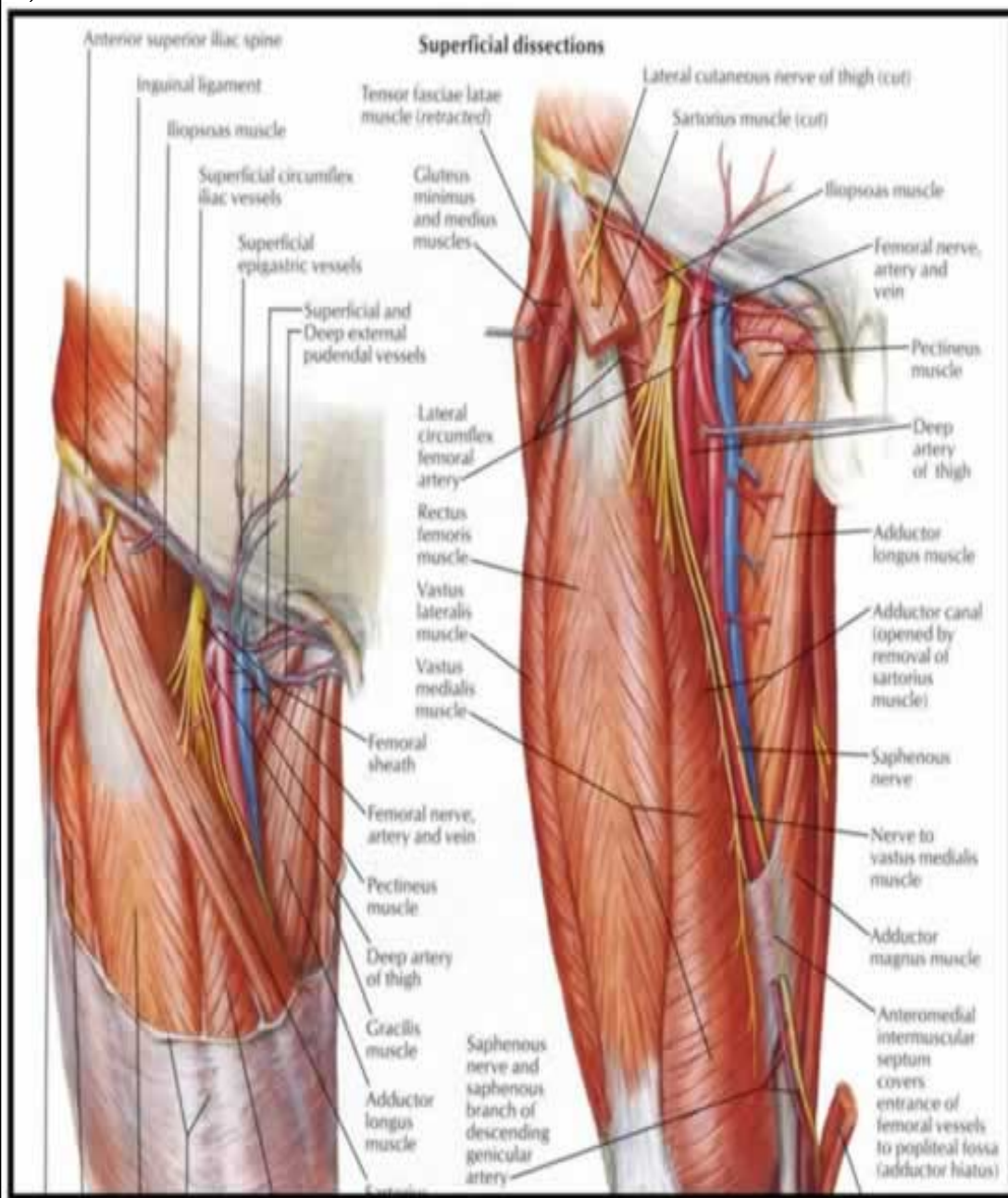
# ***ARTERIES OF LOWER LIMB***



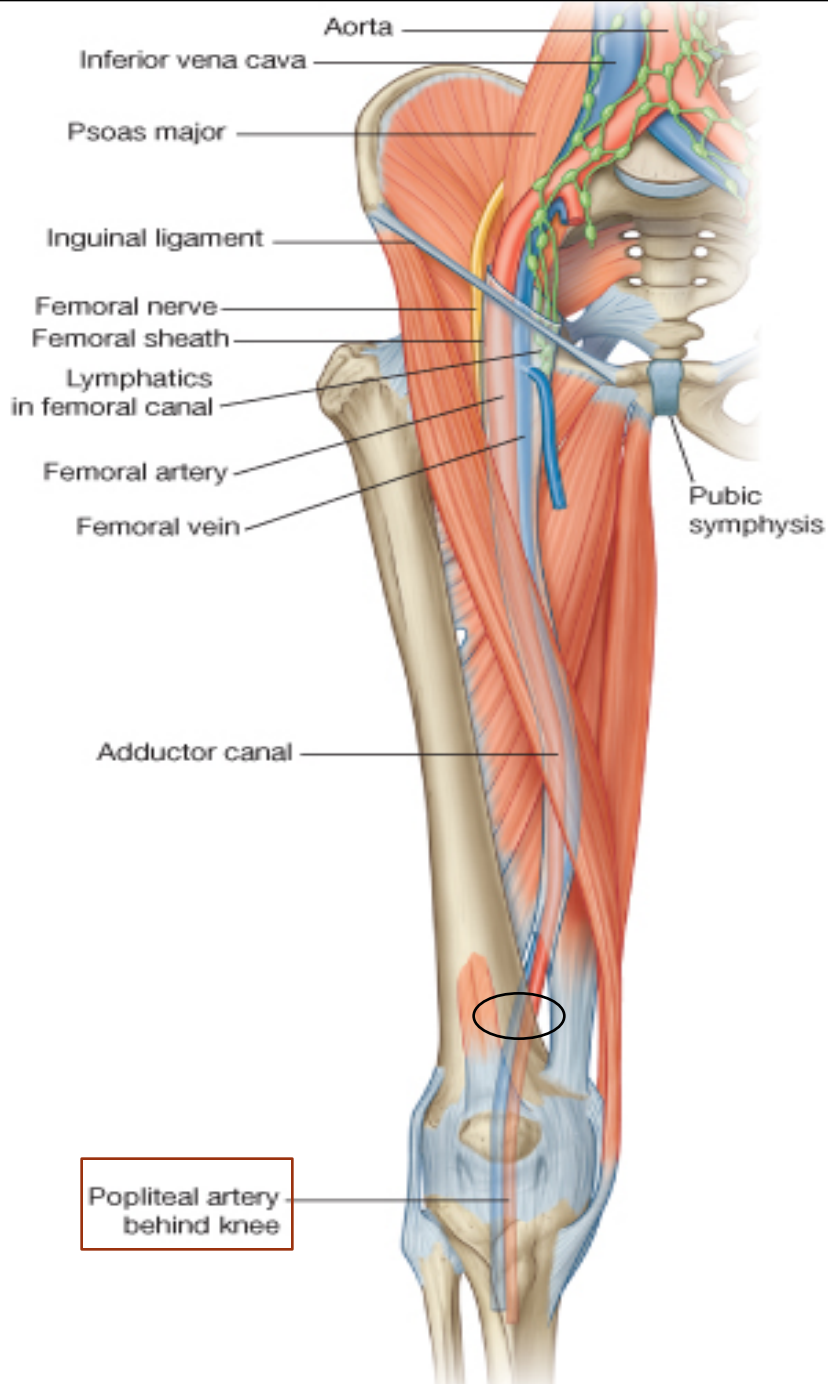
# ***FEMORAL ARTERY***



- *Is the main arterial supply to the lower limb.*
- *It is the continuation of the **External Iliac artery**.*
- **BEGINNING:**
- *It enters the thigh behind the inguinal ligament at the **Mid Inguinal Point** (midway between the anterior superior iliac spine and the symphysis pubis).*

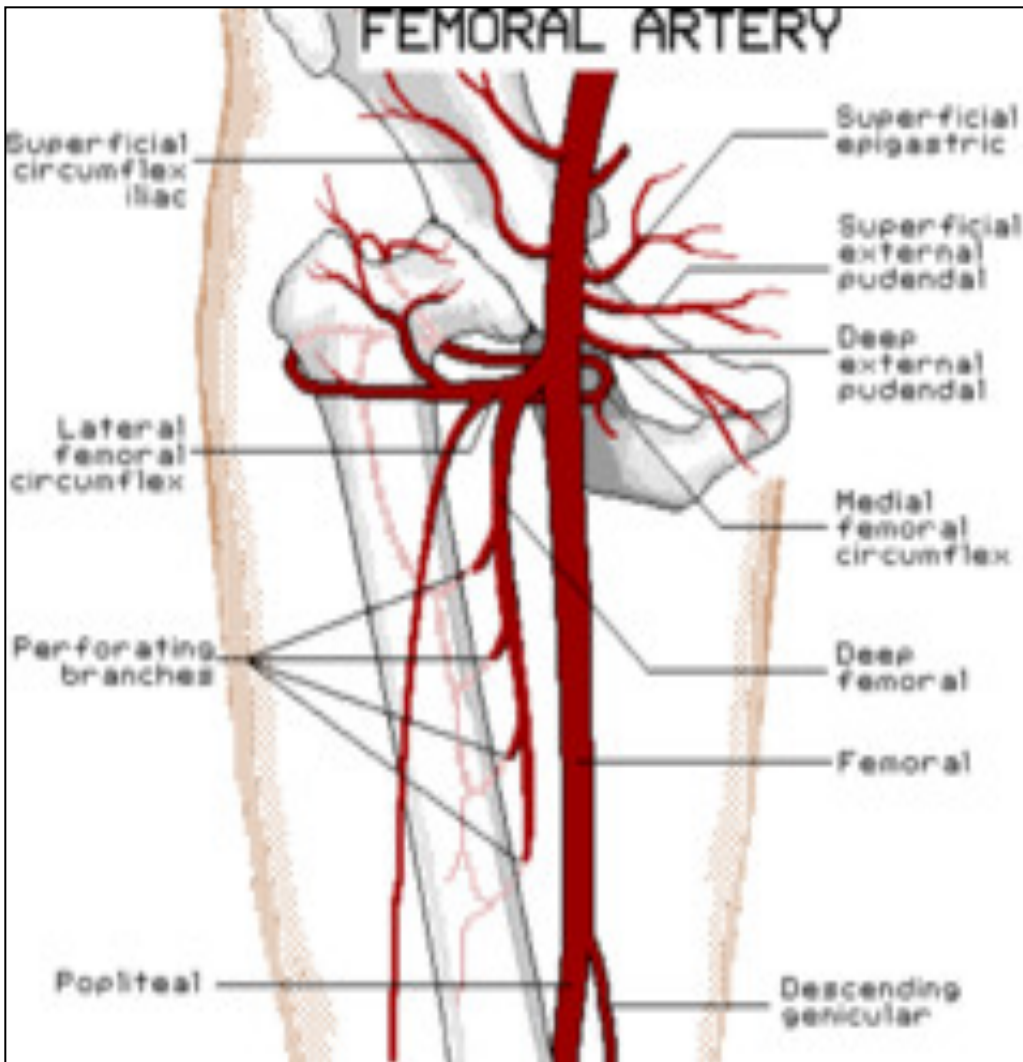


- **Relations:**
- ***In the femoral triangle the artery is superficial covered only by***
- ***Skin & fascia.***
- **Posterior:**
- ***Hip joint , separated from it***
- ***by Psoas muscle***
- **Medial:**
- ***Femoral vein.***
- **Lateral :**
- ***Femoral nerve and its***



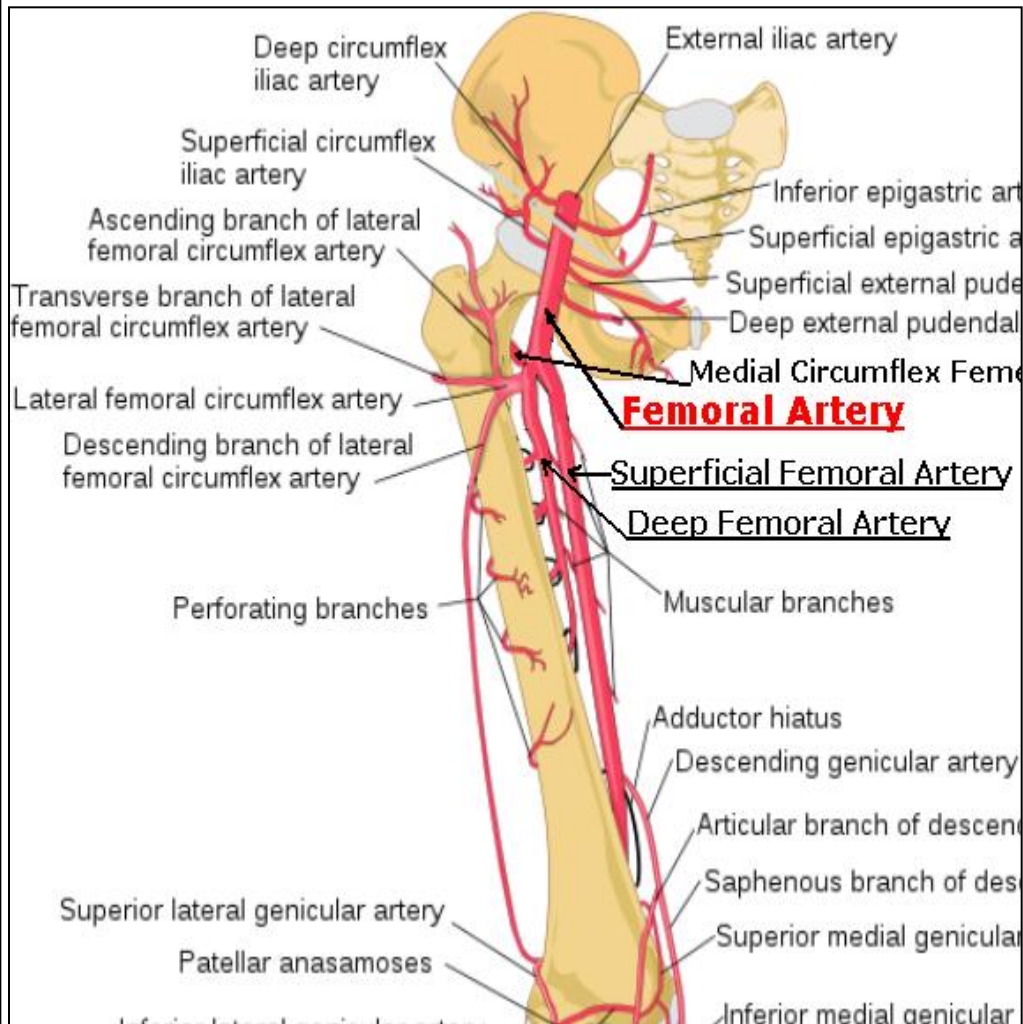
- **Termination:**
- **The artery terminates by passing through the Adductor Canal (deep to sartorius)**
- **It exits the canal by passing through the Adductor Hiatus and becomes the **Popliteal artery**.**

# ***Branches***



- ***The femoral artery supplies: Lower abdominal wall, Thigh & External Genitalia through the following branches:***
  - ***1. Superficial Epigastric.***
  - ***2. Superficial Circumflex Iliac.***
  - ***3. Superficial External Pudendal.***
  - ***4. Deep External Pudendal.***
  - ***5. Profunda Femoris (Deep Artery of Thigh)***

# ***Profunda Femoris Artery***



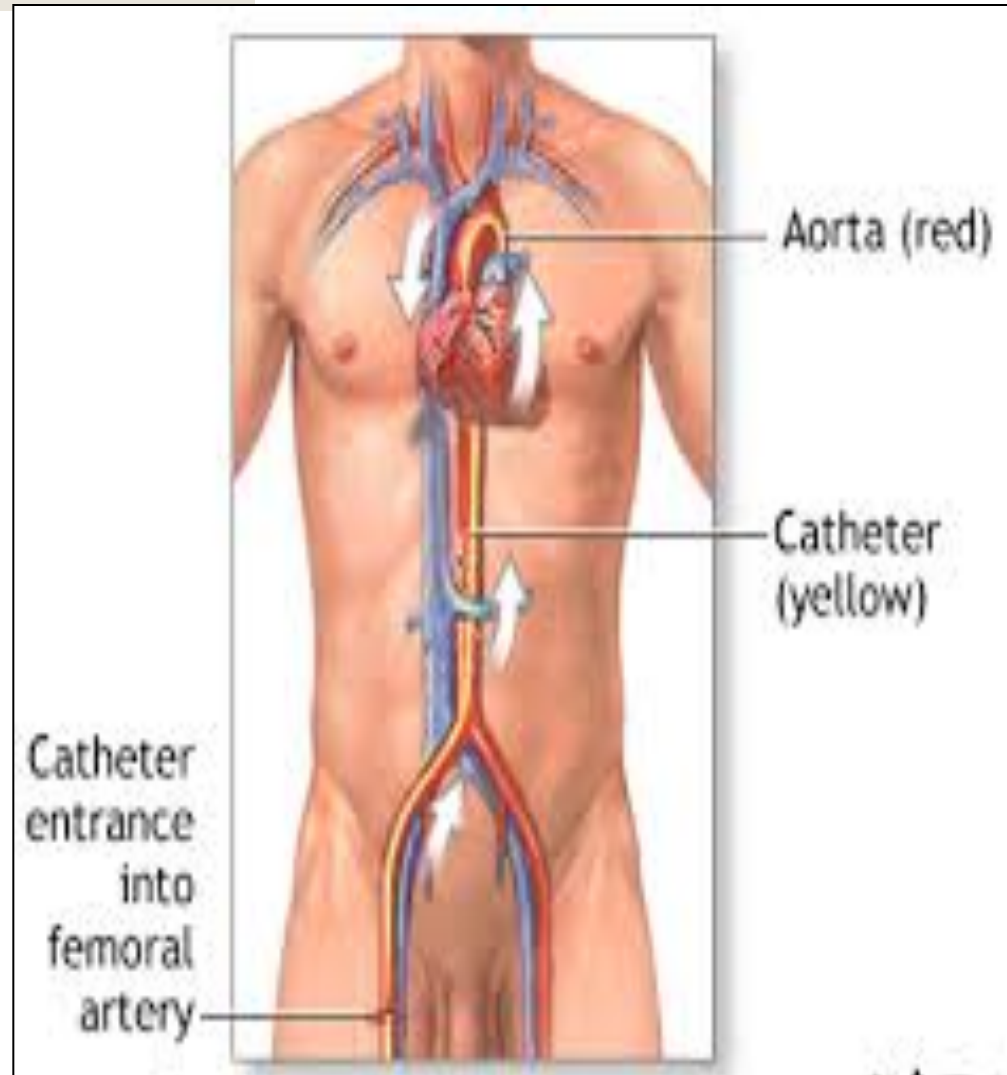
- ***It is the main arterial supply to the thigh.***
- ***It arises from the lateral side of the femoral artery &***
- ***Passes medially behind the femoral vessels.***
- ***It gives:***
- ***Medial & lateral circumflex femoral arteries.***
- ***Three perforating arteries.***
- ***It ends by becoming the 4<sup>th</sup> perforating artery.***



# Cannulation of FA

**Because of the superficial position of the femoral artery, it is used for left cardiac angiography.**

**A long catheter is inserted percutaneously into the artery and passed up the external iliac artery, common iliac artery, aorta to the left ventricle.**

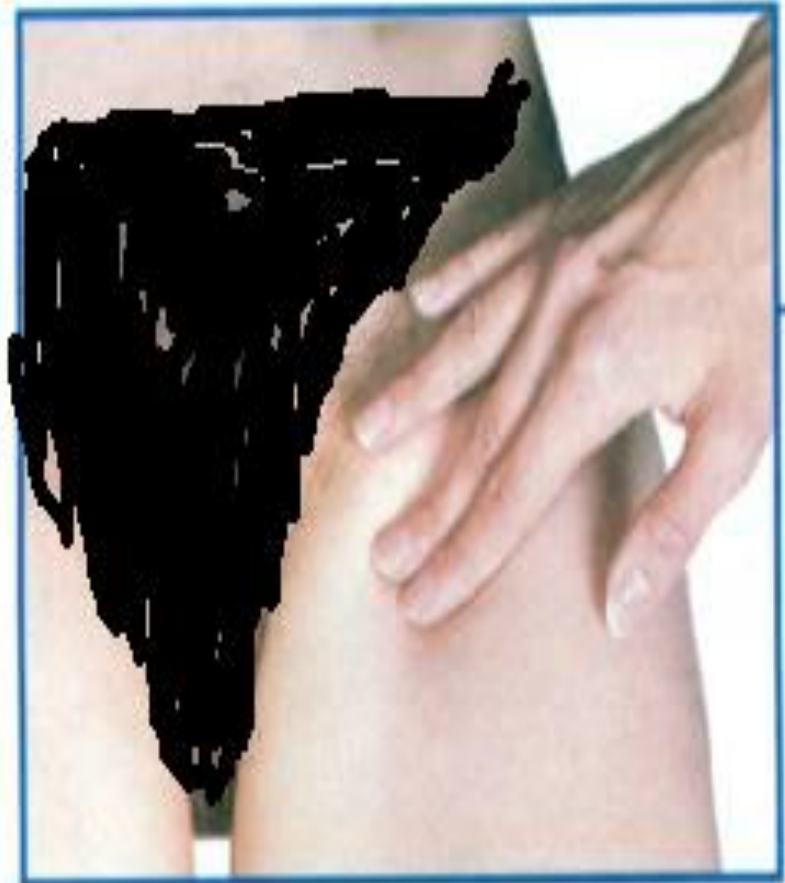

# FEMORAL PULSE

It can be palpated just inferior to the *Midinguinal* point.

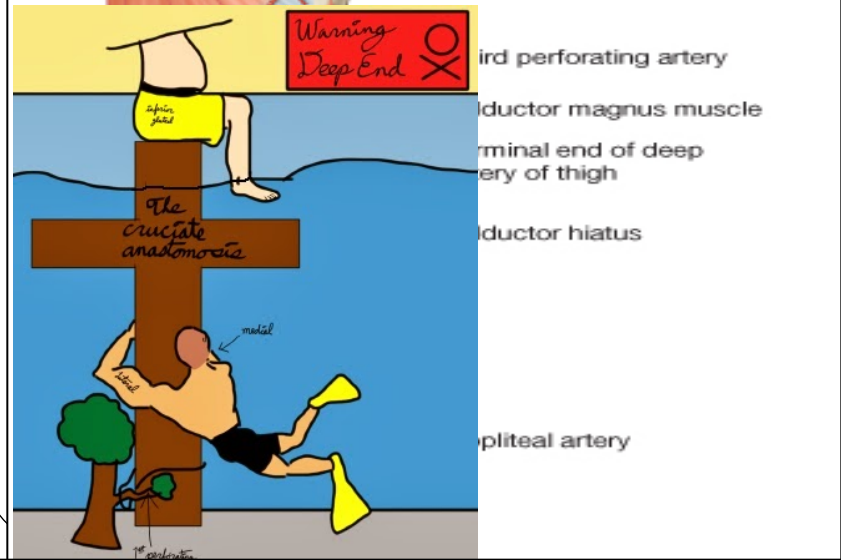
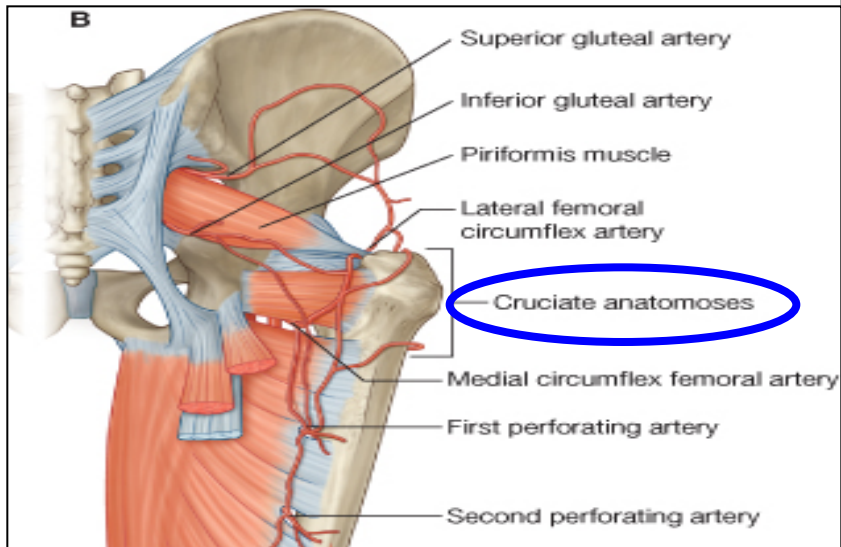
**How to Stop bleeding from the femoral artery?**

By pressing the artery directly posterior against the superior pubic ramus and the femoral head.



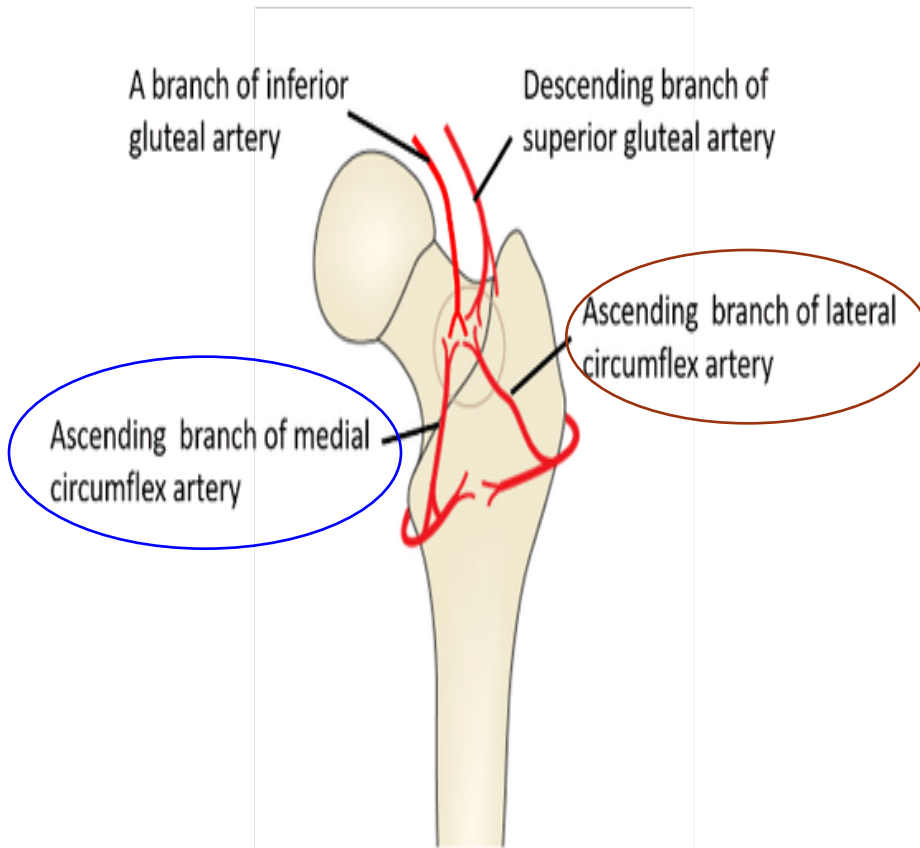
Femoral pulse

# ARTERIAL ANASTOMOSIS IN THE II



- **CRUCIATE ANASTOMOSIS:**
- **At the gluteal region**
- ***It Provides blood supply to the lower limb in case of ligation of the femoral artery.***
- ***It lies at the level of the lesser trochanter.***
- ***It is formed by the union of***
- ***Medial & Lateral circumflex femoral arteries + the Inferior gluteal artery + the First perforating artery.***

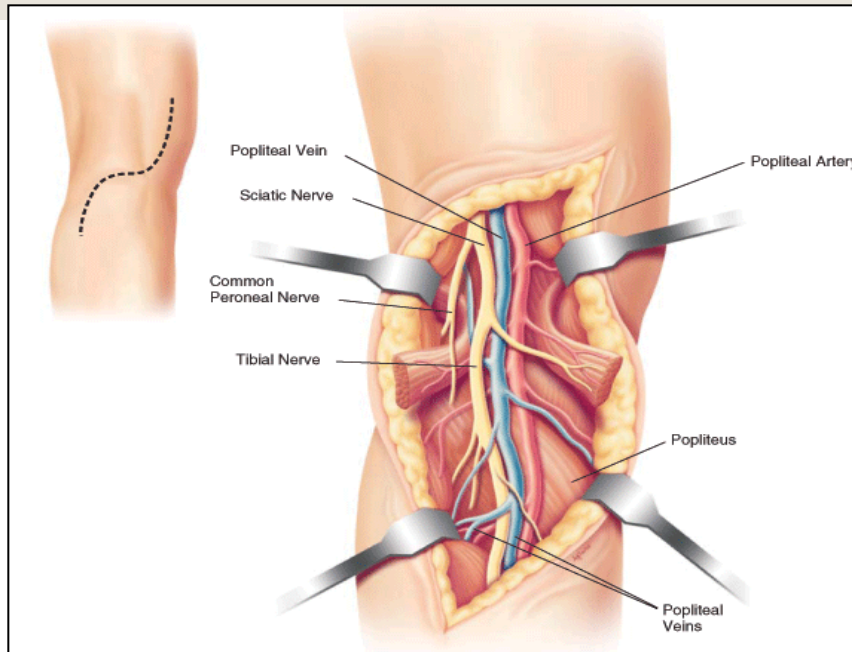
## Trochanteric Anastomosis



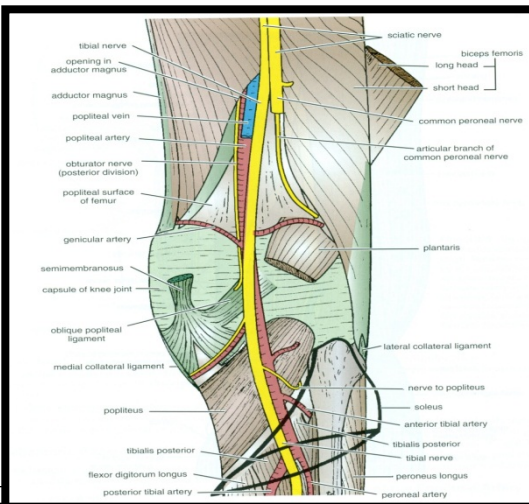
**Its main function is to supply the head & neck of femur.**

**The **Cruciate & Trochanteric** anastomosis provide a connection between the internal iliac & femoral arteries**

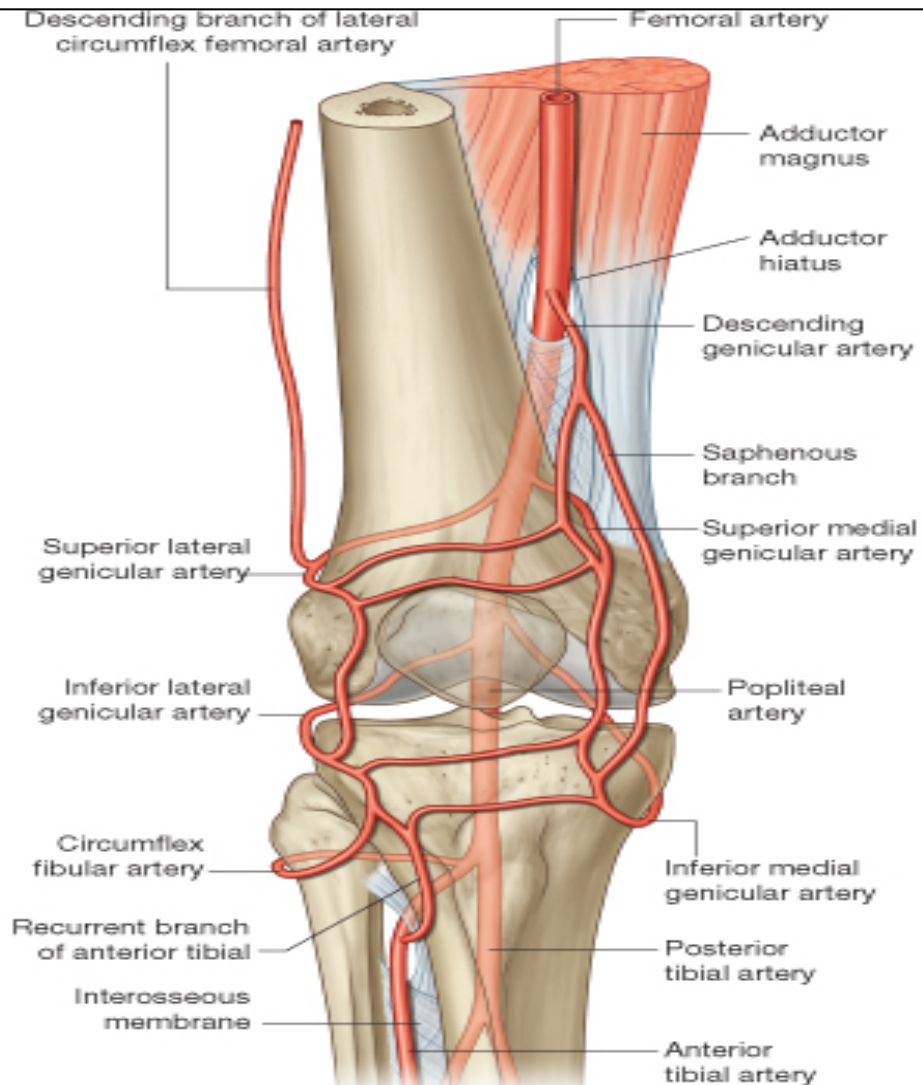
# POPLITEAL ARTERY



- ***The continuation of the femoral artery.***
- ***It is the deepest structure in the Popliteal Fossa (posterior to the Popliteal Vein & Tibial Nerve), it runs close to the capsule of the knee joint.***
- ***It Ends at the lower border of popliteus muscle by dividing into Anterior and Posterior Tibial Arteries.***

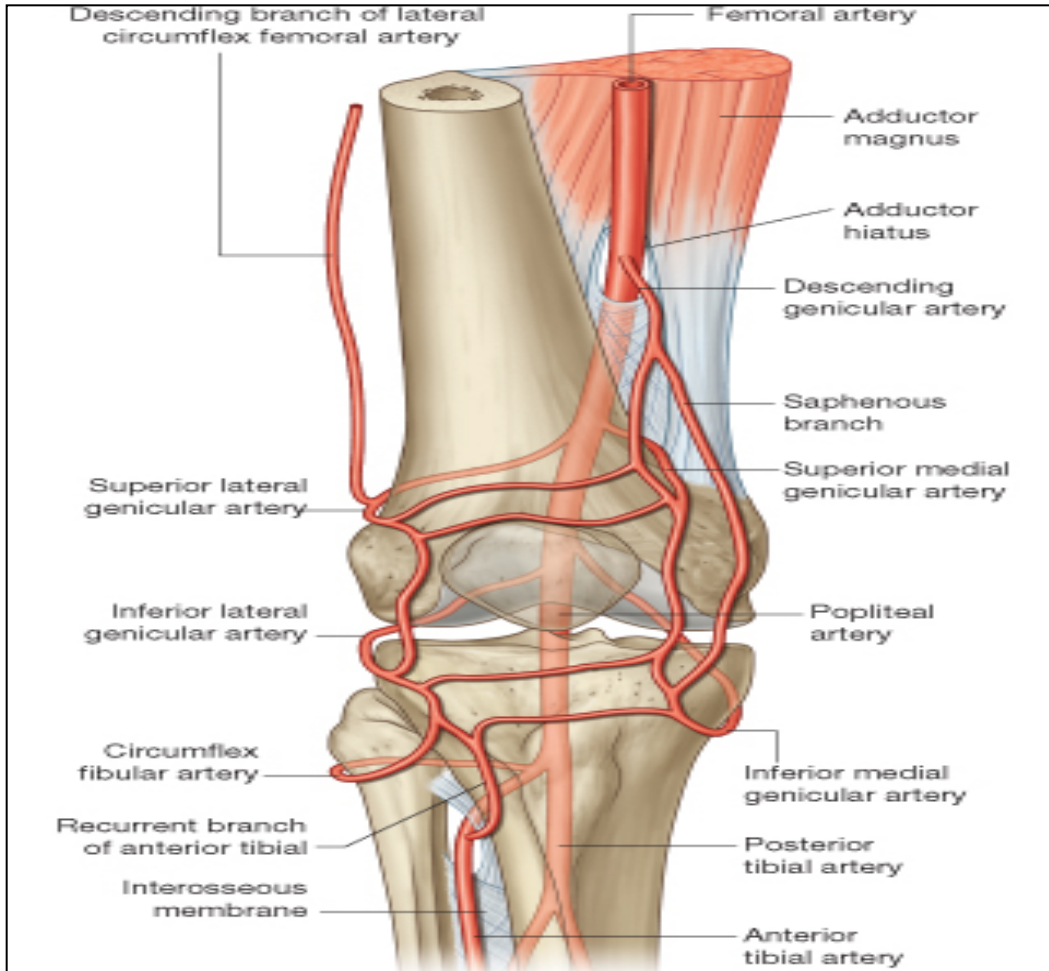


# ***Branches of Popliteal Artery***



- **Muscular**
- **Five *Genicular branches* to the articular capsule and ligaments of the knee joint**
-

# ***Genicular Anastomosis***



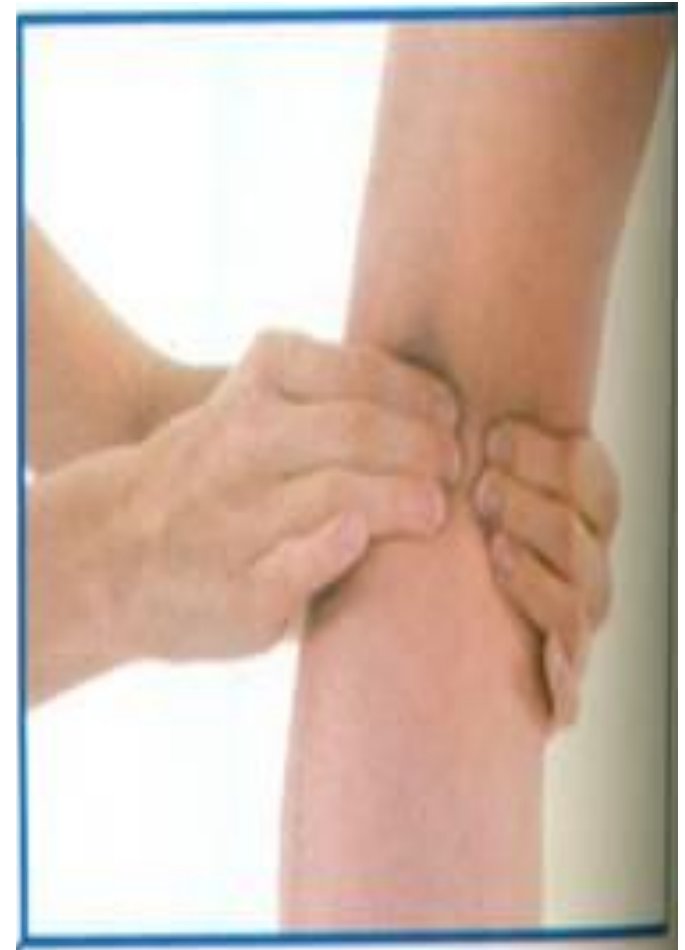***It is an important anastomosis around the knee. It compensates for the narrowing of the Popliteal artery during prolonged flexion of the knee.***

***Formed from the genicular branches of the popliteal artery.***

# Popliteal Pulse

**Because of the deep position of the artery, its pulsations are best felt in the inferior part of the popliteal fossa ( here the artery is related to the tibia).**

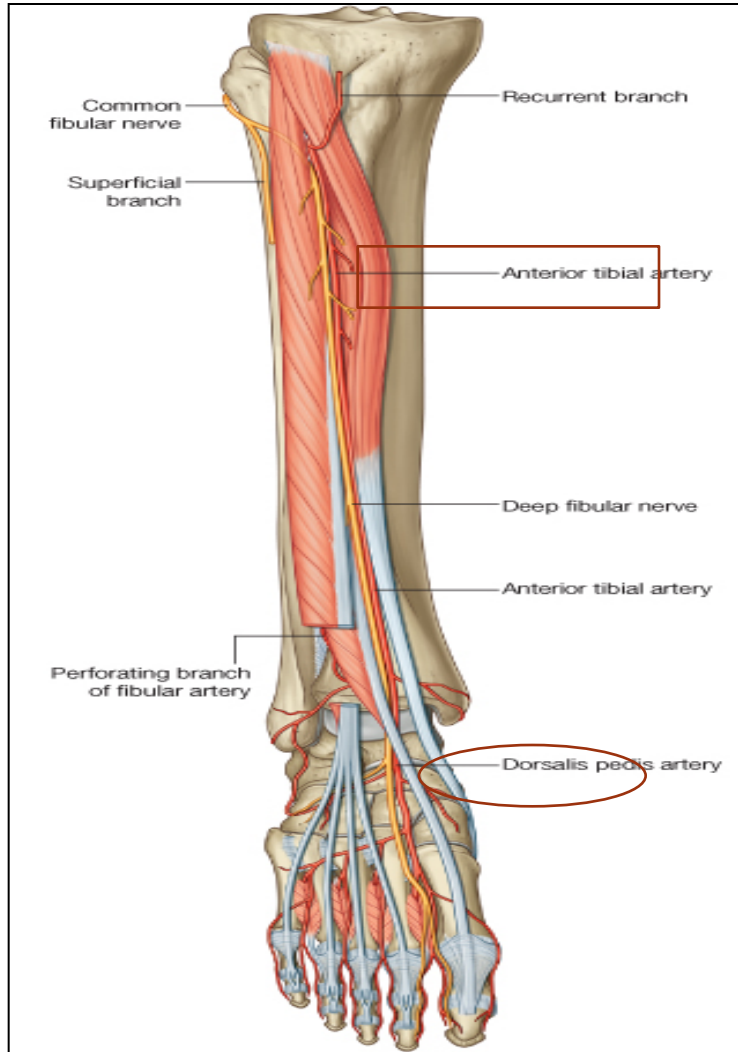
**Weakening or loss of the popliteal pulse is a sign of femoral artery obstruction.**



Popliteal pulse

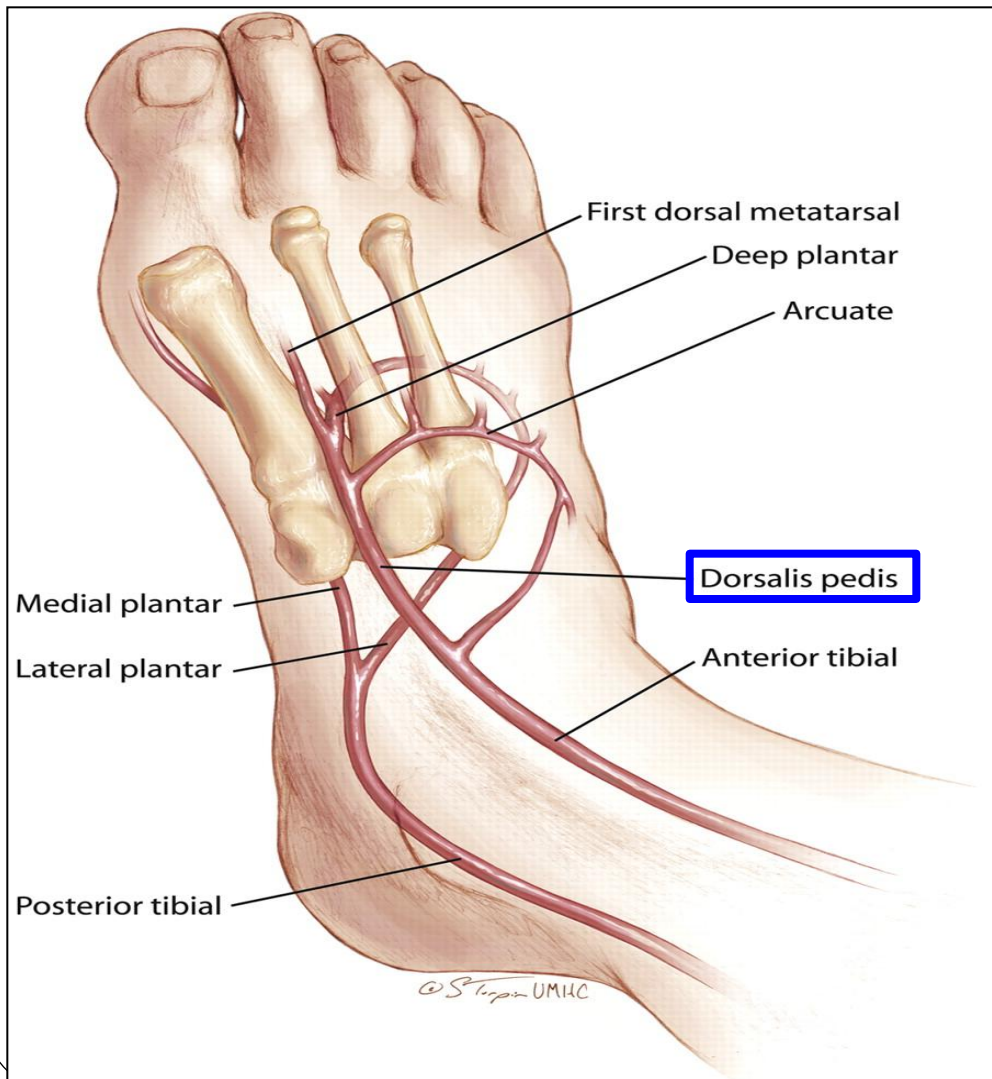


# ANTERIOR TIBIAL ARTERY



- *It is the smaller terminal branch of the popliteal artery.*
- *It enters the anterior compartment of the leg in company with the Deep Peroneal nerve.*
- *It supplies structures in the **Anterior Compartment of the Leg & Dorsum of foot.***
- ***It ends** at the ankle joint midway between the malleoli where it becomes the **Dorsalis Pedis** artery (dorsal artery of the foot).*

# ***DORSALIS PEDIS ARTERY***



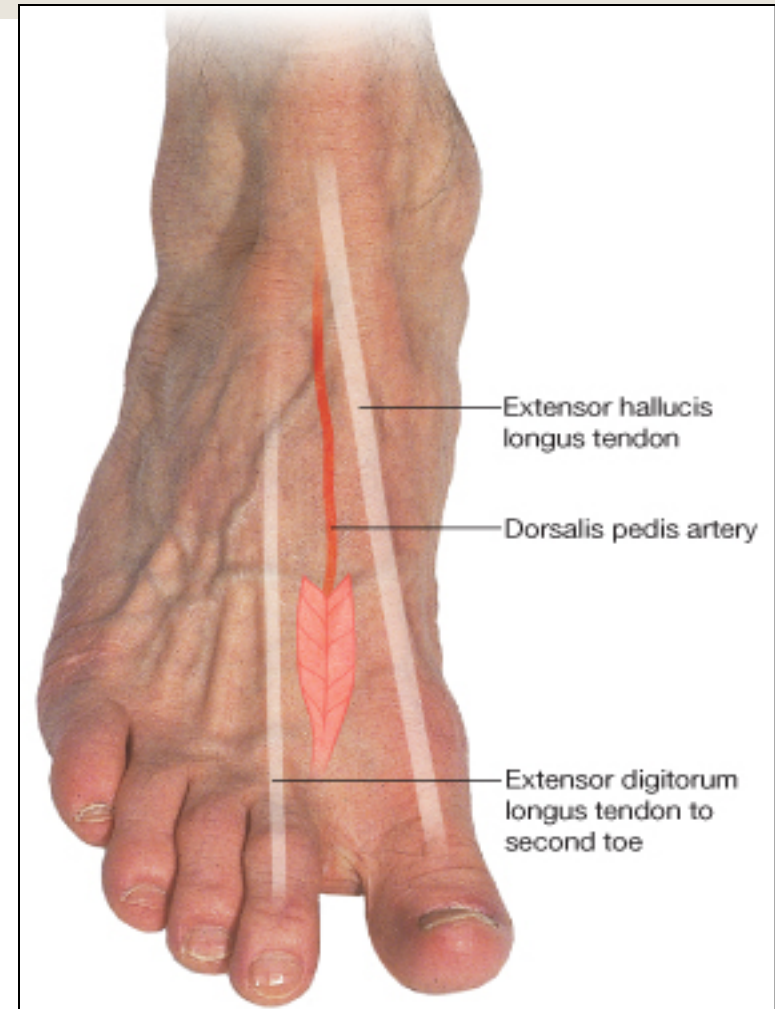
- ***It is the main source of blood supply to the toes.***
- ***Begins in front of ankle joint as the direct continuation of the **Anterior Tibial artery**.***
- ***It is superficial in position.***
- ***It passes to the 1<sup>st</sup> interosseous space where it divides into a deep plantar artery (to the sole to join the plantar arch) and the first dorsal metatarsal artery.***

# DP Pulse

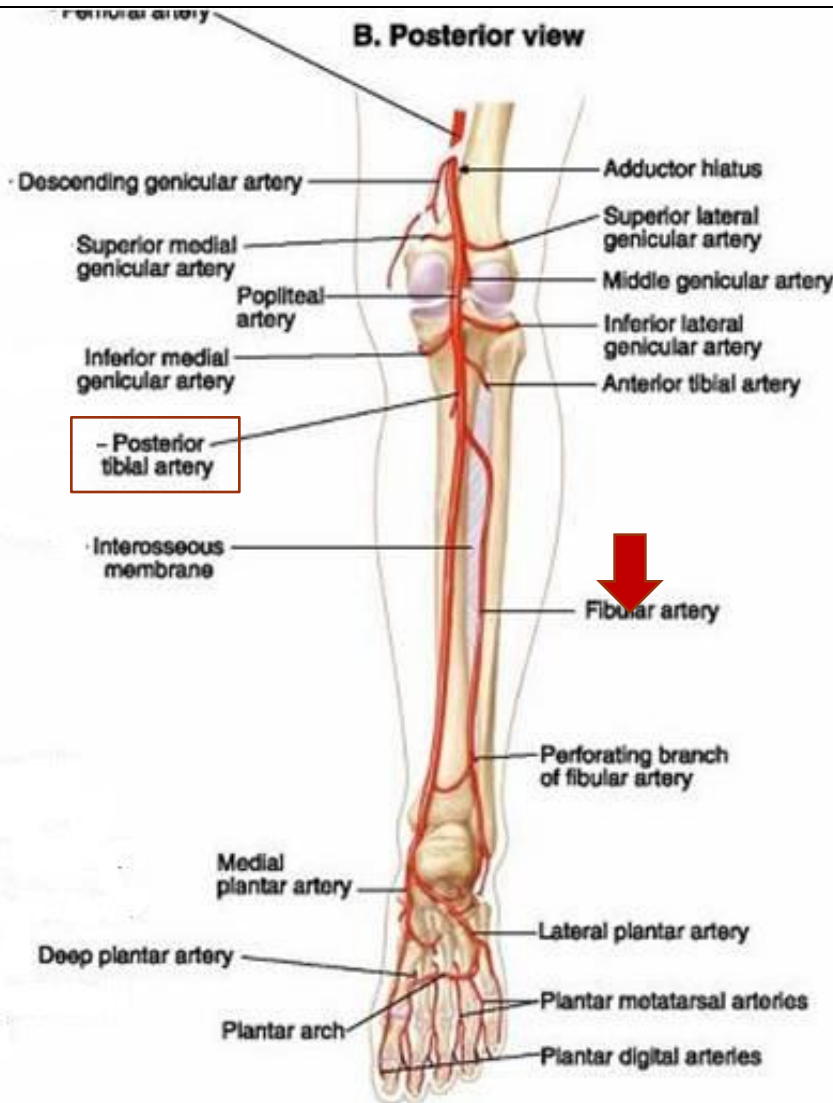
*It is easy to be felt being subcutaneous, over the tarsal bones between the tendons of Extensor hallucis longus and Extensor digitorum longus*

*Some people have congenitally non palpable DP pulse, the anomaly is usually bilateral.*

*A diminished or absent dorsalis pedis pulse usually suggests vascular insufficiency resulting from arterial disease.*



# POSTERIOR TIBIAL ARTERY



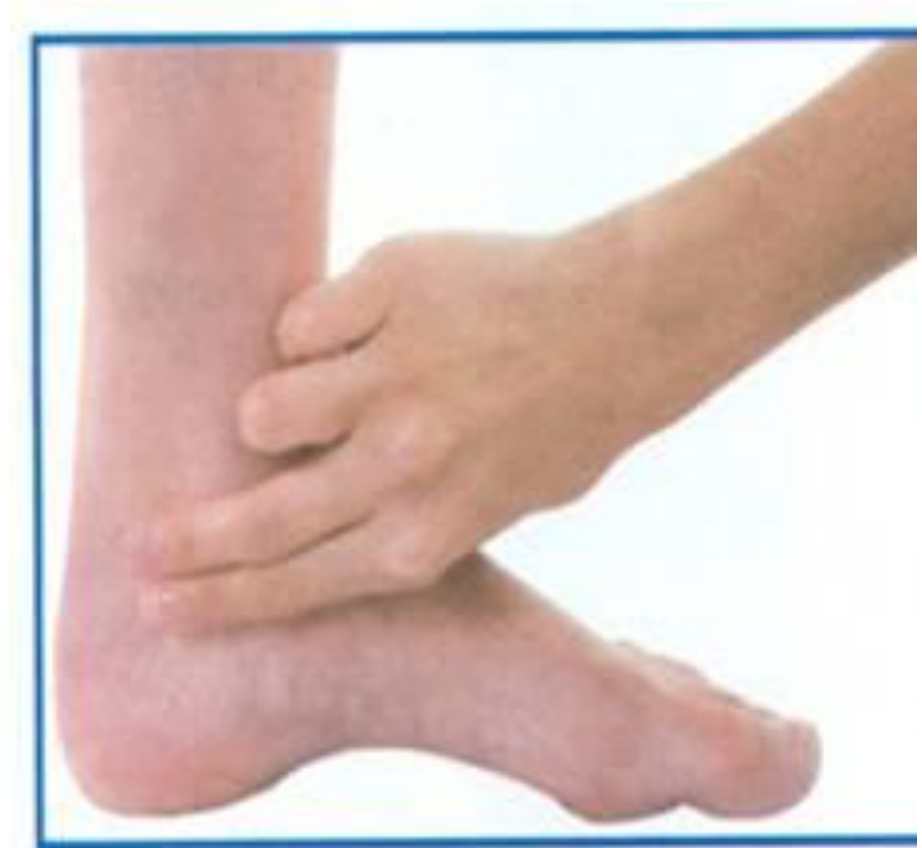- It is the larger terminal branch of the popliteal artery and provides the main blood supply to the **Posterior compartment of the Leg & Sole of the Foot**.
- Its lower part is covered by skin & fascia only.
- It **Terminates** by dividing into:
- **Medial & Lateral plantar arteries**.
- **Branches:**
- 1. **Nutrient artery to the tibia** (the largest nutrient artery of the body).
- 2. **Calcaneal arteries:** supply the Heel.
- 3. **Peroneal (Fibular) artery:**
- The largest and most important branch.
- It supplies a nutrient artery to the fibula & Muscular branches to the muscles of the lateral and posterior compartments of the leg..

# POSTERIOR TIBIAL PULSE

***Taken Postero inferior to the medial malleolus (in the groove between the malleolus and the heel)***

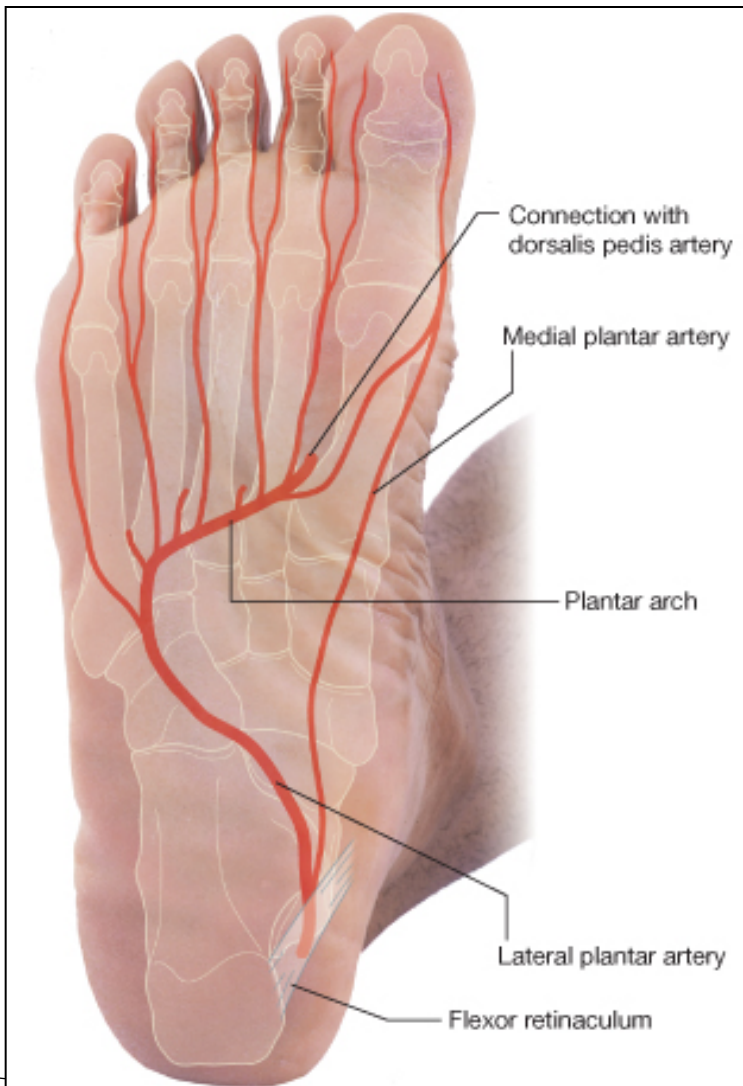
***The flexor retinaculum must be relaxed by inverting the foot.***

***Palpation of PT pulse is essential for examining patients with **occlusive peripheral arterial diseases.*****



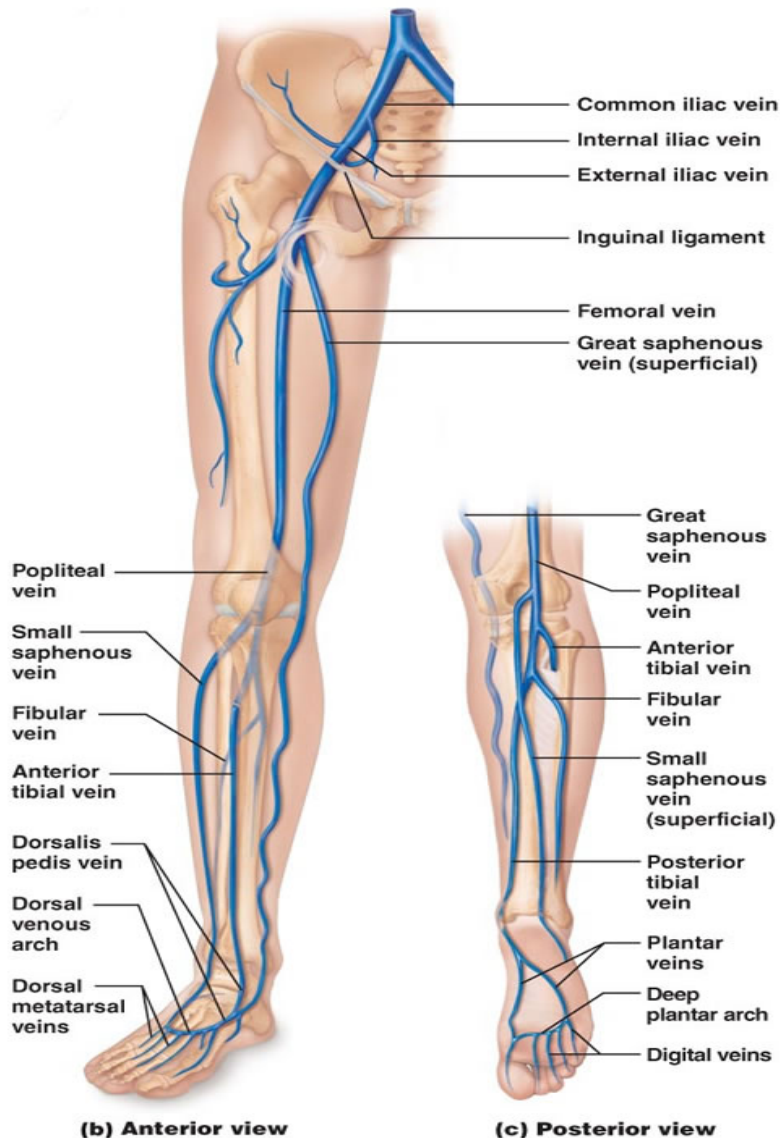
Posterior tibial pulse

# ***PLANTAR ARTERIES***



- **Medial plantar:**
- ***The smaller terminal branch of the posterior tibial artery.***
- ***It supplies mainly the muscles of the great toe, and gives most of plantar digital arteries.***
- ***Its superficial branch supplies the skin of the medial side of the sole.***
- **Lateral plantar:**
  - ***The larger branch.***
  - ***At the base of the 5<sup>th</sup> metatarsal bone, it curves medially to form***
  - **Plantar Arch : completed by the medial plantar artery and branch from DP artery.**
  - ***The arch supplies the skin, fascia and muscles in the sole and plantar digital arteries to the adjacent digits .***

# VEINS OF THE L.L



□ *The veins of the lower limb are classified into:*

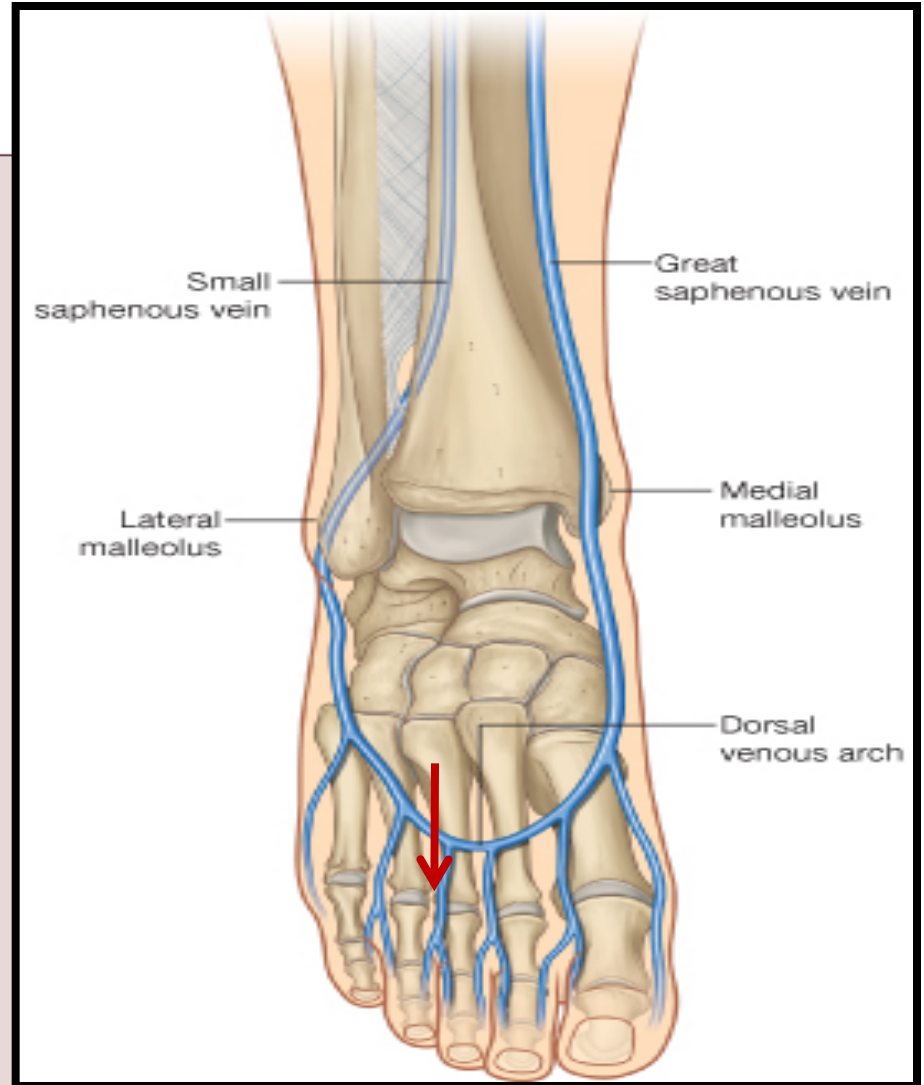
□ *Superficial veins : lie in the subcutaneous tissue ( GSV & SSV )*

*Deep veins: deep to the deep fascia and accompany all major arteries (Femoral, Popliteal veins).*

**The superficial & deep veins have valves which are more numerous in the deep veins. The blood passes from the superficial to the deep veins.**

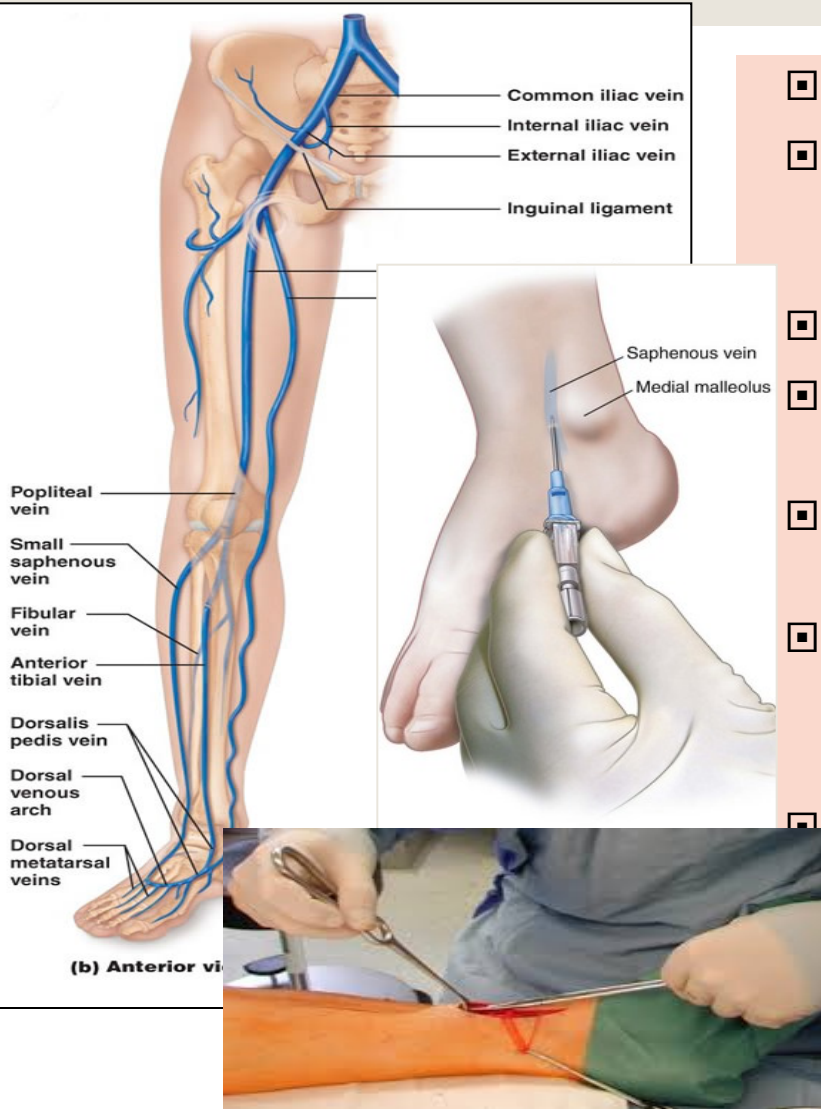
# ***Superficial veins***

- ▣ ***Dorsal Venous arch***  
***(network)***:
- ▣ ***Receives most of the blood of the foot through Digital and***
- ▣ ***Communicating veins.***
- ▣ ***Drained on:***  
***Medial side by the Great Saphenous vein.***  
***Lateral side by the Small saphenous vein***

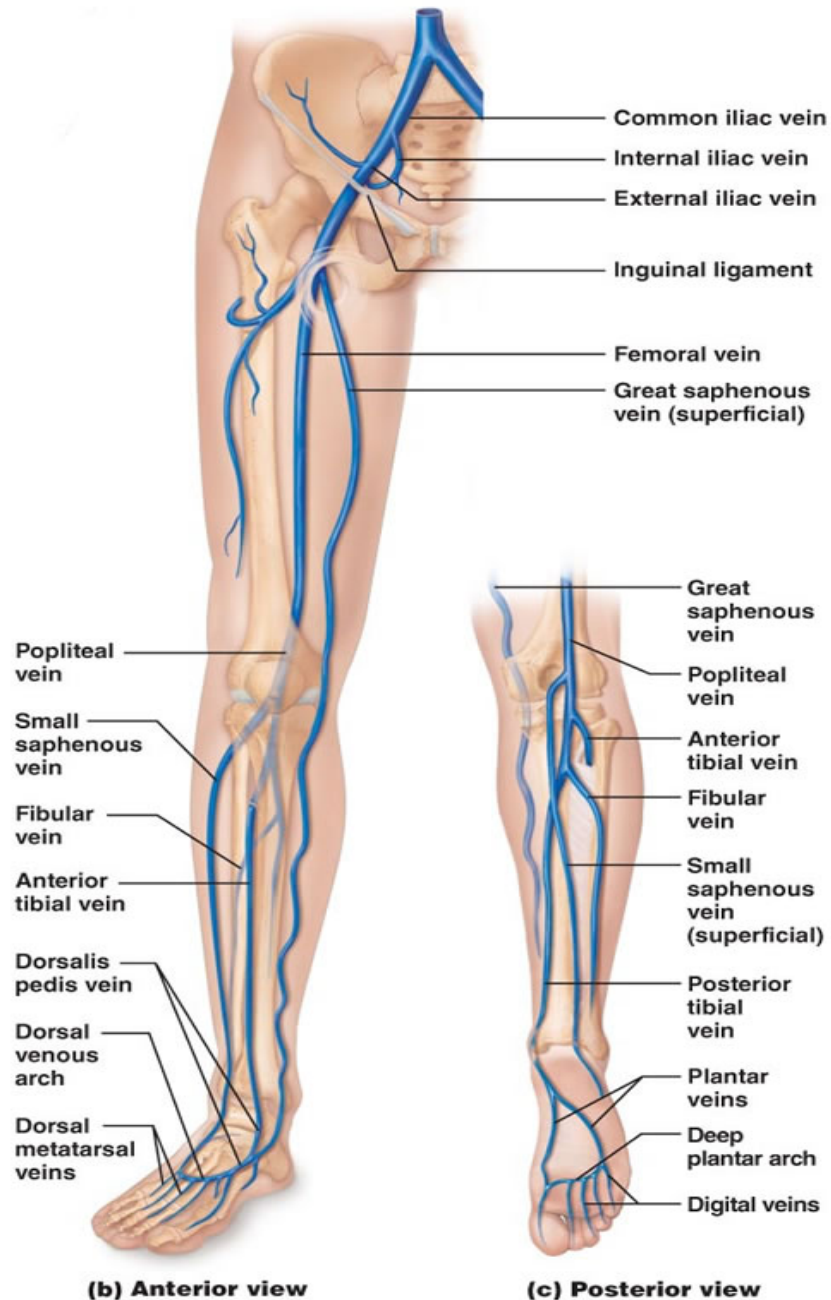




# Superficial veins : GREAT SAPHENOUS VEIN



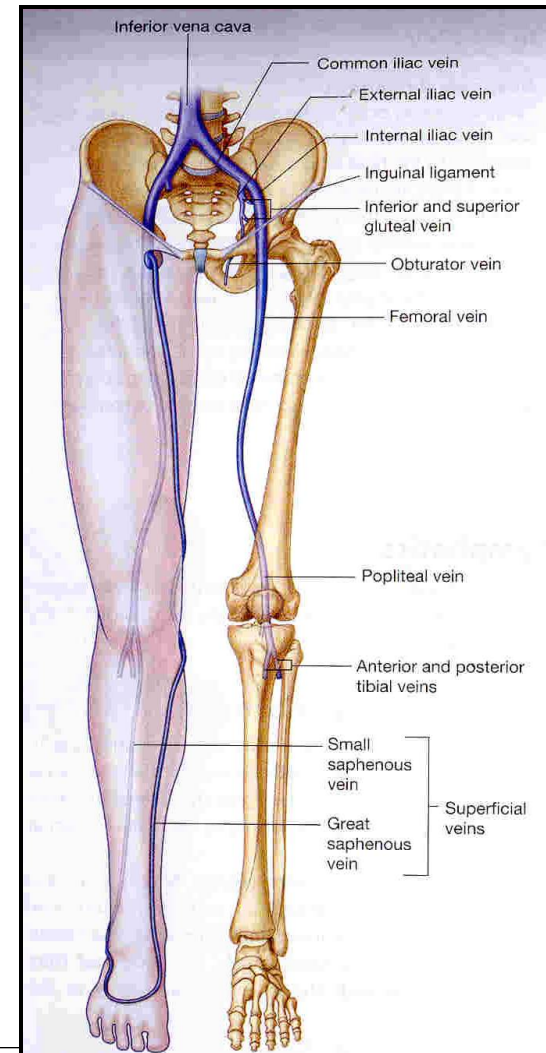
- **The Longest Superficial vein of the body.**
  - **Begins from the medial end of the dorsal venous arch (as the medial marginal vein).**
  - **Ascends:**
  - **A. In front of the **Medial Malleolus** accompanied by the (Saphenous nerve).**
  - **B. Posterior the **Medial Condyle** of the femur.**
  - **C. Passes through the **Saphenous Opening** (2.5-3.25) cm below and lateral to the pubic tubercle.**
  - **Terminates in **Femoral Vein**.**
- Because of its constant position in front of the medial malleolus, it is used for saphenous cutdown especially in infants, obese and shocked patients.**



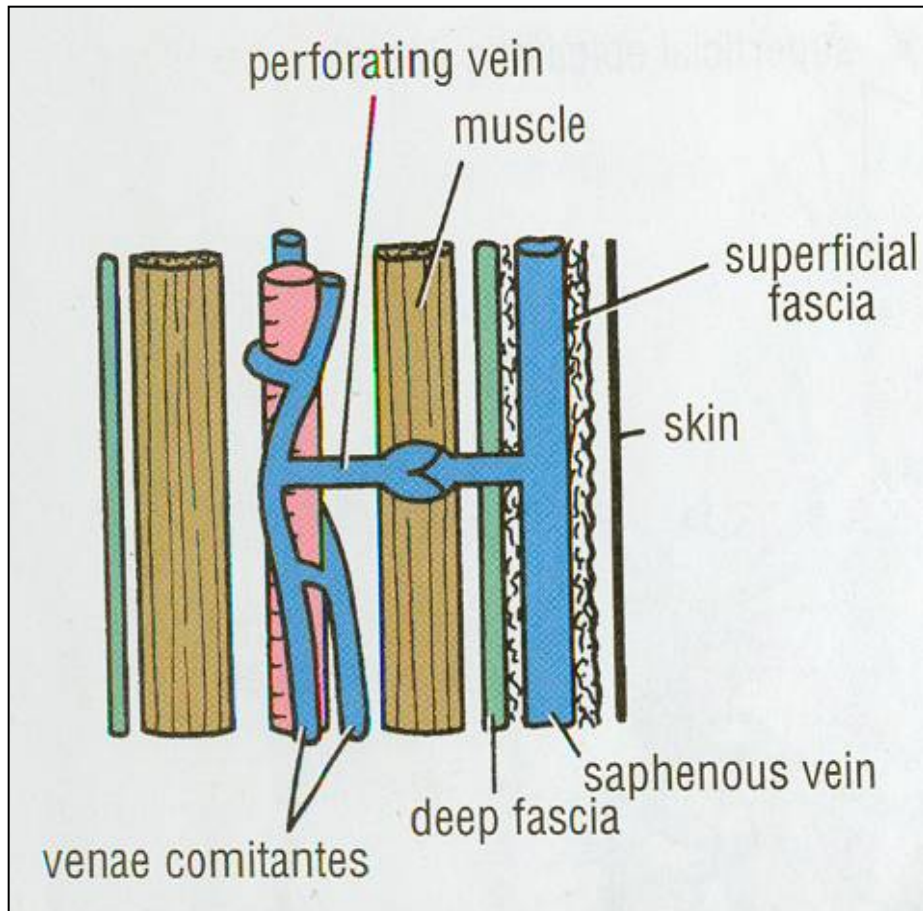
- **SMALL SAPHENOUS VEIN**
- ***Originates from the lateral end of the dorsal venous arch.***
- **Ascends:**
- ***Behind the **lateral Malleolus** along the middle of the back leg***
- **It Terminates in :**
- ***1. **Popliteal vein*****
- ***2. It may join the **Great Saphenous vein.*****
- ***3. Or Bifurcates:***
- ***One branch joins the **Great saphenous** and the other joins the **Popliteal vein.*****

# Deep Veins

- **Popliteal vein**
- **Formed by the union of venae comitantes around the anterior & posterior tibial arteries.**
- **lies posterior to popliteal artery.**
- **Femoral vein**
- **It enters the thigh by passing through the opening in the adductor magnus .**
- **It leaves the thigh in the intermediate compartment of the femoral sheath.**
- **Passes behind the inguinal ligament to become the External iliac vein**

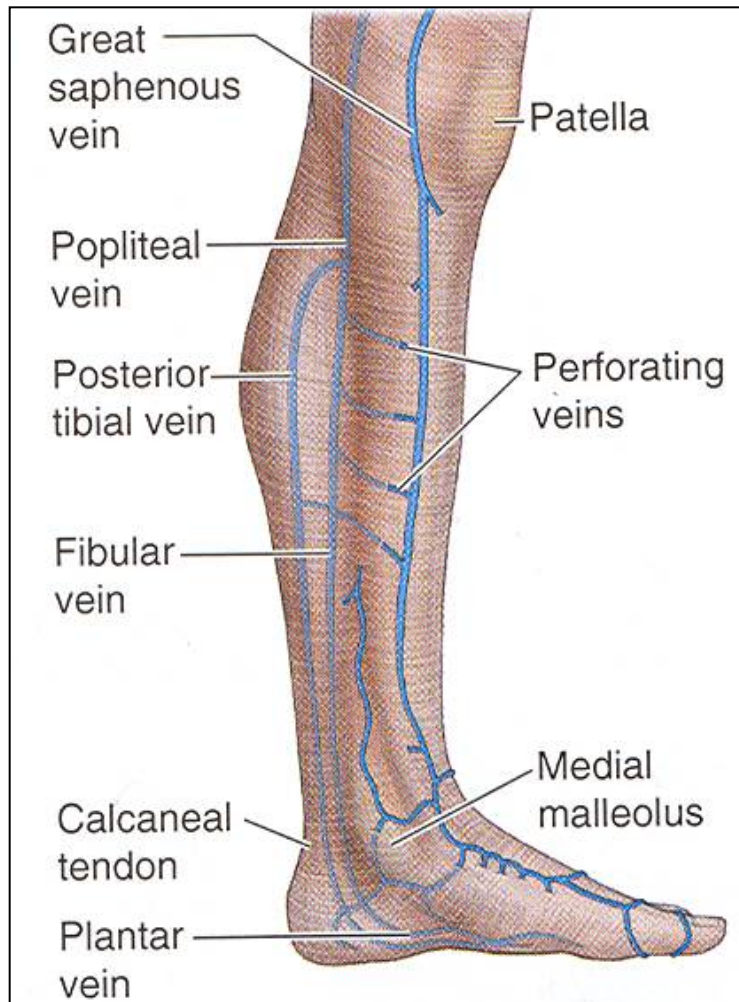


# ***VENAE COMITANTES***



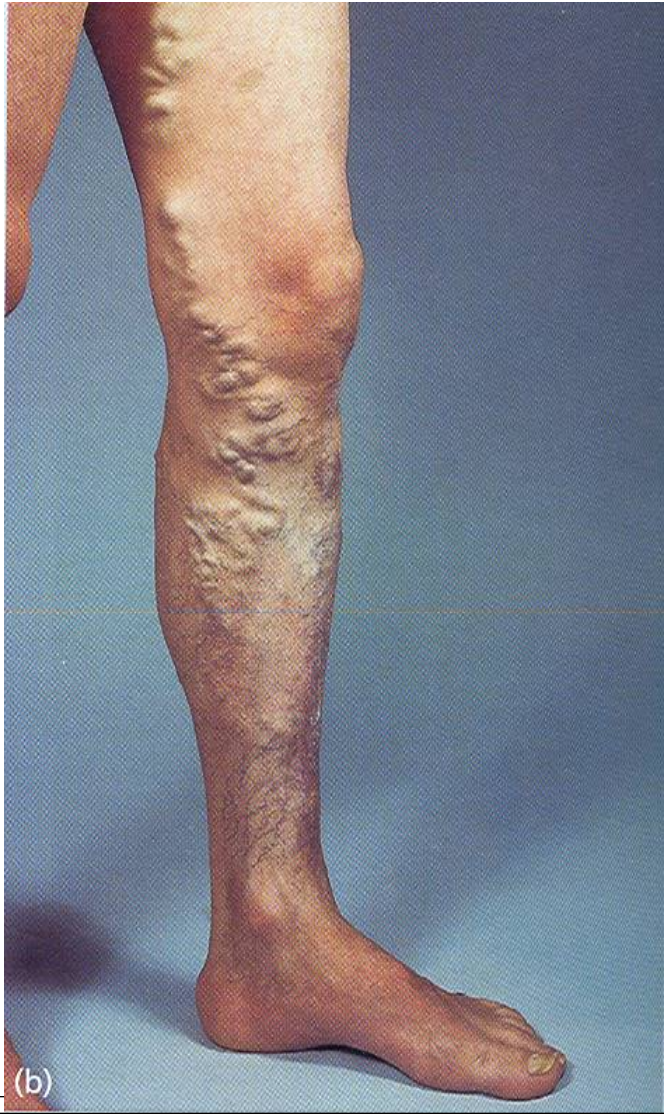- ***Deep veins ,usually they are paired and accompany arteries.***
- ***They are contained within the vascular sheath of the arteries, so the arterial pulsations help to compress and move blood in the veins especially during exercise.***

# ***PERFORATING VEINS***



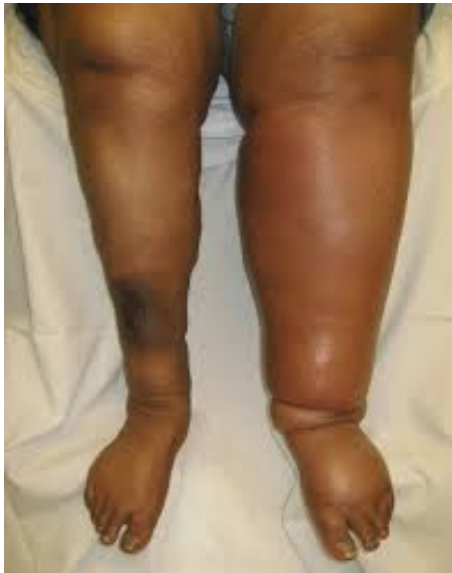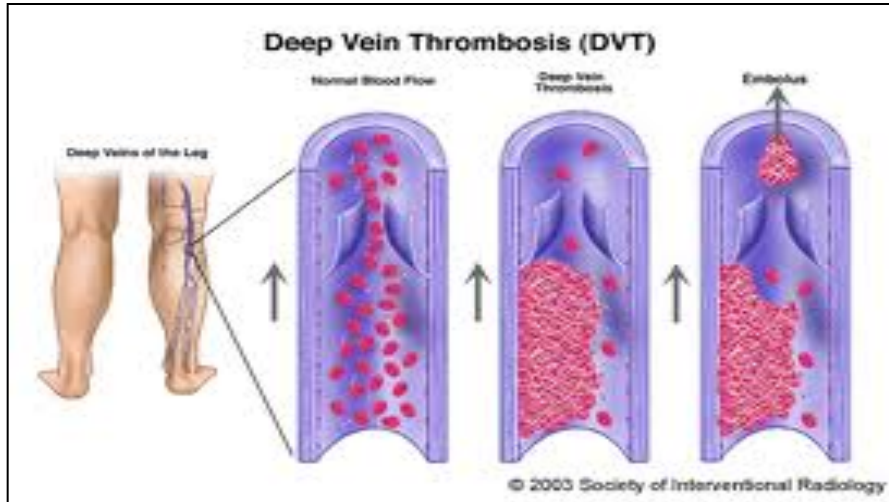
- ▣ ***Penetrate the deep fascia close to their origin from the superficial veins. They contain valves which normally allow the blood to flow from the superficial to the deep veins.***
- ▣ ***The perforating veins pass through the deep fascia at an oblique angle so during muscular contraction, they are compressed. This also prevents blood flowing from the deep to the superficial veins..***

# ***VARICOSE VEINS***



- ▣ ***It is Dilatation and Degeneration of the superficial veins that may be complicated by ulcers.***
- ▣ ***More common in the postero medial part of the lower limb.***
- ▣ ***Results because of incompetence of the valves in the perforating veins,***
- ▣ ***Or valves within the great saphenous itself.***
- ▣ ***This allows the passage of high pressure blood from the deep to the superficial veins.***

# Deep Vein Thrombosis (DVT)



- The veins of the lower limb are subject to venous thrombosis after a bone fracture.
- Venous stasis is the main cause by pressure on the veins from the bedding during prolonged hospital stay and aggravated by muscular inactivity.
- Thrombophlebitis may develop around the vein.
- Pulmonary thromboembolism may occur when a thrombus breaks free from the lower limb vein and passes to the lungs.

**Thank You**