

**\* KNEE JOINT**  
**\* ANKLE JOINT**  
**\* HIP JOINT**

***Prof. Ahmed Fathalla Ibrahim***  
***Professor of Anatomy***  
***College of Medicine***  
***King Saud University***  
***E-mail: [ahmedfathala@gmail.com](mailto:ahmedfathala@gmail.com)***

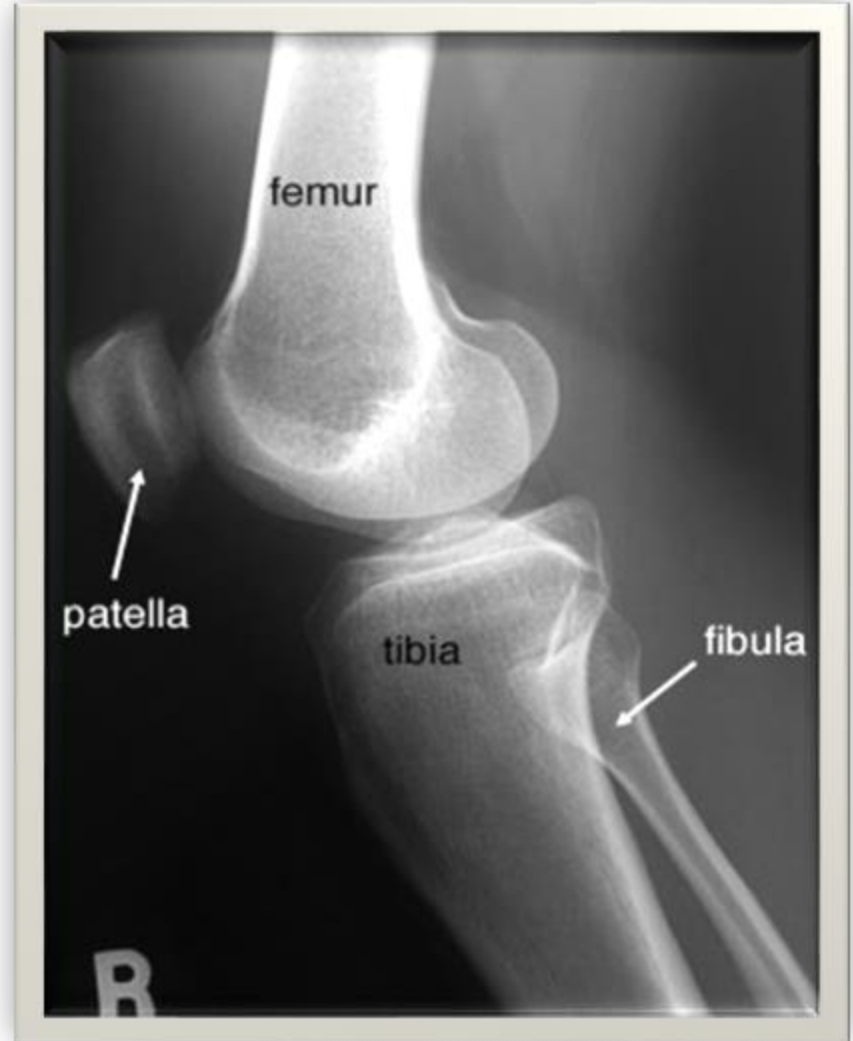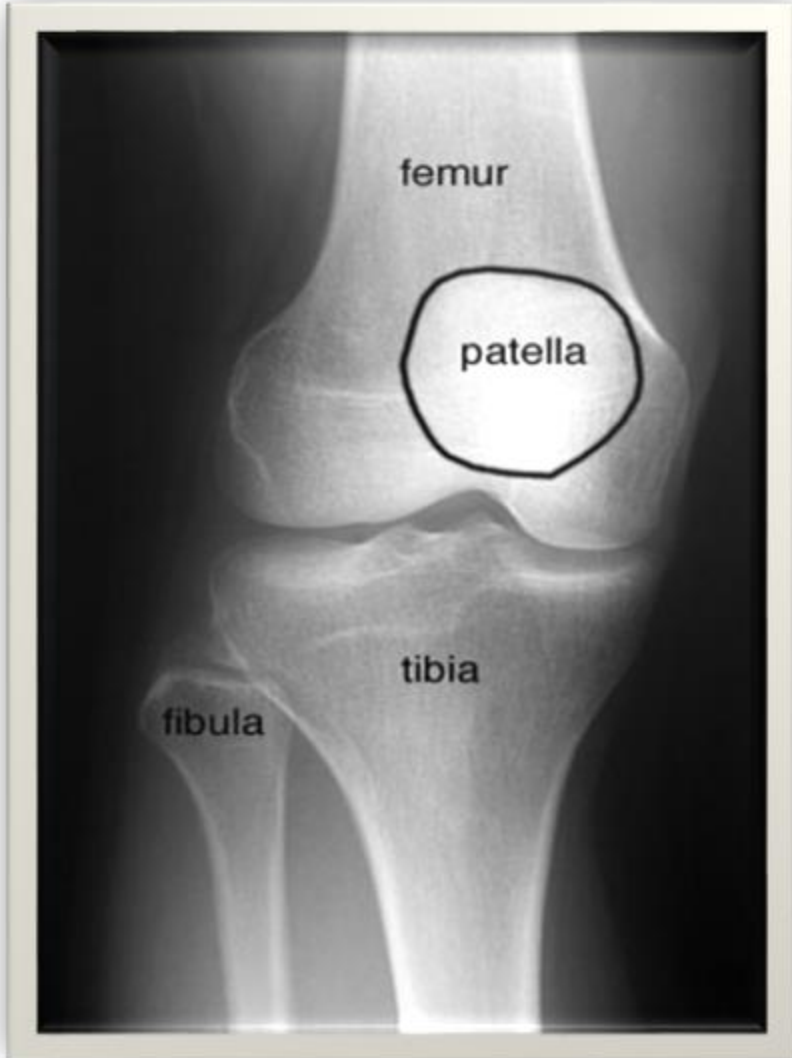# **KNEE JOINT**

# OBJECTIVES

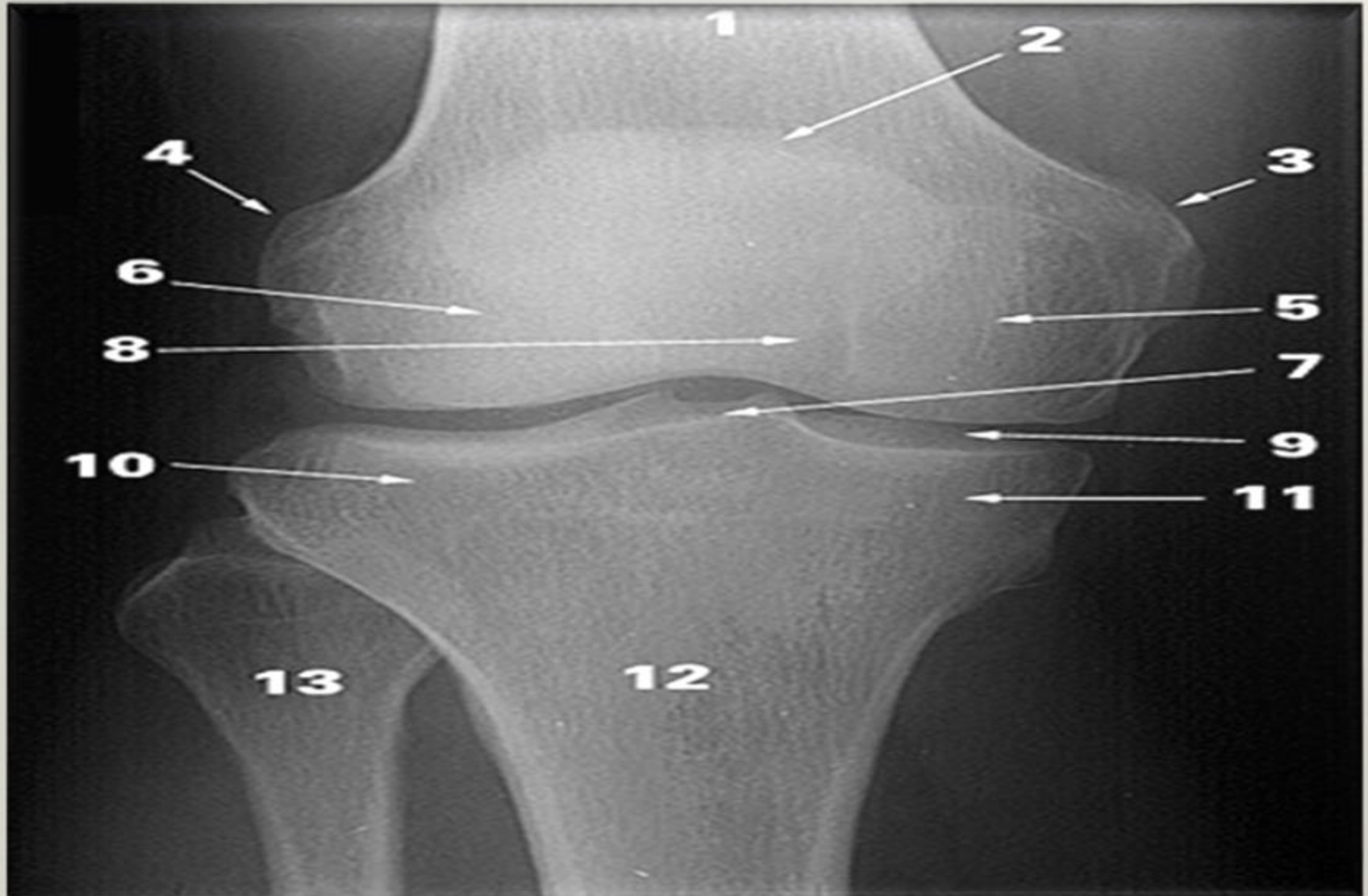
**At the end of the lecture, students should be able to:**

- *List the type & articular surfaces of knee joint.*
- *Describe the capsule of knee joint, its extra- & intra-capsular ligaments.*
- *List important bursae in relation to knee joint.*
- *Describe movements of knee joint.*
- *Apply Hilton's law about nerve supply of joints.*

# KNEE JOINT



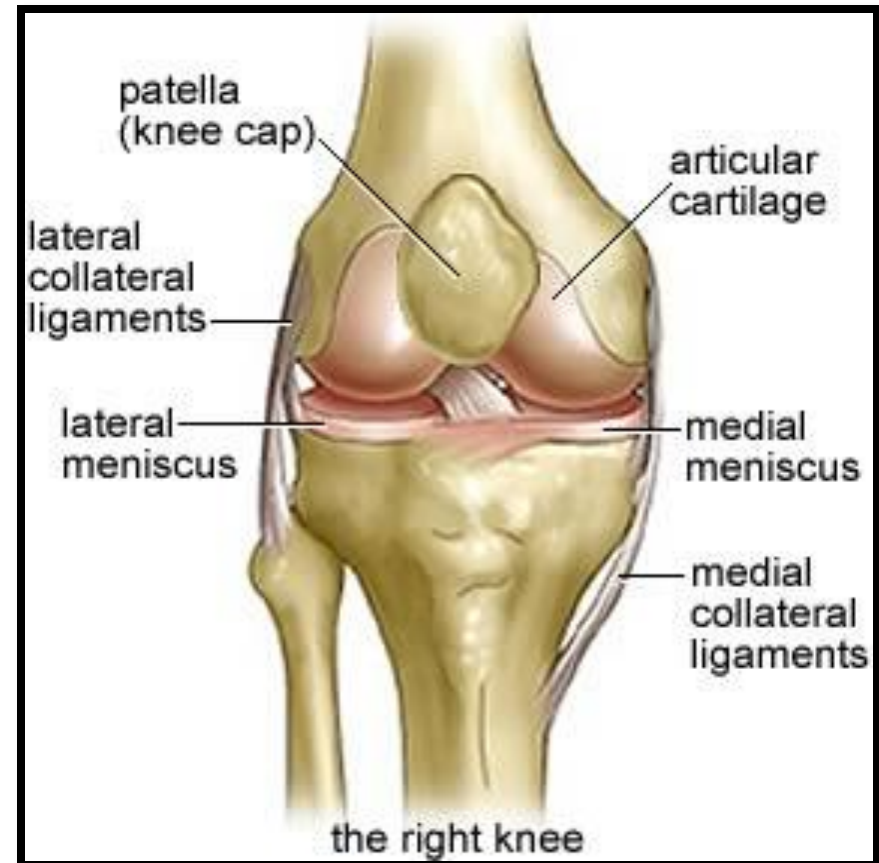
# IDENTIFY

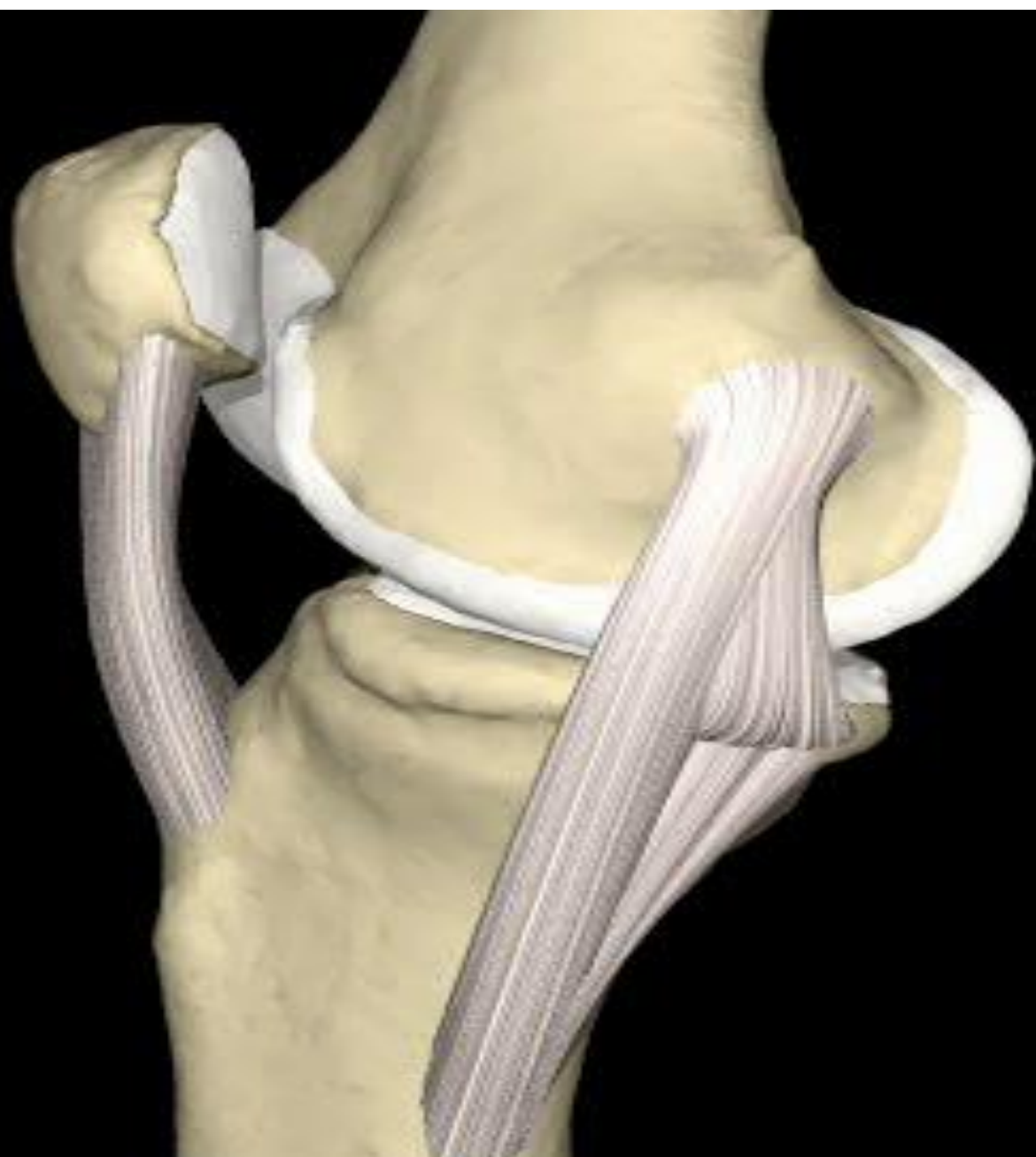


# TYPES & ARTICULAR SURFACES

**Knee joint** is formed of:

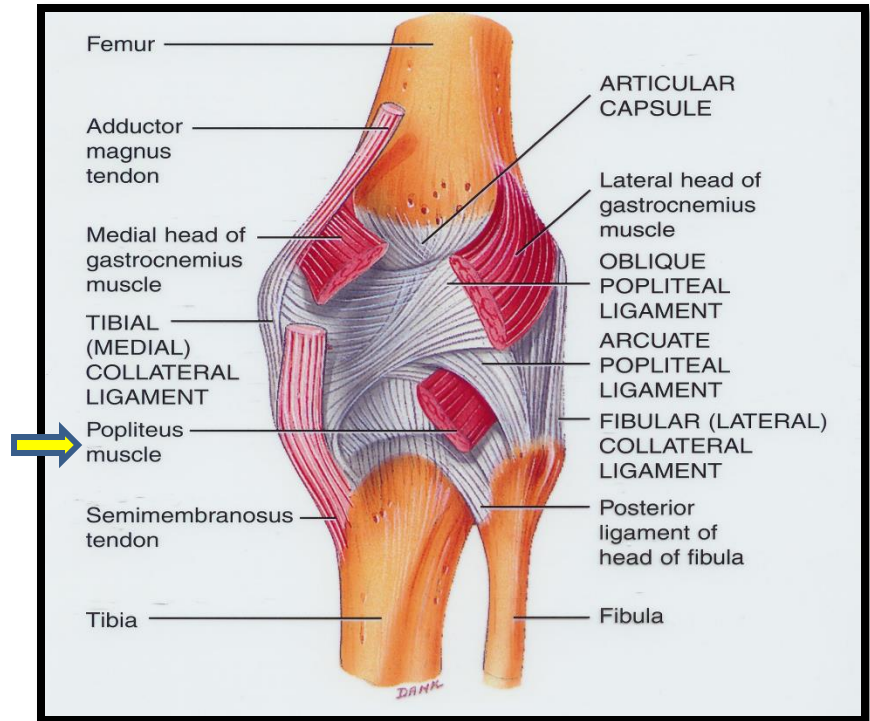
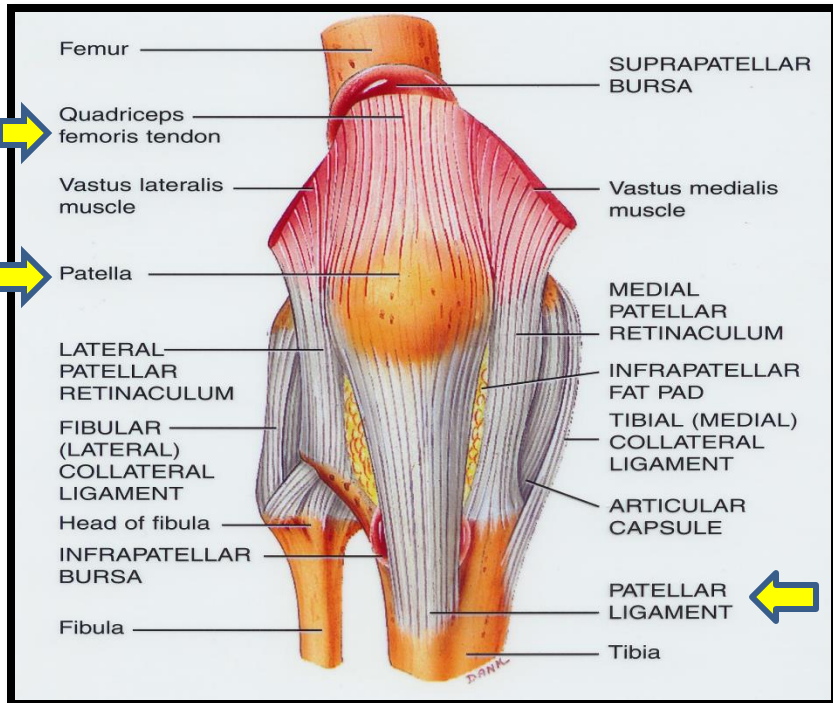
- **Three bones.**
- **Three articulations.**
- **Femoro-tibial articulations:**  
between the 2 femoral condyles & upper surfaces of the 2 tibial condyles (*Type: synovial, modified hinge*).
- **Femoro-patellar articulations:**  
between posterior surface of patella & patellar surface of femur (*Type: synovial, plane*).







# CAPSULE

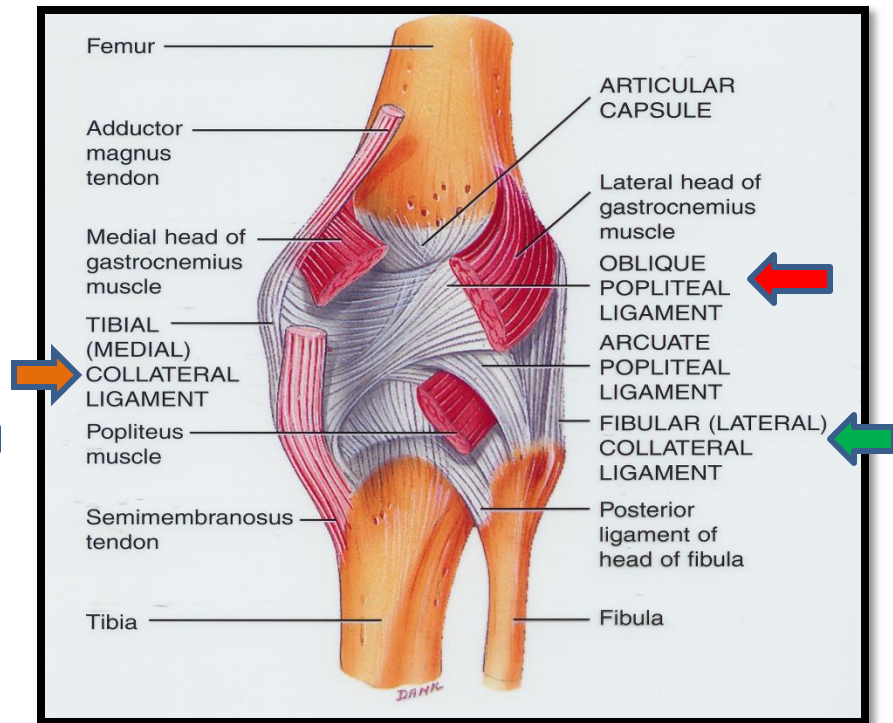
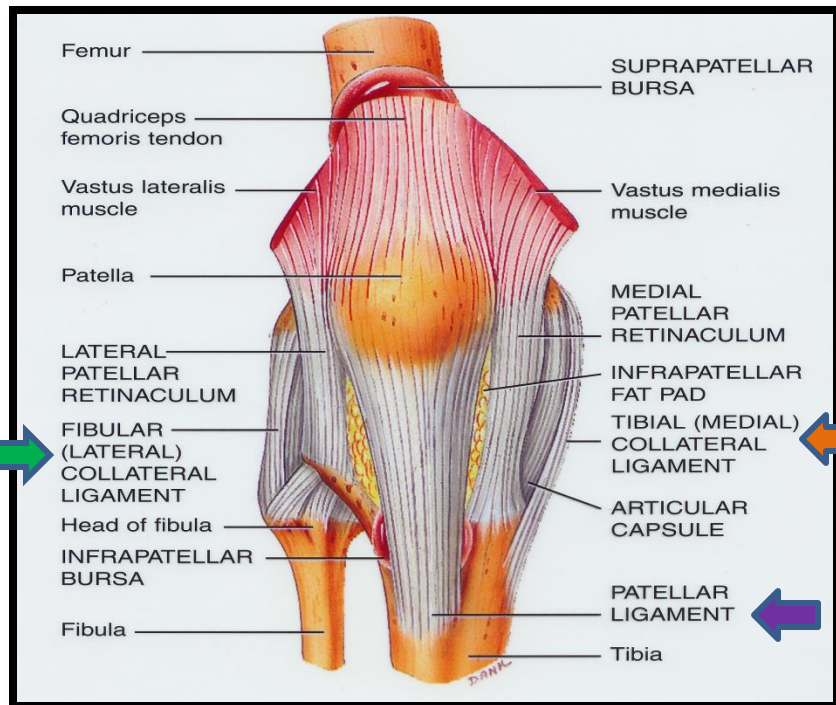


▪ Is deficient anteriorly & is replaced by: *quadriceps femoris tendon, patella & ligamentum patellae.*

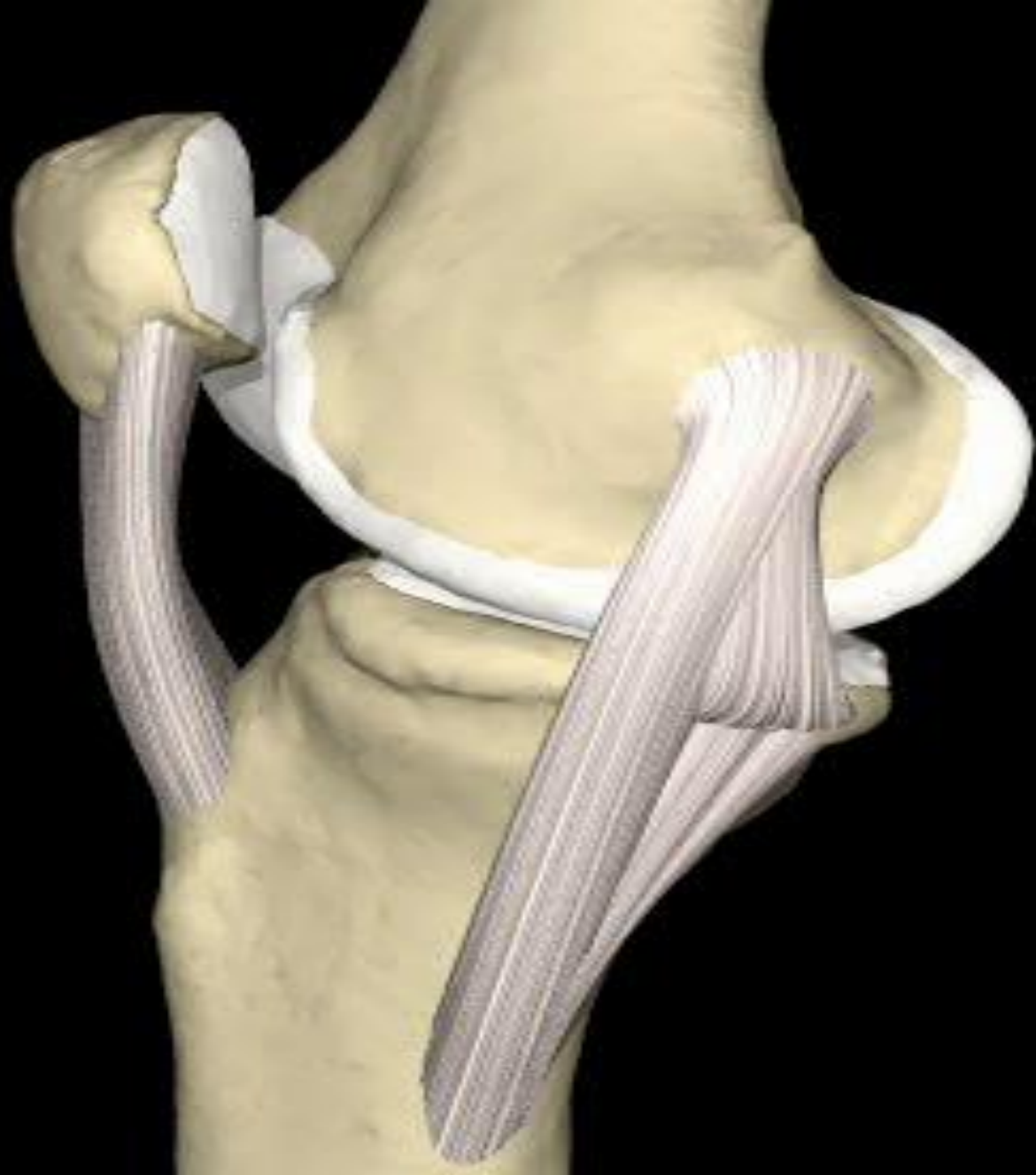
▪ Possesses 2 openings: one for popliteus tendon & one for communication with suprapatellar bursa.

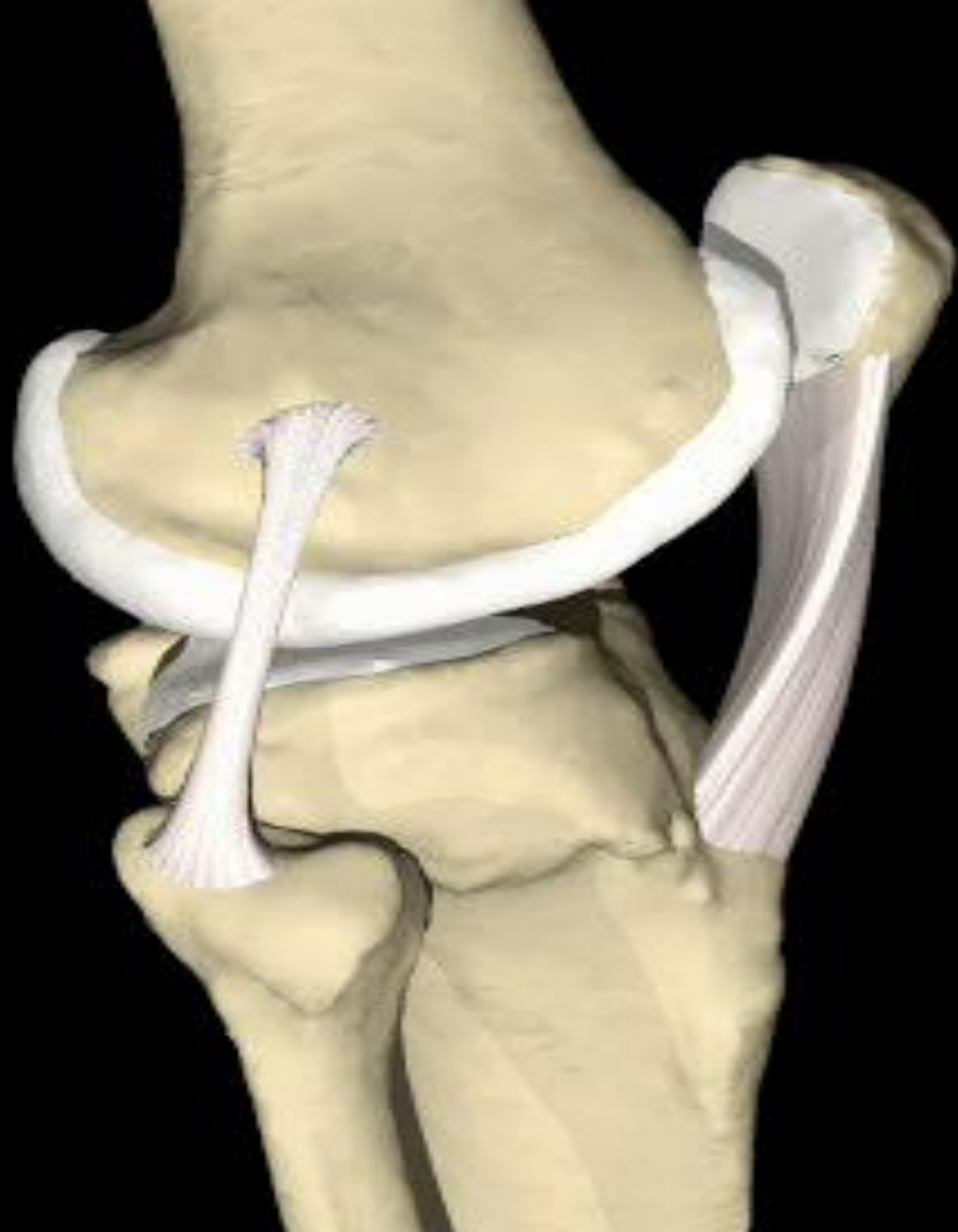

# EXTRA-CAPSULAR LIGAMENTS



1. **Ligamentum patellae (patellar ligament):** from patella to tibial tuberosity.
2. **Medial (tibial) collateral ligament:** from medial epicondyle of femur to upper part of medial surface of tibia (firmly attached to medial meniscus).
3. **Lateral (fibular) collateral ligament:** from lateral epicondyle of femur to head of fibula (separated from lateral meniscus by popliteus tendon).
4. **Oblique popliteal ligament:** extension of semimembranosus tendon.





# INTRA-CAPSULAR LIGAMENTS

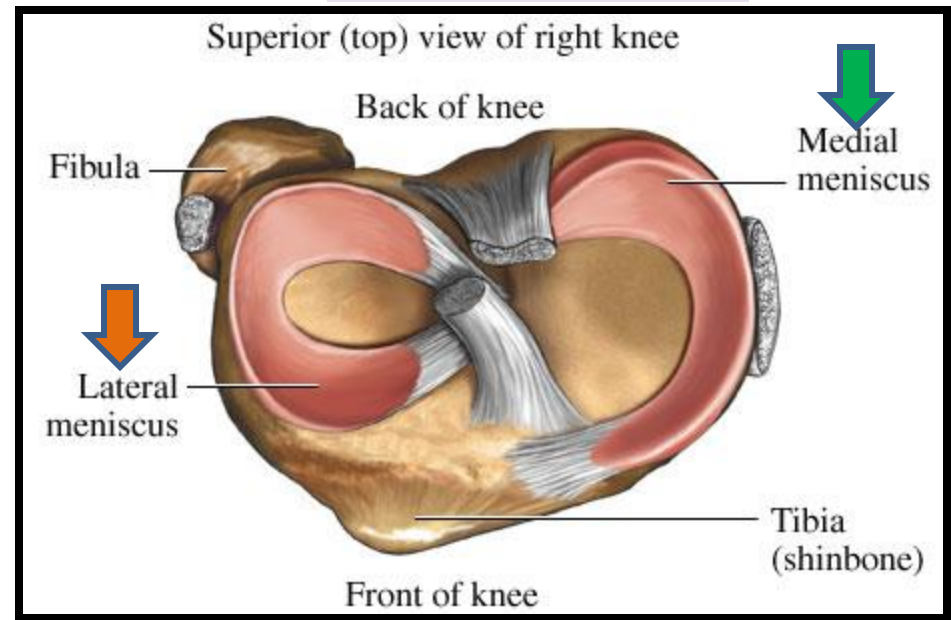
## ATTACHMENTS:

- Each meniscus is attached by anterior & posterior horns into upper surface of tibia.
- The outer surface of medial meniscus is also attached to capsule & medial collateral ligament: *medial meniscus is less mobile & more liable to be injured.*

## FUNCTIONS:

- They deepen articular surfaces of tibial condyles.
- They serve as cushions between tibia & femur.

## MENISCI



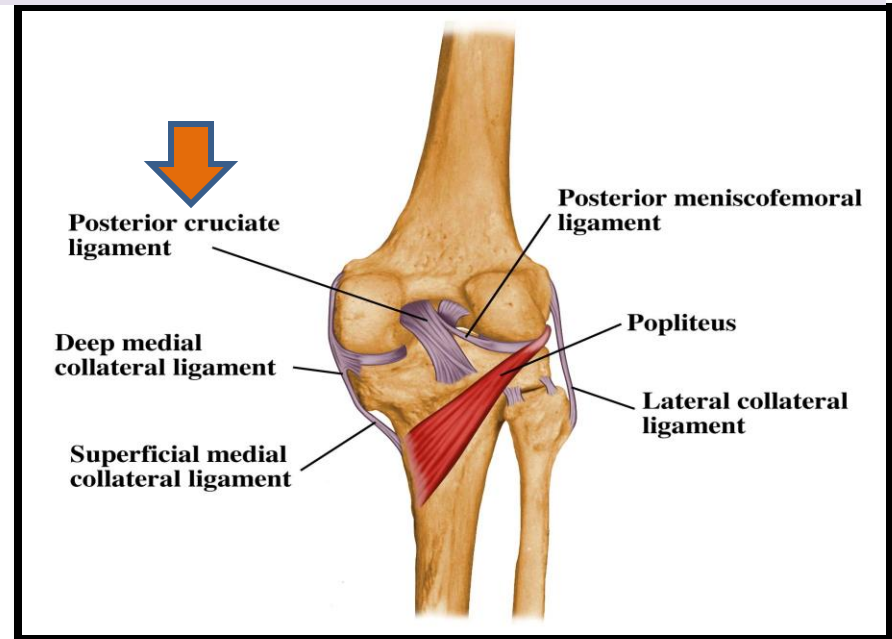
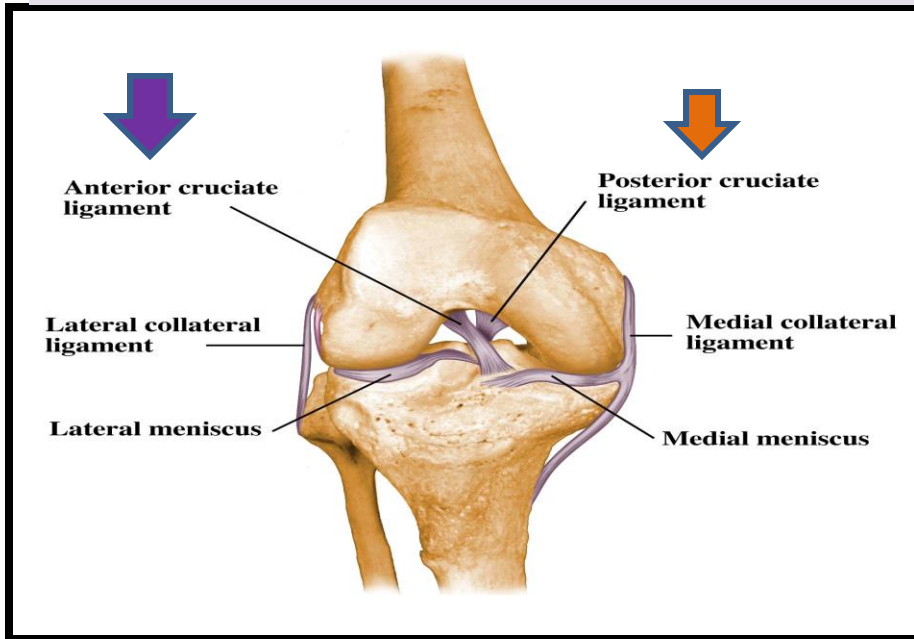
They are 2 C-shaped plates of fibrocartilage.

The **medial** meniscus is large & **oval**.

The **lateral** meniscus is **small & circular**.

# INTRA-CAPSULAR LIGAMENTS

## ANTERIOR & POSTERIOR CRUCIATE LIGAMENTS



### ATTACHMENTS:

**Anterior cruciate:** from **anterior part** of intercondylar area of tibia to **posterior part of lateral condyle** of femur.

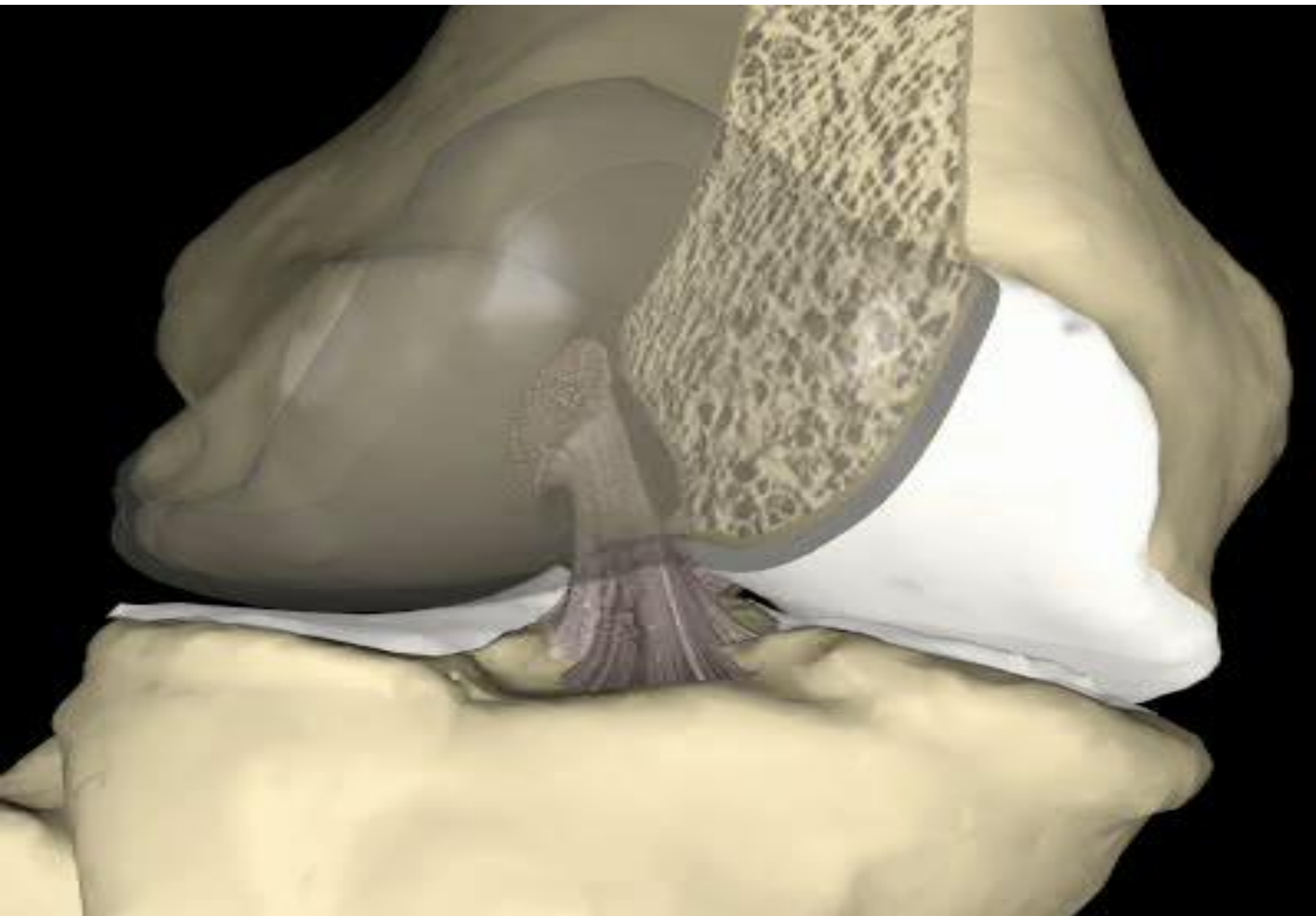
**Posterior cruciate:** from **posterior part** of intercondylar area of tibia to **anterior part of medial condyle** of femur.

### FUNCTIONS:

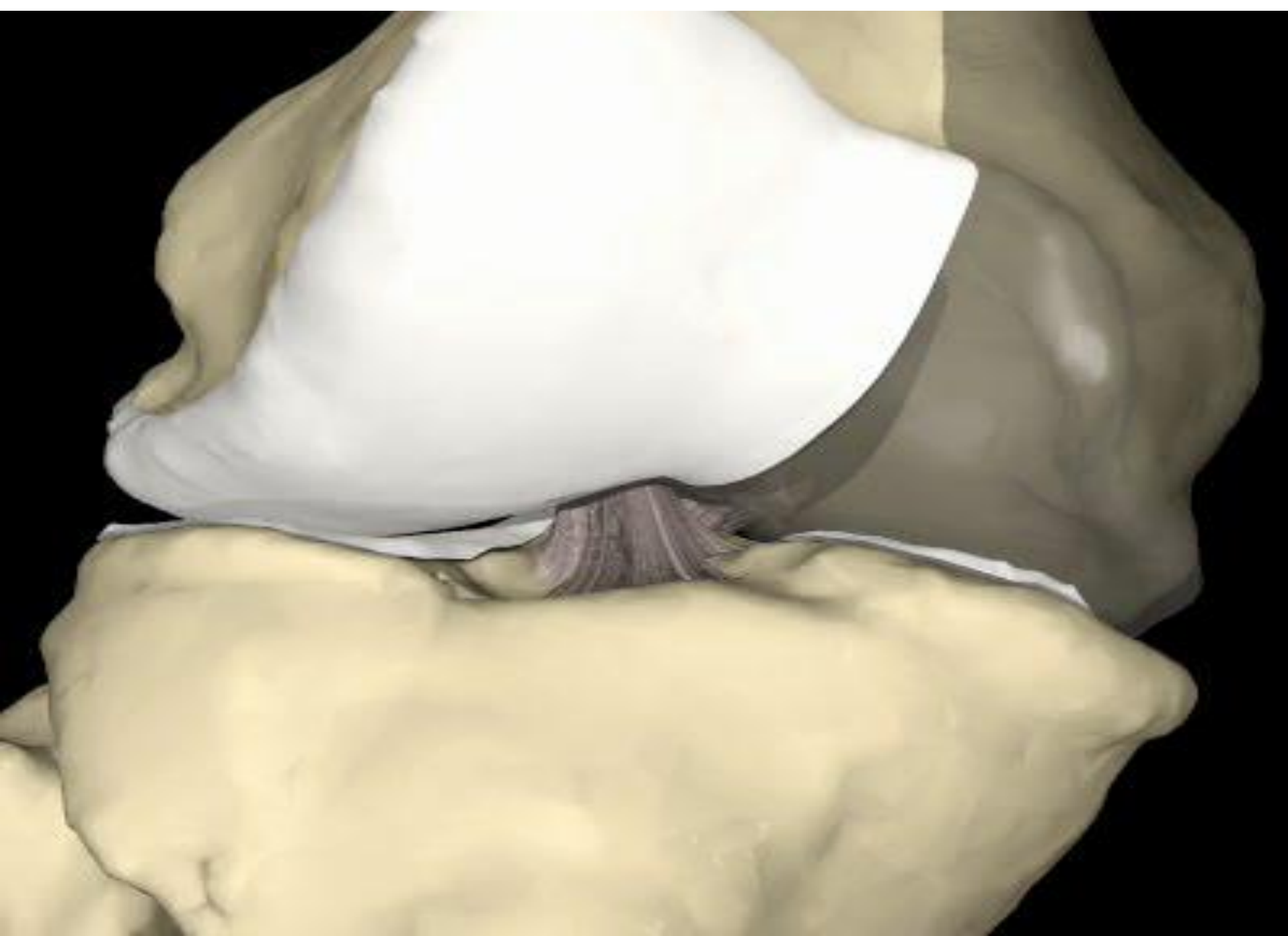
**Anterior cruciate:** prevents **posterior** displacement of femur on tibia.

**Posterior cruciate:** prevents **anterior** displacement of femur on tibia.

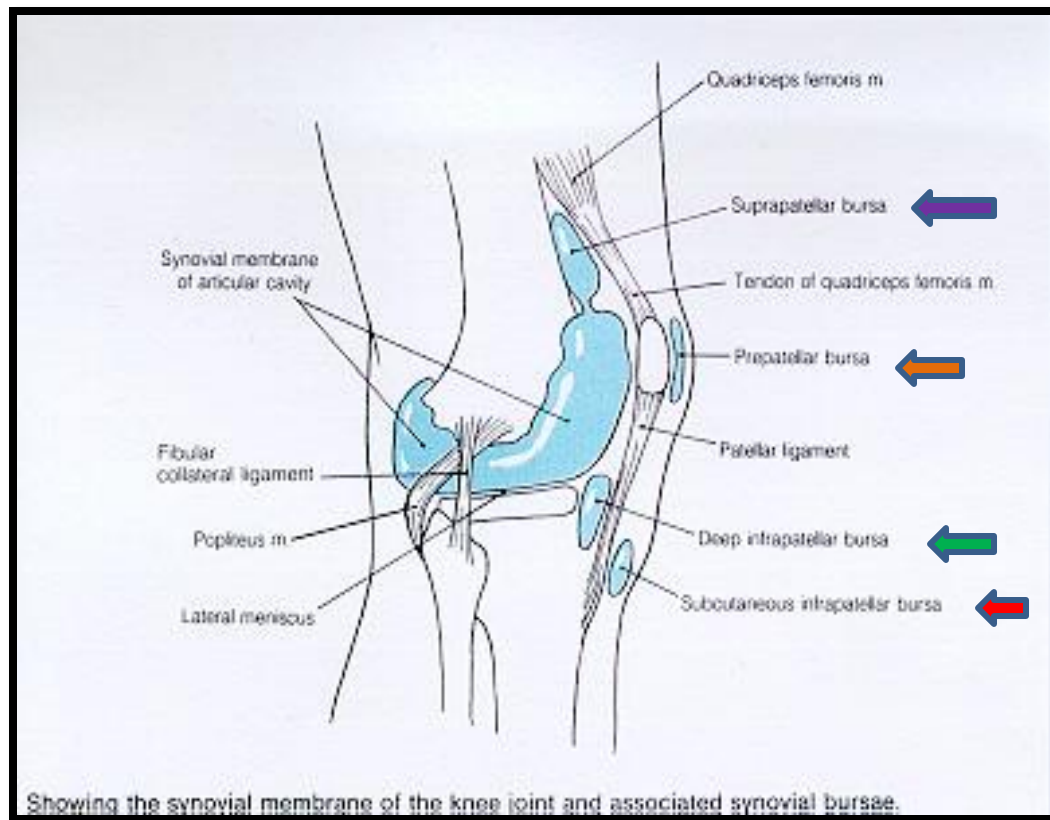








# IMPORTANT BURSAE RELATED TO KNEE



- **Suprapatellar bursa:** between femur & quadriceps tendon, communicates with synovial membrane of knee joint (Clinical importance?)
- **Prepatellar bursa:** between patella & skin.
- **Deep infrapatellar bursa:** between tibia & ligamentum patella.
- **Subcutaneous infrapatellar bursa:** between tibial tuberosity & skin.
- **Popliteal bursa (not shown):** between popliteus tendon & capsule, communicates with synovial membrane of knee joint.

# MOVEMENTS

- FLEXION:

1. Mainly by hamstring muscles: biceps femoris , semitendinosus & semimembranosus.
2. Assisted by sartorius , gracilis & popliteus.

- EXTENSION:

Quadriceps femoris.

- ACTIVE ROTATION (PERFORMED WHEN KNEE IS FLEXED):

- A) MEDIAL ROTATION:

1. Mainly by semitendinosus & semimembranosus.
2. Assisted by sartorius & gracilis.

- B) LATERAL ROTATION:

Biceps femoris.

# MOVEMENTS (cont'd)

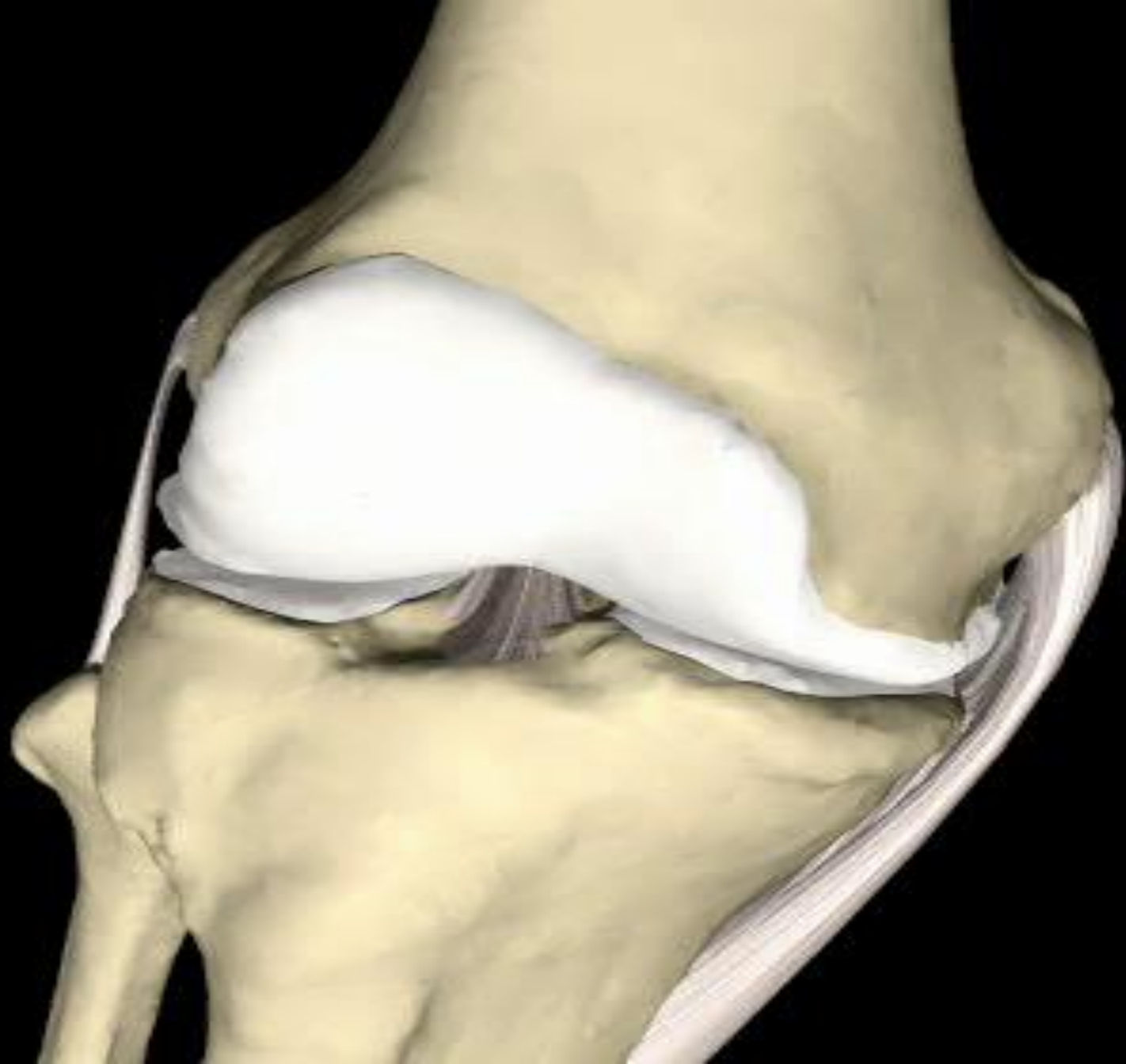## ■ INACTIVE (DEPENDANT) ROTATION:

### A) LOCKING OF KNEE:

- Lateral rotation of tibia (medial rotation of femur), at the end of extension
- Results mainly by tension of anterior cruciate ligament.
- In locked knee, all ligaments become tight.

### B) UNLOCKING OF KNEE:

- Medial rotation of tibia (lateral rotation of femur), at the beginning of flexion.
- Performed by popliteus to relax ligaments & allow easy flexion.



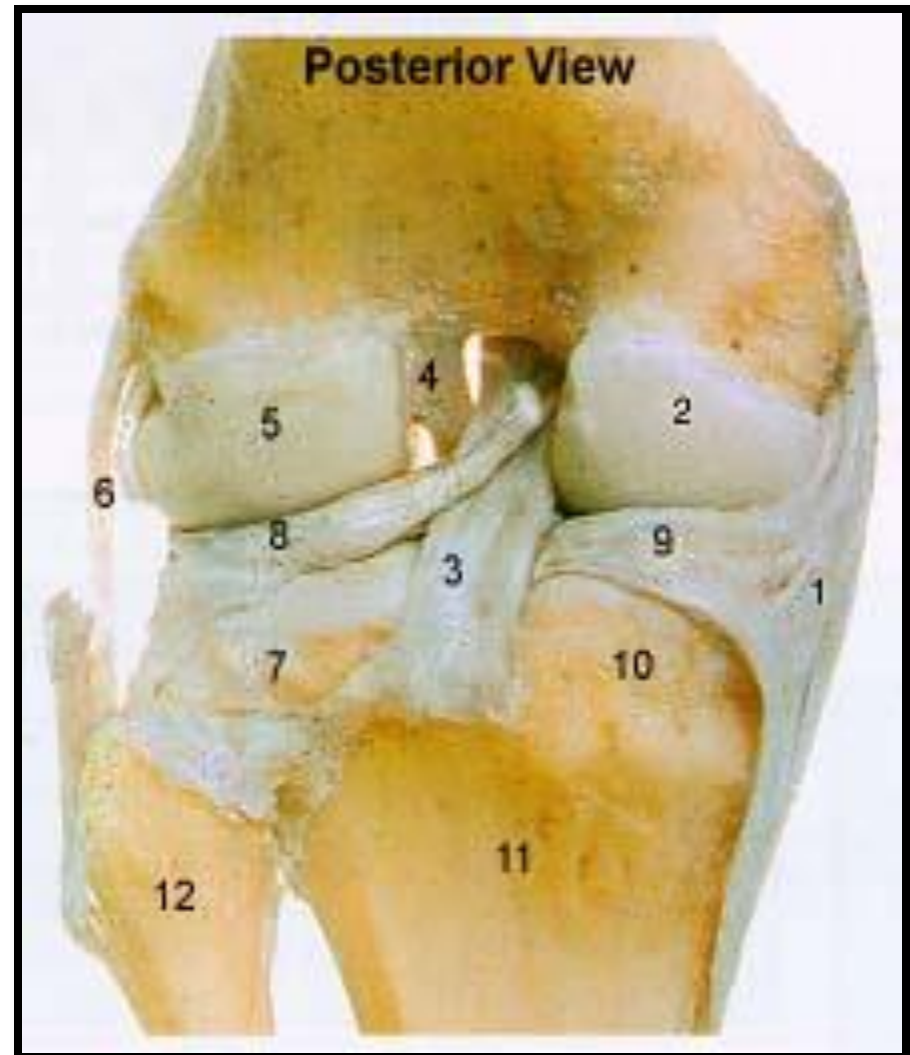
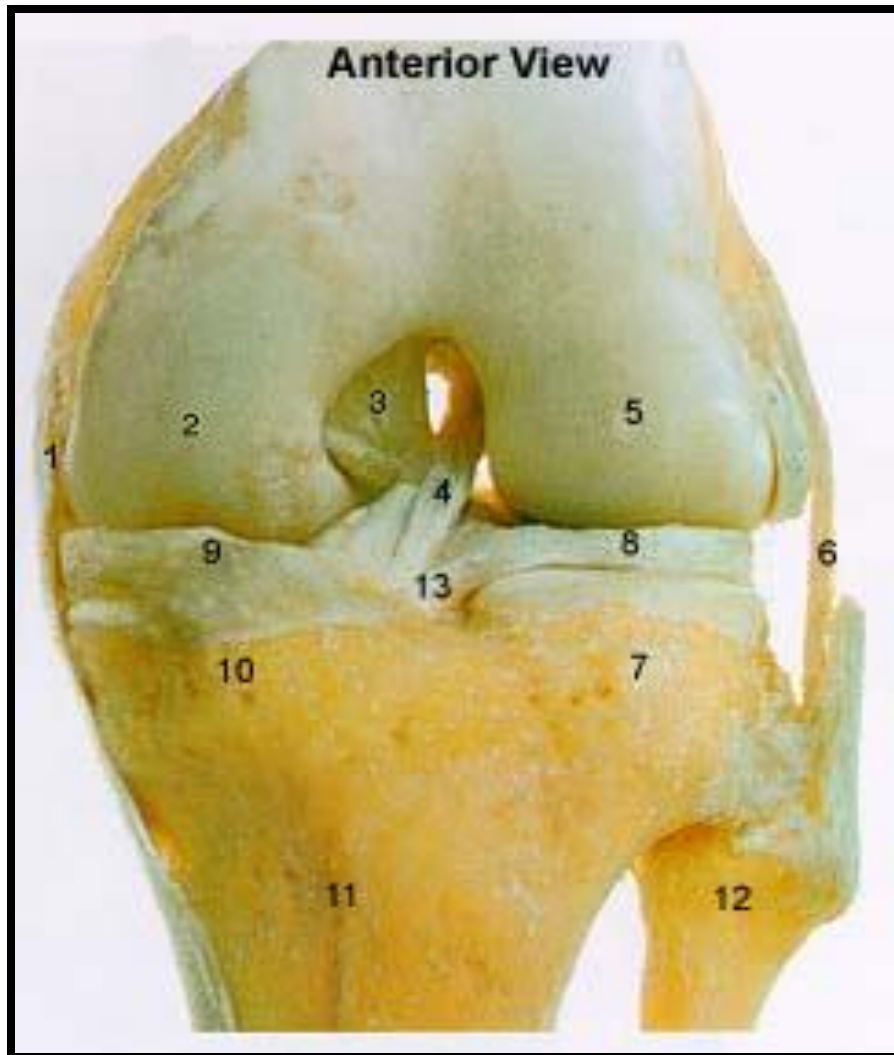# NERVE SUPPLY

## REMEMBER HILTON'S LAW:

*“The joint is supplied by branches from nerves supplying muscles acting on it”.*



# IDENTIFY



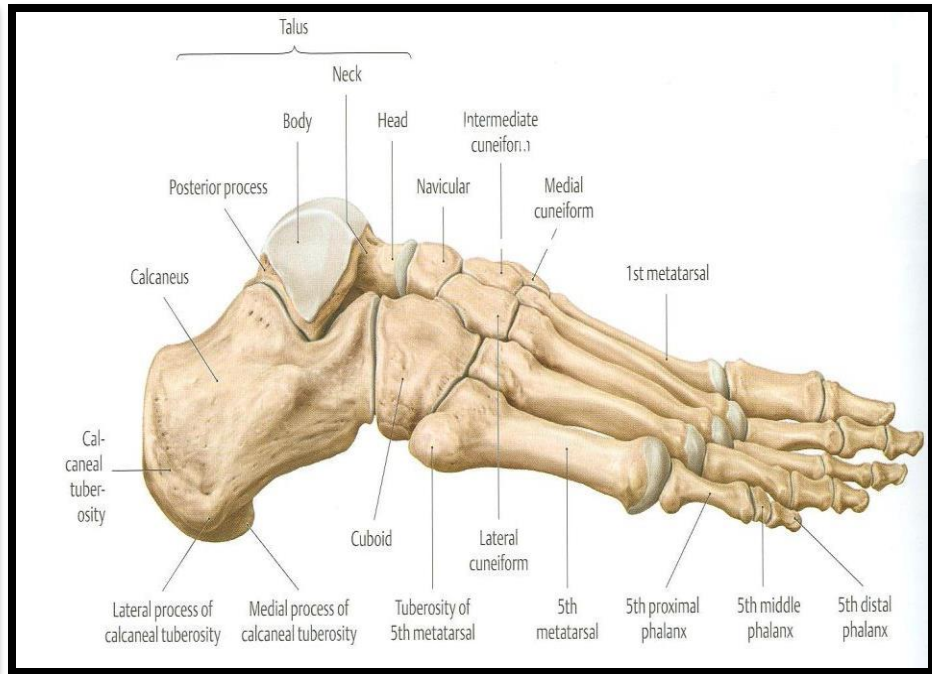
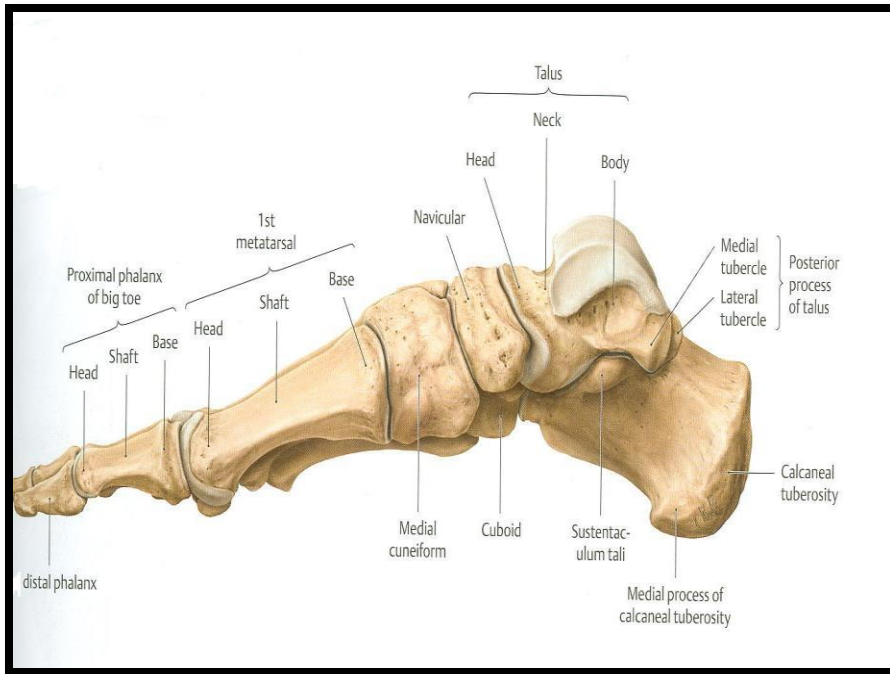
**ANKLE JOINT**

# OBJECTIVES

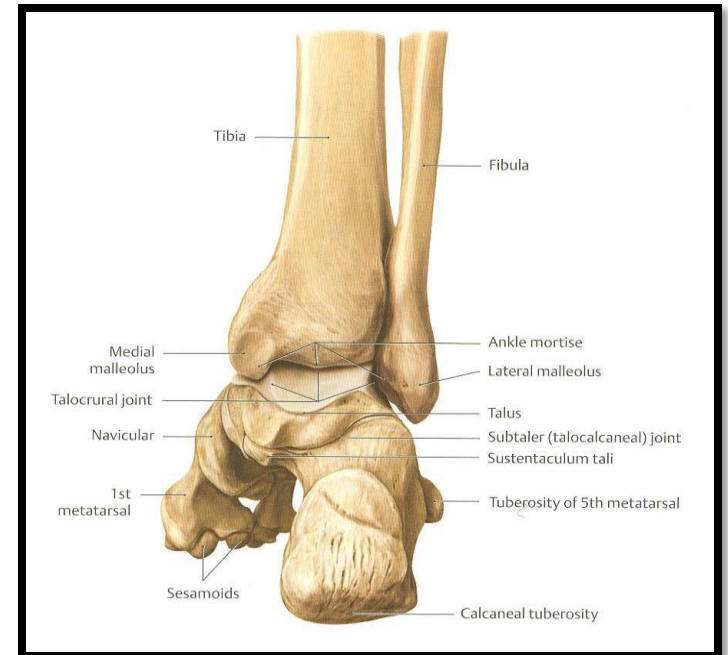
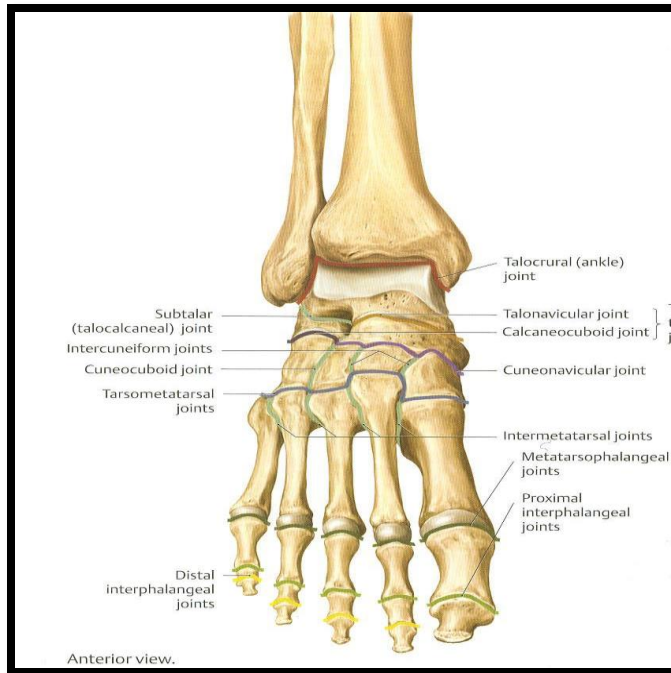
**At the end of the lecture, students should be able to:**

- *List the type & articular surfaces of ankle joint.*
- *Describe the ligaments of ankle joints.*
- *Describe movements of ankle joint.*

# SKELETON OF FOOT



# TYPES & ARTICULAR SURFACES



## ■ TYPE:

It is a synovial, hinge joint.

## ■ ARTICULAR SURFACES:

### UPPER:

A socket formed by: the lower end of tibia, medial malleolus & lateral malleolus.

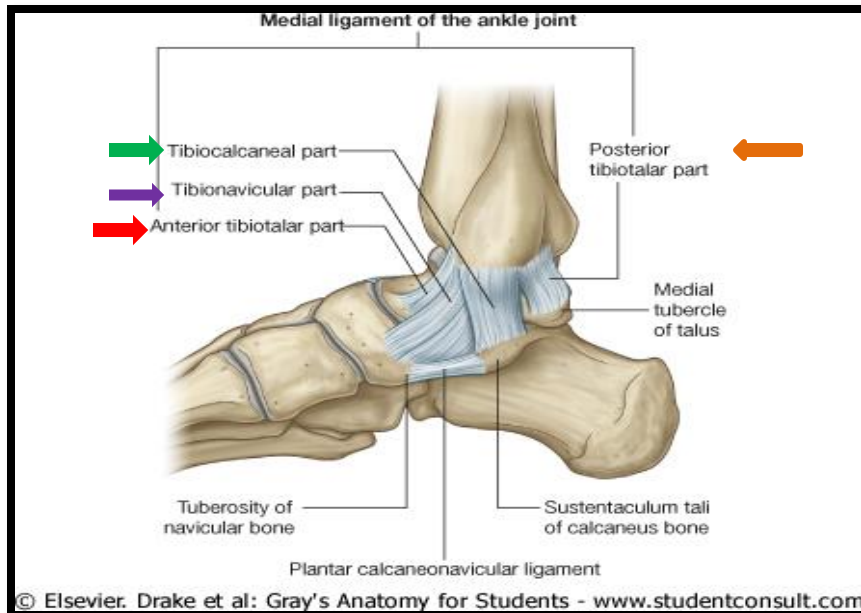
### LOWER:

Body of talus.

# LIGAMENTS

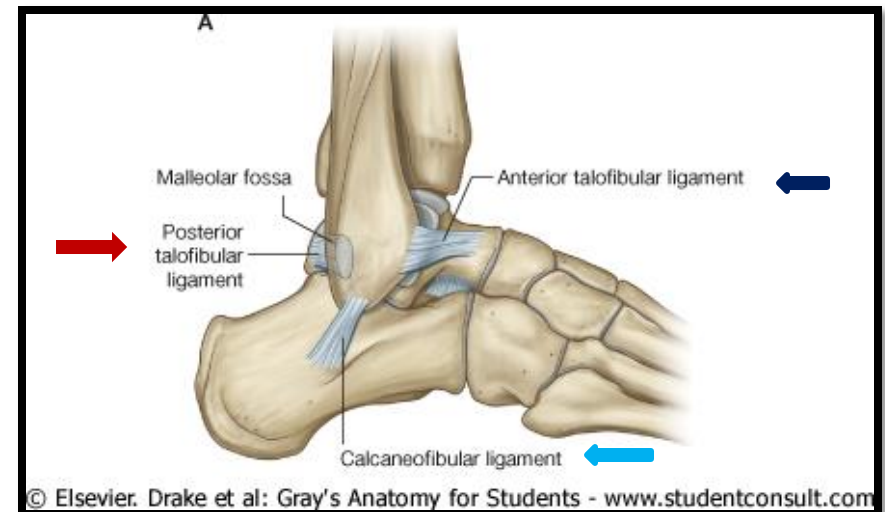
## MEDIAL (DELTOID) LIGAMENT:

- A strong triangular ligament.
- Apex: attached to medial malleolus.
- Base: subdivided into 4 parts:
  1. Anterior tibiotalar part.
  2. Tibionavicular part.
  3. Tibiocalcaneal part.
  4. Posterior tibiotalar part.



## LATERAL LIGAMENT:

- Composed of 3 separate ligaments (**WHY?**).
- Anterior talofibular ligament.
- Calcaneofibular ligament.
- Posterior talofibular ligament.





# MOVEMENTS

## DORSIFLEXION:

- Performed by muscles of anterior compartment of leg (*tibialis anterior, extensor hallucis longus, extensor digitorum longus & peroneus tertius*).

## PLANTERFLEXION:

- Initiated by soleus.
- Maintained by gastrocnemius.
- Assisted by other muscles in posterior compartment of leg (*tibialis posterior, flexor digitorum longus & flexor hallucis longus*) + muscles of lateral compartment of leg (*peroneus longus & peroneus brevis*).

**N.B.**

□ **INVERSION & EVERSION MOVEMENTS** occur  
*at the talo-calcaneo-navicular joint.*

# HIP JOINT

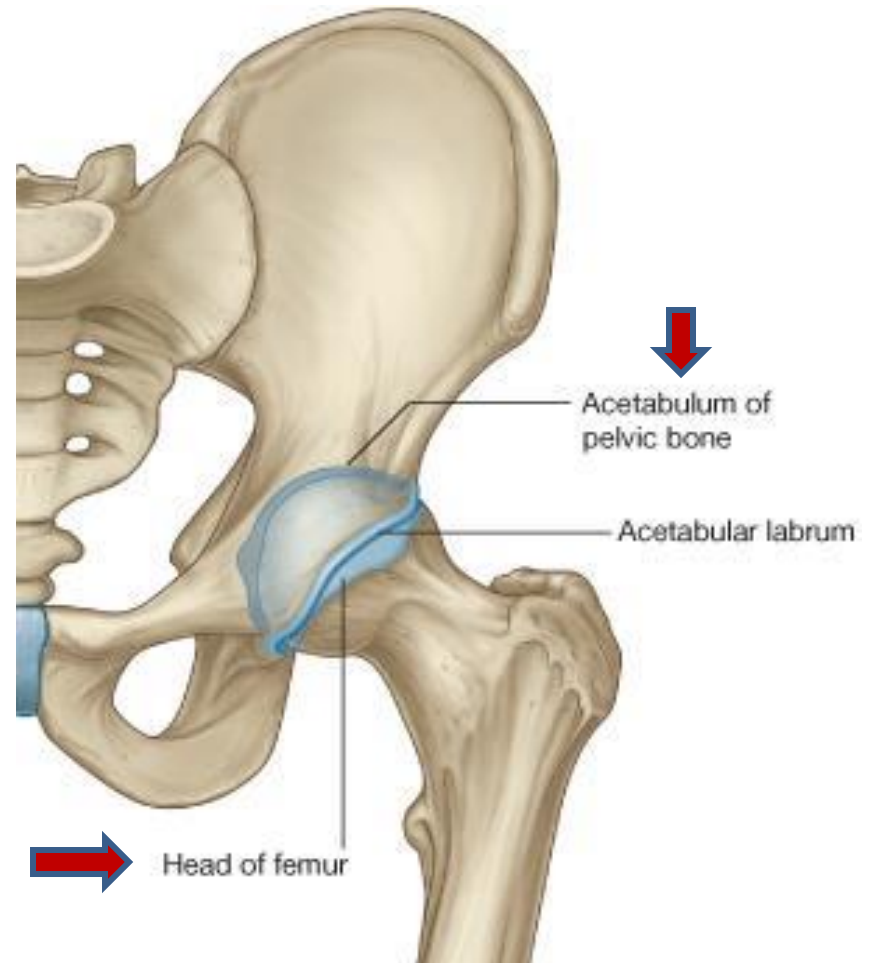
# OBJECTIVES

**At the end of the lecture, students should be able to:**

- *List the type & articular surfaces of hip joint.*
- *Describe the ligaments of hip joints.*
- *Describe movements of hip joint.*

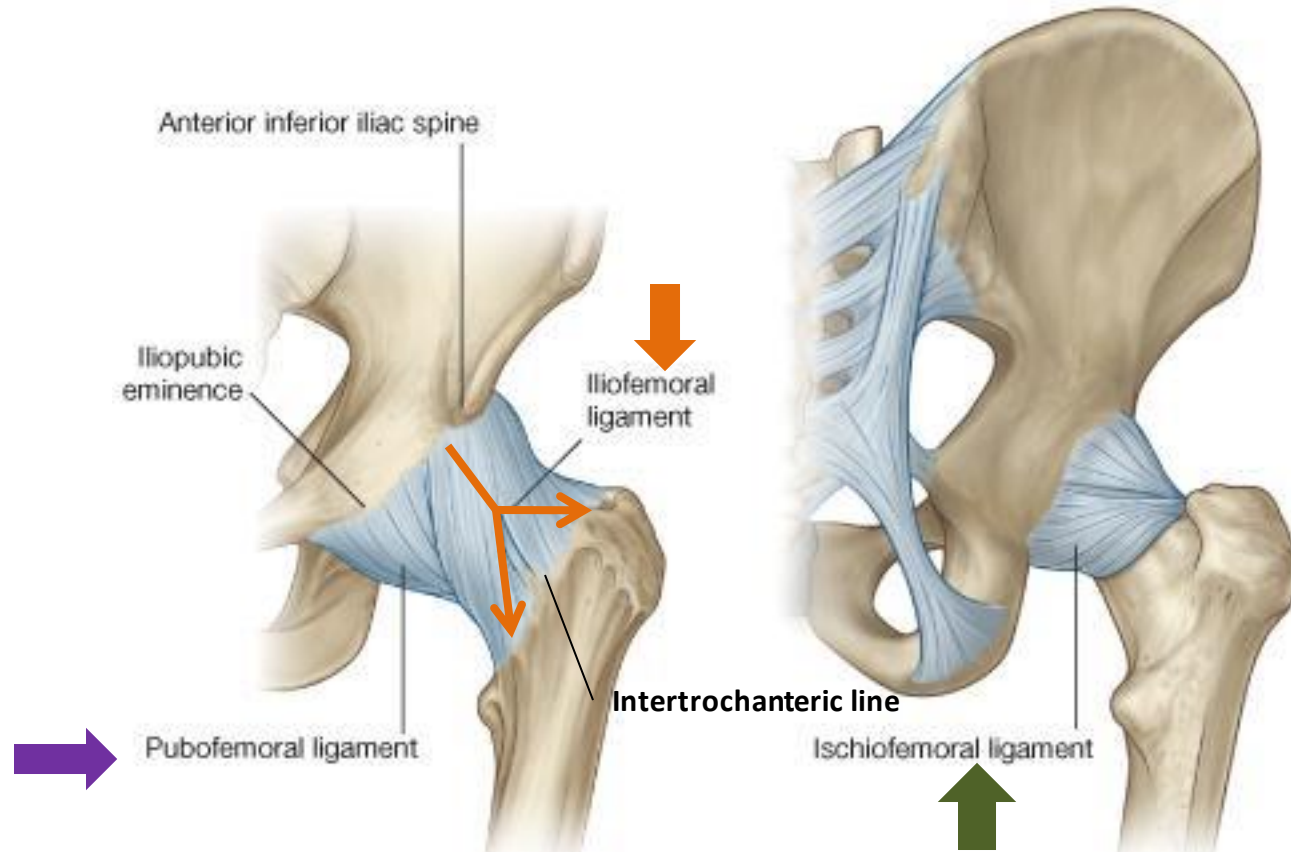
# TYPES & ARTICULAR SURFACES

- **TYPE:**
  - It is a synovial, ball & socket joint.
- **ARTICULAR SURFACES:**
  - **Acetabulum of hip (pelvic) bone**
  - **Head of femur**



# LIGAMENTS

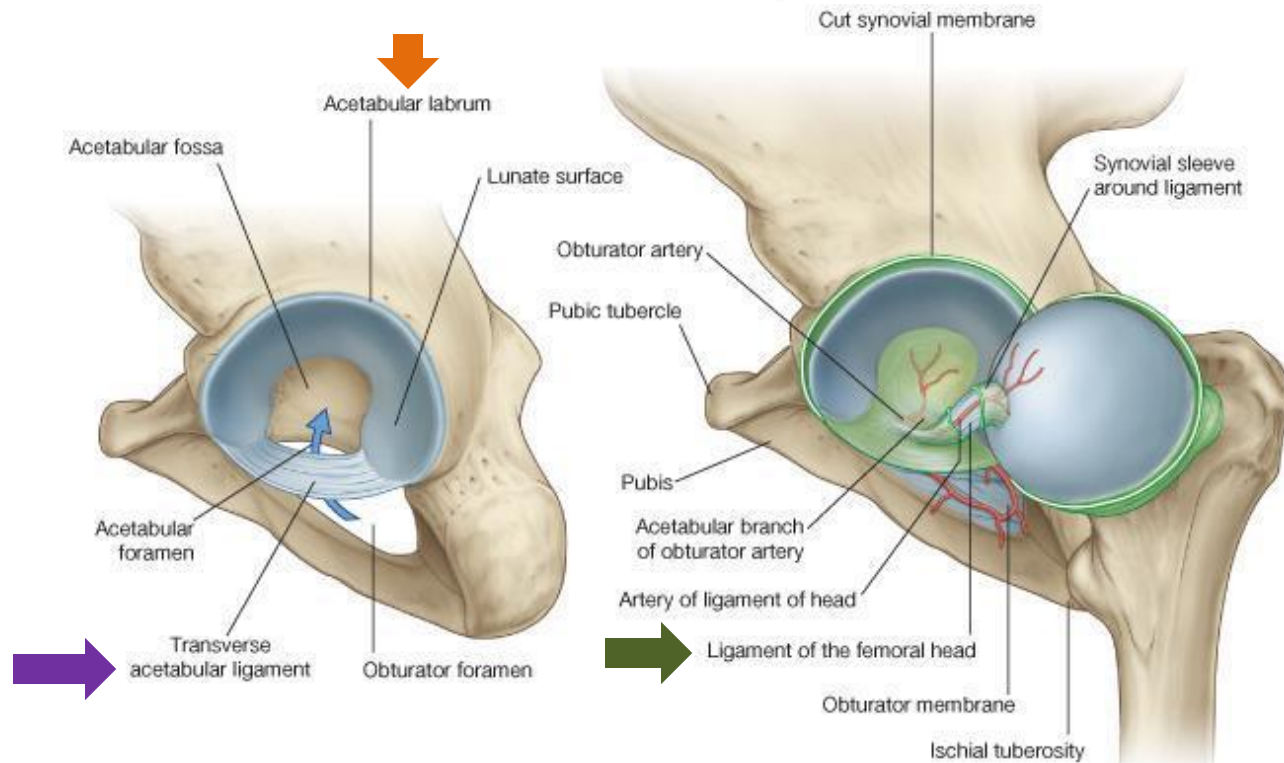
## *(3 Extracapsular)*



- **Iliofemoral ligament:** Y-shaped, anterior to joint, limits extension
- **Pubofemoral ligament:** antero-inferior to joint, limits abduction & lateral rotation
- **Ischiofemoral ligament:** posterior to joint, limits medial rotation

# LIGAMENTS

## (3 Intracapsular)



- **Acetabular labrum:** fibro-cartilaginous collar attached to margins of acetabulum to increase its depth for better retaining of head of femur.
- **Transverse acetabular ligament:** converts acetabular notch into foramen through which pass acetabular vessels
- **Ligament of femoral head:** carries vessels to head of femur



# MOVEMENTS

- **FLEXION:** Iliopsoas (mainly), sartorius, pectineus, rectus femoris.
- **EXTENSION:** Hamstrings (mainly), gluteus maximus (powerful extensor).
- **ABDUCTION:** Gluteus medius & minimus, sartorius.
- **ADDUCTION:** Adductors, gracilis.
- **MEDIAL ROTATION:** Gluteus medius & minimus.
- **LATERAL ROTATION:** Gluteus maximus, quadratus femoris, piriformis, obturator externus & internus.

# QUESTION 1


The muscle that extends the hip & flexes the knee joint is:

1. Gluteus maximus.
2. Quadriceps femoris.
3. Sartorius.
4. Semitendinosus.




## QUESTION 2

The bursa that communicates with the synovial membrane of knee joint is:

1. Suprapatellar. 
2. Prepatellar.
3. Subcutaneous infrapatellar.
4. Deep infrapatellar.

# QUESTION 3

The muscle that dorsiflexes the ankle is:

1. Flexor digitorum longus.
2. Tibialis anterior. 
3. Peroneus brevis.
4. Gastrocnemius.

The image features two large, stylized yellow roses with white and yellow petals, set against a teal background. The roses are positioned on the left and right sides of the frame. The text "THANK YOU" is written in a bold, blue, sans-serif font across the center of the image, overlapping the roses. The entire scene is enclosed in a thin orange border.

**THANK YOU**