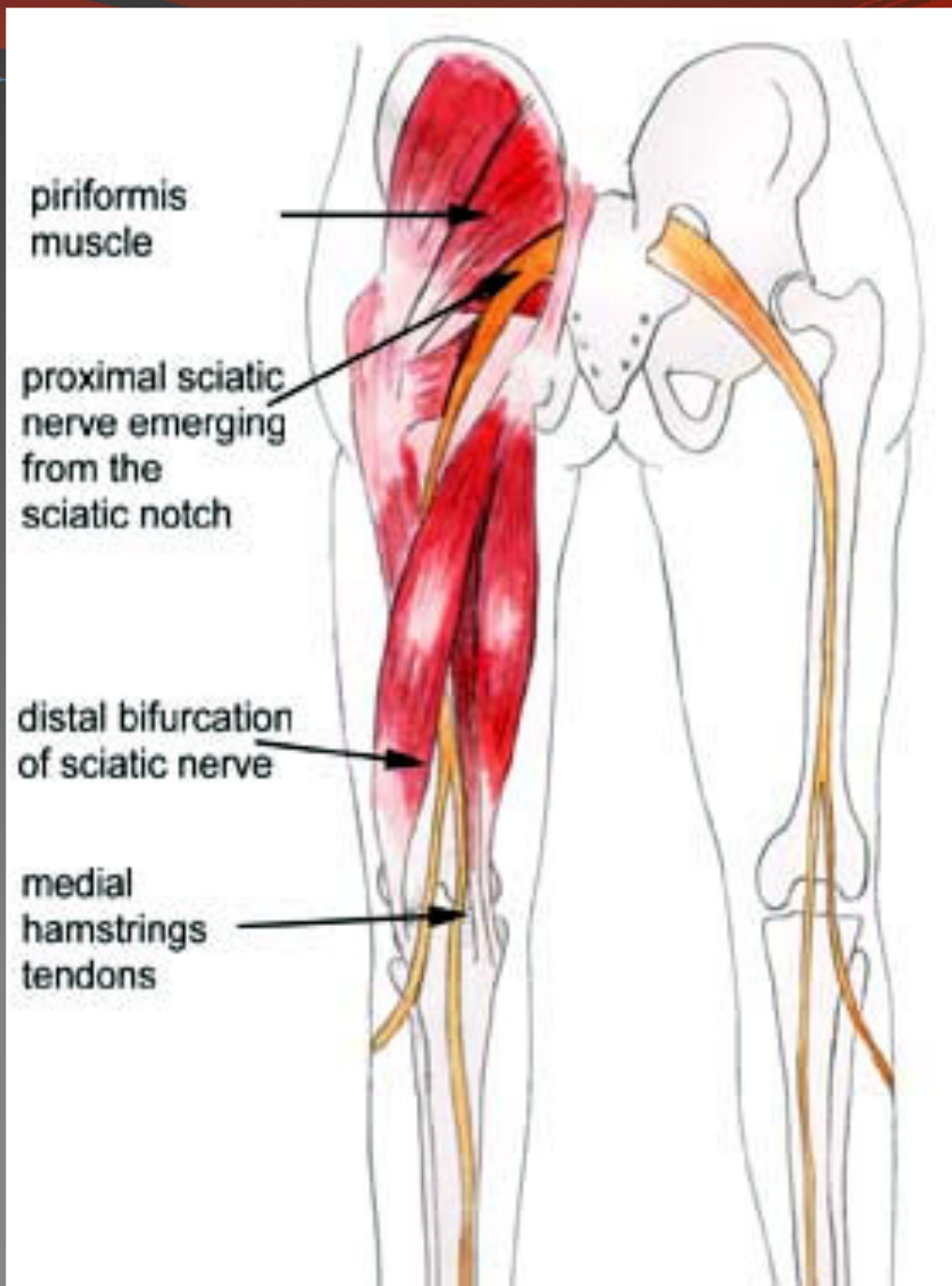


SCIATIC NERVE



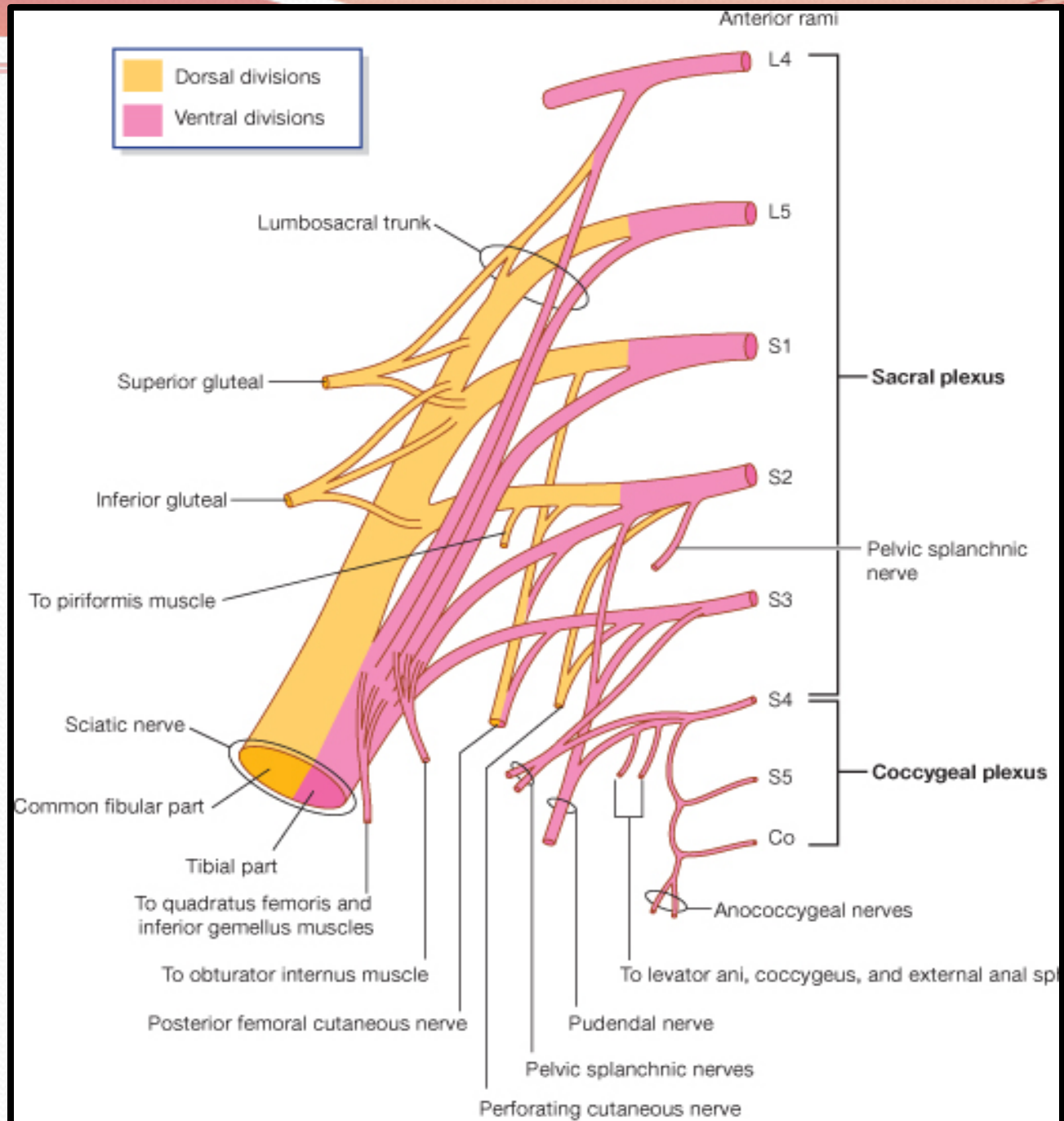
Prof. Saeed Abuel Makarem

OBJECTIVES

- By the end of the lecture, you should be able to:
- Describe the anatomy (origin, course & distribution) of the sciatic nerve.
- List the branches of the sciatic nerve.
- Describe briefly the main motor and sensory manifestations in case of injury of the sciatic nerve or its main branches.

Origin

- ❖ From the Sacral Plexus:
- ❖ (L4,5, S1, 2, 3).
- ❖ It is the largest branch of the plexus.
- ❖ It is the largest nerve of the body.



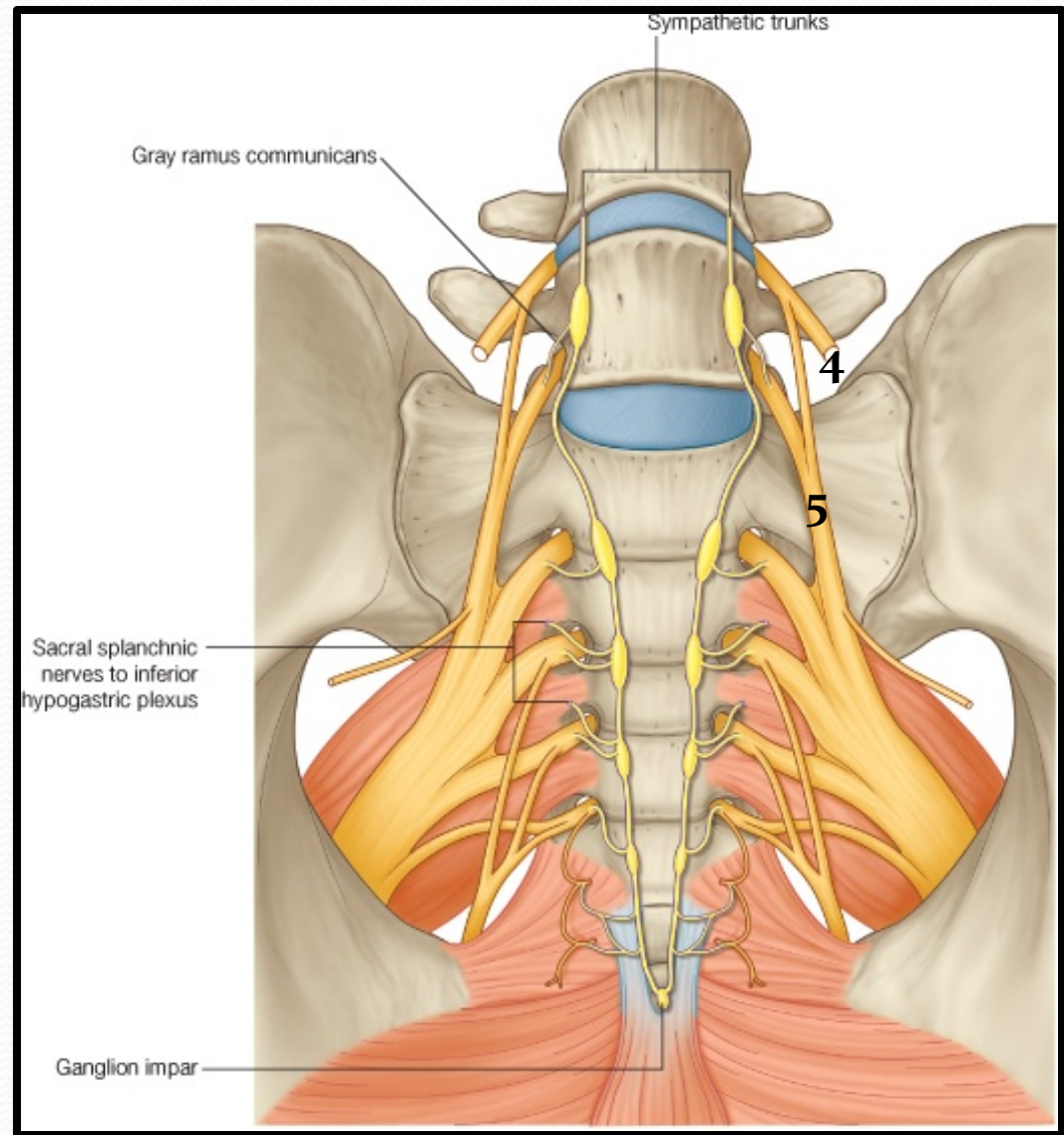
Sacral Plexus

❑ Formation:

- ❑ Ventral (anterior) rami of (L4, 5 S1, 2, 3 & 4).
- ❑ Part of L4 & whole L5 (lumbosacral trunk) + S1,2,3 and most of S4.

❑ Site:

- ❑ On the posterior pelvic wall.
- ❑ In front of Piriformis muscle.



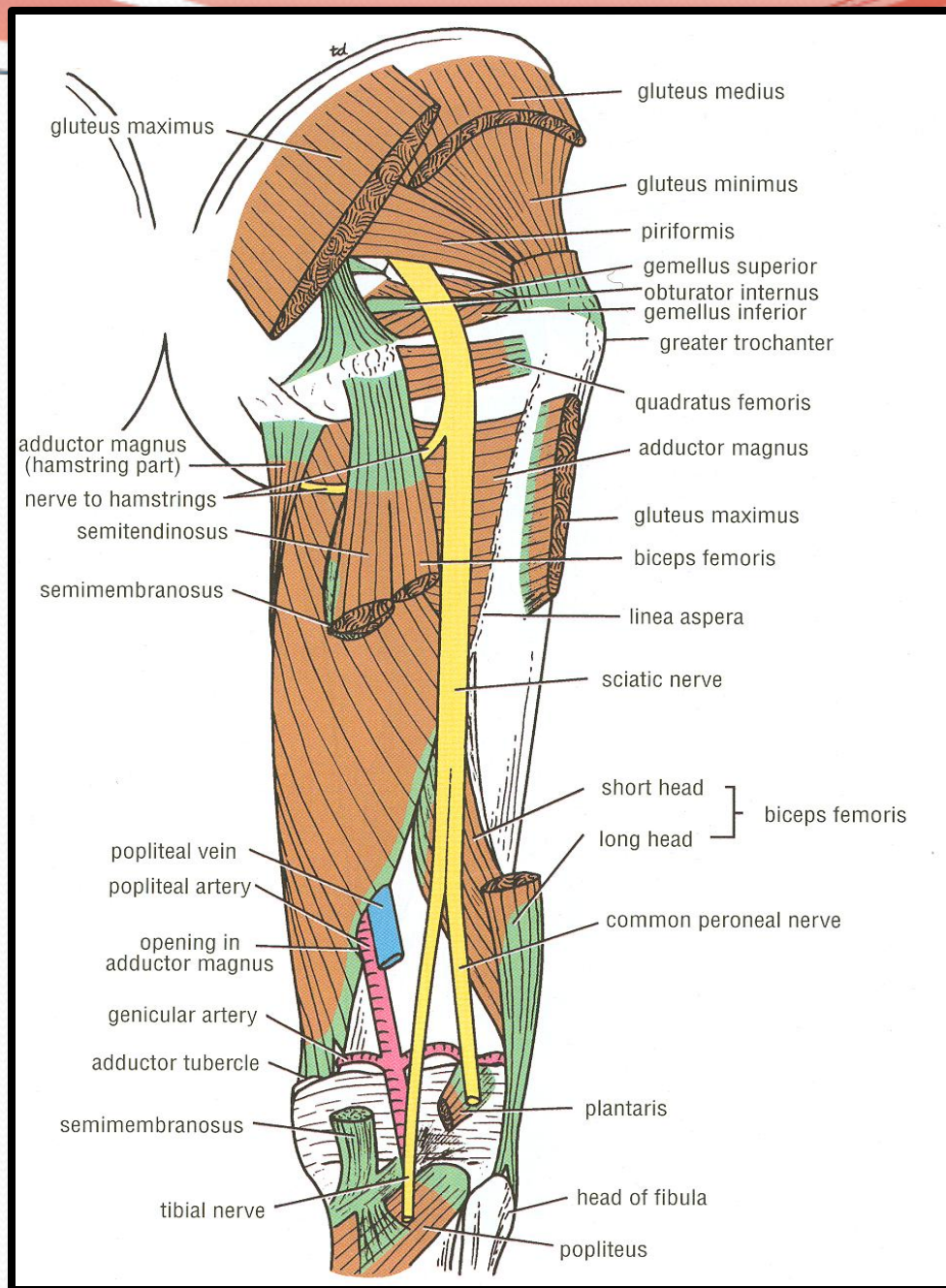
Course & Distribution

- The sciatic nerve leaves the pelvis through greater sciatic foramen, below piriformis muscle.
- It passes in the gluteal region midway (between ischial tuberosity & greater trochanter).
- Then it enters the posterior compartment of the thigh.

➤ Termination:

In the middle of the back of the thigh it divides into 2 terminal branches:

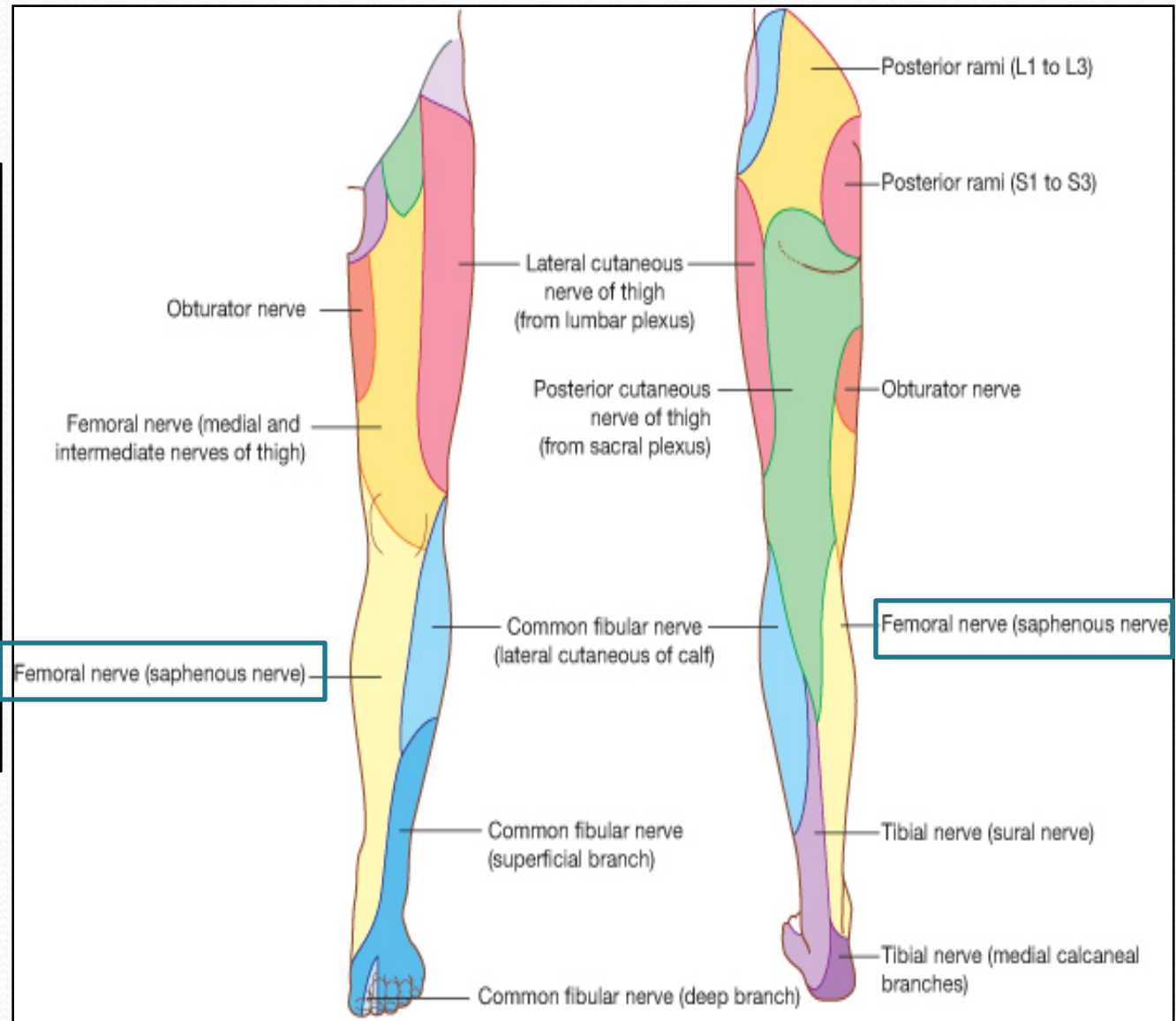
- **Tibial** (medial popliteal).
- **Common Peroneal**, or lateral popliteal or (**Fibular**).



Branches of Sciatic Nerve

1. Cutaneous:

- To all leg & foot **EXCEPT:** areas supplied by **saphenous nerve** (branch of femoral nerve).



❑ 2. Muscular:

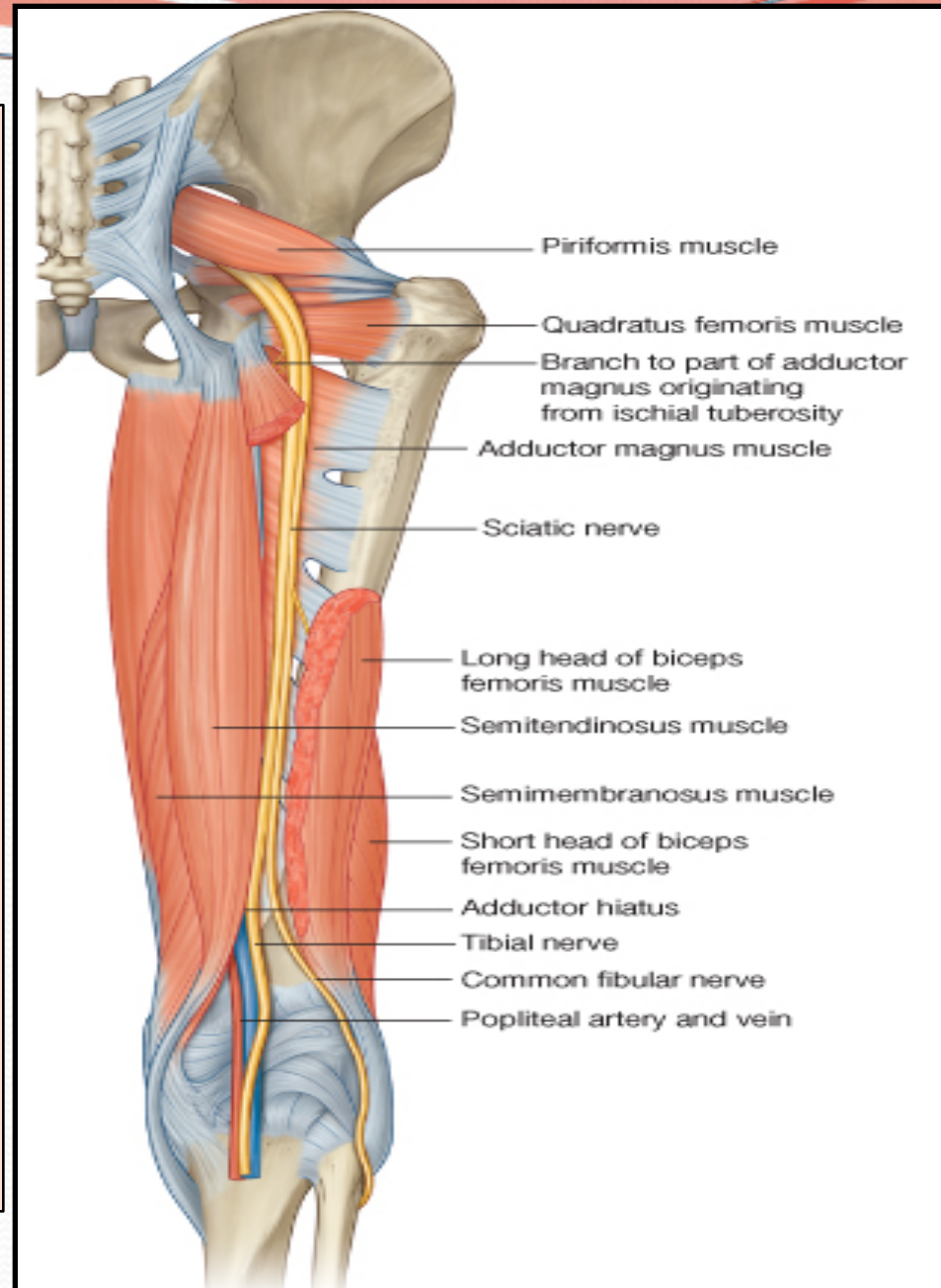
• To Hamstrings:

(flexors of knee & extensors of the hip).

(through tibial part) to:

1. Long head of Biceps Femoris.
2. Semitendinosus.
3. Semimembranosus.
4. Hamstring part of Adductor Magnus.

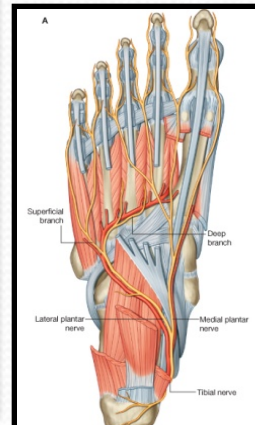
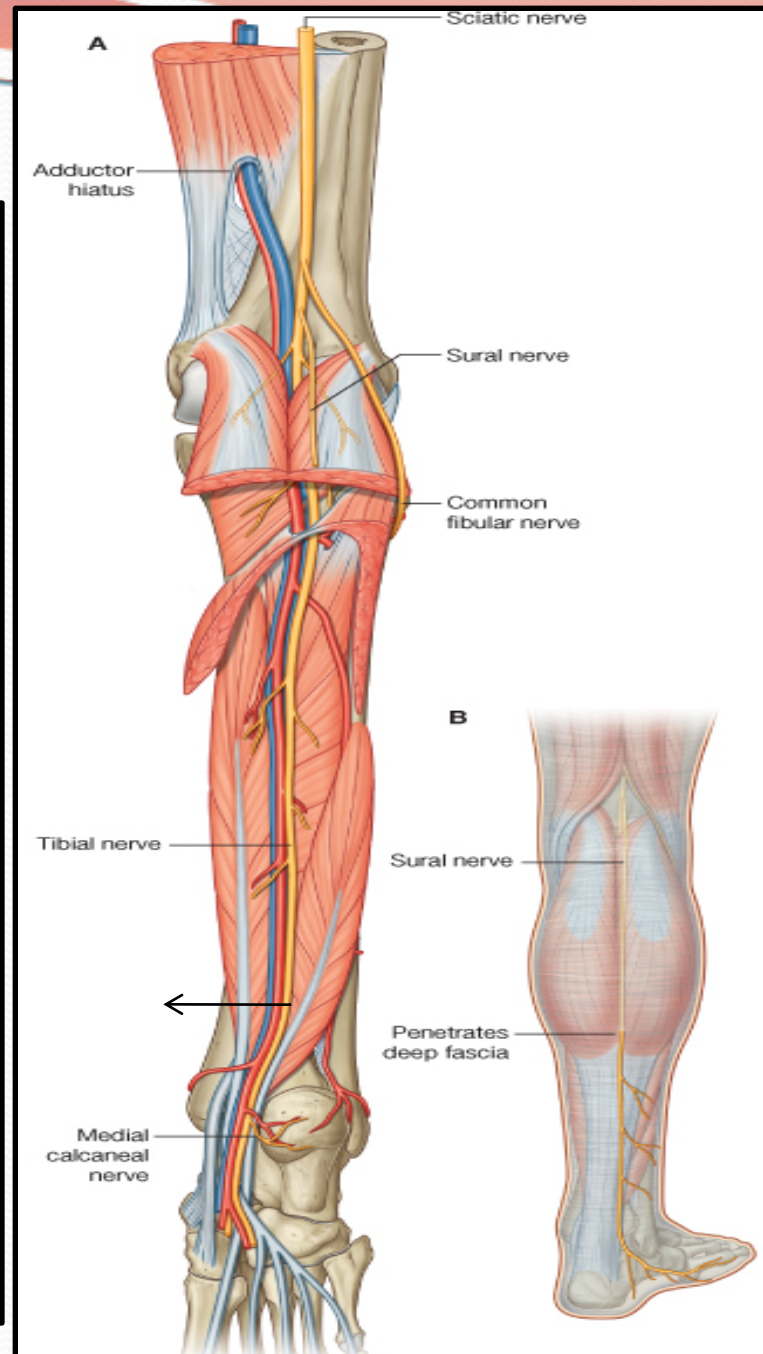
NB. The short head of biceps receives its branch from the lateral popliteal (common peroneal) nerve.



Tibial Nerve

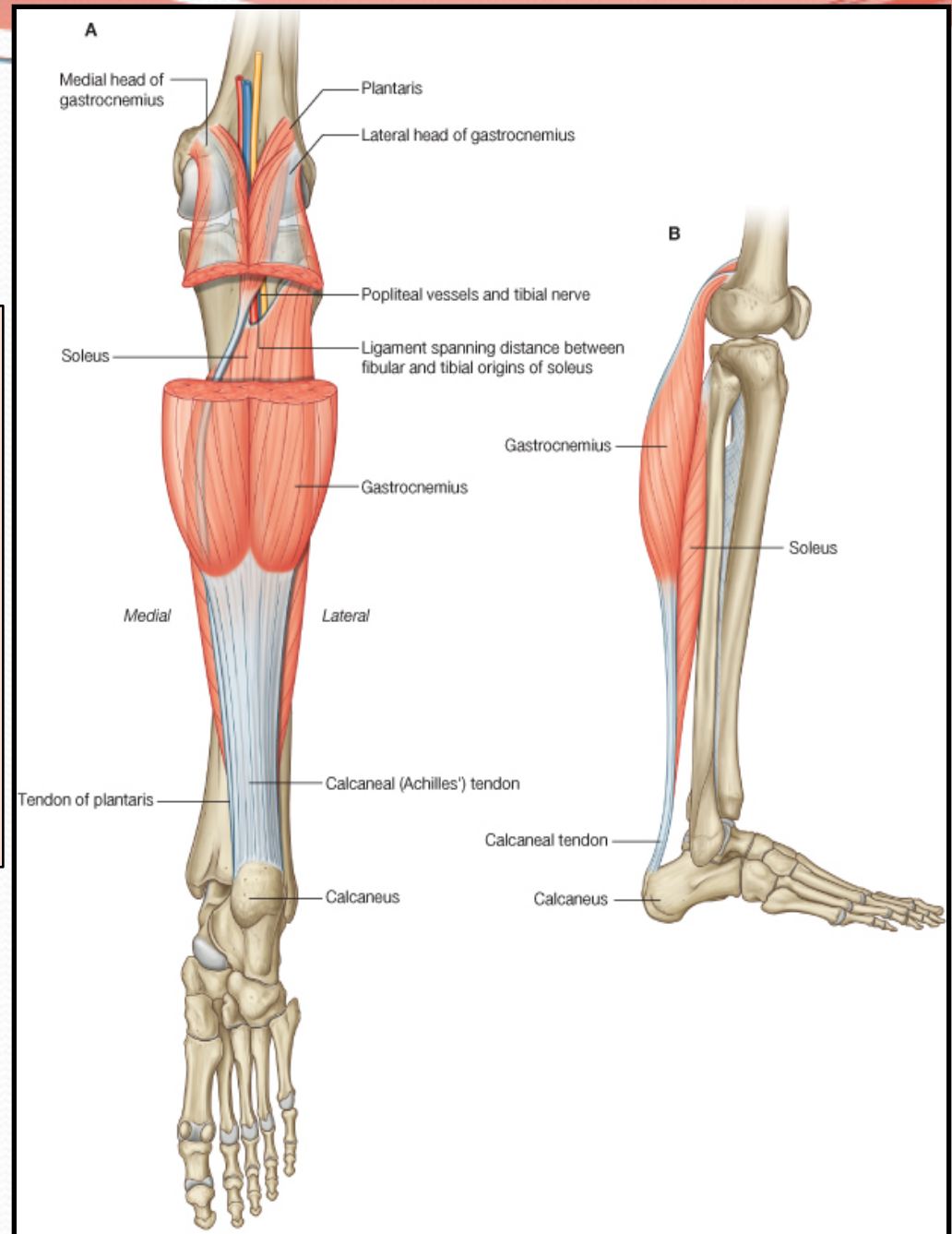
□ Course:

- Bisect the popliteal fossa.
- Then descends through posterior compartment of the leg.
- Accompanied with posterior tibial vessels.
- Passes deep to flexor retinaculum (through the tarsal tunnel, behind **medial malleolus**) to reach the sole of foot.
- In the sole it divides into **2 terminal branches**:
- **Medial planter nerve.**
- **Lateral planter nerve.**



Muscular Branches

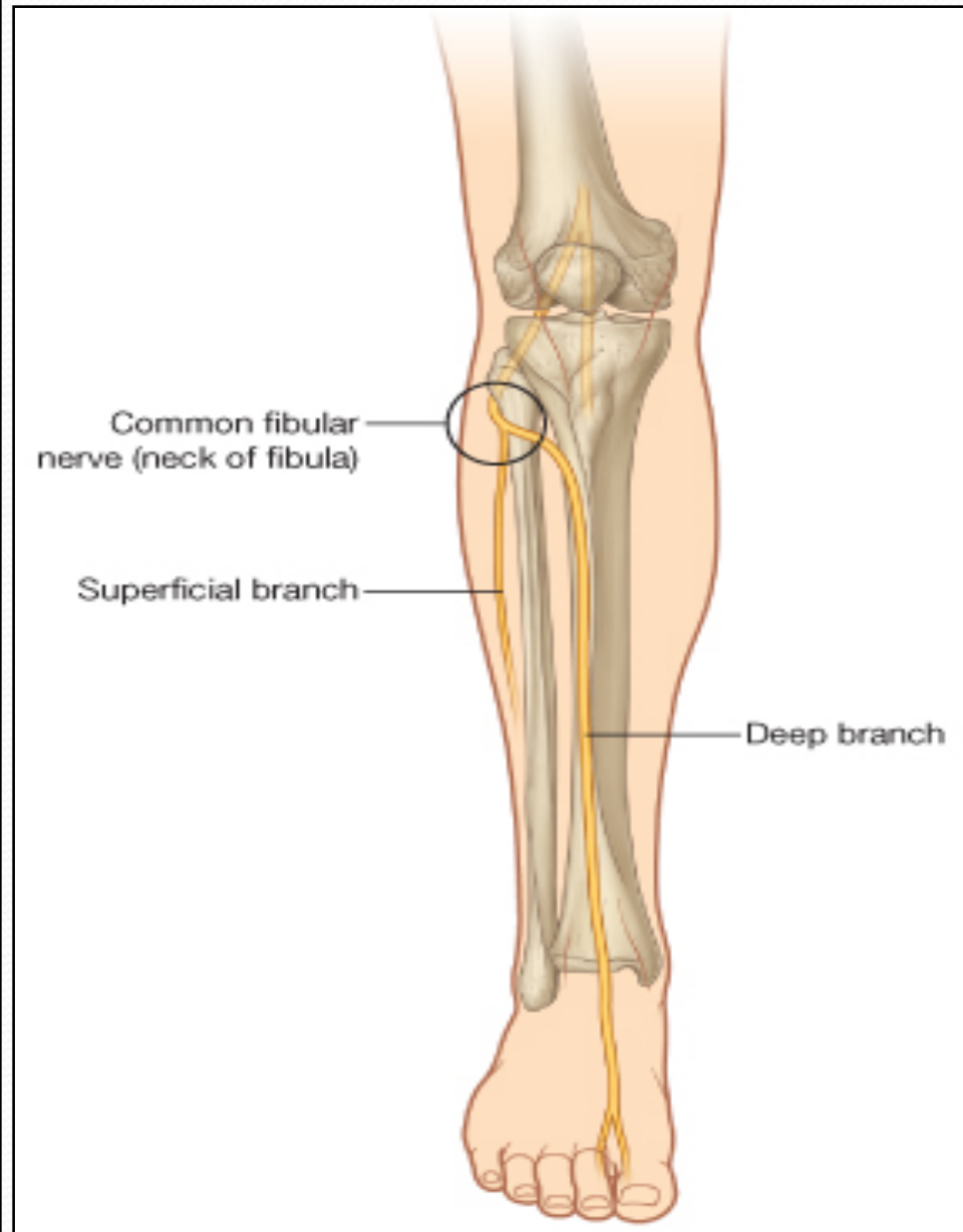
1. Muscles of posterior compartment of leg (Planter flexors of the ankle, Flexors of toes).
2. Intrinsic muscles of sole.
3. ONE invertor of the foot (tibialis posterior).



Common Peroneal or Lateral Popliteal (Fibular) Nerve

□ Course:

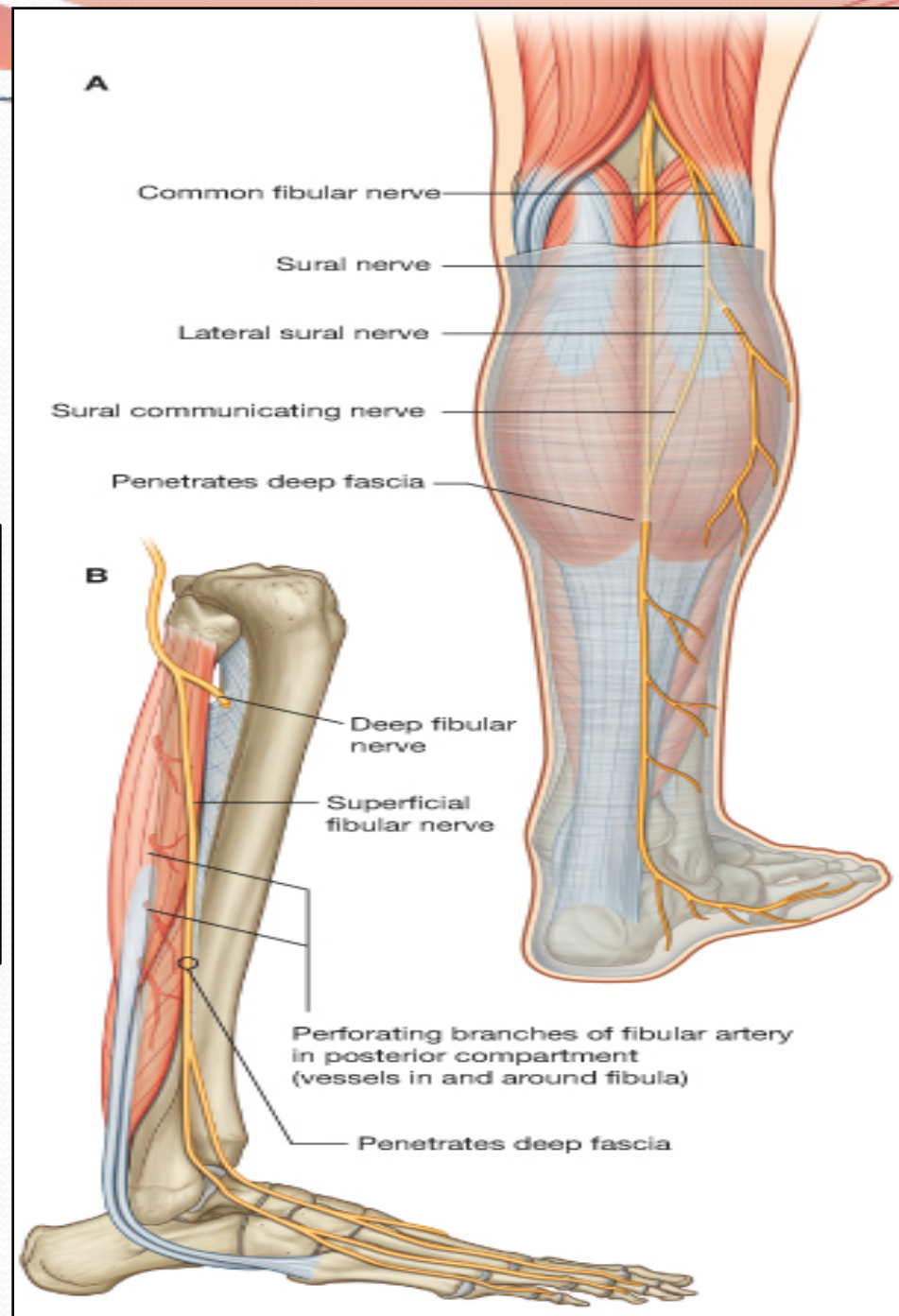
- Inters the popliteal fossa through its upper angle.
- Leaves the fossa through its lateral angle.
- It turns around the **lateral aspect of neck of the fibula**, (Dangerous Position).
- It enters the upper part of the substance of peroneus longus muscle where it divides into:
 - Superficial peroneal or (Musculocutaneous):
which supply the **Lateral** compartment of the leg.
 - Deep peroneal or (Anterior Tibial):
which supply the **Anterior** compartment of the leg.



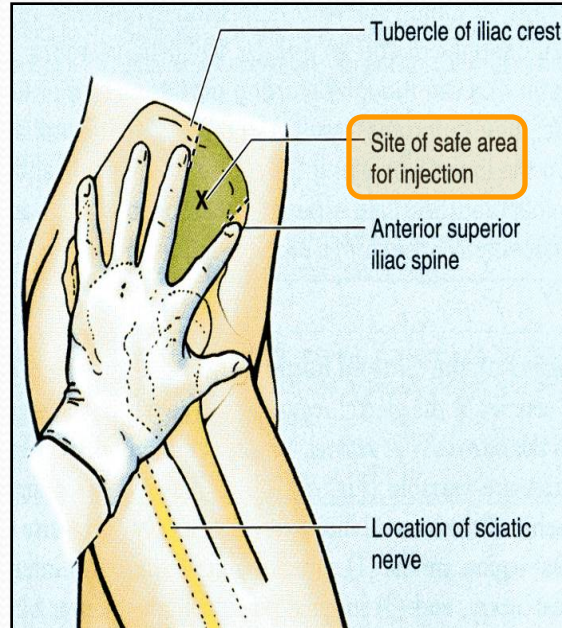
Muscular Branches

To the muscles of anterior & lateral compartments of leg:

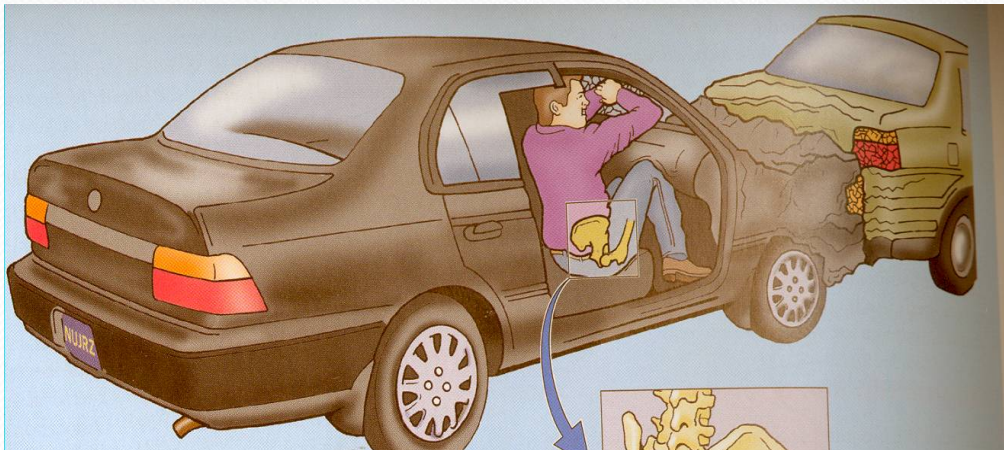1. Dorsi flexors of ankle,
2. Extensors of toes,
3. Evertors of foot.



CAUSES OF SCIATIC NERVE INJURY



II-Posterior dislocation of the hip joint

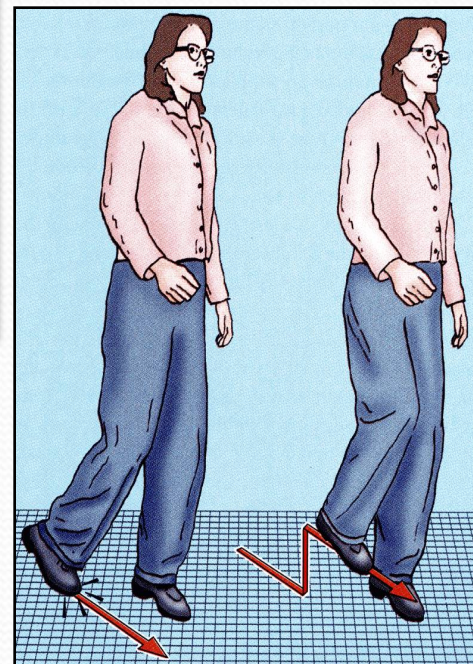
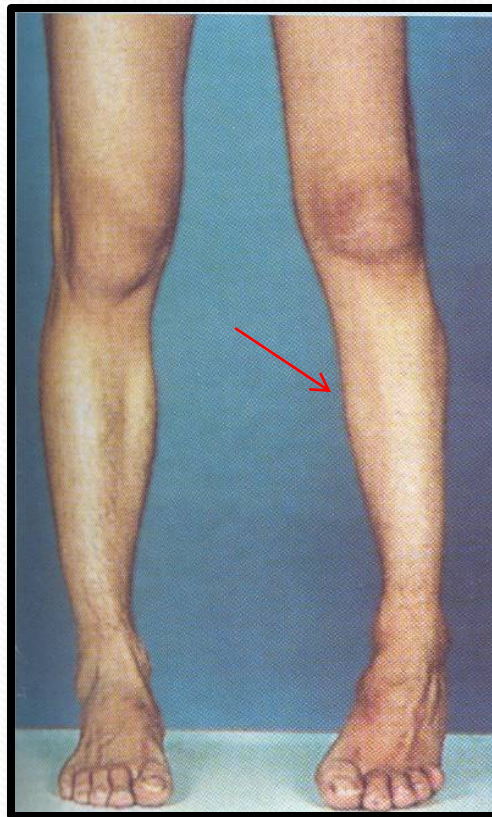


- The sciatic nerve is *most frequently injured* by...?
I- Badly placed intramuscular injections in the gluteal region.
- To avoid this, injections should be done into the gluteus maximus or medius (into the **upper outer quadrant of buttock**).
- *Most nerve lesions are incomplete, and in 90 % of injuries, the common peroneal nerve is the mostly affected. Why?*
 - The common peroneal nerve fibers lie **superficial within** the sciatic nerve.

SCIATIC NERVE INJURY

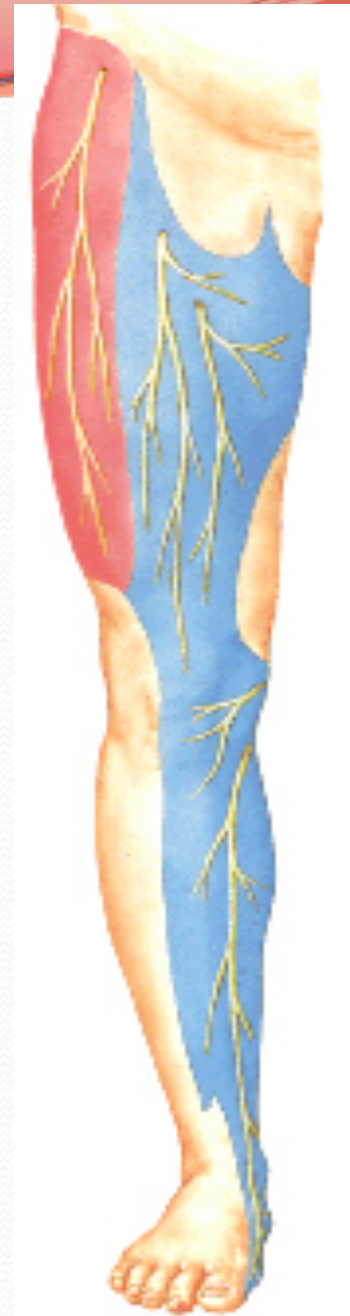❑ MOTOR EFFECT:

- Marked wasting of the muscles below the knee.
- **Weak flexion of the knee** (sartorius & gracilis are intact).
- **Weak extension of hip** (gluteus maximus is intact).
- All the muscles below the knee are paralyzed, and the weight of the foot causes it to assume the *plantar-flexed position*, or *Foot Drop*.
- (*High steppage gait*).



Sensory Loss

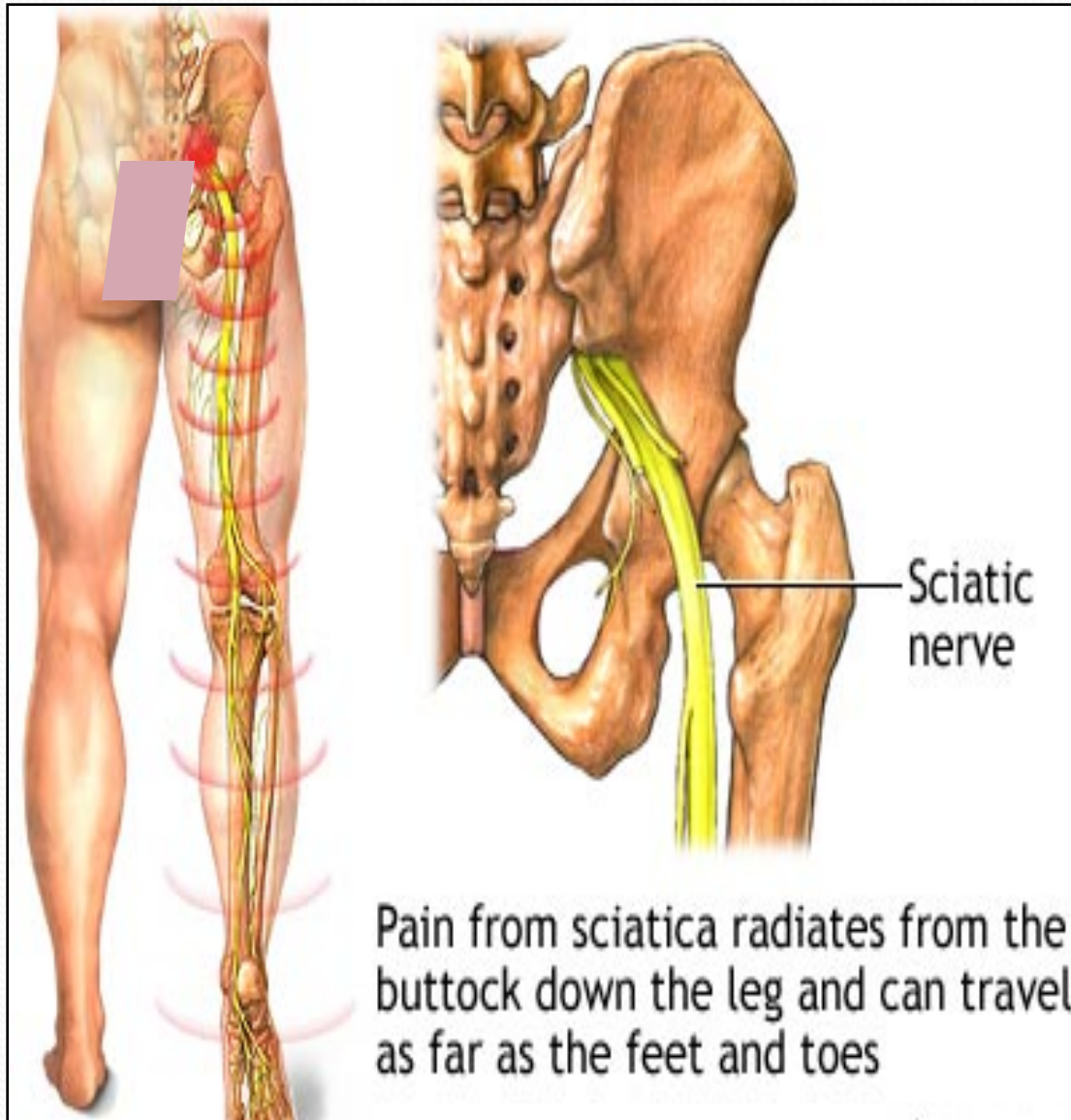
- Sensation is lost *below the knee*, **EXCEPT**, for a **narrow area down the medial side of the lower part of the leg (blue)** and along the medial border of the foot as far as the ball of the big toe, which are supplied by the saphenous nerve (femoral nerve).



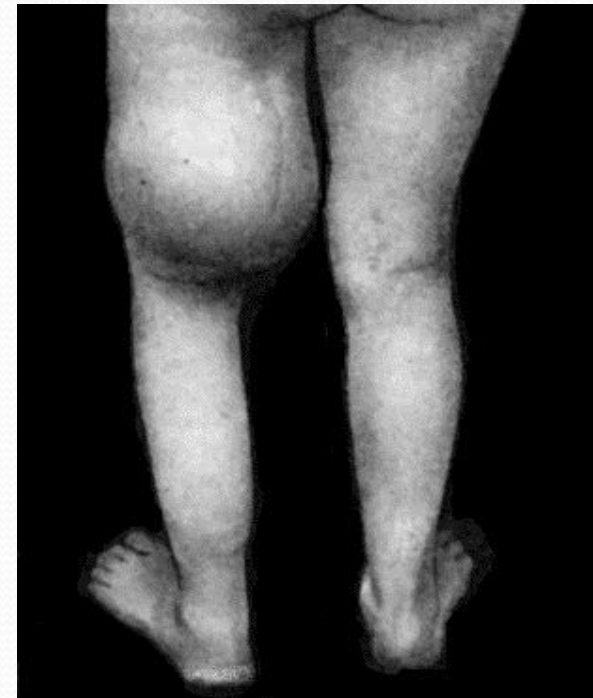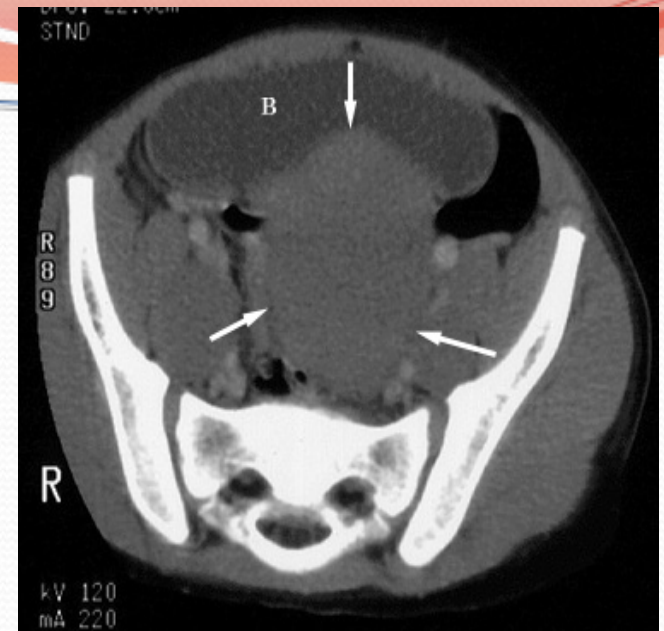
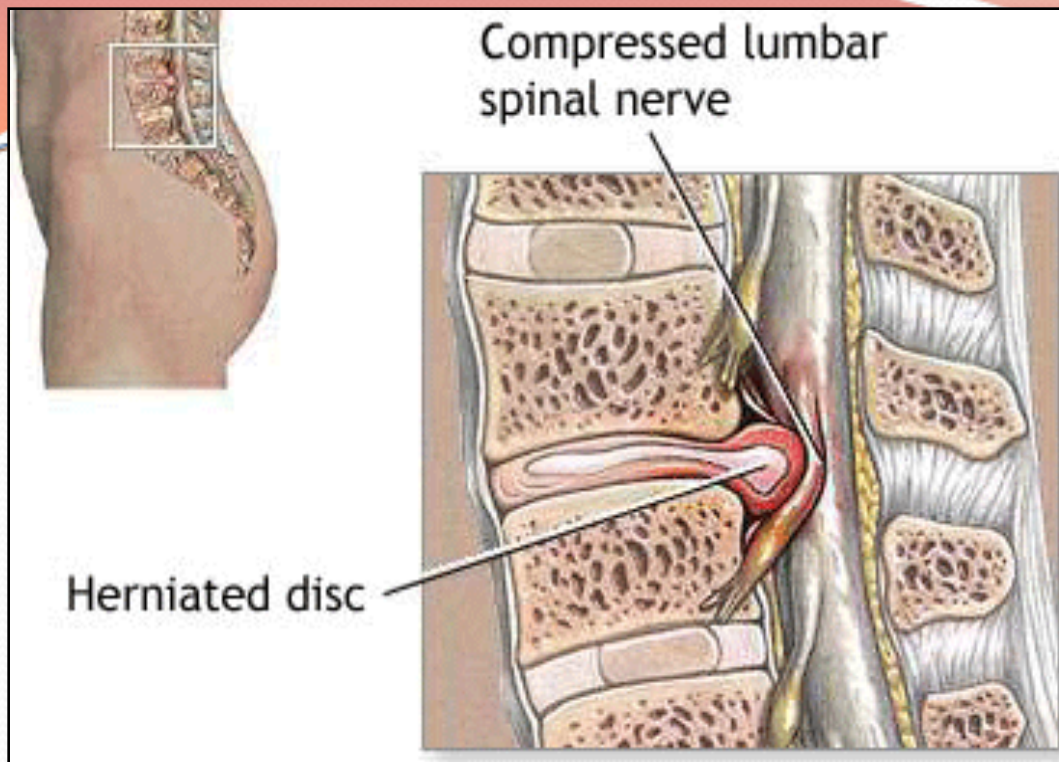
EFFECT OF SCIATIC NERVE INJURY

MOTOR EFFECT	Paralysis of	Movements affected
	<u>Hamstrings</u>	Flexion of knee & Extension of hip
	<u>All muscles of Leg & Foot</u>	All movements of the <u>leg & Foot</u>
SENSORY EFFECT	Loss of sensation of the areas supplied by sciatic nerve (below knee).	EXCEPT: area supplied by the (Saphenous nerve).

SCIATICA



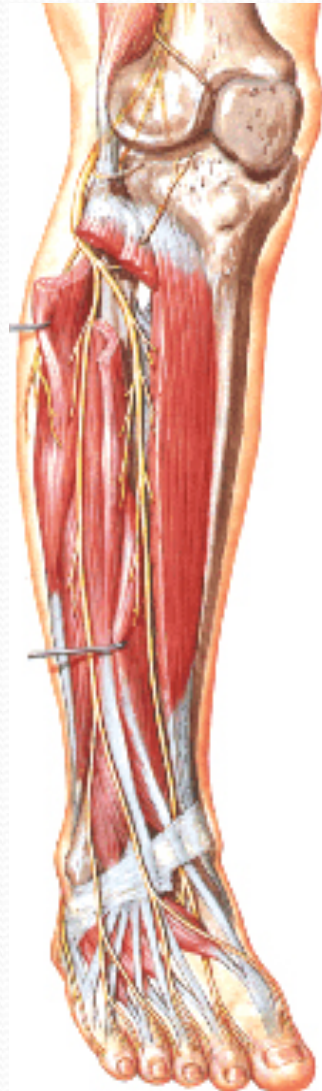
- Sciatica describes the condition in which patients have *pain along the sensory distribution of the sciatic nerve*.
- Thus the pain is experienced in the posterior aspect of the thigh, the posterior and lateral sides of the leg, and the lateral part of the foot.



Causes of Sciatica:

- Prolapse of an intervertebral disc, with pressure on one or more of the roots of the lower lumbar and sacral spinal nerves,
- Pressure on the sacral plexus or sciatic nerve by an intrapelvic tumor,
- Inflammation of the sciatic nerve or its terminal branches.

Common Peroneal Nerve Injury

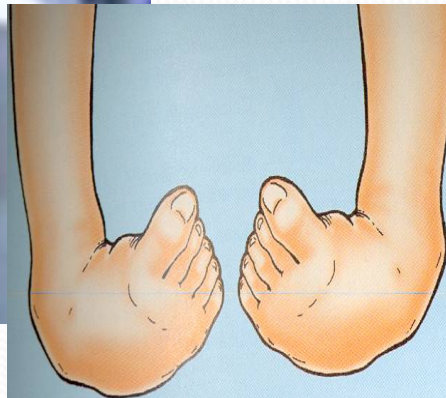
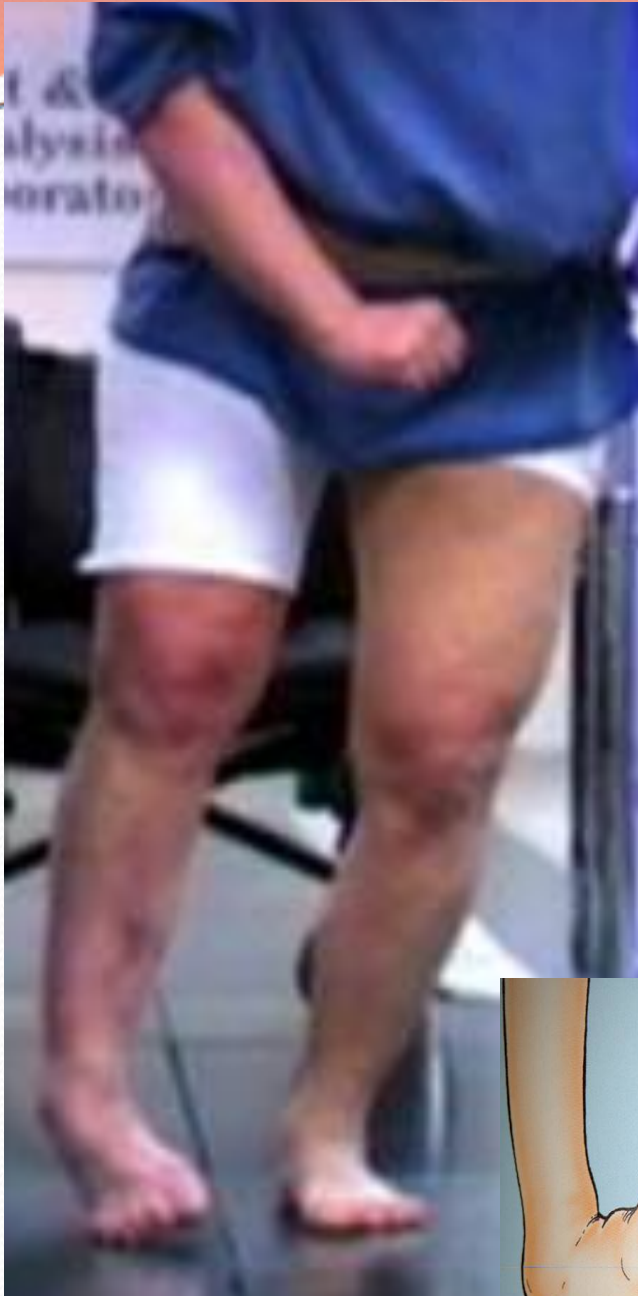

The **common peroneal nerve** lies in an **exposed position** as it leaves the popliteal fossa through its lateral angle. Then it winds around neck of the fibula to enter the substance of peroneus longus muscle, **(Dangerous Position) !!!**.



The common peroneal nerve is commonly injured In **Fractures** of the neck of the fibula and By **pressure** from low casts or splints.

Manifestations of Common Peroneal Nerve Injury



- The following clinical features are present:
 - **Motor:**
 - *The muscles of the anterior and lateral compartments of the leg are paralyzed,*
 - As a result, the opposing muscles, the plantar flexors of the ankle joint and the invertors of the subtalar joints, *cause the foot to be **Plantar Flexed (Foot Drop) and Inverted***, an attitude referred to as **Talipes Equinovarus.**

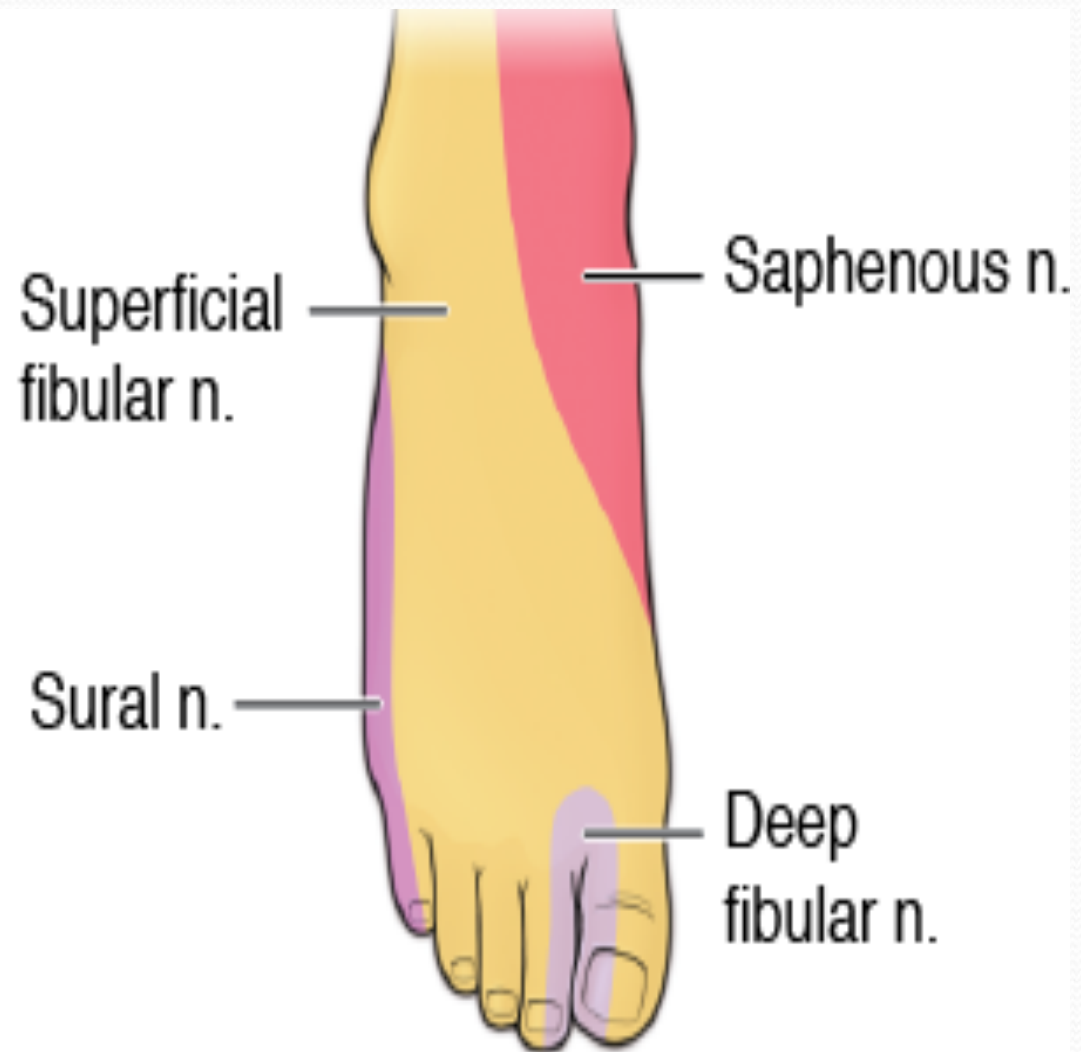
Common Peroneal Nerve Injury

Sensory

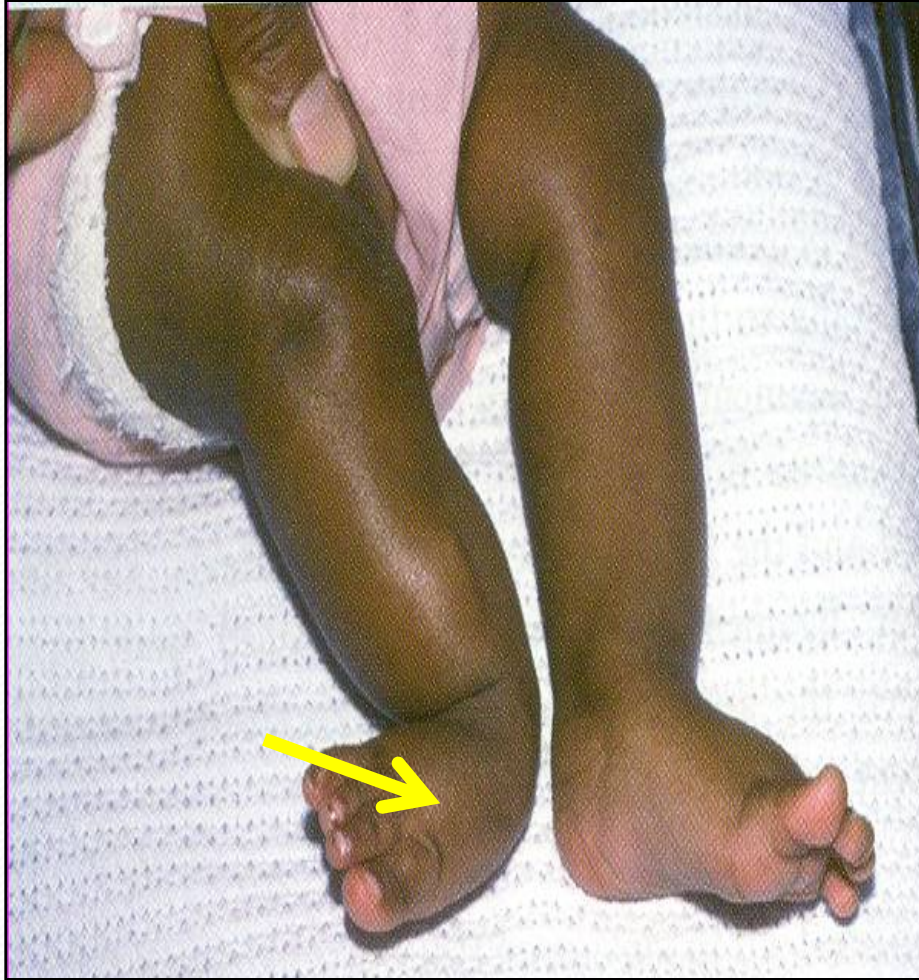Sensation is lost between the first and second toes.

Dorsum of the foot and toes.

Medial side of the big toe.



Tibial Nerve Injury



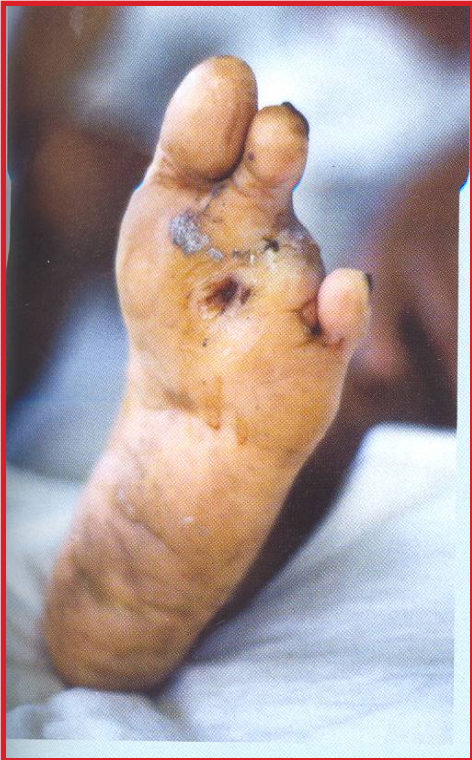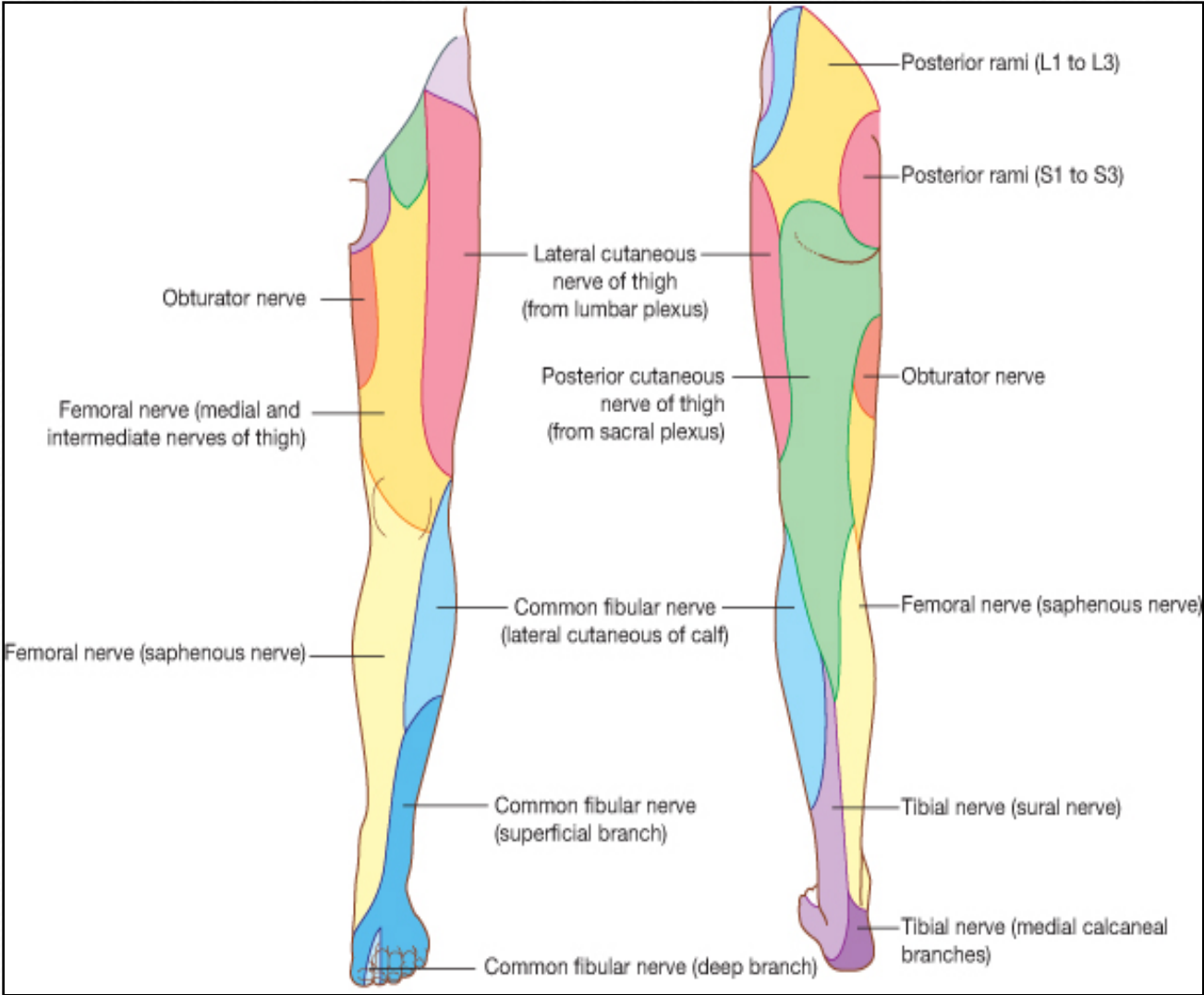
- Because of its deep and protected position, the tibial nerve is rarely injured.
- **Complete** division results in the following clinical features:
- **Motor:**
- All the muscles in the back of the leg and the sole of the foot are paralyzed.
- The opposing muscles *Dorsiflex* the foot at the ankle joint and *Evert the foot* at the subtalar joint, an attitude referred to as **Talipes Calcaneovalgus.**

Sensory loss:

On the Lateral side of the leg and foot (sural nerve).

trophic ulcers in the sole.

Tibial Nerve Injury





**THANK YOU AND
GOOD LUCK**