

# CARTILAGE & BONE

---

## Objectives:

- By the end of this lecture, the student should describe the microscopic structure, distribution and growth of the different types of:
  - (1) Cartilage.
  - (2) Bone.

# CARTILAGE

---

- Cartilage is a specialized type of C.T. with a rigid matrix.
- Cartilage is **usually** nonvascular (avascular).
- **3 Types:**
  - Hyaline cartilage.
  - Elastic cartilage.
  - Fibrocartilage.

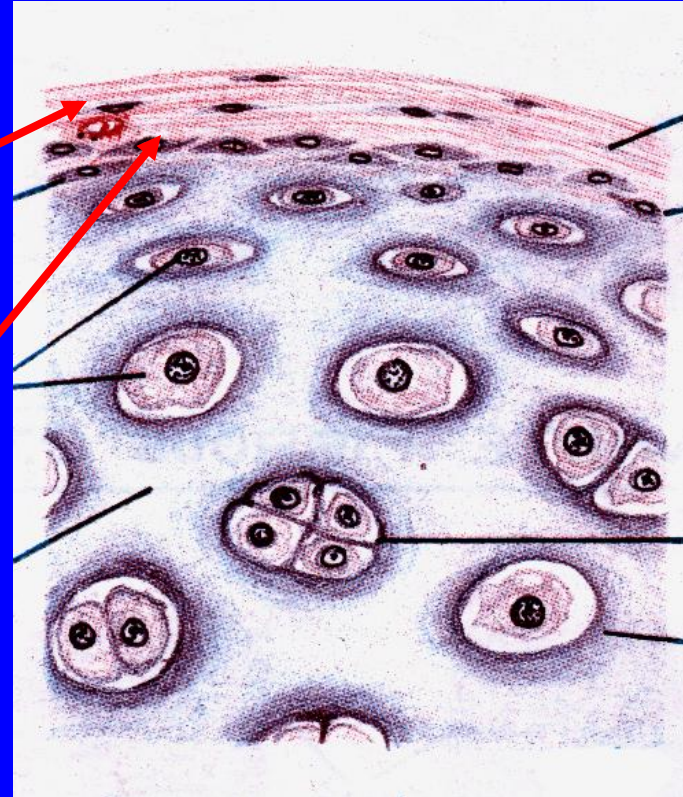
# Hyaline Cartilage

## 1- Perichondrium:

– Vascular C.T. membrane formed of 2 layers:

» Outer fibrous layer:  
dense fibrous C.T.

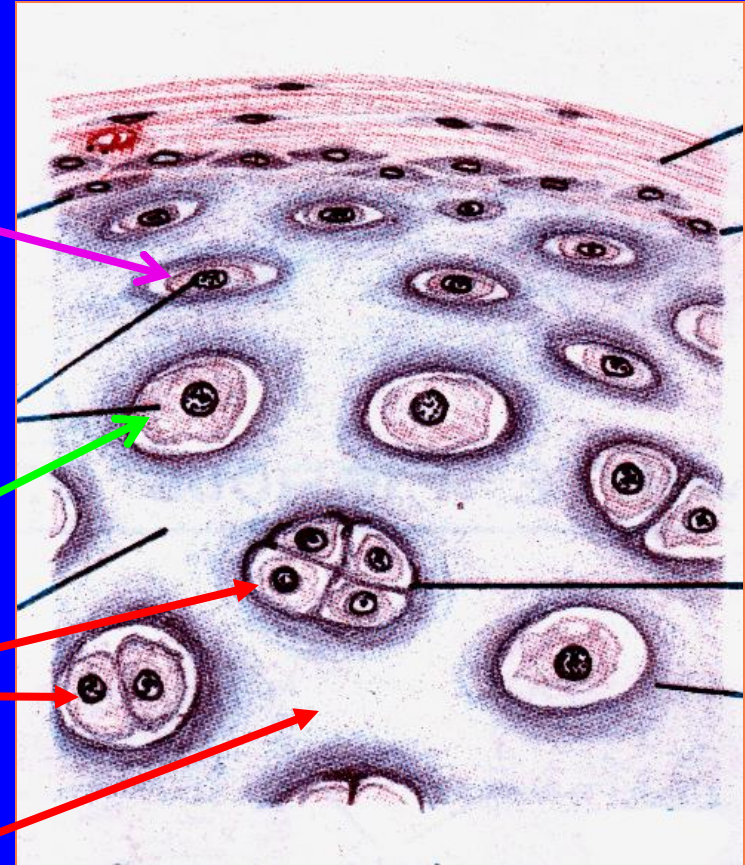
» Inner chondrogenic layer:  
contains chondroblasts (no lacunae). They secrete cartilage matrix and give rise to chondrocytes.



# Hyaline Cartilage

## 2- Cells (Chondrocytes):

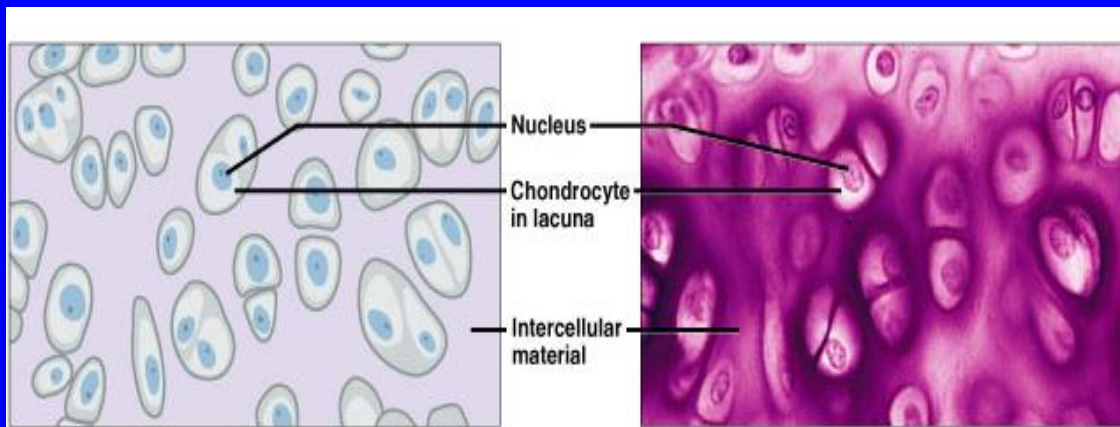
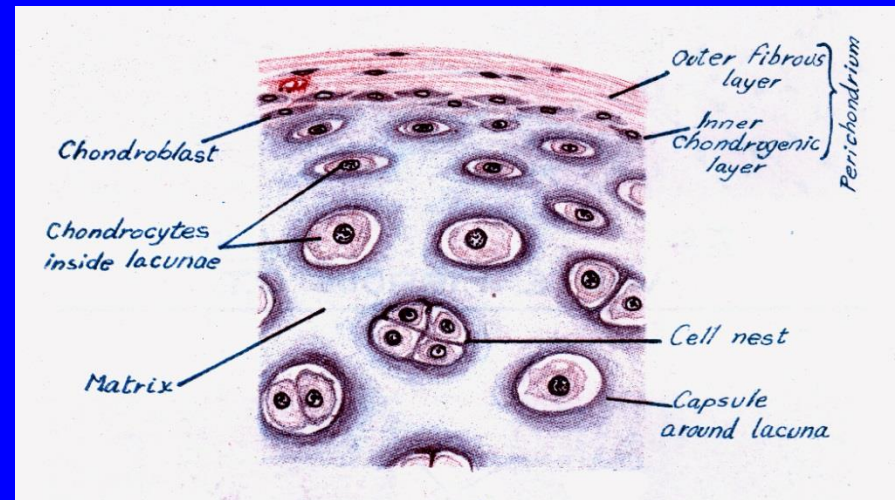
- Found in spaces called lacunae.
- **Young chondrocytes:** are small & present singly in their lacunae.
- **Mature chondrocytes:** are large, and are found **singly** or in groups of 2, 4 or 6 cells in their lacunae (cell nests).



## 3- Matrix:

- Homogeneous and **basophilic**.
- Contains **collagen type II**.

# Hyaline Cartilage



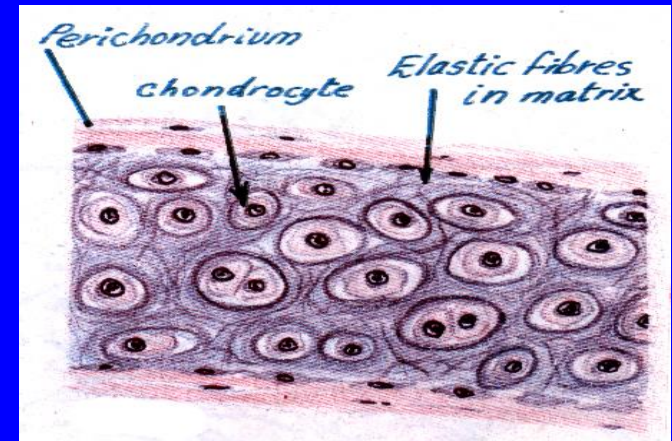
# Hyaline Cartilage

---

- Sites of hyaline cartilage:
  - Foetal skeleton.
  - Costal cartilages.
  - Articular surfaces of bones.
  - Nose, trachea & bronchi.

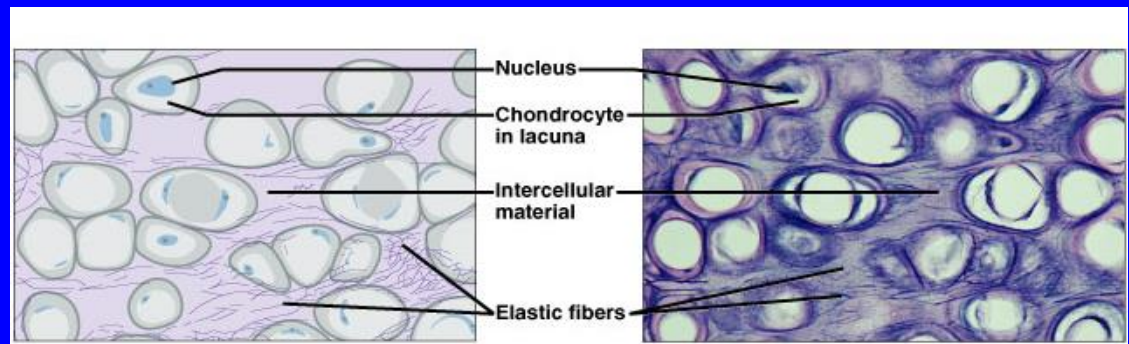
# Elastic Cartilage

- Similar to hyaline cartilage + elastic fibres in the matrix.



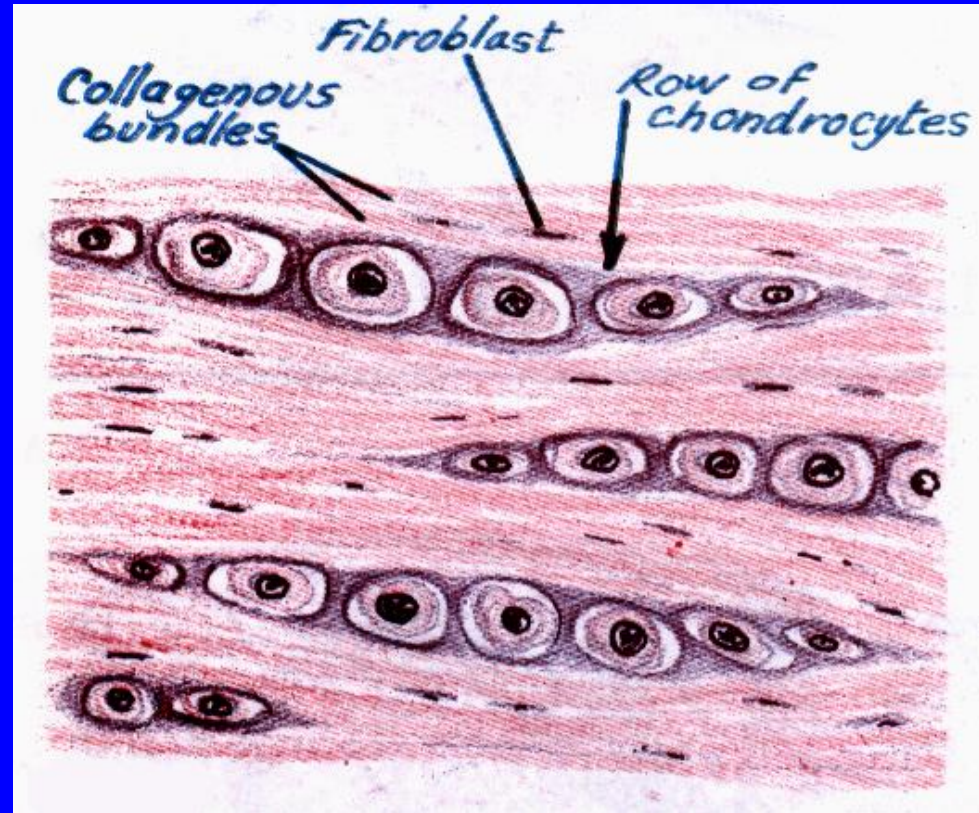
- Sites:

- External ear.
- Epiglottis.



# Fibrocartilage

- No perichondrium.
- Rows of chondrocytes in lacunae separated by parallel bundles of collagen fibers (type I).
- Sites:  
e.g. Intervertebral disks.

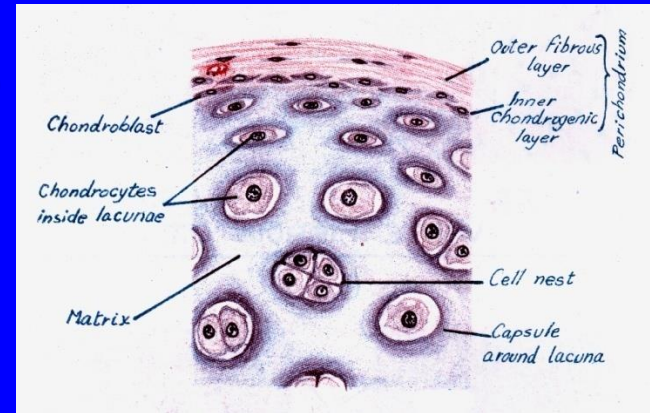




# Growth of cartilage

## 1. Appositional growth:

- Is produced by the activity of Chondroblasts in the inner chondrogenic layer.
- It leads to **increase in width**.



## 2. Interstitial growth:

- Is produced by division and activity of mature chondrocytes.
- It leads to **increase in length**.

# BONE

- Bone is a specialized type of C.T. with a hard matrix.
- **Types:** 2 types
  - Compact and spongy (cancellous) bone.
- **Components:**
  - Bone Cells: 4 types.
  - Bone Matrix (calcified osteoid tissue):
    - hard because it is calcified (Calcium salts).
    - It contains type I collagen fibers.
    - It forms **bone lamellae and trabeculae**.
  - Periosteum.
  - Endosteum.
- **Functions:**
  - body support.
  - protection of vital organs as brain & bone marrow.
  - calcium store.

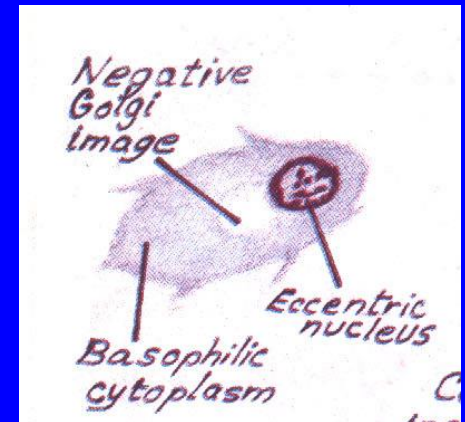
# Bone Cells

## 1- Osteogenic Cells:

- in periosteum & endosteum.
- Fate: give rise to osteoblasts.

## 2- Osteoblasts:

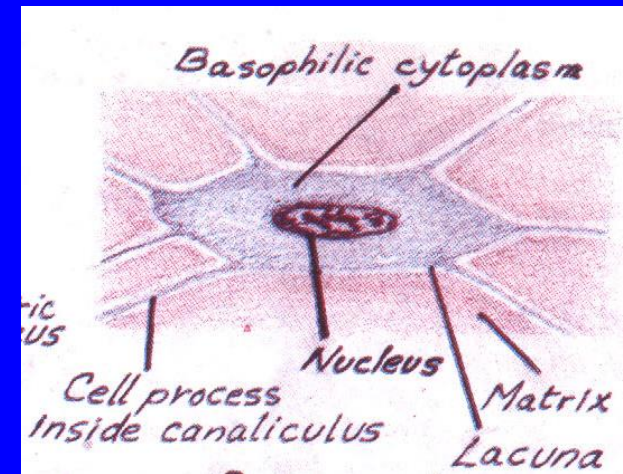
- in periosteum & endosteum.
- Origin: osteogenic cells.
- Function: They secrete the bone matrix & deposit Ca salts in it.
- Fate: change to osteocytes.



# Bone Cells

## 3- Osteocytes :

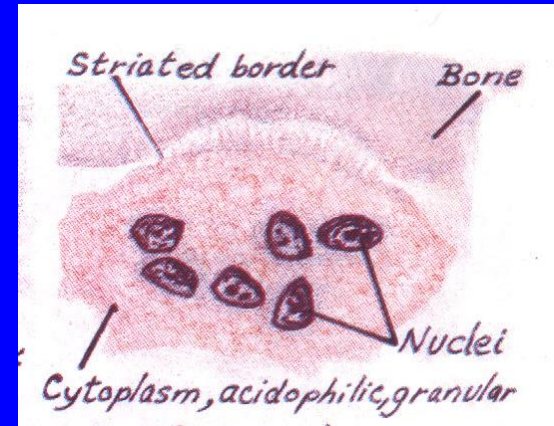
- Branched cells.
- Present singly in lacunae.  
Their branches run in the canaliculi.
- Origin: osteoblasts.
- Function: They maintain the bone matrix.



# Bone Cells

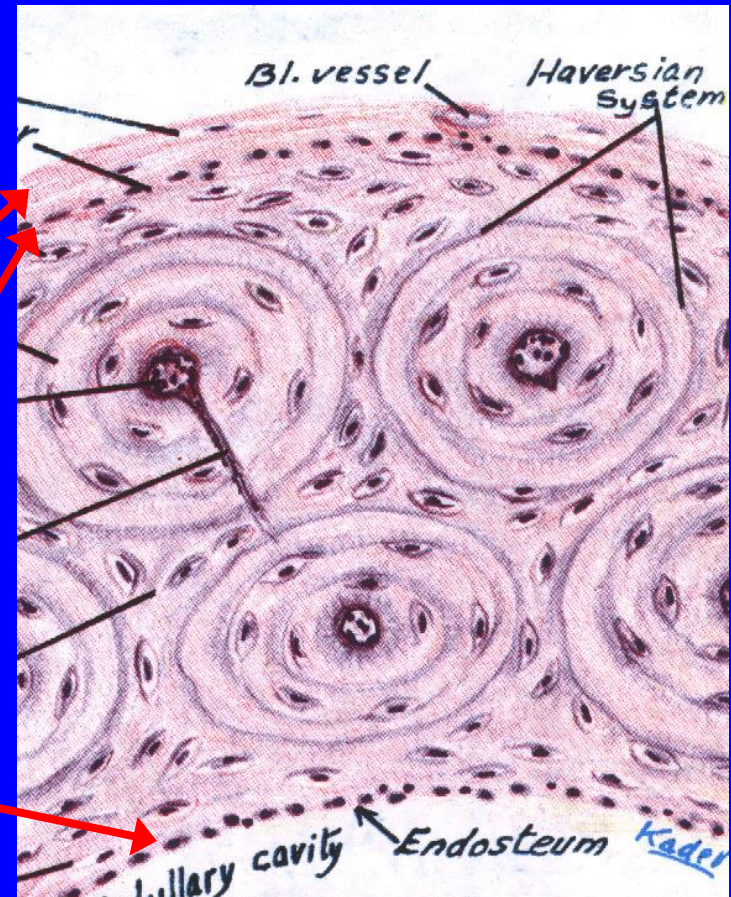
## 4- Osteoclasts:

- Large multinucleated cells on bony surfaces, in Howship's lacunae.
- They have striated or ruffled border.
- Cytoplasm is rich in lysosomes.
- Origin: blood monocytes.
- Function: bone resorption.



# Compact Bone

- It is found in the diaphysis of long bones.
- Consists of:
  - 1- Periosteum:
    - » Outer fibrous layer.
    - » Inner osteogenic layer.
  - 2- Endosteum.
  - 3- Bone Lamellae.
  - 4- Bone Cells.



# Compact Bone

## Bone Lamellae:

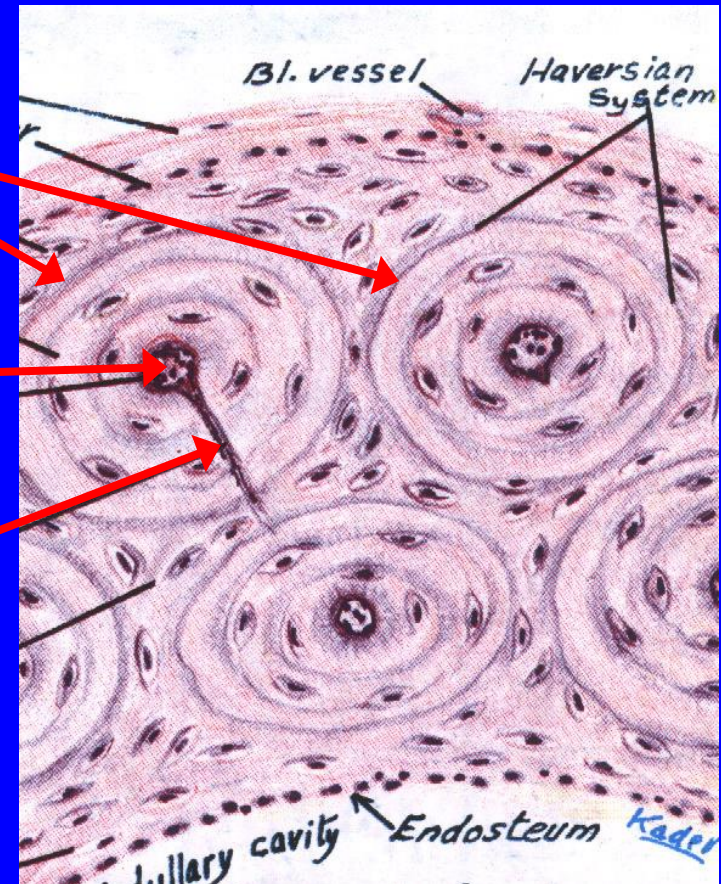
### 1- Haversian Systems (Osteons):

- Longitudinal cylinders.
- Each is formed of:
  - » a Haversian canal in the center,
  - » surrounded by concentrically arranged bone lamellae separated by osteocytes in lacunae.
- Volkman's canals: connect the Haversian canals together. They run obliquely or transversely.

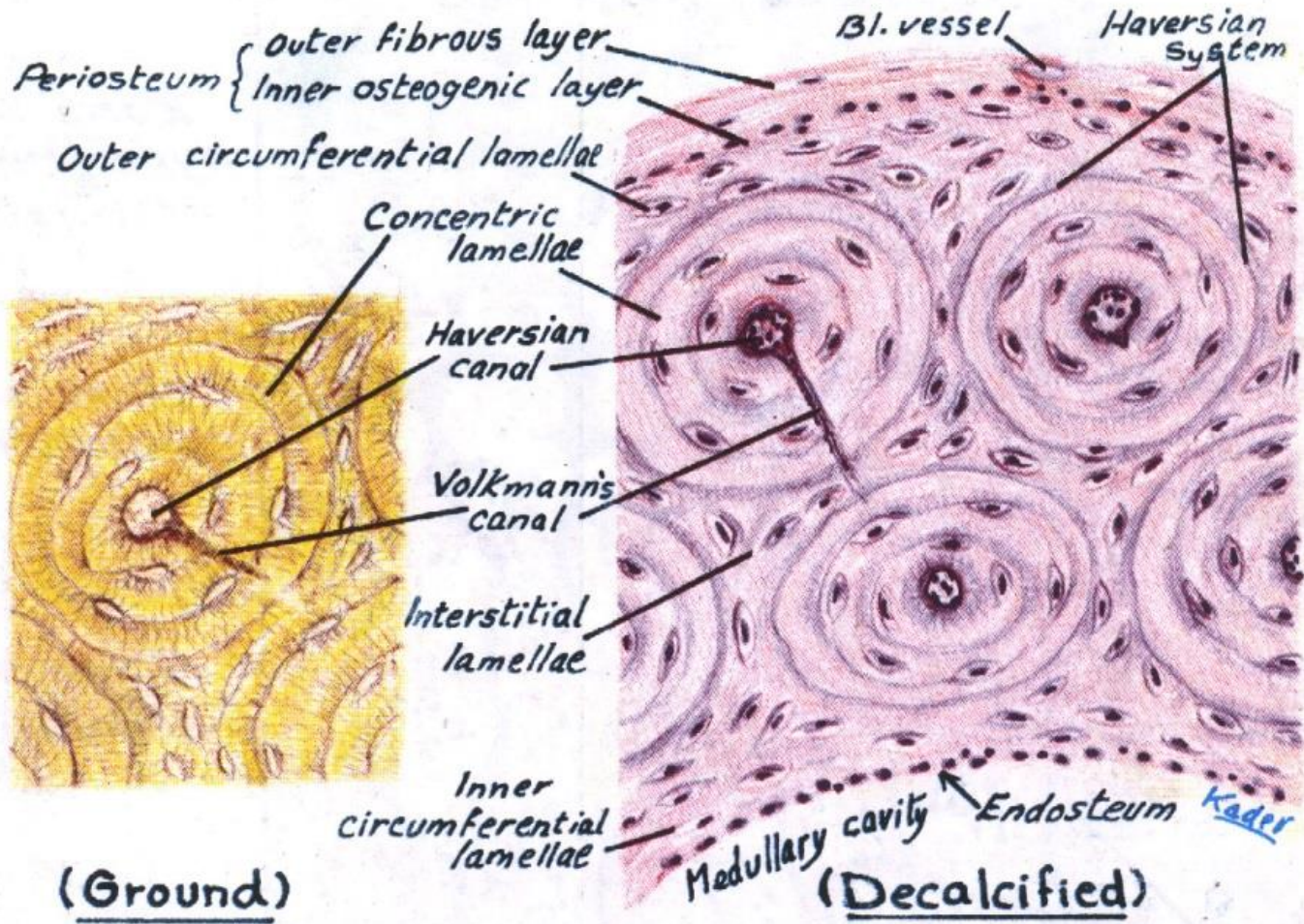
### 2. External Circumferential Lamellae.

### 3- Internal Circumferential Lamellae.

### 4- Interstitial Lamellae: between osteons.



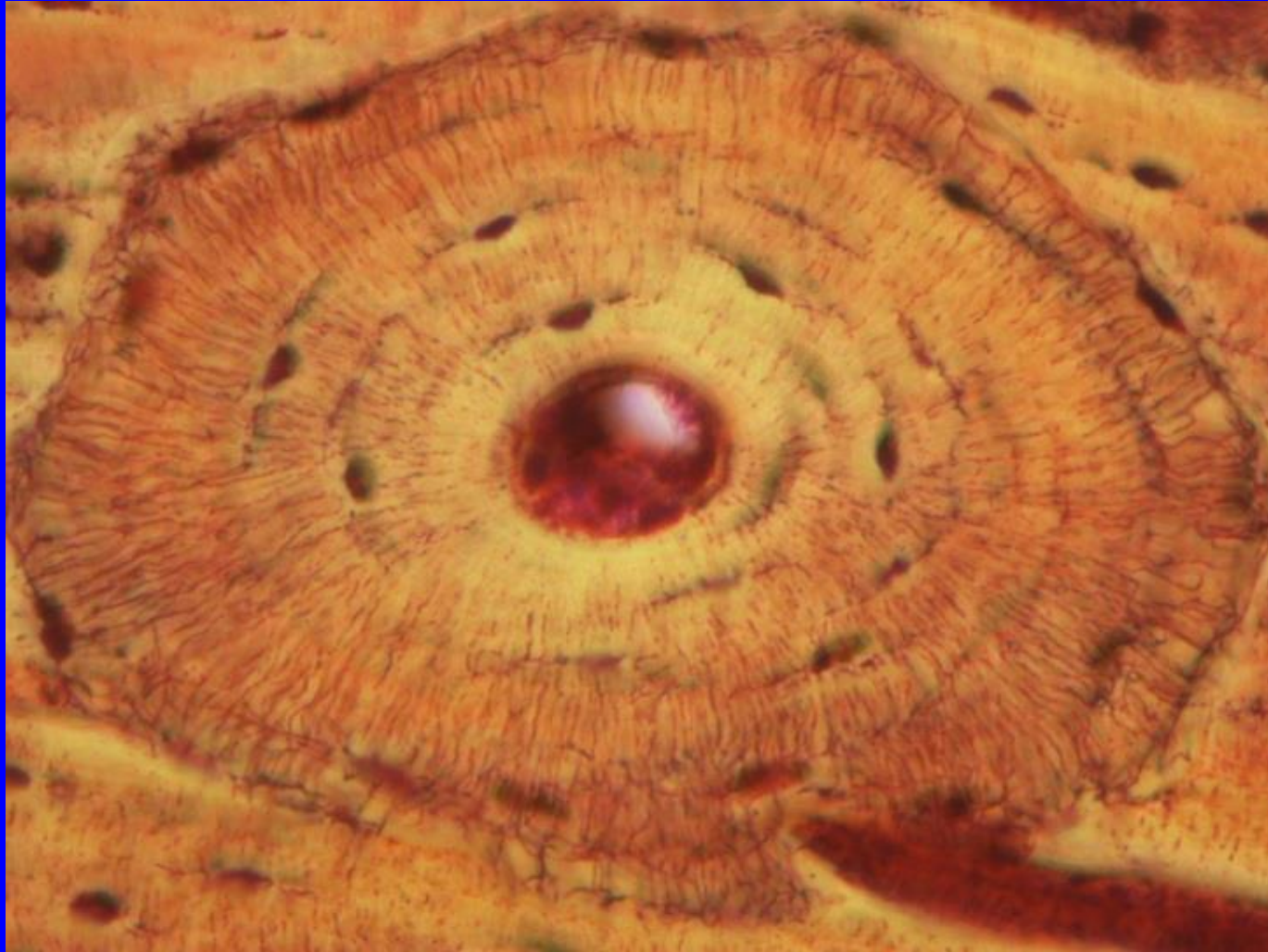# Compact Bone



COMPACT BONE (Long Bone, T.S)

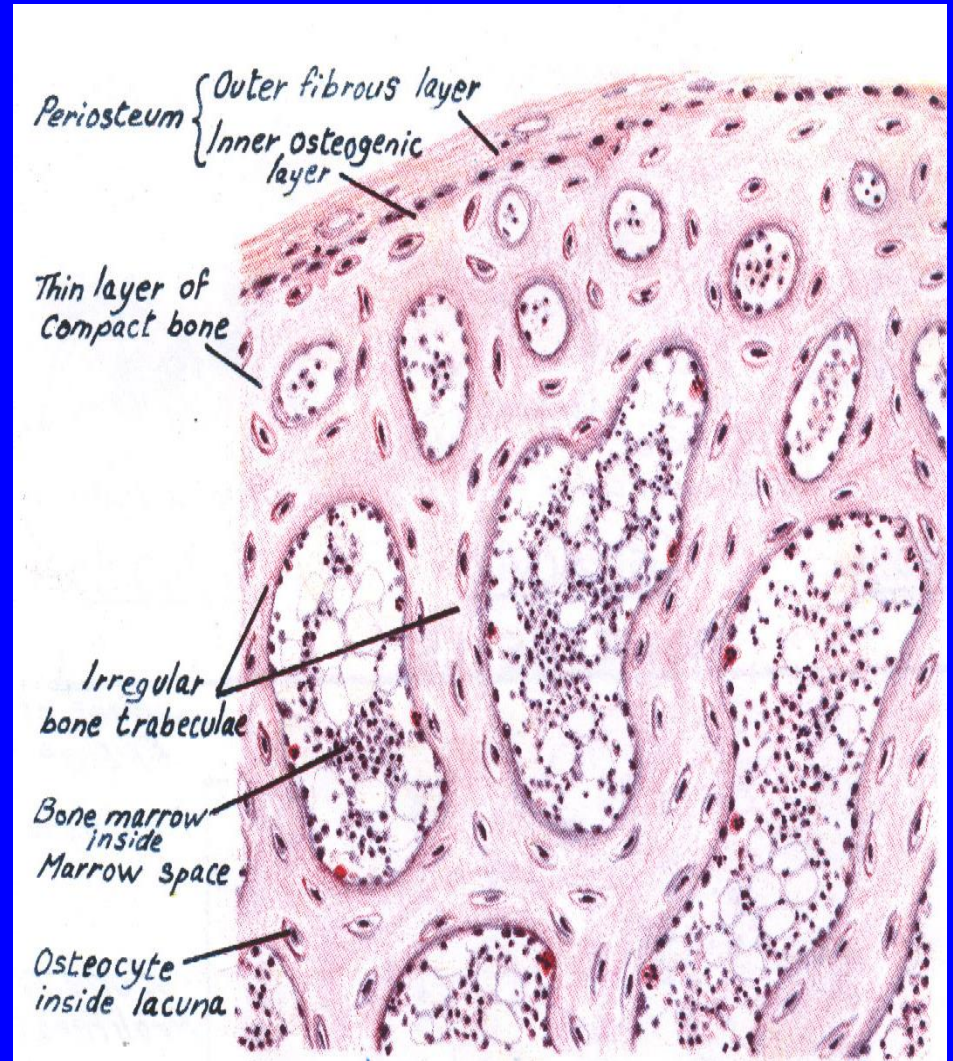


# Osteon of Compact Bone



# Spongy (Cancellous) Bone

- In flat bones & epiphysis of long bones.
- Consists of :
  1. Periosteum.
  2. Endosteum.
  3. Irregular bone trabeculae.  
(are formed of irregular bone lamellae separated by osteocytes inside lacunae).
  4. Many irregular red bone marrow spaces.
  5. Bone Cells.
- **No Haversian systems**  
**(no osteons).**



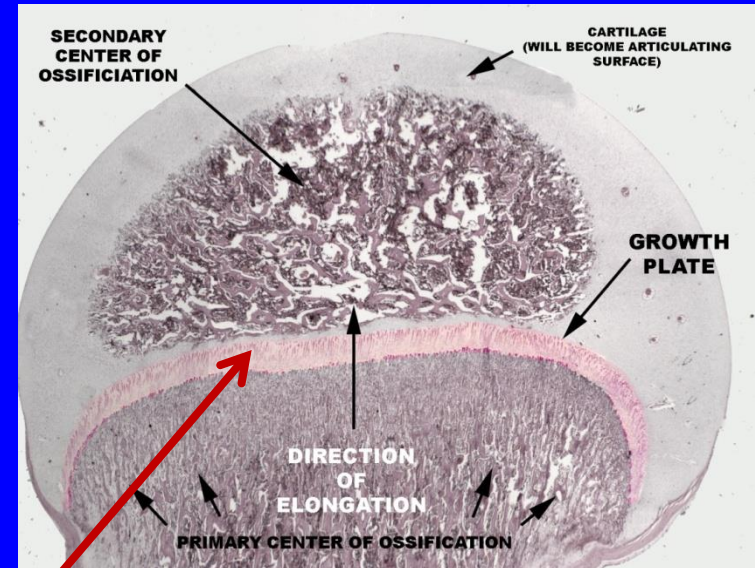
# Growth of Bone

## ■ Appositional growth:

- Is produced by the activity of osteoblasts.
- It leads to **increase in width.**

## ■ Growth in length:

- Is produced by the activity of epiphyseal plate of cartilage.



*Thank you*

---

