

# MUSCLES OF BACK

Department of Anatomy  
King Saud University



**Dr. Sameerah Shaheen**  
Assistant Professor of Anatomy  
College of Medicine  
[sshahee@ksu.edu.sa](mailto:sshahee@ksu.edu.sa)

# OBJECTIVES

At the end of the lecture, students should be able to:

- *Distinguish between the different groups of back muscles.*
- *Compare between groups of back muscles as regard their nerve supply and action.*
- *List the back muscles of each group.*
- *Describe the attachments of each muscle of the **superficial group**, as well as, its nerve supply and action.*
- *Describe the **triangles of back** and their clinical significance.*

# BACK MUSCLES

They are organized into 3 groups:

**Deep group:** attached to & involved in the **movement** of **vertebral column & head.**

**Superficial group:** attached to & involved in the **movements** of **upper limb (shoulder).**

**Intermediate group:** attached to **ribs** & associated with of the thoracic cage movements.  
Serve **respiratory functions.**

## Intrinsic muscles:

- Develop in the back
- Supplied by **posterior rami of spinal nerves**

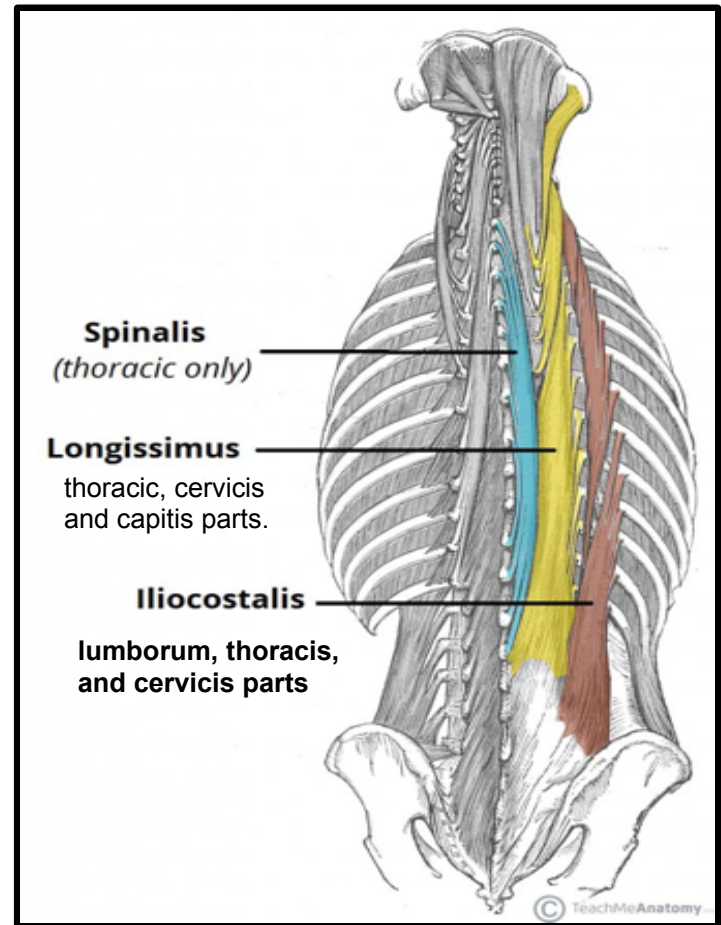
## Extrinsic muscles:

- Not developed in the back.
- Supplied by **anterior rami of spinal nerves.**

# DEEP GROUP OF BACK MUSCLES

- ❑ They extend from sacrum to skull.
- ❑ They include extensors and rotators of head & vertebral column. So, It is a set of muscles that straighten and rotate the back.
- ❑ Their tone is responsible for maintenance of normal curvature of vertebral column.
- ❑ The largest muscle of this group is **“erector spinae”** which is formed of 3 vertical columns (*from lateral to medial* : *iliocostalis*, *longissimus* & *spinalis*).

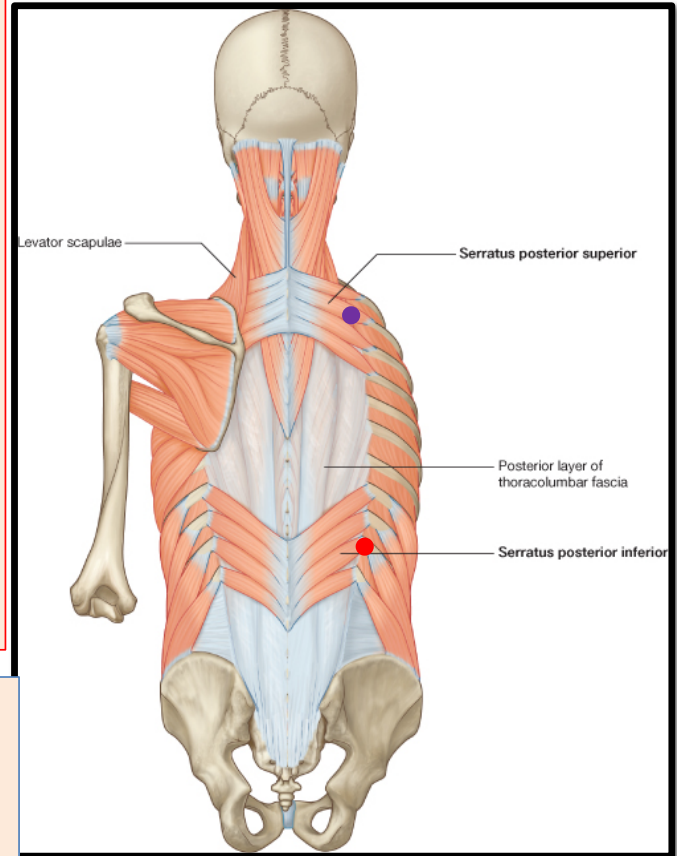
(Note the length and attachment of the muscle fibers)



# INTERMEDIATE GROUP OF BACK MUSCLES

- ❑ It is separated from the deep group by thoracolumbar fascia.
- ❑ It includes:
  - **Serratus posterior superior** (*rib elevator*).
  - **Serratus posterior inferior** (*rib depressor*).
- ❑ **Nerve supply:** anterior rami of thoracic spinal nerves (intercostal nerve).

- **Serratus posterior superior** contributes in deep inspiration.
- **Serratus posterior inferior** contributes in forced expiration.



# SUPRERFICIAL GROUP OF BACK MUSCLES

## Includes two sets of muscles:

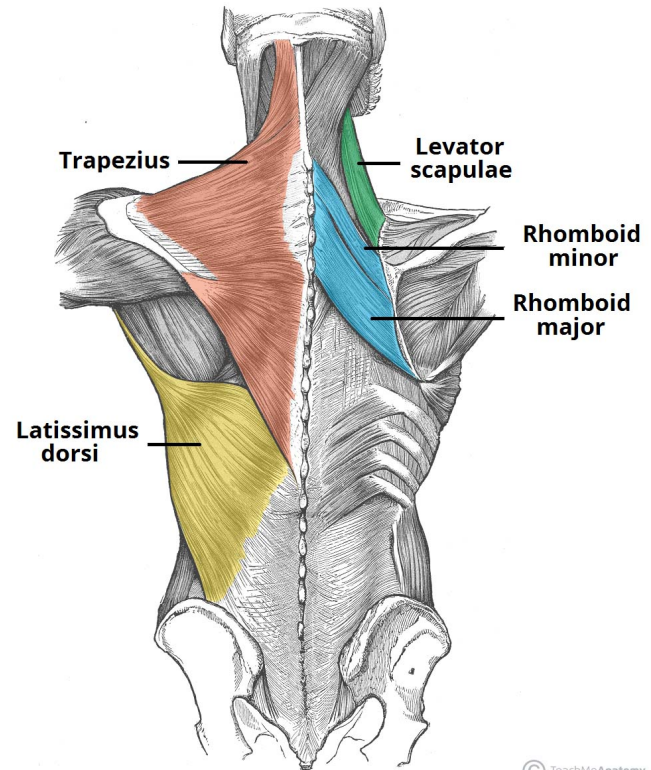
They originate from the vertebral column and attach to the bones of the shoulder – the clavicle, scapula and humerus.

❑ Muscles connecting vertebral column to scapula (move scapula through shoulder girdle joints) & include:

1. *Trapezius.*
2. *Levator scapulae.*
3. *Rhomboid minor.*
4. *Rhomboid major.*

❑ Muscle connecting vertebral column to humerus (move humerus through shoulder joint), & include:

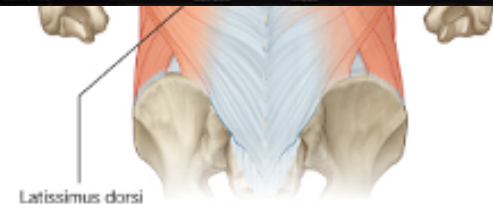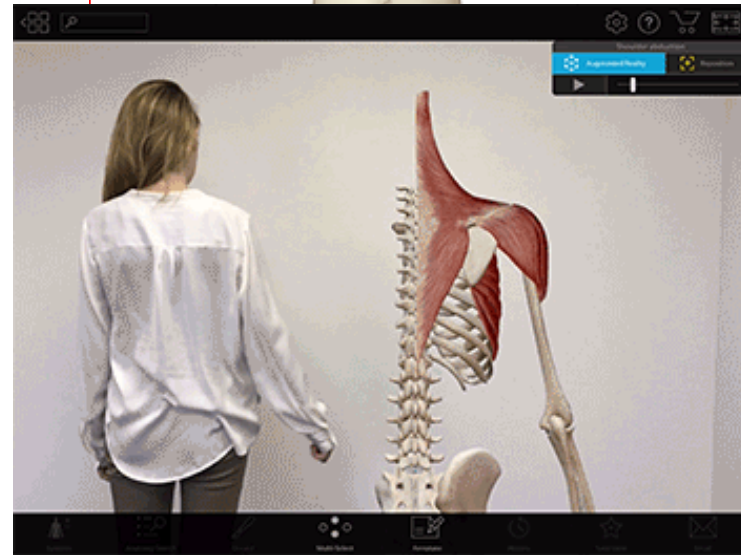
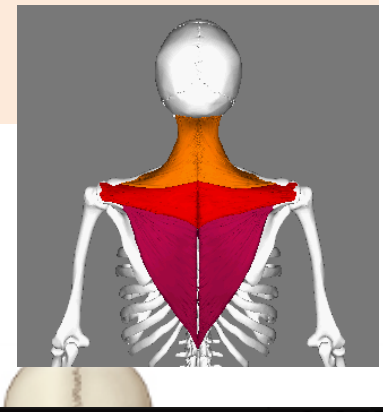
- *Latissimus dorsi.*



# TRAPEZIUS

- ❑ **Origin:** Skull, ligamentum nuchae & spinous processes of cervical & thoracic vertebrae (C7-T12).
- ❑ **Insertion:** lateral 1/3 of clavicle, acromion & spine of scapula.
- ❑ **Action:**
  1. **Upper fibers:** elevates scapula & rotates it during abduction of the arm.
  2. **Middle fibers:** retract scapula
  3. **Lower fibers:** depress scapula.
- ❑ **Nerve supply:** Motor innervation is the accessory (11<sup>th</sup> cranial) nerve. Also, proprioceptor fibers from C3 and C4 spinal nerves.

To test the accessory nerve, trapezius function can be assessed by shoulders shrug



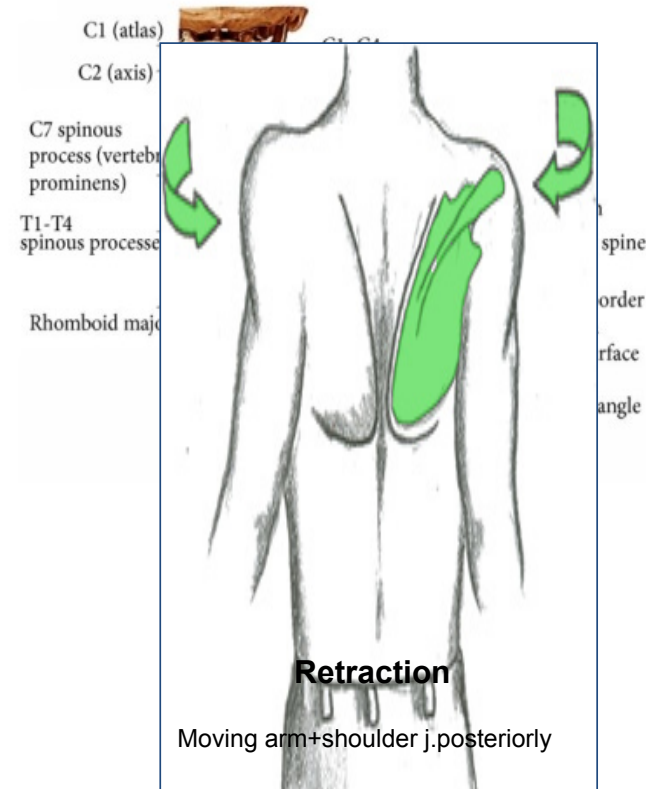
# LEVATOR SCAPULAE RHOMBOID MINOR & MAJOR

## ❑ Origin:

1. *Levator scapulae*: cervical transverse processes **C1-C4**, **Insertion**: medial border of scapula.
2. *Rhomboid major*: thoracic spinous processes of T2-T5 vertebrae, **Insertion**: medial border of the scapula, between the scapula spine and inferior angle
3. *Rhomboid minor*: the spinous processes of C7-T1 vertebrae, **Insertion**: medial border of scapula at the level of the spine of scapula.

## ❑ Nerve supply: dorsal scapular nerve. **Actions**:

1. *Levator scapulae*: elevates scapula.
2. *Rhomboid minor & major*: retract & rotate scapula .





# LATISSIMUS DORSI

## ❑ Origin:

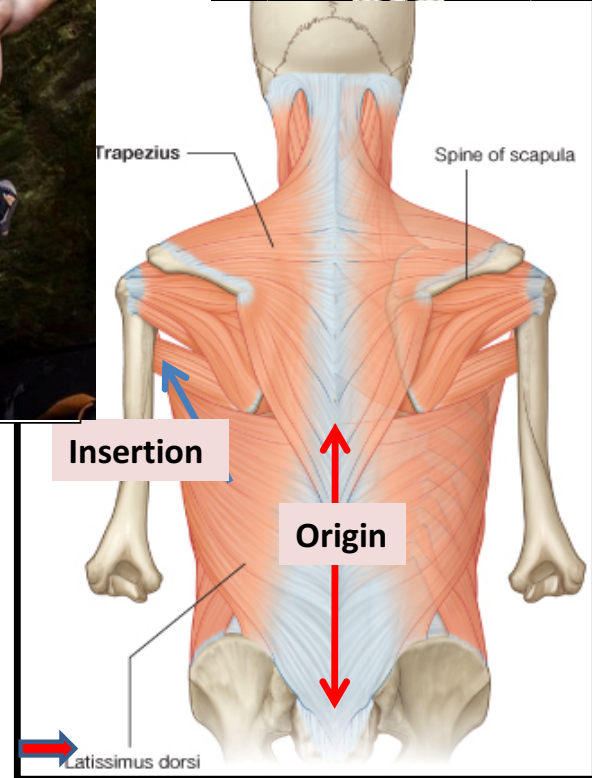
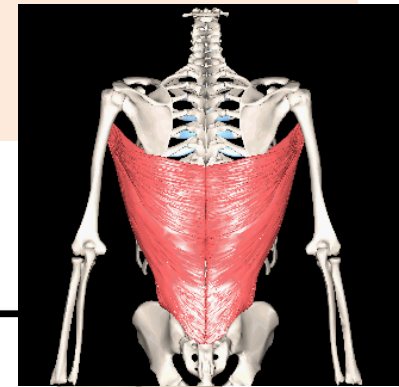
- Spinous processes of T6-T12
- Iliac crest
- Thoracolumbar fascia
- inferior 3 or 4 ribs

❑ **Insertion:** tendon attaches to the intertubercular sulcus of the humerus.

❑ **Nerve supply:** thoracodorsal nerve. (C6,7,8) From posterior cord of brachial plexus

❑ **Actions:** *extension, adduction & medial rotation* of upper limb.

❑ It is also called the **climbing muscle**.



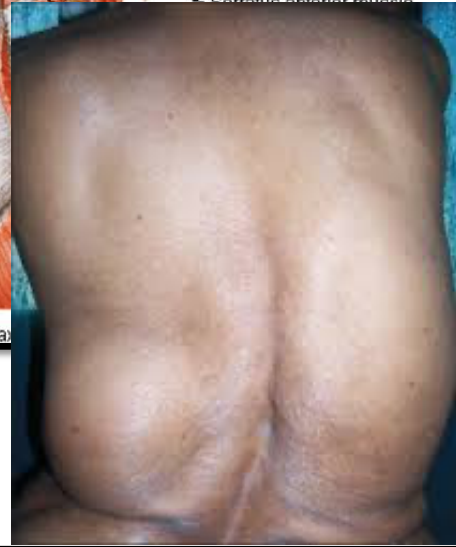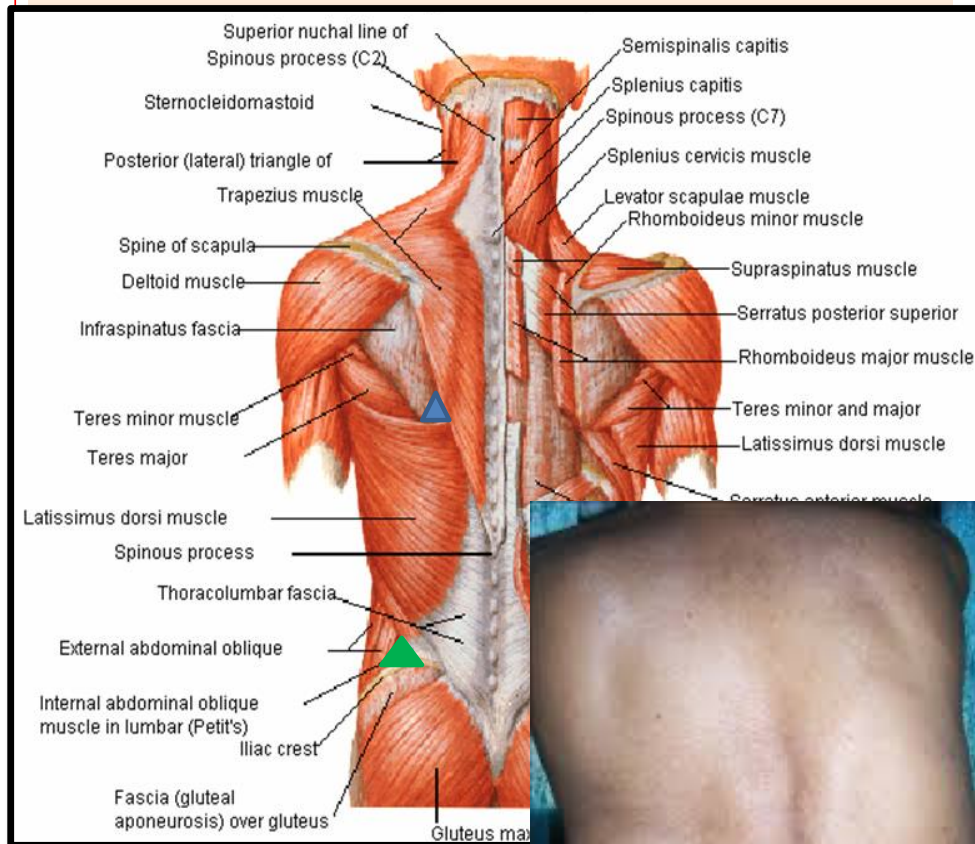
# MUSCULAR TRIANGLES OF BACK

## ❑ Auscultatory Triangle: ▲

- Boundaries:** latissimus dorsi, trapezius, and medial border of scapula.
- Site** where breath sounds are most easily heard with a stethoscope.

## ❑ Lumbar Triangle: ▲ (Triangle of Petit)

- Boundaries :** latissimus dorsi, posterior border of external oblique muscle of the abdomen, and iliac crest.
- Site** of an abdominal hernia; or where pus may emerge from the abdominal wall in extra-abdominal lumbar abscess.



# SUMMARY

## ❑ BACK MUSCLES:


1. Deep group: attached to & moves **vertebral column**, supplied by **posterior rami of spinal nerves**.
2. Intermediate group: attached to & moves **ribs**, supplied by **anterior rami of spinal nerves**.
3. Superficial group:
  - Origin: vertebral column.
  - Insertion: scapula (**EXCEPT latissimus dorsi**: humerus).
  - Action: moves scapula (**EXCEPT latissimus dorsi**: moves humerus).
  - Nerve supply: anterior rami of spinal nerves through brachial plexus (**EXCEPT trapezius**: 11<sup>th</sup> cranial nerve).

A graphic illustration of two yellow roses with green leaves and a dark brown stem, set against a teal background. The roses are rendered in a stylized, low-poly manner. The text "THANK YOU" is written in a bold, blue, serif font across the center of the image. The entire composition is enclosed in a thin orange border.

**THANK YOU**


# QUESTION 1

Which one of the following muscles of back that rotates the humerus medially ?

1. Trapezius.
2. Latissimus dorsi. 
3. Rhomboid major.
4. Serratus posterior superior.

## QUESTION 2

Regarding back muscles, which one of the following statements is correct?

1. All back muscles are supplied by posterior rami of spinal nerves.
2. Muscles of intermediate group move vertebral column.
3. Muscles of superficial group are involved in upper limb movements. 
4. Muscles of deep group serve respiratory functions.