

# MSK Block

# NONinfectious arthritis

Afaf AlSolami

Bone and Soft tissue Pathologist

aalsolami1@ksu.edu.sa

- **Has four main causes**

1. **Degeneration**, e.g. osteoarthritis.
2. **Autoimmunity**, e.g. rheumatoid arthritis, SLE
3. **Crystal deposition**, e.g. gout and other crystalline arthropathies.
4. **Infection**, e.g. septic arthritis, tuberculous arthritis.

## OSTEOARTHRITIS (OA)

Type 2 collagen  
eburnation  
Joint mice  
Bouchard  
osteophyte  
Heberden

## RHEUMATOID ARTHRITIS (RA)

CCP  
Pannus  
HLA-DR  
Boutonniere  
Ankylosis  
Swan neck

## GOUT AND PSEUDOGOUT (CRYSTAL-INDUCED)

Tophi  
Rhomboid  
Needle  
birefringence

# 1) Osteoarthritis (OA)

- **Osteoarthritis (OA), also called degenerative joint disease, is characterized by degeneration of cartilage that results in structural and functional failure of synovial joints.**
- It is the most common disease of joints.
- Intrinsic disorder of cartilage in which chondrocytes respond to biochemical and mechanical stresses resulting in the breakdown of the matrix and failure of its repair.
- Role of inflammatory mediators...??

#### PRIMARY (IDIOPATHIC)

- Insidious, with aging
- Oligoarticular (affect few joints)

#### SECONDARY

- 5%
- Younger
- Previous trauma, developmental anomaly, systemic disease (DM, Hemochromatosis, obesity, SCD)

# Pathogenesis

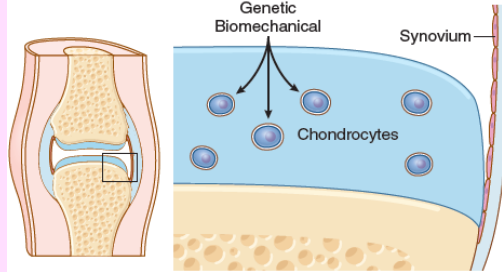
- **Articular cartilage bears the brunt of the degenerative changes in osteoarthritis.**

Normal articular cartilage performs two functions:

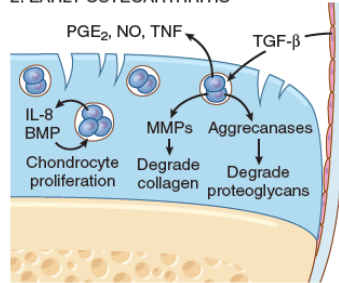
- (1) Along with the synovial fluid, it provides friction-free movement within the joint.
  - (2) In weight-bearing joints, it spreads the load across the joint surface.
- These functions require the cartilage to be elastic (i.e., to regain normal architecture after compression) and to have high tensile strength. These attributes are provided by **proteoglycans and type II collagen**, both produced by chondrocytes.

- Chondrocyte function is affected by a variety of influences: **mechanical stresses** , **aging** and **Genetic factors**.
- Regardless of the inciting stimulus, there is an imbalance in the expression, activity, and signaling of cytokines and growth factors that results in **degradation and loss of matrix**.
- Early osteoarthritis is marked by degenerating cartilage containing more water and **less proteoglycan**
- The **type II collagen** network also is **diminished**, presumably as a result of decreased local synthesis and increased breakdown

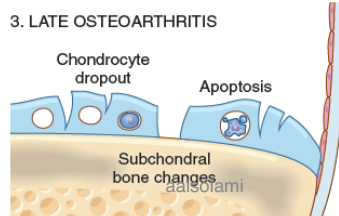
### 1. CHONDROCYTE INJURY



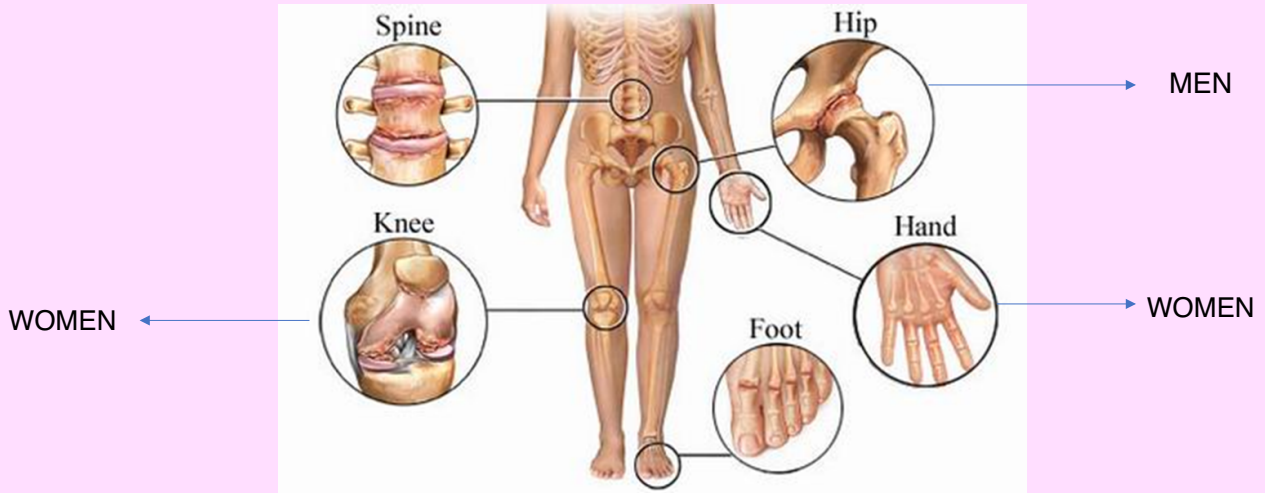
### 2. EARLY OSTEOARTHRITIS

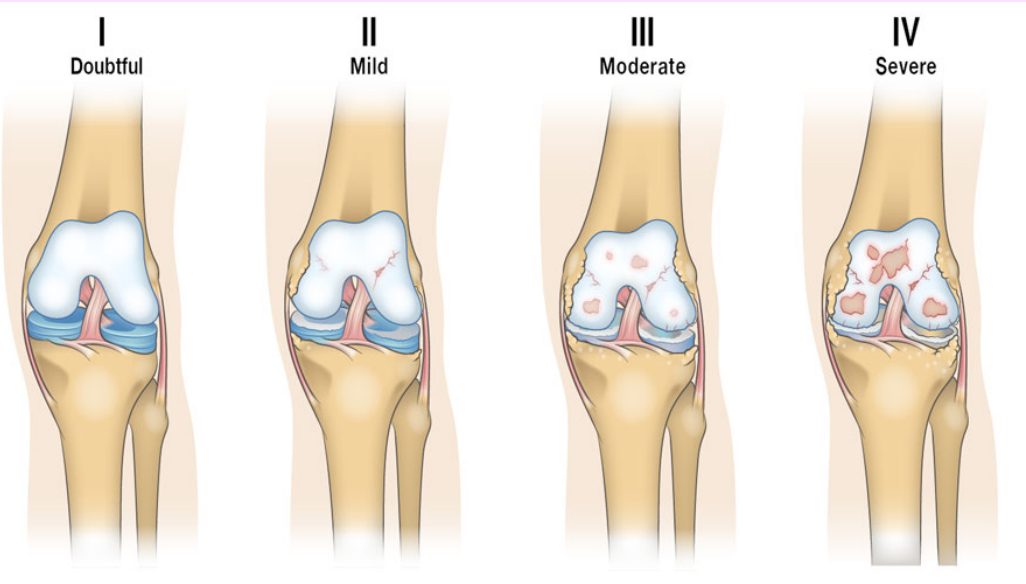


### 3. LATE OSTEOARTHRITIS



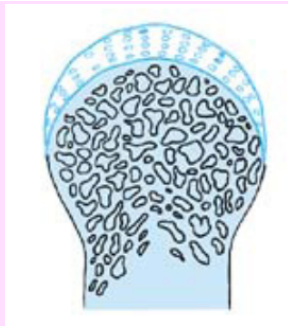





constant friction of bone surfaces,  
leading to a polished ivory bony  
articular surface (**eburnation**)

1



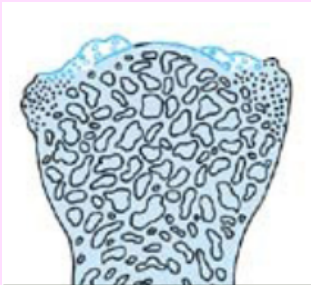Normal articular cartilage

2



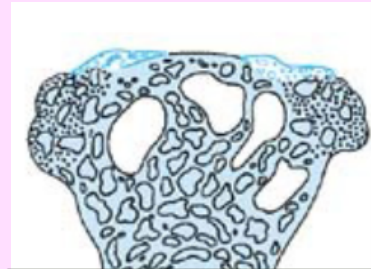Fragmentation of articular surface and thinning of cartilage

3

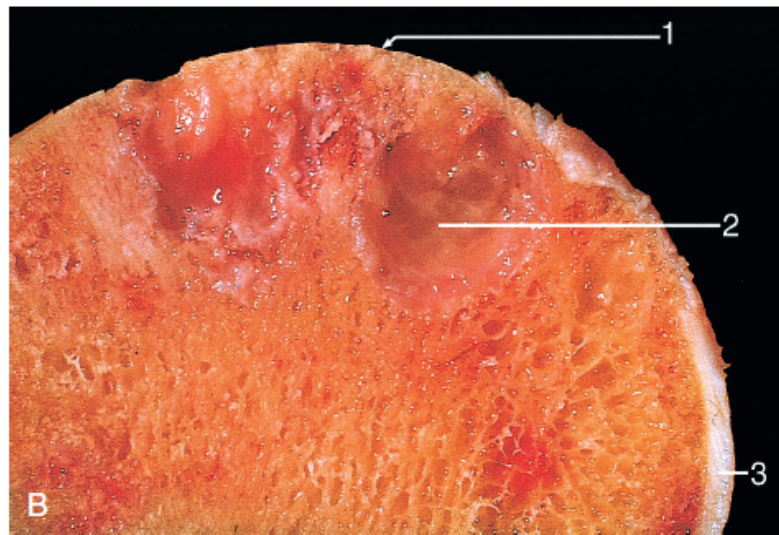
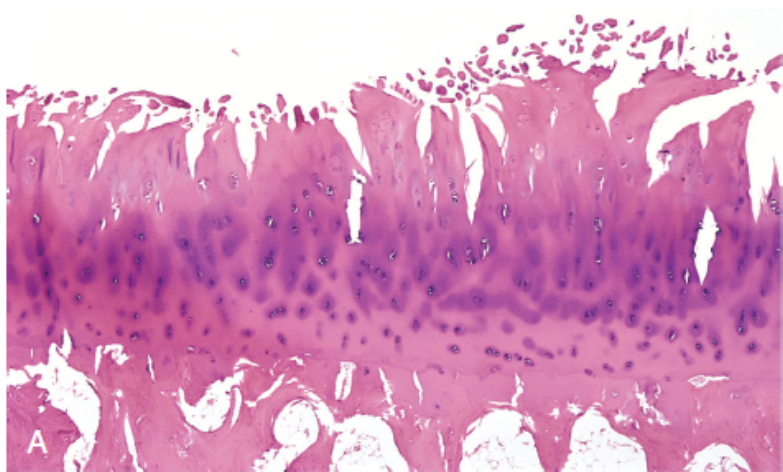


Calcification of cartilage margins. Patchy loss of cartilage revealing bare bone (eburnation).

4

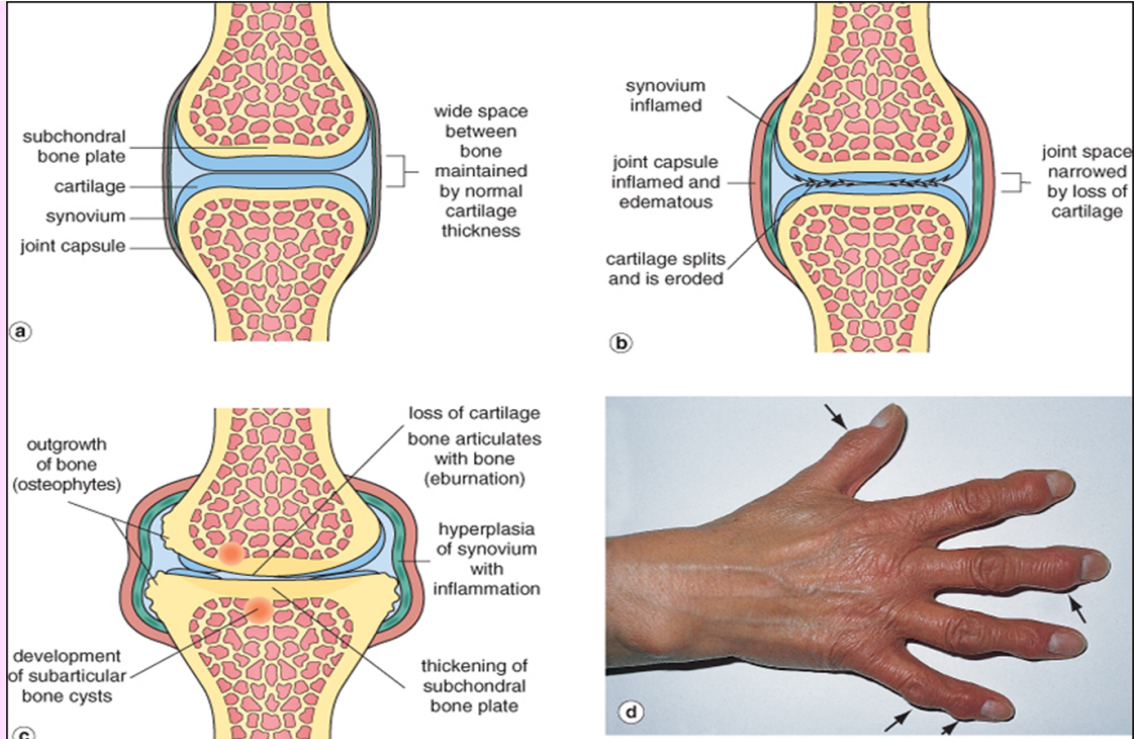


Formation of lips of new bone ("osteophytes")  
Extensive loss of cartilage  
Cystic degeneration of underlying bone

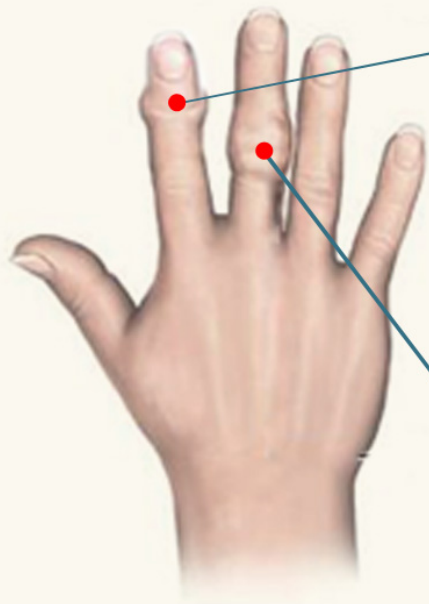


**Fig. 21.33 Osteoarthritis.** (A) Histologic demonstration of the characteristic fibrillation of the articular cartilage. (B) Eburnated articular surface exposing subchondral bone (1), subchondral cyst (2), and residual articular cartilage (3).

- **Fibrillation and cracking of the matrix** occur as the superficial layers of the cartilage are degraded
- Eventually, full-thickness portions of the cartilage are lost, and the subchondral bone plate is exposed and is smoothed by friction, giving it the appearance of polished ivory (**bone eburnation**)
- Small fractures can dislodge pieces of cartilage and subchondral bone into the joint, forming loose bodies (**joint mice**).
- The fracture gaps allow synovial fluid to be forced into the subchondral regions to form fibrous walled **cysts**.
- Mushroom-shaped **osteophytes** (bony outgrowths) develop at the margins of the articular surface



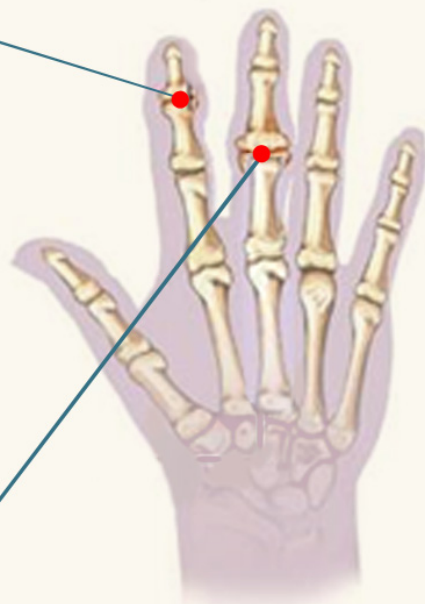
Osteophytes on the interphalangeal joints of the fingers

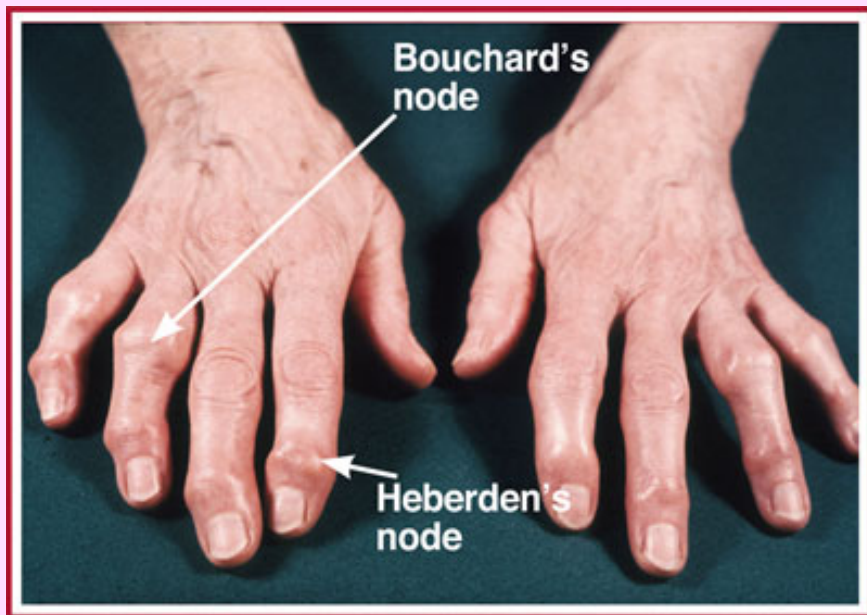


Heberden's  
node

women

Bouchard's  
node





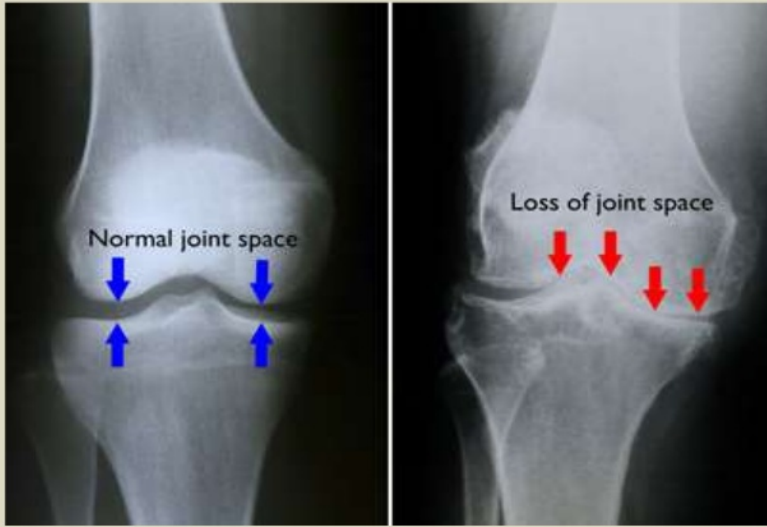


# Clinical course

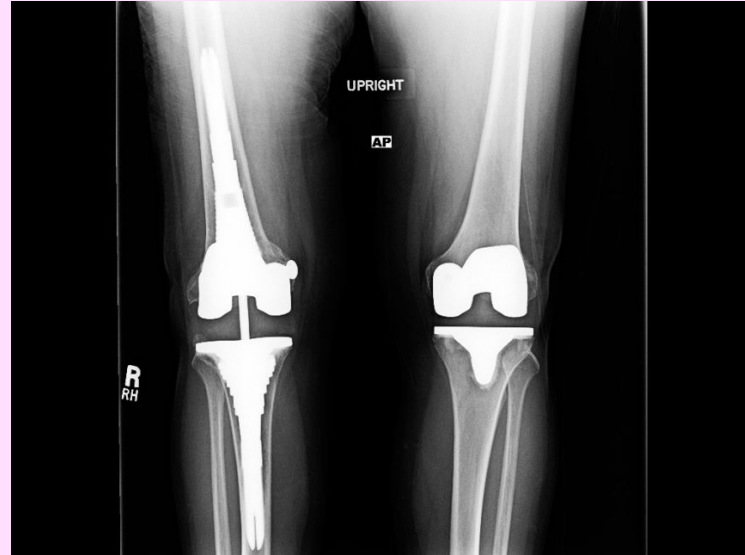- Pain exacerbated by use, morning stiffness, crepitus (grating or popping sensation in the joint), and limitation in range of movement.
- Osteophyte impingement on spinal foramina can cause nerve root compression with radicular pain and neurologic deficits.
- Hips, knees, lower lumbar and cervical vertebrae, proximal and distal interphalangeal joints of the fingers, first carpometacarpal joints, and first tarsometatarsal joints of the feet are commonly involved.

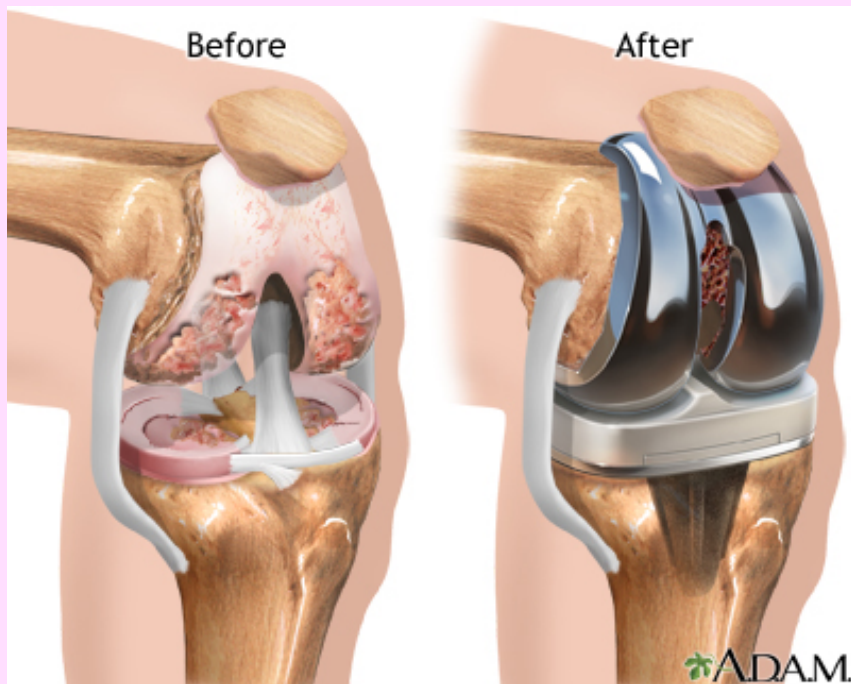
# Prognosis

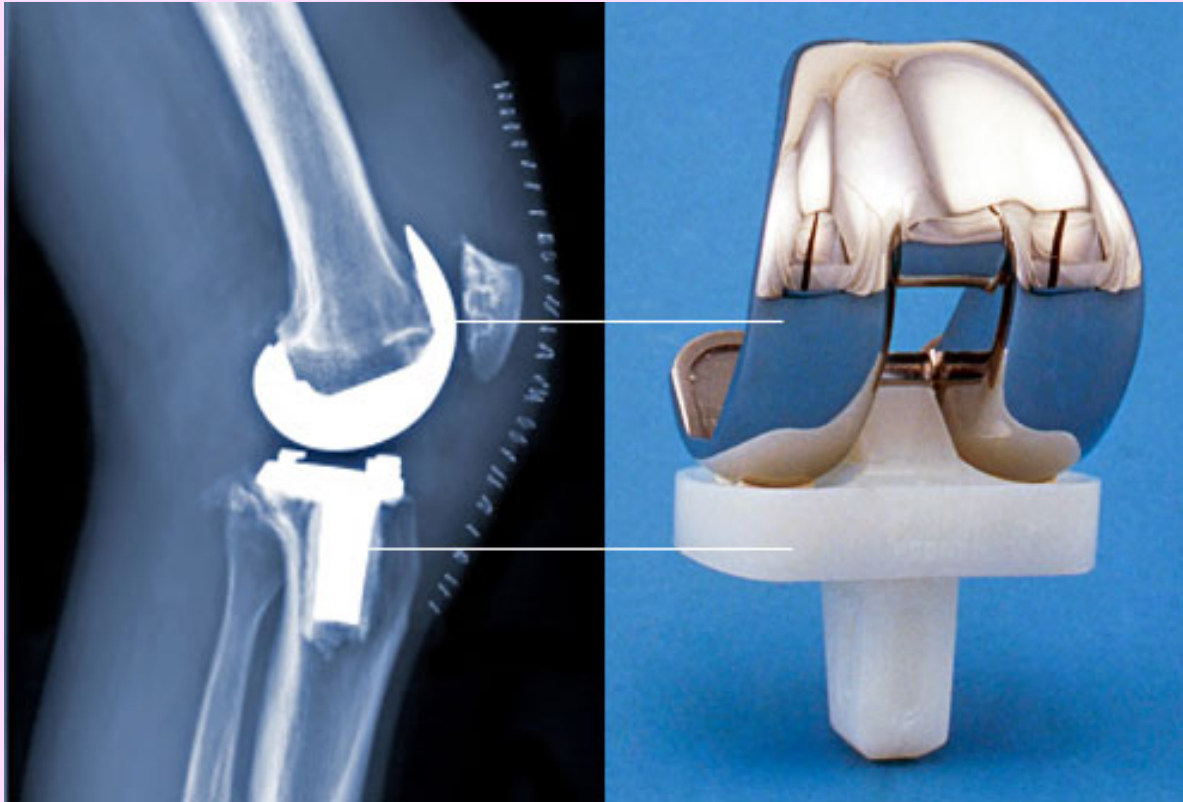
- Slowly progressive.
- With time, significant joint deformity can occur, Treatment usually is based on symptoms, with joint replacement in severe cases.
- NSAIDs, intra-articular injection, arthroplasty.



*(Left)* In this x-ray of a normal knee, the space between the bones indicates healthy cartilage (arrows). *(Right)* This x-ray of an arthritic knee shows severe loss of joint space.







# Rheumatoid Arthritis (RA)

- *Rheumatoid arthritis (RA)* is a systemic, chronic **inflammatory autoimmune** disease affecting many tissues (skin, heart, blood vessel, lung) but principally attacking the joints.
- It causes a **nonsuppurative proliferative synovitis** that frequently progresses to destroy articular cartilage and underlying bone with resulting disabling arthritis and ankylosis (adhesions).
- RA is a relatively common condition, with a prevalence of approximately 1%; it is three to five times more common in women than in men.
- The peak incidence is in the second to fourth decades of life, but no age is immune.

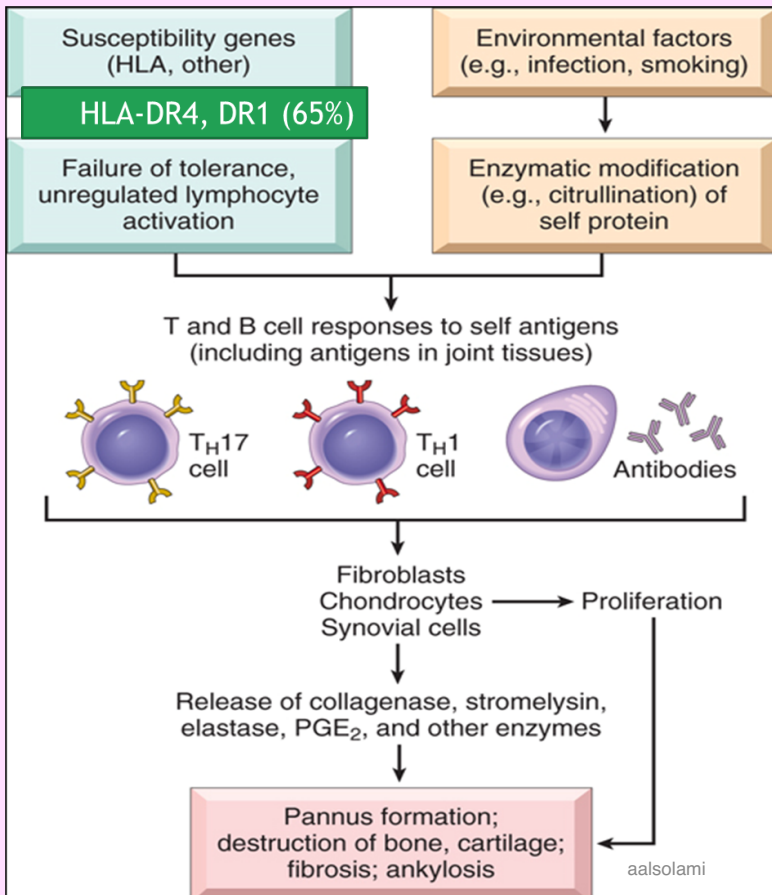
# Pathogenesis

- RA is an autoimmune disease involving complex, and still poorly understood, interactions of 1) genetic risk factors, 2) environment, and the 3) immune system.
- The changes are caused mainly by **cytokine-mediated inflammation, with CD4+ T helper cells being the principal source of the cytokines.**
- Many patients also produce **antibodies against cyclic citrullinated peptides (CCPs)**, which may contribute to the joint lesions In RA, antibodies to citrullinated fibrinogen, type II collagen,  $\alpha$ -enolase, and vimentin are the most important and may form immune complexes that deposit in the joints. **These antibodies are a diagnostic marker for the disease and may be involved in tissue injury.**



- **Genetic factors:** It is estimated that 50% of the risk of developing RA is related to genetic factors. Susceptibility to rheumatoid arthritis is linked to the HLA-DRB1 locus.
- **Environmental factors:** Many candidate infectious agents whose antigens may activate T or B cells have been considered, but none has been conclusively implicated. Smoking.

- About 80% of patients have serum immunoglobulin M (IgM) or IgA autoantibodies that bind to the Fc portions of their own IgG.
- These autoantibodies are called **rheumatoid factor**. They may form immune complexes with self-IgG that deposit in joints and other tissues, leading to inflammation and tissue damage.
- Although they are not uniformly present in all patients with RA and can be found in patients without the disease.



Antibodies against cyclic citrullinated peptides (CCP protein antibodies) is the most specific for a diagnosis of rheumatoid arthritis

# Laboratory findings

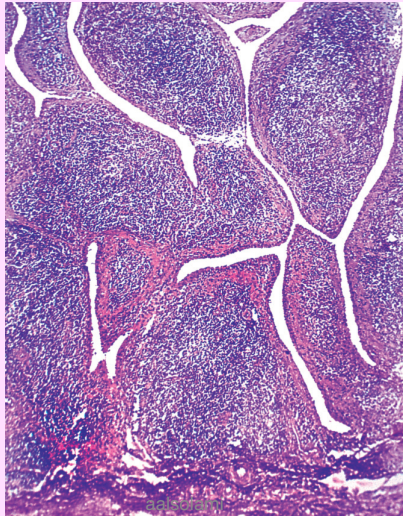
? **Rheumatoid factor:** 80% have IgM autoantibodies to Fc portion of IgG

? not sensitive or specific

? Anti-CCP (cyclic citrullinated peptides) protein antibodies **most specific** for a diagnosis of rheumatoid arthritis

? ESR and C-reactive protein

- Symmetric arthritis, small joints of hand and feet.
- Synovium is edematous, thickened, and hyperplastic, transforming its smooth contour to one covered by delicate and bulbous villi.



PANNUS

**synovial cell hyperplasia** and proliferation

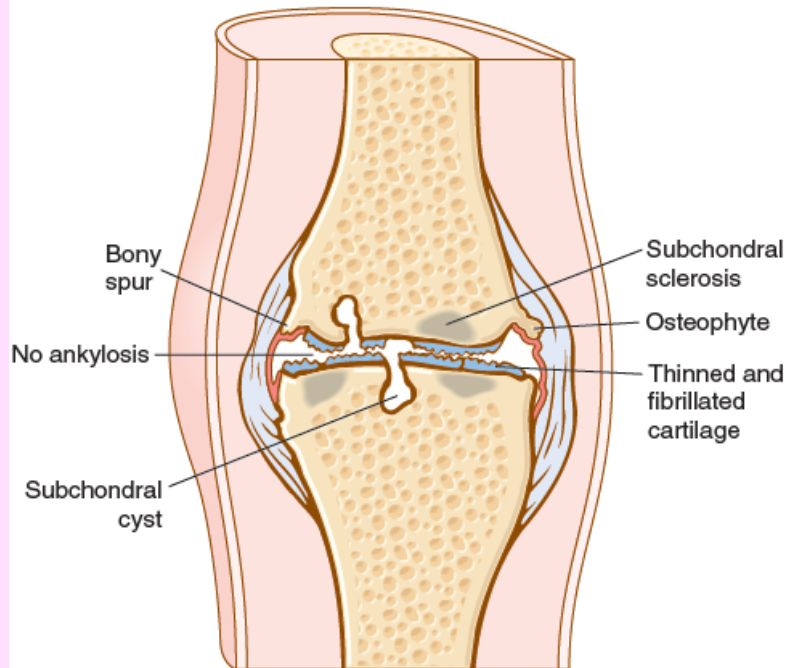
**dense inflammatory infiltrates** of CD4+ helper T cells, B cells, plasma cells, dendritic cells, and macrophages

Increased vascularity resulting from angiogenesis;

neutrophils and aggregates of organizing fibrin on the synovial and joint surfaces

osteoclastic activity in underlying bone, allowing the synovium to penetrate into the bone, causing periarticular erosions and subchondral cysts.

## OSTEOARTHRITIS



## RHEUMATOID ARTHRITIS

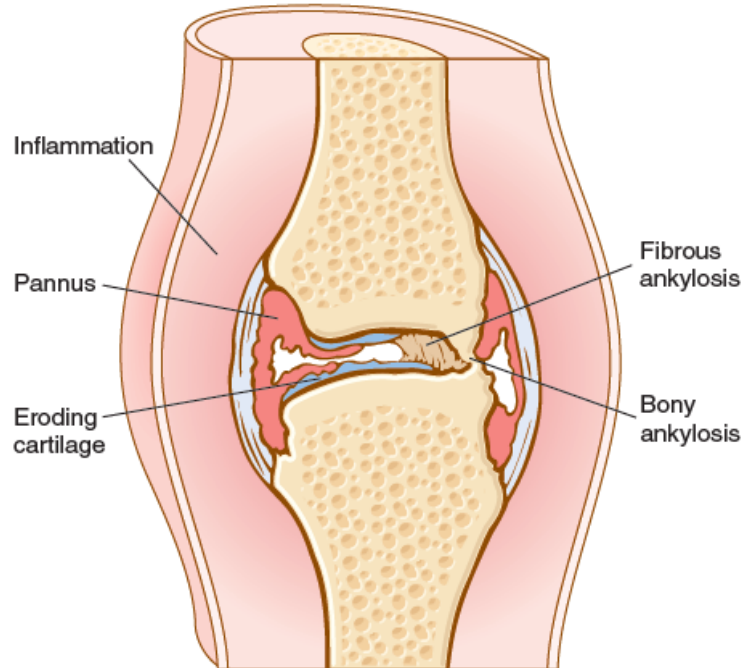


Fig. 21.35 Comparison of the morphologic features of rheumatoid arthritis and osteoarthritis.

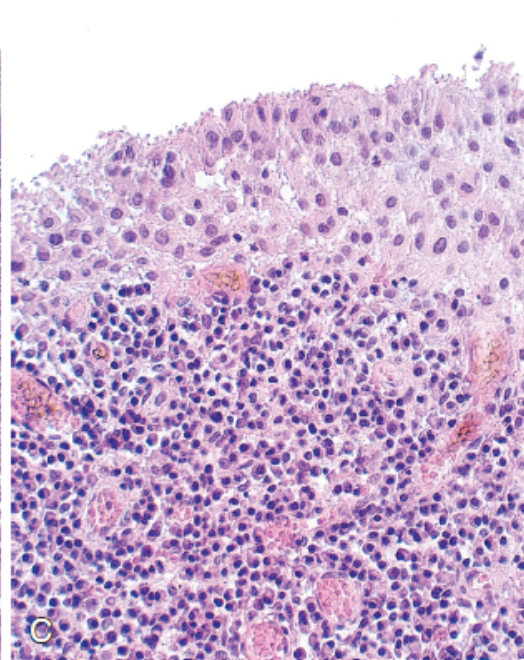
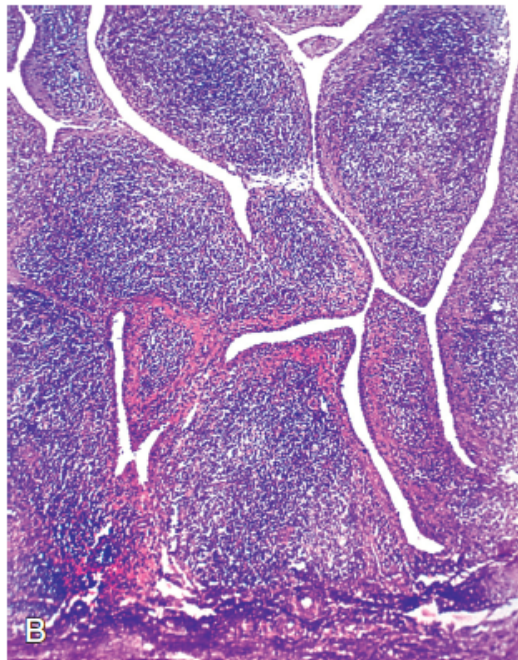
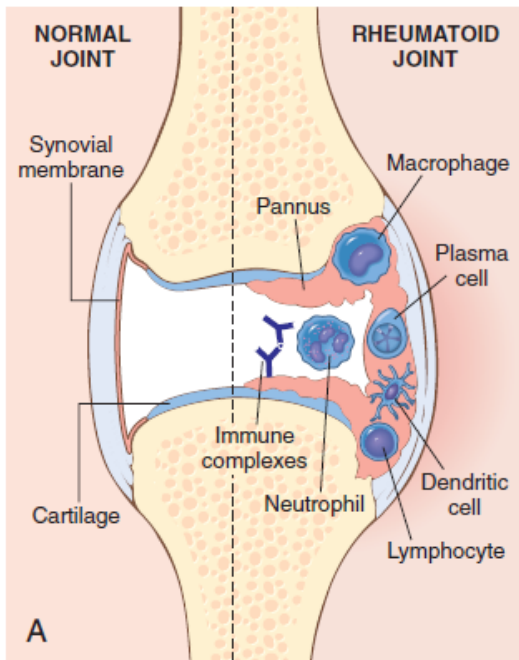
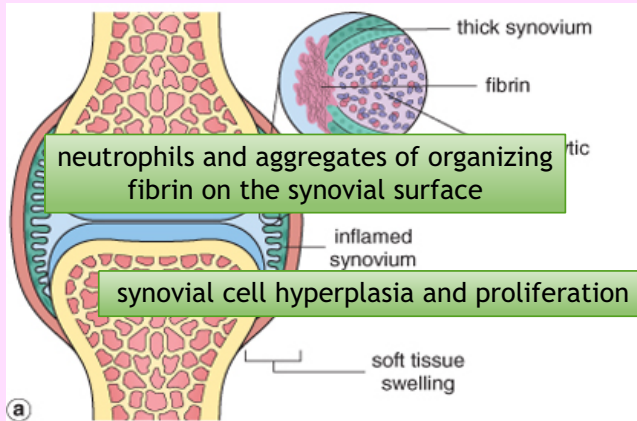


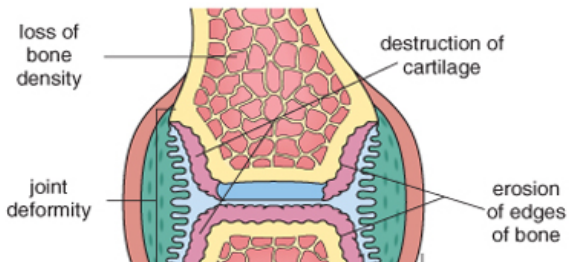
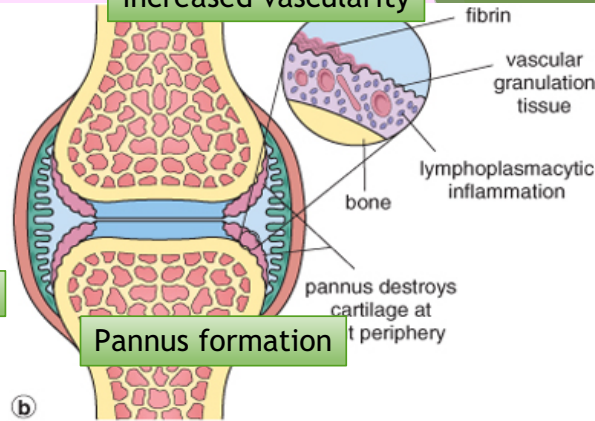
Fig. 21.37 Rheumatoid arthritis. (A) Schematic view of the joint lesion. (B) Low magnification shows marked synovial hypertrophy with formation of villi. (C) At higher magnification, subsynovial tissue containing a dense lymphoid aggregate. (A, Modified from Feldmann M: Development of anti-TNF therapy for rheumatoid arthritis. Nat Rev Immunol 2:364, 2002.)



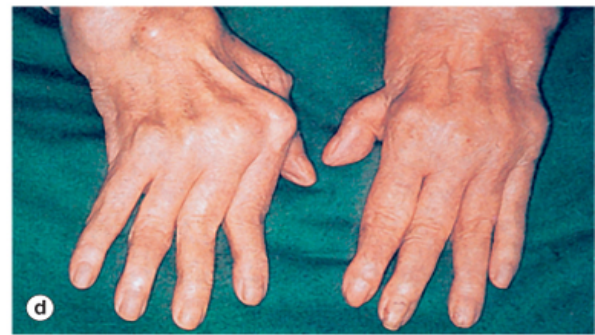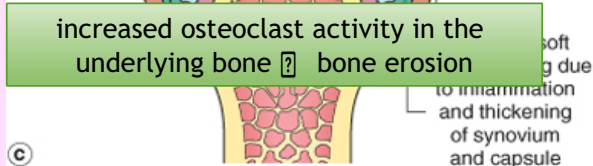
dense perivascular inflammatory cell infiltrates



increased vascularity



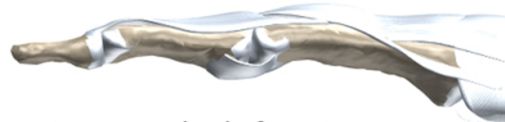increased osteoclast activity in the underlying bone [?] bone erosion



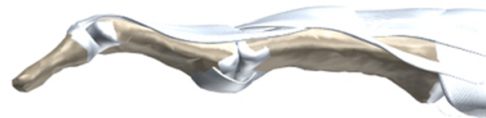
swan neck finger



Normal joint



Swan neck deformity



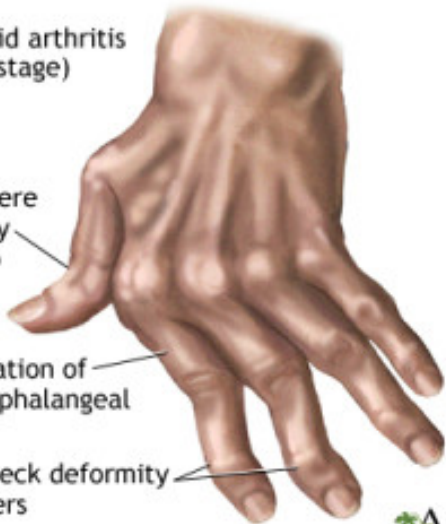DIP flexion with PIP hyperextension

Rheumatoid arthritis  
(late stage)

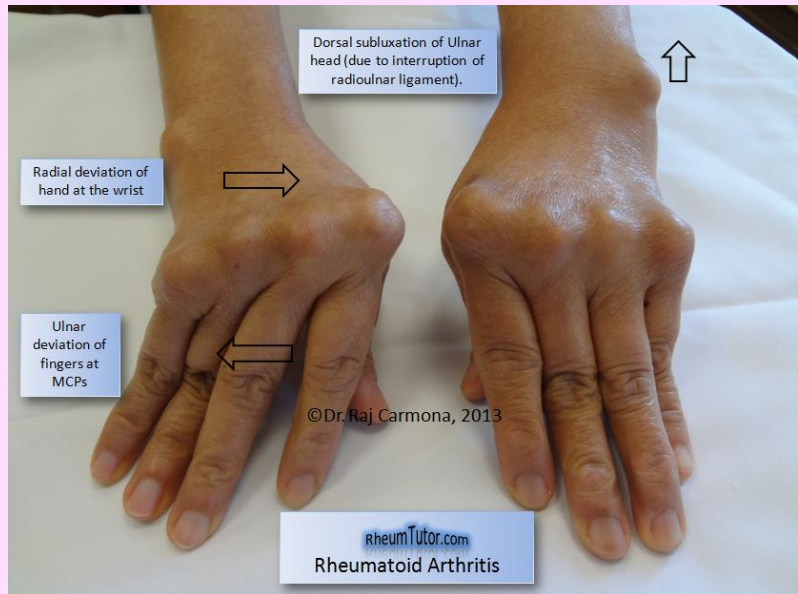
Boutonniere  
deformity  
of thumb

Ulnar deviation of  
metacarpophalangeal  
joints

Swan-neck deformity  
of fingers



ADAM



Dorsal subluxation of Ulnar  
head (due to interruption of  
radioulnar ligament).


Radial deviation of  
hand at the wrist

Ulnar  
deviation of  
fingers at  
MCPs

©Dr. Raj Carmona, 2013

rheumTutor.com  
Rheumatoid Arthritis

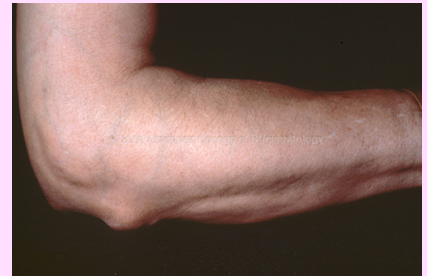## Boutonniere Deformity

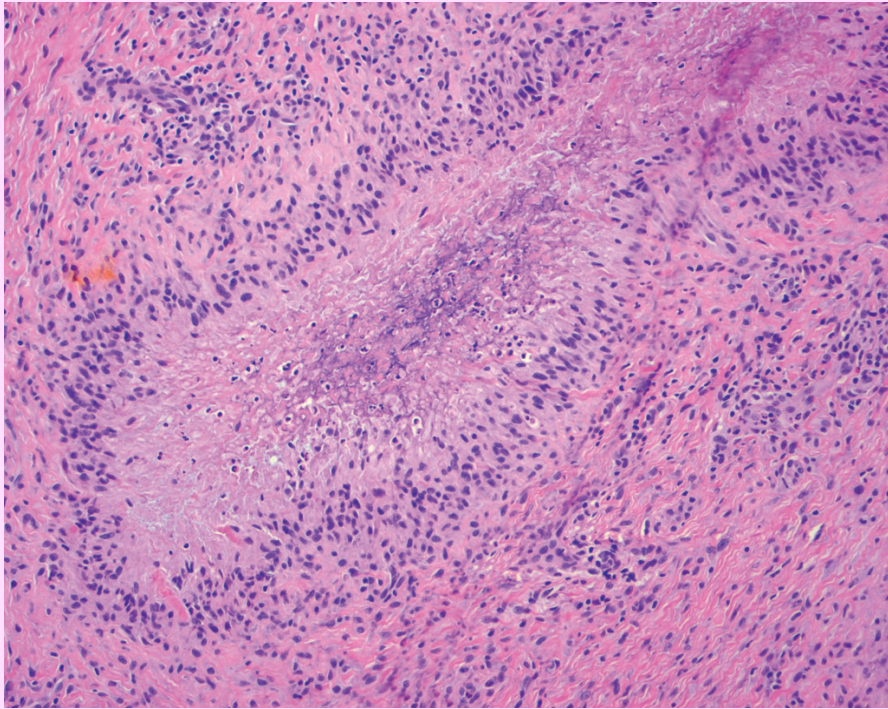


PIP flexed and DIP hyperextended

# Rheumatoid nodules

- Infrequent (1/4)
- Subcutaneous tissue including the forearm, elbows, occiput, and lumbosacral area.
- Resemble necrotizing granulomas.
- Rarely, RA can involve the lungs (rheumatoid nodules, interstitial lung disease).
- Rheumatoid nodules are firm, nontender, oval or rounded masses as large as 2 cm in diameter.
- They are characterized microscopically by a central focus of fibrinoid necrosis surrounded by a palisade of macrophages, which in turn is rimmed by granulation tissue and lymphocytes





aalsolami

# Clinical

- **Symmetric arthritis, principally affecting the small joints** of the hands and feet, ankles, knees, wrists, elbows, and shoulders.
- Most often, the proximal interphalangeal and metacarpophalangeal joints are affected, but distal interphalangeal joints are spared.
- Axial involvement, when it occurs, is limited to the upper cervical spine; similarly, hip joint involvement is extremely uncommon.

- Weakness , low grade fever
- aching and stiffness of the joints, particularly in the morning
- As the disease advances, the joints become enlarged, motion is limited
- characteristic deformities develop. These include:

Radial deviation at the wrists.

Ulnar deviation at the fingers.

Flexion and hyperextension deformities of the fingers (swan neck and boutonniere deformities).



# X-ray

- Loss of articular cartilage leading to narrowing of the joint space.
- Joint effusions.
- Erosions.

## Prognosis:

- The clinical course of RA is highly variable.
- In a minority of patients, the disease may stabilize or even regress
- in most patients it pursues a chronic, remitting-relapsing course.
- progressive joint destruction leading to disability after 10 to 15 years. The outcome has been dramatically improved by recent advances in therapy.
- RA is an important cause of reactive amyloidosis, which develops in 5% to 10% of these patients, particularly those with long-standing severe disease

# Treatment

- Corticosteroid
- Immunosuppressant like methotrexate, TNF antagonist
- Long term treatment with TNF antagonists carries with it increased risk of infections with organisms such as *M. tuberculosis*

	<b>Osteoarthritis</b>	<b>Rheumatoid Arthritis</b>
Basic process	Degenerative	Immunologic, inflammatory
Site of initial lesion	Articular cartilage	Synovium
Age	50 plus	Any, but peaks at age 20–40 years
Sex	Male or female	Female > male
Joints involved	Especially knees, hips, spine; asymmetric involvement	Hands, later large joints; multiple symmetric involvement
Fingers	Herberden's nodes	Ulnar deviation, spindle swelling
Nodules	No	Rheumatoid nodules
Systemic features	None	Uveitis, pericarditis, etc.
Constitutional symptoms	None	Fever, malaise in some
Laboratory findings	None	Rheumatoid factor; ↑erythrocyte sedimentation rate; anemia, leukocytosis, hyperglobulinemia
Joint fluid	Clear, normally viscous; no inflammatory cells	Clear; low viscosity, high protein; neutrophils, some lymphocytes; immunoglobulins, complement, rheumatoid factor

# Crystal-induced arthritis

Gout and pseudogout

# 1) Gout (Podagra)

Gout is marked by transient attacks of **acute arthritis** initiated by **urate crystals** deposited within and around joints

- Gout affects about 1% of the population, and shows a predilection for males.
- It is caused by excessive amounts of *uric acid*.
- **Hyperuricemia (plasma urate level above 6.8 mg/dL) is necessary, but not sufficient, for the development of gout.**
- **Monosodium urate crystals** precipitate from supersaturated body fluids and induce an acute inflammatory reaction.
- Gout is marked by recurrent episodes of acute arthritis, sometimes accompanied by the formation of large crystalline aggregates called *tophi*, and eventual permanent joint deformity.
- Risk factors for the disease include age (more than 30) , genetic, obesity, excess alcohol intake, consumption of purine-rich foods, diabetes, the metabolic syndrome, drugs, and renal failure.

**Table 20-3** Classification of Gout

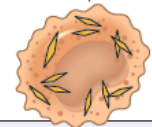
Clinical Category	Metabolic Defect
<b>Primary Gout (90% of cases)</b>	
Enzyme defects—unknown (85% to 90% of cases)	Overproduction of uric acid Normal excretion (majority) Increased excretion (minority) Underexcretion of uric acid with normal production
Known enzyme defects—e.g., partial HGPRT deficiency (rare)	Overproduction of uric acid
<b>Secondary Gout (10% of cases)</b>	
Associated with increased nucleic acid turnover—e.g., leukemias	Overproduction of uric acid with increased urinary excretion
Chronic renal disease	Reduced excretion of uric acid with normal production
Inborn errors of metabolism	Overproduction of uric acid with increased urinary excretion, e.g., complete HGPRT deficiency (Lesch-Nyhan syndrome)

HGPRT, hypoxanthine guanine phosphoribosyl transferase.

Hyperuricemia

Precipitation of urate crystals in joints

Activation of complement



Phagocytosis by macrophages

Release of LTB<sub>4</sub>, prostaglandins, free radicals

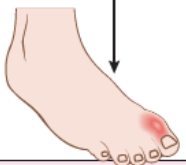Activation of inflammasome

Release of IL-1 $\beta$

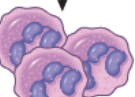
Secretion of chemokines and other cytokines

Cartilage  
Synovium

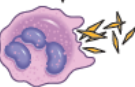Release of proteases



Tissue injury and inflammation

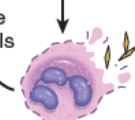


Neutrophil chemotaxis



Phagocytosis of crystals by neutrophils

Release of crystals



Lysis of neutrophils

Release of lysosomal enzymes

Negatively birefringent needle shape crystals



### Acute arthritis

- Dense inflammation in synovium and synovial fluid.
- Crystals in cytoplasm of neutrophils and synovium.
- Long, slender, needle, negative birefringence.
- Synovium is edematous and congested with few lymphocytes, plasma cells and macrophages.

### Chronic tophaceous arthritis

- Repetitive precipitation of crystals.
- **Chalky deposits** in synovium.
- Synovium: hyperplastic, fibrotic and thickened by inflammatory cells that form PANNUS destroy the cartilage.

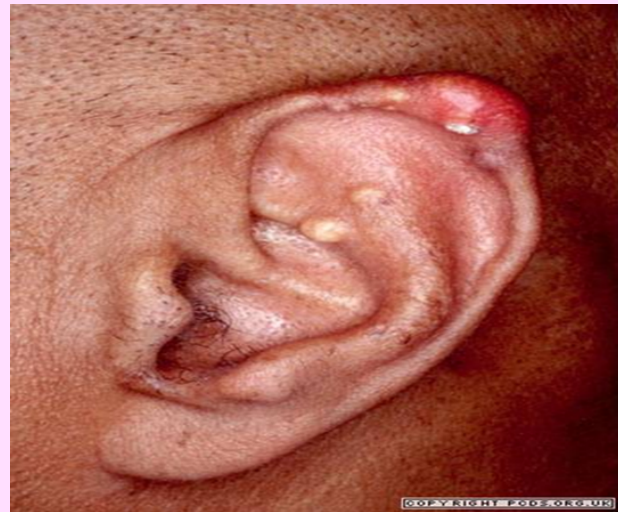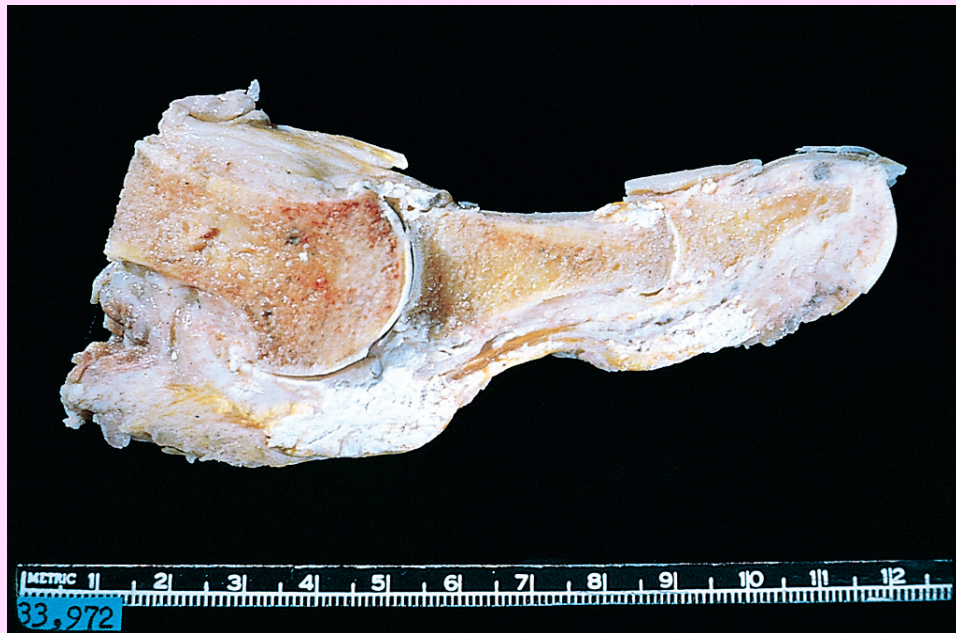### TOPHI

- large aggregations of urate crystals surrounded by an intense foreign body giant cell reaction.
- **cartilage, ligaments, tendons, and bursae are pathognomonic of gout**

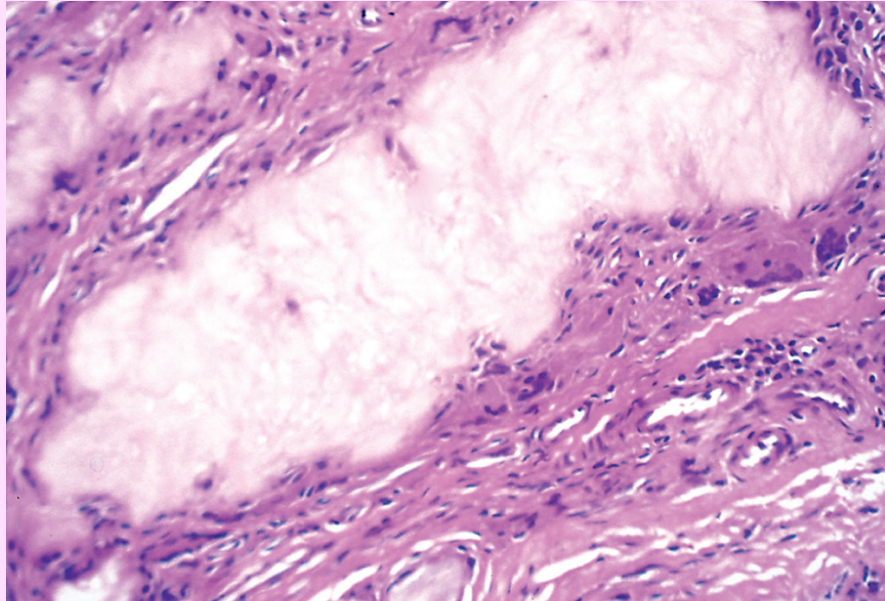
### Gouty nephropathy

- urate crystals or tophi in the renal medullary interstitium or tubules
- uric acid nephrolithiasis and pyelonephritis.

white tophi involving the  
joint and soft tissues



Gouty tophus—an aggregate of dissolved urate crystals is surrounded by reactive fibroblasts, mononuclear inflammatory cells, and giant cells.



Urate crystals are needle shaped and negatively birefringent under polarized light



### Asymptomatic hyperuricemia

- Around puberty in men and after menopause in women.

### Acute arthritis

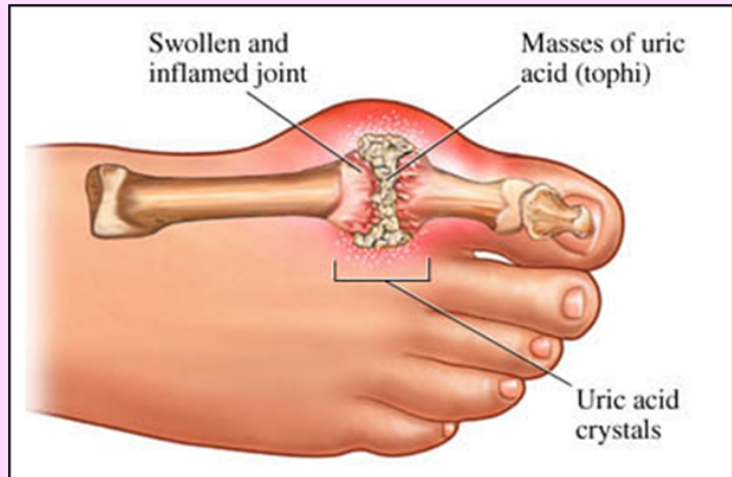
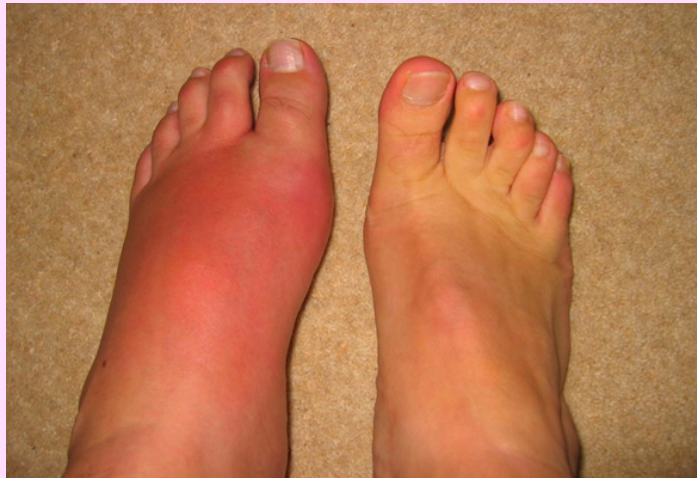- Sudden, excruciating joint pain, hyperemia, warmth
- 50% metatarsophalangeal joint.
- Last for hours to weeks.

### Asymptomatic intercritical period

- Resolution of acute.
- Symptom free.
- Not treated.. Frequent attacks and multiple joints.

### Chronic tophaceous gout

- 12 years after initial attack.
- Radiology..loss of joint space.



# Treatment

- Lifestyle modification
- Reduce symptoms (NSAIDs)
- Lower urate level (medications)

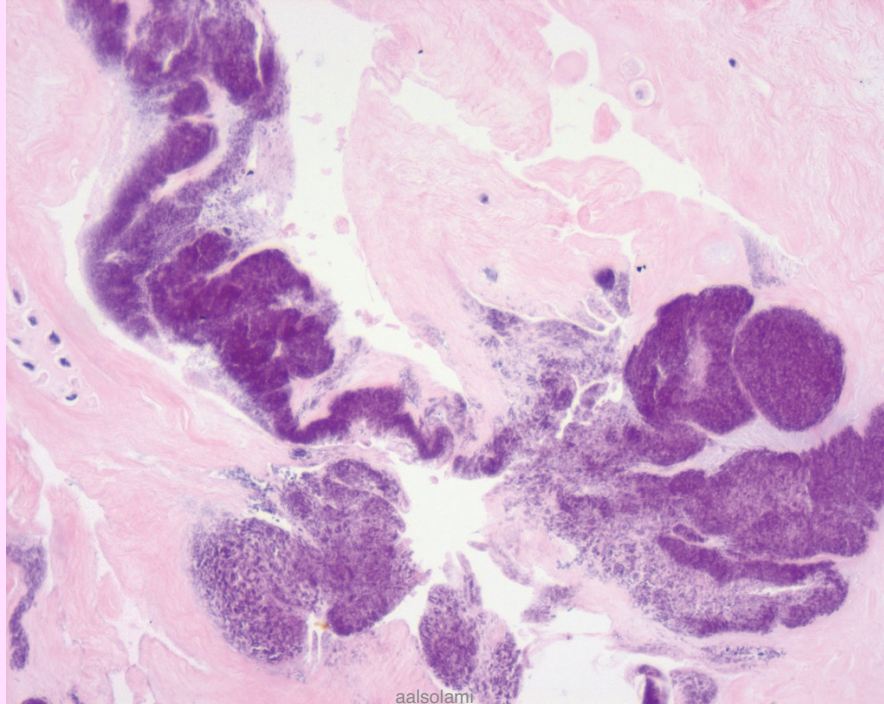
# Calcium Pyrophosphate Crystal Deposition Disease (Pseudogout)

- CPPD.
- This condition is due to the deposition of CPPD in the synovium (pseudogout) and articular cartilage (chondrocalcinosis).
- It can occur in three main settings:
  - 1) Sporadic (more common in the elderly).
  - 2) Hereditary.
  - 3) Secondary to other conditions, such as previous joint damage, hyperparathyroidism, hypothyroidism, haemochromatosis and diabetes.
- The crystals first develop in the articular cartilage (chondrocalcinosis), which is usually asymptomatic. From here, the crystals may shed into the joint cavity resulting in an acute arthritis, which mimics gout and is therefore called pseudogout.

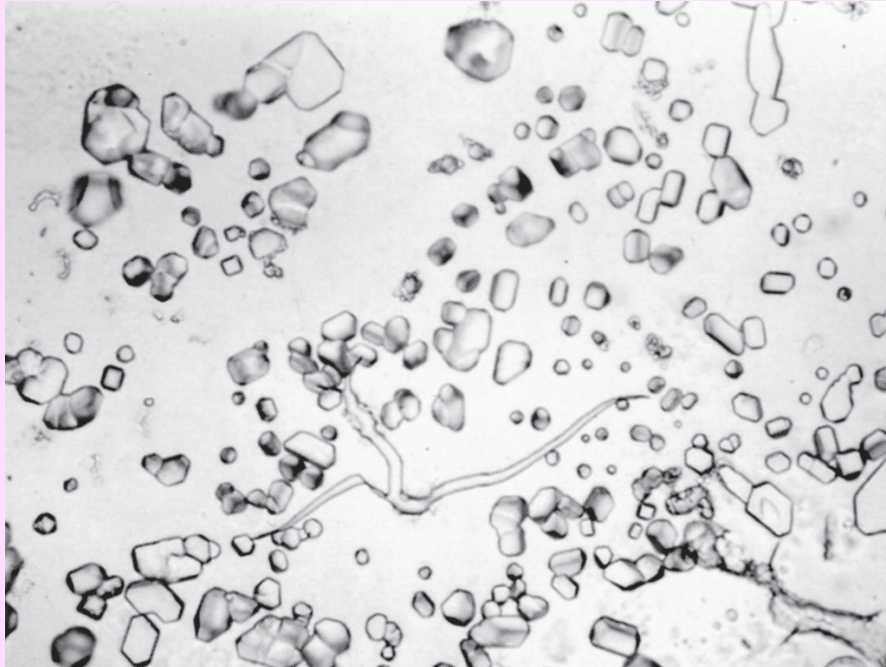


- Pseudogout can be differentiated from gout in three ways:
  - 1) The knee is most commonly involved, wrist, elbow, shoulder, ankle.
  - 2) X-rays show the characteristic line of calcification of the articular cartilage.
  - 3) The crystals look different under polarizing microscopy, they are rhomboid in shape, positively birefringent .

Deposits are present in cartilage and consist of amorphous basophilic material (blue-purple)



Smear preparation of calcium pyrophosphate crystals.



## OSTEOARTHRITIS (OA)

Type 2 collagen  
eburnation  
Joint mice  
Bouchard  
osteophyte  
Heberden

## RHEUMATOID ARTHRITIS (RA)

CCP  
Pannus  
HLA-DR  
Boutonniere  
Ankylosis  
Swan neck

## GOUT AND PSEUDOGOUT (CRYSTAL-INDUCED)

Tophi  
Rhomboid  
Needle  
birefringence

# Reference

Kumar V, Abbas AK, Aster JC. Robbins Basic Pathology. 10<sup>th</sup> ed. Elsevier; 2017. Philadelphia, PA.  
p. 817-821 and 823-826.

aalsolami1@ksu.edu.sa

