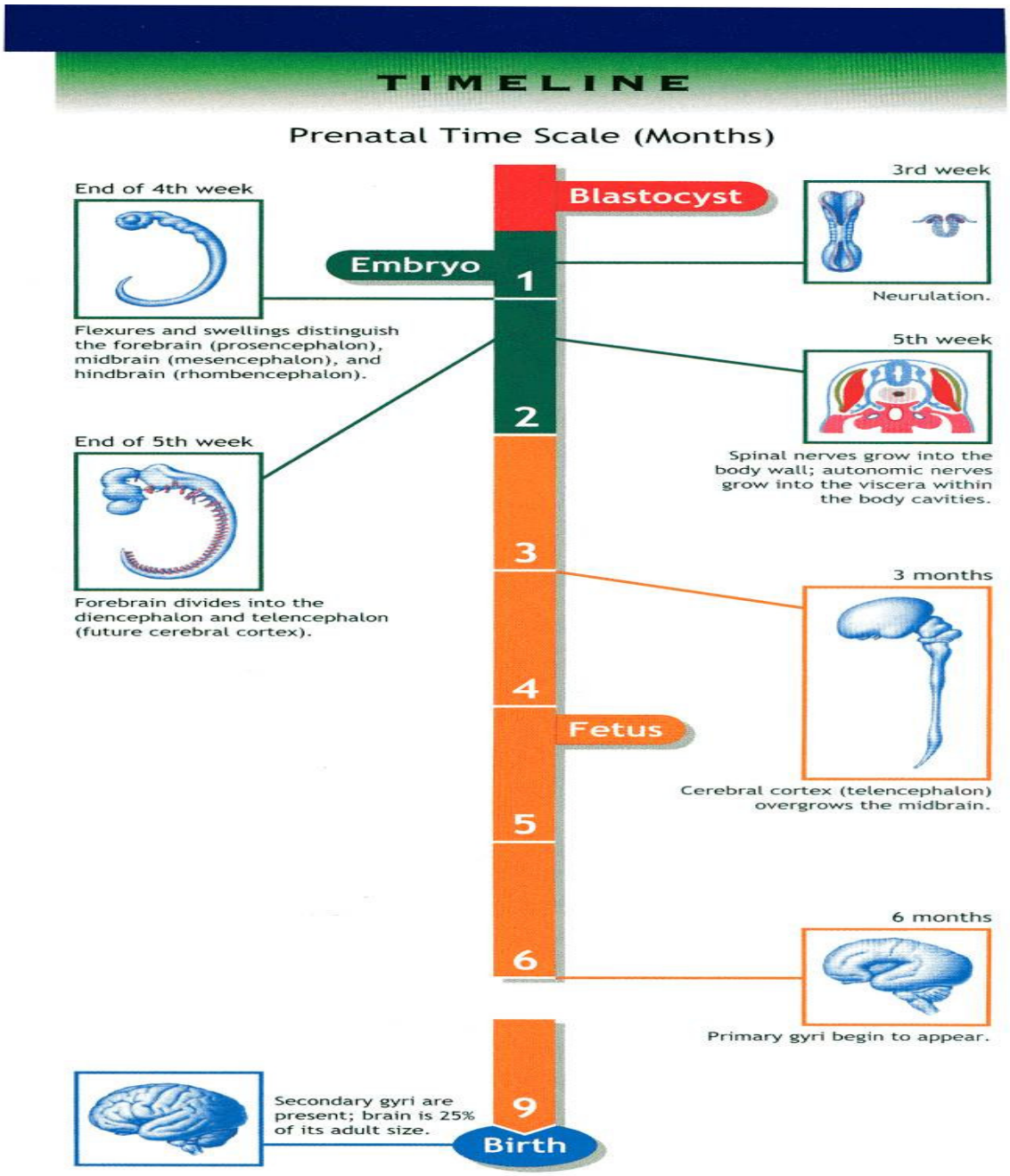

EARLY DEVELOPMENT :

- By the beginning of the 2nd week of human embryonic development, 3 germ cell layers become established : **ectoderm, mesoderm** and **endoderm.**

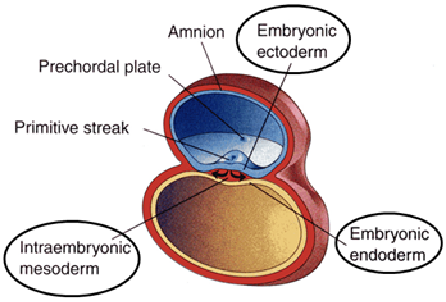

- Subsequently, these each germ layer give rise to particular tissues and organs in the adult.

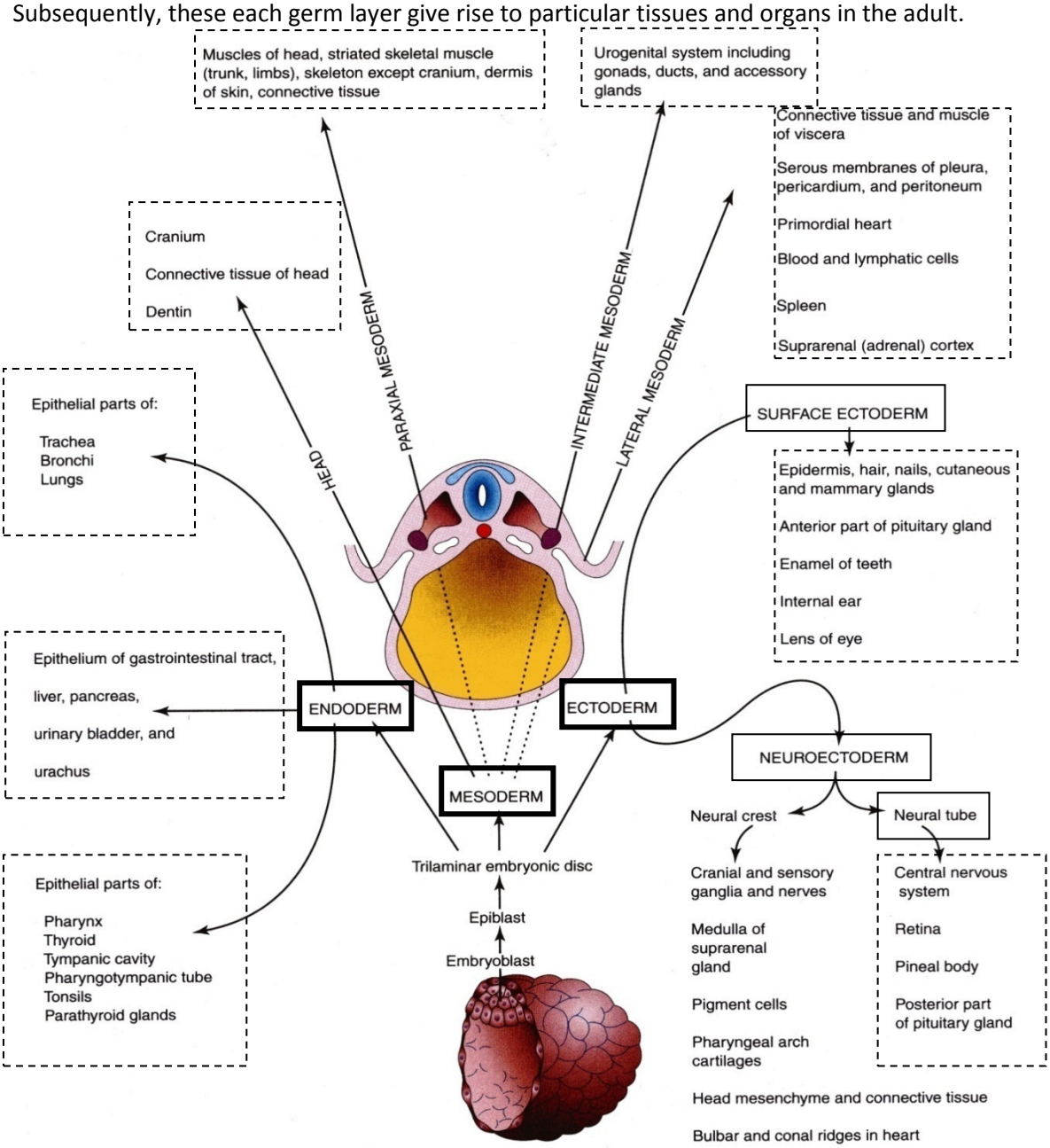

- The **ectoderm** gives rise to the skin and the nervous system.
- The **mesoderm** forms skeletal, muscular and connective tissues.
- The **endoderm** gives rise to the alimentary, respiratory and genitourinary tracts.

- During the third week of embryonic development, ***the dorsal midline ectoderm*** undergoes thickening to form the **neural plate.**
- The lateral margins of the neural plate become elevated, forming **neural folds** on either side of a longitudinal, midline depression, the **neural groove.**
- The neural folds then become apposed and fuse together, thus sealing the neural groove and creating the **neural tube.**

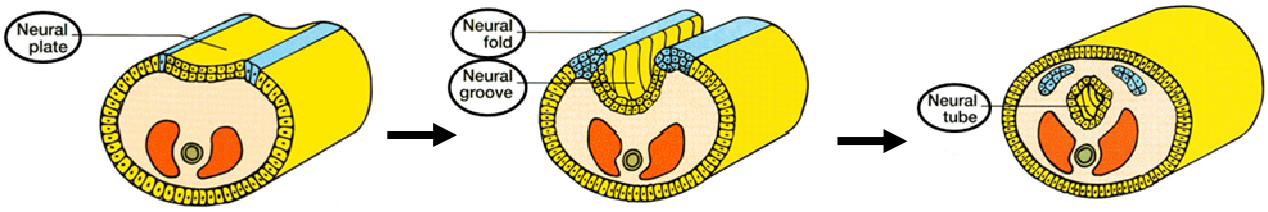

- Some cells from the apices of the neural folds become separated to form groups lying dorsolateral to the neural tube.
- These are known as the **neural crests.**
- The formation of the neural tube is complete by about the middle of the 4th week of embryonic development.

DEVELOPMENT OF THE SPINAL CORD :

- Enormous growth, distortion and cellular differentiation occur during the subsequent transformation of the neural tube into the adult CNS.
- This is maximal in the **rostral part, *which develops into the brain,*** the **caudal portion *becoming the spinal cord.***

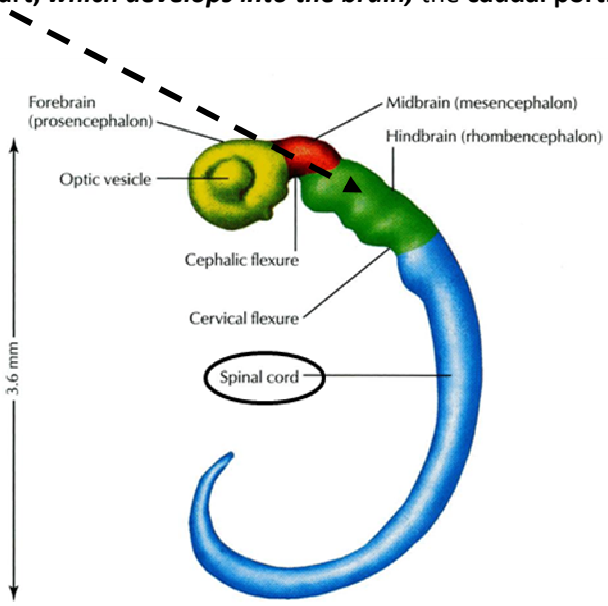

Central nervous system at 28 days

- The **central cavity** within the neural tube becomes the ***central canal*** of the spinal cord and the ***ventricles*** of the brain.

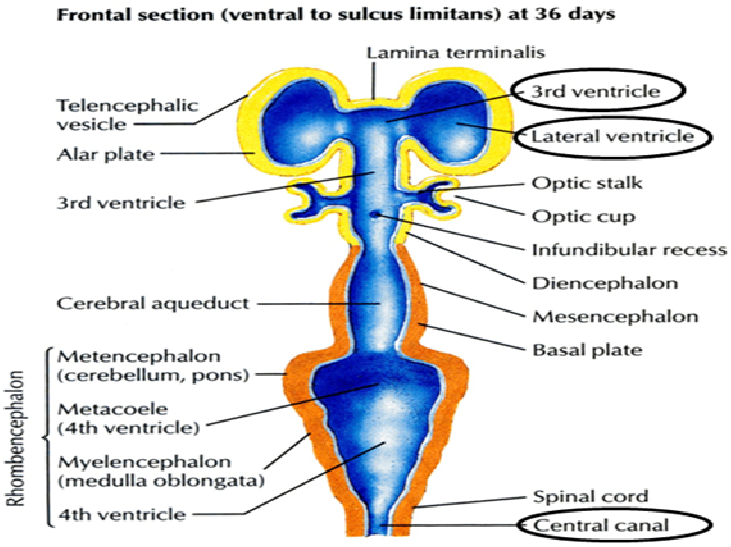

- The **neural crests** ***form the sensory ganglia*** of spinal and cranial nerves, and also the ***autonomic ganglia.***

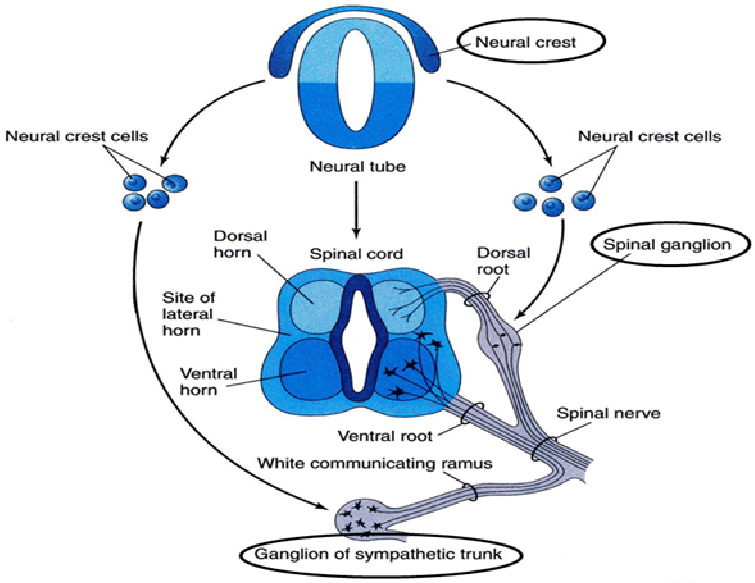

- As development continues, a longitudinal groove, the **sulcus limitans,** appears on the inner surface of the lateral walls of the embryonic spinal cord and caudal part of the brain.
- The dorsal and ventral cell groupings thus delineated are referred to as the **alar plate** and the **basal plate,** respectively.

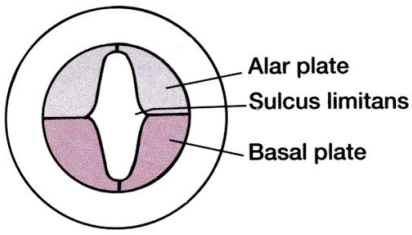

- Nerve cells that develop within the **alar plate** have predominantly ***sensory functions,*** while those in the **basal plate** are predominantly ***motor.***
- Further development also brings about ***the differentiation of grey and white matter.***
- The **grey matter** ***is located centrally around the central canal,*** with **white matter** ***forming an outer coat.***

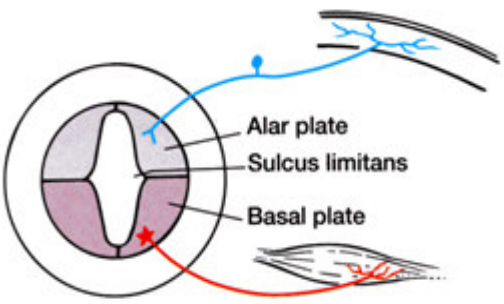

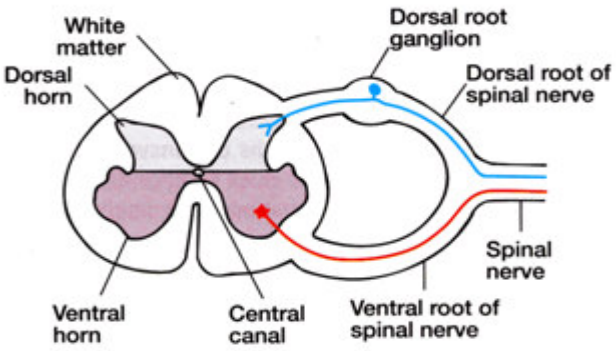

- This basic developmental pattern can still easily be recognised in the adult spinal cord.

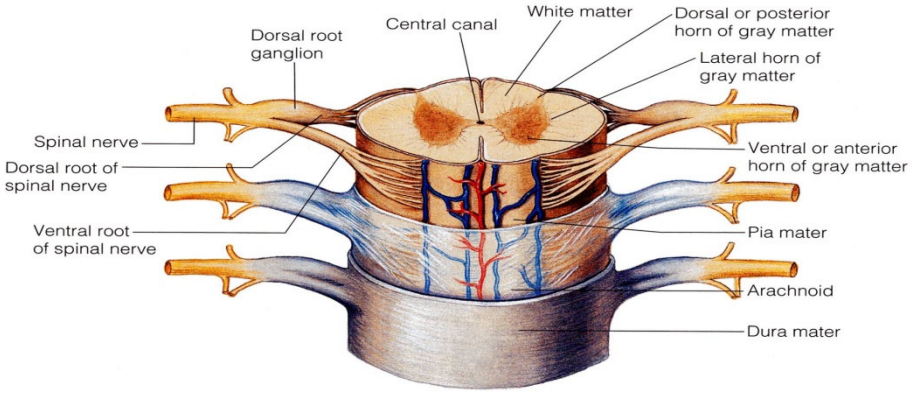

DEVELOPMENT OF THE BRAIN :

- During embryonic development, the rostral portion of the neural tube undergoes massive differentiation and growth to form the brain.
- By about the fifth week, ***three primary brain vesicles*** can be identified :
  the **prosencephalon** (forebrain), **mesencephalon** (midbrain) and **rhombencephalon** (hindbrain).
- The longitudinal axis of the developing CNS (neuraxis) does not remain straight but is bent by a **midbrain** or **cephalic flexure,** occurring at the junction of midbrain and forebrain, and a **cervical flexure** between the brain and the spinal cord.

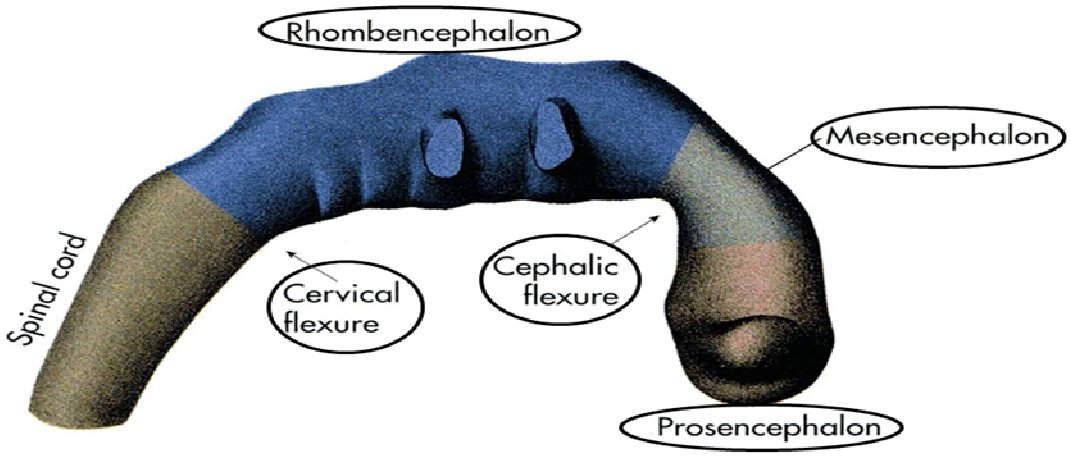

- By the ***seventh week*** further differentiation distinguishes **five secondary brain vesicles** produced by :
  - ***division of the prosencephalon*** into the **telencephalon** and **diencephalon** and
  - ***division of the rhombencephalon*** into the **metencephalon** and **myelencephalon.**
- The junction between the metencephalon and the myelencephalon is marked by an additional bend in the neuraxis, called the **pontine flexure.**

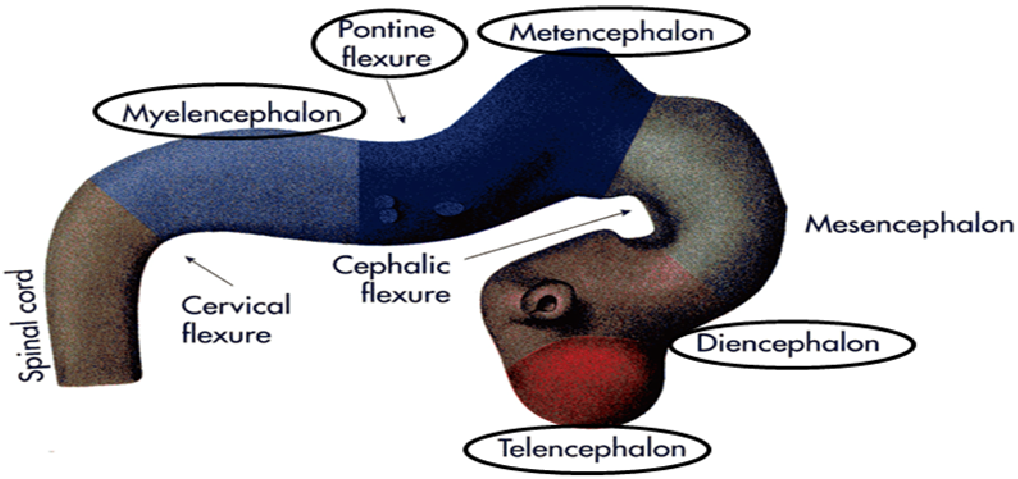

Primary brain vesicles	Secondary brain vesicles	Derivatives in mature brain
Prosencephalon (forebrain)	Telencephalon	Cerebral hemisphere
	Diencephalon	Thalamus
Mesencephalon (midbrain)	Mesencephalon	Midbrain
Rhombencephalon (hindbrain)	Metencephalon	Pons, cerebellum
	Myelencephalon	Medulla oblongata

FURTHER DEVELOPMENT OF THE BRAIN :

- Of the three basic divisions of the brain, the **prosencephalon** or forebrain is by far the largest.
- It is also referred to as the **cerebrum.**

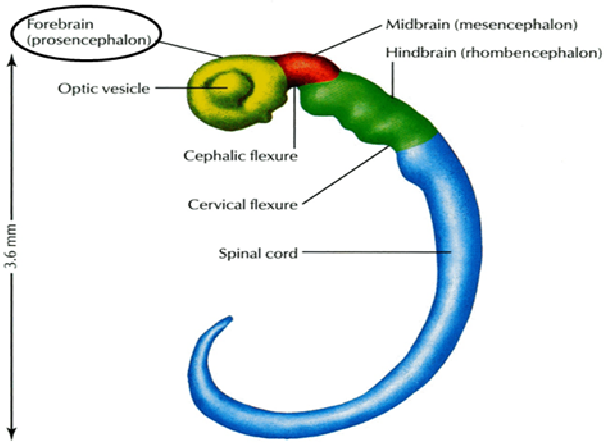

Central nervous system at 28 days

- Within the cerebrum, **the telencephalon** undergoes the greatest further development and gives rise to the two **cerebral hemispheres.**

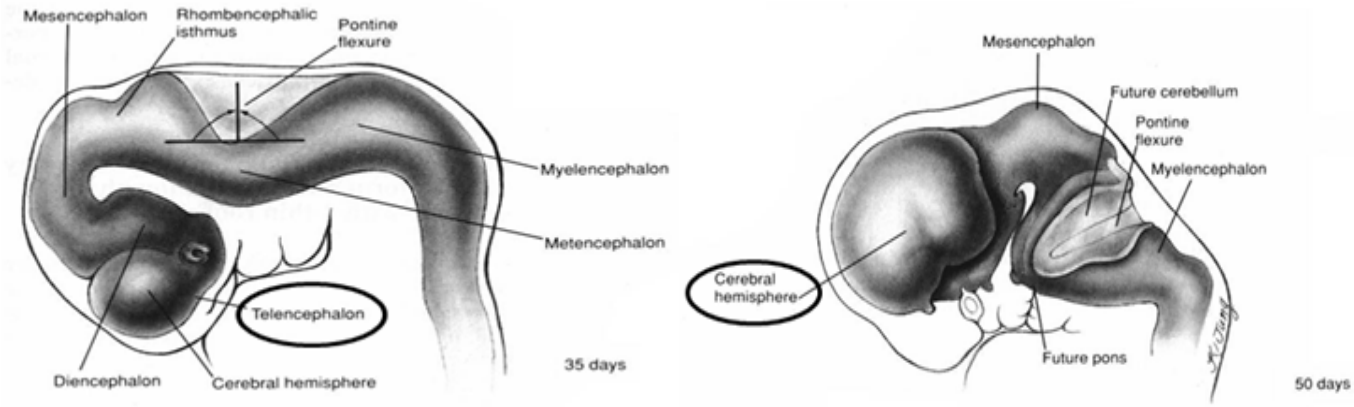

- The cerebral hemispheres consist of :
  - an **outer layer of grey matter *(the cerebral cortex)*** and
  - an **inner mass of white matter,** within which various groups of ***nuclei*** lie buried (the largest being the corpus striatum).

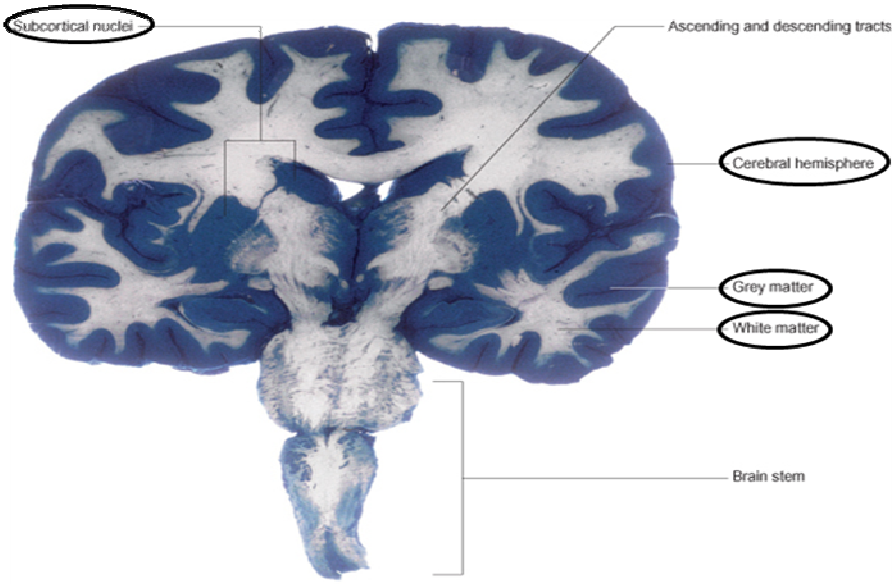

- **The diencephalon** consists largely of the ***thalamus,*** which contains numerous cell groupings and is intimately connected with the cerebral cortex.

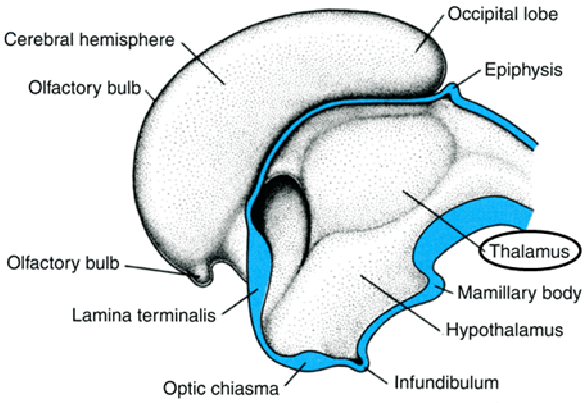

Medial surface of the right half of telenecephalon and diencephalon in an 8-week embryo

- ***The mesencephalon,*** or midbrain, is relatively undifferentiated
  (it still retains a central tube-like cavity surrounded by grey matter).

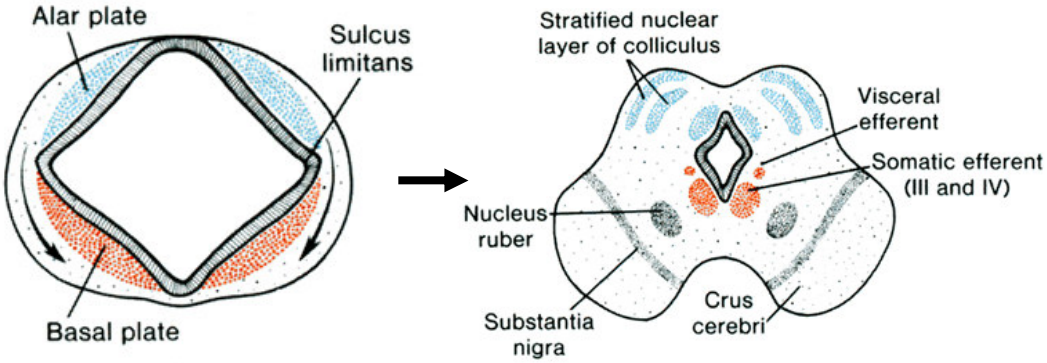

- **The metencephalon** develops into the ***pons*** and overlying ***cerebellum.***
- **The myelencephalon** forms the ***medulla oblongata (medulla).***

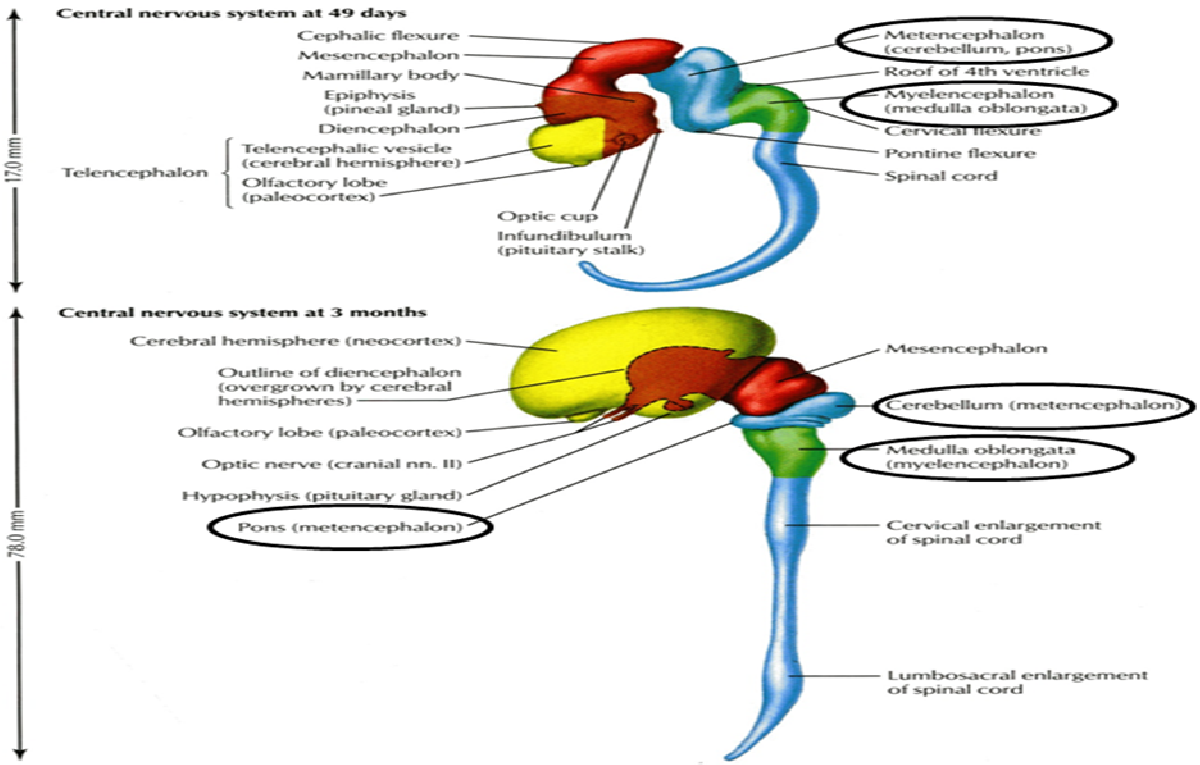

- As the brain develops, its **central cavity** also undergoes considerable changes in size and shape forming a system of chambers or ***ventricles,*** which contain ***cerebrospinal fluid*** *(CSF).*

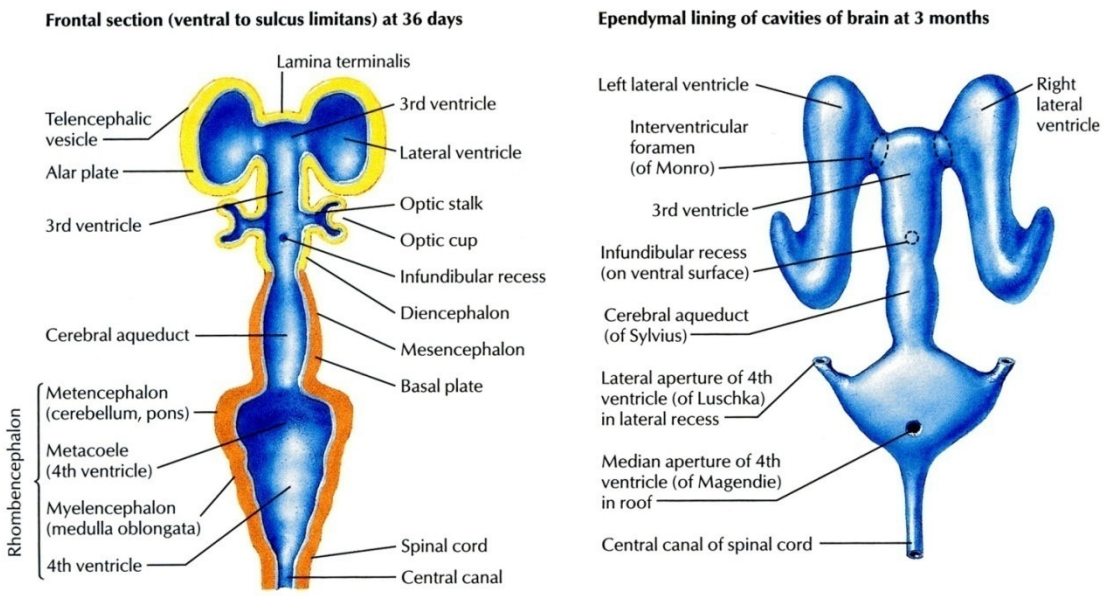

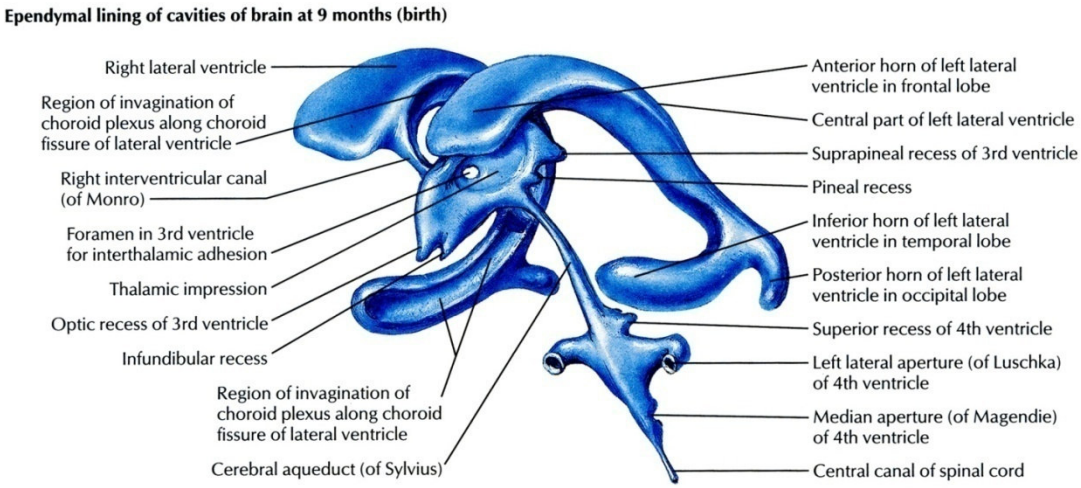

PHYLOGENY :

- Parallels have sometimes been drawn between the embryological development of the brain and the major changes that the brain has undergone during ascent of the phylogenetic, or evolutionary, scale from simple to more complex animals.
- While this is certainly an oversimplification, the concept does have the advantage of introducing some of the principal parts of the brain, and their relationships to one another, in a graphic and memorable way.

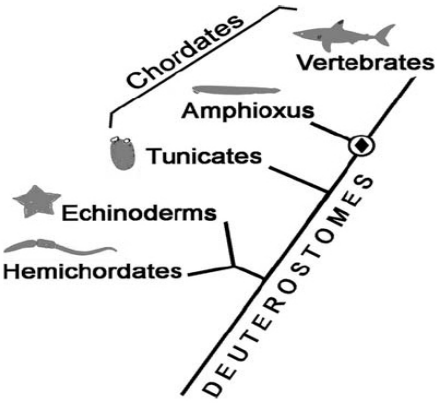

- The simplest of chordate animals (e.g. **amphioxus**), from which the vertebrates evolved, possesses a dorsal tubular nerve cord that is reminiscent of the neural tube of the developing mammalian embryo.

- During phylogeny, the rostral end of the tubular nervous system has undergone enormous modification and change; consequently, the adult human brain bears little obvious similarity to its evolutionary ancestors.

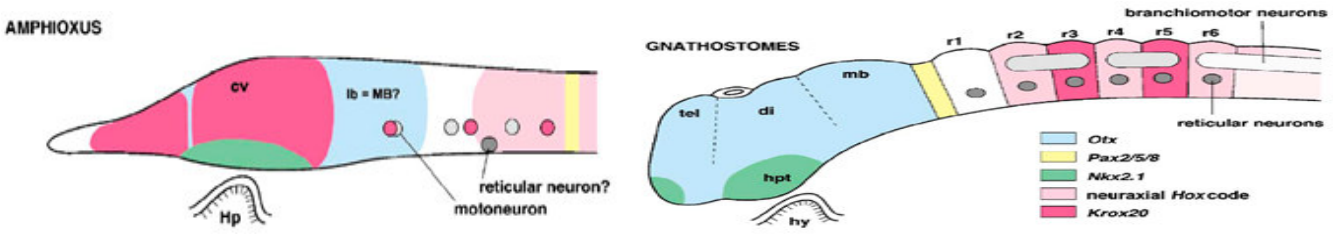

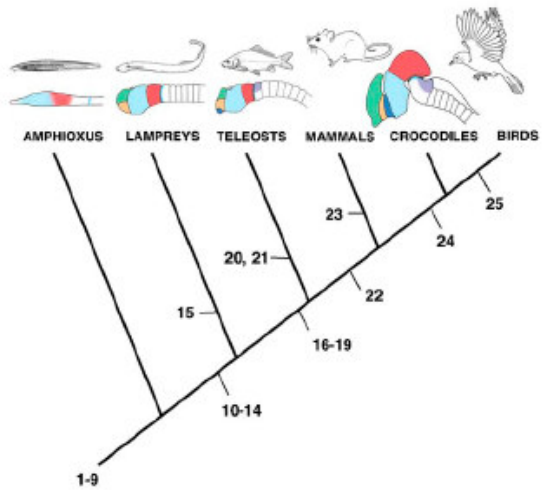

Fig. 5. Evolutionary scenario of the developmental patterning in vertebrate nervous system. On each segment of the phylogenetic tree, sequentially added developmental changes are placed as synapomorphic character states such as (1) neural tube; (2) ancestral expression pattern of regulatory genes along the anteroposterior neuraxis (*Pax6*, *Pax2/5/8*, *En*, *Fgf8/17*, *Otx*, *Emx*, *Dlx1/6*, *Nkx2.1*, etc); (3) reticular neurons?; (4) motoneurons; (5) diencephalons (shown in cyan); (6) mesencephalon? (shown in red); (7) rhombencephalon; (8) eye; (9) neuraxial *Hox* code; (10) neuromeres (establishment of neurepithelial compartments as serial homologues); (11) *Hox* code-dependent specification of branchiomotor neurons; (12) telencephalon (pallium (shown in green) + LGE (shown in orange)); (13) neural crest (peripheral ganglia); (14) paired eyes; (15) lamprey-specific serial homologues in reticulospinal neurons (B neurons); (16) integration of *Hox*-dependent- and rhombomere-dependent specification programs; (17) MGE (shown in blue) and migrating GABAergic interneurons; (18) sympathetic trunk; (19) cerebellar system (shown in gray); (20) teleost-specific serial homologues in reticulospinal neurons; (21) eversion of the telencephalon; (22) loss of serial homologues from reticulospinal neurons; (23) neocortex with six layers in mammals; (24) dorsal ventricular ridge; (25) loss of layers from the dorsal pallium.

- **Regional specialisation** has been an important theme in the evolution of the brain and this is especially obvious ***in relation to the senses and in movement control.***
- Long ago in phylogeny, centres devoted to these functions developed as expansions or ***outgrowths from the dorsal aspect of the simple tubular brain.***
- In form, they consisted of an ***outer cortex of nerve cell bodies with an underlying core of nerve fibres.***



- **Bilaterally paired centres** ***developed in relation to the senses of smell, vision and hearing,*** and a **symmetrical, midline centre** ***developed in association with vestibular function and the maintenance of equilibrium.***

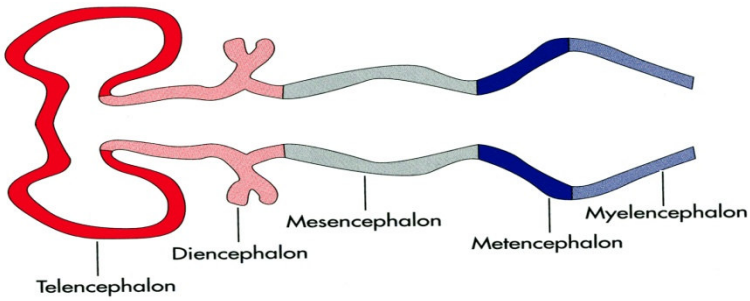

PROSENCEPHALISATION :

- Each of the brain centres underwent subsequent evolutionary change, but this was most evident in the rostral, 'olfactory', part of the brain, which developed into the massive cerebral hemispheres.

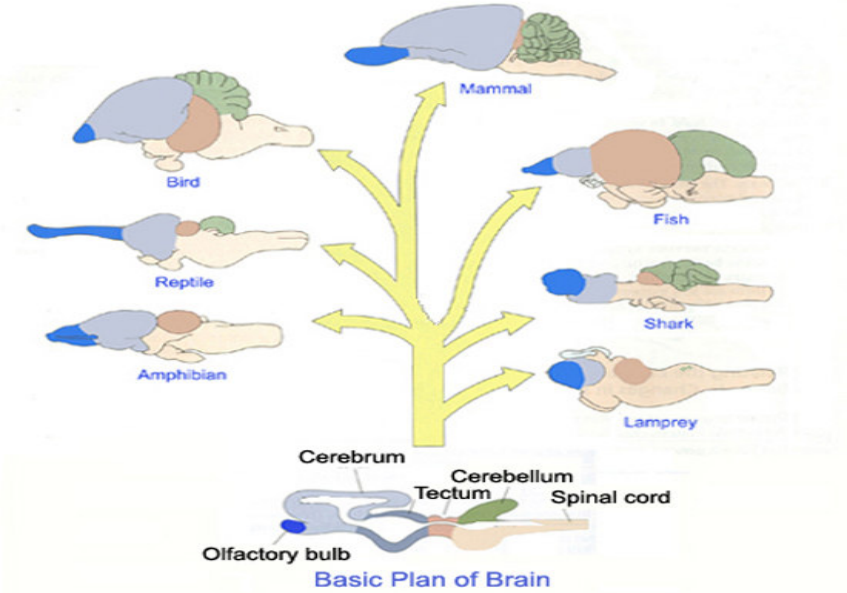

- During this **process of prosencephalisation,** the cerebral hemispheres ***came to take on an executive role*** in many areas of brain function.
- For example, the highest level for **perception and correlation of all sensory modalities** eventually became localised in the cortical surface of the cerebral hemispheres, as did the highest level for **motor control.**

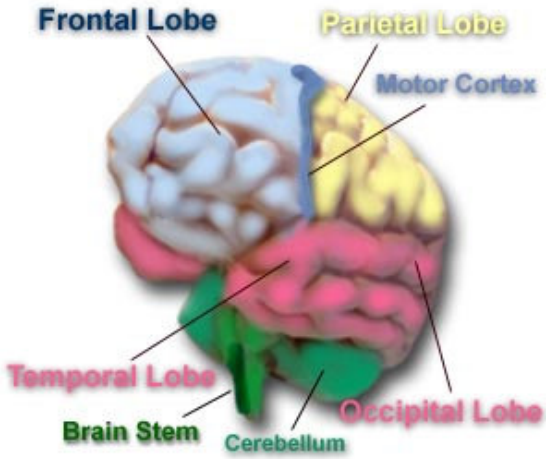

- This is reflected by the fact that only a small proportion of the adult human cerebral hemisphere remains directly related to olfactory function.

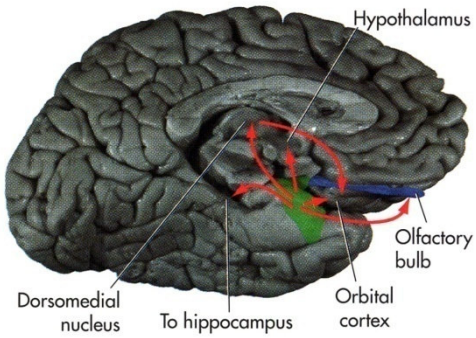

Projections of the primary olfactory cortex

- The process of prosencephalisation meant that ***the other centres became progressively subservient to the cerebral hemispheres.***
- For example, those for vision and hearing underwent relatively little development and fulfil largely automatic, reflex functions in the human brain.
- They may still be identified, however, as four small swellings on the dorsal surface of the midbrain : the **corpora quadrigemina** or **superior and inferior colliculi.**

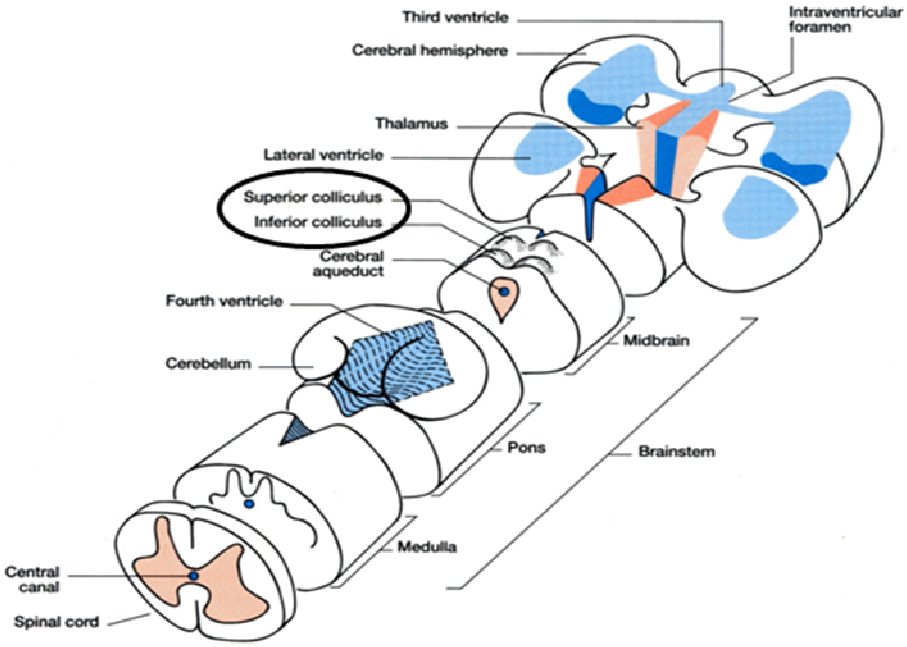

- ***The motor centre near the caudal end of the brain developed into the cerebellum,*** which retains a very important role in the maintenance of equilibrium and the coordination of movement.

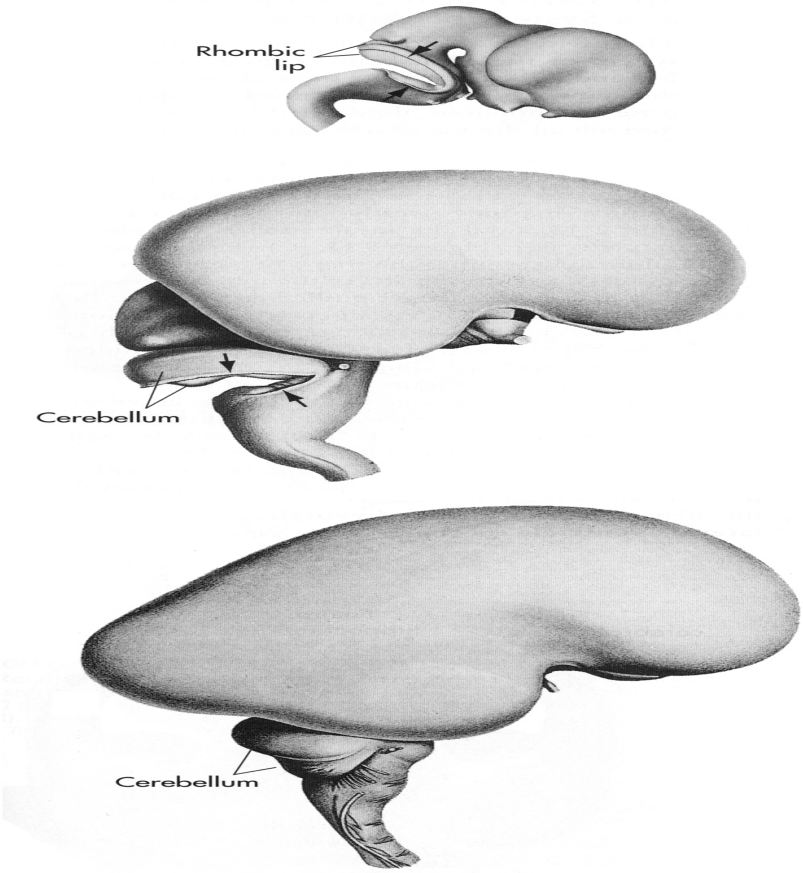

DEVELOPMENTAL ANOMALIES

- Disorders of development disrupt the normal growth and structural organisation of the spinal cord and brain.
- Because the nervous system is derived from embryonic ectoderm, these developmental anomalies also involve the coverings of the nervous system (skin and bone).

ANENCEPHALY :

- In **anencephaly,** the brain and skull are minute and the infant does not usually survive.

SPINA BIFIDA :

- In **spina bifida,** the lower spinal cord and nerve roots are underdeveloped and may lie uncovered by skin or the bony spine on the infant's back **(meningiomyelocele).**
- Such infants are left with withered, paralysed and anaesthetic lower limbs together with incontinence of the bowel and bladder.

THE END

LoveTomy Team 426

Team leader : Dr. hams

Done by : Omar H.

SELF QUIZ

1- Regarding development of the brain, all are true, EXCEPT :

a- The rostral portion of the neural tube undergoes massive differentiation and growth to form the brain.
b- Rhombencephalon become finally midbrain.
c- By about the fifth week, *three primary brain vesicles* can be identified.
d- By the *seventh week* further differentiation distinguishes five secondary brain vesicles.
e- Prosencephalon or forebrain is by far the largest, It is referred to as the cerebrum.

2- Regarding development of the CNS, all the statements are true, EXCEPT :

a- The formation of the neural tube is complete by about in the fourth week.
b- Rostral part, *it develops into the brain*.
c- The caudal portion *becoming the spinal cord.*
d- Nerve cells that develop within the alar plate have predominantly *motor functions.*
e- Nervous system is derived from embryonic ectoderm.

1. b	2. d

MATCHING

a. Rhombencephalon	1. Telencephalon and diencephalon
b. Prosencephalon	2. Metencephalon and myelencephalon
c. Telencephalon	3. Cerebral hemispheres
d. Diencephalon	4. Pons ,cerebellum
e. Metencephalon	5. Thalamus

a. 2	b. 1	c. 3	d. 5	e. 4