

Motor lesions

By

Dr. Hayam Gad

*Associate Professor of
Physiology*

• Objectives

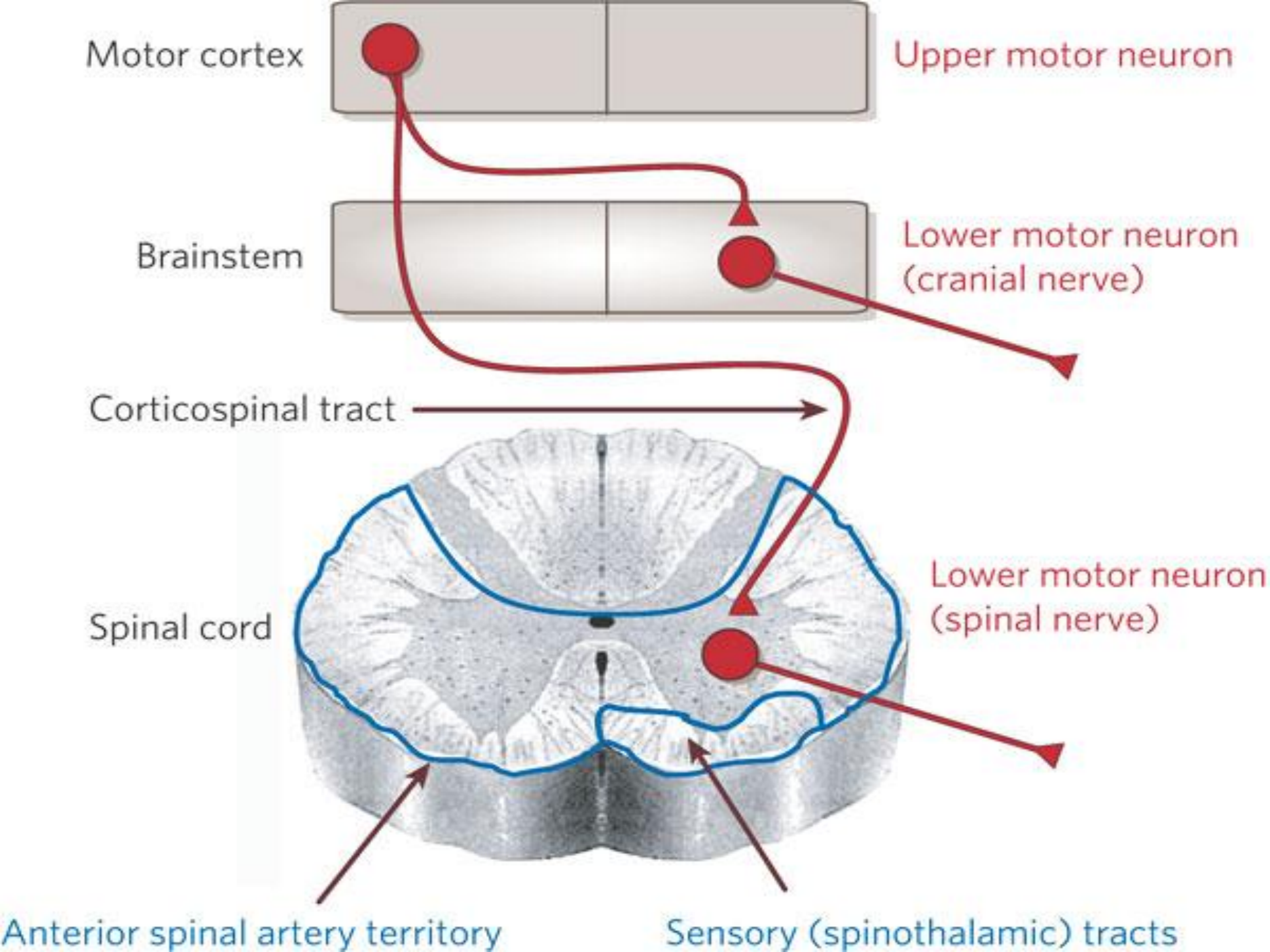
- Appreciate what is meant by upper and lower motor neurons
- Explain manifestations of upper and lower motor neurons lesions
- Know effects of lesion in pyramidal tracts at various levels
- Know effects of lesion in the internal capsule
- Explain the manifestations of complete spinal cord transection and hemisection.

Upper and lower motor neurons

- The performance of a voluntary act needs the integrity of 2 sets of motor neurons; upper and lower motor neurons.

Upper motor neurons:

- These consist of the motor cells of the cerebral cortex and their axons, which relay at the motor nuclei of the brain stem and spinal cord; chiefly of the opposite side.



- These descending tracts include:
 - The corticonuclear tract: which arises from area 8 of the frontal cortex and terminates in the motor nuclei of the III, IV, VI cranial nerves.
 - The cortico-bulbar tract: which arises from the motor area and terminates in the motor nuclei of V, VII, IX, X, XI, and XII cranial nerves.
 - The corticospinal tract (pyramidal tract): which arises from the motor area and terminates at the anterior horn cells of the spinal cord.

**Lower motor neurons include the
following sets:**

- 1- Neurons in the motor nuclei of all the above mentioned cranial nerves and their axons to skeletal muscles of the eyes and the head.
- 2- Anterior horn cells of the spinal cord and their axons to skeletal muscles of the body.

Upper and lower motor neuron lesions

Manifestations of upper motor neuron lesion (UMNL):

- Extent of paralysis; is wide spread because the pyramidal fibers form a compact bundle which occupies a small area.
- Site of paralysis; is opposite to the lesion e.g. hemorrhage into the right internal capsule causes hemiplegia or paralysis of the muscles of the left half of the face and of the left upper and lower limbs.

- Tone of the muscles; there is hypertonia and hyperreflexia due to block of the extrapyramidal inhibitory discharge on the gamma efferent and hence the excitatory reticular formation becomes unopposed. So, spasticity is a release phenomenon from the normal inhibitory discharge.

- Reflexes;
 - Superficial reflexes are absent on the affected side as they receive their facilitatory influence from the pyramidal tracts.
 - Deep reflexes are exaggerated with appearance of clonus. Babinski's sign with its center in S1& 2 is positive.

- Wasting of the muscles; is very slight due to exaggerated tone (spasticity). The slight wasting results from the lack of voluntary movements.
- Response of muscles to electrical stimulation is normal, with normal excitability.

Manifestations of lower motor neuron lesion (LMNL):

- Extent of paralysis; is localized depending on the site of the lesion.
- Site of paralysis; is at the same side of the lesion e.g. damage of the AHCs on the right side of spinal cord causes paralysis of the muscles supplied by these AHCs on the right side.

- Tone of the muscles; there is hypotonia because the stretch reflex arc is cut.
- Reflexes; both superficial and deep reflexes are absent in the affected segments.

- Wasting of the muscles; is very marked due to absence of reflex tone as well as lack of voluntary movements.
- Response of muscle to electrical stimulation is abnormal. The response is weak contraction with decreased excitability, then no response when it is transformed into fibrous tissues.

Effect of lesions of the pyramidal tracts at various levels

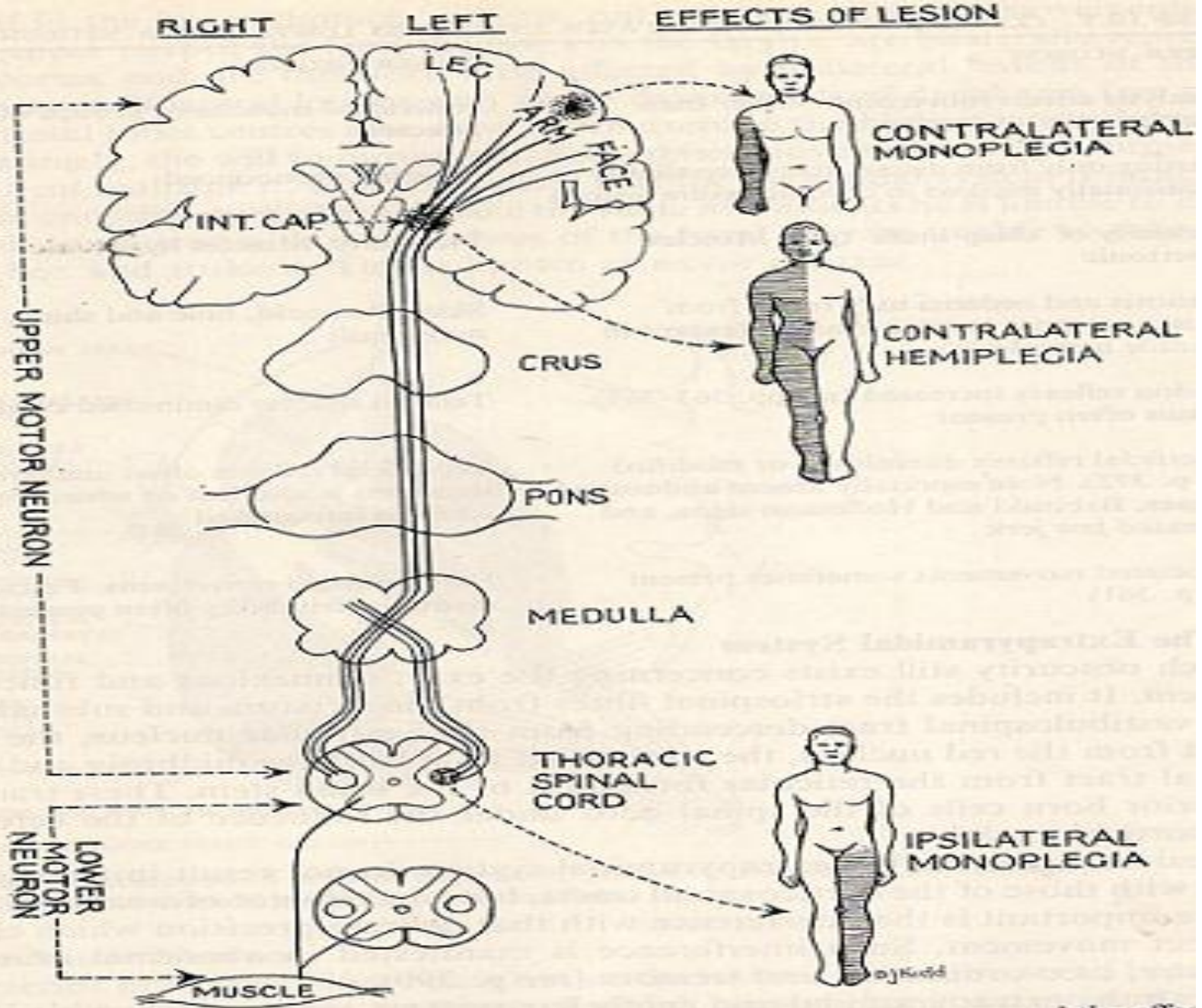
Lesions of pyramidal tract cause paralysis of the UMN type below the level of the lesion. However, the side affected and the extent of paralysis vary according to the site of the lesion:

1- In area 4: this leads to restricted paralysis in the opposite side e.g. monoplegia (paralysis of one limb because area 4 is widespread so it is rarely damaged completely).

2- In the corona radiata: this leads to contralateral monoplegia or hemiplegia, depending on the extent of the lesion.

3- In the internal capsule: this often leads to contralateral hemiplegia because almost all fibers are injured.

4- In the brain stem: this leads to contralateral hemiplegia + ipsilateral paralysis of the cranial nerves of the LMNL type (due to damage of their nuclei in the brain stem). This condition is called crossed hemiplegia, and the nerves affected differ as follows:



The effect of a lesion in different parts of the motor system

- * If the lesion was in the midbrain, the 3rd & 4th are affected.
- * If the lesion was in the pons, the 5th, 6th, 7th, and 8th cranial nerves are affected.
- * If the lesion was in the medulla, the 9th, 10th, 11th & 12th cranial nerves are affected.
- * Bilateral lesion in the brain stem is rare and leads to quadriplegia and bilateral paralysis of the cranial nerves.

5- In the spinal cord:

Bilateral lesions:

- In the upper cervical region, are fatal due to interruption of the respiratory pathway.
- In the lower cervical region, they lead to quadriplegia.
- In the midthoracic region lead to paraplegia.

Unilateral lesions:

- In the cervical region, they lead to ipsilateral hemiplegia,
- While in the midthoracic lesion they lead to ipsilateral monoplegia in the corresponding lower limb.
- In both conditions, there is ipsilateral paralysis (LMNL) of the muscles at the level of the lesion due to damage of the spinal motor neurons.

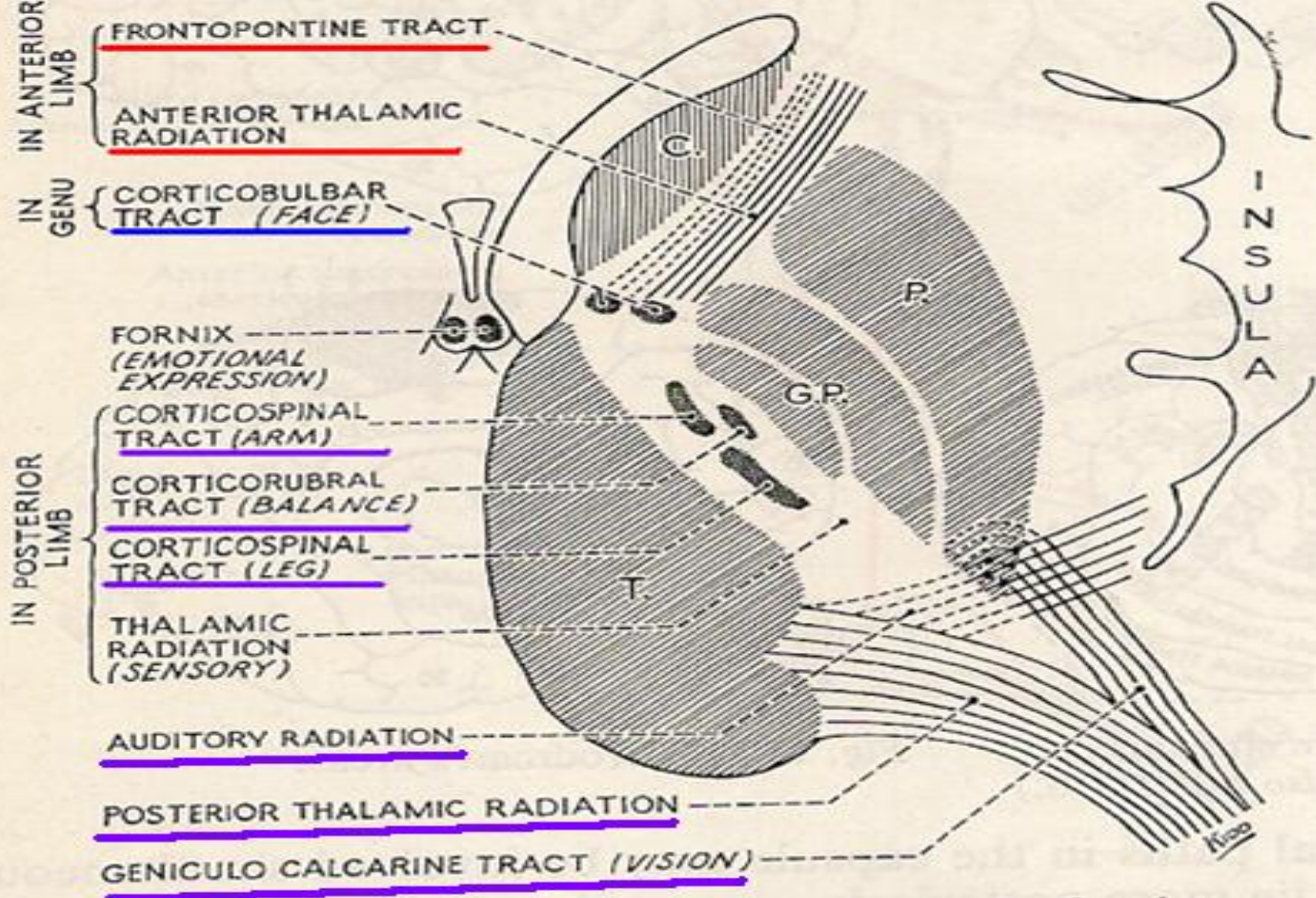
The internal capsule

- The internal capsule is the only subcortical pathway through which nerve fibers ascend to and descend from the cerebral cortex. It is V-shaped, consisting of anterior & posterior limb and a genu (knee). It is surrounded by the putamen and globus pallidus laterally and the caudate nucleus and thalamus medially.

The internal capsule

- The anterior limb:
Contains descending fibers from the cerebral cortex to red nucleus, pons to cerebellum, thalamus, 3, 4, and 6 cranial nerves.
- The genu
Contains corticobulbar tract.

- The posterior limb contains:
- The descending pyramidal & extrapyramidal fibers in the anterior 2/3.
- The somatosensory radiation that ascends behind the pyramidal fibers from thalamic nuclei to cortical sensory areas.
- The optic radiation that ascends behind the somatosensory radiation from the lateral geniculate body to visual areas in the occipital lobe.
- The auditory radiation that ascend most posteriorly from the medial geniculate body to auditory areas in the temporal lobe.



The internal capsule

Effects of a unilateral lesion in the posterior limb of internal capsule

- Such lesion commonly called cerebral stroke is usually caused by thrombosis or hemorrhage of lenticulo-striate artery (a branch of the middle cerebral artery).
 - * Patients pass into an acute then chronic stage.

Acute stage:

- This lasts a few days up to 2-3 weeks. It is a stage of acute UMNL, showing the following manifestations in the opposite side:
- Flaccid paralysis including the upper and lower limbs, the lower parts of the face and half of the tongue.
- Hemianaesthesia (loss of all sensations).
- Hypotonia and areflexia.
- Loss of the superficial reflexes.
- May be +ve Babinski's sign.

- N.B: The manifestations of this stage are similar to those of LMNL. However, they can be differentiated from the LMNL by the following:
 - a. The extent of paralysis is much more widespread than in LMNL.
 - b. There is associated hemianaesthesia.
 - c. There may be +ve Babinski's sign
 - d. Absence of muscle atrophy.

Chronic (permanent or spastic) stage:

The main manifestations of this stage include the following:

- Contralateral hemiplegia of the UMNL type, which is characterized by hypertonia, muscle spasticity of clasp knife type, exaggerated tendon jerks and clonus, loss of superficial reflexes, apparent +ve Babinski's sign.

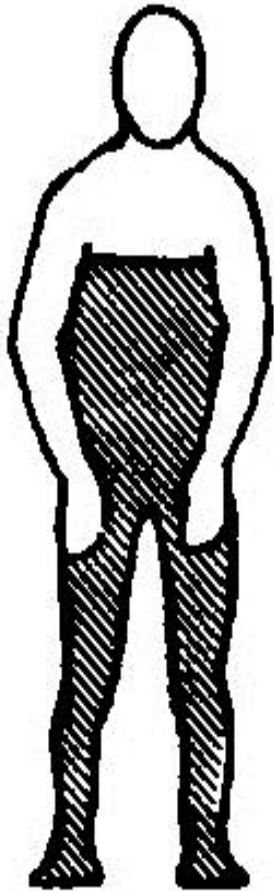
N.B: Partial recovery occurs after a variable period by the effect of the ipsilateral corticospinal tract, the extrapyramidal tracts as the corticorubral spinal pathway, so, the patient can stand and even walk, but the fine skilled movements of the fingers and hands are permanently lost.

- Permanent loss of fine sensations in the opposite side, but the crude sensations recover gradually.


- Contralateral homonymous hemianopia (loss of vision in the opposite halves of the 2 visual fields due to interruption of signals from the temporal part of ipsilateral retina and nasal part of contralateral retina).
- Diminished hearing power in both areas (by about 50 %), because of damage of auditory radiation.

Complete spinal cord transaction

- This results usually from accidents. Immediate and ever-lasting loss of sensations and voluntary movements occur due to cut of all sensory and all motor tracts below the transaction.
- * Transection in the upper cervical regions (above the 3rd cervical segment) results in immediate death due to respiratory arrest as in hanging. However, at lower levels, patients pass 3 stages: spinal shock, recovery of spinal reflex activity, then its failure and death.



{ Bilateral loss of all modalities.
Bilateral leg weakness. }



**COMPLETE CORD
LESION**

The following stages follow cord transaction:

I- Stage of spinal shock (weeks to months in man)

All cord functions are depressed.

The manifestation shown are

- Paralysis of all muscles below the lesion (quadriplegia or paraplegia) due to cut of UMN.
- Complete loss of all sensation below the level of transection.

- Loss of cord reflexes as the stretch reflex, hence the paralysed muscles are flaccid and the deep reflexes are absent. The other reflexes are also absent such as the withdrawal flexor reflex.
- ABP drops markedly if the transaction is at the level of the first thoracic segment, but slight drop occurs if the lesion is below the second lumbar segment. This drop of ABP as well as the vascular VD are due to sympathetic activity block. However, the pressure returns to normal within a few days.

- Loss of control of micturition and defecation reflexes because facilitatory pathways from the higher centers, responsible for bladder and rectum evacuation are interrupted by the transaction leading to retention with overflow with dribbling of urine by a full bladder. This returns back after the first few weeks.
- Loss of erection.

Cause of spinal shock

It is due to sudden withdrawal of supraspinal facilitation on the spinal alpha motor neurons, namely; the continual tonic discharge transmitted along the excitatory reticulospinal, vestibulospinal and corticospinal tracts.

Duration of the spinal shock

The duration of spinal shock differs in different animals according to the degree of development of the cerebral cortex. It is only a few minutes in rats. In humans the duration lasts 2-6 weeks.

Complications of spinal shock

- 1- Hypotension specially in high-level spinal cord lesion.
- 2- Increased protein catabolism due to lack of movement causing muscle wasting and bone dissolution.
- 3- Ischemia of the areas compressed against bed (upper back, gluteal region and heels) (decubitus ulcers or bed sores) which heal poorly due to protein depletion.
- 4- Urinary tract infection due to urine stasis.
- 5- Fall of body temp. due to reduction of the metabolic rate after loss of muscle tone.

Management of spinal shock

This aim at rapid recovery of spinal reflex activity which can be achieved by the following:

- 1- Giving antibiotics to prevent infection.
- 2- Giving stimulants to the spinal centers.
- 3- Bladder catheterization to prevent urine stasis and rectal enema to evacuate the rectum.
- 4- Prevention of bed sores by cleaning the skin with antiseptics and frequent changing the patient's position in bed.
- 5- Adequate nutrition.

II- Stage of recovery of reflex activity:

- After spinal shock, the spinal centers below the level of the lesion recover gradually but paralysis and loss of sensations are permanent because the tracts in the spinal cord cannot regenerate due to lack of neurolemma. Spinal recovery occurs as follows:
- The flexor withdrawal reflex and Babinski's sign are usually the first responses to appear followed by the extensor reflexes as the knee jerk.

- The static stretch reflex (muscle tone) recovers resulting in spastic paralysis. It appears first in flexor muscles causing paraplegia in flexion. Then a few months later, the extensor muscle tone predominates resulting in paraplegia in extension.
- The body temperature rises towards normal level as a result of recovery of muscle tone.

- The spinal sympathetic VC centers in the lateral horns below the level of the transaction regain their activity and send their impulses to the arterioles and veins, which regain tone. Hence, the ABP rises and the limbs become warm and with a healthy skin with good color helping healing up of the ulcers.
- Micturition and defecation become automatic as in children with residual urine due to weakness of the reflex.
- Erection can occur by direct stimulation and ejaculation follows.

- Touch of the patient with a relatively noxious stimulus applied to the skin produces a flexor withdrawal reflex and impulses may radiate to autonomic centers which lead to provocation of a mass reflex i.e. sweating, pallor, swinging blood pressure, micturition, defecation in addition to wide spreading flexor activity as flexor spasm of both lower extremities and contraction of the anterior abdominal wall.
- N.B: patients can be trained to induce urination or defecation through producing intentional mass reflex by striking the thigh's skin.

Reappearance of spinal reflexes may be due to:

- Release of spinal centers from the normal inhibitory control of the higher centers.
- Denervation hypersensitivity, the spinal neurons become hypersensitive to the transmitters released by any remaining spinal excitatory nerves.
- Growth of new collaterals from preexisting neurons with formation of additional excitatory endings on spinal neurons.

III- Stage of failure of reflex activity:

- This is a terminal (premortal) stage that results from bad management during the recovery stage. Urinary tract infections and bed sores infection result in failure of reflex activity and the patient dies from renal failure.
- The spinal centers below the level of the lesion are depressed once more leading to:
- 1- Loss of the muscle tone and tendon jerks, then mass reflex, withdrawal reflex and Babinski's sign. The muscles become flaccid and body temperature falls.

2- Loss of the defecation and micturition reflexes resulting in constipation and urine retention with overflow.

3- Hypotension due to depression of the spinal VC centers.

The third stage does not nowadays occur because of perfect nursing and the administration of antibiotics; both lines of treatment guard against bed sores and renal infections.

Hemisecion of spinal cord

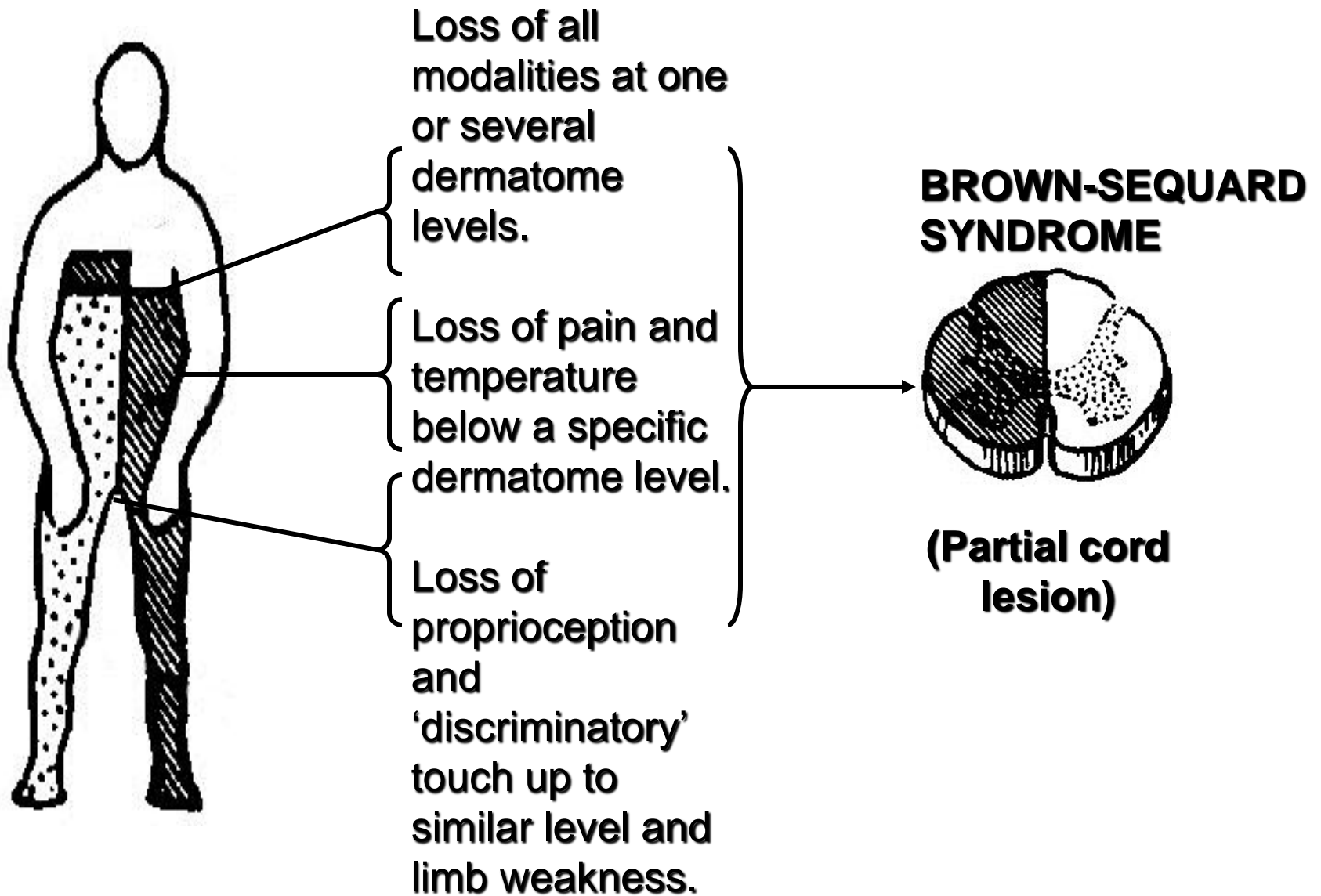
(Brown Sequard syndrome)

- This is unilateral transverse lesion in SC that interrupts the continuity of both ascending & descending tracts at only one half e.g. due to tumor or trauma.

Manifestations

Above the level of lesion

- Cutaneous hyperaesthesia i.e. increased sensibility to pain, touch & temp. occurs in ipsilateral dermatome due to irritation of the dorsal nerve roots by the neighboring lesion.



At the level of lesion and at the same side

- Loss of all sensations in area innervated by afferent nerves that enter damaged segments.
- Paralysis of muscles supplied by efferent nerves that arise from damaged segments (LMNL).
- Loss of all reflexes (both superficial and deep) mediated by damaged segments.

Below the level of lesion

On the same side

- Paralysis of voluntary muscles (UMNL).
- Dorsal column sensations are lost.
- Touch is impaired (but not lost) because the dorsal column is transected. Yet, crude touch sensation still persists because of its transmission by the opposite intact ventral spinothalamic tract.

On the opposite side

Loss of pain & temperature sensations due to cut of lateral spinothalamic tract coming from intact side.



شكراً لله