



بِسْمِ اللَّهِ الرَّحْمَنِ الرَّحِيمِ

السلام عليكم ورحمة الله وبركاته



Gastrointestinal Physiology *(Lecture 7)*

Physiology of The Colon: Motility



Dr. Hayam Gad



Learning Objectives

- * Parts of the Colon
- * Functions of the Colon
- * The physiology of Different Colon Regions
- * Secretion in the Colon
- * Absorption in the Colon
- * Bacterial Action in the Colon
- * Motility in the Colon
- * Defecation Reflex



Parts of the Colon

Cecum

- Saclike first part of the large intestine

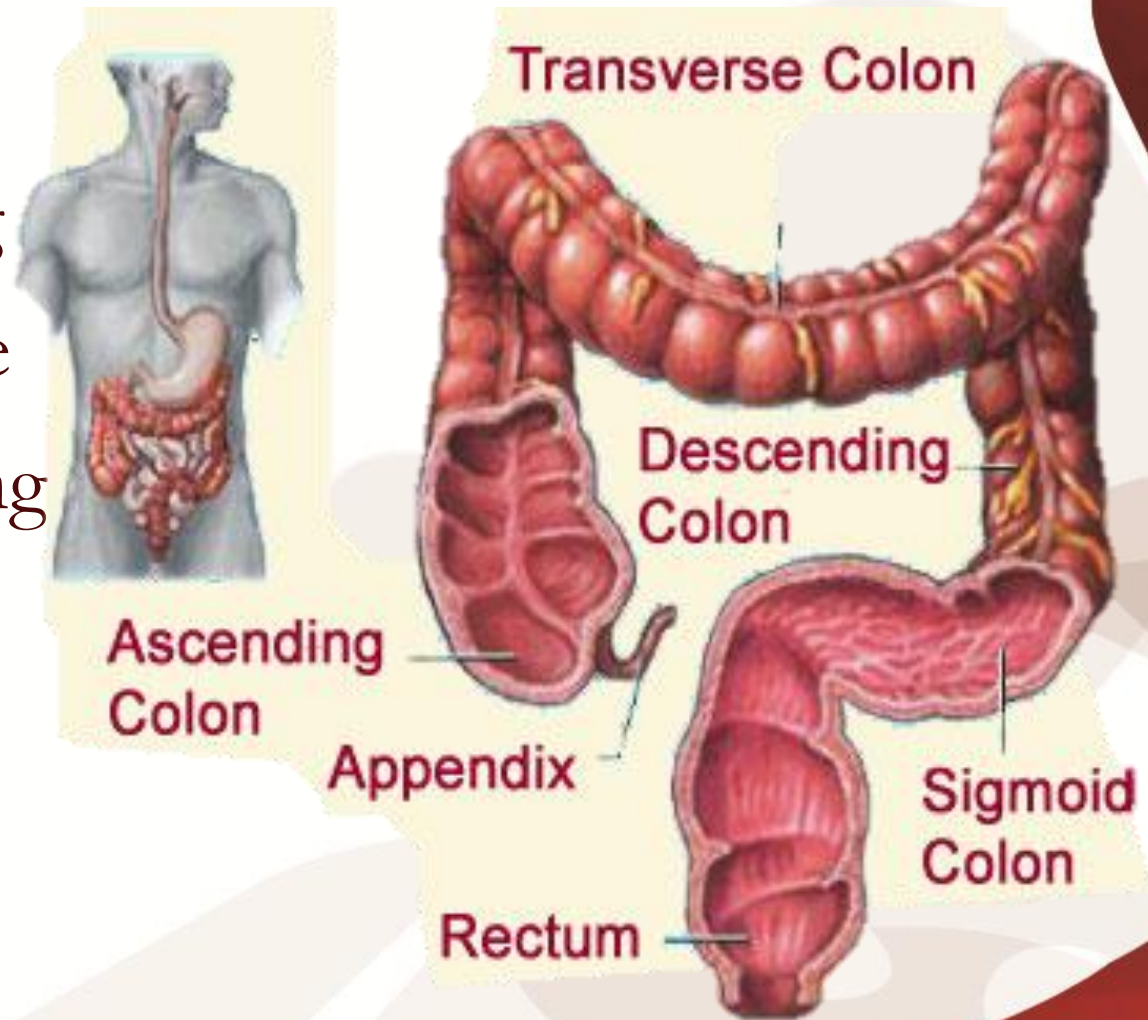
Appendix

- Accumulation of lymphatic tissue that sometimes becomes inflamed (appendicitis)
- Hangs from the cecum



Colon

- Ascending
- Transverse
- Descending
- S-shaped sigmoidal

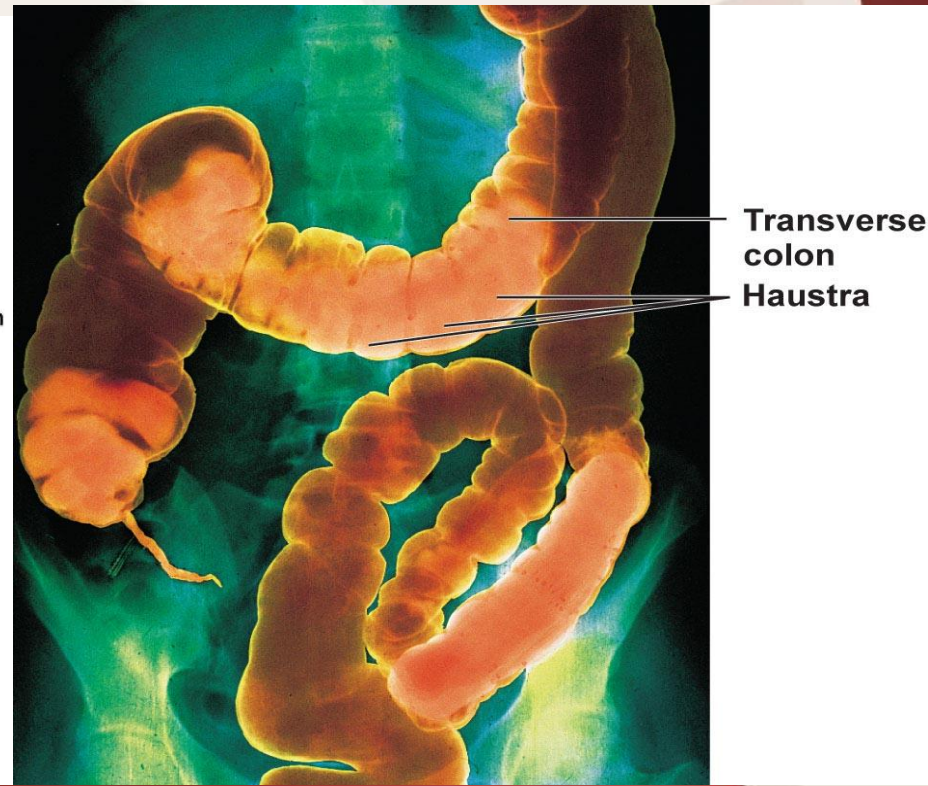
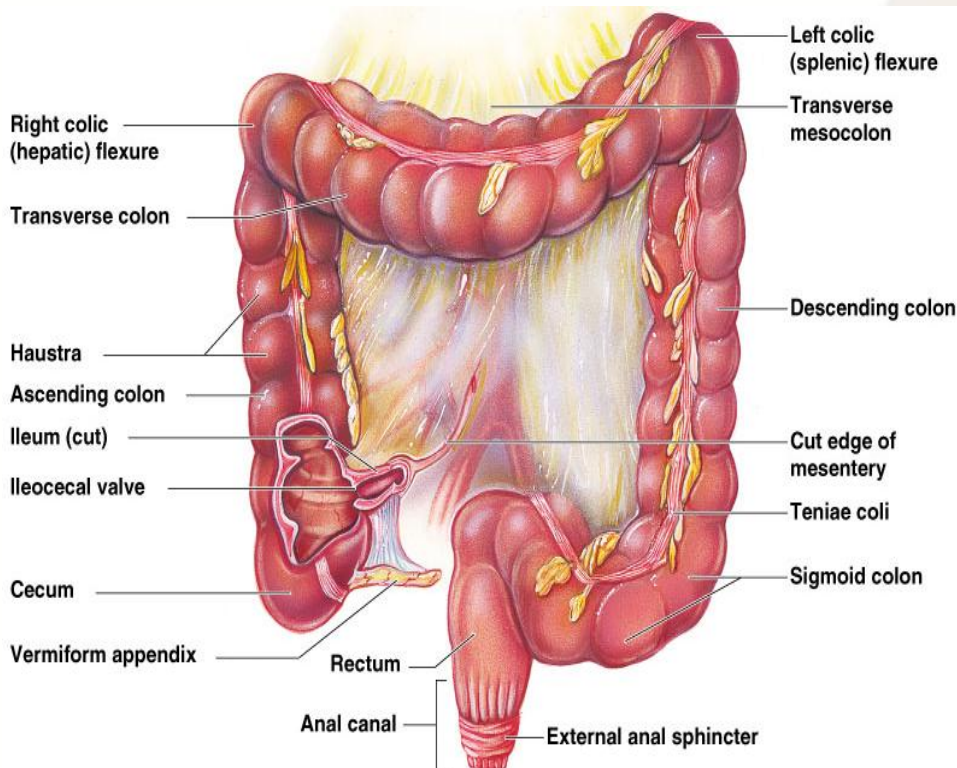


Rectum

Anus

The colon

- The outer longitudinal layer is modified to form three longitudinal bands called **tenia coli** visible on the outer surface.
- Since the muscle bands are shorter than the length of the colon, the colonic wall is sacculated and forms **haustra**.



- ❁ The mucous membrane of the colon lacks villi and has many crypts of Lieberkühn.
- ❁ They consist of simple short glands lined by mucous-secreting goblet cells.
- ❁ The epithelial cells contain almost no enzymes.
- ❁ The colon has a length of 150 cm.
- ❁ The transit of small labeled markers through the large intestine occurs in 36-48 hrs.



Functions of the Large Intestine

- ✓ Absorb vitamins produced by bacteria
- ✓ Reabsorb water and compact material into feces
- ✓ Store fecal matter prior to defecation

THE PHYSIOLOGY OF DIFFERENT COLON REGIONS

1. The ascending colon:

Specialized for processing chyme delivered from the terminal ileum.

2. The transverse colon:

Specialized for the storage and removal of water & electrolytes from feces.

3. The descending colon:

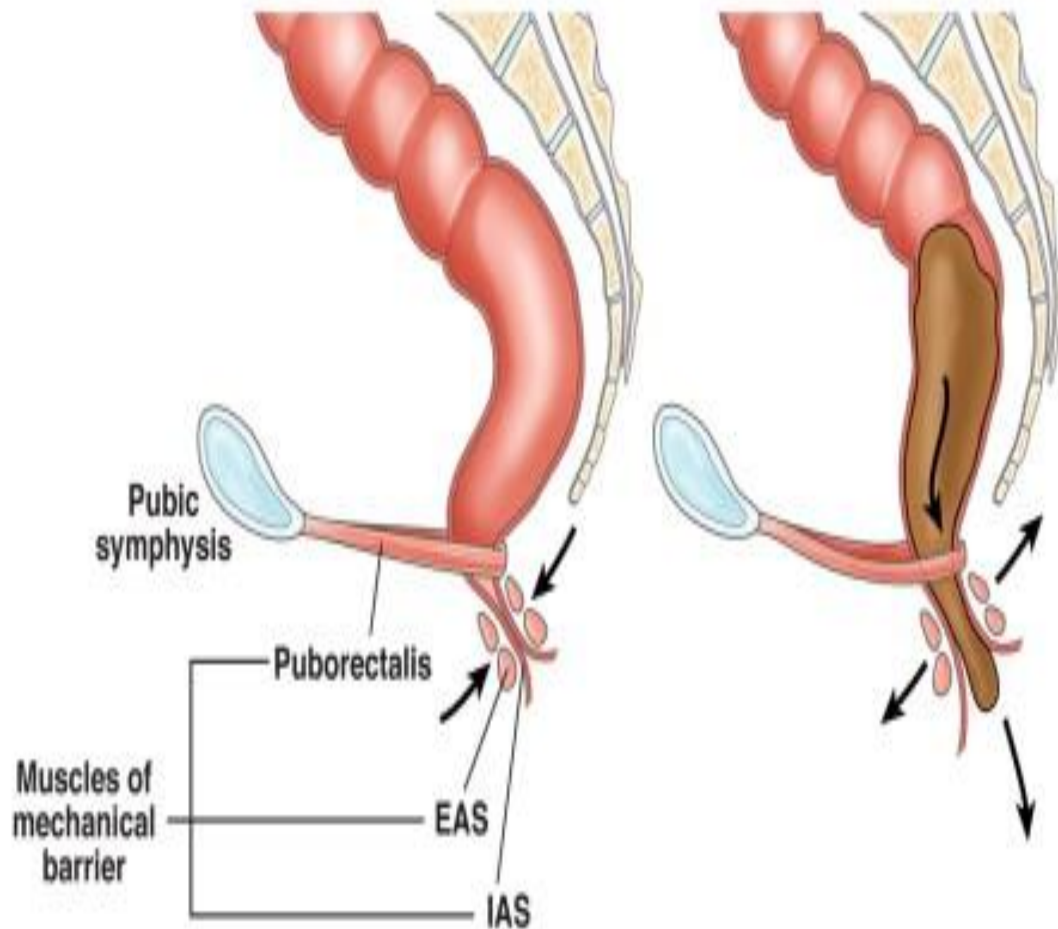
A conduit between the transverse and sigmoid colon. This region has the neural program for power propulsion that is involved in **defecation reflex**.

4-The rectosigmoid region, anal canal, together with pelvic floor musculature maintains fecal continence.

- The sigmoid and rectum are reservoirs with a capacity of up to 500 mL.
- The puborectalis muscle and external anal sphincter comprise a functional unit that maintain continence.
- Fibers of puborectalis join behind the anorectum and pass around it to form a U-shaped sling (physiological valve).

Normal defecation

Resting



- Sensory perception of stool
- Rectal distension
- Contract diaphragm, abdomen, and rectal muscles
- Relax EAS (decreased sphincter pressure)
- Relax puborectalis muscle

Secretion in the Colon

It is mainly mucus, no digestive enzymes.

The mucus has the following *functions*:

- 1- It neutralizes against any acids present.
- 2- It protects against irritation.
- 3- It helps to lubricate feces.
- 4- It provides a binding medium for fecal matter.

☆ Stimulation of the **pelvic nerves** from the spinal cord can cause marked increase in mucus secretion. This occurs along with increase in peristaltic motility of the colon.

☆ During extreme parasympathetic stimulation, so much mucus can be secreted into the large intestine that the person has a bowel movement of ropy mucus as often as every 30 minutes; this mucus often contains little or no fecal material.

Secretion of water & electrolytes

- ◆ Whenever a segment of large intestine becomes irritated as occurs in bacterial infection, the mucosa secretes large amount of water & electrolytes in addition to the alkaline mucus.
- ◆ This dilute the irritating factors and causes rapid movement of the feces toward the anus.

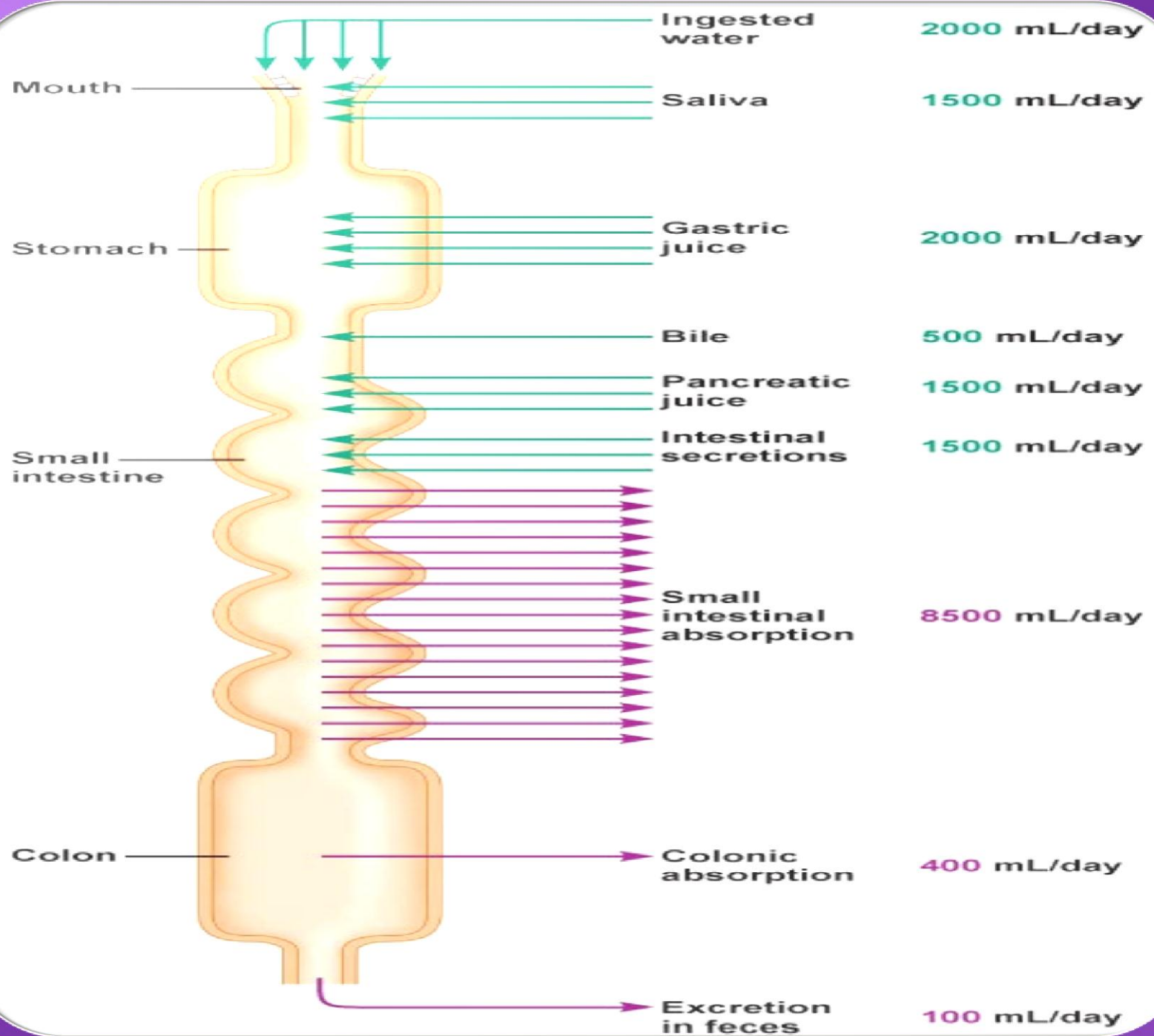


Absorption in the Colon

Most of absorption in the colon occurs in the proximal half of the colon (absorptive colon). Whereas the distal colon function for storage (storage colon).

- ❶ Water absorption, about 0.5- 1.5L/day is absorbed. The net water loss is 150-200 ml/day.

N.B: The large intestine can absorb a maximum of 5 to 8 liters of fluid and electrolytes each day.



- ② Na^+ is actively absorbed (in the presence of Na^+-K^+ ATPase) at the basolateral membrane to blood.
- ③ K^+ is secreted into the lumen of colon.
- ④ Cl^- is absorbed in exchange for HCO_3^- which is secreted.
- ⑤ Vitamins as Vit. K, biotin, B5, folic acid and some AA and short chain FA resulting from bacterial fermentation of CHO are absorbed.
- ⑥ Certain drugs as steroids and aspirin may be absorbed.
- ⑦ Bile salts and organic wastes as urobilinogens and sterobilinogens can be absorbed.



Bacterial Action in the Colon

This bacterial flora is living in symbiosis with human and its effects are beneficial to the body as follows:

① Synthesis of vitamin K and some B group vitamins as folic acid, biotin, thiamine and B₁₂.

The bacteria-formed vitamin K is especially important because the amount of this vitamin in the daily ingested foods is normally insufficient to maintain adequate blood coagulation.

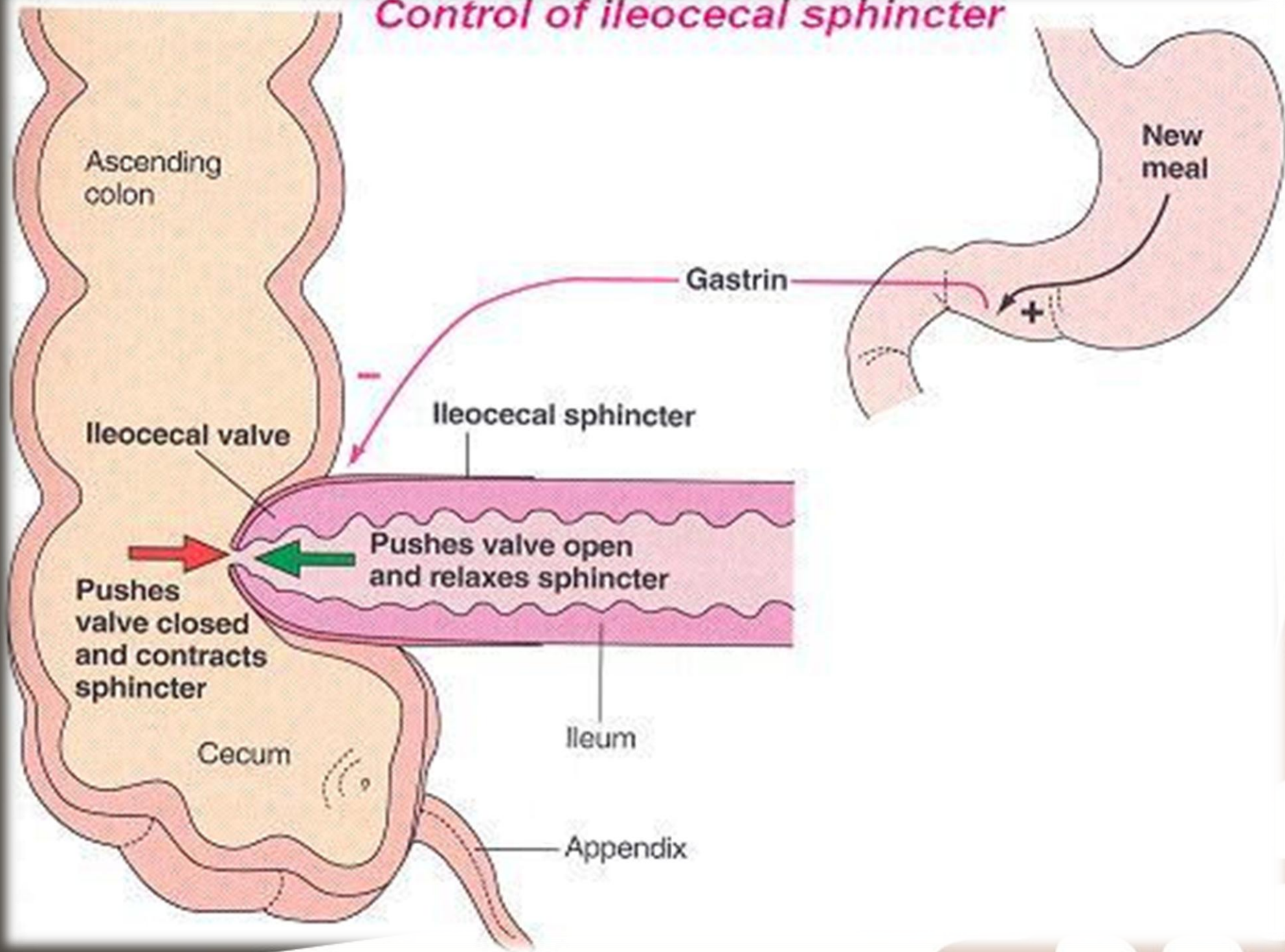
② Deconjugation and decarboxylation of Bile salts.

- ③ Break down of bile pigments to produce stercobilinogen.
- ④ Decarboxylation of some AA to produce amine and histamine. The amines are excreted in feces and are responsible for its smell.
- ⑤ Break down of urea by bacterial urease to ammonia. Most ammonia is absorbed and reconverted into urea by liver. In hepatic failure, accumulation of ammonia can cause hepatic encephalopathy.
- ⑥ Fermentation of undigested CHO.

The ileocaecal valve

- ☆ It prevents backflow of contents from colon into small intestine.
- ☆ It remains closed and open only when an intestinal peristaltic wave reaches it.
- ☆ Distension of the cecum, Secretin, Ach, alpha adrenergic stimulation **contract** ileocaecal valve.
- ☆ Gastrin, CCK, B adrenergic stimulation **relax** ileocaecal valve.

Control of ileocecal sphincter





Motility in the Colon

1- Mixing Movement (Haustrations)

- ⇒ The motor events in the cecum and ascending colon
- ⇒ Large circular constrictions occur. At each of these constrictions points, 2.5 cm of the circular muscle contracts, at the same time the longitudinal strips contract.
- ⇒ These combined contractions cause the unstimulated portion of large intestine to bulge outward into baglike sacs called **haustrations**.

- ➡ They also at times move slowly analward during their period of contraction.
- ➡ After another few minute new haustral contractions occur in other areas nearby.
- ➡ In this way all fecal material is gradually exposed to the surface of the large intestine & fluid is progressively absorbed.

2- Propulsive (mass) Movement

- ⊙ This is the motor events in the transverse and descending colon
- ⊙ These movements usually occur only few times each day, most abundantly for 15 min during the first hour after eating breakfast.
- ⊙ A mass movement is a modified type of peristalsis characterized by a constrictive ring occurs at a distended or irritated point in the colon. Then rapidly the 20 or more cm of the colon distal to the constriction contract almost as a unit forcing the fecal material en mass down the colon.

- © It starts at the middle of the transverse colon and is preceded by relaxation of the circular muscle and the downstream disappearance of haustral contractions
- © The initiation of contraction is complete in about 30 seconds. During the next 2 to 3 minutes another mass movement occurs.
- © The whole series of mass movements will usually persist for only 10 minutes to half an hour. They will then return after a half day or even a day later.

© When they have forced a mass of feces into the rectum the desire for defecation is felt.

➤ **Initiation of Mass Movement:**

- ♣ Gastrocolic & duodenocolic reflexes after meals. They result from distension of the stomach & duodenum.
- ♣ Irritation of the colon e.g., castor oil.
- ♣ Intense stimulation of parasympathetic NS.
- ♣ Over distension of a segment of the colon.

3- Antiperistalsis

- ✓ It starts at the junction of ascending and transverse colon and traveling towards the cecum.
- ✓ It mixes contents and help water absorption.



Control of Colonic Motility

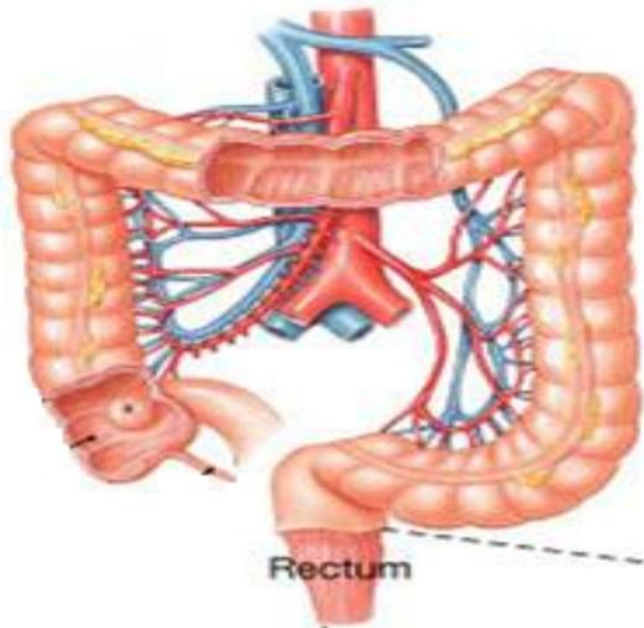
The intramural plexuses directly control the contractile behavior of the colon.

- ✿ **Stimulatory** enteric motor neurons use **acetylcholine & substance P** as neurotransmitters.
- ✿ **Inhibitory** enteric motor neurons release **VIP & NO** onto colonic smooth muscle cells.
- ✿ The extrinsic autonomic nerves to the colon **modulate** the control of the colonic motility by the enteric nervous system.

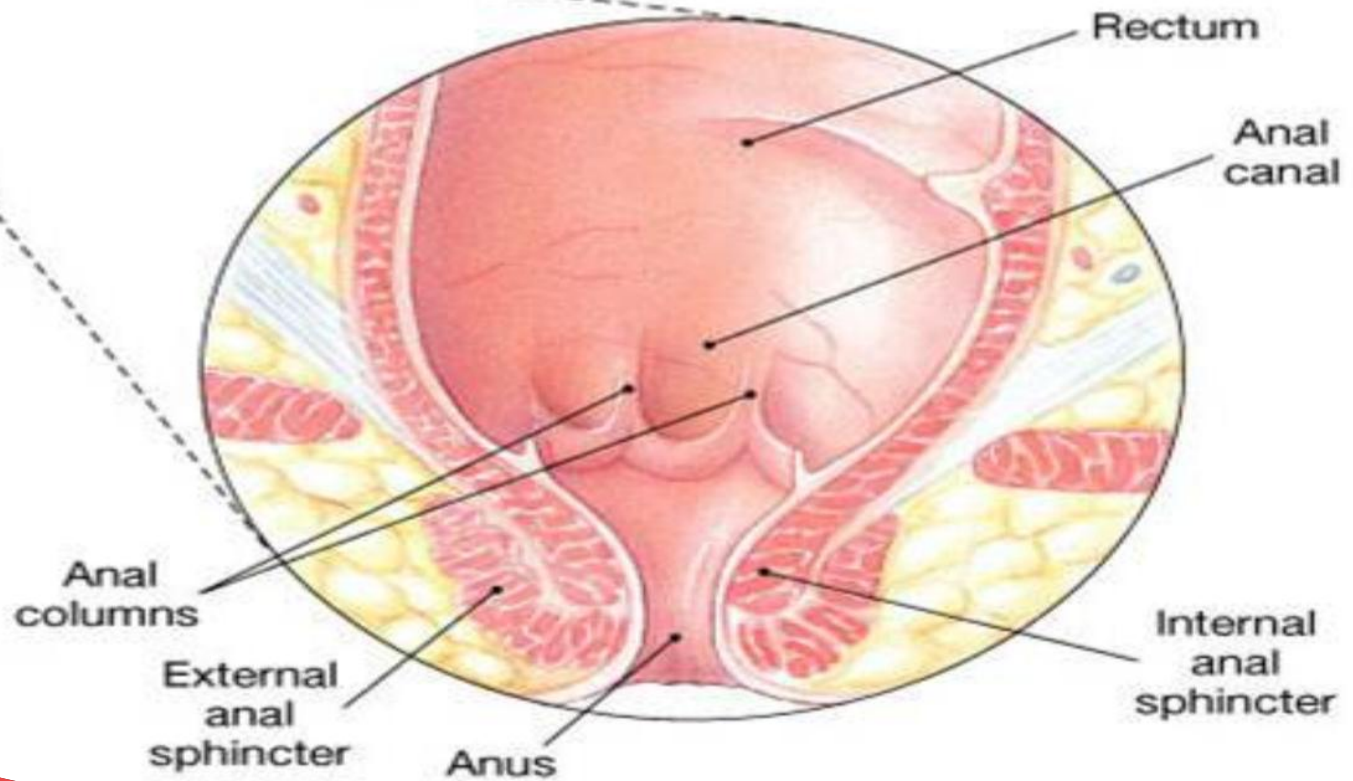


The Rectum

- ❧ Last portion of the digestive tract that terminates at the anal canal.
- ❧ Mechanoreceptors in the rectum detect distention and supply the ENS.
- ❧ The anal canal in the region of the skin is innervated by somatosensory nerves that transmit signals to CNS.
- ❧ Contraction of anal sphincters and puborectalis muscle blocks the passage of feces and maintains continence.



Rectum



Rectum

Anal canal

Anal columns

External anal sphincter

Anus

Internal anal sphincter

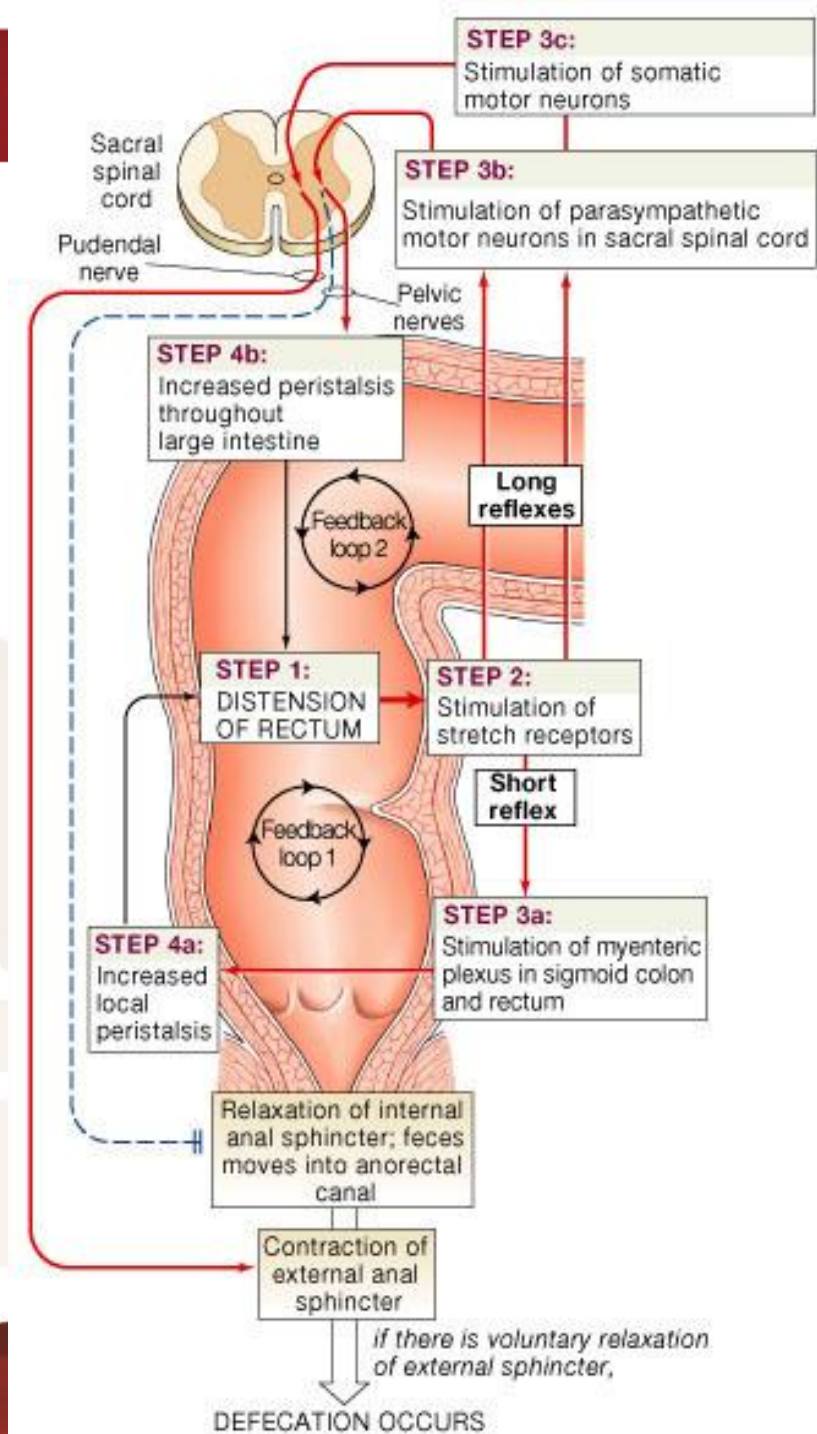


Defecation

- ◆ It is a spinal reflex which is influenced by higher center.
- ◆ Most of the time the rectum is empty and both internal and external sphincters are reflexly maintained in a state of tonic contraction.
- ◆ Gastric or intestinal filling initiate a mass movement in the colon that pushes feces into rectum (gastrocolic & dudenocolic reflexes).
- ◆ The rectum is distended and sends signals to cerebral cortex producing the desire to defecate.

Defecation Reflex

1. Distension of the rectum.
2. Stimulation of the stretch receptors in the rectum.
3. a) Short reflex: Stimulation of myenteric plexus in sigmoid colon and rectum.
b) long reflex: stimulation of parasympathetic motor neurons in sacral spinal cord.
c) Stimulation of somatic motor neurons.
4. Increased local peristalsis. Relaxation of internal anal sphincter and contraction of external anal sphincter.



If the surrounding circumstances are suitable

∞ Defecation reflex will be allowed. Stretch of the rectal wall is signaled to SC by pelvic nerve. Efferent pelvic impulses cause reflex contraction of the rectum and relaxation of IAS.

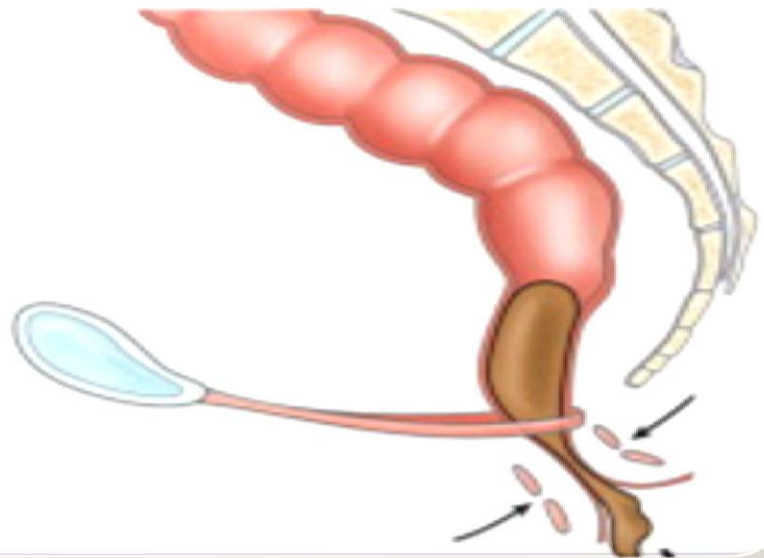
∞ This is followed by reduction in tonic impulses to EAS, so it relaxes and feces leave the rectum assisted by voluntary straining and contraction of pelvic floor muscle.

If situation is not suitable for defecation

- ☞ The reflex is inhibited by the cerebral cortex. Tonic contraction of EAS is voluntary maintained which leads to accommodation of the rectum to distension and return of tonic contraction of the IAS.
- ☞ In infants (and in spinal cord lesion) the spinal reflex of defecation operates without interference from higher centers (**fecal incontinence**).

Incontinence

- Low resting and/or low squeeze sphincter pressures (weak IAS and EAS)
- Weakness of puborectalis
- Neuropathy
- Altered rectal or anal sensation
- Diarrheal conditions
- Diminished rectal capacity





Thank You

The text "Thank You" is rendered in a large, elegant, cursive script. The letters are filled with a deep red color and have a thin, metallic gold outline. The text is surrounded by a lush arrangement of red roses with green leaves and small white flowers. Two white doves are depicted in flight, one positioned above the letter 'h' and the other above the letter 'y'. The entire composition is set against a white background with soft shadows beneath the text and flowers.