



HISTOLOGY

Endocrine Block – 432 Histology Team

Practical

Done by:

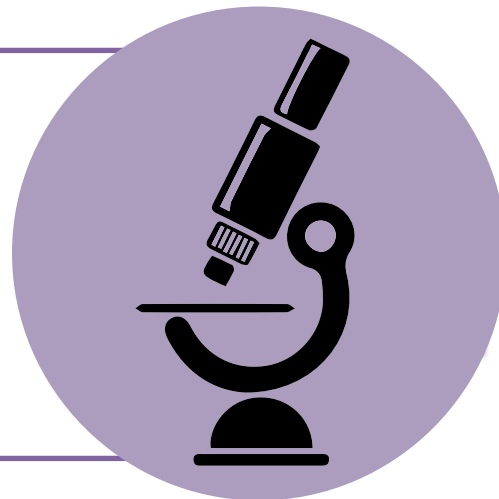Saleh Almansour

Faisal Alshuwair

Reviewed by:

Moudi AlDegether

Nada Alouda



1- Thyroid Gland

2- Parathyroid
Gland

3- Adrenal Gland

Thyroid Gland

Low Magnification

Q: Identify.

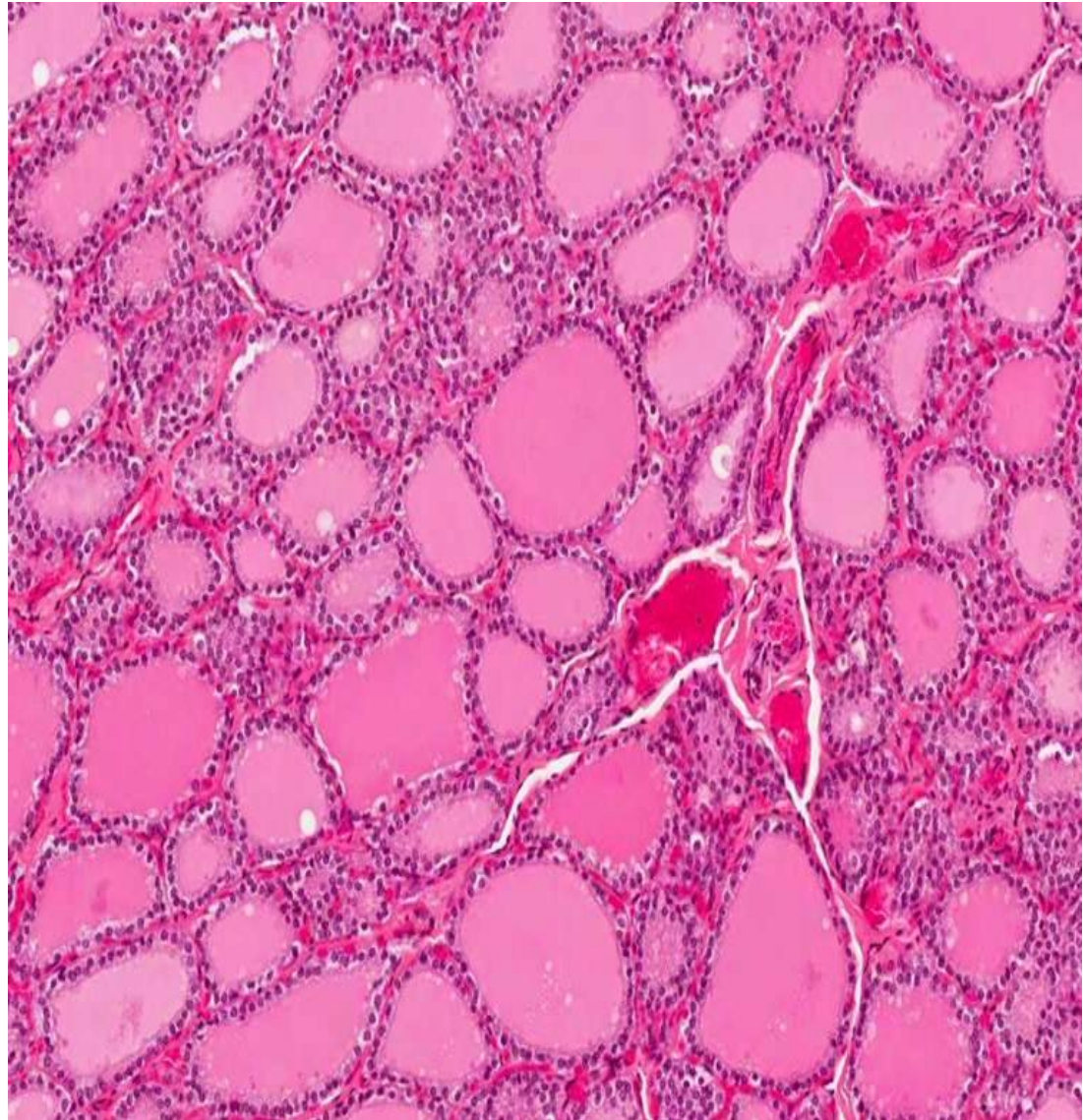
Thyroid gland.

Q: Identify features.

- 1- Thyroid follicle.
- 2- Simple cuboidal epithelium (lining epithelium):
 - Follicular cells.
 - Parafollicular cells.
- 3- Acidophilic colloid.

Extra note:

C.T is rich in fenestrated blood Capillaries.



Thyroid Gland

High Magnification

Q: Identify.

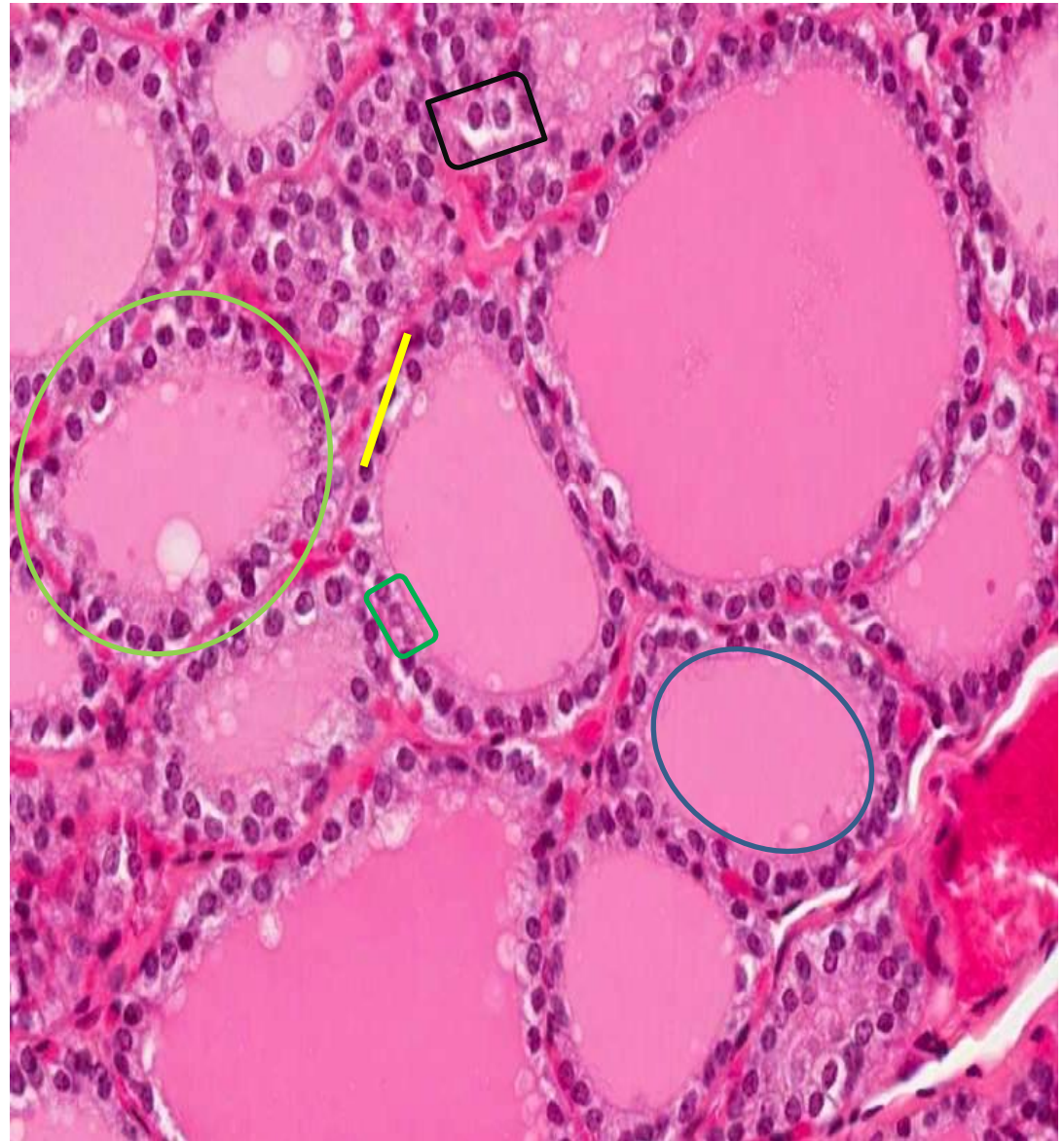Thyroid gland.

Q: Identify features.

- 1- Thyroid follicle. ○
- 2- Simple cuboidal epithelium (lining epithelium):
 - Follicular cells. □
 - Parafollicular cells. □
- 3- Acidophilic colloid. ○

Note:

The parafollicular cells are also called clear cells due to their clear cytoplasm and they're larger than follicular cells.



Parathyroid Gland

Low Magnification

Q: Identify.

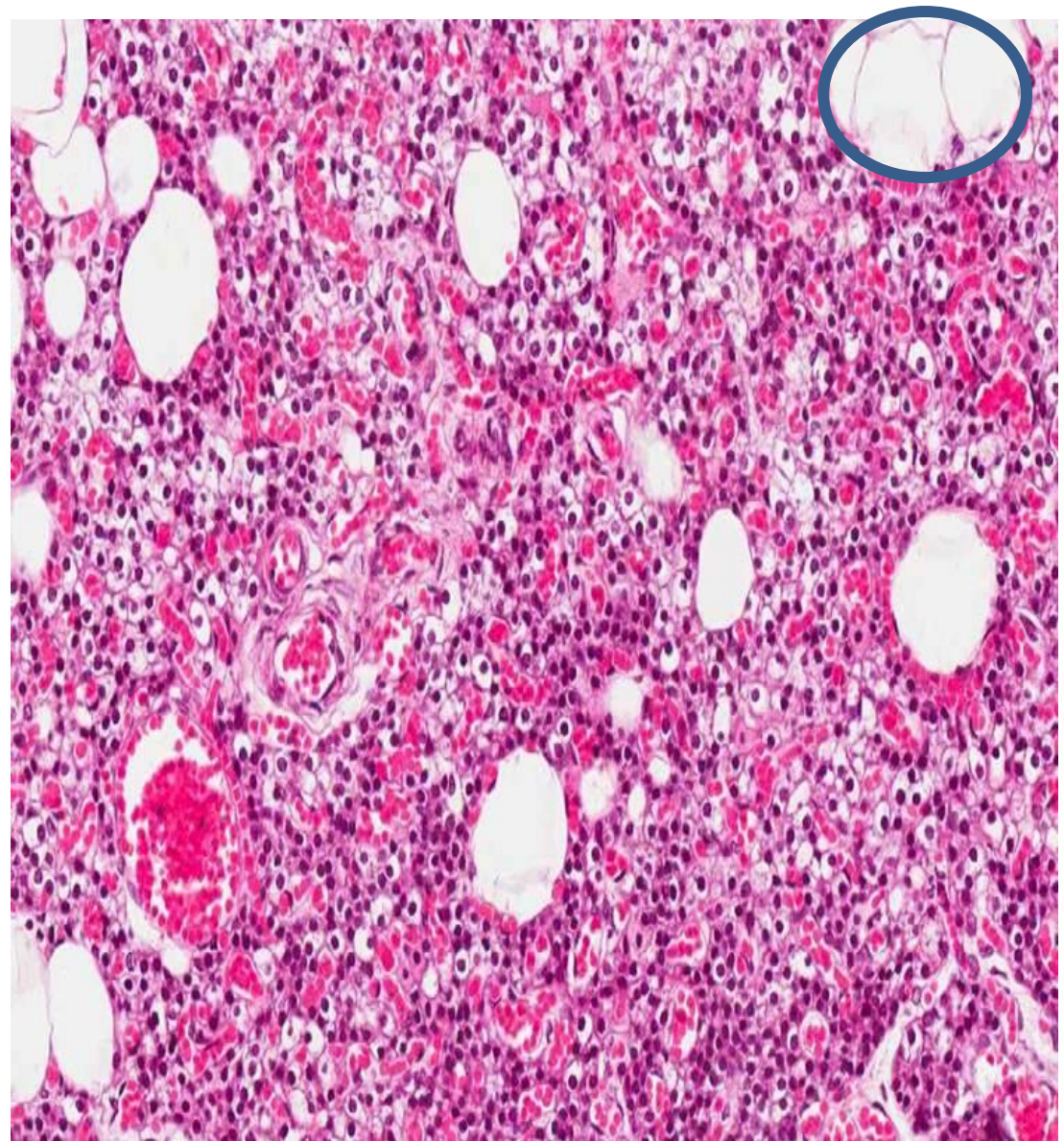
Parathyroid gland.

Q: Identify features.

1- Cells:

- Chief cells.
- Oxyphil cells.

2- Fat cells. ○



Parathyroid Gland

High Magnification



Q: Identify.

Parathyroid gland.

Q: Identify features.

1- Fenestrated blood capillaries. 

2- Cells:

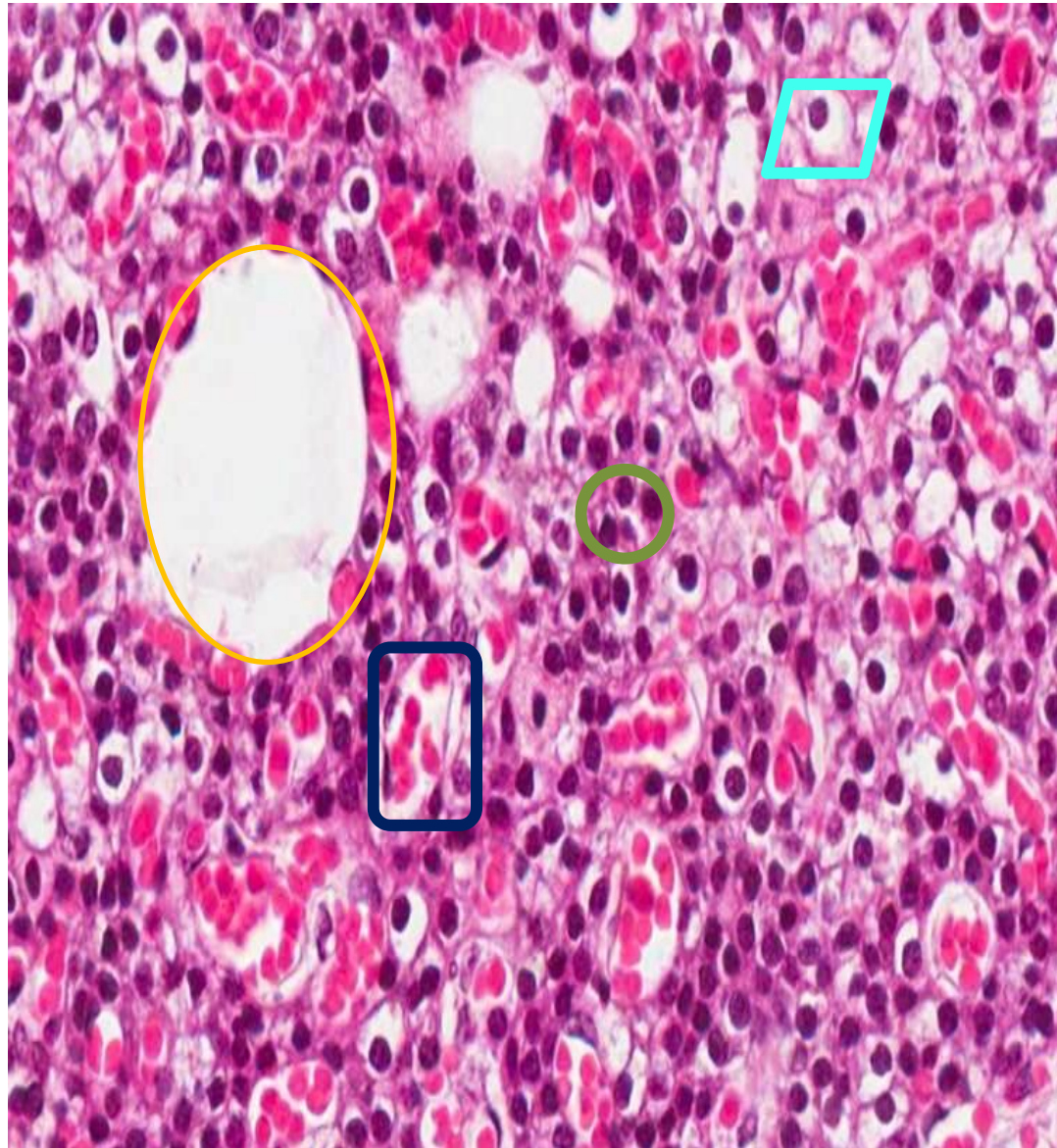
- Chief cells. 
- Oxyphil cells. 

Note that: to differentiate between chief & oxyphil cells, chief cell looks like Parafollicular cell (clear cytoplasm) while oxyphil cell has deep acidophilic cytoplasm.

- Most of the cells are chief cells.
- Oxyphil cells are larger than chief cells "Acidophilic cytoplasm".

Extra information:

Blood vessel. 



Adrenal Gland

Low Magnification

Q: Identify.

Adrenal gland.

Q: Identify features.

A. Cortex:

1- Zona Glomerulosa.

2- Zona Fasciculata: the cells are called **spongiocytes** and they are arranged in **columns**.

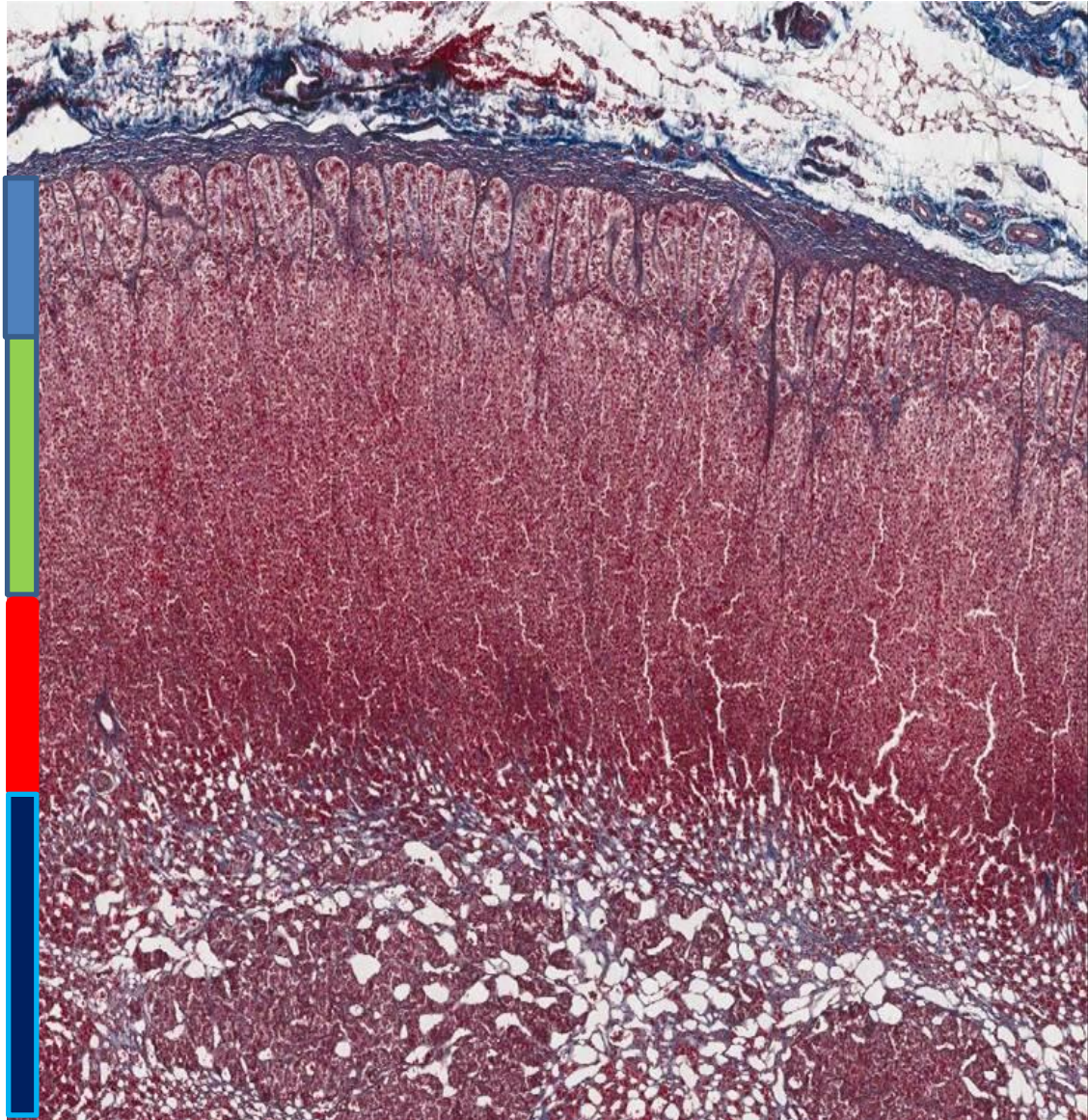
3- Zona Reticularis.

B. Medulla:

Cells:

1- Chromaffin cells (pheochromocytes).

2- Sympathetic ganglion cells.



Adrenal Gland

High Magnification

Q: Identify.

Adrenal gland.

Q: Identify features.

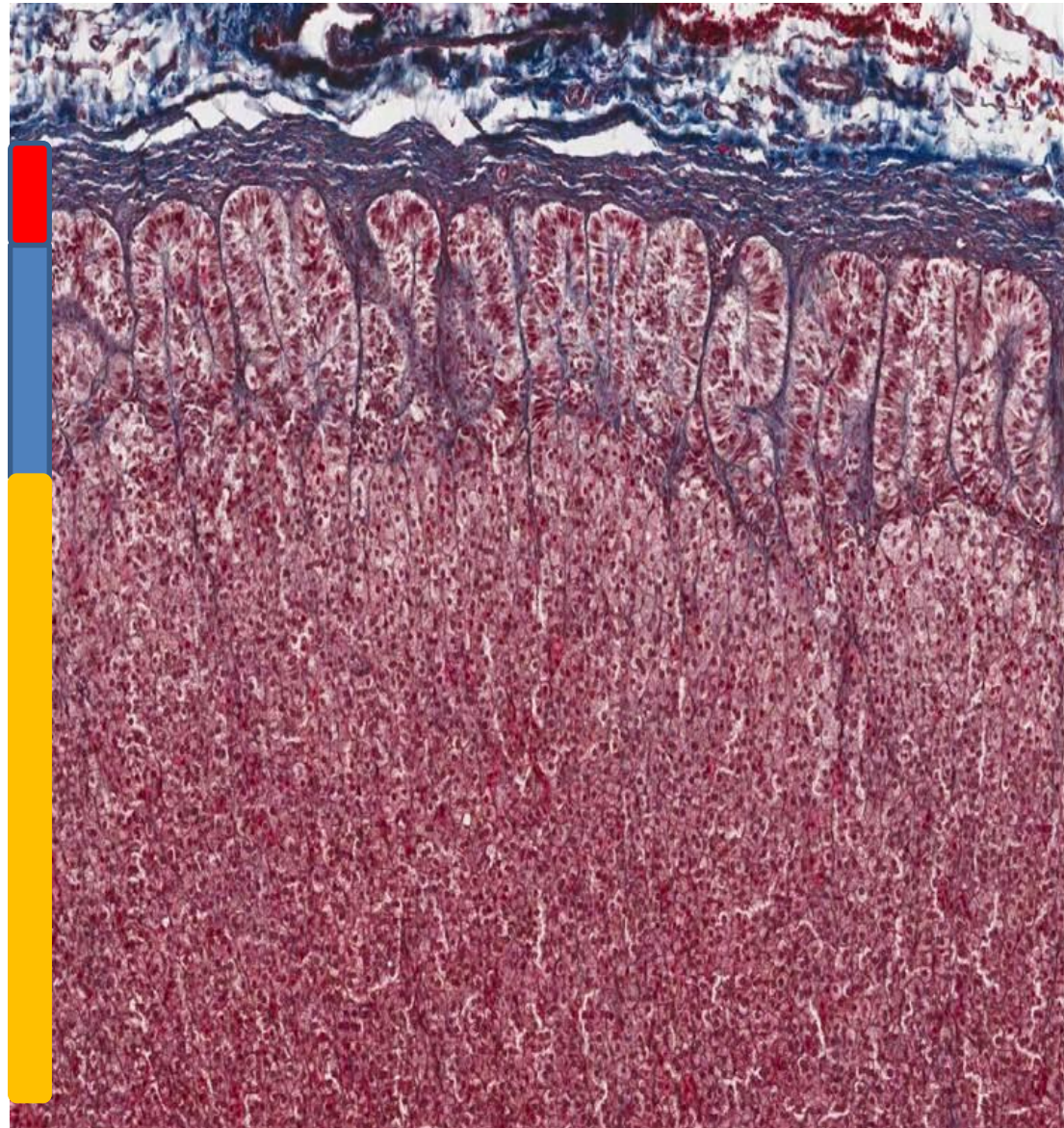
- **Cortex:**

1- Zona Glomerulosa.

2- Zona Fasciculata: the cells are called **spongiocytes** and they are arranged in columns.

Extra information:

Capsule.



**If you have any questions or suggestions please do
not hesitate to contact us on:
432histologyteam@gmail.com**



Histology Team Leaders:

Nada Alouda

Faisal Alshuwair

Best of luck!