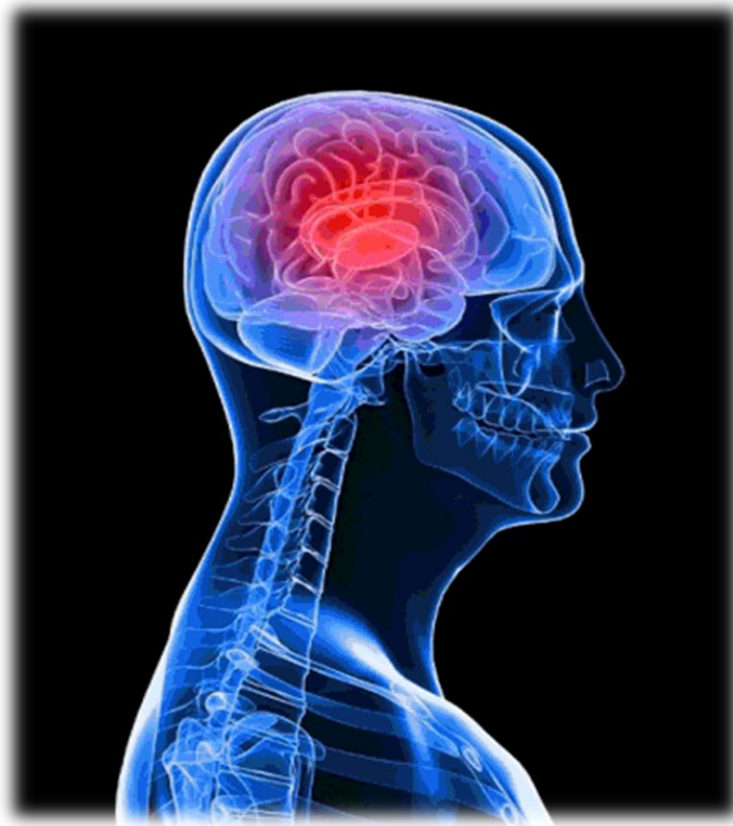

# CNS Block

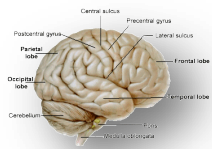
Revision Questions for weeks : 4&5



**Done by:** Lulu Alobaid, Kholoud Alraddadi, Reem Alotaibi, Khalid Alosaimi,

Tahani alshaibany

**Designed by:** Rawan Almutairi



# **Anatomy:**

## **1-The Cerebellum**

### **1) CEREBELLAR CORTEX Divided into 3 layers :**

- A. Outer molecular layer
- B. Intermediate Purkinje cell layer
- C. Inner granular layer
- D. Inner molecular layer
- E. Intermediate granular layer
- F. A,b,c
- G. A,d,e

Answer: F **Note:** My Personal Guardian

### **2) Climbing fibres from :**

- A. From inferior olivary nucleus relay to vestibular nucl
- B. from vestibular nucl relay to pons
- C. from inferior olivary nucleus, relay to purkinje cells
- D. a-b

Answer: C

### **3) regarding to Mossy fibers which of the following is true :**

- A. relay to granule cells which in turn relay to purkinje cells
- B. relay to purkinje cells which in turn relay to granule purkinje cells
- C. from vestibular nucl relay to pons
- D. b-c

Answer: A

### **4) Main efferent fibers of CEREBELLAR MEDULLA go to all the following except :**

- A. Vestibular nuclei
- B. Red nucleus
- C. Ventral lateral nucleus of thalamus
- D. Ventral anterior nucleus of thalamus

Answer: D

**5) All the following are true about ARCHICEREBELLUM except :**

- A. Part of cerebellum flocculonodular lobe
- B. Nuclei fastigial
- C. Afferents and Efferents from vestibular nuclei (through ICP)
- D. posture & muscle tone

Answer: D **Note:** Function: "controls balance" not posture & muscle tone

**6) All the following are true about PALEOCEREBELLUM except :**

- A. Part of cerebellum vermis & paravermis
- B. Nuclei: globose & emboliform
- C. Afferents fibers from spinal cord
- D. Efferents fibers to red nucleus
- E. Function coordination of voluntary movements

Answer: E **Note:** "posture & muscle tone" not coordination of voluntary movements

**7) All the following are true about NEOCEREBELLUM except:**

- A. Part of cerebellum rest of cerebellum
- B. Nuclei dentate
- C. Afferents from pons
- D. Efferents to red nucleus
- E. Most efferent fibers to ventral lateral nucleus of thalamus
- F. Function: coordination of voluntary movements and balance

Answer: F **Note:** only coordination of voluntary movements

**FUNCTIONAL SUBDIVISIONS OF THE CEREBELLUM**

<i>SUBDIVISIONS</i>	<i>Nuclei Related</i>	<i>Afferents (from)</i>	<i>Efferents (to)</i>	<i>Function</i>
<b>ARCHICEREBELLUM</b> <u>(Vestibular Part)</u>	Fastigial	Vestibular nuclei (through ICP)	Vestibular nuclei (through ICP)	Controls Balance
<b>PALEOCEREBELLUM</b> <u>(Spinal Part)</u>	Globose & Emboliform	Spinal Cord (through ICP & SCP)	Red nucleus (through SCP)	Influences posture & muscle tone
<b>NEOCEREBELLUM</b> <u>(Cerebral Part)</u>	Dentate	Pons (through MCP)	Red Nucleus (mostly to Ventral Lateral Nucleus of Thalamus (through SCP) then to motor cortex)	Coordination of voluntary movements

## 2- Cerebrum

### 1) Cerebrum separated by..... ,and connected by..... :

- A. median longitudinal fissure , vermis
- B. median longitudinal fissure, corpus callosum.
- C. corpus callosum , median longitudinal fissure

Answer: B

### 2) Insula gyri in the depth of ..... fissure and covered by..... :

- A. lateral fissure, prefrontal
- B. median fissure, frontal, parietal & temporal lobes
- C. lateral fissure , frontal, parietal & temporal lobes

Answer: C

**Note:** frontal, parietal & temporal lobes called the opercula

### 3) Regarding the cortical areas of the cerebral cortex, one is INCORRECT:

- A. All the motor areas are present in the frontal lobe.
- B. Broca's area is supplied by the middle cerebral artery.
- C. The primary visual area (area 17) is supplied by the posterior cerebral artery. d. The prefrontal cortex (frontal pole) contains the personality center.
- D. The auditory association area (area 22) lies in the middle temporal gyrus.

Answer: D

### 4) This cortical area is present in the frontal lobe of the cerebral hemisphere:

- A. Primary auditory area (areas 41 and 42).
- B. Primary visual area (area 17).
- C. Broca's area (motor speech area). "area 44-45 "
- D. Somatosensory association area (area 5 and 7).

Answer: C

### 5) Broca's (motor speech) area Located in :

- A. the middle frontal gyrus
- B. inferior frontal gyrus medial hemisphere
- C. inferior frontal gyrus dominant hemisphere
- D. Located in precentral gyrus

Answer: C

**Note:** choice "a" for "Frontal eye field Brodmann's area 8"

### 6) One of the following cortical areas of the brain is present in the parietal lobe:

- A. Primary motor area (area 4).
- B. Primary auditory area (area 41, 42).
- C. Motor eye field area (area 8).
- D. Primary visual area (area 17).
- E. General sensory area (area 3, 1, 2).

Answer: E

**7) Regarding Corpus callosum all of the following are correct EXCEPT:**

- A. It connects similar cortical areas of the two hemispheres.
- B. It is supplied by the anterior cerebral artery.
- C. It is formed of association fibers.
- D. It transmits information between the 2 hemispheres.
- E. The posterior end is called the splenium.

Answer: C

**8) Primary visual cortex located on :**

- A. lateral surface of occipital lobe
- B. medial surface of occipital lobe
- C. inferomedial part of temporal lobe
- D. a-c

Answer: B **Note:** choice "c" for Parahippocampal gyrus

**9) Language areas are located in all of the following EXCEPT:**

- A. Supramarginal gyrus.
- B. Angular gyrus.
- C. Superior temporal gyrus.
- D. Middle frontal gyrus.
- E. Inferior frontal gyrus.

Answer: D

**10) the temporal lobes that are connected by :**

- A. anterior commissure
- B. Corpus callosum
- C. Uncinate fasciculus
- D. Cingulum

Answer: A

**11) Posterior Commissure Important in**

- A. connects the inferior and middle temporal gyri

- B. bilateral pupillary reflex
- C. connect the two hippocampi

Answer: B

### 3- Meningies

#### 1) T OR F regarding to cranial dura :

- 1) cranial dura is a two layered tough, fibrous membrane T
- 2) is formed of two layers; periosteal and meningeal T
- 3) The periosteal layer is folded forming the dural folds F
- 4) The meningeal layer is attached to the skull F
- 5) Sensory innervation of the dura is mostly from the three divisions of the trigeminal and glossopharyngeal nerves & C2 to C3. F

**NOTE:** The meningeal layer is folded forming the dural folds "1-falx 2- tentorium cerebelli

The periosteal layer is attached to the skull

Sensory innervations: Vagus nerves and C1to c3

#### 2) Falx cerebri has attached border adh

- A. skull, below corpus callosum
- B. skull,below corpus striatum
- C. brain ,above corpus callosum
- D. skull, above corpus callosum

Answer: D

#### 3) Arachnoid mater separated from the dura by a narrow :

- A. subarachnoid space
- B. subdural space
- C. epidural space
- D. b-c

Answer: B **Note:** choice "A" Between the pia and arachnoid

#### 4)- Arachnoid and dural and, subarachnoid space, continue caudally to:

- A. S2
- B. L1,L2
- C. attached to the back of the coccyx.

Answer: A

#### 5)- Which one of the following opens into the subarachnoid space :

- A. Cerebral aqueduct
- B. Interventricular foramen
- C. Median foramen (of Magendi)

- D. the central canal.
- E. 2Lateral foramina of Leushka
- F. C-E

Answer: F

**6)- CEREBROSPINAL FLUID Reabsorbed into dural venous sinuses mainly ....., by .....,.....:**

- A. Cavernous, arachnoid villi
- B. superior saggital sinus, arachnoid villi, and arachnoid granulation
- C. straight , arachnoid villi, and arachnoid granulation
- D. sigmoid, arachnoid villi, and arachnoid granulation

Answer: B

#### **(4) Blood supply of cerebral hemisphere**

**Q1)CEREBRAL ARTERIAL SUPPLY by two system ?**

- A. Vertebro-Basilar System
- B. Carotid System
- C. coronary system
- D. a-b

Answer: D

**q2)Circle of Willis Encircles all of the following Except**

- a)Hypothalamus
- b)Thalamus
- C)Midbrain
- D)Optic chiasma

Answer: B

**Q3)CIRCULUS ARTERIOSUS "Circle of Willis" formed by all of the following except**

- a)Two Anterior cerebral arteries and one Anterior communicating artery
- b)Two Posterior cerebral arteriesandTwo Posterior communicating arteries
- c)Two Internal carotid arteries
- d)Middle cerebral artery

Answer: D

**q4)ANTERIOR PERFORATING ARTERIES arise from all of the following Except ?**

- a)Anterior cerebral artery
- b)Posterior cerebral arteries
- c) Anterior communicating artery
- d)Middle cerebral artery
- e)Posterior communicating arteries

**Answer: B&E** note: choices “b” & “e” are formed POSTERIOR PERFORATING ARTERIES

**q5)ANTERIOR PERFORATING ARTERIES supply by all of the following Except ?**

- a)Thalamus
- b) Hypothalamus
- c)Optic chiasma
- d)Large part of basal ganglia
- e)Internal capsule

**Answer: A**

**q6)POSTERIOR PERFORATING ARTERIES supply by all of the following**

- a)part of Hypothalamus
- b)part of subthalamus
- c)Ventral portion of Midbrain
- d) Optic chiasma

**Answer: D**

**q7) Which of these is supplied by both Anterior & Posterior Perforating arteries:**

- A. Hypothalamus
- B. Optic chiasma
- C. Basal Ganglia
- D. Subthalamus

**Answer: A**



**Q8)Anterior cerebral artery supplies which part of the brain ?**

- A)Orbital
- B)medial surfaces of frontal and parietal lobes
- C)Entire Superolateral surface
- D)Inferior temporal gyri
- e)a-b

**Answer: e** Note: Choice "c" supplied by middle cerebral artery

Choice "d" supplied by posterior cerebral artery

**Q9)POSTERIOR CEREBRAL ARTERYsupplies all of the following except ?**

- a)Inferior temporal gyri
- b)Anterior and inferior temporal lobes
- C)Uncus/
- d)Orbital
- e)Inferior and Medial Occipital lobe

**Answer: D**

**Q10)Which of these are CORRECT regarding to middle cerebral artery disorders:**

- A. Difficulty in the Prefrontal lobe functions
- B. Loss of sensation & movement of contralateral face, hand & arm
- C. Language disturbances
- D. Motor disturbance in contralateral distal leg
- E. Contralateral weakness of face, arm, and hand more than legs
- F. b-c-e
- G. A-d

**Answer: F** Note: choice "g" caused by Anterior cerebral artery disorders

**Q11)Which of these are CORRECT regarding to posterior cerebral artery disorders:**

- a) Language disturbances
- b)Memory impairment
- c)Motor disturbance in contralateral distal leg
- d)Visual disturbances

e)b-d

f)a-d

**Answer: e** note: Visual disturbances either Contralateral homonymous hemianopsia or Bilateral lesions: cortical blindness “Anton's syndrome”

**q12)When a person thinks and solves problems, which area of the cerebrum**

**is involve?**

- A. frontal lobe
- B. parietal lobe
- C. occipital lobe
- D. temporal lobe

**Answer: A**

**Q13)DEEP CEREBRAL VEINS drain into all of the following except?**

- a)Basal ganglia
- b)Thalamus
- c)Internal capsule
- d)Hypothalamus

**Answer: D**

**Q14)Blood flows from transverse & sigmoid sinuses into?**

- a)internal jugular vein
- b)external jugular vein
- c)Great Cerebral vein

**Answer: A** note: choice “C” formed by Deep veins and Internal Cerebral Veins.

---

### SUPERFICIAL CORTICAL VEINS

Features	Superior cerebral veins	Inferior cerebral veins	Superficial middle cerebral veins
Special feature	6 to 12 veins	Run <u>below</u> the lateral sulcus	Runs <u>along</u> the lateral sulcus

---

<b>Drainage</b>	lateral surface of brain <u>above</u> the lateral sulcus	lateral surface of the temporal lobe	Connected posteriorly by Superior & Inferior anastomotic veins to Superior Sagittal & Transverse sinuses respectively
<b>Termination</b>	1- <u>mainly</u> into the Superior Sagittal sinus 2- <u>partly</u> into superficial middle cerebral vein	1- <u>mainly</u> into superficial middle cerebral vein 2- <u>partly</u> into Transverse sinus.	into the Cavernous sinus

### (5) Basal ganglia

#### q1)neostriatum or striatum formed by ?

- a)Putamen and*Globus Pallidus*
- b) *Globus Pallidus* and *Amygdaloid Nucleus*
- c)Putamen and Caudate nucleus

Answer: D

#### q2)PUTAMENSeparated from globuspallidus by?

- a)lateral medullary lamina
- b)medialmedullary lamina
- c)extreme capsule
- d)external capsule

Answer: A

note:

Choice "B" between lateral & medialdivisions of globuspallidus

choice "C" between the claustrum and the insula

choice "d" Separateputamen and claustrum

#### Q3)The input portion of Corpus striatumis ?

- a)STRIATUM
- b)*Pars reticulate of SubstantiaNigra*
- c)SubthalamicNucleus

d) *Medial segment of globus pallidus*

Answer: A

Note:

striatum "Neostriatum" "CAUDATE & PUTAMEN"

*output portion of corpus striatum* "PALEOSTRIATUM" choices "B" & "C"

**q4) lentiform is separated from caudate by..... & from thalamus by.....**

- a) lateral medullary lamina, medial medullary lamina
- b) anterior limb of internal capsule, the posterior limb
- c) the posterior limb, anterior limb of internal capsule

Answer: B

**q5) Afferent fibers of striatum come from all of the following Except ?**

- a) cerebral cortex
- b) pars compacta of substantia
- c) *Pars reticulata of Substantia Nigra*
- d) *intralaminar nucleus of thalamus*

Answer: C

**q6) Afferent fibers of both lateral & medial segments of globus pallidus come from?**

- a) striatum
- b) cerebral cortex
- c) subthalamic nucleus
- d) A-C

Answer: D

**Q7) Efferent fibers of medial segment is directed to all of the following except ?**

- a) ventral lateral
- b) ventral anterior

- c) subthalamic nucleus
- d) centromedian nucleus

Answer: C

Note: Efferent fibers of lateral segment directed to "subthalamic nucleus"

## (6) Thalamus

**Q1) Thalamus connected to 3rd ventricle by the :**

- a) interventricle foramen
- b) interthalamic connexus
- c) interthalamic adhesion
- d) Massa intermedia
- e) B-C-D
- f) A-B-D

Answer: e Note: B-C-D All of them same meaning

**Q2) Lateral Nuclear Group divided into Dorsal & Ventral tiers regarding to dorsal tiers all the following are true except ?**

- a) contains Lateral geniculate N
- b) contains Pulvinar
- c) Lateral Dors
- d) Lateral Posterior

Answer: A

**Q3) All thalamic nuclei project to the ipsilateral cerebral cortex EXCEPT**

- a) anterior nuclear
- b) lateral nuclear
- c) medial nuclear
- d) reticular nucleus.

Answer: D

## #Classification of thalamic nuclei according to their projection

<u>1-Simple Sensory Relay Nuclei</u>	<u>Afferent fiber from</u>	<u>Efferent fiber to</u>
posterolateral ventral nucleus	1-Medial lemniscus 2- Spinal lemniscus	sensory cortex
Posteromedial ventral nucleus	Trigeminal lemniscus	Sensory cortex
lateral geniculate body	Optic tract	1-Optic radiation 2-visual cortex.
medial geniculate body	Lateral lemniscus	1-Auditory radiation 2-auditory cortex.

<u>2-Circuit relay nuclei</u>	<u>Efferent fiber to</u>
Lateral ventral nucleus	primary motor cortex
Anterior ventral nucleus	premotor cortex
Anterior nucleus (cingulate gyrus)	Limbic System.
Part of dorsomedial nucleus	

### Associative nuclei are

Part of dorsomedial nucleus
Pulvinar
Lateral dorsal nucleus
Lateral posterior nucleus

Q4)Most integration of the sex and food drive behaviors is accomplished through the -----areas

- A. Amygdala.
- B. hypothalamic nuclei
- C. limbic system
- D. brain stem

**Answer: C** note: choice "a"Function:It is involved in FEAR , Emotions.Anger, &Hormonal secretions

q5)limbic system is a set of brain structures including ?

- a)Habenular nuclei
- b)Anterior thalamic nuclei
- c)posterior thalamic nuclei
- D) A-B

**Answer: D**

Q6)Which of the following is the principalefferent pathway to the hippocampus?

- a. Amygdala.
- b. Dentate Nucleus
- c. Fornix.
- d. Mamillary body.

Answer: C

**Q7)FORNIX It is C-shaped group of fibers connecting the?**

- A)hippocampuswith Amygdala.
- b)Amygdala with withHabenuar nuclei
- c) hippocampuswith Mamillary body

Answer:C

**q8)According to Papez circuit which of the following is CORRECT:**

- A. Connects the parahippocampalgyrus, hippocampus, fornix, mamillary body, anterior thalamic nucelus and cingulate gyrus.
- B. Connects the parahippocampalgyrus, hippocampus, fornix, mamillary body, posterior thalamic nucelus and cingulate gyrus.
- C. Connects the parahippocampalgyrus, hippocampus, fornix, mamillary body, anterior thalamic nucelus and Olfactory system.

Answer: A

**Q9)Which of the following is the pleasure zone?**

- a. Amygdala.
- b. Dentate gyrus.
- c. Septal nuclei
- d. Hippocampus

Answer: C

## Embryology

**Q1)The embryonic hindbrain gives rise to what structures in the brain?**

- A. cerebrum and basal ganglia
- B. diencephalon
- C. midbrain
- D. cerebellum, pons, and medulla oblongata

Answer: D

**Q2)Initially, the developing forebrain is called the \_\_\_\_\_.**

- A. Prosencephalon
- B. Diencephalon
- C. Telencephalon

D. Rhombencephalon

Answer: A

**Q3) The interventricular foramen connects the -----**

- A. two lateral ventricles
- B. lateral to fourth ventricle
- C. lateral to third ventricle
- D. third to fourth ventricle

Answer: C



## **Physiology :**

### **(1) Cerebellum**

**1- cerebellum cortex contains five different cell types which are all inhibitory EXCEPT:**

- A. purkinje cells
- B. Golgi cells
- C. Granule cells
- D. Stellate cells

Answer:C

**2-Control of equilibrium & postural movements is done by vestibulocerebellum through which nucleus?**

- A. Fastigial nucleus
- B. Dentate nucleus
- C. Interpositous nuclei
- D. Emboliform nucleus

Answer: A

**3-Trunk ataxia is caused by lesion of which ONE of the following:**

- A. Vestibulocerebellum
- B. Pontocerebellar fibres

Answer: A

So, Control of equilibrium & postural movements is the function of the **vestibulocerebellum.**



**4-Which of the following is NOT one of the manifestations of neocerebellar syndrome:**

- A. Athenia
- B. Sensory ataxia
- C. Hypotonia
- D. Motor ataxia

Answer: B

**(2) Postural Reflex :**

**1-Center of visual righting reflex is:**

- A. Medulla
- B. midbrain
- C. cerebral cortex
- D. spinal cord

Answer:C.

All righting reflexes have their center in midbrain except the visual in cerebral cortex.

**2-Patient came to ER and while examine him the dr turned his head in the right side then the right limbs extended but the left limbs semi flexed. what would be your diagnosis:**

- A. decerebrate rigidity
- B. decorticate rigidity

Answer:B

In decorticate rigidity only visual righting, placing & hopping reflexes lost because their center is cerebral cortex and it's damaged.

**3-Which ONE of the following is right according to decerebrate rigidity:**

- A. Flexion in antigravity muscles
- B. Absent midbrain righting reflex
- C. Absent medullary tonic static postural reflex
- D. It's due to lesion in cerebral cortex.

Answer:B

**(3) Proprioception pathway**

**1-Which one of the following proprioceptors measure the changing length of a muscle:**

- A. Muscle spindles
- B. Joint kinesthetic receptors
- C. Golgi tendon organs

Answer:A

**2-Golgi tendon organs, Muscle spindles and Joint kinesthetic receptors are all:**

- A. Nociceptors
- B. Mechanoreceptors
- C. Thermoreceptors

Answer:B

**3-Patient went to a neurologist clinic and when the doctor asked him to close his eyes while he's standing, he was about falling down and he couldn't localize his position in a balance, what could be his diagnosis:**

- A. Cerebellar ataxia
- B. Sensory ataxia
- C. Motor ataxia

Answer:B Sensory ataxia occur due to dorsal column damage and it can be compensated for by visual inputs.

**(4) Speech and language**

**1-Choice of words to express thoughts is done by:**

- A. AngularGyrus
- B. Wernicke`s area
- C. Broca`s area
- D. Arcuatefasiculus

Answer:B

**2-Muneera came to your clinic (you're a neurologist). When you asked her about her name she understood you but she couldn't replay, then you gave her a paper and asked her to write her name she couldn't write also. Which type of aphasia you think she might have:**

- A. Sensoryaphasia
- B. Broca`s aphasia
- C. Conductive aphasia
- D. Anomic aphasia

Answer:B

**3-Which one of the following is right concerning Wernikes aphasia:**

- A. There's poorly articulated speech
- B. Patient will understand spoken & written words
- C. Failure to interprets meaning of written or spoken words

D. In some cases speech may be limited to 2-3 words

Answer:C

**4-Patient understand speech of others but can't repeat it with meaningless speech. This happen in case of:**

- A. Sensory aphasia
- B. Broca's aphasia
- C. Conductive aphasia

Answer:C

**5-Dyslexia is an example of:**

- A. Sensory aphasia
- B. Motor aphasia
- C. Anomic aphasia
- D. Conductive aphasia

Answer:C

#### **(5) Pain modulation**

**1- Impulses coming along Aβ fibers tend to:**

- A. open the gate
- B. keep the gate closed
- C. release substance p

Answer:B

**2-Which of the following substances is released by periaqueductal grey area to stimulate raphmagnus nucleus:**

- A. enkephaline
- B. Substance p
- C. aspartate
- D. dynorphine

Answer:C

**3-Allodynia is a word used for:**

- A. Excessive Pain
- B. Burning pain.
- C. Pain felt in an amputated part
- D. Pain caused by any other sensation

Answer:D

#### **(6) Spasticity**

**1-Increased resistance at the beginning of muscle stretch then a sudden collapse in resistance is called:**

- A. Cog-wheel rigidity
- B. clasp-knife spasticity
- C. decorticate rigidity
- D. Lead-pipe rigidity

**Answer:B** Lead-pipe rigidity = The same resistance all over the time. Cog-wheel rigidity = ... شدة ويفك، بعدها شدة ويفك، ...

**2-retention with overflow of urinary bladder occur in which of the following stages:**

- A. Spinal shock
- B. Recovery of reflex activity
- C. Paraplegia in extension (stage of failure of reflex activity)
- D. A&C

**Answer:D** SEE motor lesion lecture

**3-After a trauma, Ahmad had spastic left lower limb, dorsal column sensations were lost in the same limb and the doctor noticed that pain and temperature sensations are lost in the right lower limb.**

**What is the most likely diagnosis for Ahmad:**

- A. Upper motor neuron lesion
- B. Right hemisection of the Spinal Cord
- C. Left hemisection of the spinal cord

**Answer:C**

**(7) Motor lesion**

**1-Lesion in corona radiate leads to:**

- A. Quadriplegia
- B. Ipsilateralmonoplegia or hemiplegia
- C. Paraplegia
- D. contralateral monoplegia or hemiplegia

**Answer:D**

**2-Lesion in the brain stem leads to:**

- A. Contralateral hemiplegia with contralateral paralysis of the cranial nerves of the LMNL type.
- B. Ipsilateral hemiplegia with ipsilateral paralysis of the cranial nerves of the LMNL type.
- C. Ipsilateral paralysis of the cranial nerves of the LMNL type with contralateral hemiplegia
- D. Contralateral paralysis of the cranial nerves of the LMNL type ipsilateral hemiplegia

**Answer:C**

**3-Which one of the following is NOT one of the complications of spinal shock:**

- A. Ischemia of the areas compressed against bed
- B. Fall of body temp.
- C. Urinary tract infection
- D. Increased protein anabolism

Answer:D

**(8) Inner ear**

**1-bending of stereocilia towards kinocilium will open potassium channels that will result in:**

- A. Hyperpolarization
- B. Increase rate of impulses to 8th nerve fibers
- C. Basal resting tonic discharge from nerve fibers

Answer:B

**2-At deceleration (runner try to stop) >statoconia move forwards by its ..... > person try to correct this by leaning .....**

- A. Momentum, forwards
- B. Inertia, backwards
- C. Momentum, backwards
- D. Inertia, Forward

Answer:C \* At deceleration (runner try to stop) >>statoconia move forwards by its momentum >> person feels falling anteriorly>> try to correct this by leaning backwards to shift statoconia&cillia posteriorly.

**(9) Neurotransmitter**

**1-The activity of which ONE of the following areas contributes to the symptoms of opiate withdrawal:**

- A. Raphe nuclei
- B. locus coeruleus
- C. substantianigra
- D. caudate nucleus

**N.B:** Caudate nucleus release ACH which is excitatory  
Substantianigra release dopamine which is inhibitory.

Answer:B

**2-Glycine works as an inhibitory neurotransmitter by:**

- A. makes the post synaptic membrane more permeable to Cl- Ion.
- B. makes the post synaptic membrane more permeable K+ Ion
- C. makes the pre synaptic membrane more permeable to Cl- Ion
- D. makes the pre synaptic membrane more permeable to K+ Ion.

Answer:A

**3-Which ONE of the following is formed by decarboxylation of glutamate:**

- A. Glutamine
- B. Gamma Aminobutyric acid
- C.  $\alpha$  – ketoglutarate.

Answer:B

Gamma Aminobutyric acid (GABA)

**(10) Carebral hemisphere function**

**1- Which one of the following lobes is responsible for initiation and execution of voluntary movement:**

- A. Occipital lobe
- B. Temporal lobe
- C. Frontal lobe
- D. Parietal lobe

Answer:C

**2- Interprets the sense of smell once it reaches the cortex via the olfactory bulbs is done by Primary Olfactory Cortex which located in which ONE of the following lobes:**

- A. Occipital lobe
- B. Temporal lobe
- C. Frontal lobe
- D. Parietal lobe

Answer: B Olfactory bulbs is in frontal lobe.

**3- Defect in which lobe will result in problem with processing of proprioceptive:**

- A. Occipital lobe
- B. Temporal lobe
- C. Frontal lobe
- D. Parietal lobe

Answer: D

**(11) Basal ganglia**

**Which one of the following is connected to the cortex indirectly and executes skilled movement:**

- A. Caudate circuit
- B. Putamen circuit
- C. Raphe nuclei

Answer :B \* caudate has direct connection to the cortex from thalamus. Caudate circuit is excitatory, has instinctive function which works without thinking and need quick response. eg. response after seeing a lion.

**Net effect of indirect path of Intrinsic Basal Ganglia Connections is:**

- A. facilitation of movement
- B. inhibition of movement

Answer:B

**Sara is 25 year old. She went to a dr after she noticed Jerky movement of her hands and Slurred speech. After examination and investigation the dr knew that she had loss of GABAergic medium spiny projection neurons in the striatum. What would be the diagnosis:**

- A. Parkinson's disease
- B. Huntingtons Disease

Answer: B

**(12) Cerebral circulation**

**What's the effect of raising intra cranial pressure on cerebral perfusion pressure:**

- A. Raises CPP
- B. Lowers CPP
- C. Has no effect

Answer :B Raising MAP raises CPP and raising ICP lowers it.

**Which one of the following statement is true concerning regulation of CBF:**

- A. Low pH and high levels of oxygen dilate blood vessels
- B. changes in the body's overall blood pressure normally alter cerebral perfusion pressure drastically.
- C. Excess carbon dioxide and H<sup>+</sup> concentration dilate blood vessels.
- D. When pressures are outside the range of **70 to 90** mmHg, the blood vessels' ability to autoregulate pressure through dilation and constriction is lost,

Answer:C

**Which ONE of the following substances is slowly penetrating the brain:**

- A. CO<sub>2</sub>
- B. Proteins
- C. H<sub>2</sub>O

D. H<sup>+</sup>

Answer: D

### Questions from Tahani Alshaibany

**Most Excitatory neurotransmission in the brain is believed to be mediated by:**

- A. Glutamate
- B. Glycine
- C. GABA
- D. GnRH

Answer: A

**The inhibitory amino acid neurotransmitters in the CNS are:**

- A. Glutamate & glycine
- B. Glutamate & aspartate
- C. GABA & glycine
- D. Aspartate & glycine

Answer: C

**Which of the following NT has both Inhibitory & Excitatory effects:**

- A. Glycine
- B. GABA
- C. Aspartate
- D. Glutamate

Answer: A

**Which type of rigidity is clinically more common:**

- A. Decorticate rigidity
- B. Decerebrate rigidity
- C. Extensor rigidity
- D. Cog-wheel rigidity

Answer: A

**Climbing fiber input to cerebellum comes from:**

- A. Superior olivary nucleus
- B. Red nucleus
- C. Inferior olivary nucleus
- D. Locus cerules

Answer: C

**Righting reflexes are integrated for the most part in:**

- A. Medulla
- B. Midbrain



- C. Spinal cord
- D. Cerebral cortex

Answer: B

**Which of the following is absent in decorticate animals:**

- A. Gross movements
- B. Temperature regulation
- C. Hopping & placing reaction
- D. Vestibule-ocular reflex

Answer: C

**Which of the following reflexes is always absent in the blind:**

- A. Vestibule-ocular reflex
- B. Nystagmus
- C. Visual accommodation
- D. Light reflex

Answer: C

NOTS:

The ascending tracts of the spinal cord include: (T or F)

a. spinoreticular (T)

b. anterior spinothalamic (T)

c. spinotectal (F)

d. corticospinal (F)

e. spino-olivary (T)

\*\* Spinotectal & corticospinal are descending tracts

The following are true about neurotransmitters:

- A. glycine is found in the cerebral cortex (F)
- B. acetylcholine is mainly secreted by the neuromuscular junction (F)

- C. serotonin is secreted by the pineal body and parasympathetic neurones. (T)
- D. g-aminobutyric acid is found in cerebral cortex (T)
- E. dopamine is only secreted in the mid-brain (F)

\*\* Glycine and glutamic acid are found in spinal cord

\*\* Acetylcholine secreted by autonomic ganglia, parasympathetic neurons, motor nuclei of cranial nerve, caudate nucleus and parts of the limbic system.

\*\* Dopamine is secreted by hypothalamus

The following are true:

- a. glycine is involved in the metabolism of peptides (T)
- b. glutamate has a powerful inhibitory effect (F)
- c. cortical release of GABA is increased during sleep (T)
- d. the secretion of GABA is decreased in the presence of high extracellular potassium (F)
- e. release of glutamate is increased during sleep (F)

\*\*Glutamate has a powerful stimulatory effect

\*\*GABA secretion is increased in the presence high extracellular potassium

\*\*Release of glutamate is decreased during sleep

>>>>

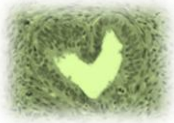The following reflexes are used to test brain stem death:

- a. Babinski's reflexes (F)
- b. accommodation (F)
- c. gag reflex (T)
- d. vestibular-ocular reflex (T)
- e. pupillary light reflex (T)

\*\* Babinski's reflexes is used to test upper motor lesion

\*\* accommodation can not be tested as the patient is in deep coma.

\*\*The other reflexes involve the brain stem



## Pathology :

### Cerebrovascular diseases :

#### 1)- Ischemia caused by :

- A. Hypotension
- B. Hypertension
- C. Vascular obstruction
- D. A-c

Answer: D **Note:** could be caused by one of them alone

#### 2)- Thrombotic occlusions causing cerebral infarctions are due to:

- A. valvular disease
- B. atrial fibrillation
- C. Myocardial infarct
- D. atherosclerosis.

Answer: D **NOTE:** A,B,C all of them Sources of emboli

#### 3)- All the following are most common sites of primary thrombosis Except :

- A. The carotid bifurcation.
- B. The origin of the middle cerebral artery.
- C. Anterior cerebral artery
- D. Either end of the basilar artery.

Answer: C

**4)- Which of the following is most frequently affected by “embolic infarction” :**

- A. The carotid bifurcation.
- B. middle cerebral artery.
- C. Anterior cerebral artery
- D. Either end of the basilar artery

Answer: B

**5)- Regarding the Global Cerebral Ischemia “T” OR “F” :**

- 1. usually below systolic pressures of less than 50mmHg. **“T”**
- 2. Caused by Cardiac arrest and hypertension. **“F”** “HYPOTENSION” SHOCK”
- 3. Persistent vegetative state remain severely impaired neurologically and deeply comatose. **“T”**
- 4. Persistent vegetative state wakeful conscious state. **“F”** " unconscious "
- 5. Respiration brain: brain death, isoelectric, or "flat" electroencephalogram and brain stem intact , reflexes are exaggerated and respiratory drive. **“F”** brain stem damage , Absent reflexes
- 6. when patients with Respiration brain of injury are maintained on mechanical ventilation, the brain gradually undergoes an autolytic “self-digestion” . **“T”**

**6)- The most susceptible to ischemia of short duration are :**

- A. Pyramidal cells of the Sommer sector (CA1) of the hippocampus
- B. Purkinje cells of the cerebellum
- C. Pyramidal neurons in the neocortex
- D. ALL

Answer: D

## (1) Global Cerebral Ischemia

### Gross pathology

**Feature :**

- 1- Brain is swollen, with wide gyri and narrowed sulci
- 2- poor demarcation between gray and white matter
- 3- Disrupted Blood brain barrier

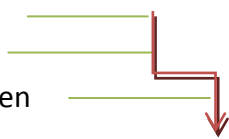

### Histopathology

Category	Duration	Feature
<b><u>Early changes</u></b>	12 to 24 hours after the insult red neuron	1-Red neurons. (1st sign of ischemia or Stroke) 2-cytoplasmic eosinophilia 3- nuclear pyknosis and karyorrhexis

A- Gross pathology: "non-hemorrhagic infarct"

<b><u>Subacute changes</u></b>	24 hours to 2 weeks	1-Necrosis of tissue 2-Reactive gliosis  The reaction to tissue damage begins with infiltration by neutrophils : A. Necrosis of tissue B. influx of macrophages C. vascular proliferation D. Reactive gliosis
<b><u>Repair</u></b>	After 2 weeks	1. Pseudo laminar necrosis 2. removal of all necrotic tissue 3. loss of organized CNS structure 4. gliosis

**(2) Focal Cerebral Ischemia**

Duration	Feature
<b><u>First 6 hours</u></b>	the tissue is unchanged in appearance.
<b><u>By 48 hours</u></b>	1-pale 2-soft 3-swollen  Corticomedullary junction indistinct
<b><u>From 2 to 10 days</u></b>	1-gelatinous 2-friable  boundaries distinct- edema subsides.
<b><u>From 10 days to 3 weeks</u></b>	liquefaction

## B- Histopathology

Duration	Feature
<b><u>1-After the first 12 hours:</u></b>	1-Red neurons and edema 2-Endothelial and glial cells, mainly astrocytes 3-swell 4-myelinated fibers begin to disintegrate.
<b><u>2-Until 48 hours</u></b>	1. 1-neutrophilic emigration 2. 2-mononuclear phagocytic cells in the ensuing 2 to 3 weeks 3. 3- Macrophages months to years.
<b><u>3- Gliosis.</u></b>	-----
<b><u>4- After several months:</u></b>	1. The striking astrocytic nuclear and cytoplasmic enlargement recedes. 2. <b><u>In the wall of the cavity</u></b> , astrocyte processes form a dense feltwork of glial fibers admixed with new capillaries and a few perivascular connective tissue fibers. 3. <b><u>In the cerebral cortex</u></b> the cavity is delimited from the meninges and subarachnoid space by a gliotic layer of tissue, derived from the molecular layer of cortex. 4. The pia and arachnoid are not affected and do not contribute to the healing process

## C- Microscopic findings "hemorrhagic infarction"

**Feature:**

1. Hemorrhagic infarction
2. parallel ischemic infarction
3. addition of blood extravasation and resorption

**7)- In cerebral hemispheres the border zone in :**

- A. The carotid bifurcation.
- B. The origin of the middle cerebral artery.
- C. between anterior and middle cerebral arteries
- D. Either end of the basilar artery.

Answer: C

**8)- laminar necrosis and watershed infarcts are most suggestive of :**

- A. Shock
- B. Hypertension
- C. Fat emboli
- D. Vascular thrombosis

Answer: A

**9)- which of the following are most common sites of aneurysm:**

- A. Anterior communicating artery and anterior cerebral artery
- B. The origin of the middle cerebral artery and anterior artery
- C. between anterior and middle cerebral arteries
- D. Either end of the basilar artery and posterior communicating artery

Answer: A

**10)- Rupture of a berry aneurysm of the Circle of Willis would likely produce hemorrhage into the:**

- A. Epidural space
- B. Cerebellum
- C. Subarachnoid space
- D. Subdural space

Answer: C

**11)-Hypertension is most closely related to the formation of which one of the following types of aneurysms:**

- A. Berry aneurysm

- B. Atherosclerotic aneurysm
- C. Mycotic aneurysm
- D. Charcot-Bouchard aneurysm
- E. Saccular aneurysm

Answer: D

12)- A 68-year-old obese woman (BMI = 34 kg/m<sup>2</sup>) suffers a stroke and expires. Histologic examination of the brain at autopsy reveals extensive arteriolar lipohyalinosis and numerous Charcot-Bouchard aneurysms. Which of the following best accounts for the pathogenesis of these autopsy findings:

- A. Atherosclerosis
- B. Autoimmunity
- C. Diabetes
- D. Hypertension
- E. Vasculitis

Answer: D

13)- A 12-year-old boy is rushed to the emergency room in a coma after falling from an upper story window of his home. MRI shows a subdural hematoma over the left hemisphere. What is the most likely source of intracranial bleeding in this patient?

- A. Bridging veins
- B. Charcot-Bouchardaneurysm
- C. Internal carotid artery
- D. Middle meningeal artery
- E. Sagittalsinus

Answer: A

14)-A 30-year-old woman suffers massive trauma in an automobile accident and expires 4 days later of respiratory insufficiency. A horizontal section of the patient's brain at autopsy reveals numerous petechiae scattered throughout the white matter. Which of the following is the most likely explanation for this pathologic finding?

- A. Fat embolism
- B. Global ischemia
- C. Occlusion of middle cerebral artery
- D. Sepsis
- E. Uremia

Answer: A

### Degenerative brain

1) A 35-year-old man presents with a history of behavioral and personality changes and unusual involuntary movements. Physical examination reveals chorea and dystonia. The patient's mother and



maternal grandfather had similar clinical symptoms. His mother died in a psychiatric institute, and his maternal grandfather committed suicide. MRI shows bilateral cerebral atrophy and enlargement of the lateral ventricles. Marked atrophy would also be expected in which of the following regions of this patient's brain?

- A. Anterior horn of the spinal cord
- B. Caudate nuclei
- C. Cerebellum
- D. Hypothalamus
- E. Substantia nigra

Answer: B **Note:** diagnosis is Huntington disease (HD) affects Striatum "caudate and putamen"

2) Which of the following causes a spongy degeneration in the brain :

- A. Creutzfeldt-Jakob disease
- B. Mad cow disease
- C. A-b
- D. Wernicke-Korsakoff syndrome

Answer: C **Note:** 1- "A" & "B" same meaning , 2- "D" Thiamine deficiency

3) A 55-year-old male presents with rapidly progressive dementia and dies. At autopsy, marked spongiform degeneration of the brain is found. These changes are suggestive of

- A. A deficiency of galactocerebrosidase
- B. Abnormal folding of a prion protein
- C. Decreased activity of superoxide dismutase
- D. Ingestion of ova of taenia solium

Answer: B

4) Which one of the listed statements describes a major risk factor for both sporadic Alzheimer's disease and late-onset familial Alzheimer's disease :

- A. amyloid precursor protein
- B. Expansion of CAG trinucleotide repeats on chromosome 4
- C. Ingestion of 1-methyl-4-phenyl-tetrahydrobiopteridine
- D. Mutations of the superoxide dismutase 1 gene
- E. Presence of apolipoprotein E4

Answer: E

5) A 65-year-old male presents with bradykinesia, tremors at rest, and muscular rigidity. Physical examination reveals the patient to have a "masklike" face. In this patient, where would intracytoplasmic eosinophilic inclusions most likely be found :

- A. Basal ganglia
- B. Caudate nucleus
- C. Hippocampus
- D. Midbrain
- E. Substantia nigra

Answer: E

**6) A 41-year-old male presents with involuntary rapid jerky movements and progressive dementia. He soon dies, and gross examination of his brain reveals marked degeneration of the caudate nucleus.**

**This individual's symptoms were caused by :**

- A. Decreased functioning of GABA neurons
- B. Increased functioning of dopamine neurons
- C. Relative increased functioning of acetylcholine neurons
- D. Relative decreased functioning of acetylcholine neurons
- E. Decreased functioning of serotonin neurons

Answer: A

**7) Liquefactive necrosis is typically seen in:**

- A. Thyroid
- B. brain
- C. liver
- D. Heart

Answer: B

**8) A 76-year-old man is admitted to the hospital for evaluation of progressive memory loss and disorientation. The pupils are small but react normally to light. Muscle tone is normal. A lumbar puncture returns clear, colorless CSF under normal pressure. An electroencephalogram shows diffuse slowing. A CT scan of the brain reveals moderate atrophy. Which of the following is the most likely diagnosis :**

- A. Alzheimerdisease
- B. Creutzfeldt-Jakobdisease
- C. Glioblastomamultiforme
- D. Huntingtondisease
- E. Pickdisease

Answer: A

**9) A 68-year-old woman complains of difficulty getting out of a chair. On examination, the patient shows reduced facial expression, a resting tremor, cogwheel rigidity, and bradyki-nesia (slowness of voluntary movements). The patient dies of congestive heart failure 10 years later. Microscopic exami-**

nation of brain tissue at autopsy is shown in the image. The spherical, eosinophilic inclusions in the cytoplasm of this pigmented neuron are composed of which of the following proteins?

- A. b-Amyloid
- B. Polyglutamine
- C. PrPsc (
- D. a-Synuclein
- E. Tau

Answer: D

10) A 60-year-old man with a history of smoking and chronic bronchitis complains of difficulty walking. On examination, the patient appears stiff and stooped, shows an expression- less face, and speaks in a monotonous voice. A tremor of his fingers is apparent but ceases when he tries to reach for some- thing. The patient dies 3 years later of metastatic lung cancer. At autopsy, the substantia nigra of the patient (right) differs from that of a normal brain (left). This pathologic finding is associated with which of the following biochemical changes?

- A. Increased b-amyloid biosynthesis
- B. Increased release of NMDA
- C. Increased synthesis of GABA
- D. Reduced levels of dopamine
- E. Reduced tau protein self-assembly

Answer: D

11) A 60-year-old chronic alcoholic was found in a state of mental confusion. Physical and neurologic examinations reveal hori- zontal diplopia, strabismus, amblyopia, nystagmus, ataxia, and peripheral neuropathy. The patient subsequently devel- ops lobar pneumonia and expires. Examination of the brain at autopsy shows calcification and brownish discoloration of atrophic mammillary bodies. Petechiae in the quadrigeminal plate and periaqueductal regions of the midbrain are also observed. Which of the following best explains the pathogen- esis of these clinical and pathologic findings :

- A. AIDS-related encephalopathy
- B. Amyotrophic lateral sclerosis
- C. Hepatic encephalopathy
- D. Hepatorenal syndrome
- E. Thiamine deficiency

Answer: E **NOTE:** Diagnosis: Wernicke encephalopathy

12) A 35-year-old man with Down syndrome dies of acute lym- phoblastic leukemia. Gross examination of the patient's brain at autopsy shows mild microcephaly and underdevelopment of the

superior temporal gyri. Histologic examination would most likely show which of the following neuropathologic changes :

- A. AAmyloidosis
- B. Lewy bodies
- C. Negri bodies
- D. Neurofibrillary tangles
- E. Spongiform encephalopathy

Answer: D **Note:** Diagnosis: Down syndrome, amyloid



## **Pharmacology :**

### **Epilepsy :**

**1- Drug of choice for absence seizure is :**

- A. Ethosuximide
- B. Phenytoin
- C. Carbamazepine

Answer: A

Note: 1-Sodium valproate could be used in "Absence seizures" for all ages but contraindicated in "pregnancy"  
2-Carbamazepine is drug of choice for "Partial Seizures"

**2- The drug of choice in status epilepticus is :**

- A. lorazepam
- B. Carbamazepine
- C. Ethosuximide

Answer: A

**3- The adverse effects of sodium valproate includes:**

- A. hepatic toxicity

- B. decrease body weight
- C. cardiac arrhythmias

Answer: A

### Balance:

#### 1- Pheocromocytoma is contraindication for:

- A. dimenhydrinate
- B. Betahistine
- C. Metoclopramide

Answer: B

#### 2- Which drug has gastroprokinetic effect :

- A. dimenhydrinate
- B. promethazine
- C. metoclopramide
- D. Answer: C

\* Gentamycin is one of the drug inducing vertigo that causes apoptosis.

### Pain :

#### 1- Patient came to the hospital complaining of mild pain, cough and diarrhea. Which of the following drugs is the most appropriate to control all his symptoms:

- A. Morphine
- B. Meperidine
- C. Codeine
- D. Fentanyl

Answer: C

#### 2- Patient will undergo a major surgery and the anesthetic said it's his condition will be unstable in anesthesia. Which of the following drugs is used instead of anesthetic drugs:

- A. Morphine
- B. Heroin
- C. Tramadol
- D. Fentanyl

Answer: D "Tramadol used in minor surgery."

**3- Which ONE of the following drugs used to treat opioid withdrawal and causes tolerance & dependence in non addicts:**

- A. Methadone
- B. Meperidine
- C. Tramadol
- D. Fentanyl

Answer: A

## Headache

**1-Which One of the following antiemetic drugs I prefer to give to a student who has an exam and she's having migraine:**

- A. Promethazine
- B. Ondansetron
- C. Domperidone
- D. Granisetron

Answer: C

**Domperidone** has Gastro-prokinetic effect and it's often preferable because 1- it increases the absorption & bioavailability of abortive therapy. 2- it doesn't cross BBB. 3- has no sedative effect. Promethazine (has sedative effect). Ondansetron&Granisetron (they're 5HT<sub>3</sub> antagonists and I use them just in severe cases also they're expensive.

**2-Which ONE of the following is a contraindication for the use of ERGOTS:**

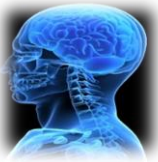- A. Young women
- B. Fever, sepsis
- C. Patients with recurrent attacks
- D. Hypotension

Answer: B because it reduces vasodilatation which is needed in these 2 situations.

**3-What is the best drug prescribed to a patient with migraine that lasts for 5 hours, as an abortive therapy:**

- A. NARATRIPTAN
- B. SUMATRIPTAN
- C. Promethazine
- D. Acetaminophen

Answer:A but be careful it's contraindicated in patients with **renal or hepatic impairment**



## Radiology :

### Radiology Lecture 1

1. Which one of the following is correct about spinal cord?

- A. Continuous with medulla oblongata
- B. Extends to approximately L3
- C. Connected to 30 pairs of spinal nerves

Answer:A

2. Which one of the following contains CSF, blood vessels and spinal roots?

- A. epidural space
- B. subdural space
- C. subarchnoid space

Answer:C

3. Which one of the following contains blood vessels and fat?

- A. epidural space
- B. subdural space
- C. subarchnoid space

Answer:A

**4. Three membranes surround all of CNS respectively (from outside to inside)?**

- A. Dura mater, Arachnoid meninx and Pia mater
- B. Arachnoid meninx, Dura mater and Pia mater
- C. Pia mater, Arachnoid meninx and Dura mater

Answer:A

**5. The diagnostic tool that uses radiographic contrast media (dye) to be injected into the spinal canal's fluid:**

- A. Myelogram
- B. Elastography
- C. Tomography

Answer:A

**6. Why do they usually use T2 weighting in spine surgery?**

- A. It highlights the hydrogen in water as bright grey
- B. It highlights the hydrogen in water as black
- C. It highlights the hydrogen in water as bright white

Answer:C

**7. The first series of images to be ordered by the physician:**

- A. Ultrasound
- B. X-Ray
- C. CT images

Answer:B

**8. To provide very detailed information about the fracture or any bony defect:**

- A. MRI
- B. X-Ray
- C. CT images

Answer:C

**9. The best diagnostic images for the soft tissue injury:**

- A. MRI
- B. X-Ray
- C. CT images

Answer:A

**10. Using MRI in Bilateral Interfacetal Dislocation, we can see:**

- A. major fracture
- B. Soft tissue swelling
- C. Disc is intact



Answer:B

**11. In Lumbar disk herniation, Myelogram shows:**

- A. major fracture
- B. Soft tissue swelling
- C. extradural lesion

Answer:C

**12. Epidural abscess caused usually by:**

- A. Staphylococcus
- B. Salmonella
- C. Brucella

Answer:A

**13. Most common injury to the spine is:**

- A. Intraspinal infection
- B. Osteomyelitis
- C. Disc

Answer:B

**14. Fracture-dislocation is characterized by:**

- A. Unstable injury
- B. Always hemorrhagic
- C. cause little spinal cord compression

Answer:A

**15. Non-hemorrhagic spinal cord injury have:**

- A. High signal on MRI due to edema
- B. Low signal intensity within the area of edema.
- C. According to the severity

Answer:A

## Radiology Lecture 2

**16. Prosencephalon gives you?**

- A. Thalamus, hypothalamus
- B. Midbrain
- C. pons and cerebellum

Answer:A

**17. Brain Stem components from superior to inferior?**

- A. Pons, midbrain and medulla oblongata
- B. medulla oblongata, Pons and midbrain
- C. Midbrain, Pons and medulla oblongata

Answer:C

**18. Radiological Feature at the level of Midbrain?**

- A. Basilar artery
- B. Circle of willis
- C. Lack of bony artifact

Answer:B

**19. At the level of superior colliculi?**

- A. Red nucleare ventral to substantianigra
- B. Red nucleiare lateral to substantianigra
- C. Red nucleiare dorsal to substantianigra

Answer:C

**20. The most anterior inferior part of the hemispheres that lies close to the midline?**

- A. Tonsils
- B. Vermis
- C. Flocculus

Answer:A

**21. Is a small ventral portion of the hemisphere?**

- A. Tonsils
- B. Vermis
- C. Flocculus

Answer:C

**FYK:**

**At the level of Midbrain, you can see:**

- ✓ Superior colliculus

- ✓ Inferior colliculus
- ✓ Cerebral peduncle
- ✓ Interpeduncular cistern

**At the level of Pons, you can see:**

- ✓ 4<sup>th</sup> ventricle
- ✓ Basilar artery
- ✓ Middle cerebellar peduncle

**At the level of Medulla oblongata, you can see:**

- ✓ Lack of bony artifact
- ✓ Ventral median anteriorly
- ✓ Pyramid laterally
- ✓ 4<sup>th</sup> ventricle posteriorly

**At the level of Cerebellum, you can see:**

- ✓ Middle cerebellar peduncle
- ✓ Petrous temporal bone
- ✓ Tentorium
- ✓ Vermis
- ✓ Flocculus
- ✓ Tonsils

**22. In the case of Acute infarction due to basilar artery thrombosis:**

- A. Hyperdense basilar artery
- B. Absence of basilar artery
- C. Normal density of basilar artery

Answer:A

## Radiology Lecture 3

**23. Which one of the following is an advantage for CT scan?**

- A. No radiation
- B. Widely available
- C. Good choice in neonates

Answer:B

**24. Which one of the following is a disadvantage for MRI?**

- A. Radiation
- B. Operator dependent
- C. Long scanning time

Answer:C

**25. Which one of the following is an advantage for Ultrasound?**

- A. Excellent soft tissue details
- B. Good choice in neonates
- C. Fast scanning time

Answer:B

**FYK:**

	CT scan	MRI	Ultrasound
Advantages	-Good soft tissue details (but less than MRI) -Widely available -Fast scanning time (seconds) -Relatively cheap (cheaper than MRI)	-Excellent soft tissue details (better than CT) -No radiation	-Good soft tissue details (but less than CT and MRI). -Good choice in neonates. -No radiation. -Cheap & Available.
Disadvantages	-Radiation -Less soft tissue details than MRI	-Expensive -Long scanning time -Less available (less than CT)	-Not used after fontanel/suture closure ( <b>after 6 months</b> ). -Operator dependent

**26. How the brain was imaged in the past?**

- A. Plain X-Ray
- B. Pneumoencephalography
- C. CT scan

Answer:B



**Psychiatry:**

Lecture 1

Decreased attention span and impaired consciousness are the clinical hallmarks of which one of the following:

- A. Dementia
- B. Amnestic Disorder
- C. Delirium

Answer:C

**Delirium is reversible.**

Abdullah came to psychiatric clinic with 2 of his sons, they reported that he couldn't remember things happened in the same day and his personality has changed since 3 months (chronic) while his consciousness was intact. What's the most likely diagnosis :

- A. Delirium
- B. Dementia
- C. Amnestic Disorder

Answer: B

Second most common cause of dementia is:

- A. Alzheimer's disease
- B. Alcohol
- C. Infection
- D. Vascular disease

Answer: D

What is the percentage of reversible cases of dementia:

- A. 50%
- B. 90%
- C. 15%
- D. 5%

Answer: C

## Lecture 2

1- As the course of the depression disorder progresses, patients tend to have :

- A. More frequent episodes that last longer.
- B. Less frequent episodes that last longer

Answer: A

2-A major depressive episode must last at least:

- A. 5 weeks
- B. 2 weeks
- C. 1 week

Answer: B

3-Most treated episodes last about:

- A. 3 months
- B. 6 months
- C. 2 months

Answer: A

If you have any questions you want to add, please send it to : [Revesiontest432@Gmail.com](mailto:Revesiontest432@Gmail.com)

**Good luck**

**Team Leaders :**

**Khalid Al-Osaimi& Lulu Al-Obaid**

**Remember this, " When you want to succeed as bad as you want to breathe, then you will  
be successful "!** 😊