

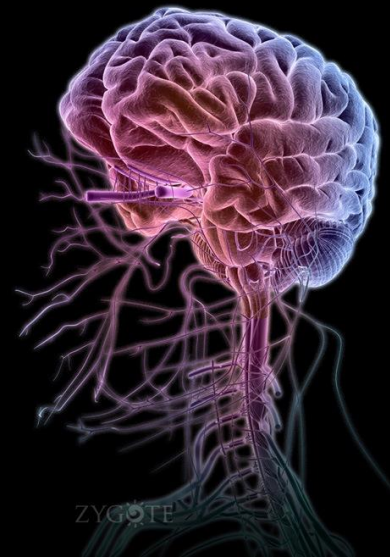THE CRANIAL NERVES (2,3,4,6)

Done by: Maram Alaql and Raya Alsuhaibani

Revised by: Hassan Almalak

هذا العمل لا يعتبر مصدر رئيسي للمذاكرة وإنما للمرجعة فقط: تنويه

[Anatomy433@gmail.Com](mailto:Anatomy433@gmail.com)



OBJECTIVES :

By the end of the lecture, you should be able to:

- List the cranial nuclei related to oculomotor, trochlear, and abducent nerves in the brain stem.
- Describe the type and site of each nucleus.
- Describe the site of emergence and course of these 3 nerves.
- Describe the important relations of oculomotor, trochlear, and abducent nerves in the orbit.
- List the orbital muscles supplied by each of these 3 nerves.
- Describe the effect of lesion of each of these 3 nerves.
- Describe the optic nerve and visual pathway.

THE CRANIAL NERVES (2,3,4,6)

Optic nerve (2nd cranial nerve)

Type

Origin

Visual pathway

Visual deficits (lesion)

Oculomotor nerve (3rd cranial nerve)

Type

Site

Origin

Course

Supplies

Function

Lesion

Trochlear Nerve (4th Cranial Nerve)

Type

Site & origin

Course

Function

Nerve lesion

Abducent Nerve (6th Cranial Nerve)

Type

Origin

Course

Function

Nerve lesion

- EXTRA-OCULAR MUSCLES (7 muscles).

- **1- Levator palpebrae superioris.**

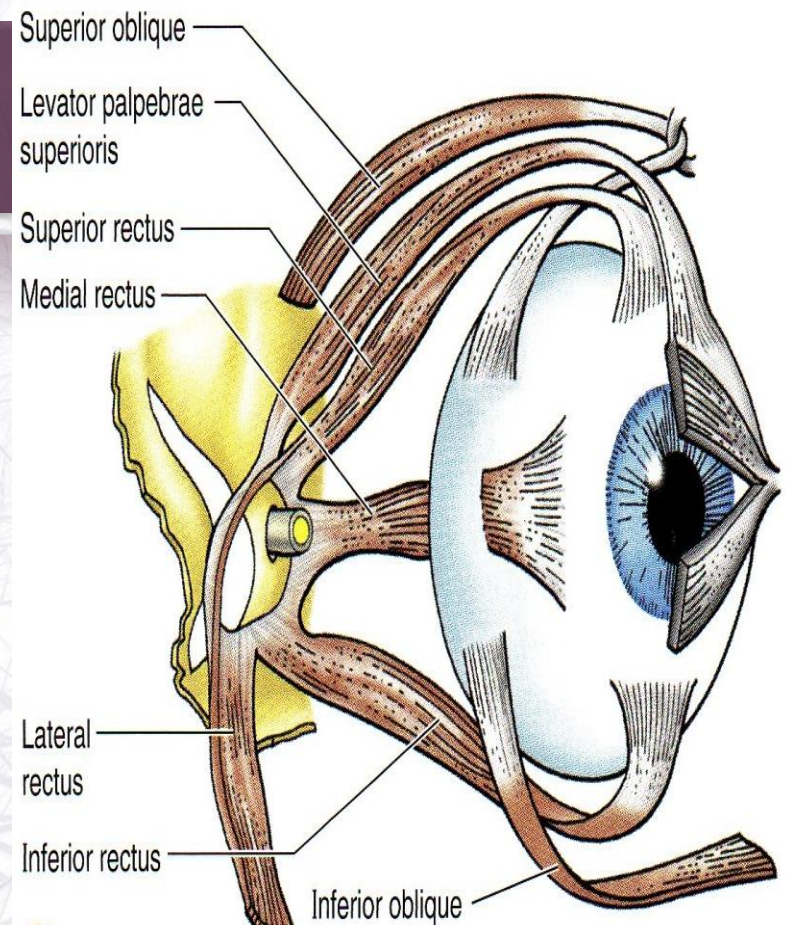
- **4 Recti muscles:**

- **Medial rectus,**
- **Lateral rectus (supplied by abducent)**
- **Superior rectus,**
- **Inferior rectus**

- **2 Oblique muscles:**

- **Superior oblique (supplied by trochlear)**
- **Inferior oblique.**

NB. All muscles of the eye are supplied by the oculomotor nerve , EXCEPT LR6 + SO4



In function, inferior oblique = superior rectus + medial rectus

Trochlear, abducent, oculomotor nerves have the same pathway :

Middle cranial fossa → run on wall of the cavernous sinus → leave the superior orbital fossa

Optic nerve (2nd cranial nerve)

Type: sensory

Receptors

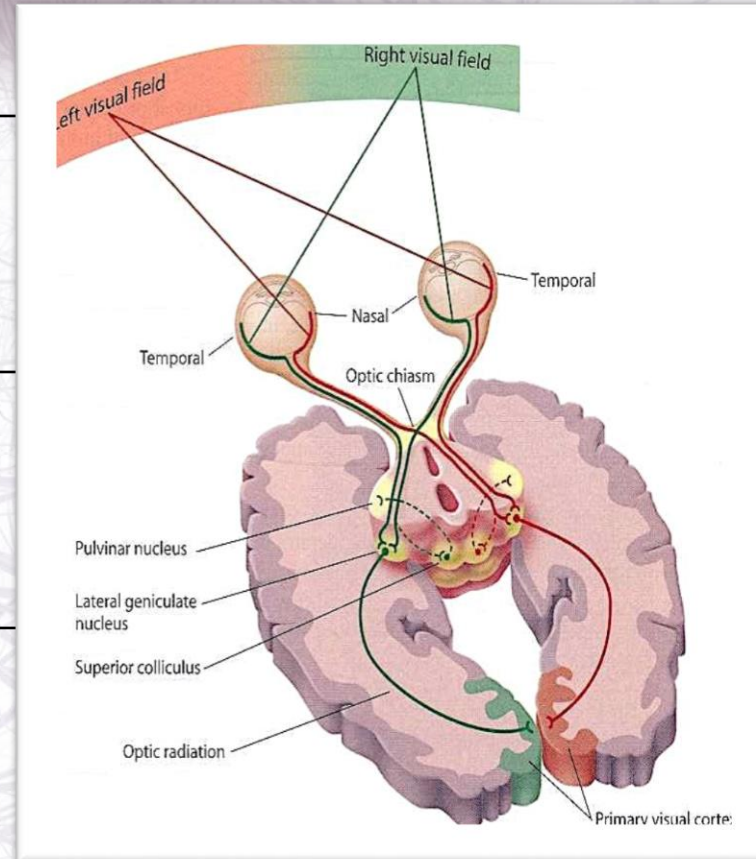
Rods & Cones of the retina

origin

Bipolar cells of retina

Visual pathway

1. **Optic nerve.**
2. **Optic chiasm.**
3. **Optic tract.**
4. **Lateral geniculate body (nucleus).**
5. **Optic radiation.**
6. **Visual cortex.**

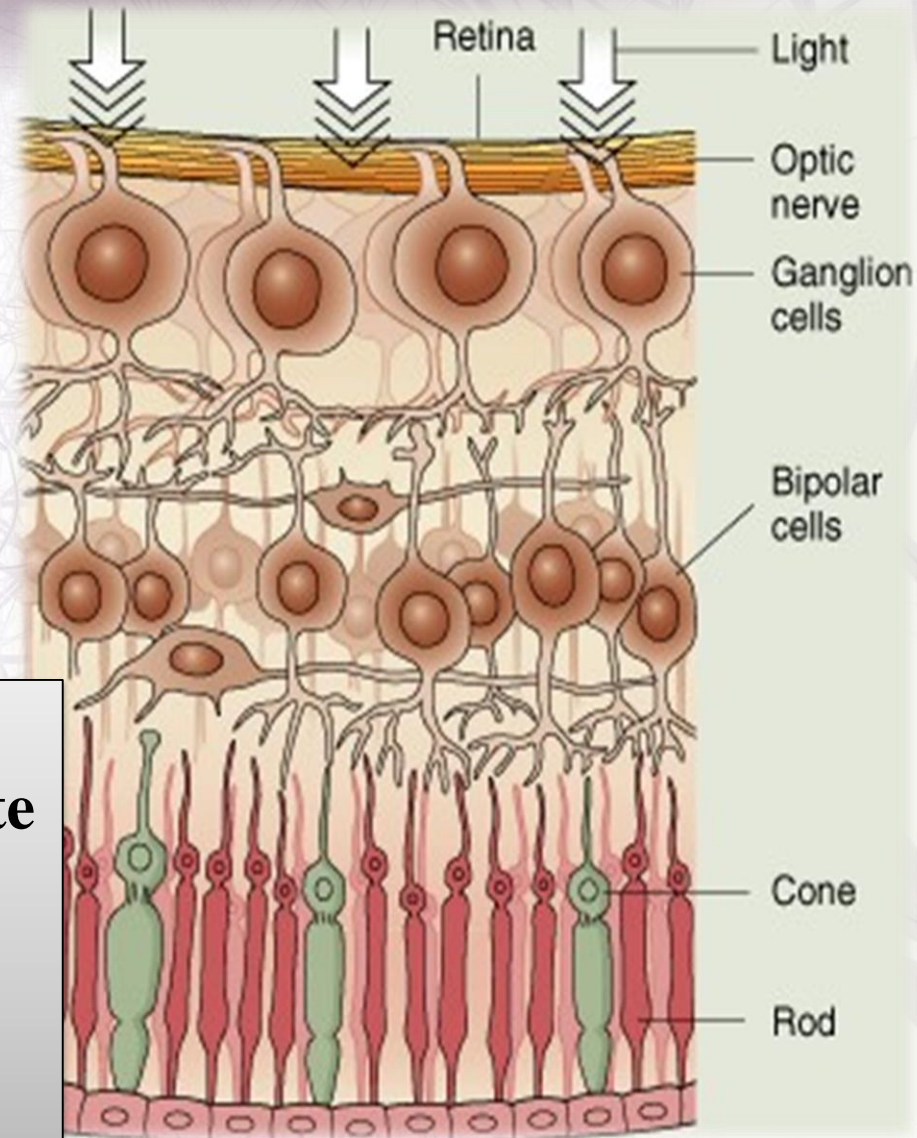


Three neurons pathway

1st order neurons:
Bipolar cells of retina

2nd order neurons:
Ganglion cells of retina.
Their axons form the **optic nerve**

3rd order neurons:
Neurons in the lateral geniculate body. Their axons **terminate** in **primary visual cortex.**

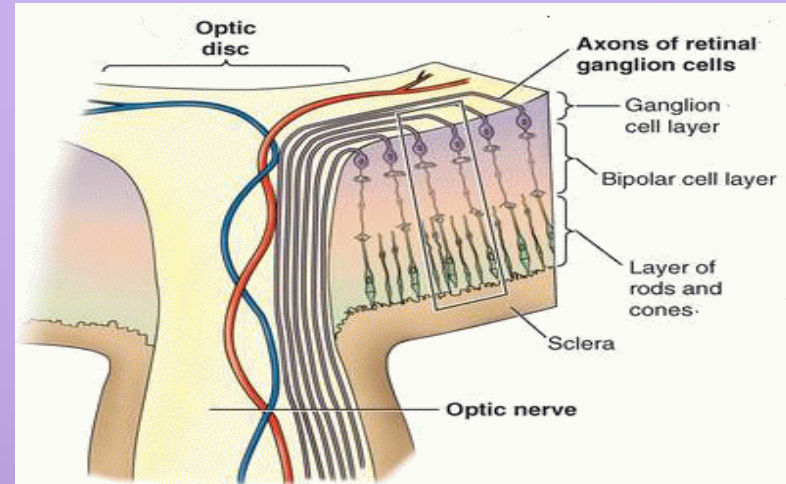


Optic Nerve

-Axons of retinal ganglion cells converge at the optic disc and pass as the optic nerve.

-Then the nerve passes posteromedially in the orbit.

-Then exits through the optic canal to enter the middle cranial fossa to joins the optic chiasma.

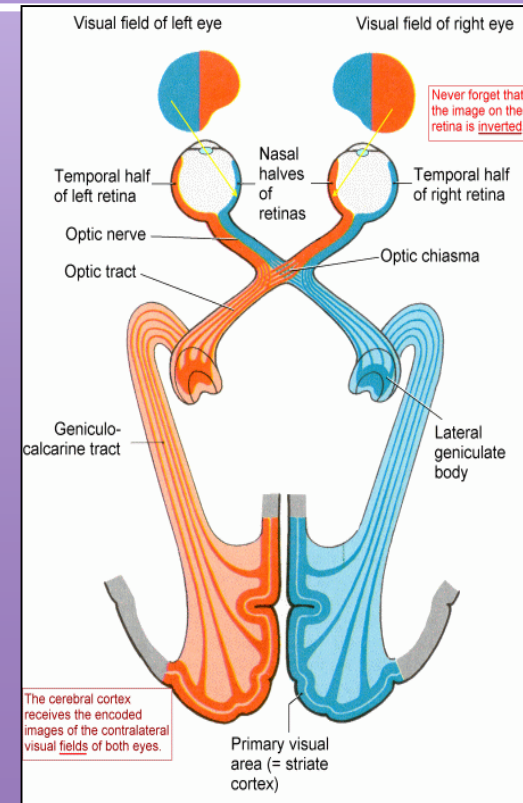


Optic Chiasma

-Fibers from the nasal (medial) half of retina decussate in the chiasm and join uncrossed fibers from the temporal (lateral) half of the retina to form the optic tract.

-The decussation of nerve fibers in the Chiasm results in the right optic tract conveying impulses from the left visual field and vice versa.

-The partial crossing of optic nerve fibers in the optic chiasma is a requirement for binocular vision.

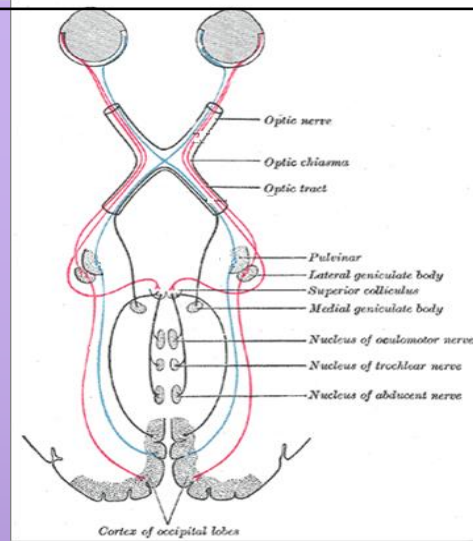


Optic Tracts

Fibers in the optic tracts:

-Mainly terminate in the (LGB), lateral geniculate body of the thalamus (3rd order neuron).

-A few fibers terminate in Pretectal area and superior Colliculus. (These fibers are related to light reflexes).

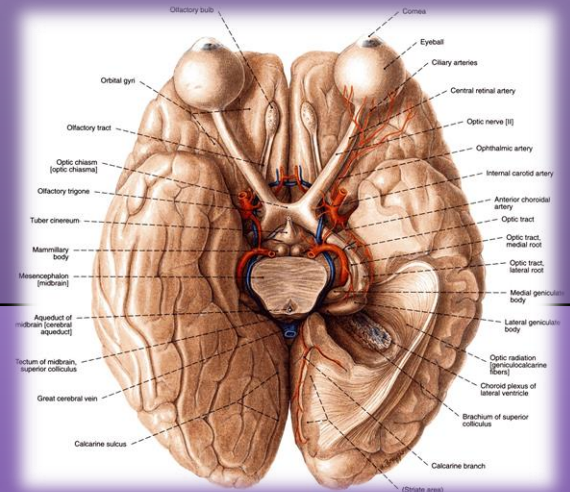


From the **lateral geniculate nucleus**

Third-order neuron thalamocortical neurones project through the retrolenticular part of the posterior limb of the internal capsule and form the optic radiation

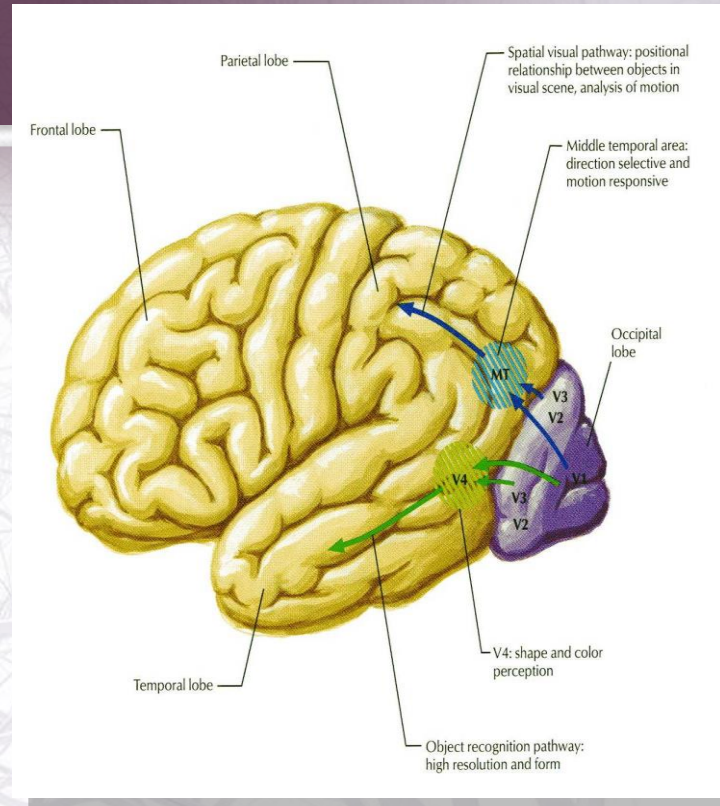
optic radiation

which terminates in the primary visual cortex of the occipital lobe. The primary visual cortex is located predominantly on the medial surface of the hemisphere in the region above and below the calcarine sulcus.



Visual Cortex

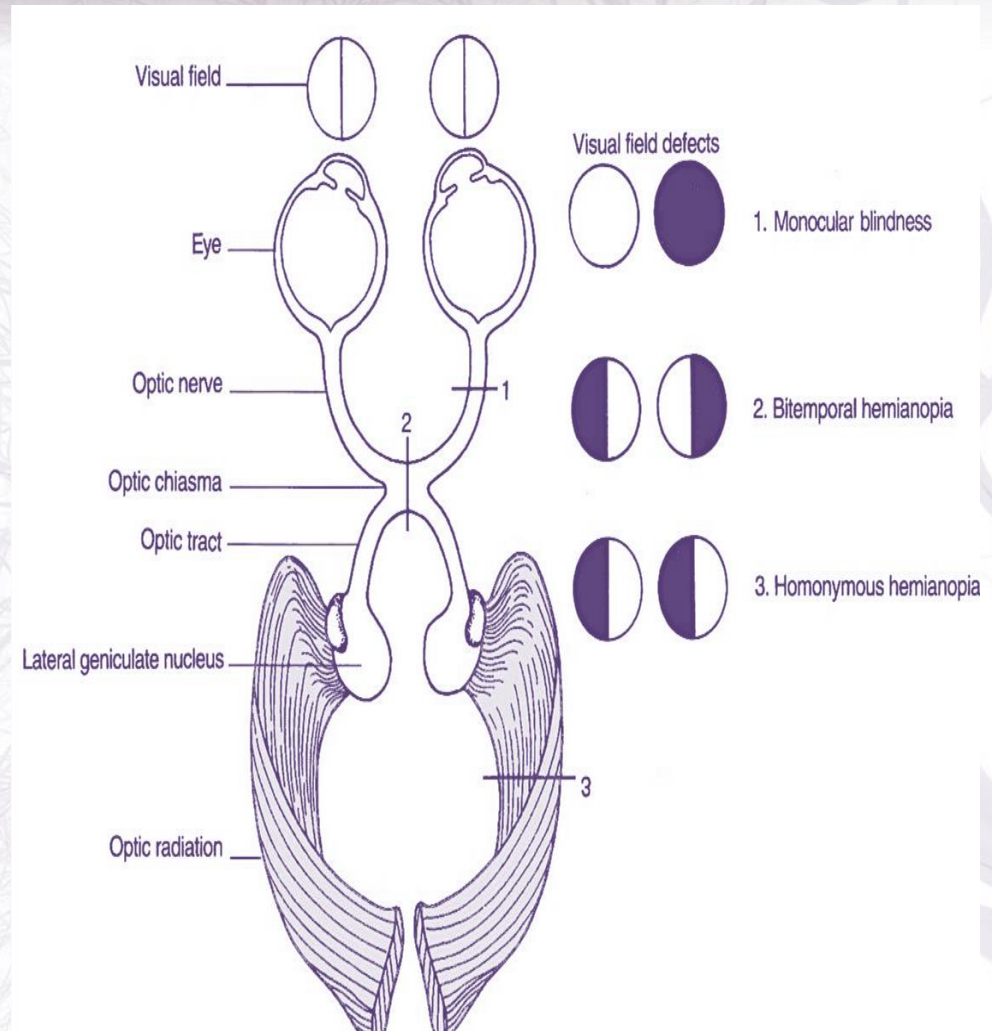
The primary visual cortex (area 17 of Brodmann's) occupies the upper and lower lips of the calcarine sulcus on the medial surface of the cerebral hemisphere.



The visual association cortex is extensive, including the whole of the occipital lobe, the adjacent posterior part of the parietal lobe. This cortex is involved in interpretation and recognition of objects and perception of color, depth, motion, and other aspects of vision.

Visual field deficits

1. Disease of the eyeball (cataract, intraocular haemorrhage, retinal detachment) and disease of the optic nerve (multiple sclerosis and optic nerve tumors) lead to loss of vision in the affected eye (**monocular blindness**).
2. Compression of the optic chiasm by an adjacent pituitary tumour leads to **bitemporal hemianopia**.
3. Vascular and neoplastic lesions of the optic tract, and optic radiation produce a **contralateral homonymous hemianopia**.



Oculomotor nerve (3rd cranial nerve)

Type of fibers	Motor for most of the extraocular Muscles (GSE)	Preganglionic parasympathetic for pupillary constrictor and ciliary Muscle (GVE)
Site (nucleus)	Main oculomotor nucleus	Accessory nucleus (Edinger-Westphal)
Origin	Lies in the mid brain, at the level of superior colliculus	Lies dorsal to the main motor nucleus. (Its cells are preganglionic parasympathetic neurons) It receives: 1-Corticonuclear fibers for the accommodation reflex. 2- From the pretectal nucleus for the direct & indirect (consensual) pupillary reflexes.

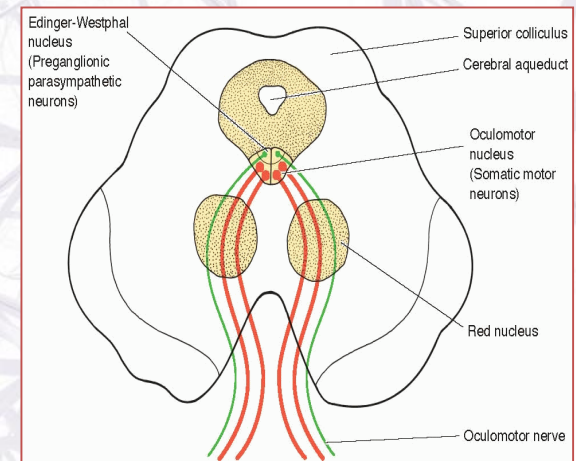
Course

- Axons curve ventrally through the tegmentum and the red nucleus in the mid brain.
- The nerve emerges on the anterior surface of the midbrain in the interpeduncular fossa.
- Then it passes forward between posterior cerebral and superior cerebellar arteries.
- In the middle cranial fossa it runs in the lateral wall of the cavernous sinus, then it divides into superior and inferior divisions which enter the orbit through the superior orbital Fissure.

supplies

- 1-Levator palpebrae superioris .
- 2-Superior rectus muscle.
- 3-Medial rectus muscle.
- 4-Inferior rectus muscle .
- 5-Inferior oblique muscle.

- Accompany the oculomotor nerve where they terminate in the ciliary ganglion.
- Postganglionic fibers pass through the short ciliary nerves to the eyebal.



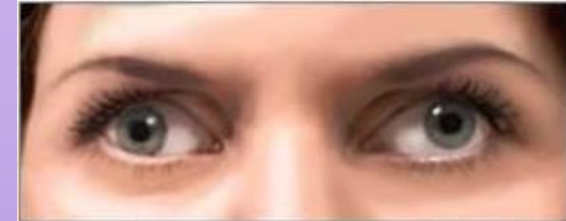- 1-Constrictor pupillae of the iris
- 2-Ciliary muscles.

Main functions

- 1-Elevation of upper eyelid.
- 2-Moving the eye upward, downwards and medially.
- 3-Constricting the pupil.
- 4-Accommodating reflex for near objects.

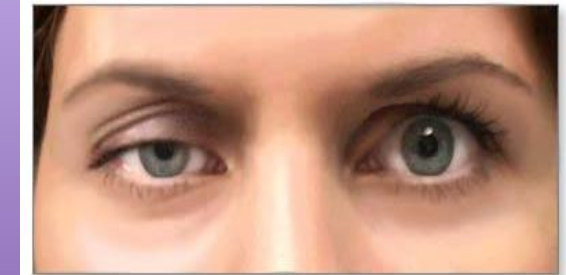

Normal eye alignment



Lateral squint

Ptosis (drooping of the eyelid)



Lesion results in:

- Lateral squint.
- Ptosis.
- Diplopia.
- Pupillary dilatation.
- Loss of accommodation.
- The eye is fully abducted and depressed(down and out) because of the unopposed activity of lateral rectus and superior Oblique.

Nerve lesion

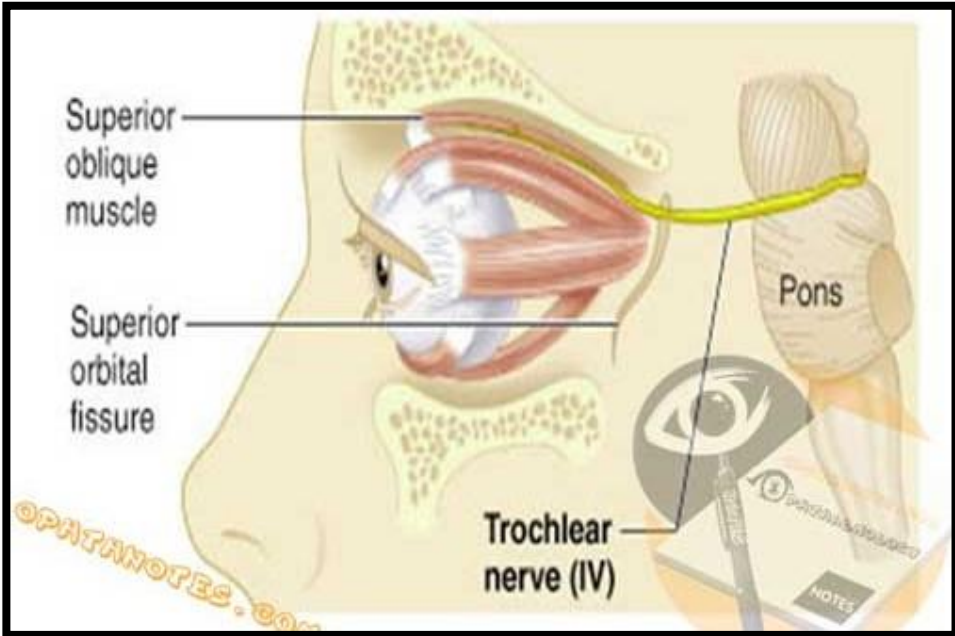
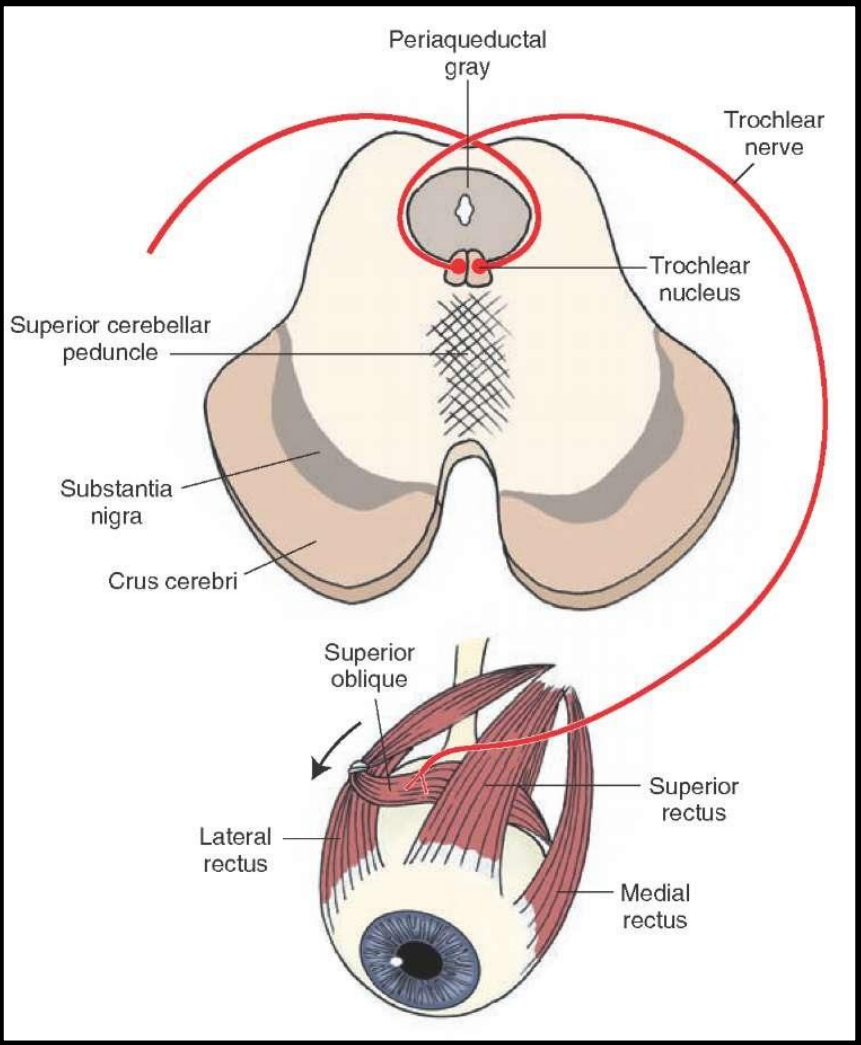
The preganglionic parasympathetic fibers run superficially in the nerve and are therefore the first axons to suffer when a nerve is affected by external pressure. Consequently, the first sign of compression of the oculomotor nerve is ipsilateral slowness of the pupillary response to light.

TROCHLEAR NERVE

Trochlear Nerve (4th Cranial Nerve)

Type : Motor

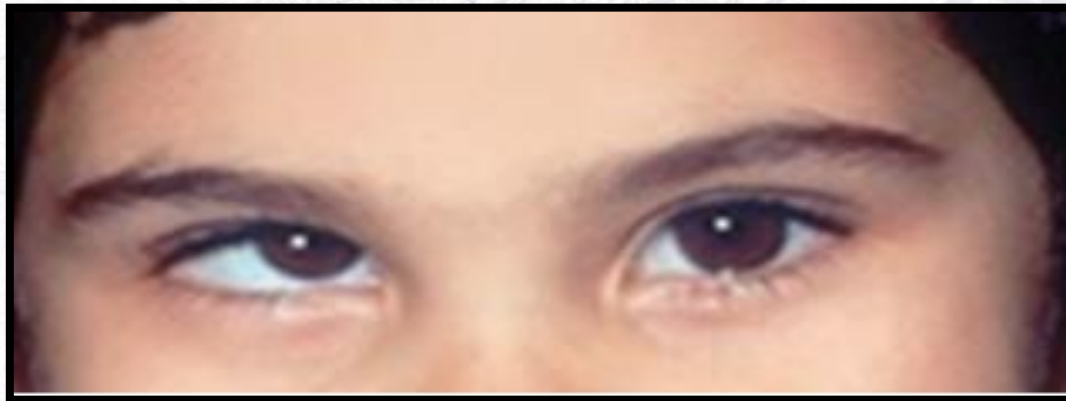Site (nucleus)	<ul style="list-style-type: none">➤ Small motor nucleus located in the periaqueductal grey matter at the level of inferior colliculus.➤ Fibers curve backwards and decussate.
Course	<p>The nerve emerges immediately caudal to the inferior colliculus, on the dorsal surface of brain stem.</p> <ul style="list-style-type: none">➤ It passes forward through middle cranial fossa in the lateral wall of the cavernous sinus.➤ The nerve then enters the orbit through the superior orbital fissure.



It supplies : Superior oblique muscle, (**only one muscle**).

Function ➤ Rotates the eye ball downwards and laterally.

Nerve Lesion ➤ Lesion results in **diplopia** & Inability to rotate the **eye infero-laterally**.
So, the eye deviates; **upward** and slightly **inward**.
➤ This person has difficulty in walking downstairs

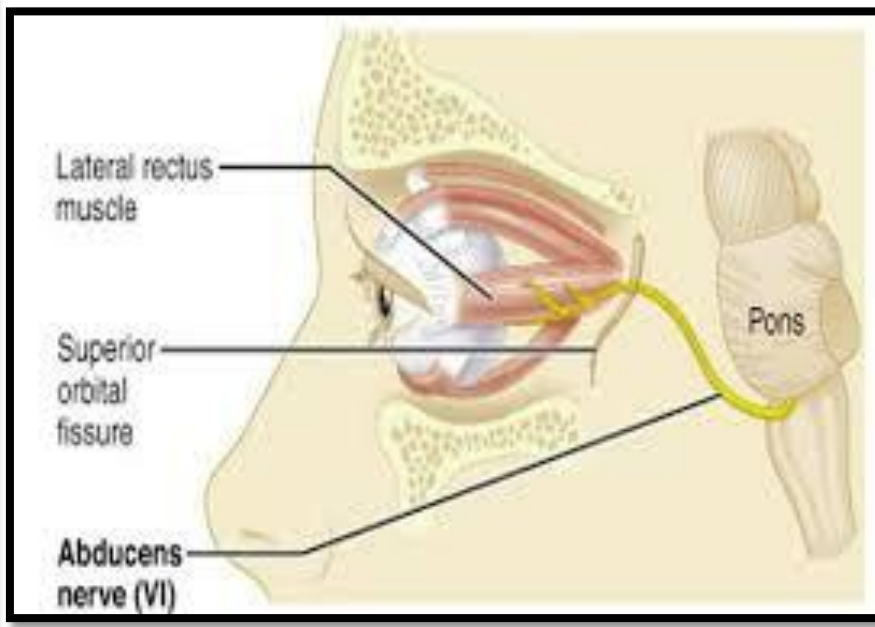
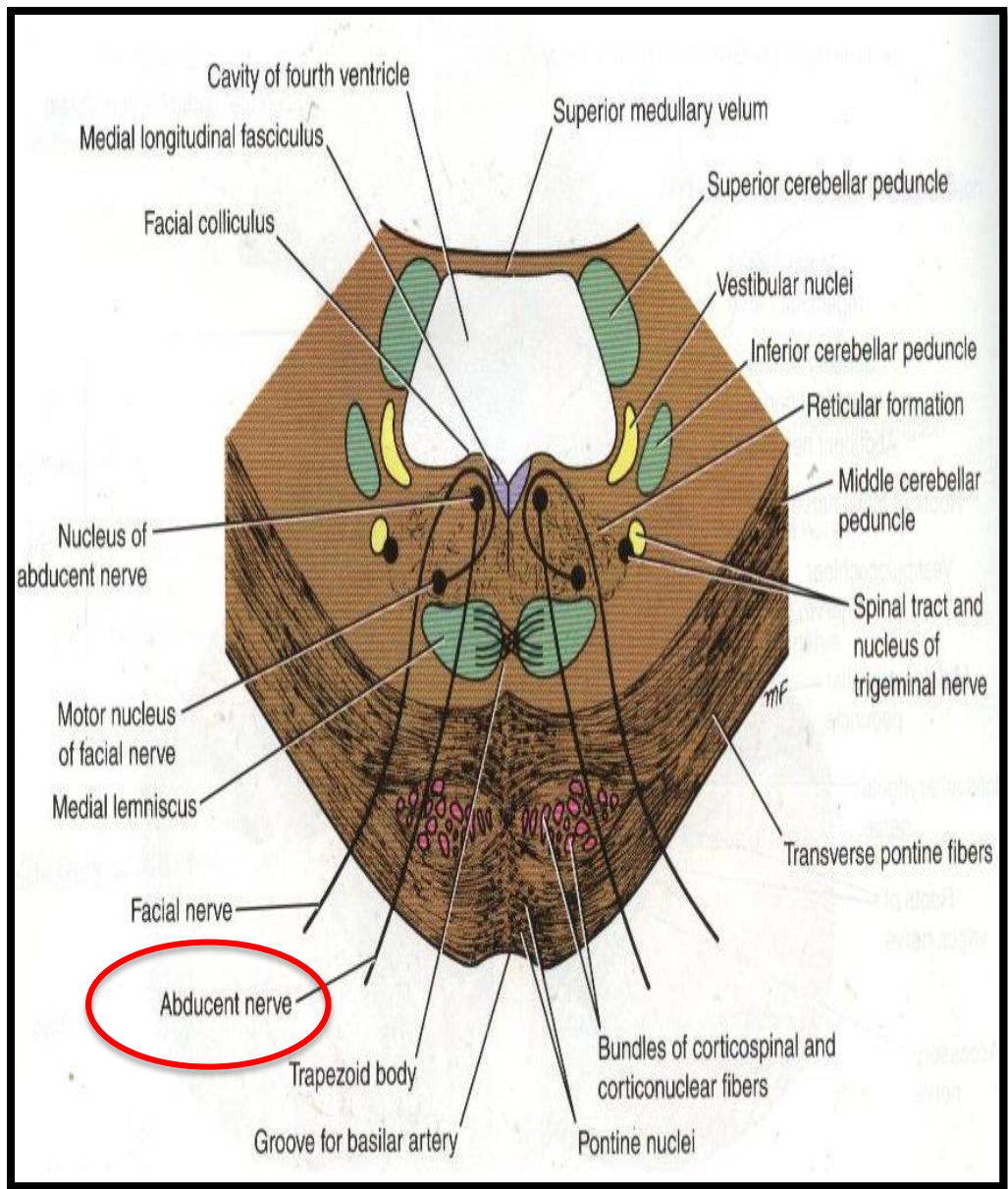


ABDUCCENT NERVE

Abduccent Nerve (6th Cranial Nerve)

Type : Motor (one motor nucleus)

Site (nucleus)	<ul style="list-style-type: none">➤ Lies in caudal pons in the floor of the 4th ventricle.➤ Lies close to the middle line, in a line with 3rd, 4th & 12th nerves.➤ It forms the facial colliculus with the fibers of facial nerve looping around the nucleus.
Origin	<ul style="list-style-type: none">➤ It emerges from the ventral aspect, at the junction of the pons and the pyramid of the medulla oblongata.
Course	<ul style="list-style-type: none">➤ It passes through cavernous sinus, lying below and lateral to the internal carotid artery➤ Then it enters the orbit through the superior orbital fissure.



It supplies : the lateral rectus muscle.

Function

- Rotates the eye ball laterally ; (**abduction**).

Nerve Lesion

- Inability to direct the affected eye laterally, so it result in (**medial squint**).
- A nuclear lesion may also involve the nearby nucleus or axons of the **facial nerve**, causing **paralysis of all facial muscles in the ipsilateral side**.



Medial squint

QUESTIONS

Q1 : lesion in the abducent nerve result in ?

- A- Diplopia
- B- Medial squint.
- C- Difficulty in walking downstairs

Q2 : Which muscle is supplying by the trochlear nerve ?

- A- the lateral rectus muscle.
- B- Levator palpebrae superioris.
- C- Superior oblique muscle.

Q3 : At which level can we find the trochlear nucleus?

- A- Inferior colliculus.
- B- Superior colliculus
- C- Lateral geniculate nucleus.

Answers :

Q1 : B

Q2 : C

Q3 : A

RETINITIS PIGMENTOSA

Retinitis pigmentosa is an inherited metabolic disorder of the photoreceptor and retinal pigment epithelial cells.

It is due to mutation of a key protein in the retinal photoreceptors.

There is:

- **Progressive night blindness**
- **Peripheral visual field constriction**
- **Pigmentation of the retina visible on ophthalmoscopy.**



Which protein?

Rhodopsin

Which type of photoreceptor is affected?

Rods

**Click the link to see
how to examines these
nerves.**

<https://www.youtube.com/watch?v=TsPrNDCUH0c>