

بِسْمِ اللَّهِ الرَّحْمَنِ الرَّحِيمِ



Gastrointestinal Physiology *(Lecture 9)*

Causes and Pathogenesis of *Jaundice*



Dr. Hayam Gad

Associate Professor of Physiology



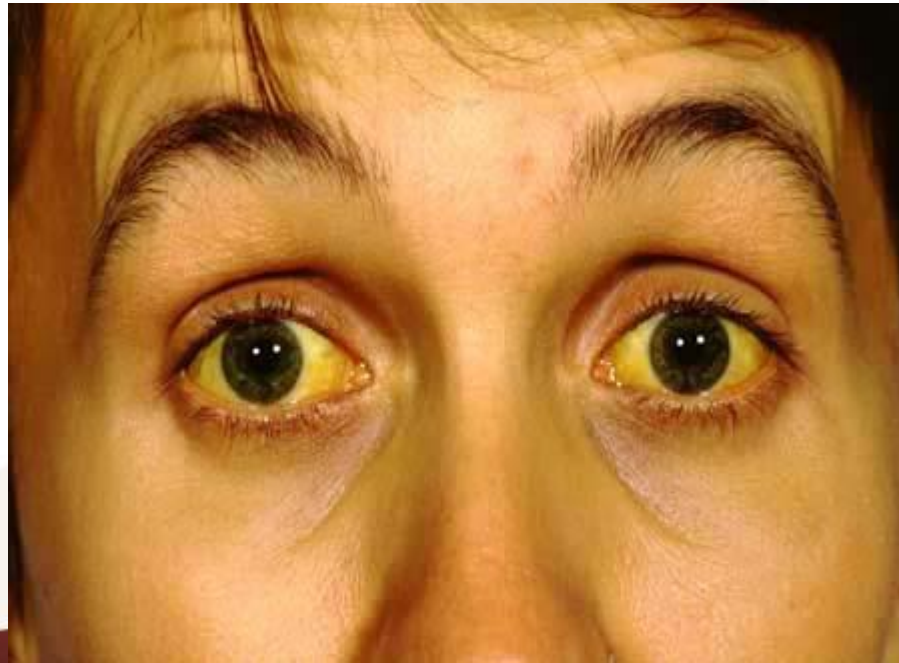Learning Objectives

- ✦ Definition of Jaundice
- ✦ The normal plasma concentration of total bilirubin
- ✦ Classification of jaundice
 - Prehepatic (hemolytic) jaundice
 - Hepatic (hepatocellular) jaundice
 - Poshepatic (obstructive) jaundice
- ✦ Neonatal Jaundice



Hyperbilirubinemia (Jaundice, Icterus)

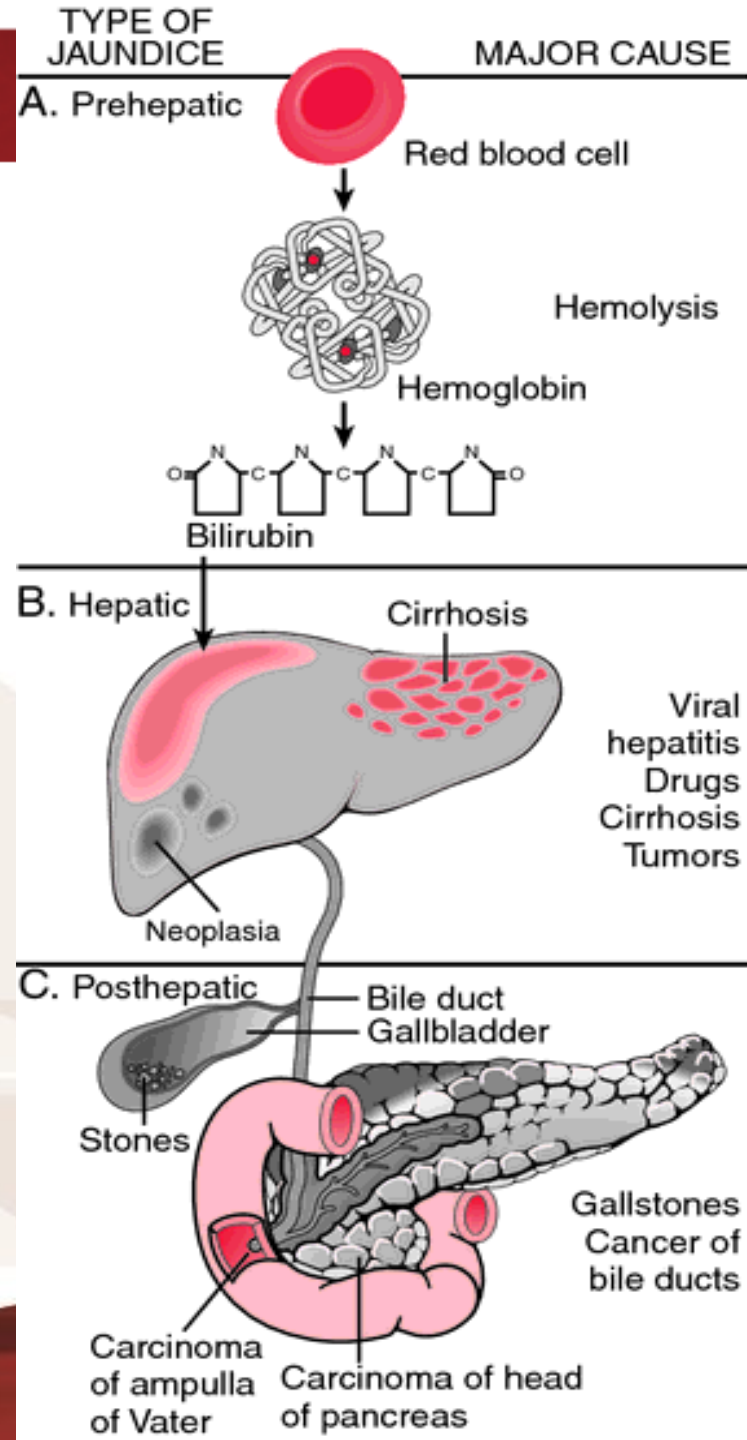
- ❁ It is the yellow coloration of the skin, sclera, mucous membranes and deep tissues
- ❁ The usual cause is large quantities of bilirubin in the ECF, either free or conjugated bilirubin.



- ✿ The normal plasma concentration of total bilirubin is **0.5 mg/dl**.
- ✿ However, in certain abnormal conditions this can rise up to 40 mg/dl.
- ✿ The skin usually begins to appear jaundiced when the concentration of total bilirubin in the plasma is greater than 2 mg/dl (34 $\mu\text{mol/l}$).
- ✿ Bilirubin level from **0.5 to 2 mg/dl** is subclinical jaundice.

Classification of jaundice

- ♠ Prehepatic (hemolytic) jaundice
- ♠ Hepatic (hepatocellular) jaundice
- ♠ Posthepatic (obstructive) jaundice





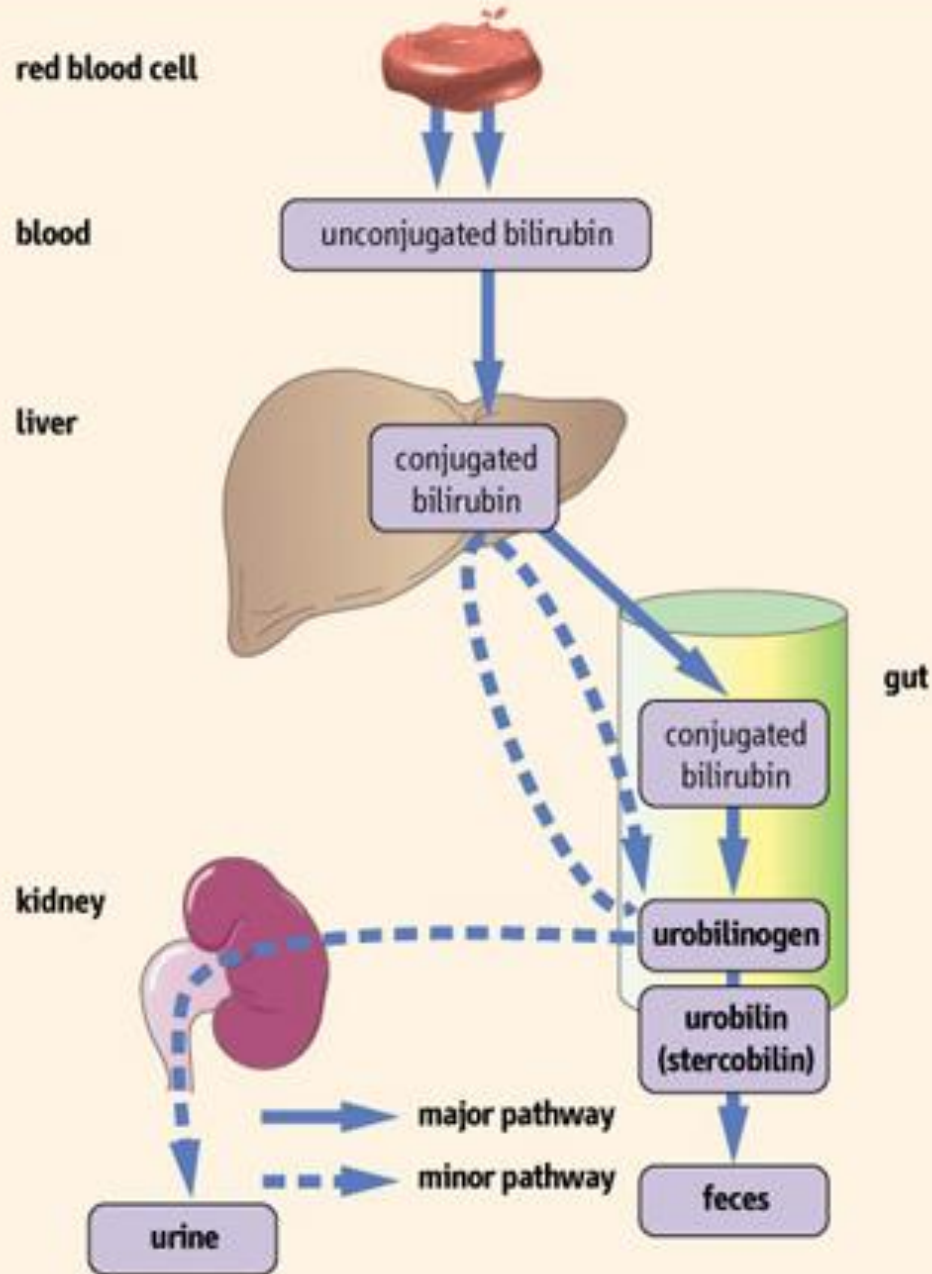
Prehepatic (hemolytic) jaundice

- ♠ In hemolytic jaundice, the excretory function of the liver is not impaired.
- ♠ It results from excess production of bilirubin (beyond the liver's ability to conjugate it) following hemolysis.
- ♠ Excess RBC lysis is commonly the result of:
 - Autoimmune disease
 - Hemolytic disease of the newborn
 - Rh- or ABO- incompatibility
 - Structurally abnormal RBCs (Sickle cell disease)
 - Breakdown of extravasated blood

Prehepatic (hemolytic) jaundice

- ♠ Therefore the plasma concentrations of free bilirubin (hemobilirubin) rises to levels much above normal but it is not filtered through the kidney.
- ♠ The urine is free from bilirubin (acholuric jaundice).
- ♠ Van der Bergh reaction is *indirect*.
- ♠ The stools appear darker than the normal color due to excessive stercobilin formation.

Prehepatic (hemolytic) jaundice





Hepatic (hepatocellular) jaundice

- ◆ Hyperbilirubinemia may be due to:
 - ☐ Impaired uptake of bilirubin into hepatic cells.
 - ☐ Disturbed intra cellular protein binding or conjugation.
 - ☐ Disturbed active secretion of bilirubin into bile canaliculi.
- ◆ The causes may be due to:
 - * Damage of liver cells e.g., viral hepatitis, drugs, chemical, alcohol, or toxins.
 - * Autoimmune hepatitis.
 - * Genetic errors in bilirubin metabolism.
 - * Genetic errors in specific proteins.

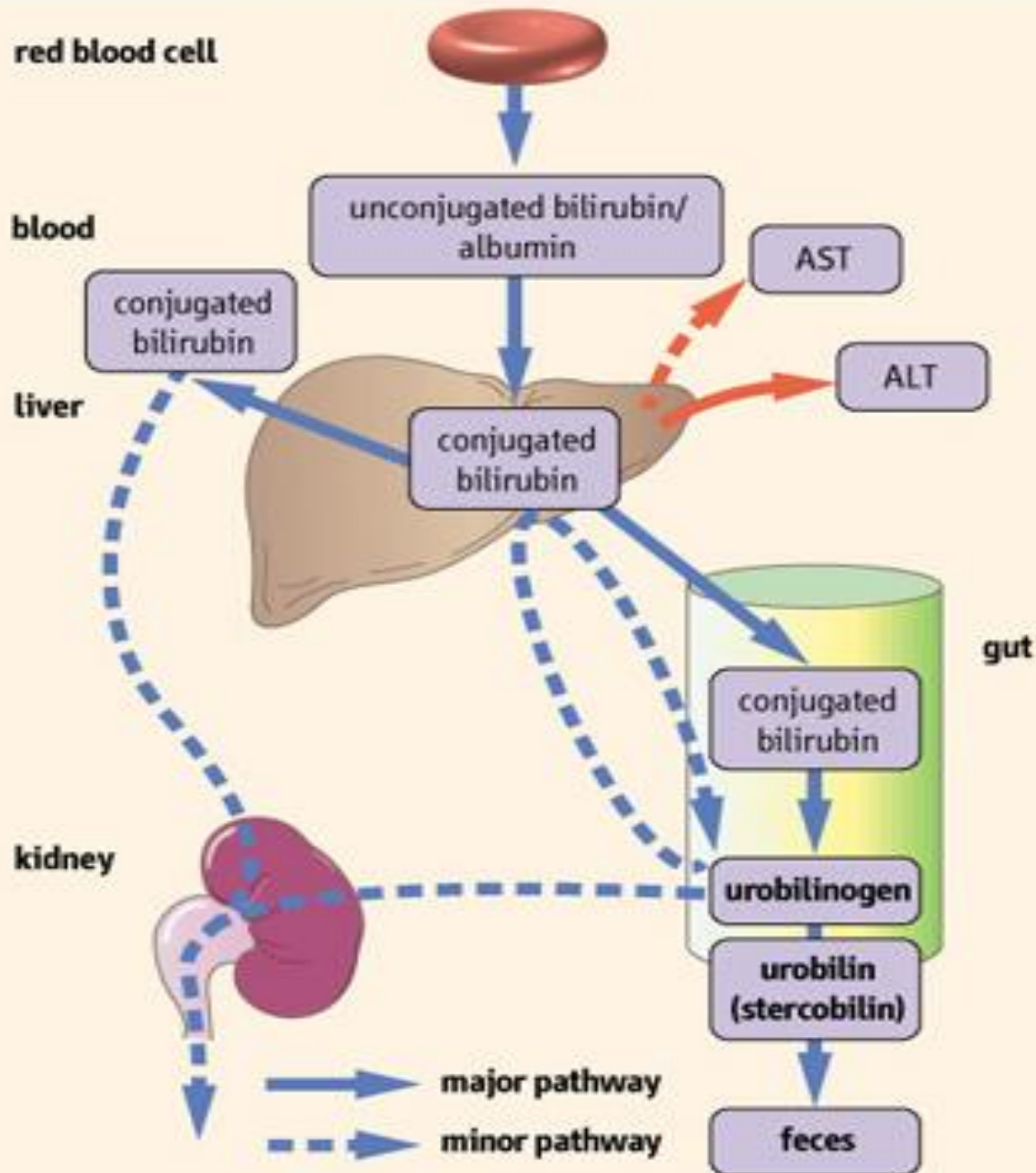
Hepatic (hepatocellular) jaundice

- ◆ The diseased liver cells are unable to take all the unconjugated hemobilirubin formed, increasing its concentration in the blood.
- ◆ Also, there is intrahepatic biliary duct obstruction that leads to regurgitation of conjugated bilirubin to blood.
- ◆ Both types of bilirubin (conjugated & unconjugated) are present in blood in high concentration.
- ◆ Van den Bergh reaction is *biphasic*.

Hepatic (hepatocellular) jaundice

- ◆ Stools appear pale grayish in color due to deficiency of stercobilin.
- ◆ Urine appears dark brown due to filtration of excess conjugated bilirubin through the kidney.
- ◆ In this case, hyperbilirubinemia is usually accompanied by other abnormalities in biochemical markers of liver function:
 1. Alanine aminotransferase (ALT), serum glutamic pyruvic transaminase (SGPT)
 2. Aspartate aminotransferase (AST), serum glutamic oxaloacetic transaminase (SGOT).

Intrahepatic jaundice





Posthepatic (obstructive) jaundice

Caused by an obstruction of the biliary tree:

1- Intrahepatic bile duct obstruction e.g

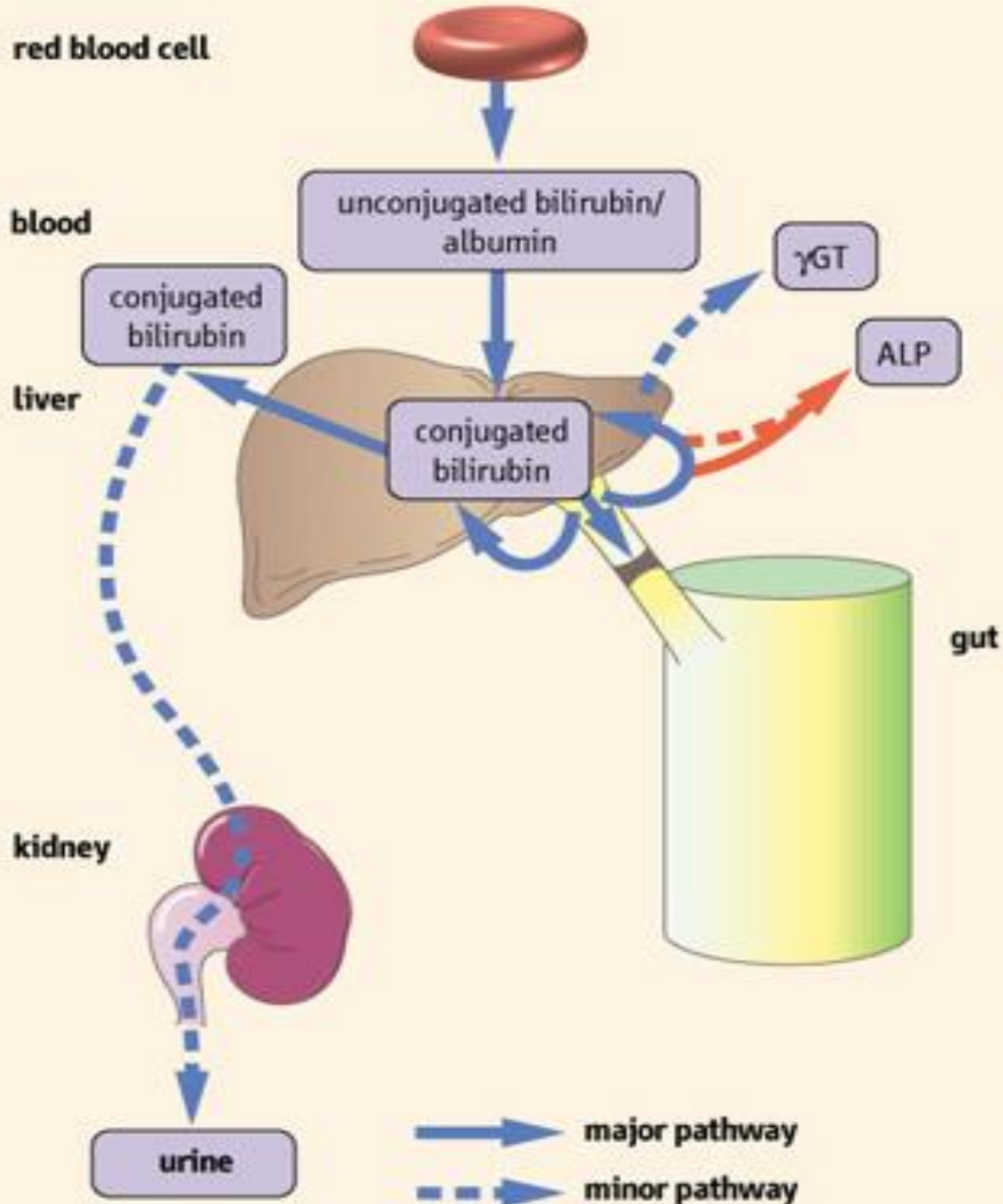
- * Drugs
- * Primary biliary cirrhosis
- * Cholangitis.

2- Extrahepatic bile duct obstruction e.g

- * Gall stones.
- * Cancer head pancreas.
- * Cholangiocarcinoma.

- ♠ The rate of bilirubin formation is normal.
- ♠ Bilirubin enters the liver cells and become conjugated in the usual way.
- ♠ The conjugated bilirubin formed simply cannot pass into small intestine and it returns back into blood.
- ♠ Van den Bergh reaction is direct.
- ♠ In this type of jaundice, conjugated bilirubin is filtered through the kidney and appears in urine giving it dark brown (liquorice) color.
- ♠ Urine is free from urobilinogen.
- ♠ Stools are clay color due to absence of stercobilin.

Posthepatic jaundice



The causes of jaundice

Type	Cause	Clinical example	Frequency
Prehepatic	hemolysis	autoimmune abnormal hemoglobin	uncommon depends on region
intrahepatic	infection	hepatitis A, B, C	common/very common
	chemical/drug	acetaminophen alcohol	common common
	genetic errors: bilirubin metabolism	Gilbert's syndrome Crigler–Najjar syndrome Dubin–Johnson syndrome Rotor's syndrome	1 in 20 very rare very rare very rare
	genetic errors: specific proteins	Wilson's disease α_1 antitrypsin	1 in 200 000 1 in 1000 with genotype
	autoimmune	chronic active hepatitis	uncommon/ rare
	neonatal	physiologic	very common
Posthepatic	intrahepatic bile ducts	drugs primary biliary cirrhosis cholangitis	common uncommon common
	extrahepatic bile ducts	gall stones pancreatic tumor cholangiocarcinoma	very common uncommon rare

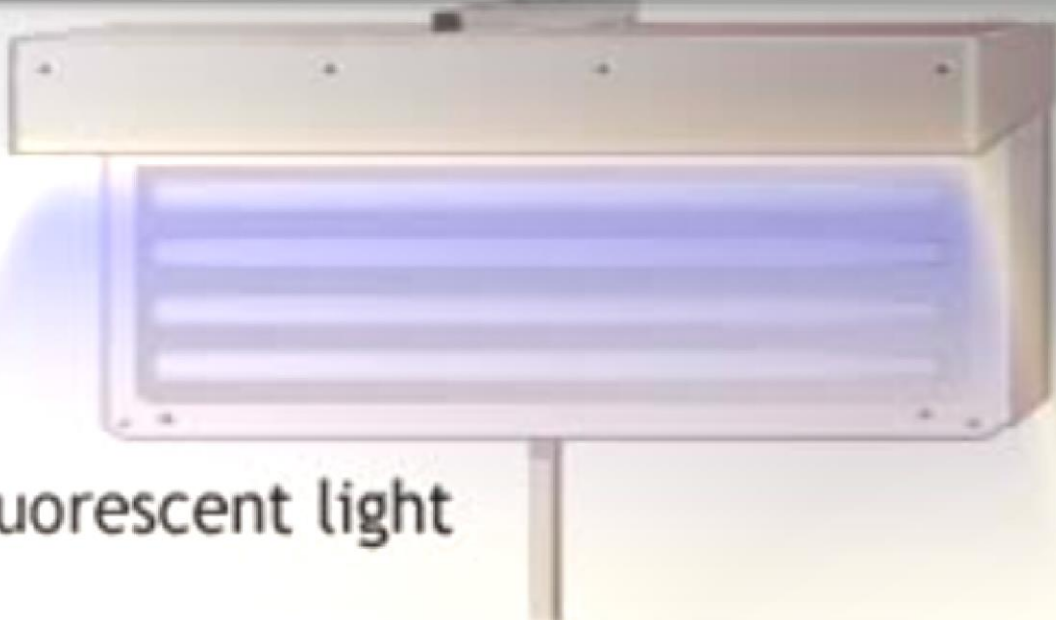
	Prehepatic hemolytic	Hepatic Hepatocellular	Posthepatic Obstructive
Unconjugated	↑	↑	Normal
Conjugated	Normal	↑	↑
VDB	Indirect	Biphasic	Direct
AST & ALT	Normal	↑	Normal
ALP & γ GT <small>(γ glutamyl transpeptidase)</small>	Normal	Normal	↑
Urine bilirubin	Absent	Present (dark brown)	Present (liquorice)
Urine urobilinogen	Present	Present	Absent
Stercobilin	↑ Darker	↓ Pale grayish	Absent (Clay Color)

Neonatal Jaundice

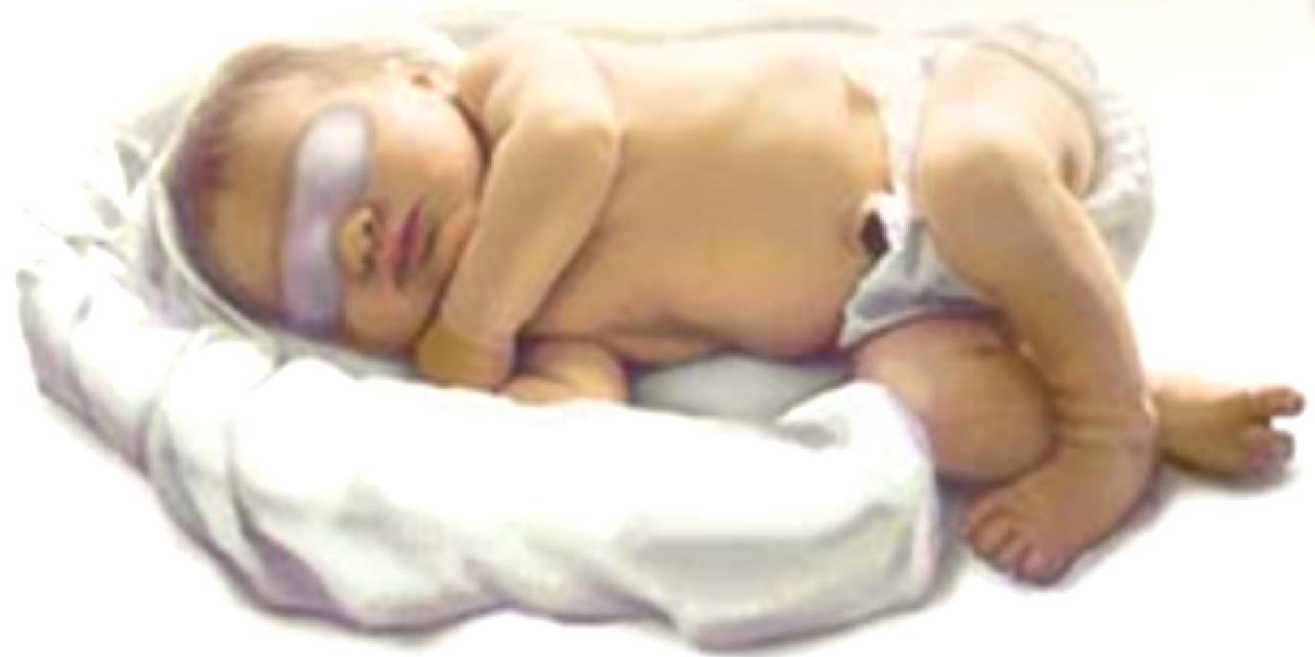- ❖ Common, particularly in premature infants
- ❖ Transient (resolves in the first 10 days)
- ❖ Due to immaturity of the enzymes involved in bilirubin conjugation
- ❖ Due to its hydrophobicity, unconjugated bilirubin can cross the blood-brain barrier and cause a type of mental retardation known as kernicterus



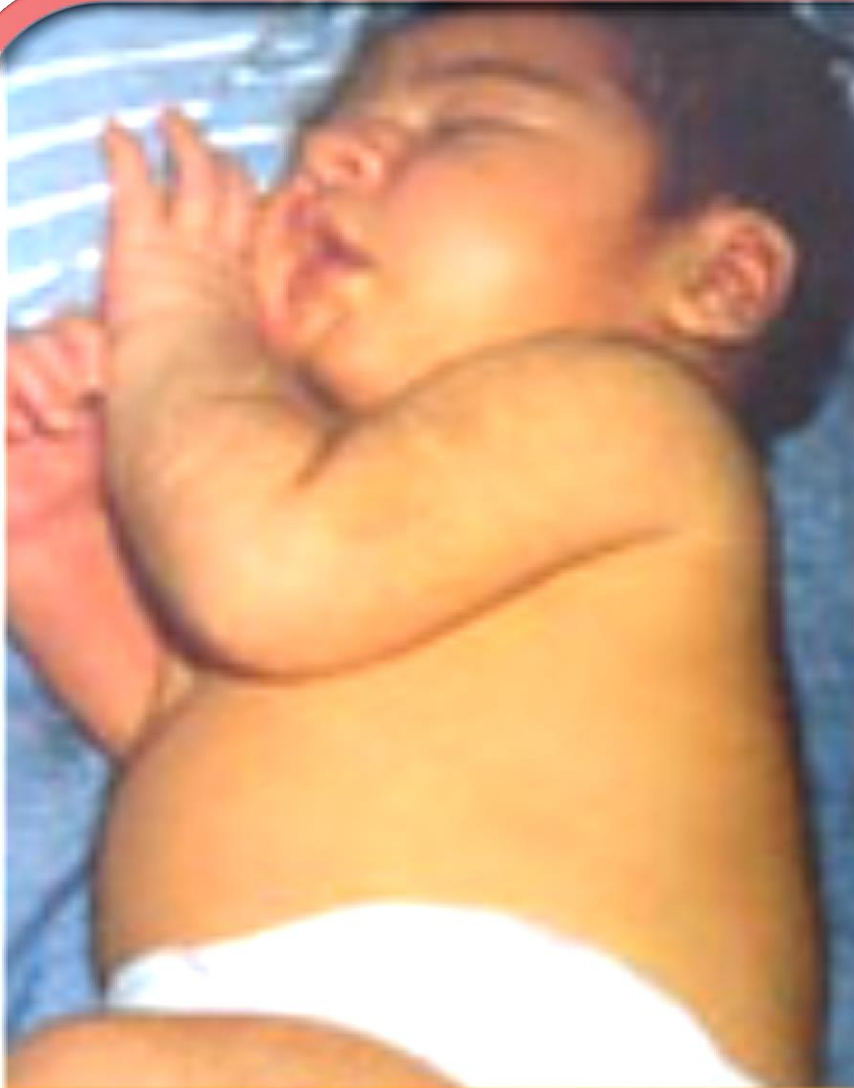- ❖ If bilirubin levels are judged to be too high, then phototherapy with UV light is used to convert it to a water soluble, non-toxic form.
- ❖ If necessary, exchange blood transfusion is used to remove excess bilirubin.
- ❖ Phenobarbital can be administered to the mother prior to an induced labor of a premature infant – crosses the placenta and induces the synthesis of UDP glucuronyl transferase.
- ❖ Jaundice within the first 24 hrs of life or which takes longer than 10 days to resolve is usually pathological, needs to be investigated.



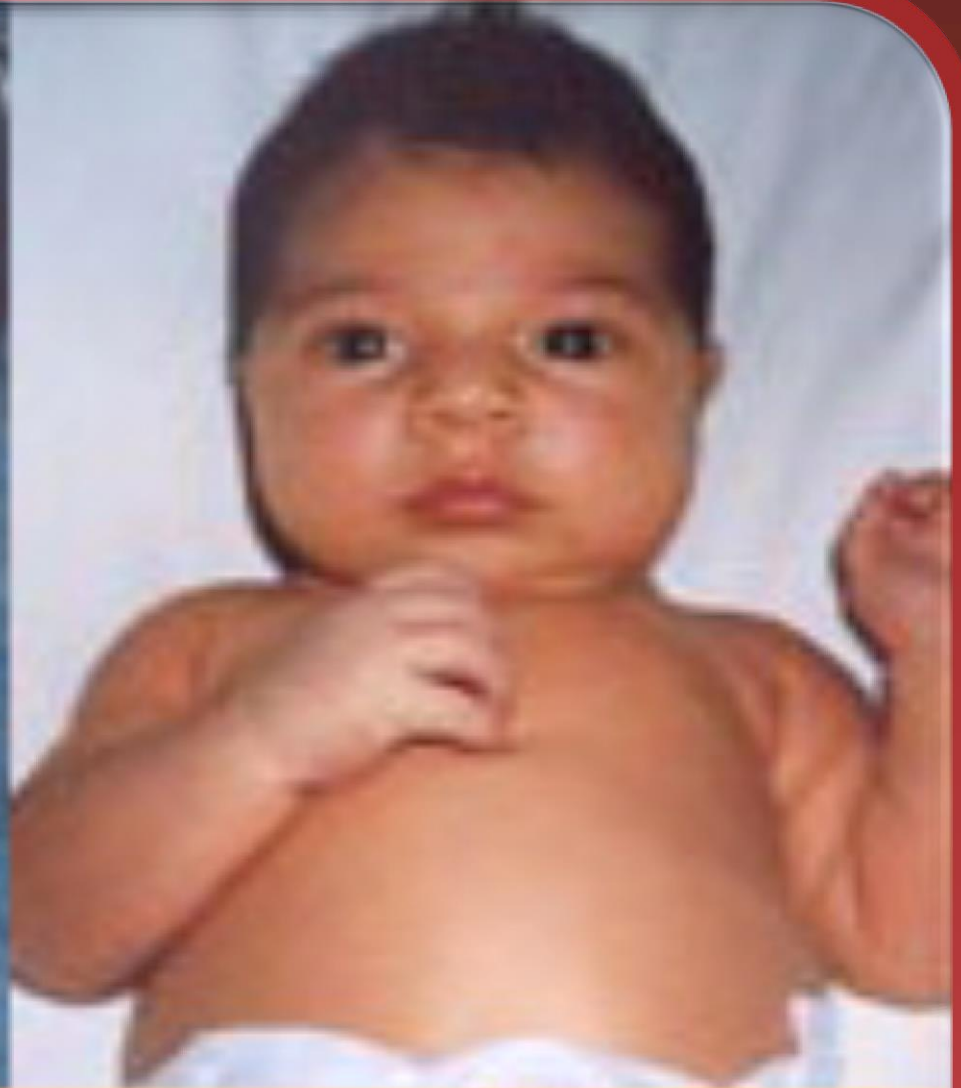Fluorescent light



Baby with mild jaundice



**Before
phototherapy**



**After
phototherapy**



Thank You

The text "Thank You" is rendered in a large, elegant, cursive script. The letters are filled with a deep red color and have a thin, metallic gold outline. The text is surrounded by decorative elements: clusters of vibrant red roses with green leaves are placed around the letters, and two white doves with outstretched wings are positioned above the 'h' and 'y'. The background features a white central area with soft, light-colored curved shapes and a dark red border at the top and bottom.