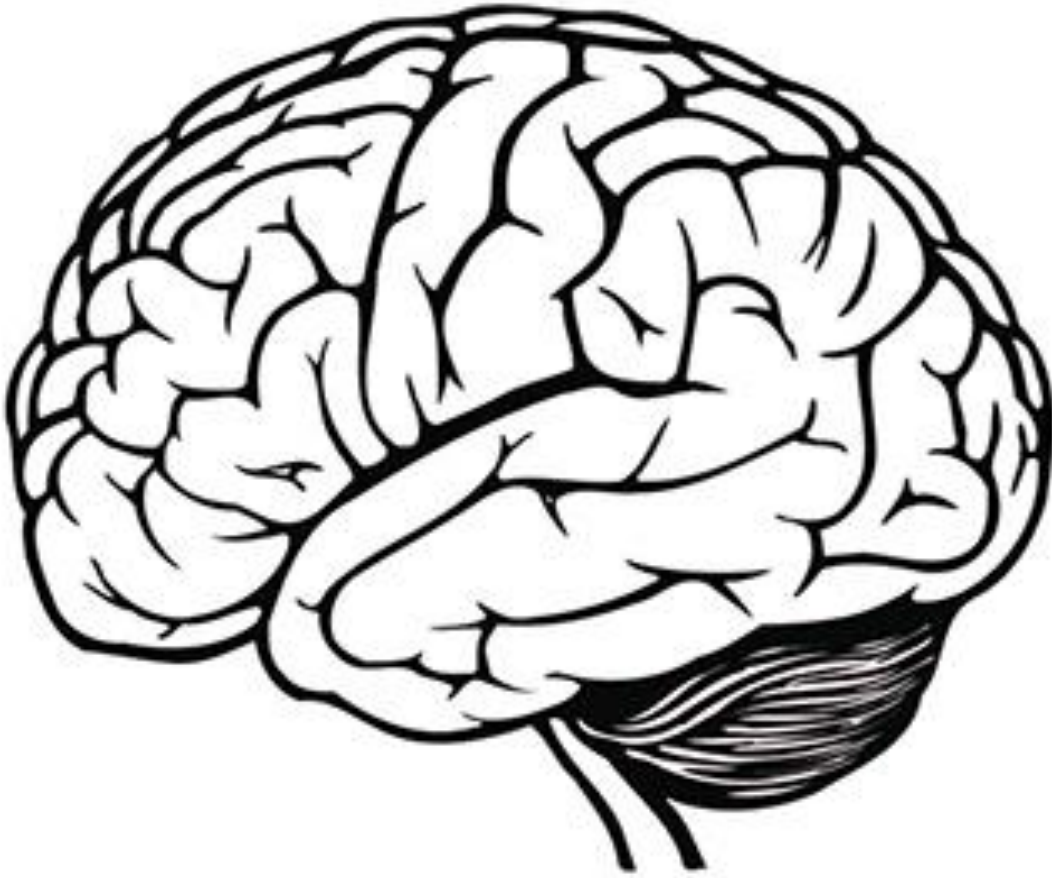

Brachial, lumbosacral plexuses

ملاحظة:

هذا الملف للمراجعة وترتيب المعلومات فقط وليس مرجع للمذاكرة لانه ليست كل المعلومات متضمنة.



Done by:

الهام الغامدي

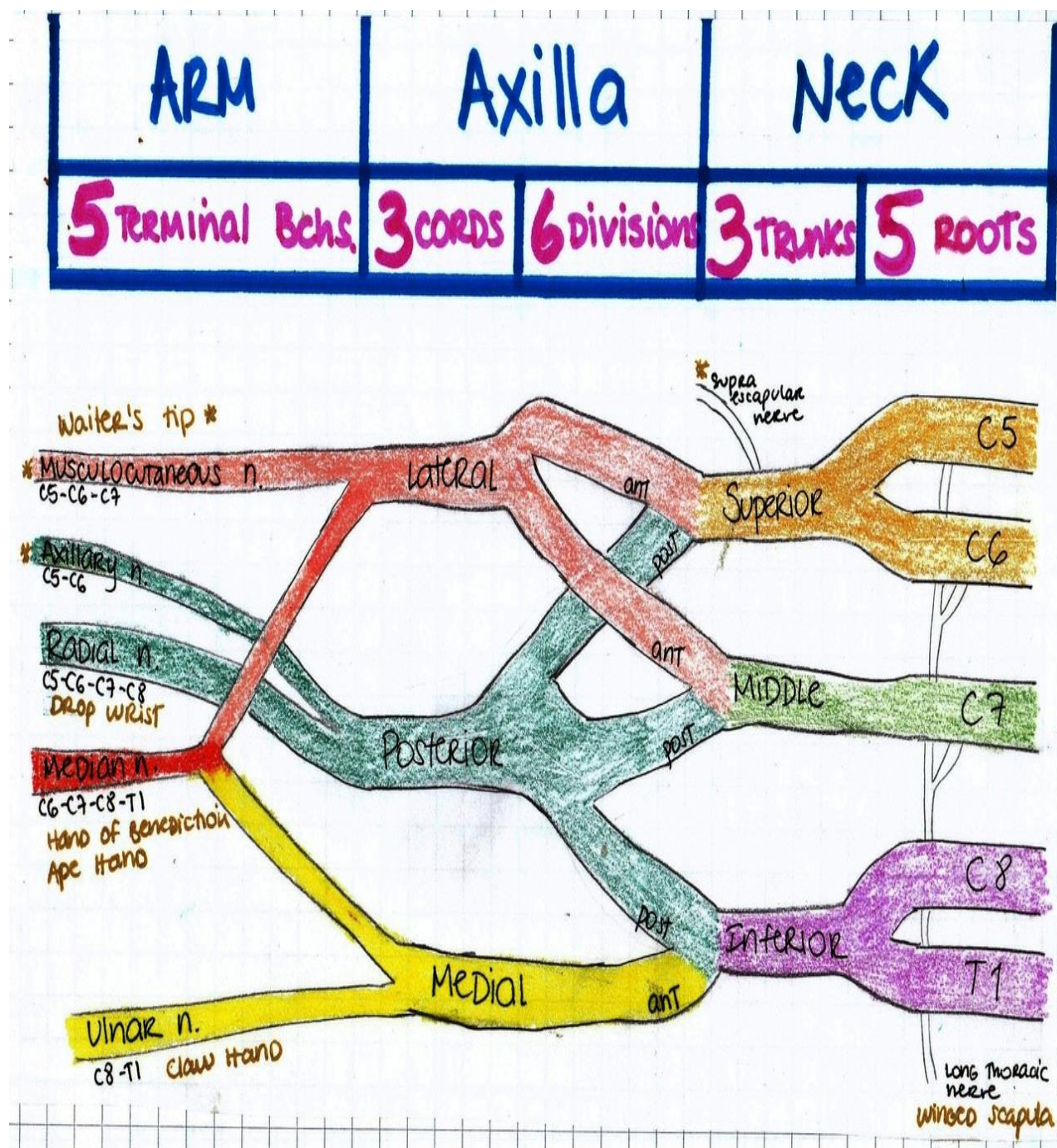
Table by:

نوف المسعود

Plexuses:

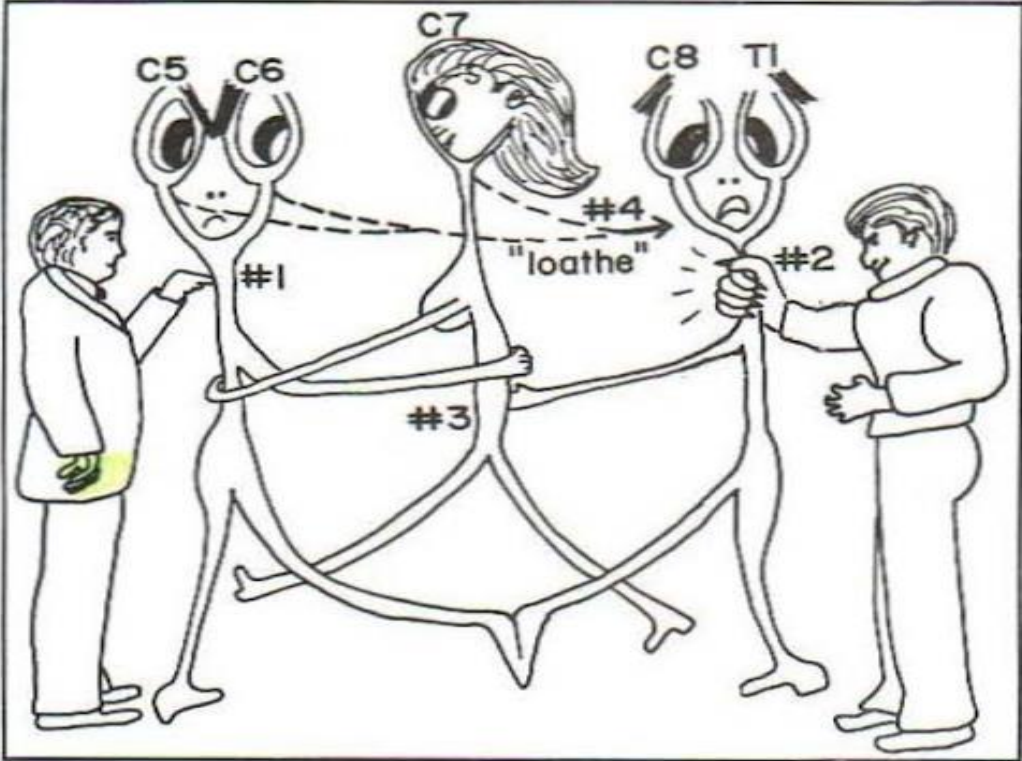
	Brachial	Lumbar	Sacral
	C5, C6, C7, C8 and T1	L1, L2, L3 and L4	L4, L5..., S1, S2, S3 and S4
	Posterior of neck → Behind clavicle → Axilla	Psoas major m.	Piriformis m.
	Read The Details Carefully Roots, Trunks, Divisions Cords		
Branches	<u>From Lateral cord C5,6&7:</u> <ul style="list-style-type: none"> Lateral root to median n. <u>From posterior cord:</u> <ul style="list-style-type: none"> Radial n. Axillary n. <u>From Medial cord C8&T1:</u> <ul style="list-style-type: none"> Medial root to median n. Ulnar n. 	<u>L1:</u> <ul style="list-style-type: none"> Iliohypogastric n. Ilioinguinal n. <u>L2, L3 & L4:</u> <ul style="list-style-type: none"> Obturator n. Femoral n. 	<ul style="list-style-type: none"> Pelvic splanchnic n. Pudendal n. Sciatic n.
Injuries	<u>Of upper trunk C5&C6:</u> <ul style="list-style-type: none"> Walters tip -Erb-Duchenne palsy. <u>Of lower trunk C8&T1:</u> <ul style="list-style-type: none"> Median > Ape Ulnar > Claw 	Femoral n. : <ul style="list-style-type: none"> ✗ Extension of knee ✗ Weak flexion of hip ✗ Wasting of Quadriceps femoris ✗ Antero-medial thigh. ✗ Medial leg. 	-

BRACHIAL PLEXUS:



In this picture you can find all the parts of the Brachial plexus, their locations, the branches originating from each part and their lesions.

Brachial Plexus lesions:



lumbosacral Story:

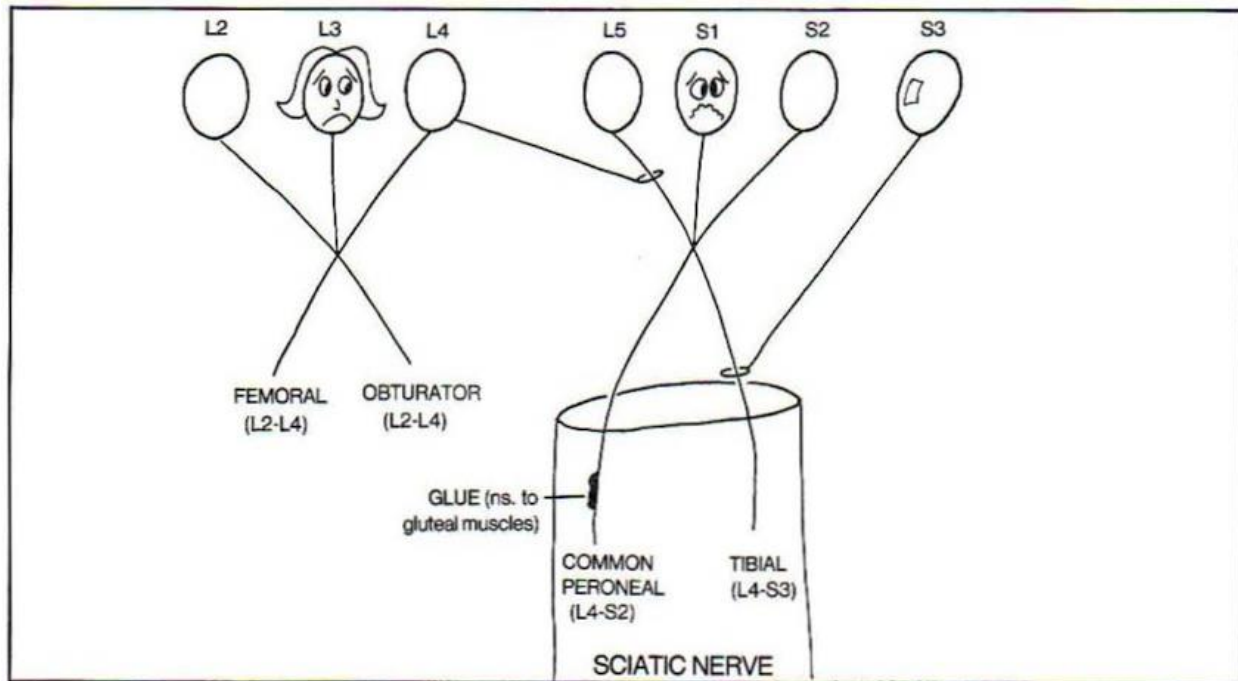


Figure 12-20

The lumbosacral plexus presented as a mad rescue scene. Elsie (L3) is trying to rescue her clumsy boyfriend Slim (S1) from a septic trunk (Sciatic nerve), using a rope and a balloon. What a mess! He has some GLUE (nerve to GLUTEUS muscle) on his leg. She is pregnant - is FEMALE (FEMORAL nerve) and has an OBSTETRIC condition (OBTURATOR nerve)(Slim's fault).
End of story..