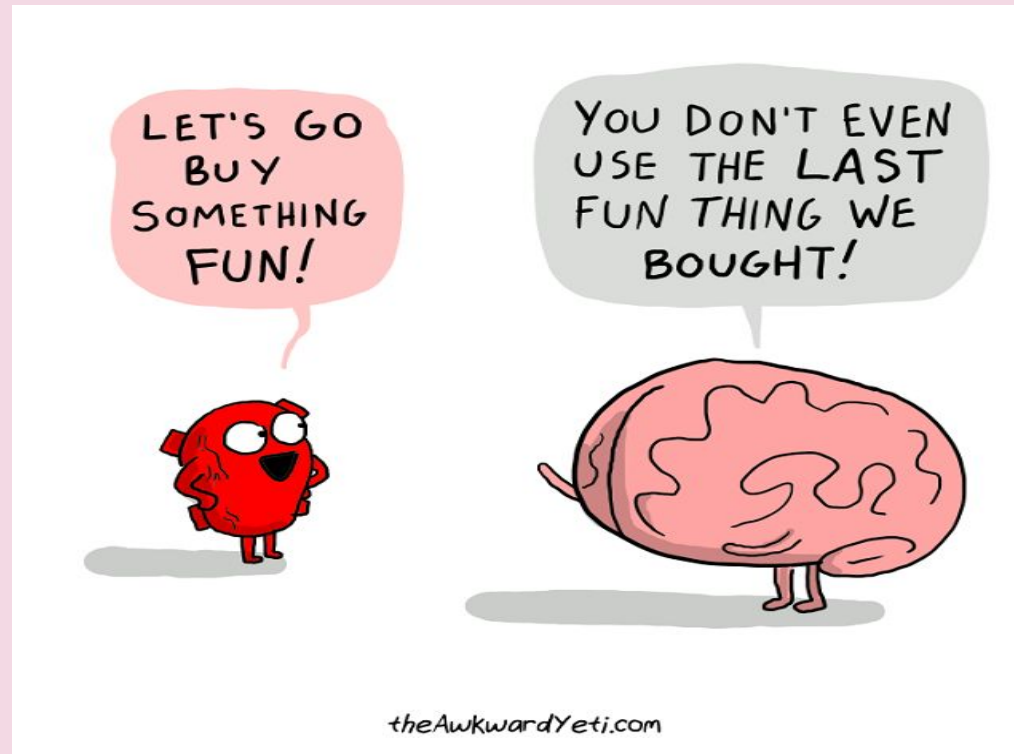




Internal Structure of the BrainStem

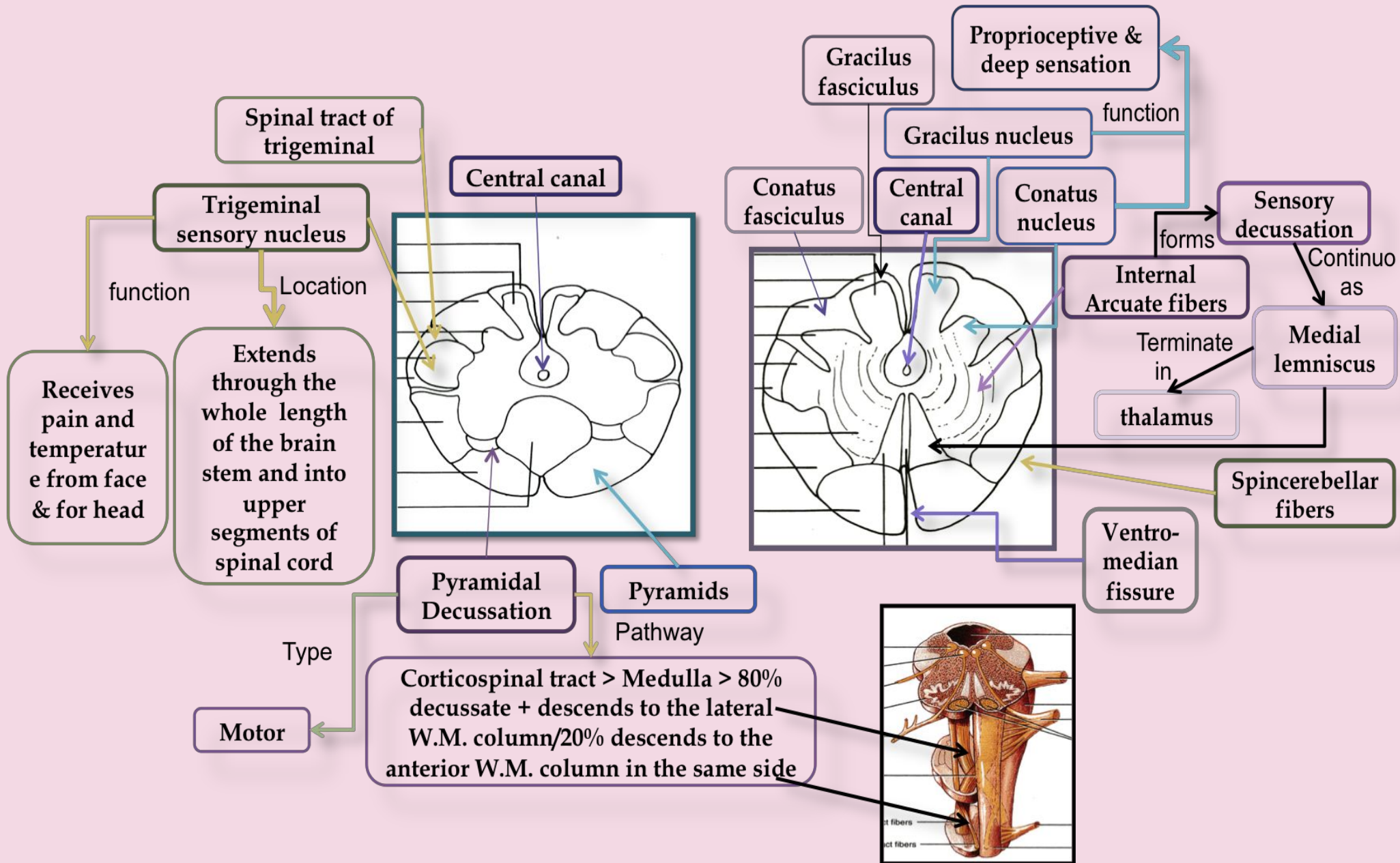


Done By:

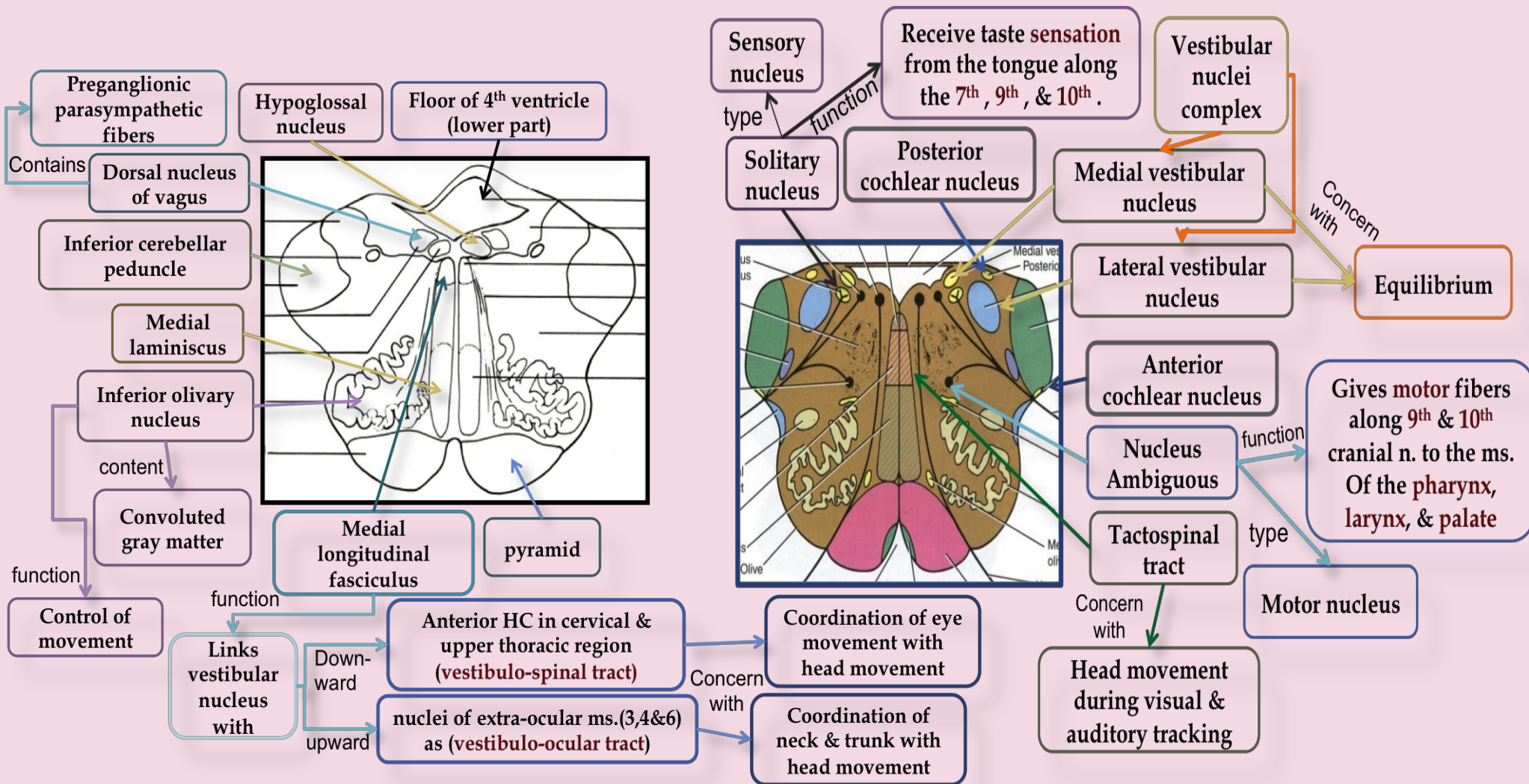
لمياء الذوايدي

CAUDAL MEDULLA

MID MEDULLA

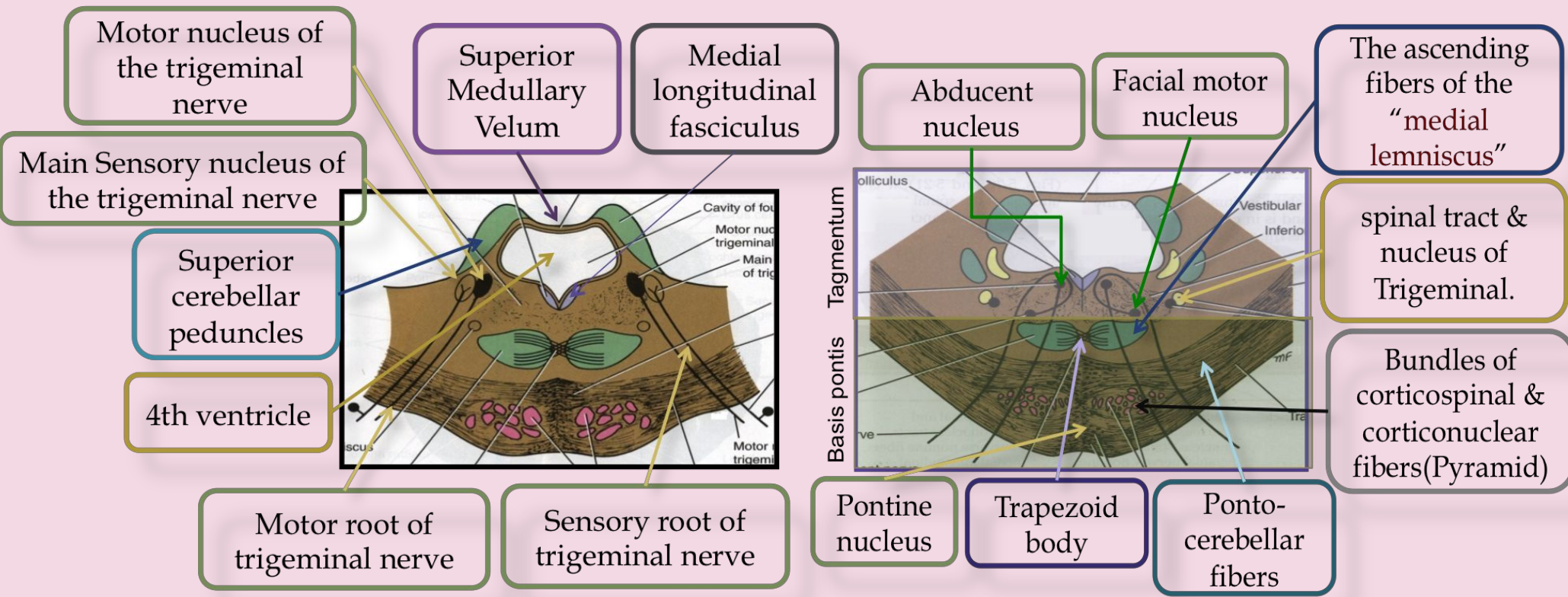


ROSTRAL MEDULLA

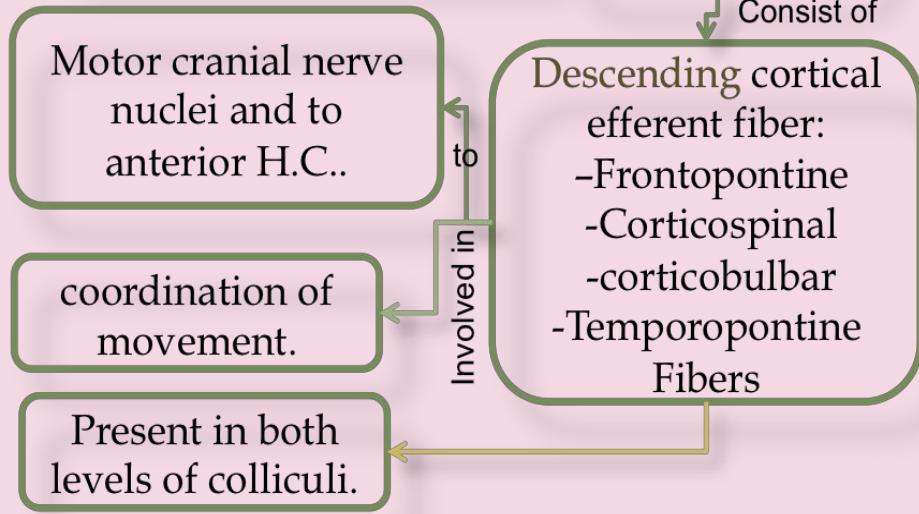
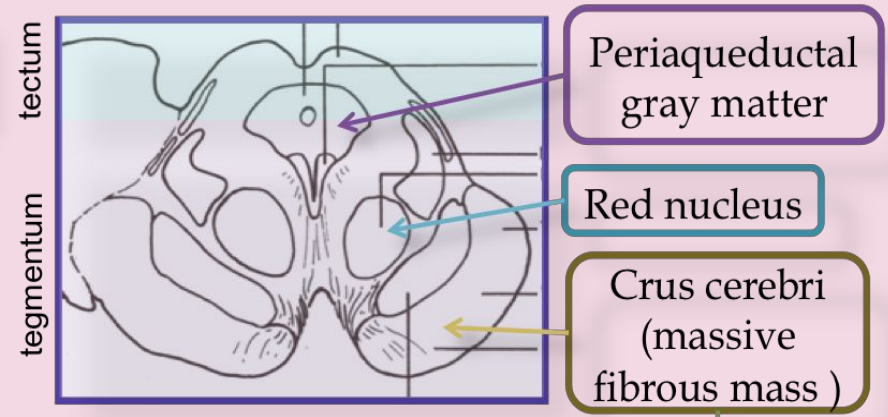
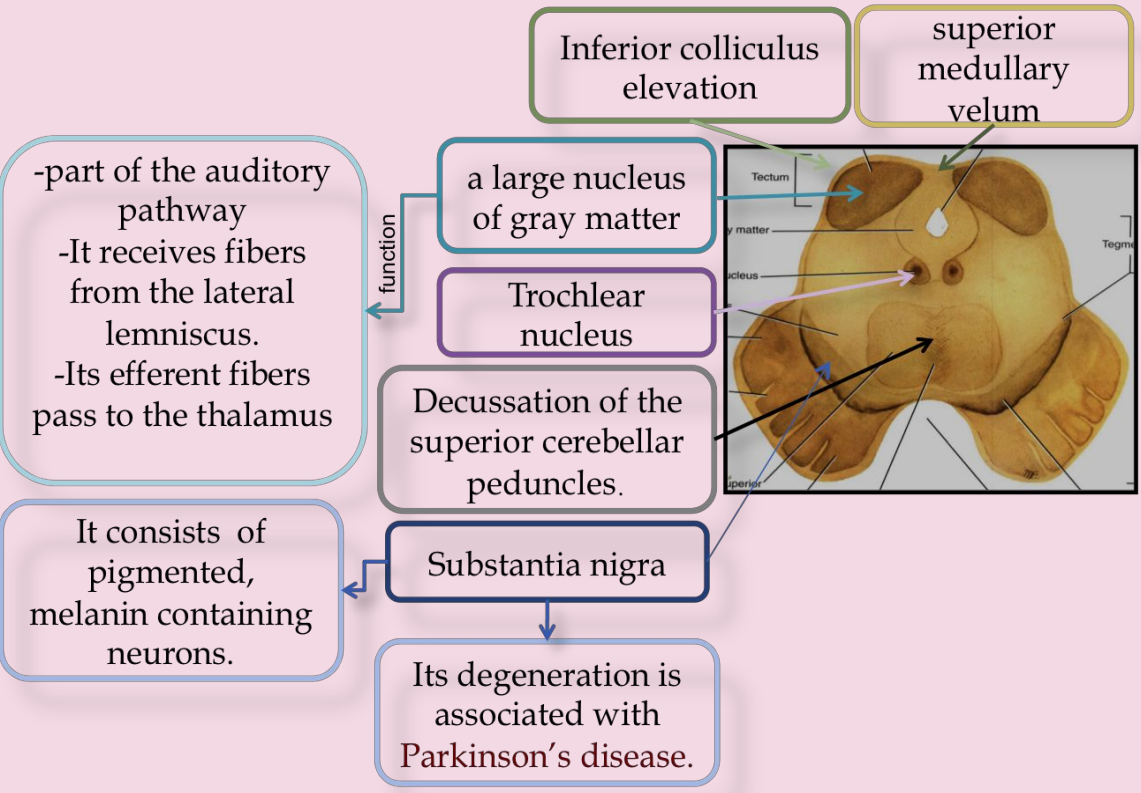


AT THE LEVEL OF THE TRIGEMINAL NERVE

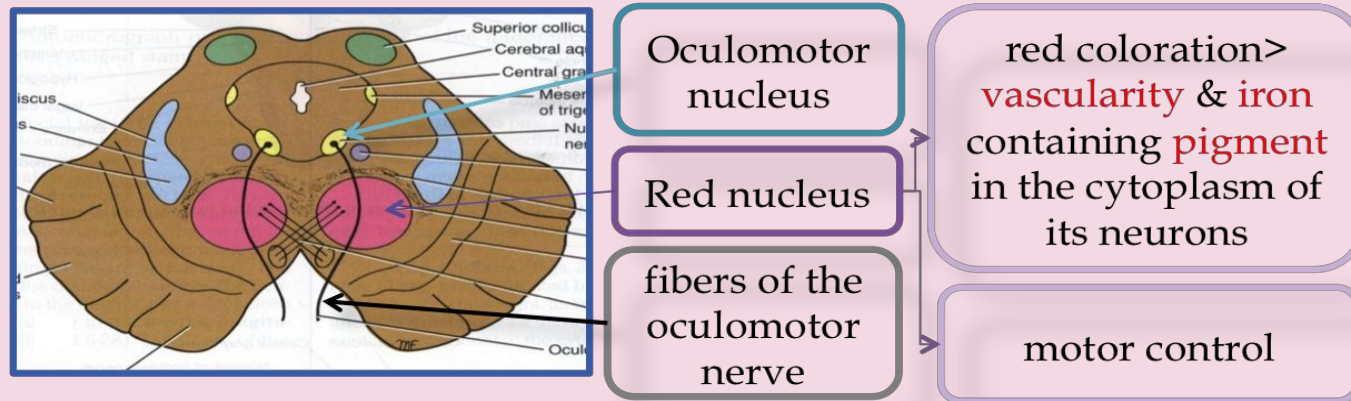
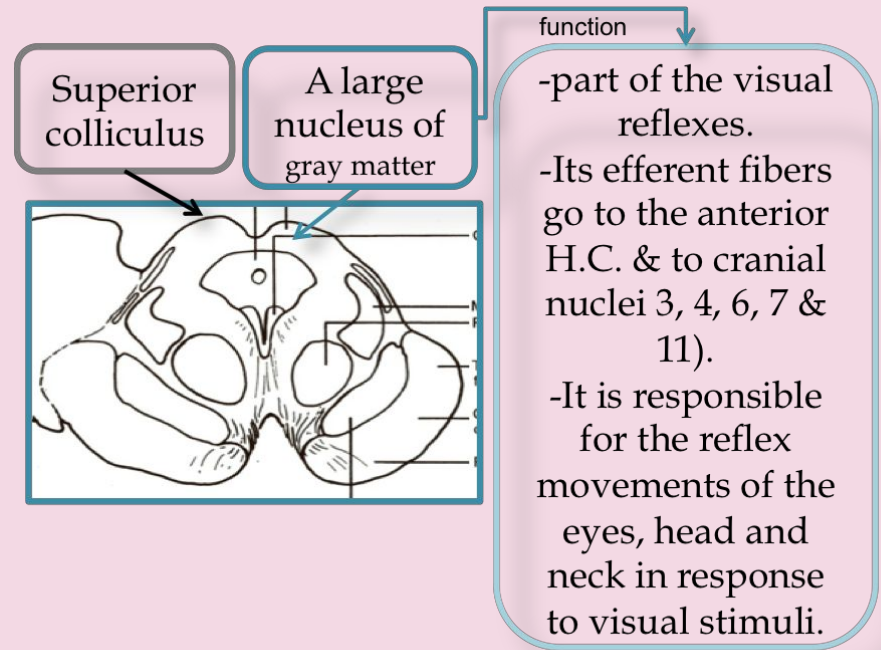
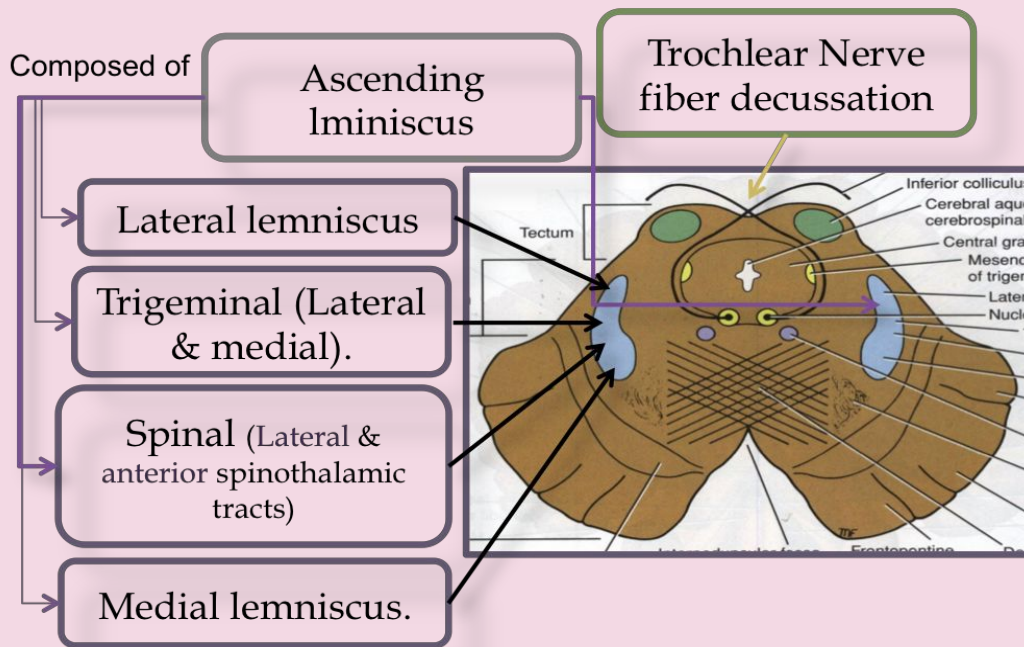
CAUDAL PART OF THE PONS



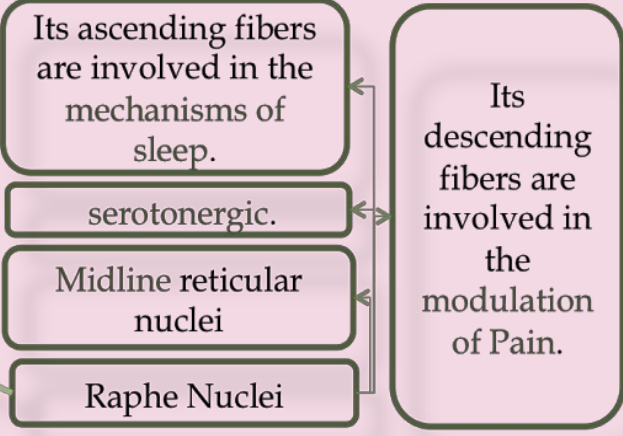
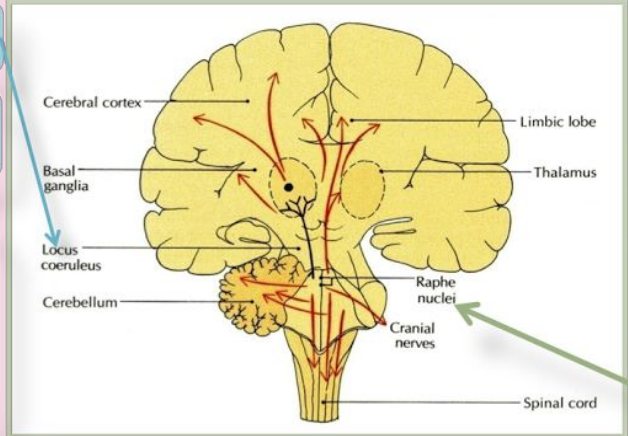
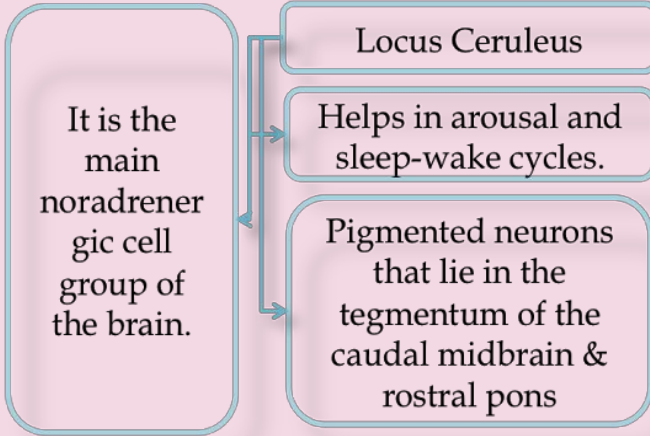
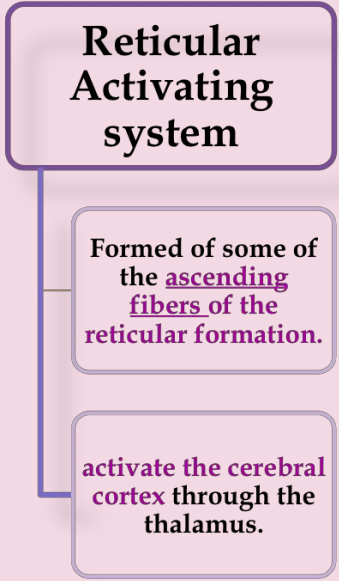
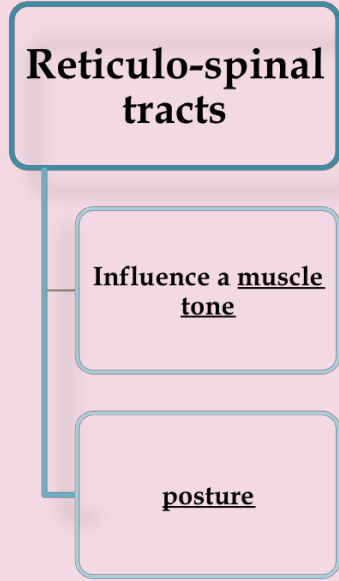
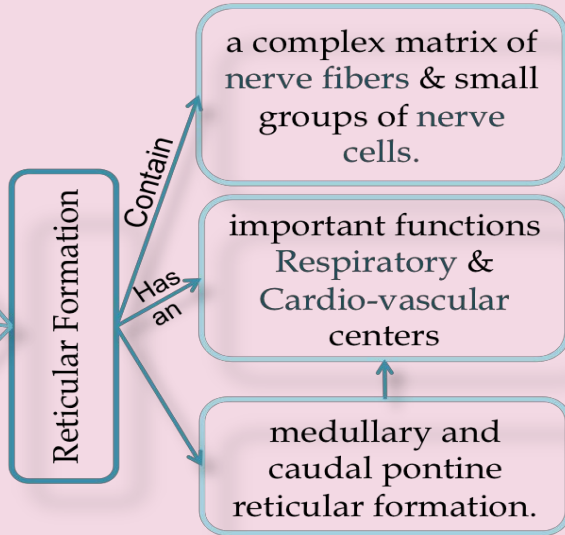
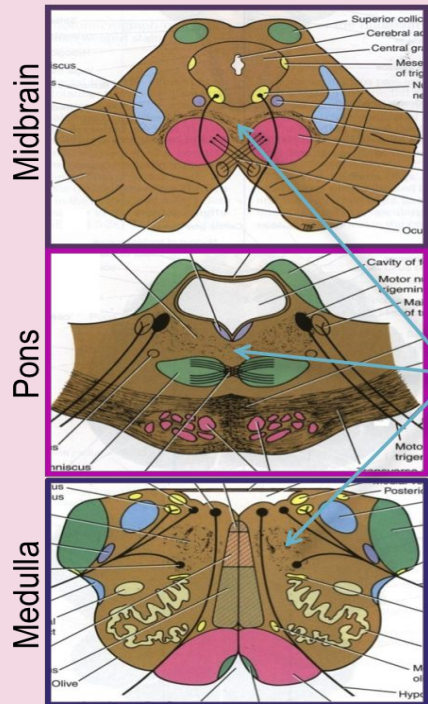
MIDBRAIN INFERIOR COLLICULUS Level



Ascending Lemniscus & SUPERIOR COLLICULUS Level



RETICULAR FORMATION (Tracts & Neurons)



Best Wishes ^ _ *