

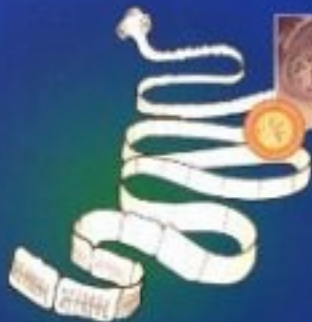
Fourth edition



Atlas of



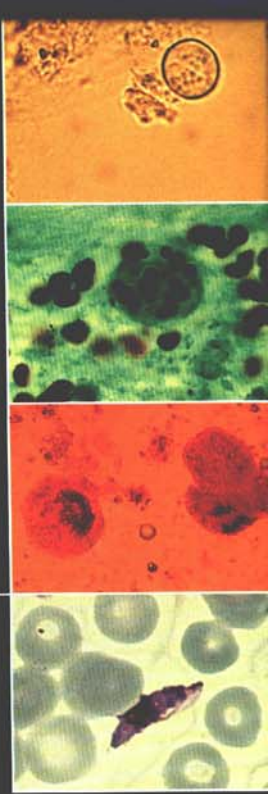
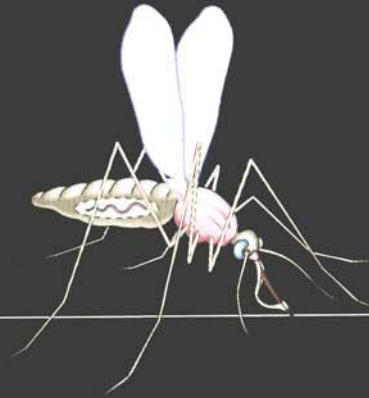
Medical Helminthology and Protozoology



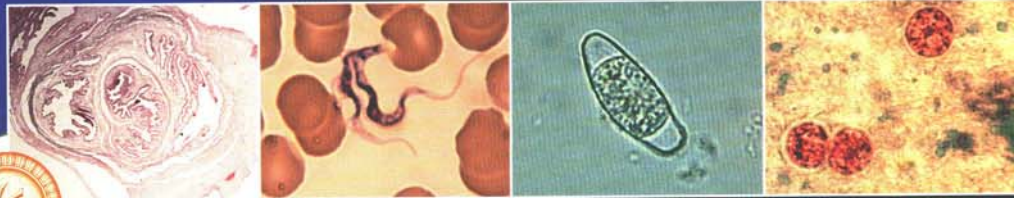
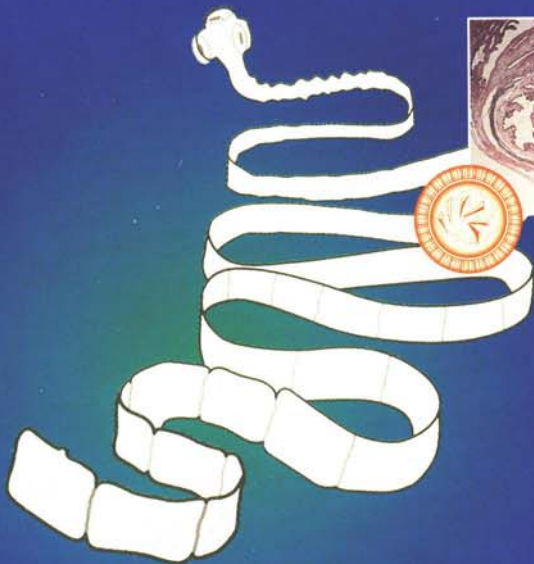P.L. Chiodini
A.H. Moody
D.W. Manser

Fourth edition

Atlas of



Medical Helminthology and Protozoology



P.L. Chiodini
A.H. Moody
D.W. Manser

Fourth Edition

Atlas of

Medical

Helminthology

and Protozoology

Edited by

Richard

Stromberg

and

John

W. Brown

with

contributions

by

many

authors


and

illustrators

and

editors

Atlas of




**Medical
Helminthology
and Protozoology**

Copyright © 2012 by Elsevier
All rights reserved.
No part of this publication may be reproduced, stored in a retrieval system, or transmitted, in any form or by any means, electronic, mechanical, photocopying, recording, or by any information storage and retrieval system, without the prior written permission of the publisher.

Commissioning Editor: Timothy Horne
Project Development Manager: Jim Killgore
Designer: Sarah Russell
Project Manager: Nancy Arnott

Fourth Edition



Atlas of

Medical Helminthology and Protozoology

Peter L. Chiodini BSc PhD FRCP FRCPath

Consultant Parasitologist, Department of Clinical Parasitology, The Hospital for Tropical Diseases,
Honorary Professor, The London School of Hygiene and Tropical Medicine, London, UK

Anthony H. Moody MPhil MIBiol C.Biol FIBMS

Laboratory Manager, Department of Clinical Parasitology, The Hospital for Tropical Diseases, London, UK

David W. Manser BSc MSc FIBMS

Biomedical Scientist, Department of Clinical Parasitology, The Hospital for Tropical Diseases, London, UK

Illustrated by **Robert Britton**



EDINBURGH LONDON NEW YORK OXFORD PHILADELPHIA ST LOUIS SYDNEY TORONTO 2001

CHURCHILL LIVINGSTONE
An imprint of Elsevier Science Limited

© Harcourt Publishers Limited 2001
© Elsevier Science Limited 2003. All rights reserved.

The right of P. L. Chiodini, A. H. Moody and D. W. Manser to be identified as authors of this work has been asserted by them in accordance with the Copyright, Designs and Patents Act 1988

No part of this publication may be reproduced, stored in a retrieval system, or transmitted in any form or by any means, electronic, mechanical, photocopying, recording or otherwise, without either the prior permission of the publishers or a licence permitting restricted copying in the United Kingdom issued by the Copyright Licensing Agency, 90 Tottenham Court Road, London W1T 4LP. Permissions may be sought directly from Elsevier's Health Sciences Rights Department in Philadelphia, USA: phone: (+1) 215 238 7869, fax: (+1) 215 238 2239, e-mail: healthpermissions@elsevier.com. You may also complete your request on-line via the Elsevier Science homepage (<http://www.elsevier.com>), by selecting 'Customer Support' and then 'Obtaining Permissions'.

First published 2001
Reprinted 2003

ISBN 0443 06268 4
International Student Edition ISBN 0443 06267 6

British Library Cataloguing in Publication Data

A catalogue record for this book is available from the British Library

Library of Congress Cataloguing in Publication Data

A catalog record for this book is available from the Library of Congress

Note

Medical knowledge is constantly changing. As new information becomes available, changes in treatment, procedures, equipment and the use of drugs become necessary. The authors and the publishers have, as far as it is possible, taken care to ensure that the information given in this text is accurate and up to date. However, readers are strongly advised to confirm that the information, especially with regard to drug usage, complies with the latest legislation and standards of practice.

**ELSEVIER
SCIENCE** your source for books,
journals and multimedia
in the health sciences

www.elsevierhealth.com

The
publisher's
policy is to use
paper manufactured
from sustainable forests

Printed in China

Preface

Since this atlas was first published, major advances in immunology and molecular biology have transformed our understanding of the parasitic diseases which affect humans. The programme to eradicate Guinea worm is well advanced and real progress is being made towards a malaria vaccine. However, none of the parasites described in the first edition have yet been consigned to history. Indeed, *Cyclospora* and the microsporidia are newly recognised as important human pathogens even since the third edition, and in some geographical areas the malaria situation is worse, with the spread of multi-drug resistant *Plasmodium falciparum* malaria. There is a great deal left to be done.

Effective action against parasitic disease requires a team approach, including epidemiologists, biologists, diagnostic

laboratory workers and clinicians. Common to all these disciplines is a need to understand the life cycles and morphology of the organisms they confront. It is hoped that this edition of the atlas will provide an appropriate introduction. The strong emphasis on diagnosis has been retained and since diagnostic parasitology still relies heavily on morphology, we have strengthened this area with the introduction of colour illustrations and photomicrographs.

We hope this book will help to kindle enthusiasm for the effort to control these parasites and the diseases they cause.

London
2001

P. L. C.
A. H. M.
D.W. M.

Acknowledgement

This atlas first originated from the Royal Army Medical College, London. The late Major-General HC Jeffrey and the late RM Leach wrote the first two editions. Colonel, later

Major-General, GO Cowan undertook revision for the third edition and an abridged version of his introduction is included in this latest edition.

Contents

Introduction 1

Helminthology 3

Nematode (round) worms 5

- Enterobius vermicularis* (thread or pin worm) 5
- Trichuris trichiura* (whip worm) 6
- Ascaris lumbricoides* (round worm) 7
- Hookworms 8
- Strongyloides stercoralis* 9
- Trichinella spiralis* 10
- Wuchereria bancrofti* (filariasis) 12
- Brugia malayi* 13
- Loa loa* (eye worm) 14
- Onchocerca volvulus* (blinding worm) 15
- Other filarial worms 16
- Dracunculus medinensis* (Guinea worm) 17
- Phasmid nematodes 18
 - Toxocara canis* (dog round worm) 18
 - Toxocara cati* (cat round worm) 18
 - Gnathostoma spinigerum* 19
- Cutaneous larva migrans (creeping eruption) 19

Cestode (tape) worms 20

- Taenia solium* (pork tape worm) 20
- Taenia saginata* (beef tape worm) 21
- Dwarf tape worms 22
 - Hymenolepis nana* 22
 - Hymenolepis diminuta* (rat tape worm) 22
- Diphyllobothrium latum* (fish tape worm) 23
- Larval forms of cestode infection in humans 24
- Echinococcus granulosus* (dog tape worm) 25
- Echinococcus multilocularis* 26

Trematode (flat) worms 27

- Schistosoma* species (blood flukes) 27
- Schistosomiasis 29
- Clonorchis sinensis*, syn. *Opisthorchis sinensis* (Oriental liver fluke) 30
- Opisthorchis felineus*, *Opisthorchis viverrini* (cat liver fluke) 31
- Fasciola hepatica* (sheep liver fluke) 32
- Fasciolopsis buski* 33
- Heterophyes heterophyes* 34
- Metagonimus yokogawai* 34
- Paragonimus westermani* (lung fluke) 35

Common helminth ova 36

Protozoology 39

An outline classification of the parasitic protozoa of humans 40

Intestinal protozoa 41

- Coccidia 41
 - Isospora belli* 41
 - Cryptosporidium parvum* 42
 - Cyclospora cayentanensis* 43
 - Sarcocystis hominis* 44
- Microsporidia — general characteristics 45
- Amoebae 47
 - Entamoeba histolytica* (causing amoebiasis) 48
- Other intestinal amoebae 54
- Intestinal flagellates 56
 - Giardia intestinalis* (*G. lamblia*) 56
 - Chilomastix mesnili* 56
 - Trichomonas* species 57
- Intestinal ciliates 58
 - Balantidium coli* 58

Tissue protozoa 59

- Toxoplasma gondii* 59

Malaria parasites 61

- Life cycle 62
- Morphology 63
- Pathology and Clinical features 68
- Laboratory diagnosis 69

Body-fluid and tissue flagellates 70

- Leishmaniasis 71
 - Visceral leishmaniasis (kala azar) 72
 - Cutaneous leishmaniasis 73
 - Mucocutaneous leishmaniasis (espundia) 73
 - Diagnosis of leishmaniasis 73
- Trypanosomiasis 74
 - African type: sleeping sickness 74
 - South American type: Chagas' disease 76
 - Laboratory diagnosis of trypanosomiasis 78

Recapitulation 79

- Luminal intestinal protozoa 79

Index 81

Introduction

The protozoon and the helminth, as regards tropical pathology, are in the ascendant.

Sir Patrick Manson (1899)

Parasites to the Ancient Greeks were those who sat at another's table and paid for their meal with flattery. In biology, a parasite is an animal or plant living in or on another (the host) and drawing nourishment from it. This definition could include viruses, bacteria and fungi as well as protozoa and helminths, but historically the first group has been studied in microbiology, the second in parasitology. In tropical diseases, Manson's dictum remains valid today.

Protozoa are small, unicellular organisms, which contain a nucleus and functional organelles. They reproduce quickly and asexually in the host, but may have a sexual phase of their life cycle in another host or vector.

Helminths (worms), which are metazoa, are larger, multicellular organisms, normally visible to the naked eye in their adult form. They reproduce sexually, usually within the host, and have pre-adult stages (ova, larvae) which live externally or in other hosts.

Transmission of parasites requires:

- a source or reservoir which may be human or animal
- a route of infection, e.g. ingestion, penetration or an insect vector.

The **definitive** host is that in which sexual reproduction occurs (e.g. mosquitoes for malaria) or in which the mature form of the parasite occurs (e.g. humans for African trypanosomiasis). An **intermediate** host is another animal essential to the completion of the life cycle (e.g. snails for schistosomiasis).

Parasites cause disease in humans by:

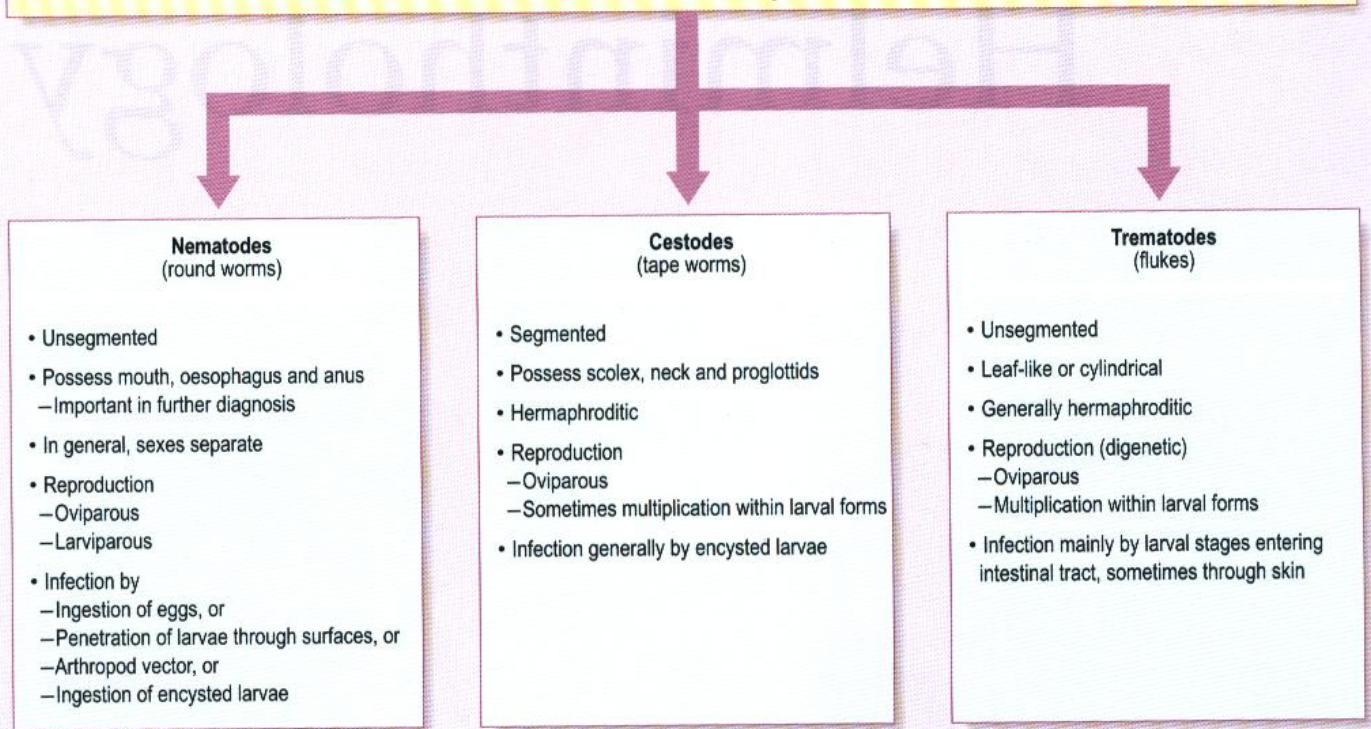
- mechanical effects, e.g. hydatid cyst
- invasion and destruction of host cells, as in malaria
- allergic or inflammatory immune reaction by the host to the parasite, e.g. toxocariasis and trypanosomiasis
- competition for specific nutrients, e.g. *Diphyllobothrium latum* for vitamin B₁₂
- or there may be no obvious disease, as in *Taenia saginata* in humans.

Diagnosis in parasitic diseases depends on:

- a history of exposure and the clinical pattern of illness in the patient
- identification of the parasite itself in excreta (stool, urine), blood, or specific tissues
- indirect evidence of the parasite by testing the patient's blood for antibodies
- detection of parasite antigens in clinical specimens
- detection of parasite DNA or RNA in clinical specimens.

Helminthology

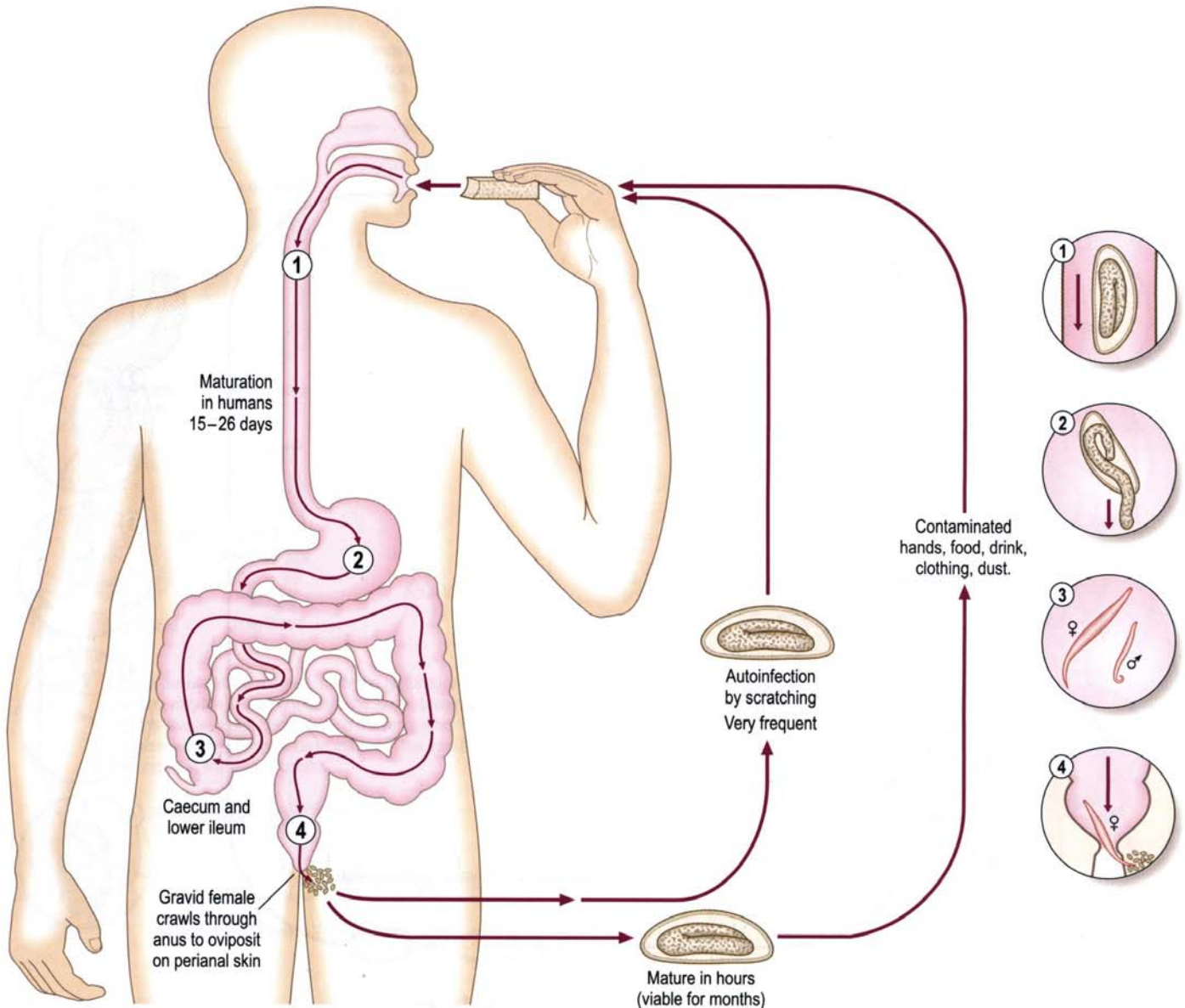
Worms of medical importance



Nematode (round) worms

Enterobius vermicularis (thread or pin worm)

Life cycle



Distribution

350 million infected worldwide, often group or institutional infection.

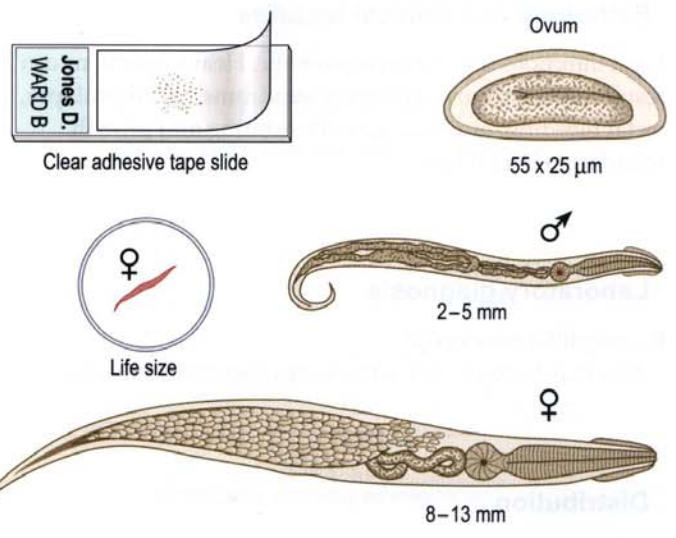
Pathology and Clinical features

Most infections are asymptomatic. Perianal itching may be troublesome. In females, migrating worms may cause pruritis vulvae or vaginitis. Rarely, urinary tract infection or appendicitis can occur. Migration into the peritoneal cavity has been recorded.

Laboratory diagnosis

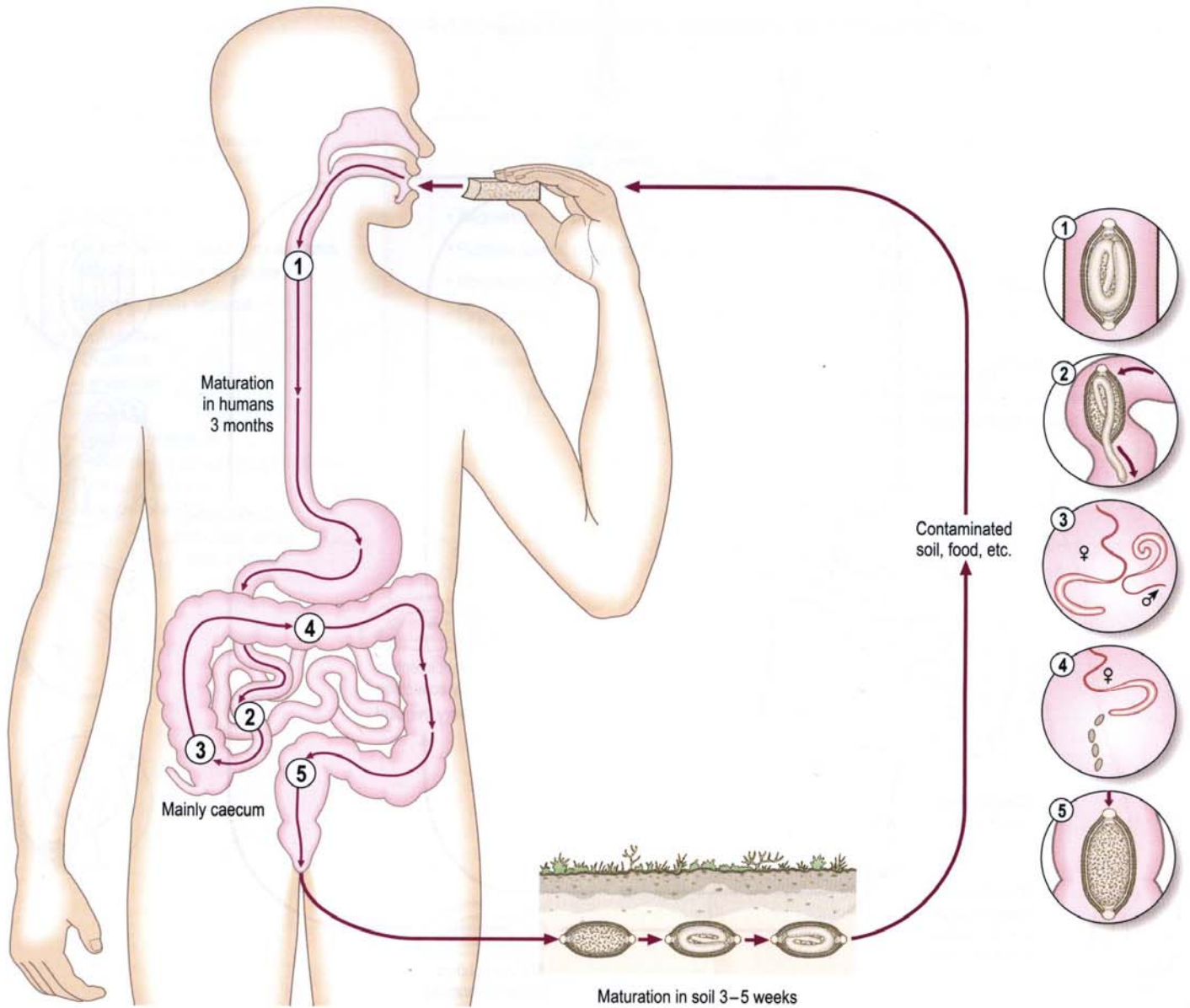
Mild eosinophilia.

Ova can be recovered from the perianal area using clear adhesive tape or a cotton swab moistened with saline. Early morning collection before washing gives best recovery. In females, ova may occasionally be recovered from urine.



Trichuris trichiura (whip worm)

Life cycle



Pathology and Clinical features

Light infections may be asymptomatic. Heavy infections can result in the trichuris dysentery syndrome, rectal prolapse, rectal bleeding, anaemia, growth stunting and growth retardation in children.

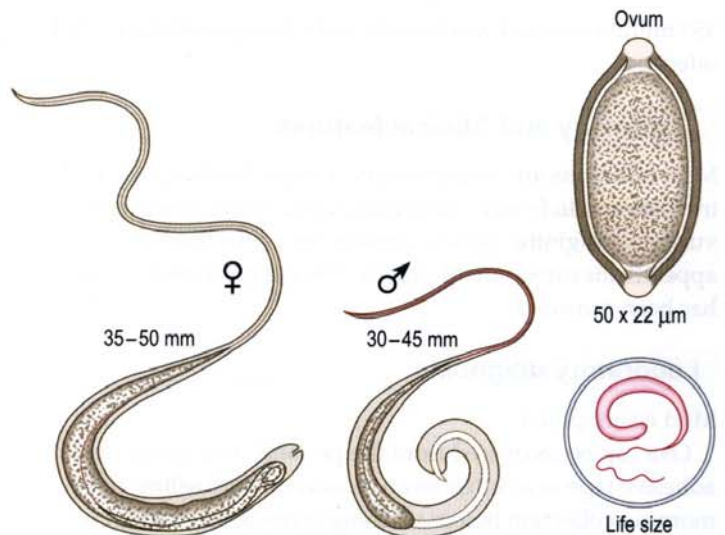
Laboratory diagnosis

Eosinophilia may occur.

Ova may be recovered in faeces by concentration methods.

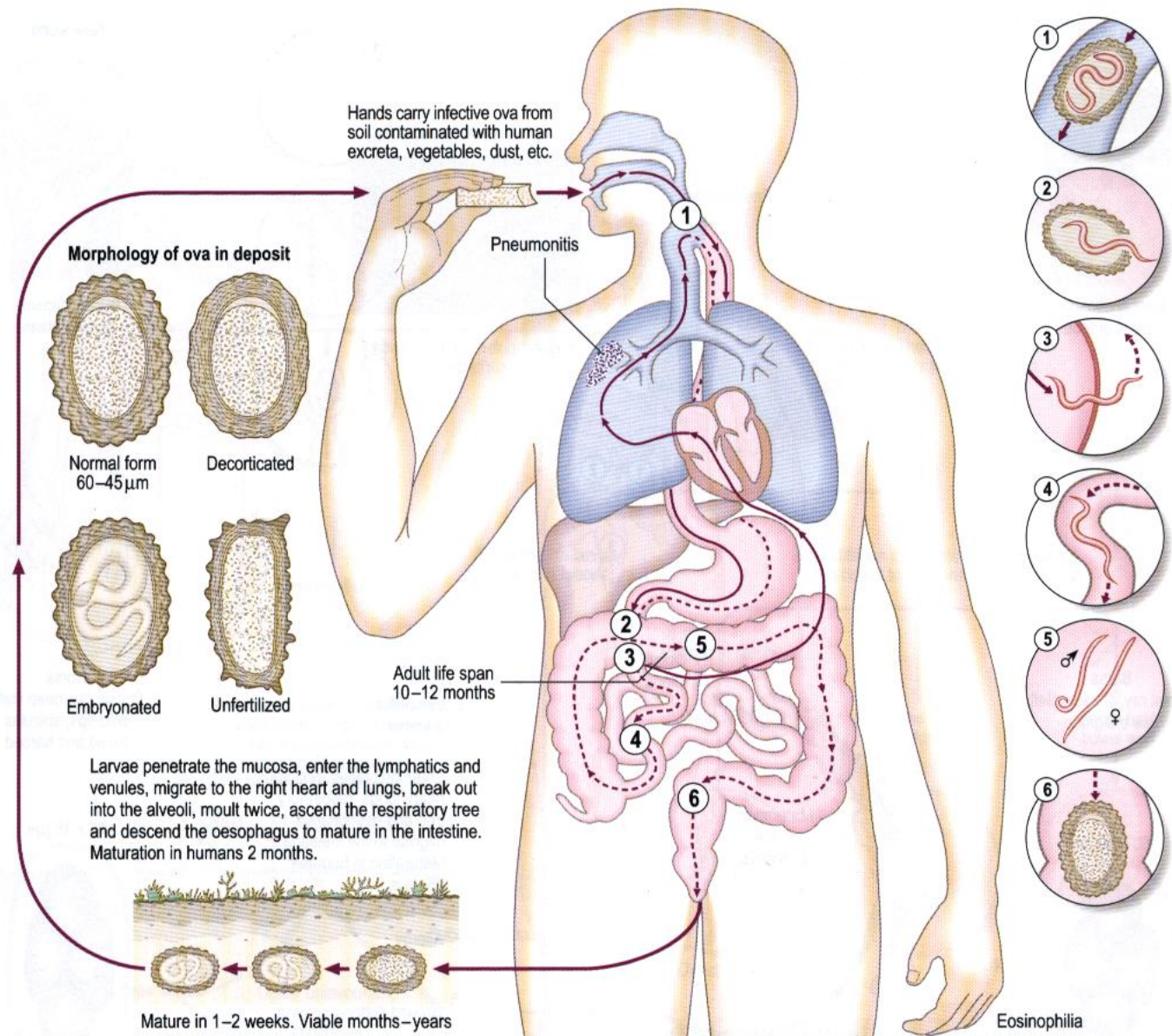
Distribution

1.3 billion infected worldwide.



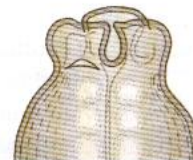
Ascaris lumbricoides (round worm)

Life cycle



Pathology and Clinical features

Larvae can cause pneumonitis with eosinophilia. Adult worms can cause obstruction of the small intestine, bile ducts and trachea; also appendicitis, pancreatitis and peritonitis. Children may vomit up a bolus of adult worms, or cough up immature worms.



Head of adult to show arrangement of the three lips

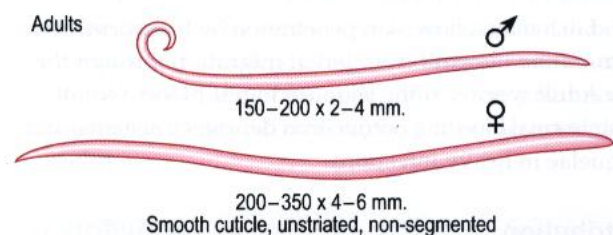
Laboratory diagnosis

Ova may be recovered from faeces by concentration methods. Rarely larvae can be found in sputum, and must be distinguished from those of *Strongyloides*. Eosinophilia is present in the larval invasion stage.

No specific serology is currently available.

Distribution

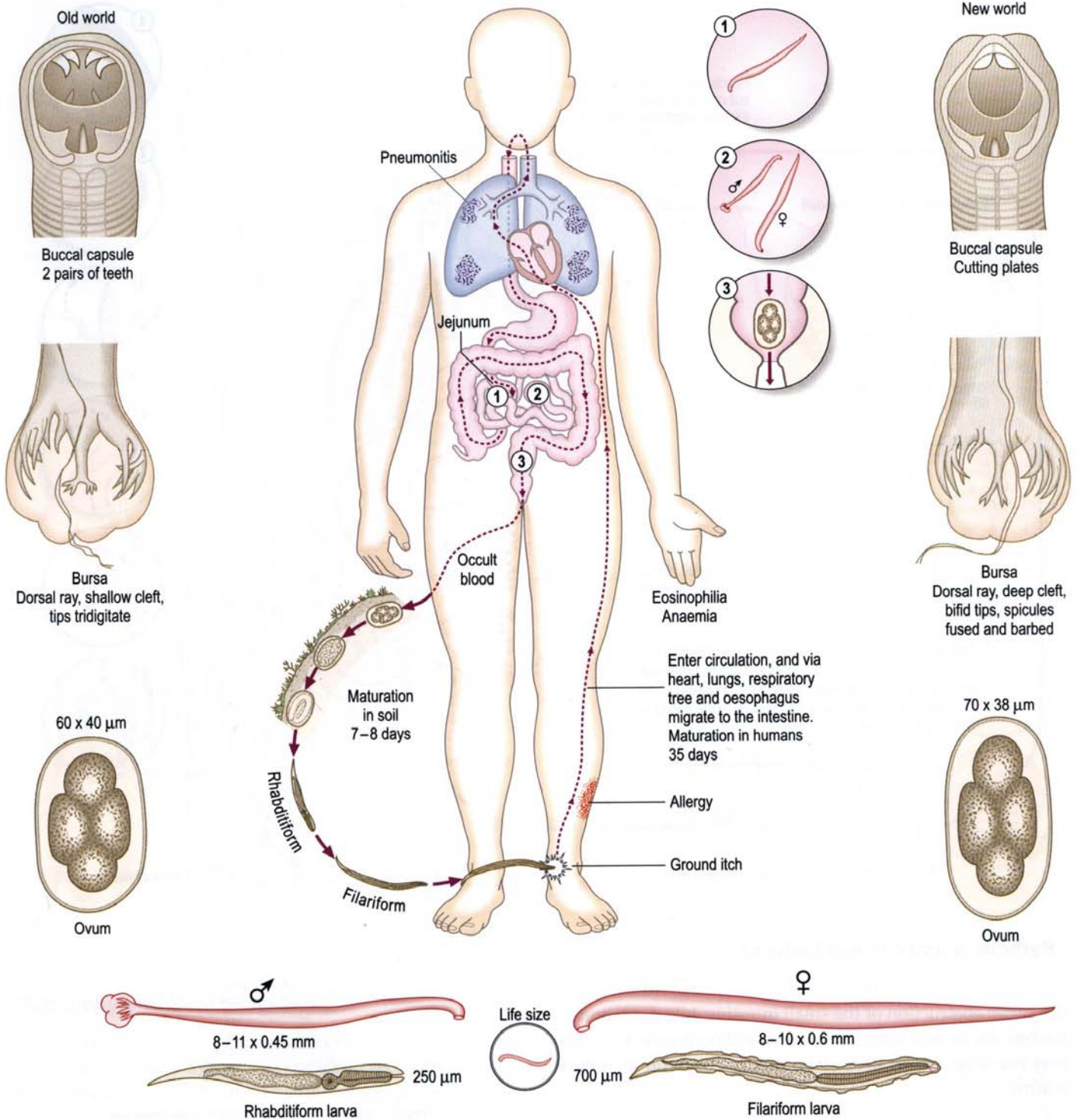
1.47 billion infected worldwide.



Hookworms

Ancylostoma duodenale

Necator americanus



Pathology and Clinical features

Ground itch may follow skin penetration by filariform larvae. Pneumonitis can result from larval migration through the lungs. Adult worms in the jejunum ingest blood. Occult gastrointestinal bleeding occurs. Iron deficiency anaemia and its sequelae in heavy infections.

Distribution

900 million infected worldwide.

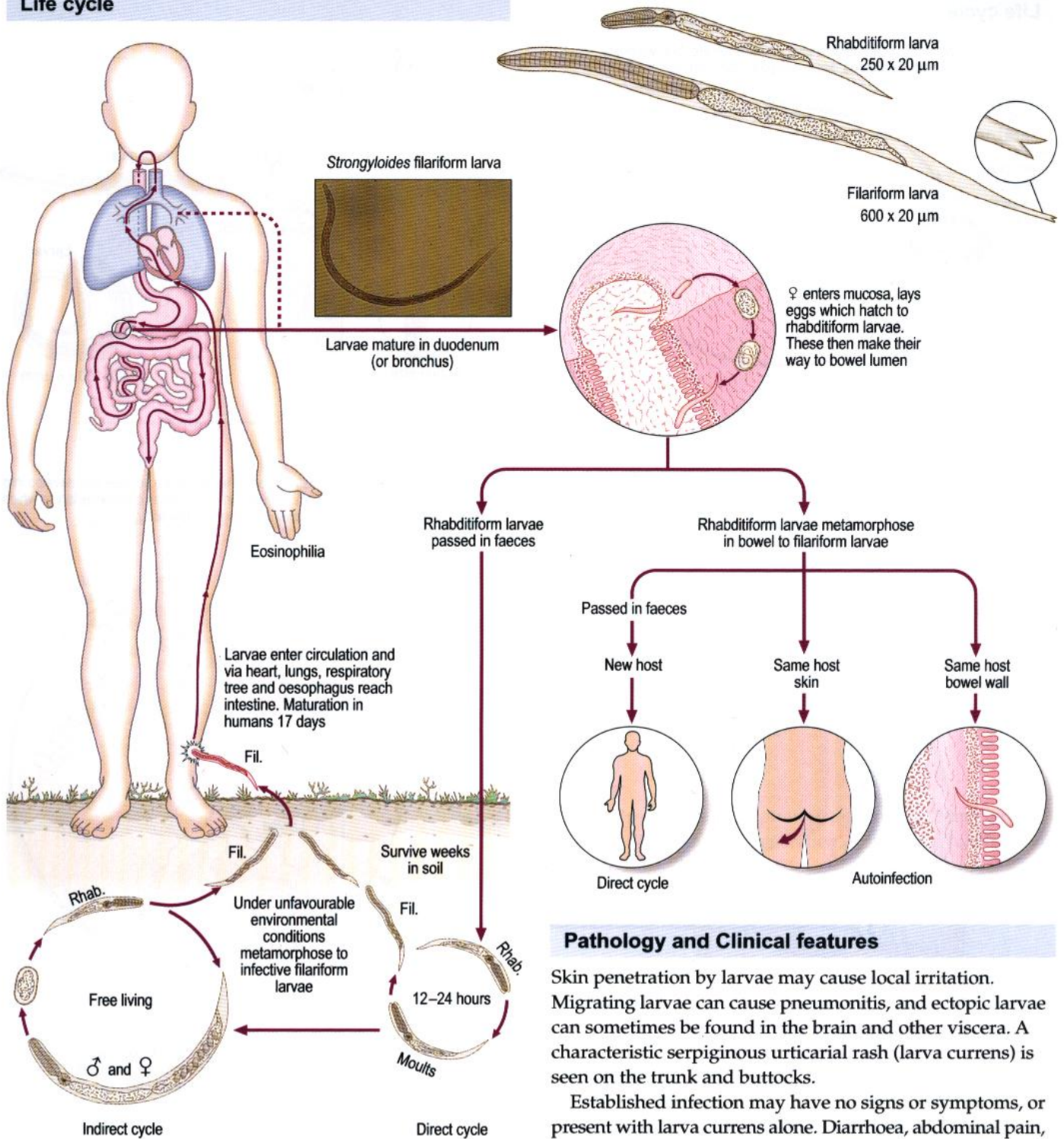
Laboratory diagnosis

Eosinophilia.

Ova may be recovered from faeces by concentration methods. Rhabditiform larvae may be seen in old faecal specimens and must be distinguished from *Strongyloides* by the appearance of the buccal cavity.

Strongyloides stercoralis

Life cycle



Laboratory diagnosis

Eosinophilia may be present, but its absence does not exclude diagnosis. It is essential to examine fresh specimens. Rhabditiform larvae can be seen in faeces by direct microscopy or by concentration methods. Filariform larvae may also be seen in faeces, sputum and other body fluids, particularly in immunocompromised hosts. Faecal culture using charcoal is an important diagnostic method. Duodenal aspiration and the 'string test' are also recommended isolation methods. Serology by ELISA is useful in chronic infection.

Pathology and Clinical features

Skin penetration by larvae may cause local irritation. Migrating larvae can cause pneumonitis, and ectopic larvae can sometimes be found in the brain and other viscera. A characteristic serpiginous urticarial rash (larva currens) is seen on the trunk and buttocks.

Established infection may have no signs or symptoms, or present with larva currens alone. Diarrhoea, abdominal pain, bloating and sometimes malabsorption can be found. The *Strongyloides* hyperinfection syndrome results from massive autoinfection with filariform larvae in the presence of severe immunosuppression or cachexia. Risk factors include steroid and/or cytotoxic therapy, HTLV1 infections, HIV infections, malignancy, severe malnutrition and other severe systemic disorders. Clinical features include diarrhoea, gastrointestinal haemorrhage or perforation, pneumonitis, Gram-negative bacterial meningitis or septicaemia with high mortality.

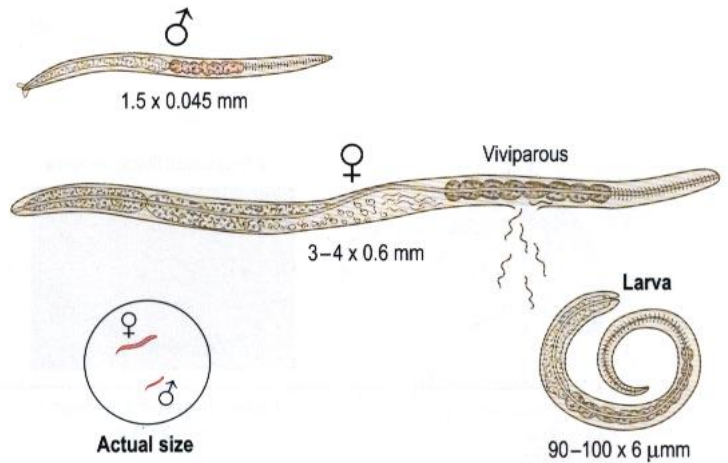
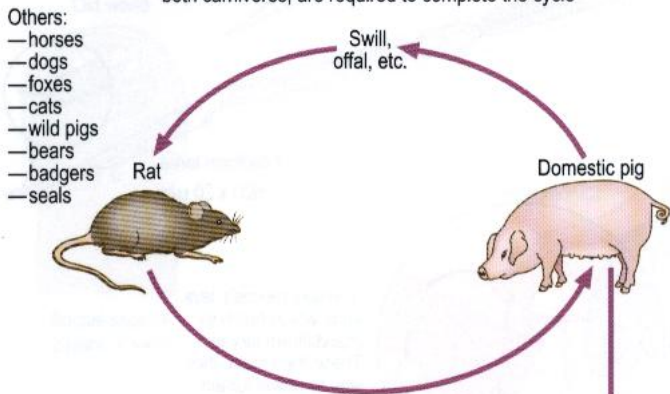
Distribution

70 million infected worldwide.

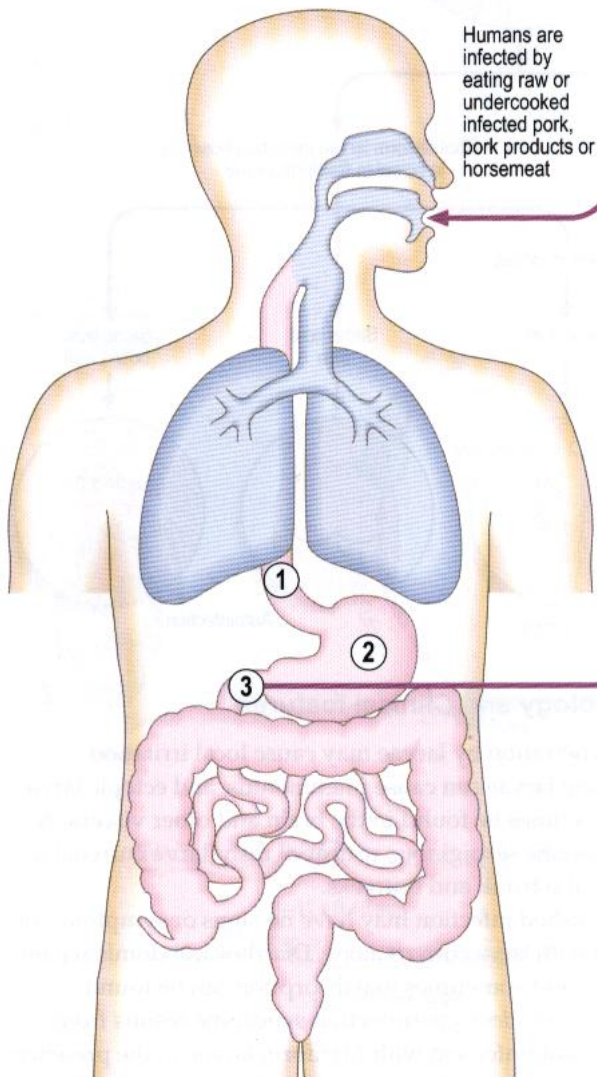
Trichinella spiralis

Life cycle

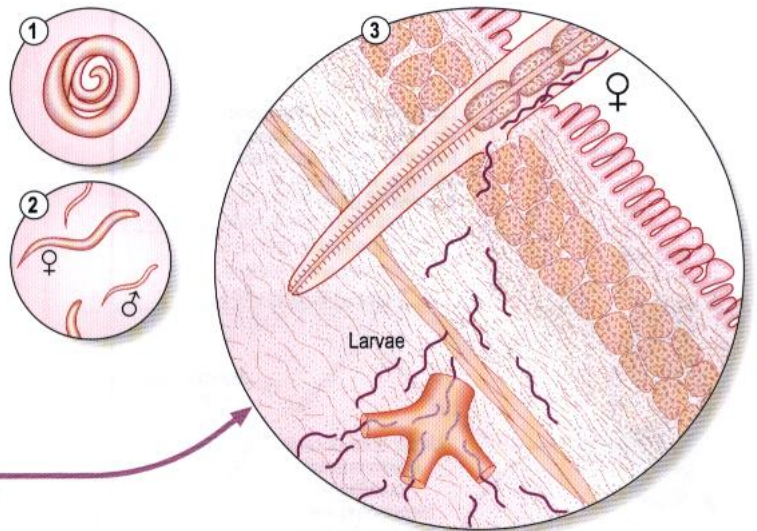
A given host can be definitive or intermediate, but two hosts, both carnivores, are required to complete the cycle



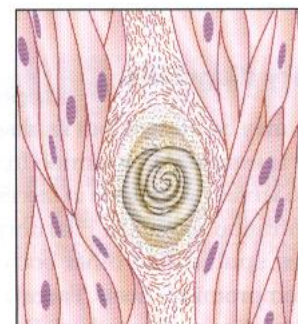
Infected flesh is digested by gastric juices; the larvae are set free and develop into adults in duodenum. The gravid ♀ burrows into mucosa and releases larvae which enter circulation and are disseminated throughout the body



Humans are infected by eating raw or undercooked infected pork, pork products or horsemeat



Dissemination through the blood and lymph



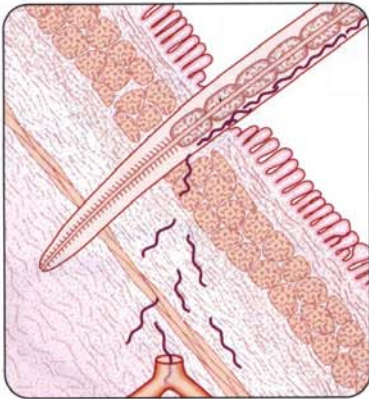
Encysted larva in muscle

Laboratory diagnosis

Eosinophilia and high serum CPK in the acute phase. At the encystment stage, use muscle biopsy, muscle crush preparation and serology (IFAT or ELISA).

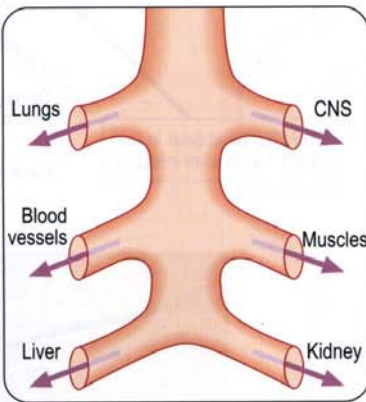
Distribution

50 million infected worldwide.



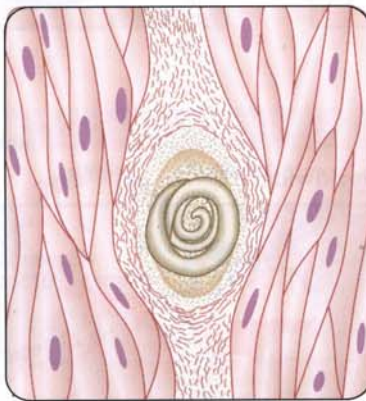Invasion

Intestinal inflammation leading to diarrhoea. Inflammatory response leading to periorbital oedema, haemorrhages under nails, muscle pains and myocarditis.



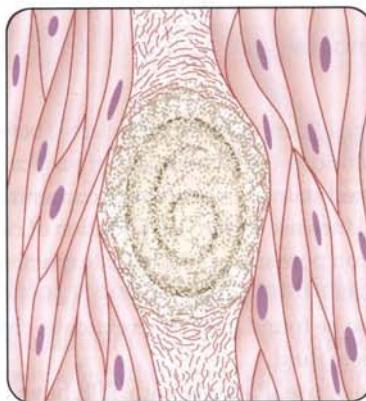
Dissemination

Migration may occur through any tissue but larval encystment is only in striated muscle. A granulomatous response develops elsewhere.



Localization

Especially muscles of respiration and tongue. Long term: eventual fibrosis and degeneration, resulting in calcification.



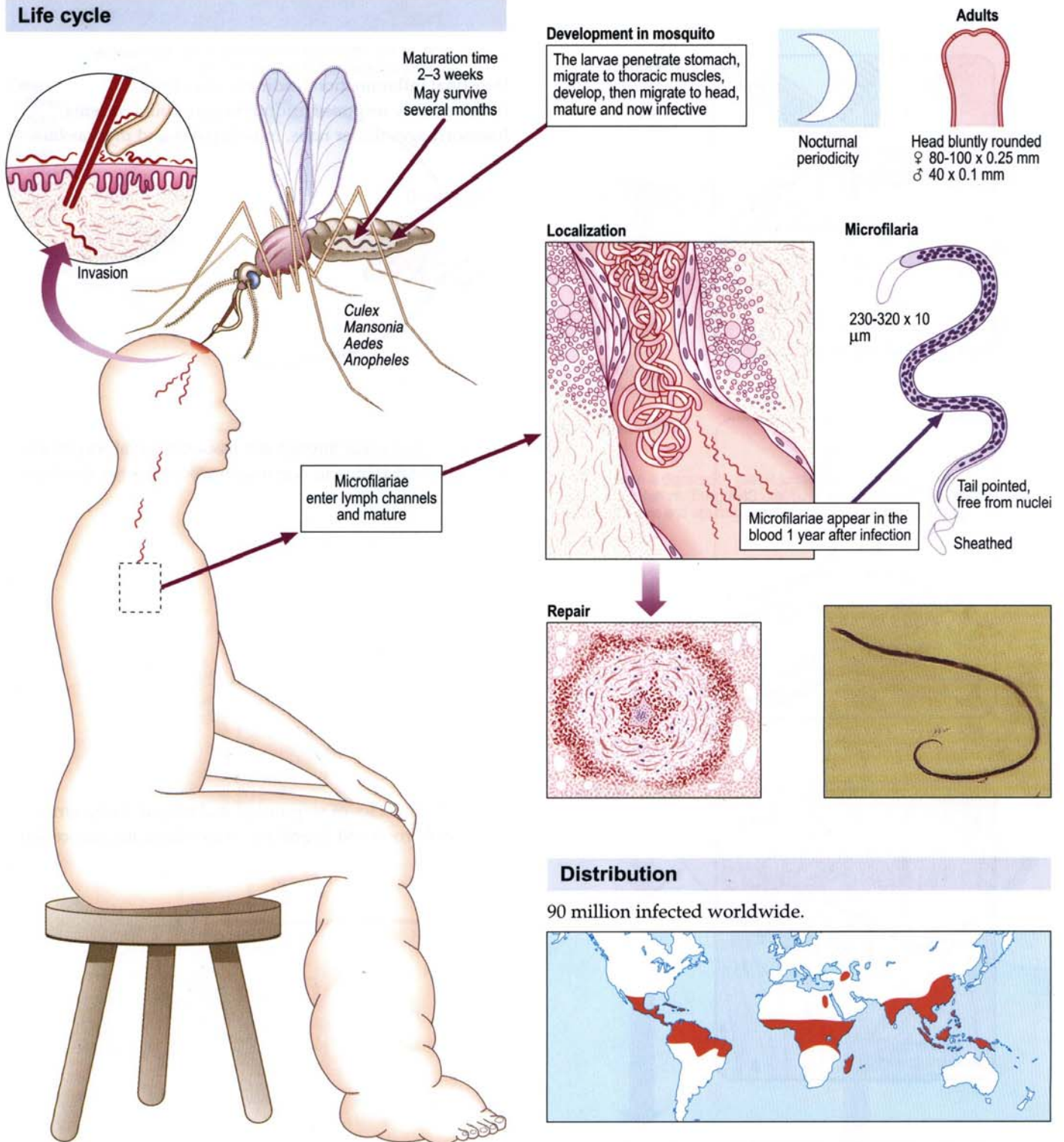
Organization

Laboratory diagnosis

At the diarrhoeal stage, adults and larvae may be found occasionally in faeces. Eosinophilia is high. At the encystment stage, use muscle biopsy, muscle crush preparation and serology (IFAT or ELISA).

Wuchereria bancrofti (filariasis)

Life cycle

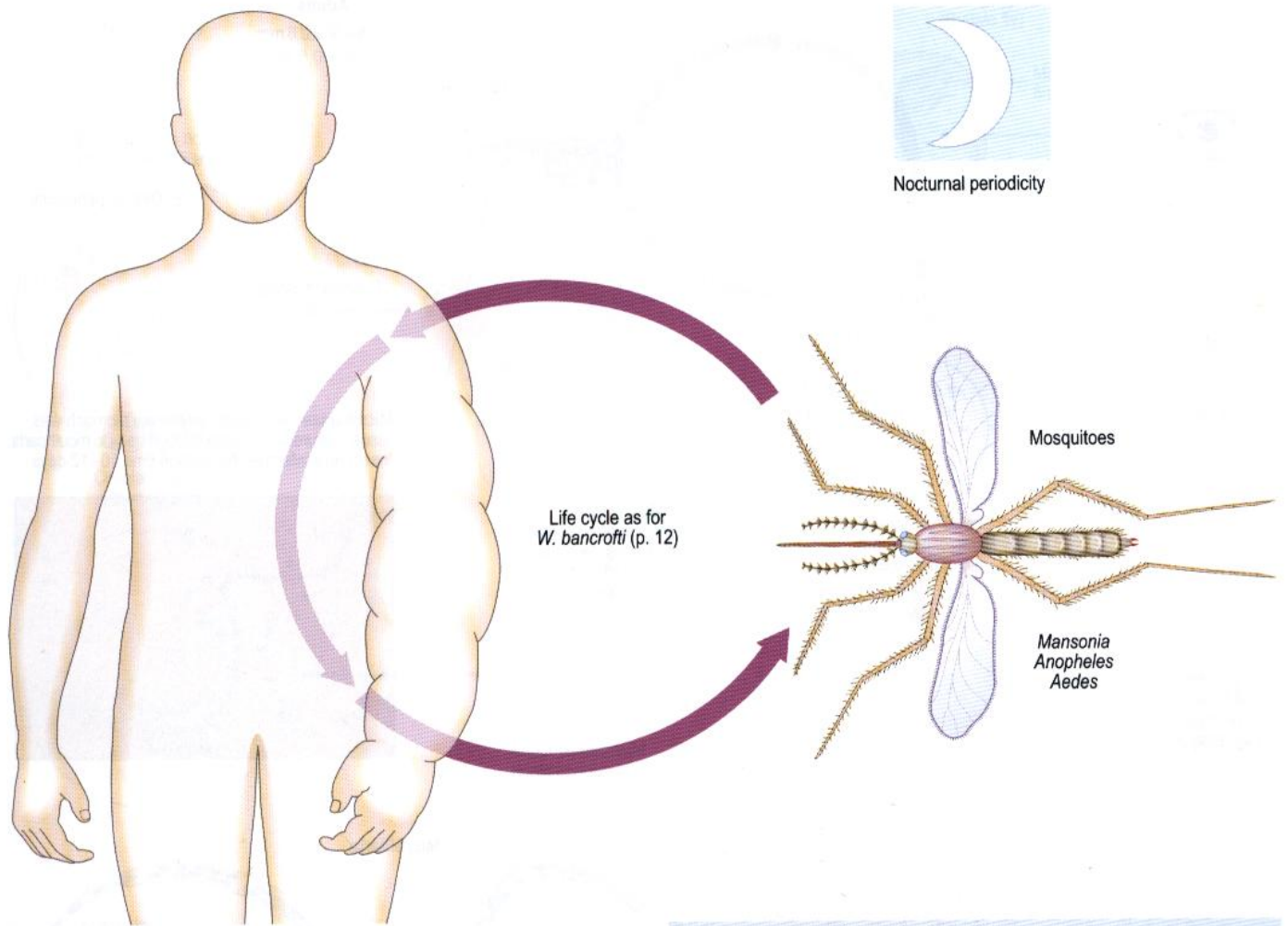


Pathology and Clinical features

Adult worms in the lymphatic channels cause proliferation of the lining of the endothelium. Surrounding infiltration of eosinophils, macrophages, lymphocytes and giant cells causes filarial granulation tissue leading to obstruction, secondary infection, fibrosis and calcification. The results of this are acute lymphangitis, filarial abscess, lymphadenopathy, elephantiasis, hydrocoele and chyluria. Tropical pulmonary eosinophilia (TPE) occurs in individuals who are hyper-responsive to filarial antigens, giving rise to nocturnal cough, wheeze and low-grade fever.

Brugia malayi

Life cycle



Nocturnal periodicity

Laboratory diagnosis

As for *Wuchereria bancrofti* except for the specific antigen test.

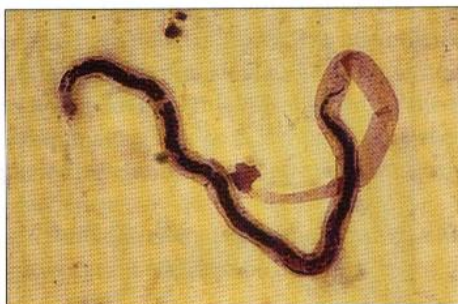Microfilaria

170–260 x 5–6 μ m

Sheathed

Two discrete nuclei in tip of tail

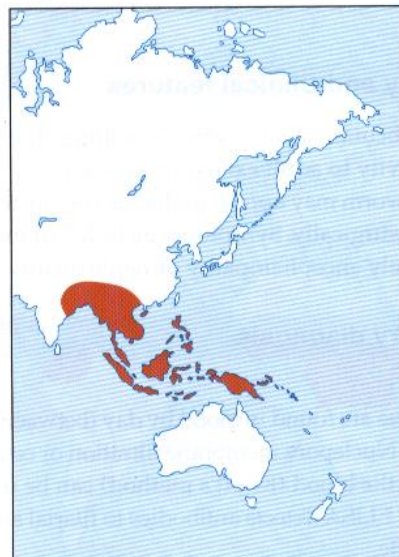
The adults resemble *W. bancrofti* but are smaller



Pathology and Clinical features

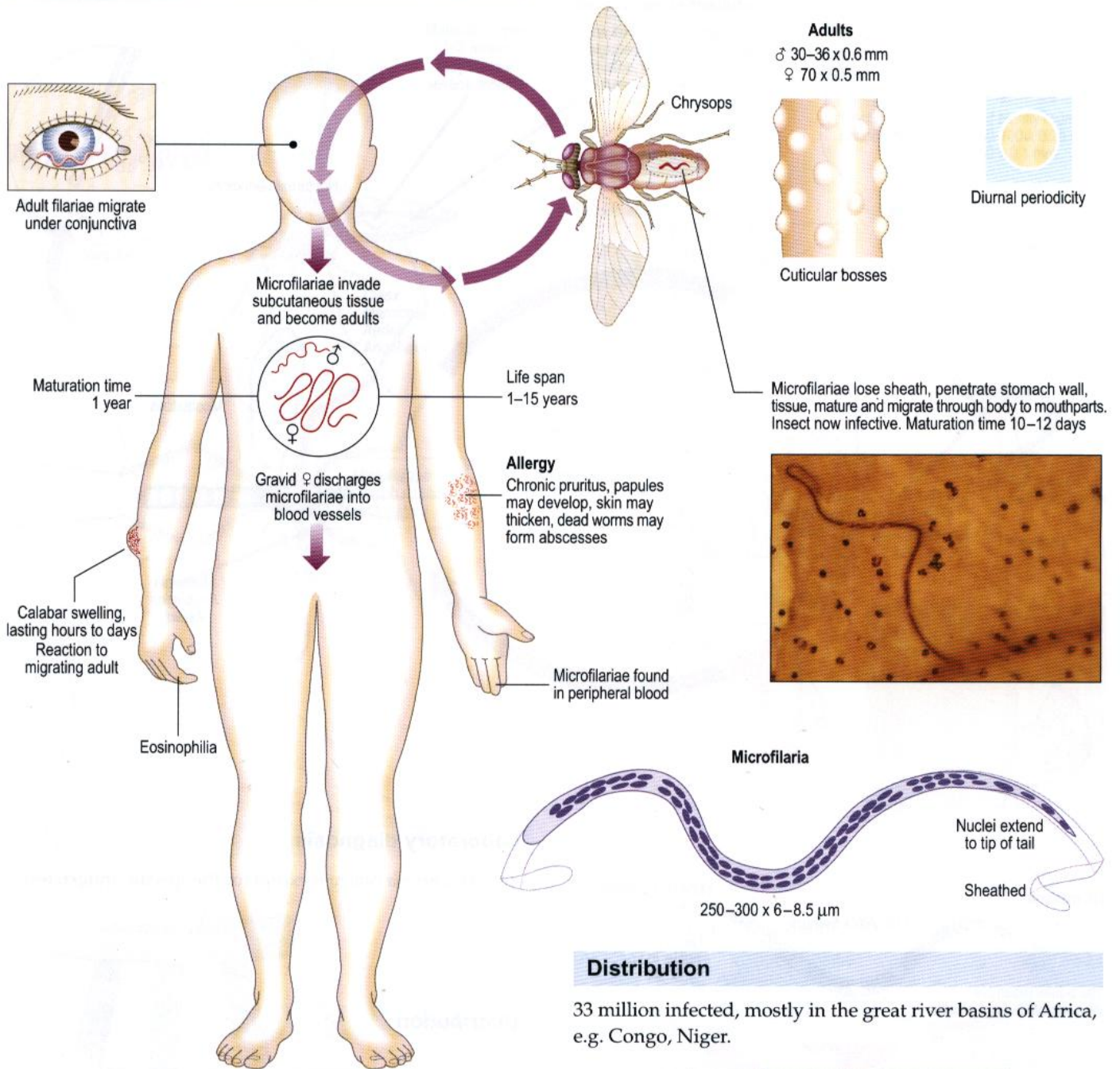
These are similar to those of *Wuchereria*, but *Brugia* more commonly affects the upper limbs. Hydrocoele, other genital lesions and chyluria are rare.

Distribution



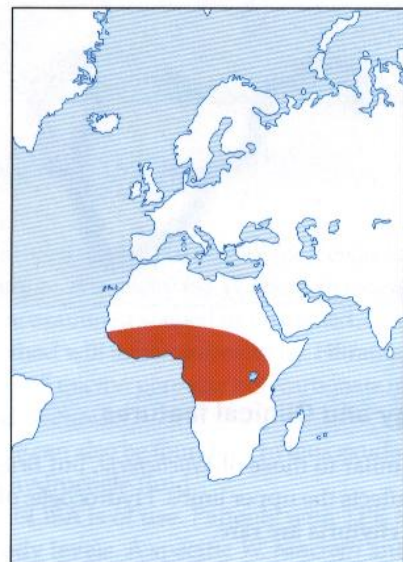
Loa loa (eye worm)

Life cycle



Distribution

33 million infected, mostly in the great river basins of Africa, e.g. Congo, Niger.



Pathology and Clinical features

Transient subcutaneous (Calabar) swellings due to hypersensitivity to adult excretory products.

The adult worm may appear under the conjunctiva and can be removed surgically. Symptoms include fatigue, chronic pruritus, rarely encephalopathy or nephropathy.

Laboratory diagnosis

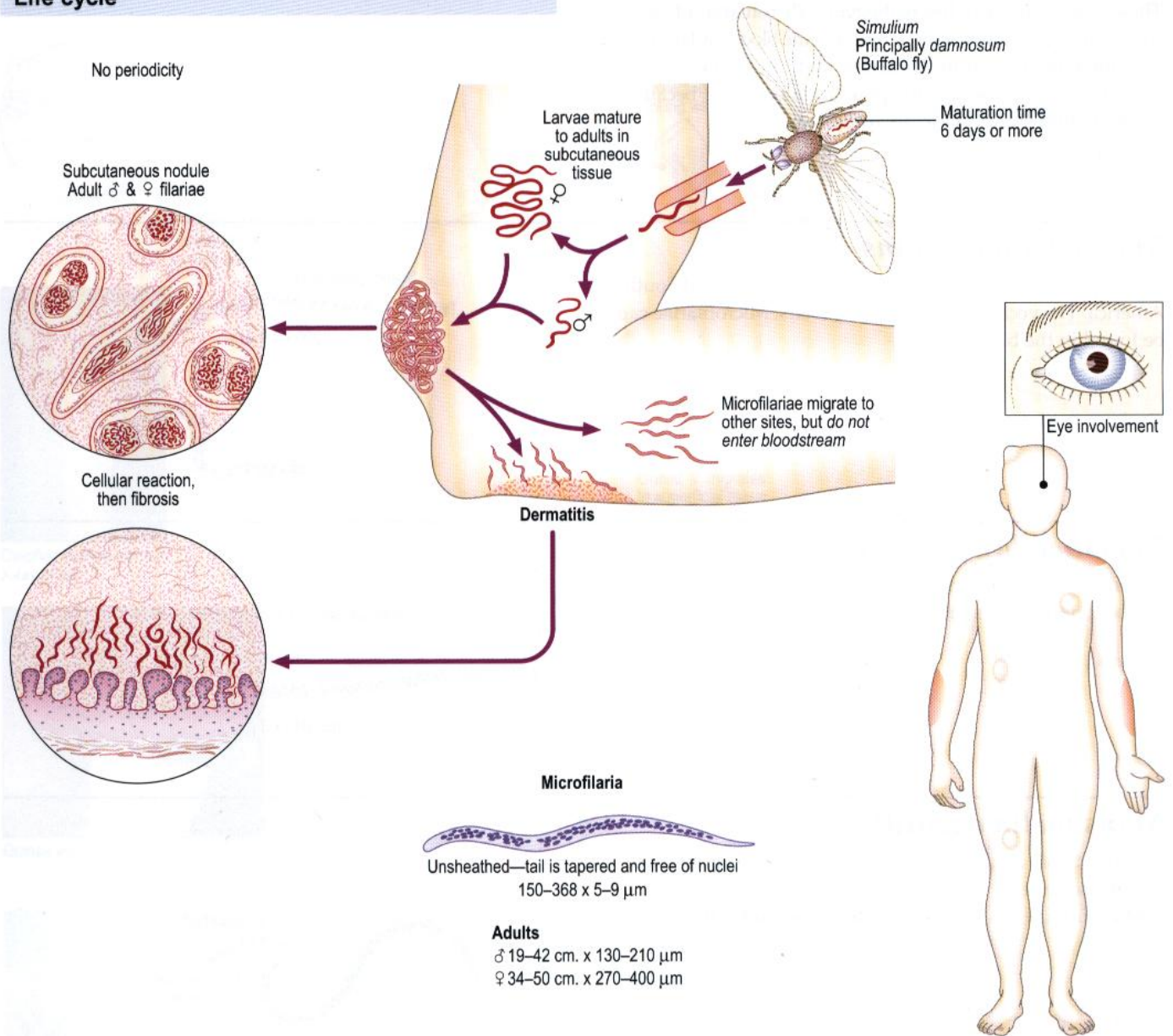
Eosinophilia.

Microfilariae are found in blood by day (between noon and 14:00 hours). Nuclepore membrane filtration or centrifugation after lysis of the blood (Knott's method) can be used.

Serology. ELISA detects antibodies to filarial antigens but is non-specific.

Onchocerca volvulus (blinding worm)

Life cycle



Pathology and Clinical features

Fibrous nodules develop round the adult worms, especially over the iliac crests. There may be some lymphatic obstruction; elephantiasis has been noted in Africa. The microfilariae cause itching, excoriation, urticaria, depigmentation, lichenification, 'sowda' and lymphadenopathy. When invading the eye, they can cause inflammatory lesions in any part of the eye such as sclerosing keratitis, choroidoretinitis and optic atrophy. Blindness may ensue.

Where microfilariae cannot be demonstrated, a Mazzotti test (DEC provocation test) can be useful.

Laboratory diagnosis

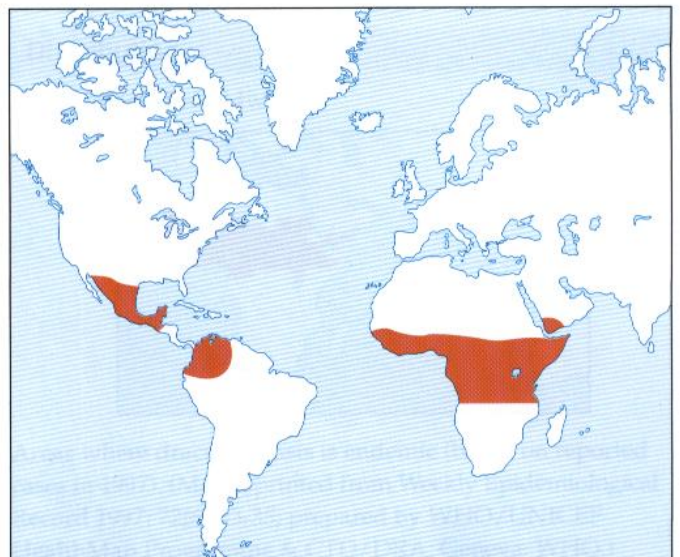
Eosinophilia.

Adult worms can be detected in excised nodules, microfilariae in the anterior chamber of the eye (slit lamp), skin snips and rarely in blood and urine.

Specific serodiagnosis by ELISA and PCR for parasite DNA on skin samples is in use.

Distribution

17 million infected worldwide.



Other filarial worms

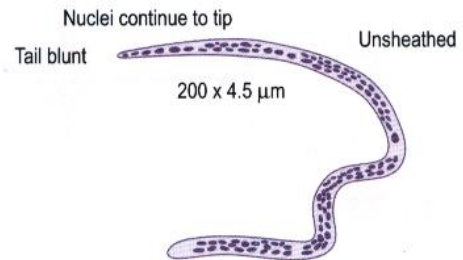
These worms are much less pathogenic. Microfilariae of other species are unsheathed, may be found in the blood and tissues and differentiation from *Wuchereria* and *Brugia* is necessary.

Filtration requires 3 micron pore size membrane, because of the smaller size of these microfilariae.

No periodicity.

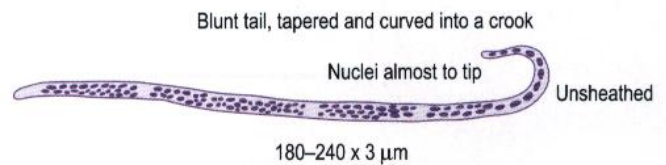
Mansonella perstans

Found in Tropical Africa and the coasts of Central and South America. The vector is the midge *Culicoides*. Microfilariae can be found in the blood.



Mansonella streptocerca

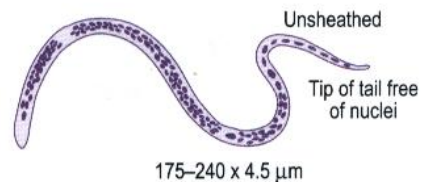
Found in Africa. The vector is the midge *Culicoides*. Microfilariae can be found in the skin.



Mansonella ozzardi

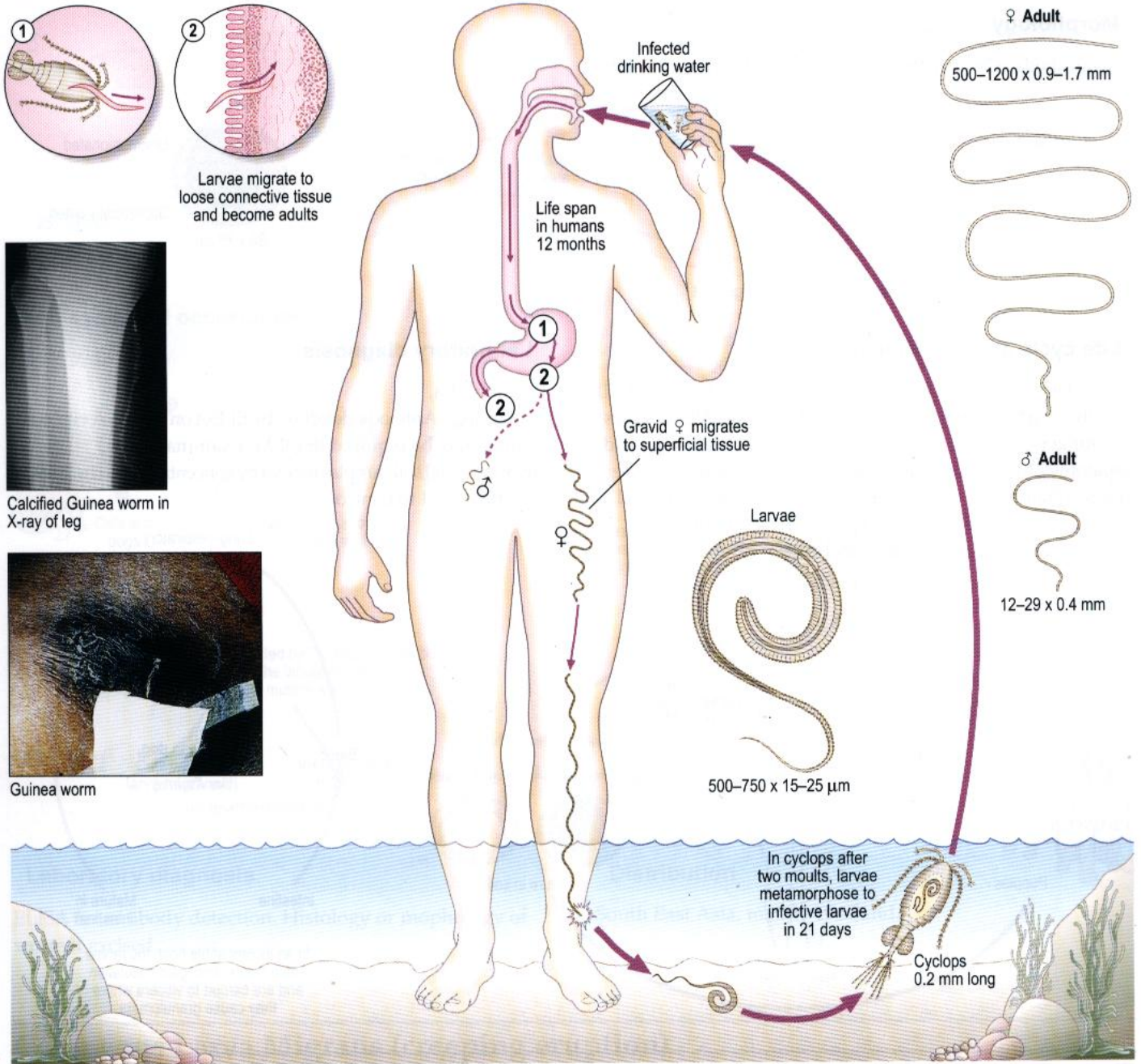
Found in South America and the Caribbean. The vector is the midge *Culicoides*.

Microfilariae can be found in the blood and skin.



Dracunculus medinensis (Guinea worm)

Life cycle



Pathology and Clinical features

The gravid female causes itching, urticaria and a burning sensation. A blister appears which bursts to become an ulcer (usually leg) with discharge of embryos and some fibrosis. The adult female may be seen protruding from the ulcer. There is often secondary bacterial infection, and sometimes arthritis of the knee and ankle. Worms may fail to emerge, die and calcify.

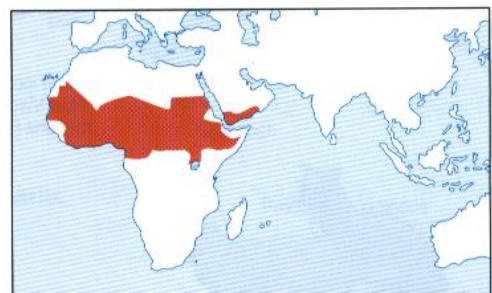Laboratory diagnosis

Eosinophilia.

Larvae may be found in fluid from the ulcer.

Distribution

70 000 infected worldwide.



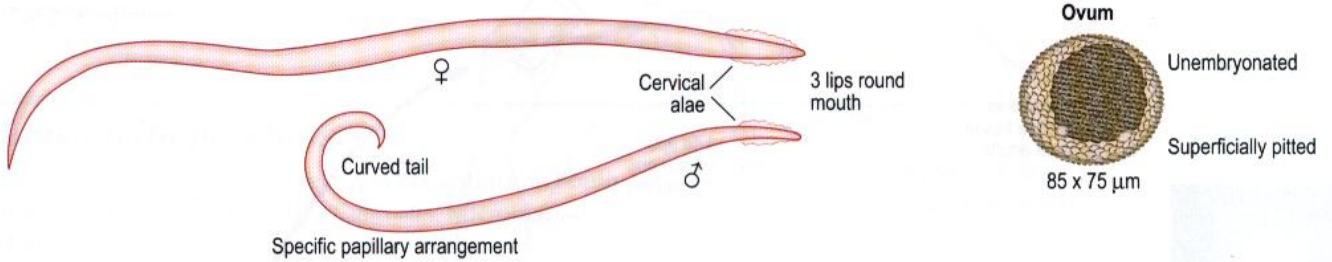
Areas where dracunculiasis is endemic (based on reported cases in 1997). (Map reprinted from Weekly Epidemiological Record 1997; 72(6):33-35; prepared by WHO/UNICEF HealthMap Programme & CTD/DRA, Geneva: WHO.)

Phasmid Nematodes

Toxocara canis (dog round worm)

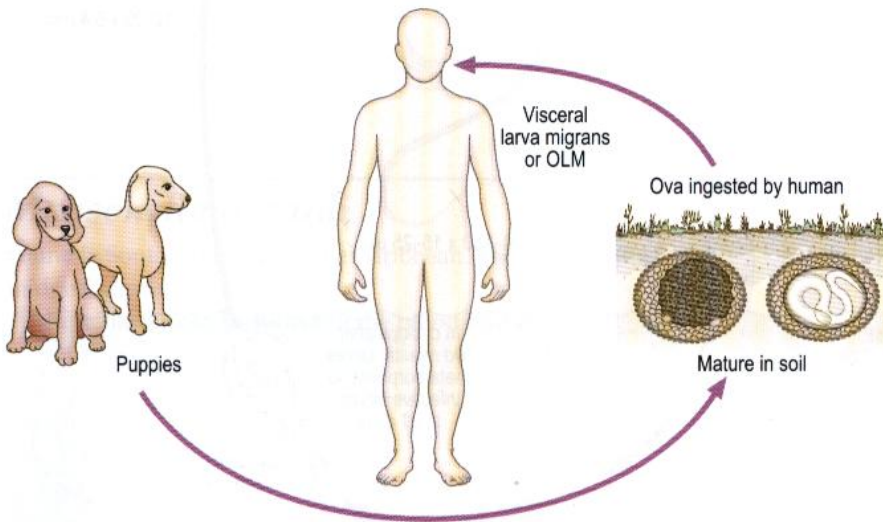
Morphology

Toxocara: body is bent ventrally. *Toxascaris*: body is bent dorsally.



Life cycle and occurrence

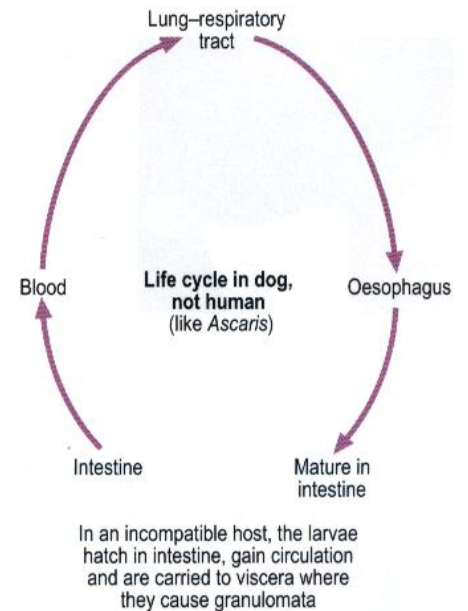
Ocular larva migrans (OLM) and visceral larva migrans (VLM) usually occur as distinct entities without overlap. VLM occurs in younger children and gives rise to fever, pneumonitis and hepatomegaly. Myocarditis, convulsions, psychiatric changes or encephalopathy may occur. OLM presents as unilateral visual loss, often with squint. Retinal detachment, endophthalmitis or papillitis may occur.



Laboratory diagnosis

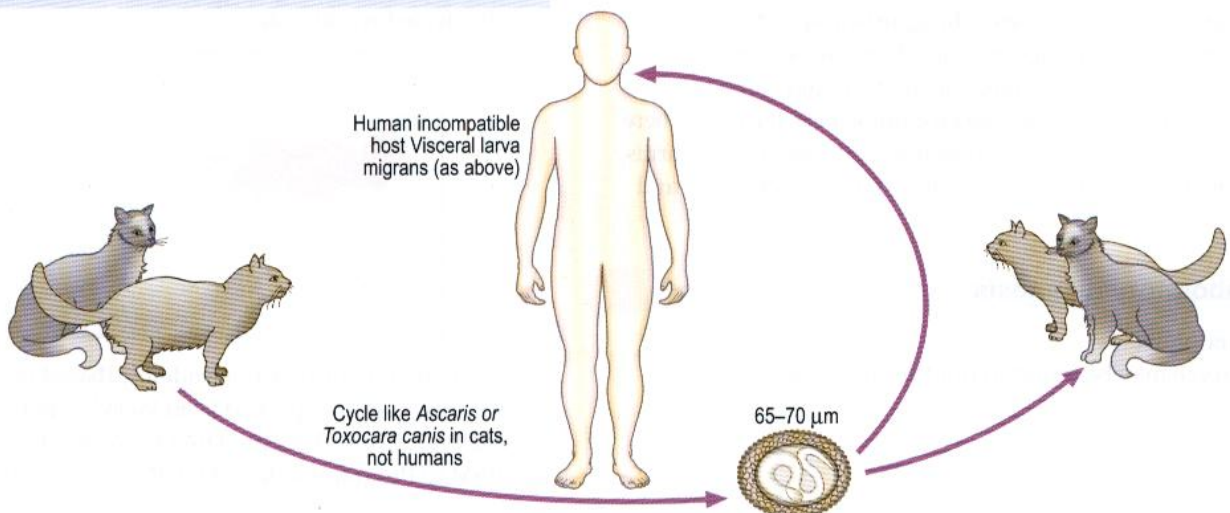
Eosinophilia.

Serology. Antibody detection by ELISA on serum. A vitreous sample may be required in OLM. Examination of environmental soil samples for ova by concentration techniques may be an aid to control.



Toxocara cati (cat round worm)

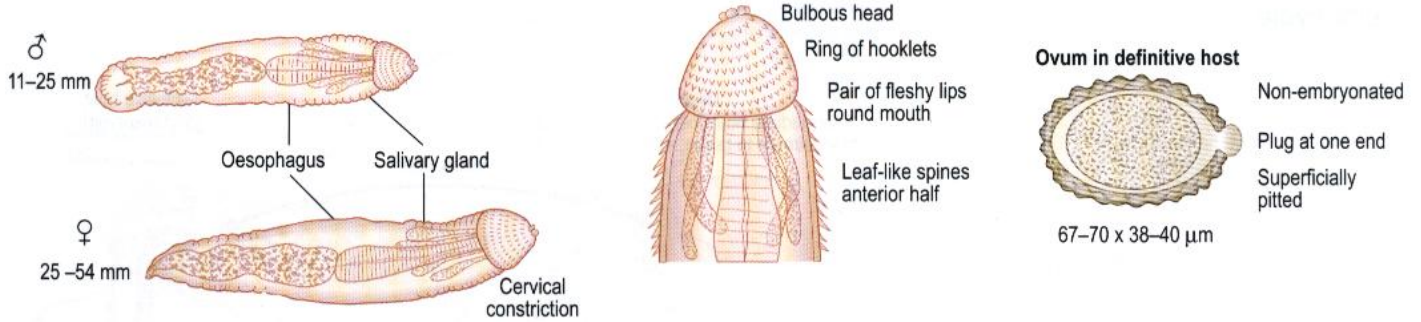
Life cycle



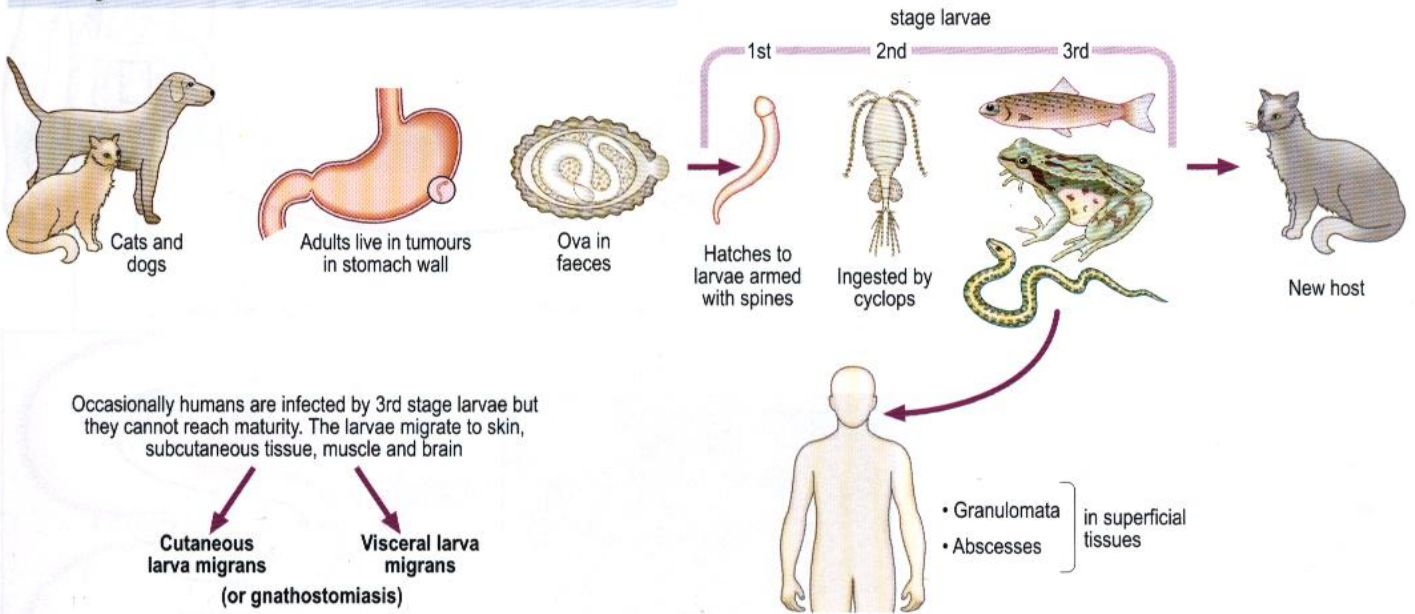
Gnathostoma spinigerum

Morphology

Stout, reddish-coloured worms



Life cycle and occurrence



Laboratory diagnosis

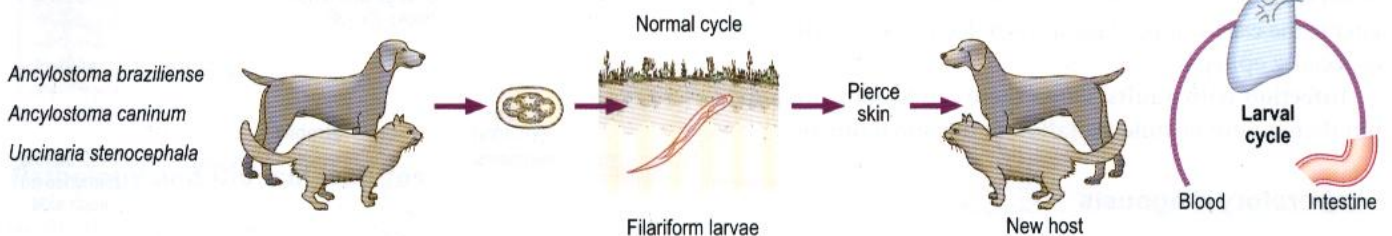
ELISA for antibody detection. Histology or morphology of worm if excised.

Distribution

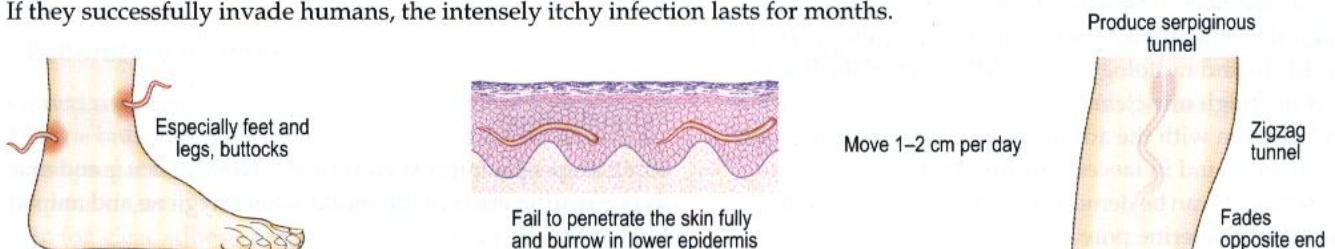
South East Asia, mainly Thailand.

Cutaneous Larva Migrans (creeping eruption)

Caused by non-human hookworm larvae.



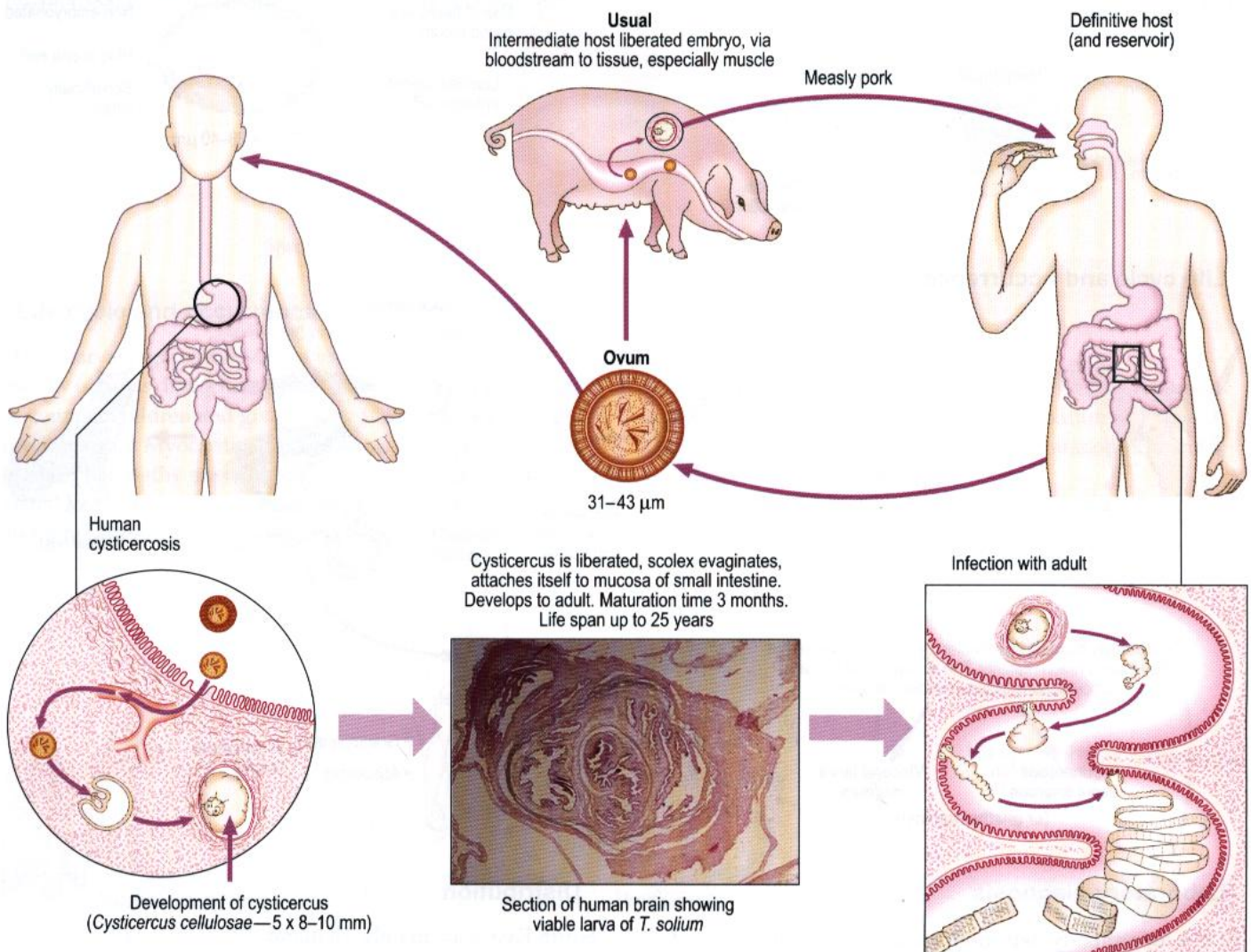
If they successfully invade humans, the intensely itchy infection lasts for months.



Cestode (tape) worms

Taenia solium (pork tape worm)

Life cycle



Pathology and Clinical features

Infection by larvae (cysticercosis). Cysticerci, generally multiple, may occur in any site but are more frequent in the brain and muscle. They excite reaction in the area, especially when they die, which manifests as inflammation, fibrosis and later some calcification. This leads to focal CNS syndromes, especially epilepsy.

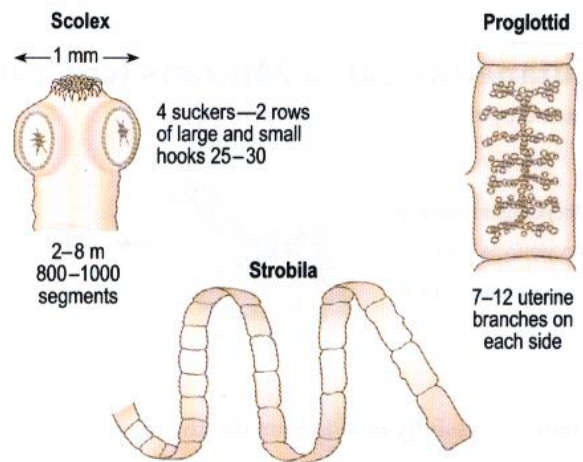
Infection with adults. Often there can be no pathology, but there might be mild irritation of intestinal mucosa.

Laboratory diagnosis

Eosinophilia.

Larval infections. There are several methods, including histological examination of biopsy material, serology (IFAT, ELISA, EITB) and radiology (CT or MRI scan of the brain, X-ray of the thigh muscles).

Pure infection with the adult. Gravid segments, ova and scolex can be found in faeces. The uterine branches of the mature segments can be demonstrated by injection of Indian ink through the uterine pore.

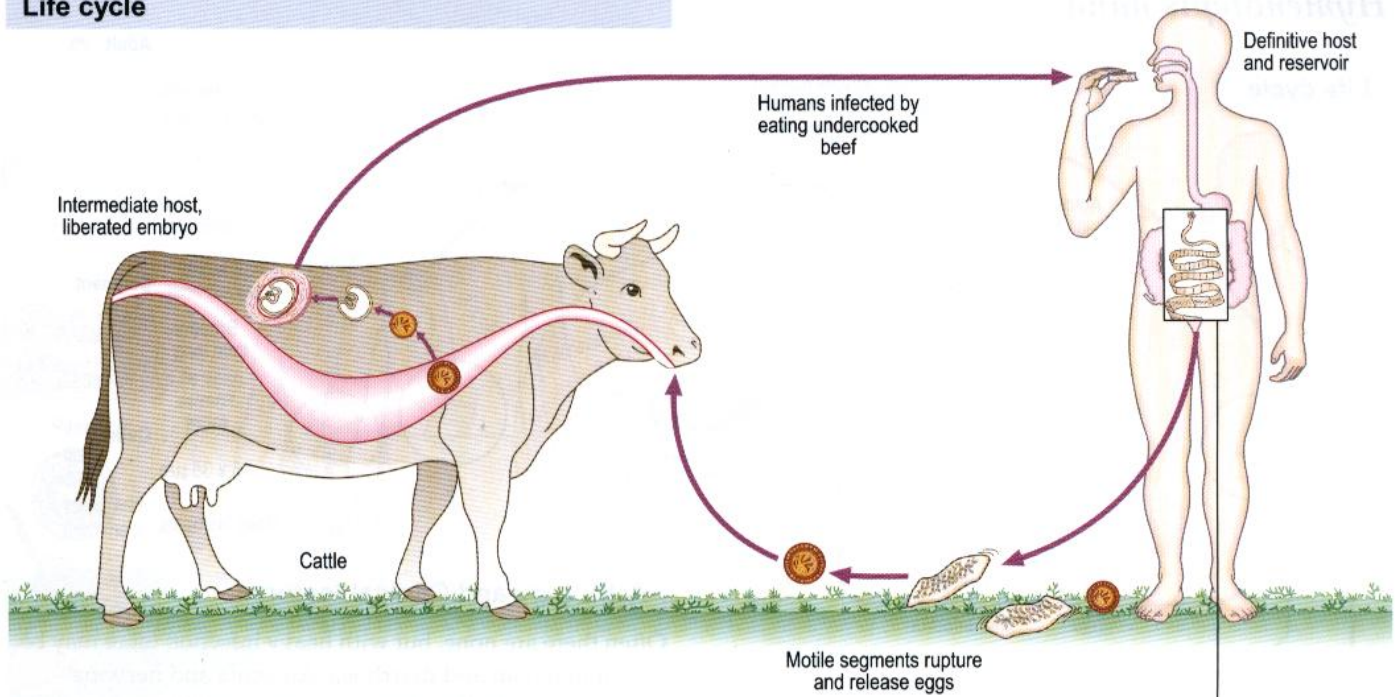


Distribution

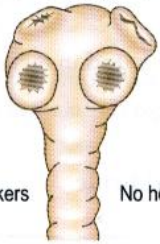
5 million people infected worldwide. *Taenia solium* is endemic in pig-rearing areas of the world where hygiene and animal husbandry are poor.

Taenia saginata (beef tape worm)

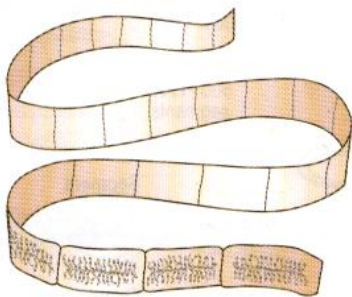
Life cycle



Scolex
1-2 mm



5-10 m
1000-2000 segments

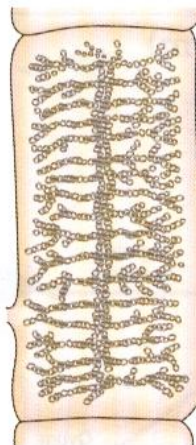

Strobila

Ovum
30-40 μm

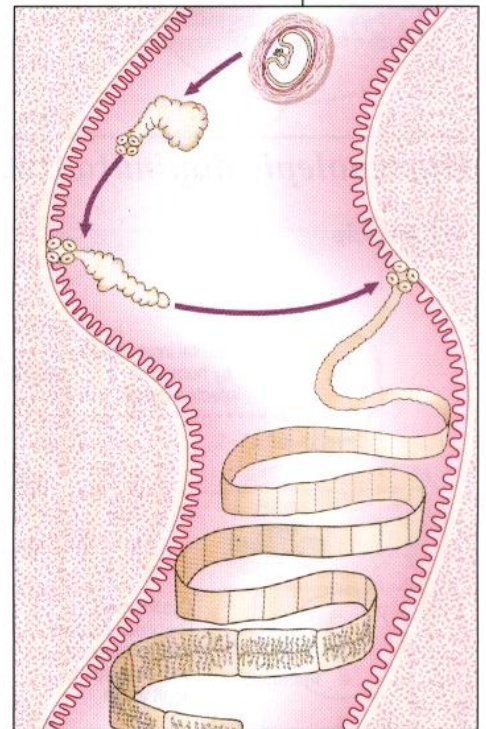


Gravid segment



Uterus with 15-30 lateral branches
16-20 x 5-7 mm

Scolex evaginates in small intestine and attaches itself to mucosa of jejunum



Maturation time 8-10 weeks.
Life span up to 25 years

Pathology and Clinical features

Usually there is no pathology as *Cysticercus bovis* is unknown in humans. Occasionally there is vague alimentary upset.

Laboratory diagnosis

Gravid segments, ova and scolex can be found in faeces. Uterine branches of the mature segments may be seen in a crush preparation between two glass slides, or by Indian ink preparation, as in *T. solium*. Ova are also found on the perianal skin (on clear adhesive tape slides).

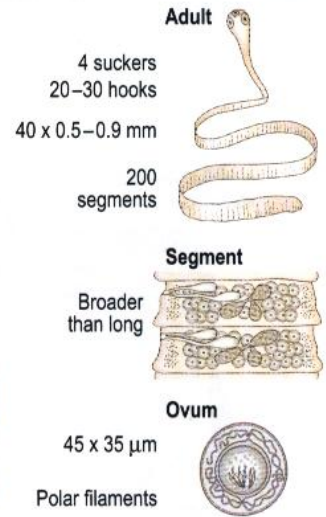
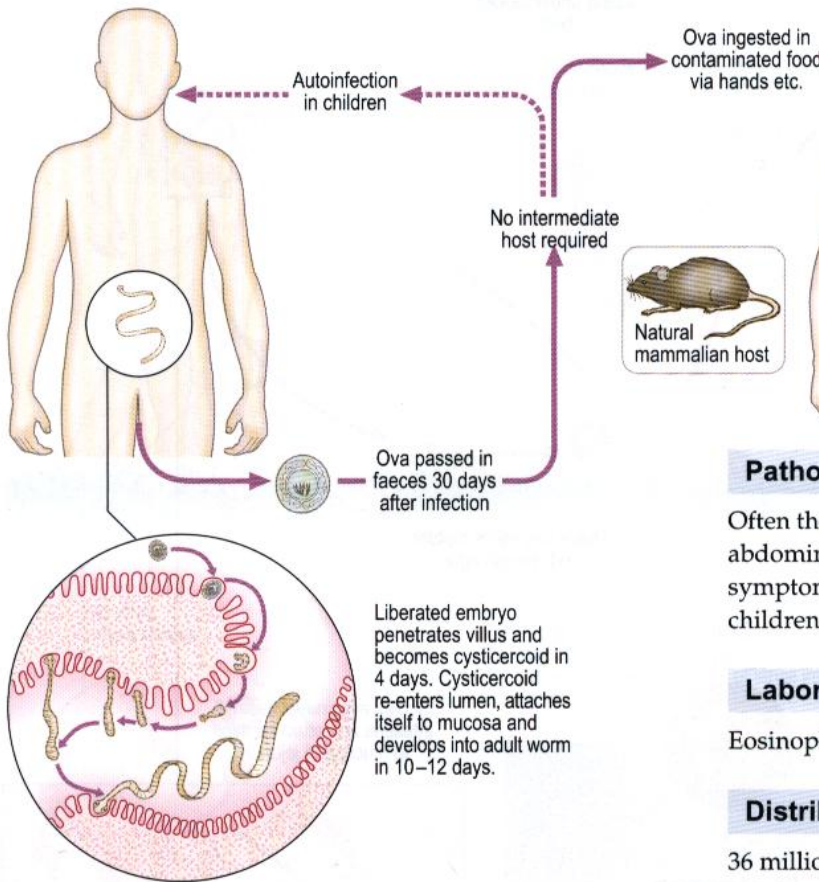
Distribution

Taenia saginata is found in beef-eating areas, especially in the tropics.

Dwarf tape worms

Hymenolepis nana

Life cycle



Pathology and Clinical features

Often there are none, but with heavy infection there may be abdominal pain and diarrhoea. Anaemia and nervous symptoms, including dizziness and irritability, can occur in children.

Laboratory diagnosis

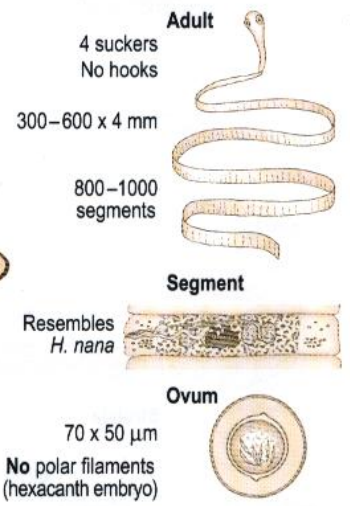
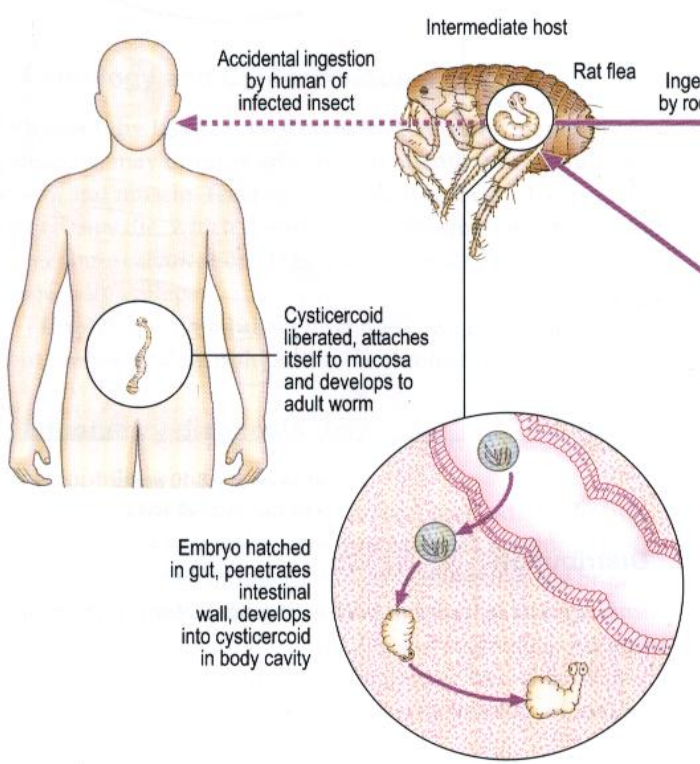
Eosinophilia may be present. Ova found in faeces.

Distribution

36 million people are infected worldwide.

Hymenolepis diminuta (rat tape worm)

Life cycle



Pathology and Clinical features

Generally there is no effect on the host.

Laboratory diagnosis

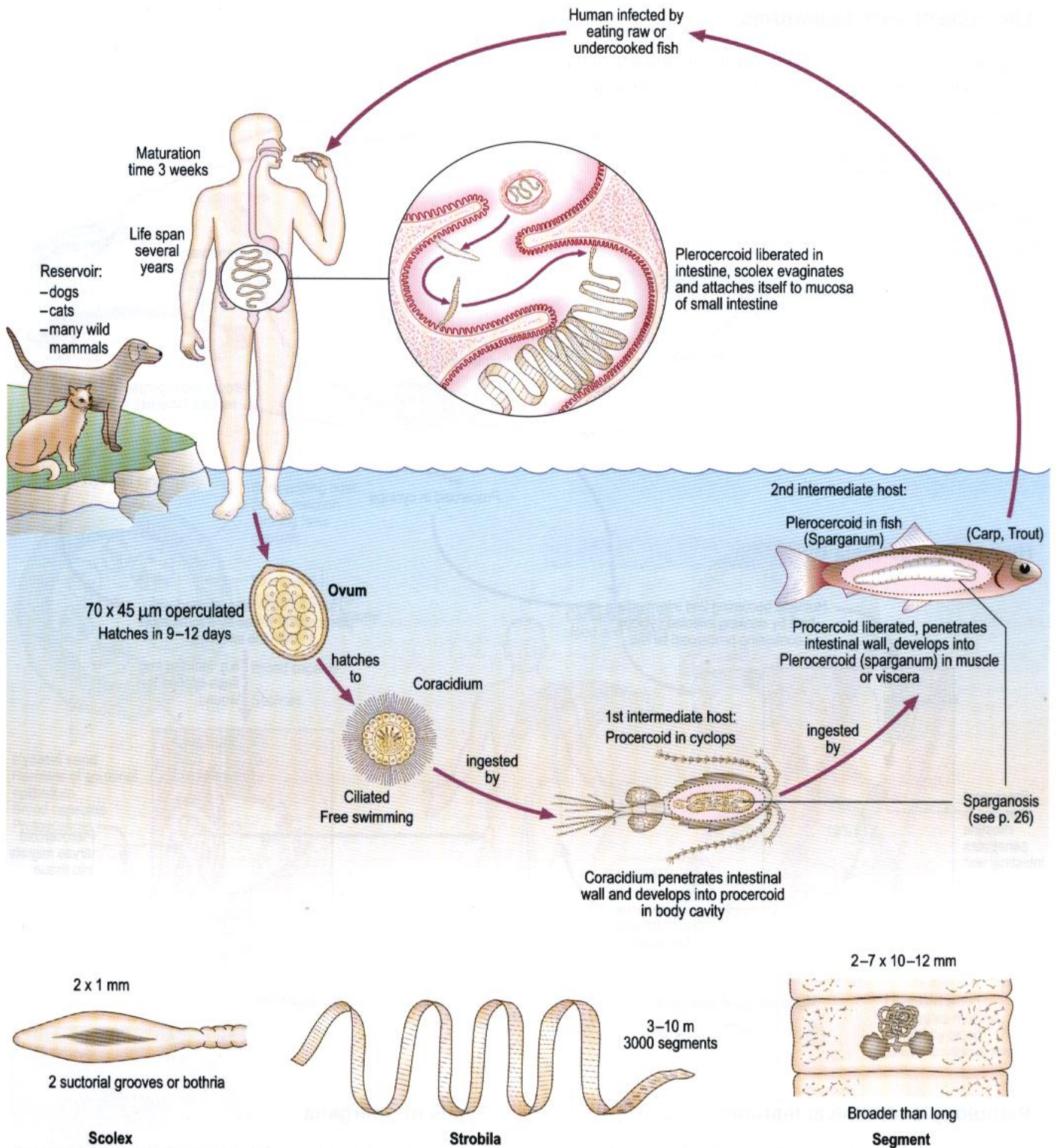
Ova in faeces.

Distribution

Worldwide, but rare in humans.

Diphyllobothrium latum (fish tape worm)

Life cycle



Pathology and Clinical features

Generally there is none, but occasionally there can be megaloblastic anaemia (through absorption of vitamin B₁₂ by the worm).

Laboratory diagnosis

Eggs and gravid segments can appear in faeces. Megaloblastic anaemia (low serum B₁₂).

Distribution

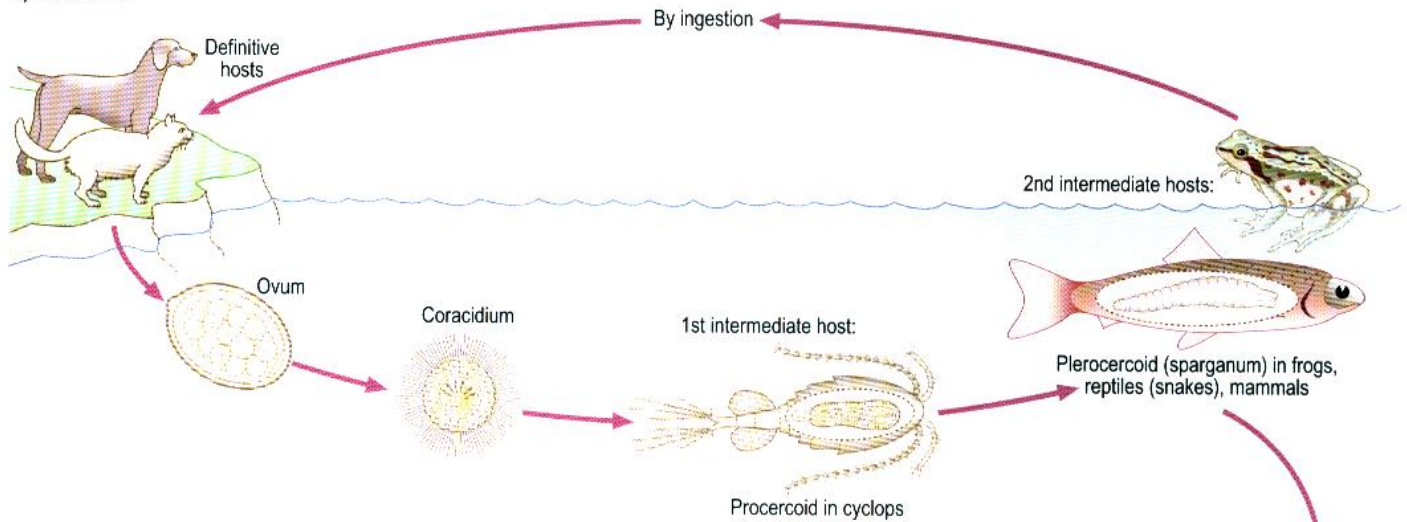
16 million infected worldwide in eastern seaboard of Canada and America, Brazil, Baltic States, parts of West Africa, North Siberia and South East Asia.

Larval forms of cestode infection in humans


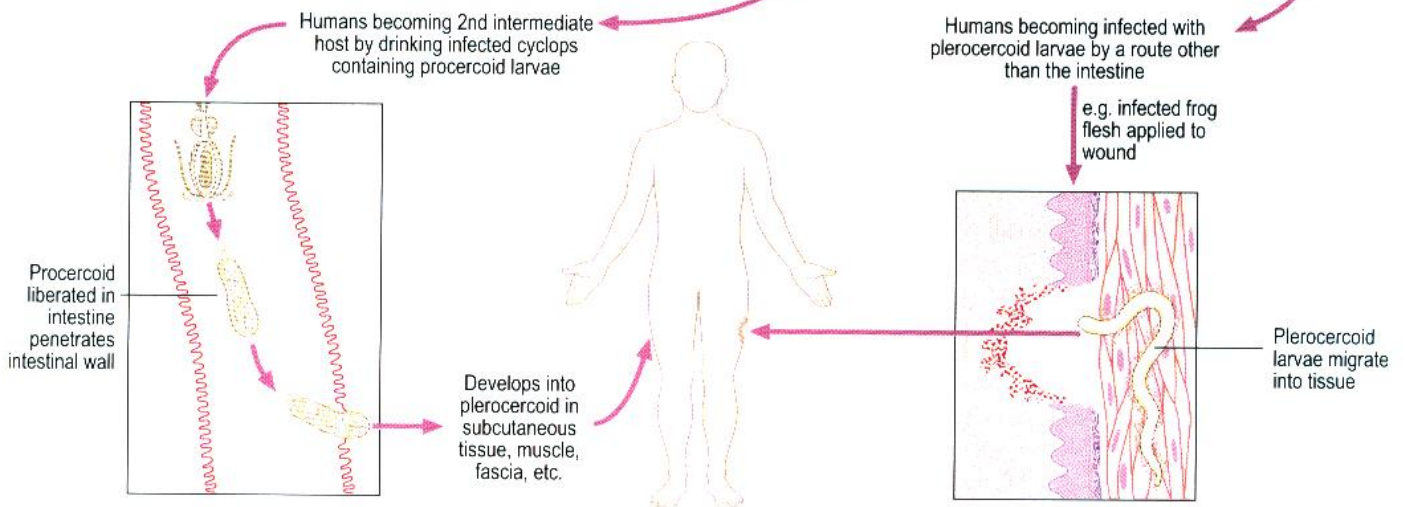
Sparganosis

Life cycle of such tapeworms

Sparganosis is caused by the extra-intestinal presence in the human body of larvae of non-human tapeworms of the genus *Spirometra*.



Human sparganosis by



Pathology and Clinical features

Infestation with living larvae causes a painful oedematous reaction. Dead larvae cause intense local inflammatory reactions. There are numerous eosinophils and there can be abscess formation. There can be ocular sparganosis in the soft tissues near the eye, resulting in severe damage. Invasion of the CNS may occur.



Types of spargana

Most *Spargana* do not proliferate in human tissues. *Sparganum proliferum* is a very rare parasite in which sparganum proliferates by lateral budding.

Laboratory diagnosis

Diagnosis of the disease is by examination of biopsy material or excised larvae.

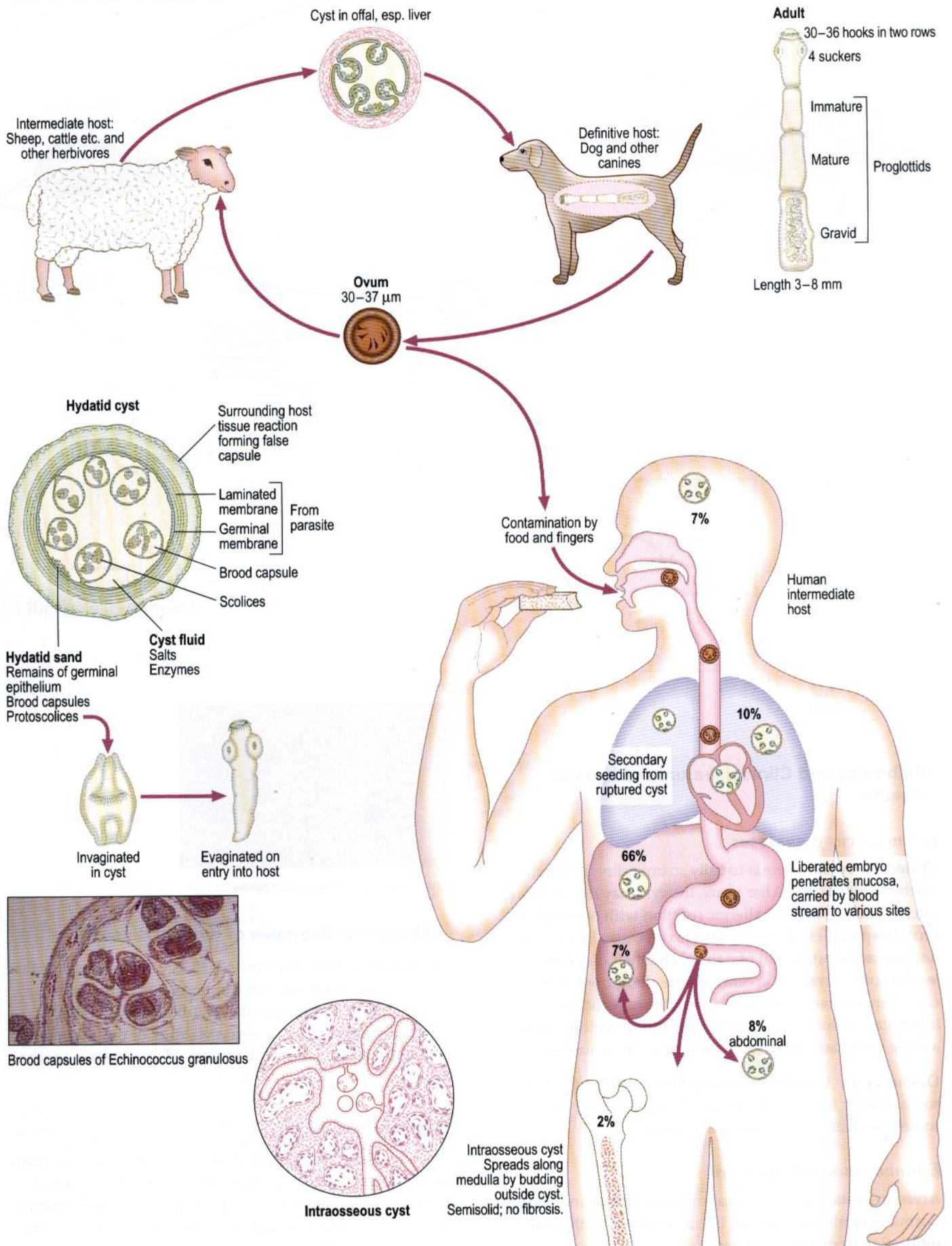
Distribution

The Far East mainly but occasionally elsewhere.

Echinococcus granulosus (dog tape worm)

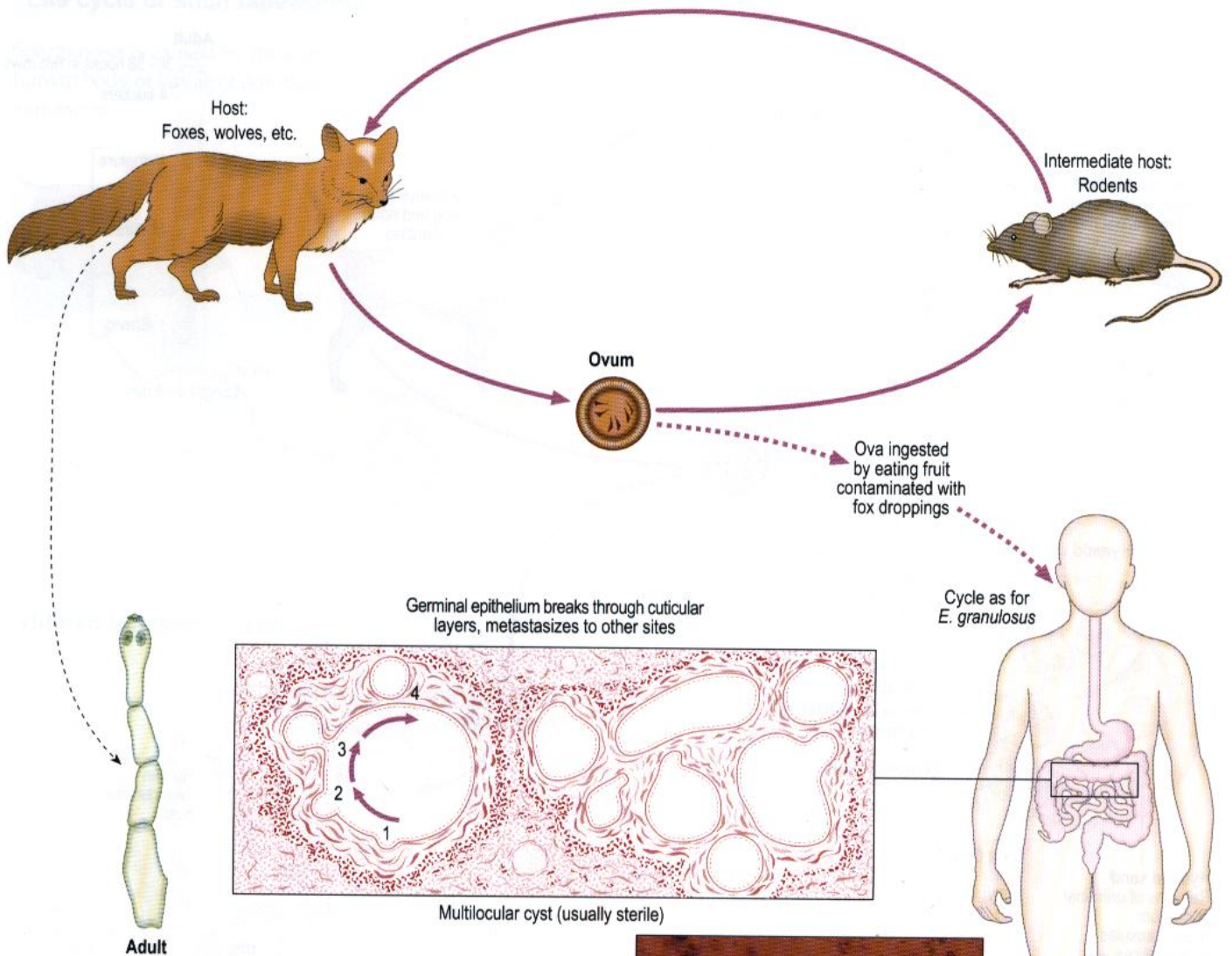
Life cycle

Echinococcus granulosus causes hydatid disease.



Echinococcus multilocularis

Life cycle



Pathology and Clinical features of hydatid disease

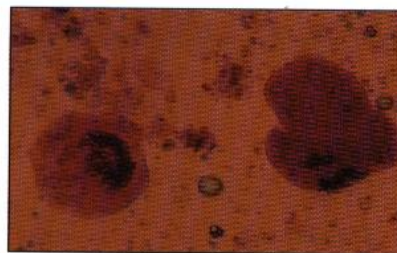
Echinococcus granulosus

Unilocular cysts. There is usually surrounding inflammatory reaction and fibrosis. After years, the cyst may die, shrink and calcify. There is general allergic reaction with eosinophilia, bronchospasm, etc. Pressure effects can cause local tissue damage and obstruction of natural channels. Rupture or leakage of the cyst can accentuate the allergic reaction. There can be anaphylactic shock and sometimes secondary implantation, for example in the peritoneal region. There can also be secondary infection with formation of abscess.

Osseous cysts. Usually there is no fibrosis although there is some cellular infiltration. Destruction of the bone can sometimes lead to spontaneous fracture.

Echinococcus multilocularis

Alveolar cysts. There are local pressure effects and allergy. Germinal epithelium can act like a neoplasm with local infiltration or distant metastases.



Eosin penetration of dead protoscolices

Laboratory diagnosis of hydatid disease

Use serological tests on serum (e.g. ELISA, complement fixation, counter current immunoelectrophoresis for Arc 5 or immunoblot). Microscopy of cyst fluid from operative specimens can be used to assess viability of protoscolices. Histological examination of a removed specimen is another possibility.

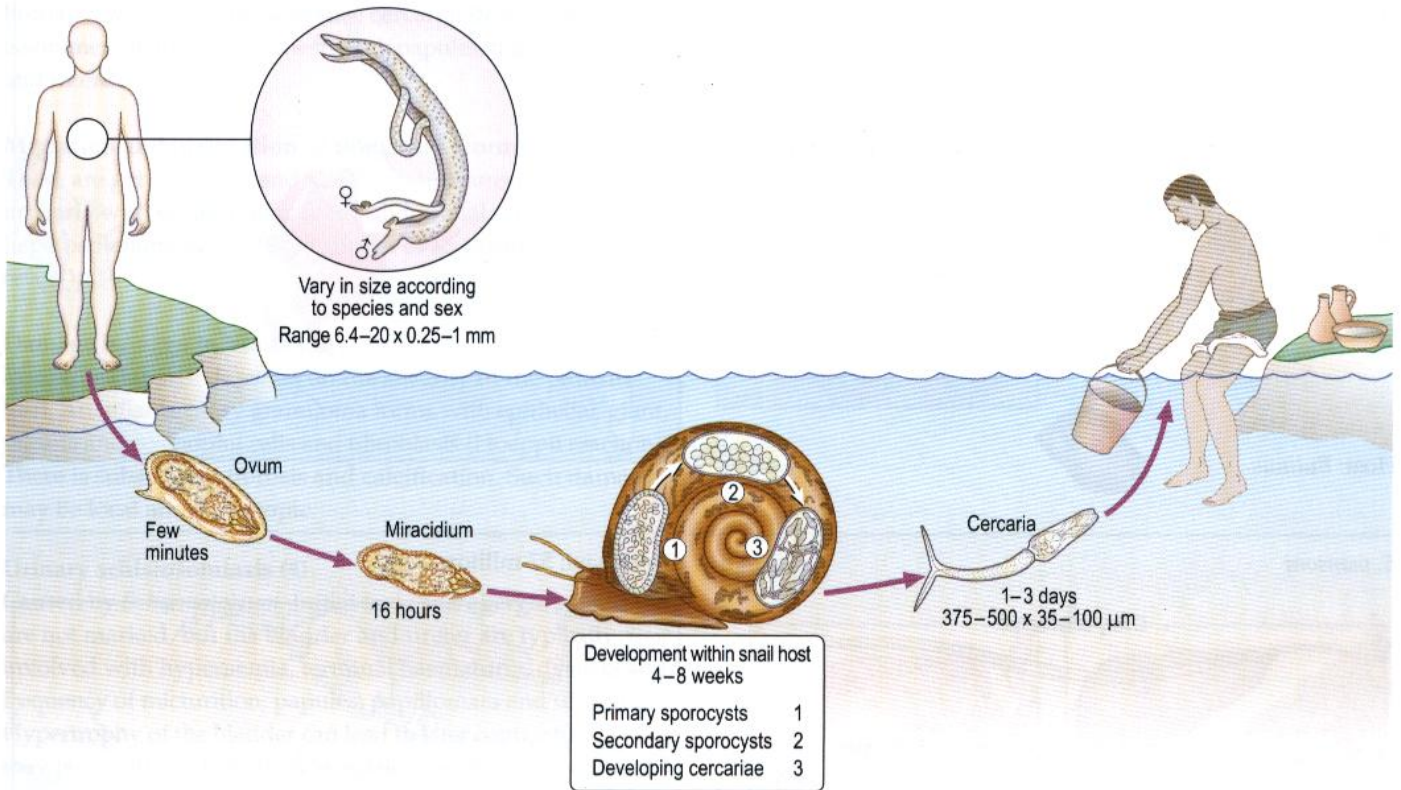
Distribution

1 million infected worldwide. *E. multilocularis* is rare in humans, but occurs in Northern Europe, Asia, North America and Arctic regions. *E. granulosus* is widespread in sheep-rearing areas of the world. Eradication is well advanced in Australia and New Zealand.

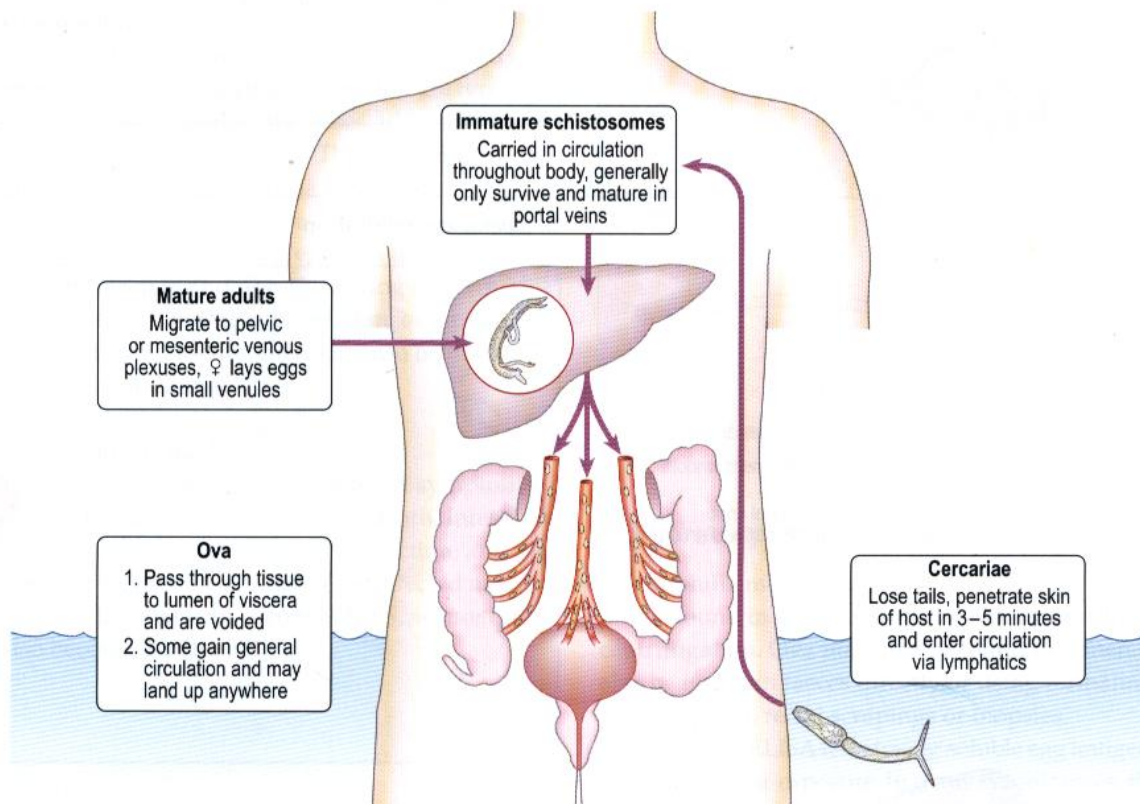
Trematode (flat) worms

Schistosoma species (blood flukes)

Life cycle for all species



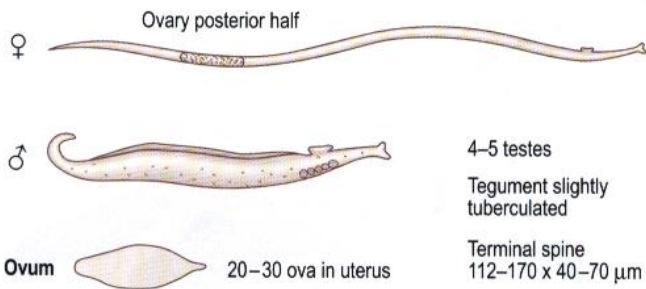
Life cycle in humans



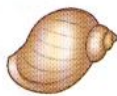Schistosoma species (blood flukes) (Continued)

Morphology

S. haematobium

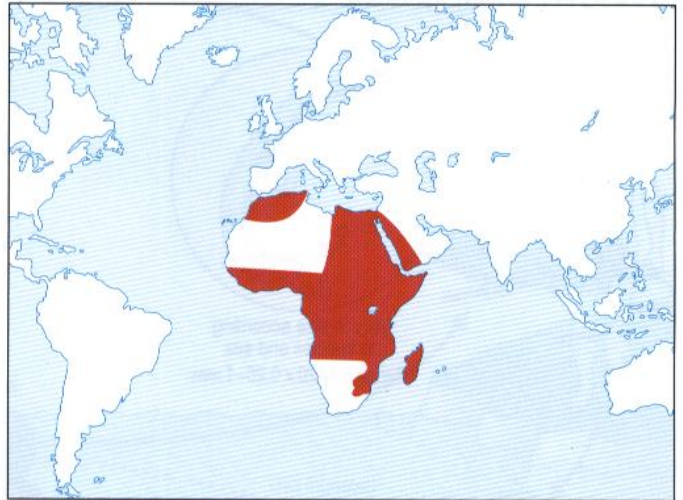


Host: *Bulinus*

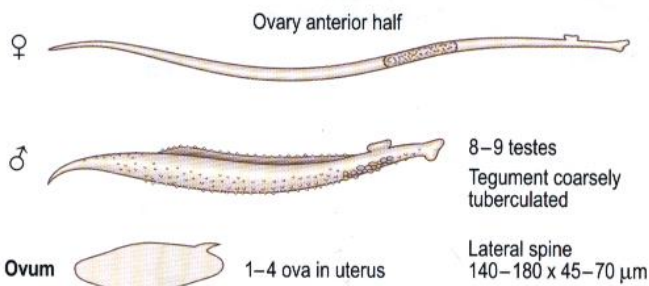


Distribution

S. haematobium: 78 million



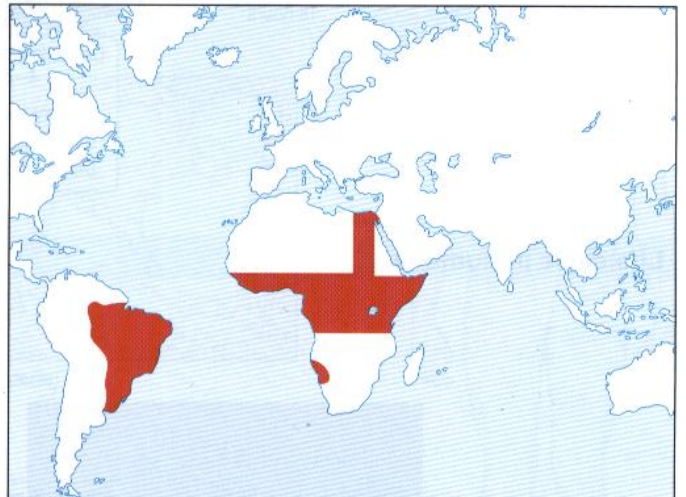
S. mansoni



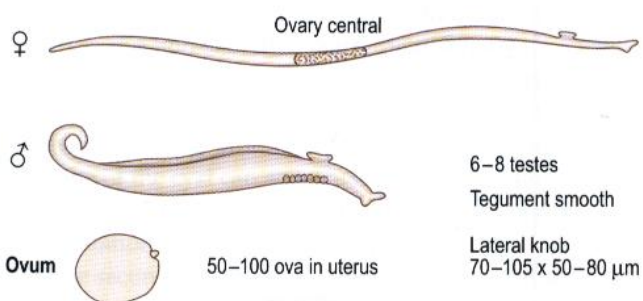
Host: *Biomphalaria*



S. mansoni: 57 million



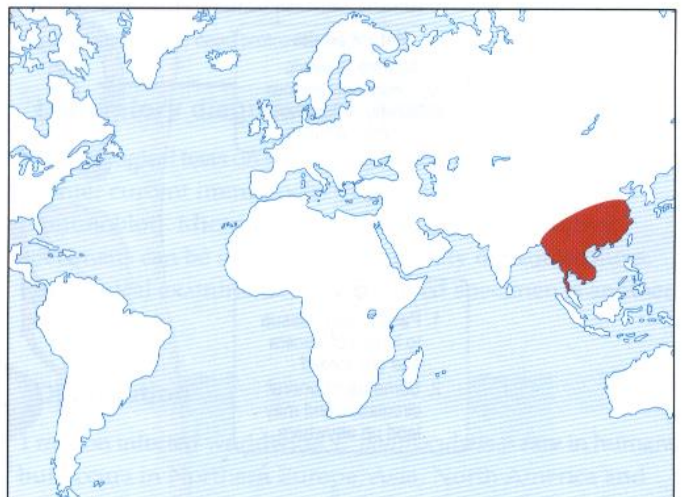
S. japonicum



Host: *Oncomelania*



S. japonicum: 69 million



Schistosomiasis

Pathology

Penetration of the skin by cercariae (1)

Skin penetration may not be apparent. Human and some non-human *Schistosoma* species cause cercarial dermatitis (swimmer's itch). This manifests with papules, macules, vesicles and intense itching.

Migration and maturation of immature worms (2)

There are general toxic and allergic symptoms including urticaria with eosinophilia, fever, abdominal pain and tender hepatosplenomegaly. This is known as Katayama or snail fever.

Damage by eggs in tissue (3)

Resulting damage depends on the severity of the parasite load. An inflammatory granuloma forms with epithelial, giant, plasma and eosinophil cells and fibroblasts (Hoeppli reaction). There is subsequent fibrosis and calcification. Such damage may be local and/or ectopic.

Urinary schistosomiasis (4)

Caused by *S. haematobium*. Initial toxic and allergic symptoms are not marked, but the bladder and ureter are typically involved with hyperaemia, terminal haematuria, dysuria and frequency of micturition, papules, papillomata and ulceration. Hypertrophy of the bladder can lead to later contraction. There may be cystitis and calculus formation, with calcification and squamous cell carcinoma. Fistulae may develop. There can also be hydronephret and hydronephrosis. Ectopic lesions are less severe than in other species. Genital schistosomiasis may lead to lumpy semen, haemospermia or wart-like lesions on the vulva.

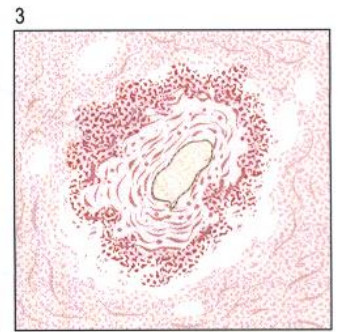
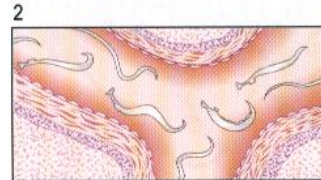

Intestinal schistosomiasis (5)

Caused by *S. mansoni*. There are marked initial toxic and allergic symptoms. The large intestine and rectum are typically involved with polyposis, papules, abscesses, ulcers, papillomata, fistulae and ova in faeces. The bladder is sometimes involved, with pathology as for urinary schistosomiasis as above. There can be ectopic lesions; the liver is frequently involved (receiving eggs via the portal vein with inflammatory reaction and fibrosis leading to periportal ('pipe-stem') fibrosis with portal hypertension, oesophageal varices, splenomegaly and ascites; there can also be lesions in the brain, spinal cord and lungs).

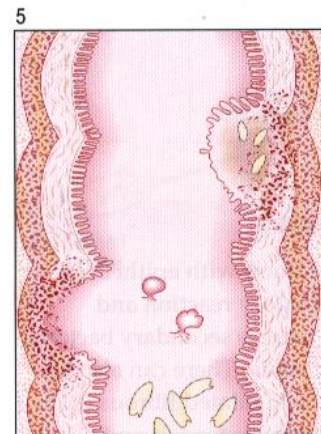
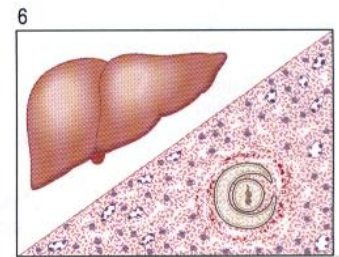
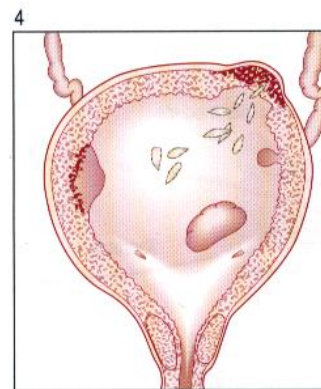Oriental schistosomiasis (6)

Caused by *S. japonicum*. Initial toxic and allergic symptoms are marked and can lead to myocarditis and death. Intestinal lesions are similar to those with *S. mansoni* infection, and the small intestine is often involved. The liver is infected as in *S. mansoni*. Hepatic involvement occurs as for *S. mansoni*. The brain may also become involved.

General



Particular



Laboratory diagnosis

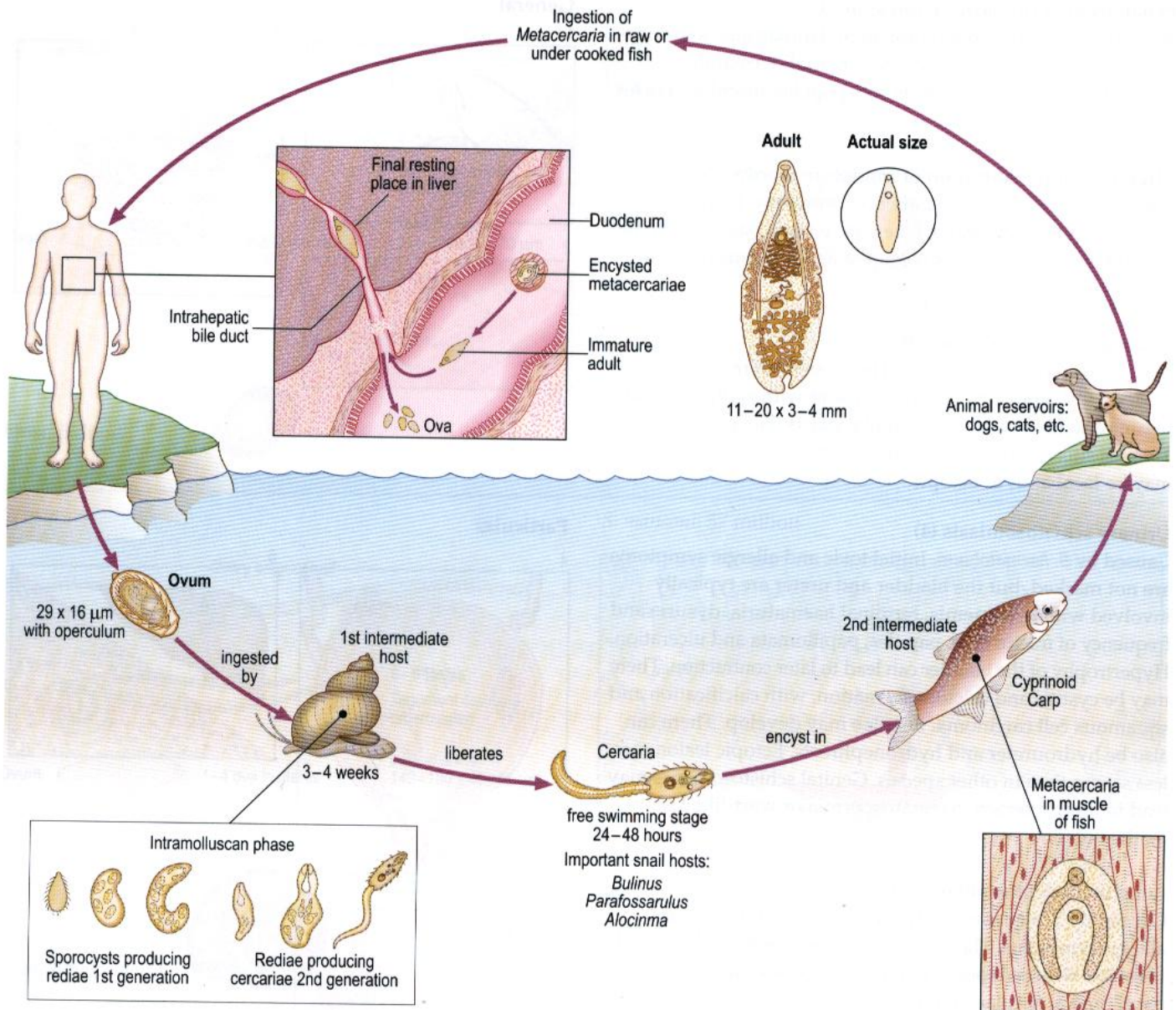
Eosinophilia may be present.

Ova found in terminal urine by Nuclepore filtration or after centrifugation. Ova may also be found in semen. Ova may also be found in faeces directly or using formalin-ether concentration, rectal scrapings or biopsies.

Serology. ELISA tests (using soluble egg antigen) are useful 6–12 weeks post-exposure. In many chronic cases, the diagnosis will be made by serology alone.

Clonorchis sinensis, syn. *Opisthorchis sinensis* (Oriental liver fluke)

Life cycle



Pathology and Clinical features

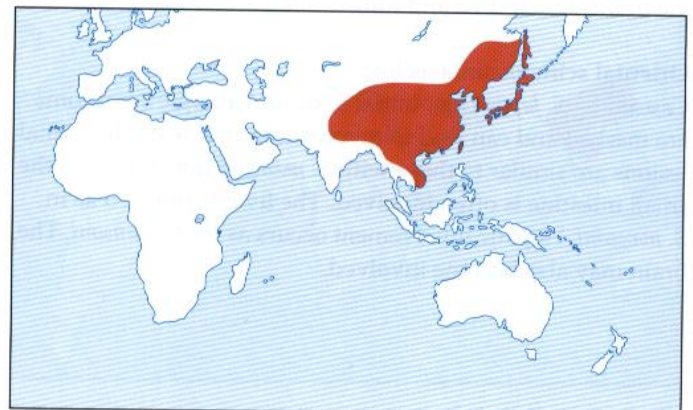
Adult flukes inhabit the distal bile ducts with epithelial proliferation, surrounding inflammatory reaction and ascending cholangitis. Sometimes there is secondary bacterial infection with jaundice and septicaemia. There can also be eosinophilia. All this can lead to thick, dilated fibrous ducts with adenomata of epithelium, bile duct stenosis and cholangiocarcinoma. Many cases are asymptomatic. Acute infection may lead to tender hepatomegaly. Chronic infection can result in anorexia, low-grade fever, epigastric pain and tender hepatomegaly.

Laboratory diagnosis

Ova are found in faeces and in bile (via duodenal aspiration or 'string test').

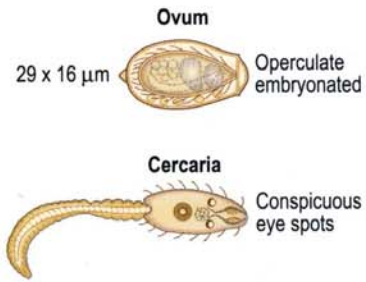
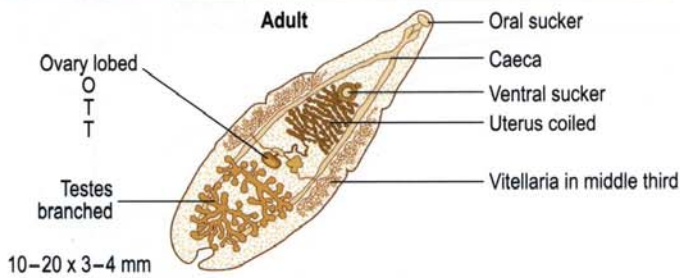
Distribution

28 million infected worldwide.



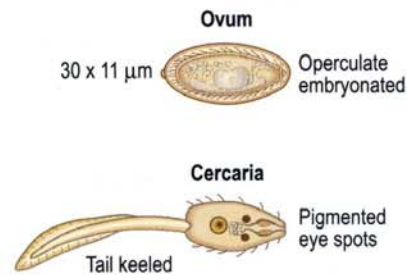
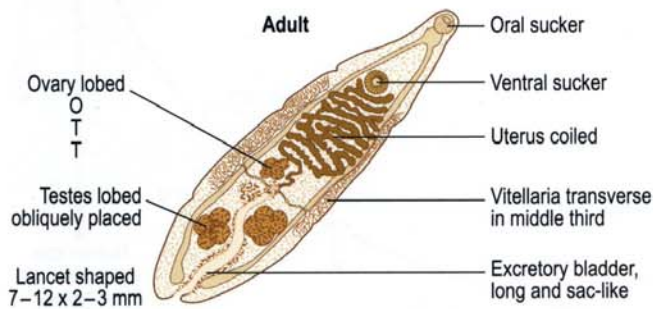
Clonorchis sinensis (continued)

Morphology

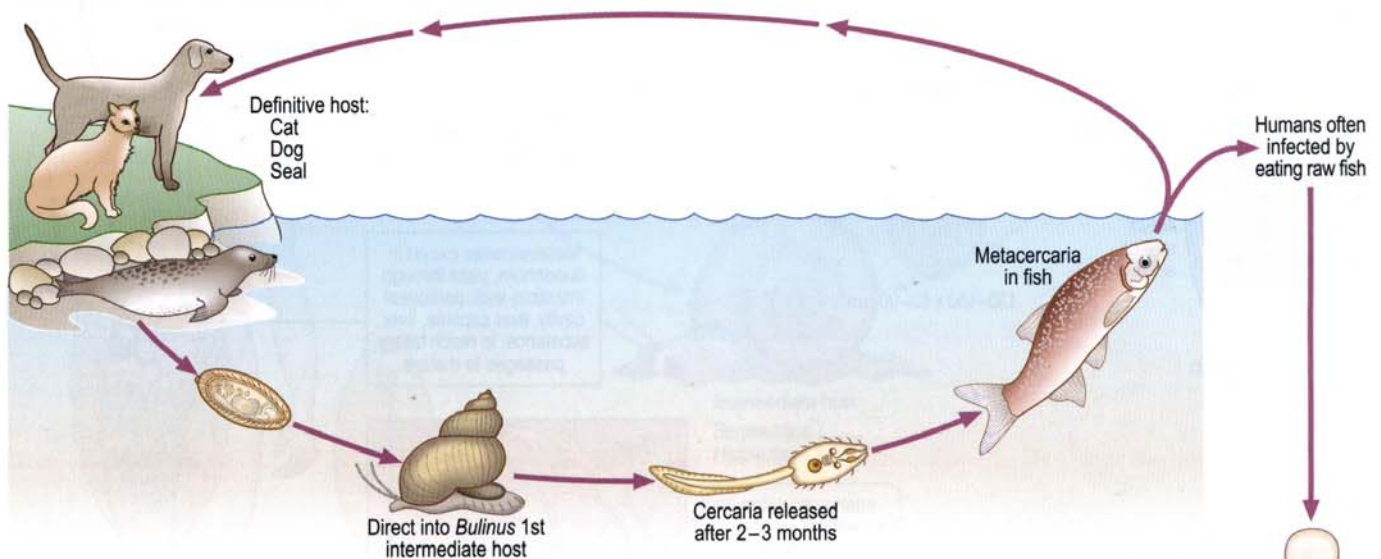


Opisthorchis felineus, Opisthorchis viverrini (cat liver fluke)

Morphology



Life cycle



Pathology and Clinical features

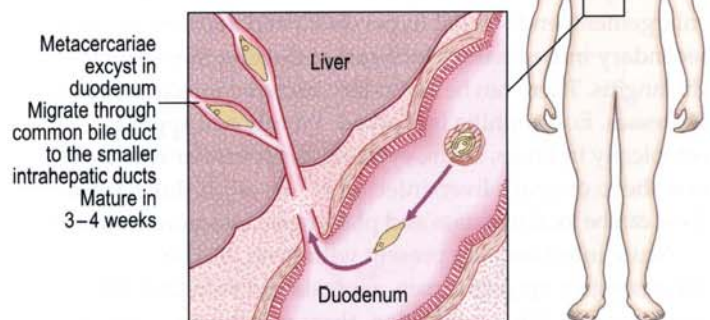
There are proliferative changes in the bile ducts. If the infection is massive or repeated then there may be chronic cholangitis. Clinical features are similar to those of clonorchiasis.

Laboratory diagnosis

Ova can be found in faeces.

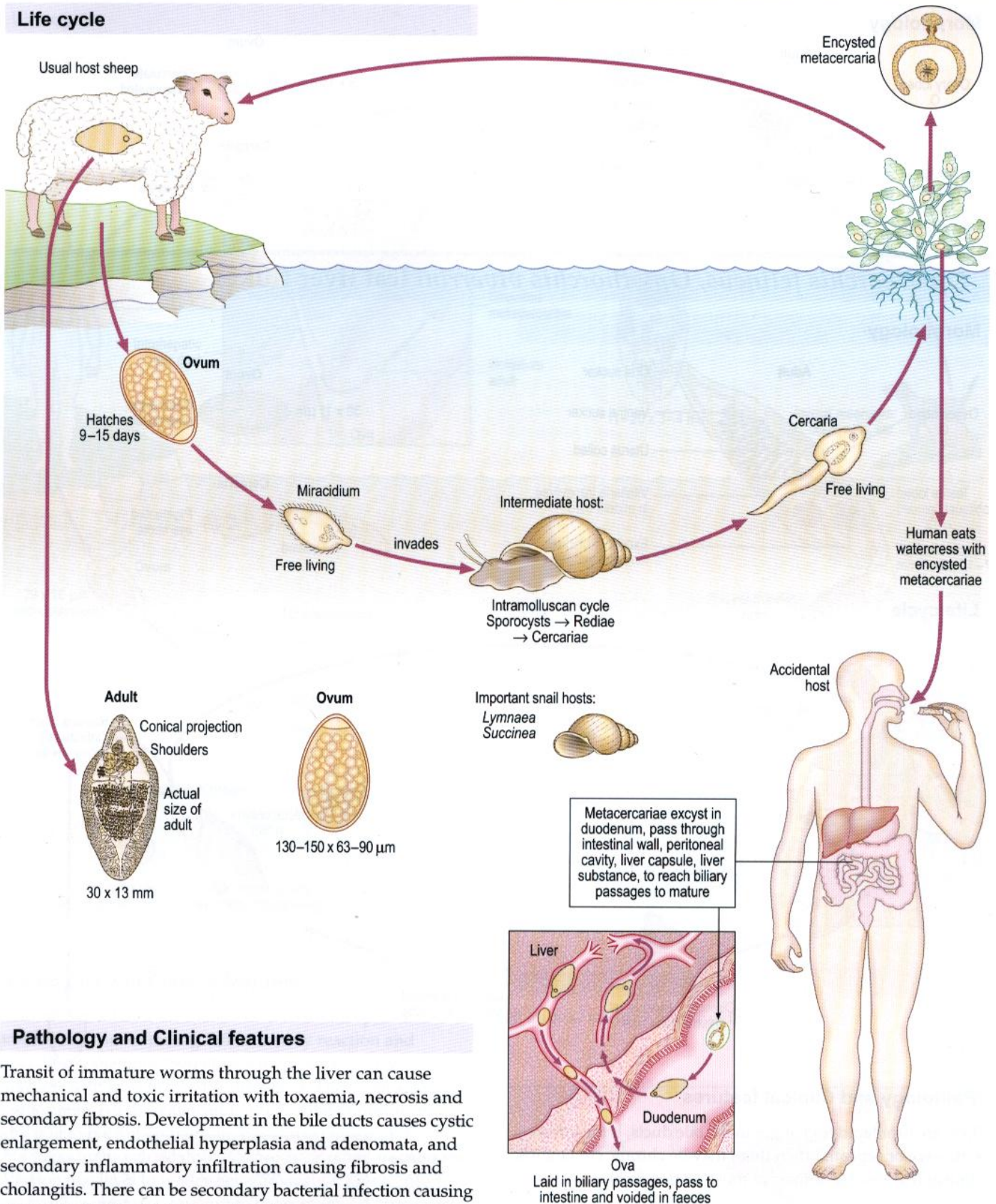
Distribution

O. felineus is found mainly in Eastern Europe and Russia.
O. viverrini occurs in Thailand.



Fasciola hepatica (sheep liver fluke)

Life cycle



Pathology and Clinical features

Transit of immature worms through the liver can cause mechanical and toxic irritation with toxæmia, necrosis and secondary fibrosis. Development in the bile ducts causes cystic enlargement, endothelial hyperplasia and adenomata, and secondary inflammatory infiltration causing fibrosis and cholangitis. There can be secondary bacterial infection causing abscesses. Eosinophilia is marked. Worms can appear ectopically in lungs, brain, eyes, etc. with similar reactions. If raw sheep or goat's liver, infected by the adult fluke, is eaten there can be local irritation and pharyngeal infection (Halzoun).

Acute infection may present with fever, tender hepatomegaly, epigastric pain, anorexia and vomiting. Jaundice may occur. In chronic infection, there may be no symptoms or epigastric/right upper quadrant pain, hepatomegaly and vomiting.

Laboratory diagnosis

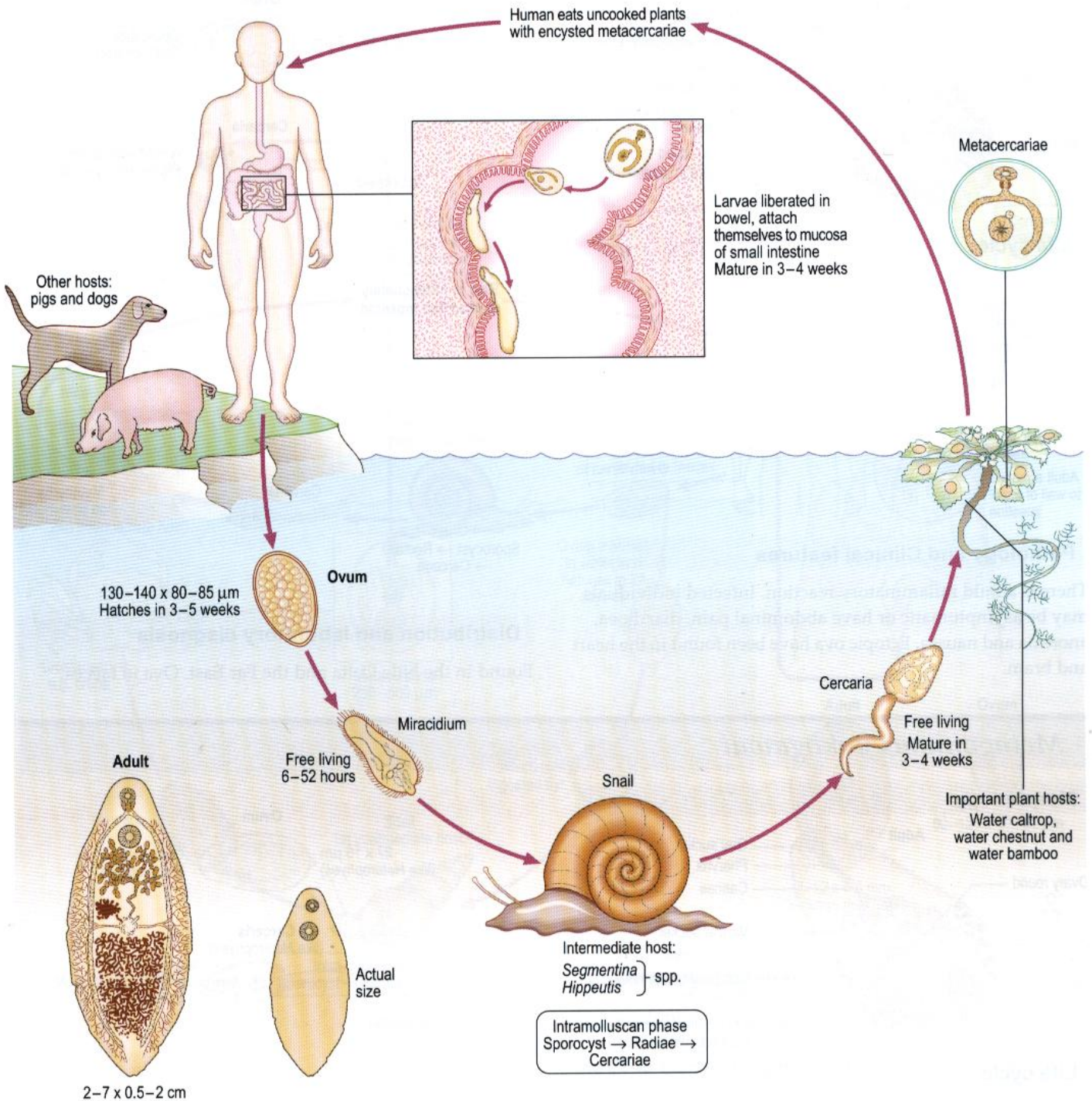
Ova are found in faeces. Serology (IFAT) is available.

Distribution

The fluke is found in all sheep-rearing countries. About 1 million people are infected worldwide.

Fasciolopsis buski

Life cycle



Pathology and Clinical features

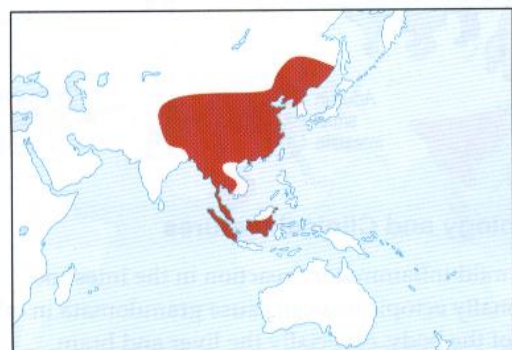There is localized inflammation at the site of attachment with haemorrhages and occasional abscesses. There is also eosinophilia. Lightly infected individuals may be asymptomatic. Diarrhoea, abdominal pain, anorexia, nausea and vomiting may occur.

Laboratory diagnosis

Ova, and sometimes adults, are found in faeces.

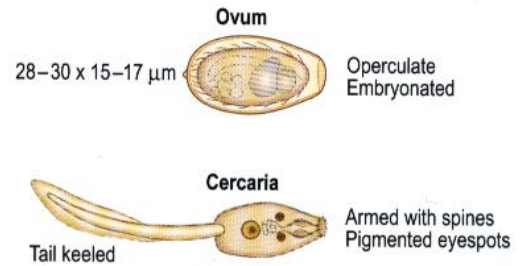
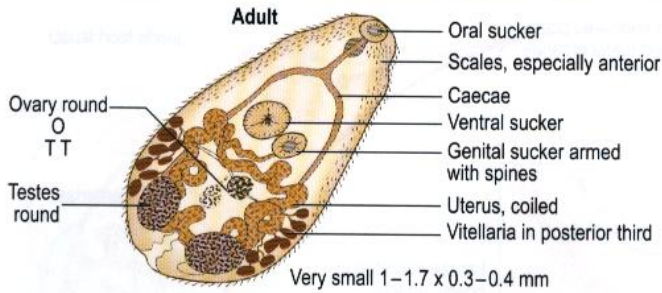
Distribution

15 million infected worldwide.

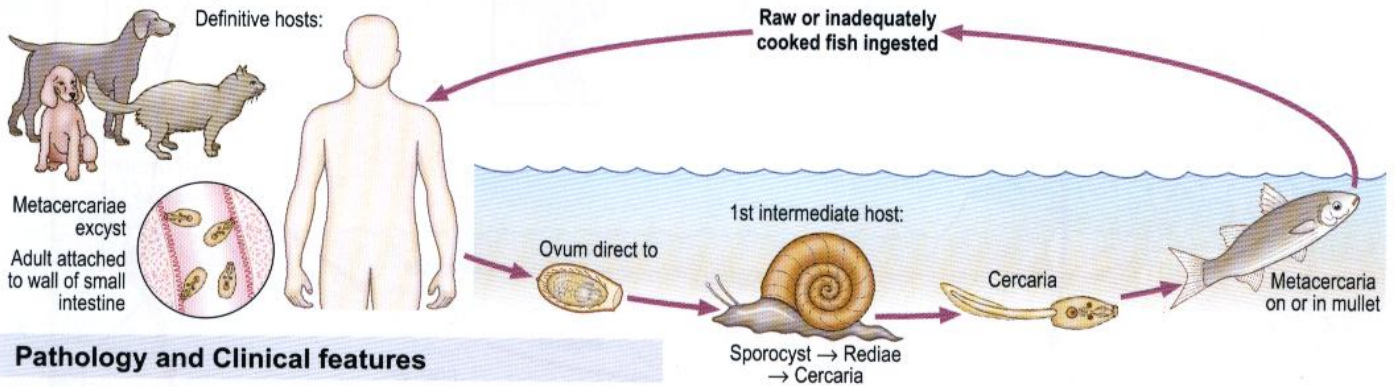


Heterophyes heterophyes

Morphology



Life cycle



Pathology and Clinical features

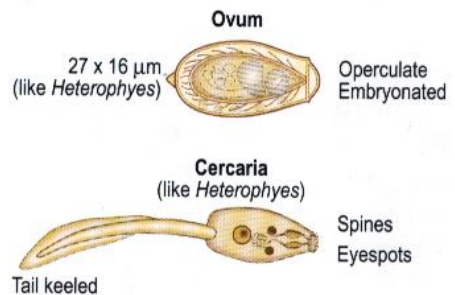
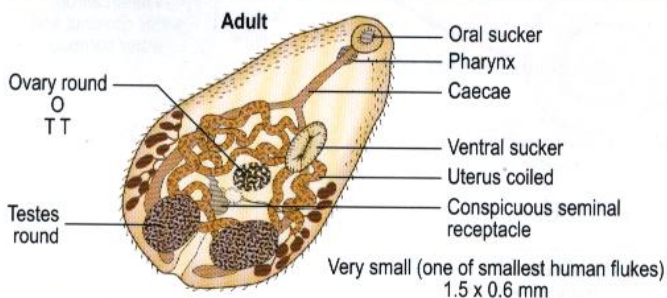
There is a mild inflammatory reaction. Infected individuals may be asymptomatic or have abdominal pain, diarrhoea, anorexia and nausea. Ectopic ova have been found in the heart and brain.

Distribution and laboratory diagnosis

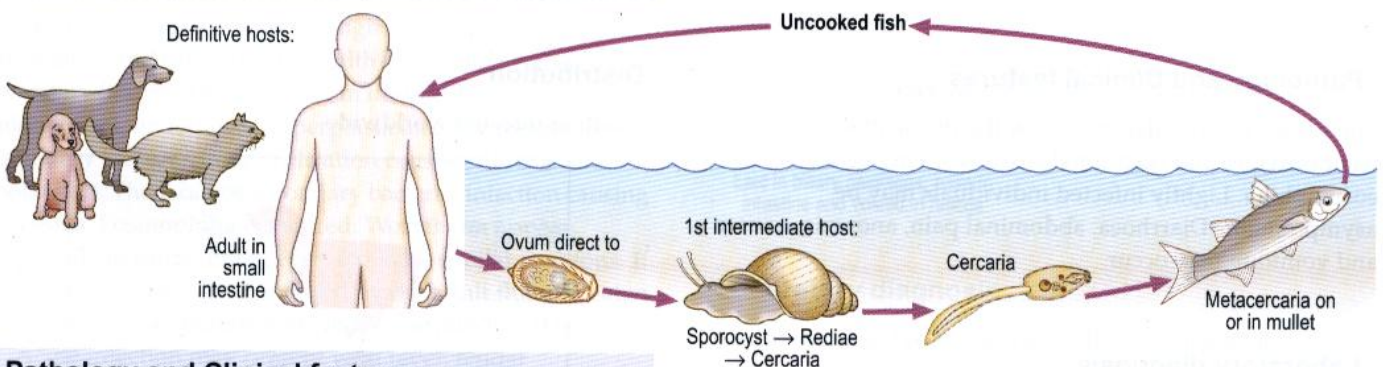
Found in the Nile Delta and the Far East. Ova in faeces.

Metagonimus yokogawai

Morphology



Life cycle



Pathology and Clinical features

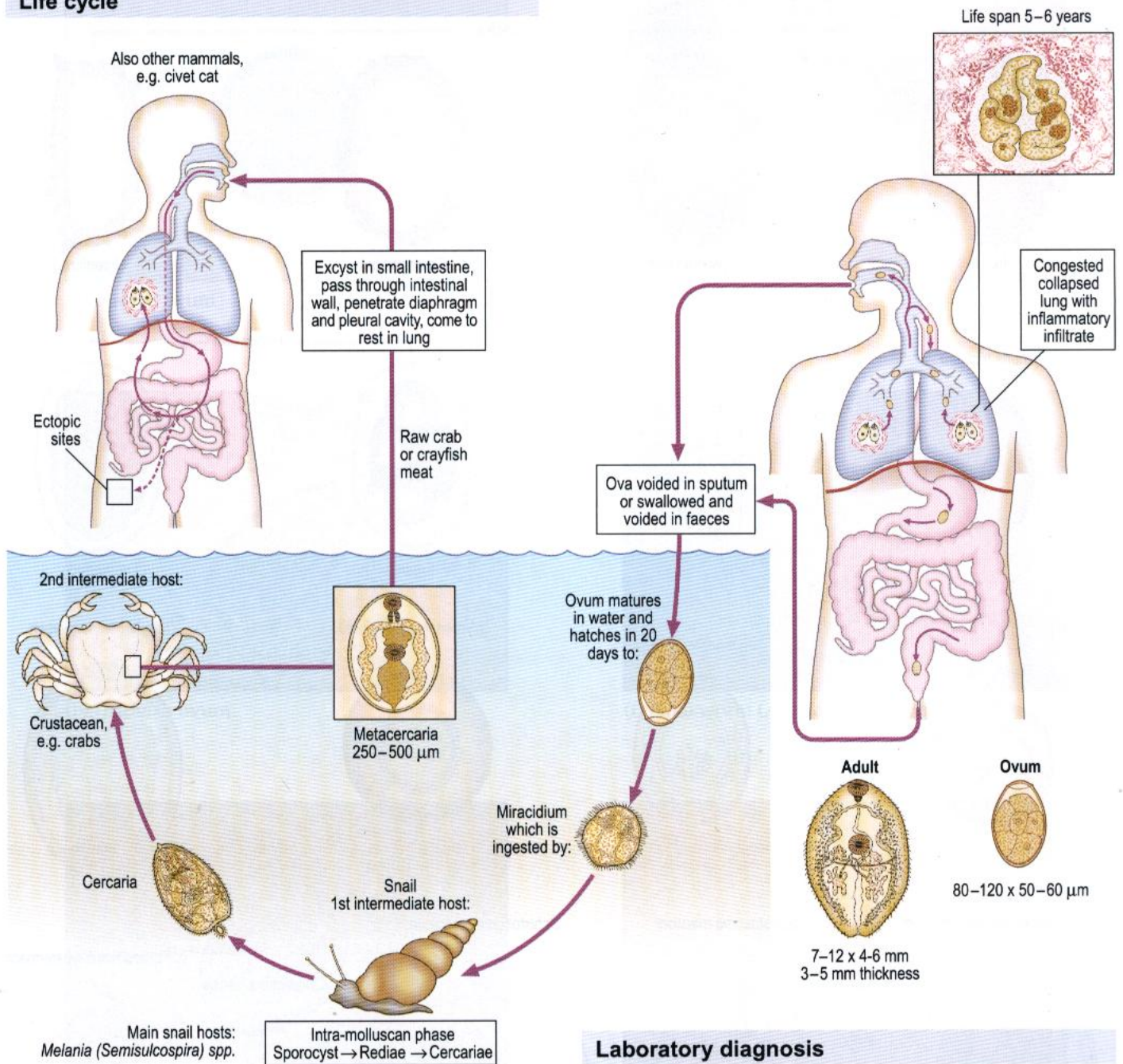
Causes mild inflammatory reaction in the intestine. Occasionally ectopic ova can cause granulomata in other organs of the body, especially the liver and brain.

Distribution

Prevalent in the Far East.

Paragonimus westermani (lung fluke)

Life cycle



Pathology and Clinical features

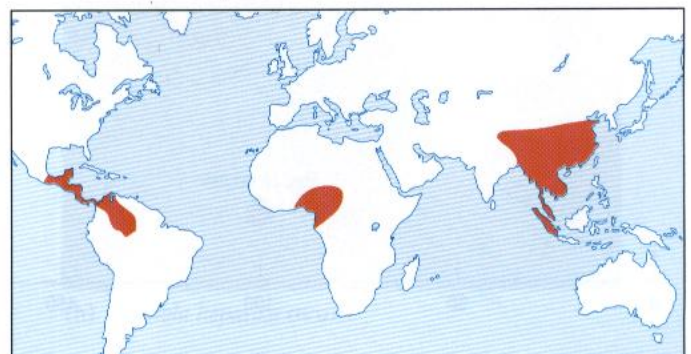The initial invasion has little pathological effect on the host. On localization in the lungs, there is tissue reaction leading to formation of a fibrous tissue capsule (of a slate blue colour) containing worms (generally in pairs), ova and inflammatory infiltrate. The capsule is connected with the respiratory passages. Secondary complications of these lung cysts include bronchiectasis, abscess formation and haemoptysis. Localization in other sites can cause cysts in any part of the body (for example the brain, causing epilepsy). Eosinophilia is a general manifestation. Chronic infection may be asymptomatic. Cough, brown gelatinous sputum, chest discomfort, shortness of breath and pleuritic chest pain may occur.

Laboratory diagnosis

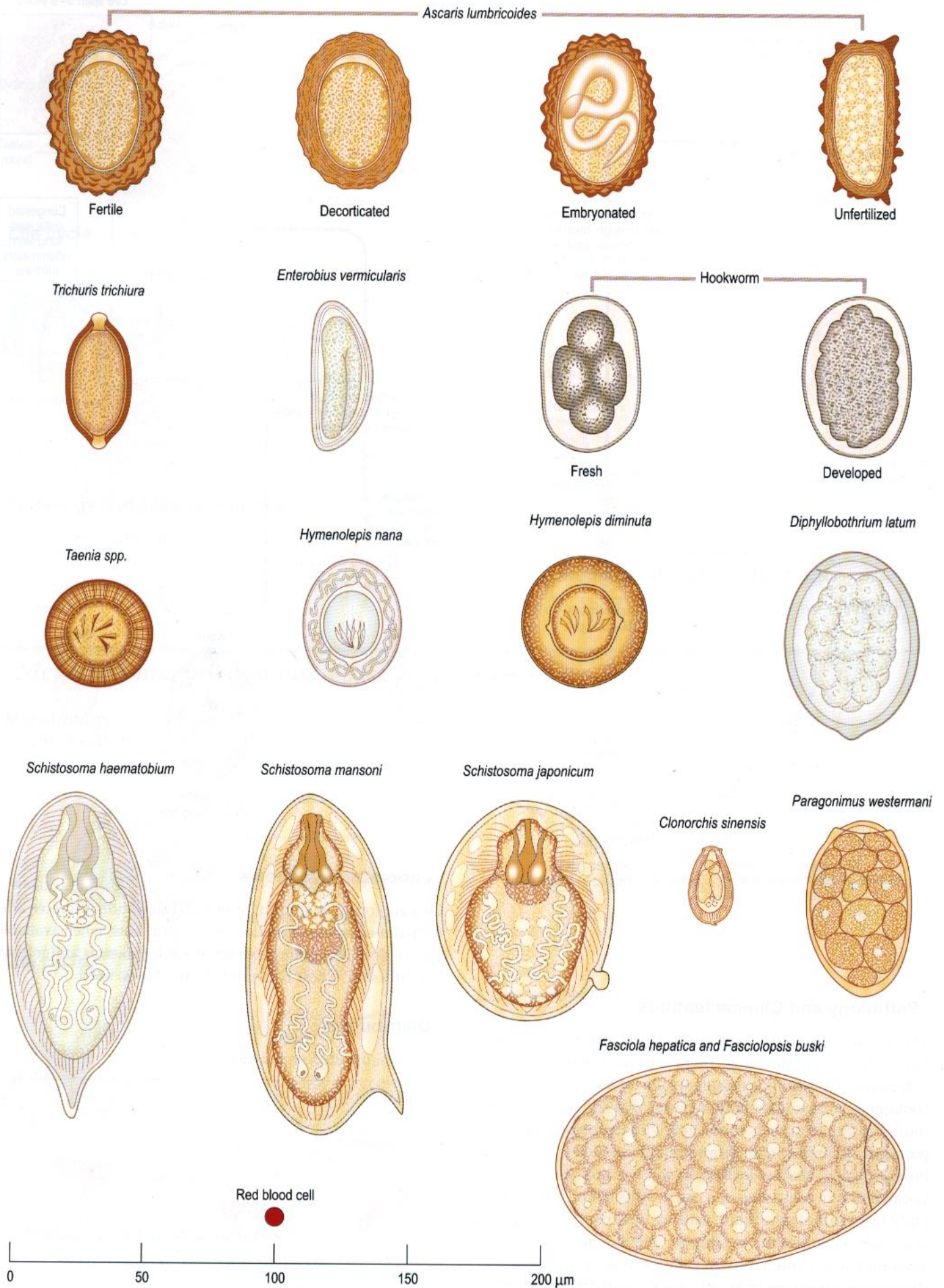
Ova are found in sputum after KOH digestion or faeces after formalin-ether concentration. Serological tests, when available, are CF or ELISA (using extract of adult flukes as antigen) or gel diffusion. Chest X-ray or CT can also be used.

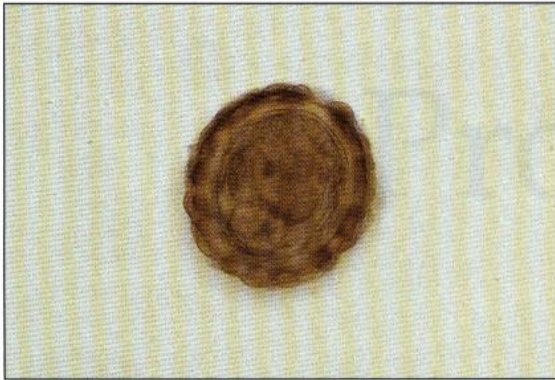
Distribution

5 million infected worldwide.

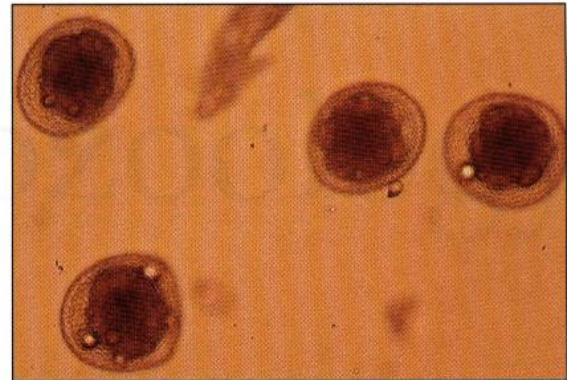


Common helminth ova

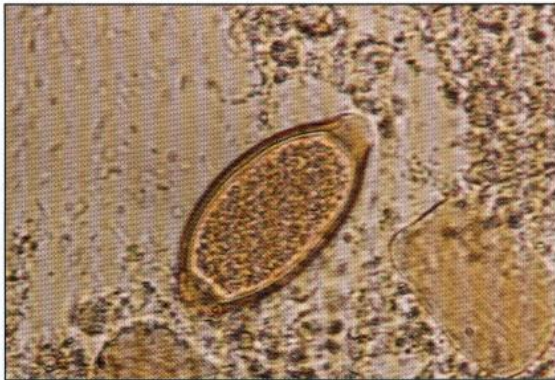



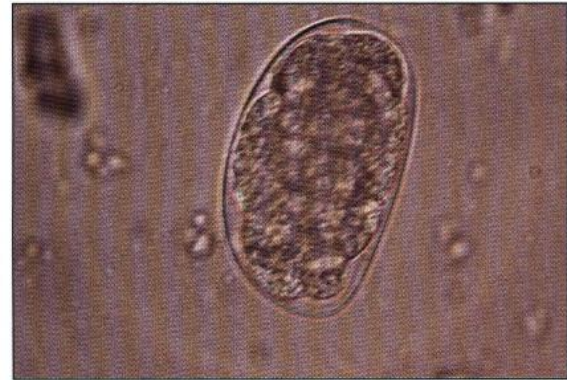(a) *Ascaris* ovum



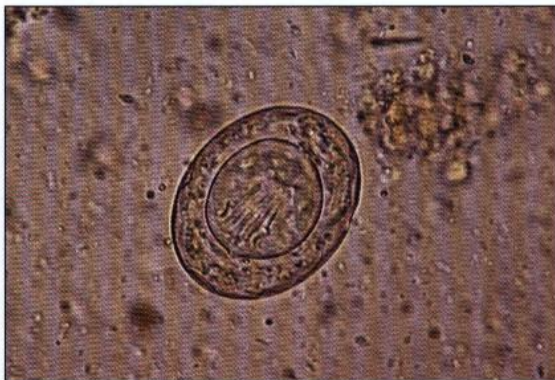(e) *Toxocara canis* ova



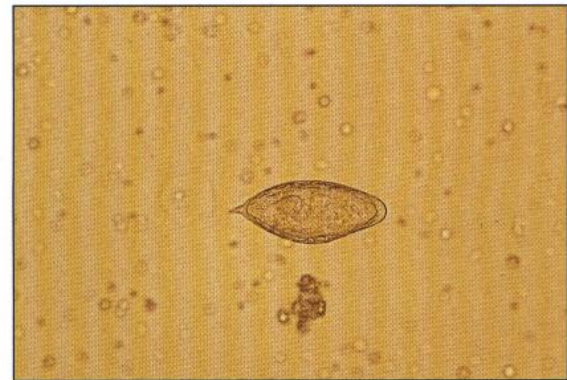(b) *Trichuris* ovum



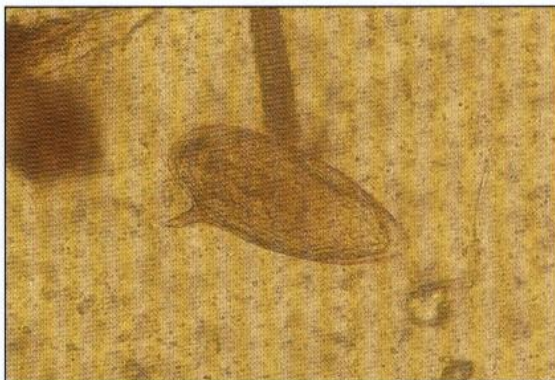(f) Hookworm (*Ancylostoma*) ovum



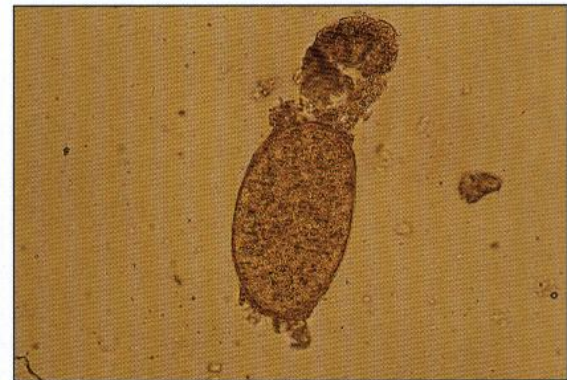(c) *Hymenolepis nana* ovum



(g) *Schistosoma haematobium* ovum



(d) *Schistosoma mansoni* ovum



(h) *Fasciola hepatica* ovum

An outline classification of the parasitic protozoa of humans etc.

Coccolis

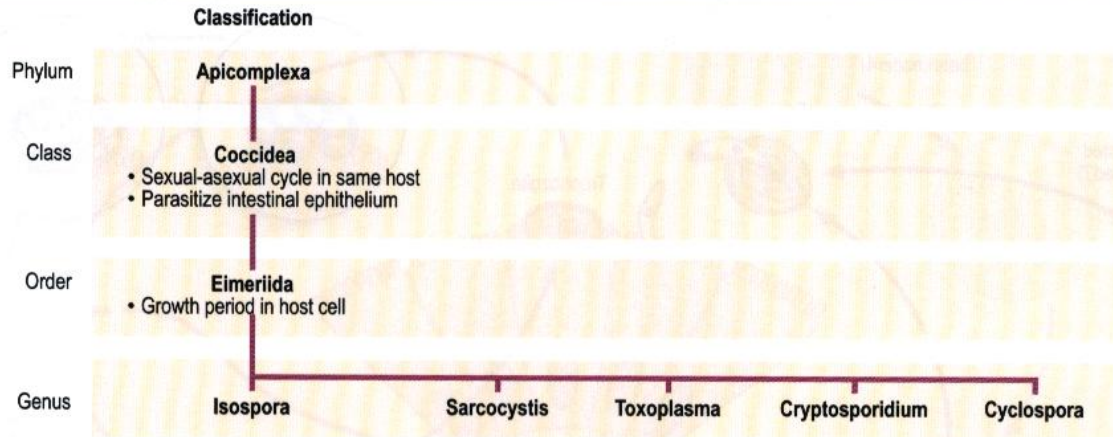
Protozoology

An outline classification of the parasitic protozoa of humans

Empire	Kingdom	Phylum	Class	Order	Genus
Eukaryota	Archezoa Haeckel 1894	Metamonada	Trepomonadea	Diplomonadida Enteromonadida	<i>Giardia</i> <i>Enteromonas</i>
			Retortamonadea	Retortamonadida	<i>Chilomastix</i> <i>Retortamonas</i>
		Microspora	Microsporea	Microsporida	<i>Encephalitozoon</i> <i>Enterocytozoon</i> <i>Nosema</i> <i>Septata</i> <i>Trachipleistophora</i>
	Protozoa Goldfuss 1818	Percolozoa	Heterolobosea	Schizopyrenida	<i>Naegleria</i>
		Parabasala	Trichomonadea	Trichomonadida	<i>Dientamoeba</i> <i>Trichomonas</i>
		Euglenozoa	Kinetoplastidea	Trypanosomatida	<i>Leishmania</i> <i>Trypanosoma</i>
		Ciliophora	Litostomatea	Vestibuliferida	<i>Balantidium</i>
		Apicomplexa (Sporozoa)	Coccidea	Eimeriida	<i>Cryptosporidium</i> <i>Cyclospora</i> <i>Isospora</i> <i>Sarcocystis</i> <i>Toxoplasma</i>
			Haematozoa	Haemosporida Piroplasmida	<i>Plasmodium</i> <i>Babesia</i>
		Rhizopoda	Lobosea	Acanthopodida	<i>Acanthamoeba</i> <i>Balamuthia</i>
		Entamoebidea	Euamoebida	<i>Endolimax</i> <i>Entamoeba</i> <i>Iodamoeba</i>	

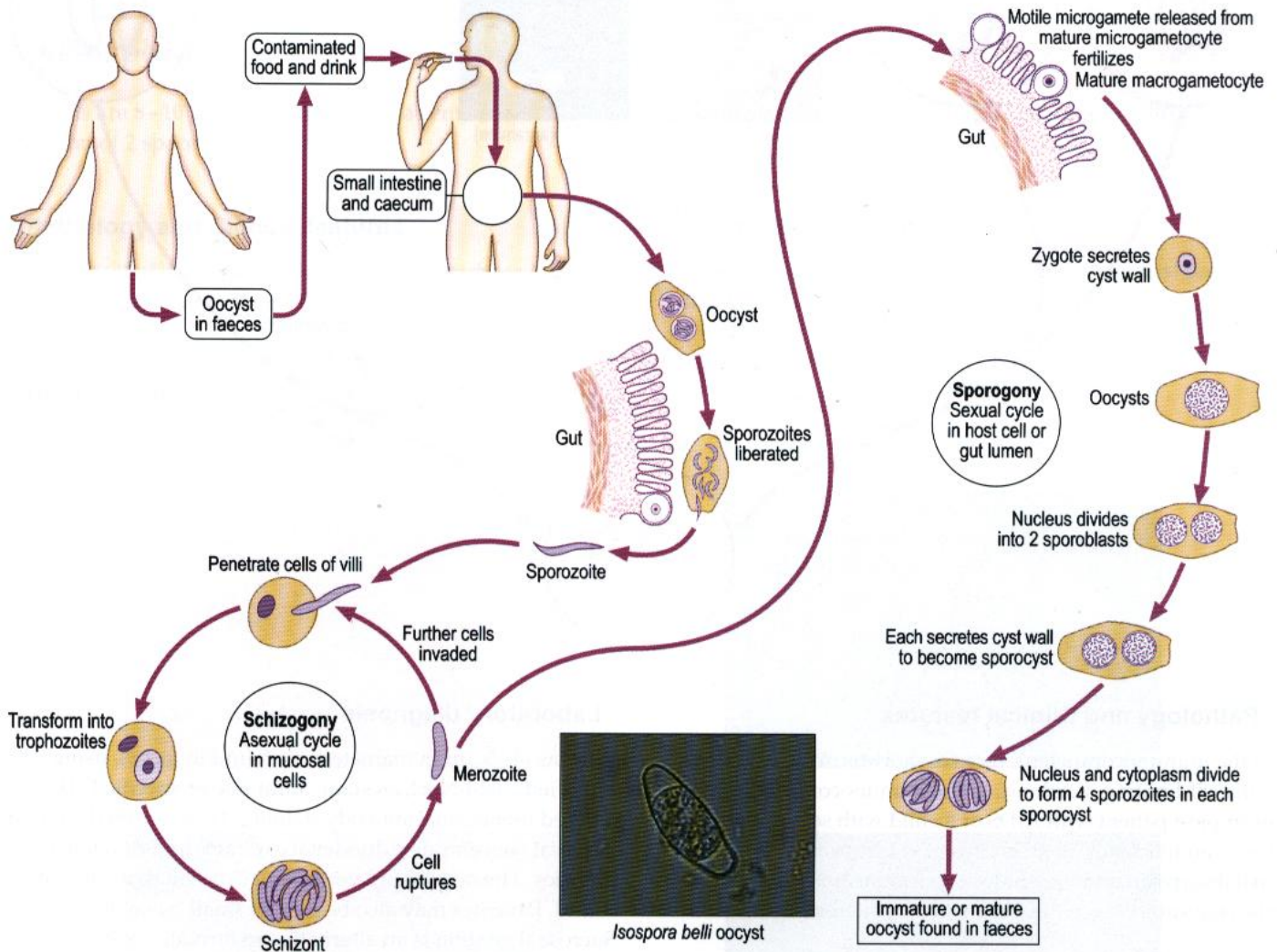
Intestinal protozoa

Coccidia



Isospora belli (causing coccidiosis in humans)

Life cycle



Pathology and Clinical features

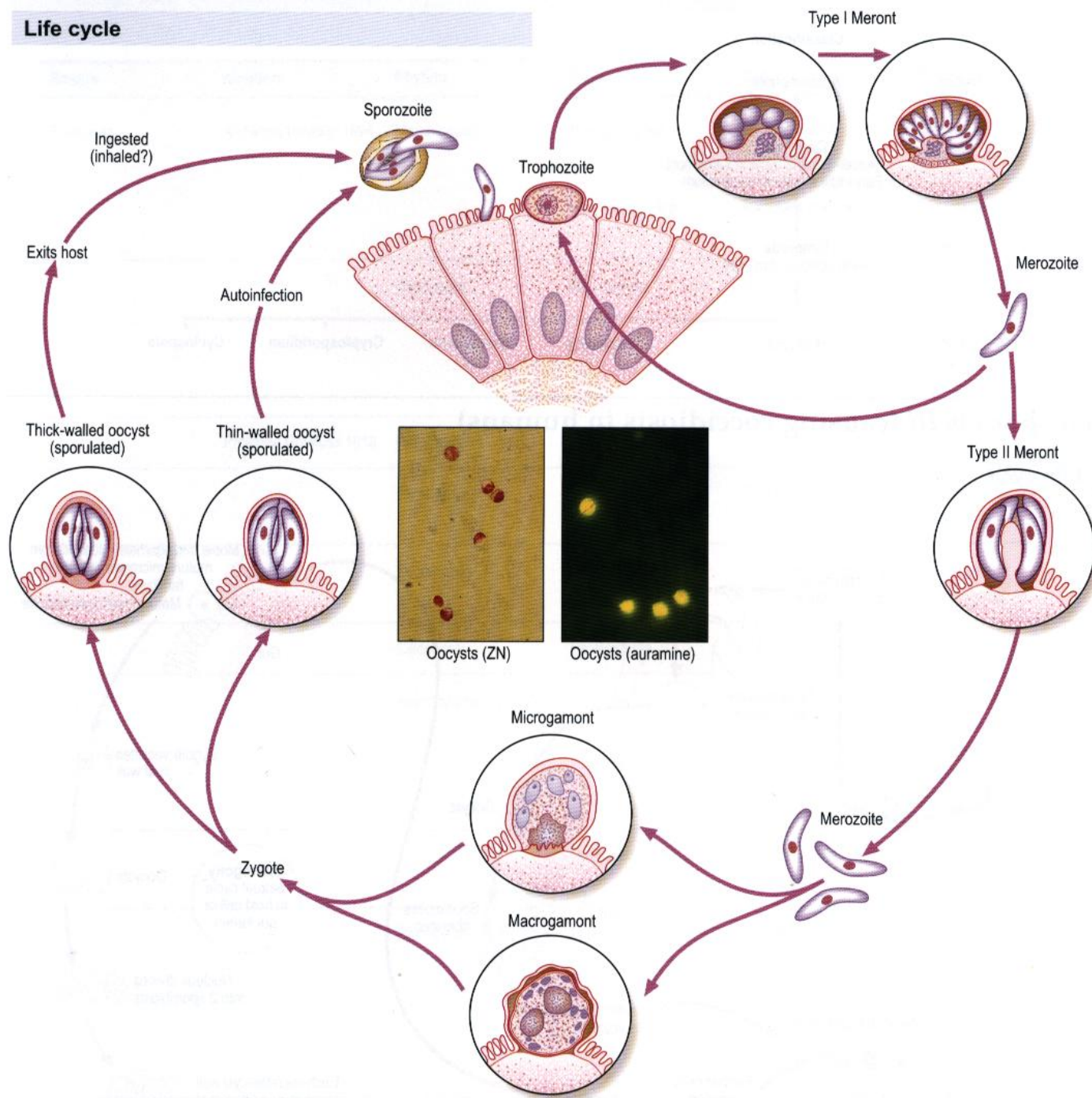
Small bowel mucosal atrophy. Watery diarrhoea or steatorrhoea, weight loss and sometimes cholecystitis occur in AIDS.

Laboratory diagnosis

Oocysts are seen in formalin-ether concentration of faeces or modified Ziehl-Neelsen or auramine-stained faecal smears. Intraepithelial parasites may be seen in small bowel biopsies.

Cryptosporidium parvum

Life cycle



Pathology and Clinical features

In the immunocompetent, there is short-term enteropathy with self-limiting diarrhoea. In the immunocompromised, for example a patient with AIDS or a child with severe combined immunodeficiency, there is chronic diarrhoea with malabsorption and weight loss. Extraintestinal infection of the respiratory tract, biliary tract and pancreas may occur.

Distribution

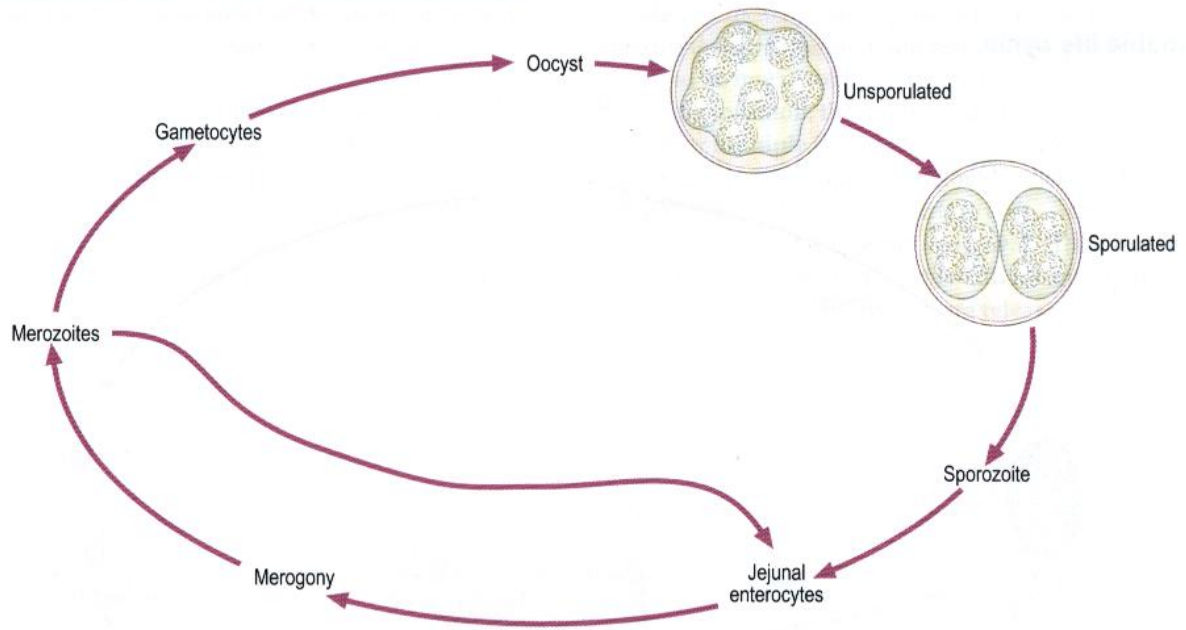
Cryptosporidia have a cosmopolitan distribution. Human and farm animal strains exist; both can cause human disease. Human infection is usually waterborne.

Laboratory diagnosis

Oocysts (4–5 µm in diameter) are found in faeces, using modified Ziehl-Neelsen stain, auramine or specific FITC labelled monoclonal antibody staining. They can also be found in faecal concentrates, duodenal aspirates and duodenal biopsies. The oocysts are very small (5 µm in diameter) and round. Parasites may also be seen in small bowel biopsies. Sucrose floatation is an alternative to formalin–ether concentration.

Cyclospora cayetanensis

Life cycle



Cyclospora

Oocysts are 8–10 µm in diameter with a central morula of refractile spheres when unsporulated. These mature into a final division of 2 sporocysts.

Pathology and Clinical features

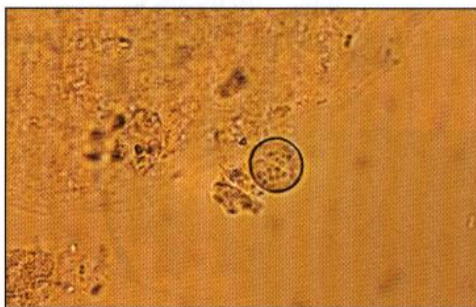Acute onset of diarrhoea, followed by steatorrhoea. Colicky abdominal pain and malaise. Partial villous atrophy may be seen.

Distribution

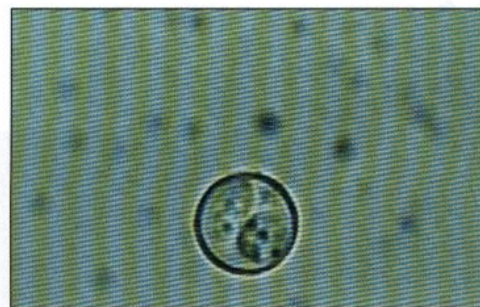Widespread, probably worldwide.

Laboratory diagnosis

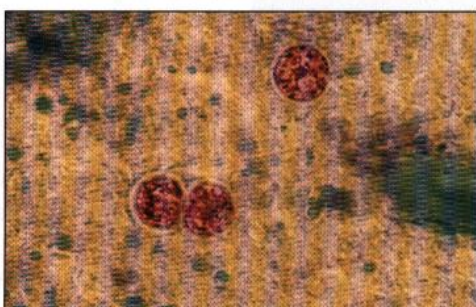
Oocysts are seen in faeces unsporulated when first passed. Diagnosis is either by formalin–ether concentration, modified Ziehl-Neelsen stain or by autofluorescence.




Unsporulated



Sporulated



Modified Ziehl-Neelsen stain

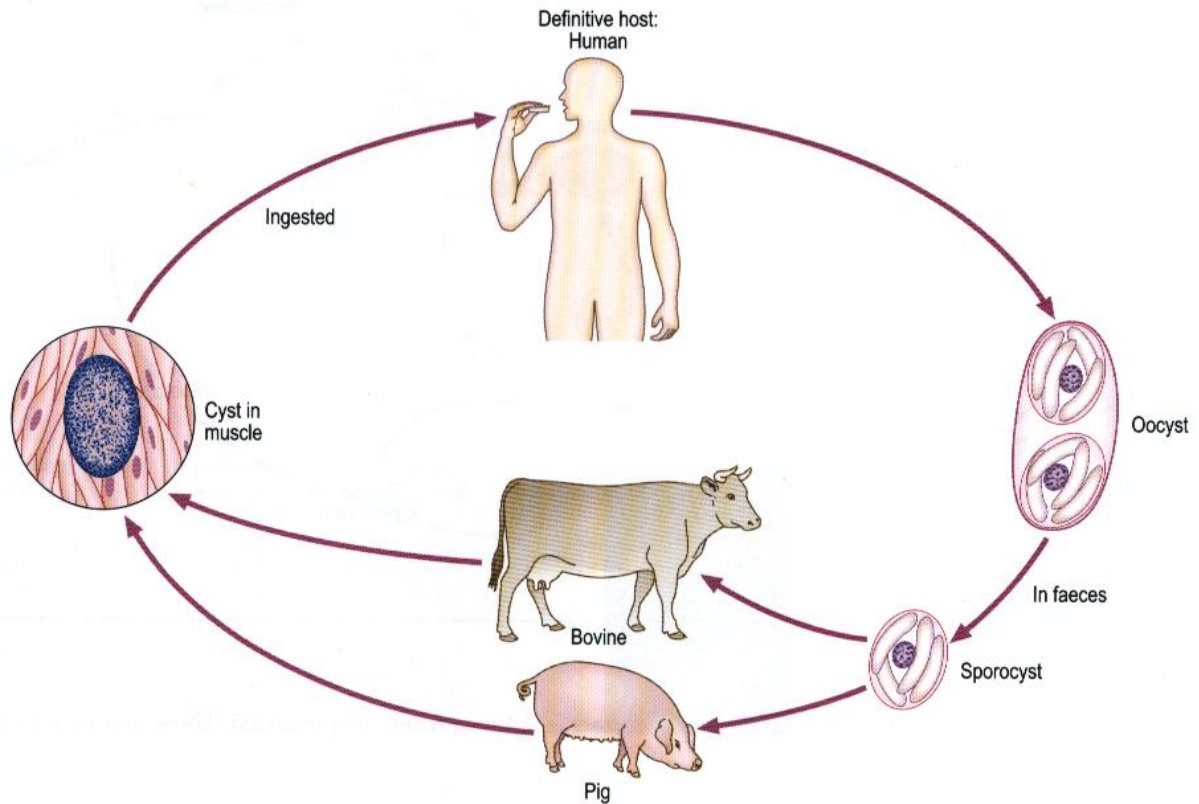


Autofluorescence

Coccidia (continued)

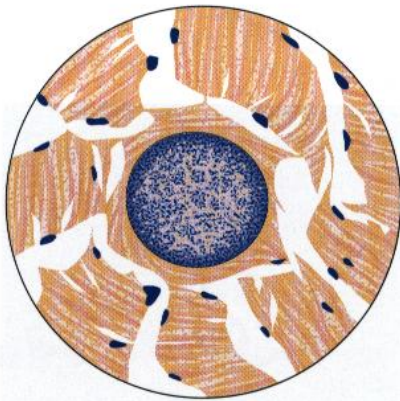
Sarcocystis hominis

Probable life cycle

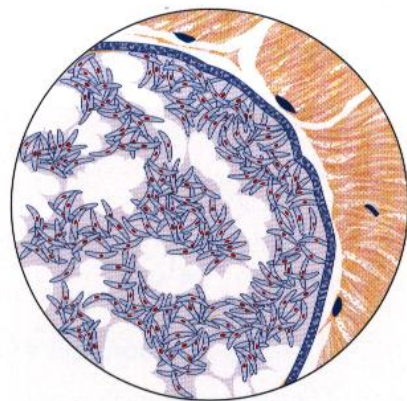


Occasionally humans can act as intermediate hosts for *Sarcocystis* of other animals.

Morphology



Cyst in human muscle
Miescher's tube x 100



Enlarged portion of
Miescher's tube showing
Rainey's corpuscles (each
12-16 x 4-9 μm): from
a human case

Pathology and Clinical features

The intestinal stages produce diarrhoea and abdominal pain. The clinical significance of muscle cysts is unknown.

Laboratory diagnosis

Oocysts or free sporocysts are found in faeces. Histological examination of biopsy specimens may show the sexual stages in the intestinal epithelium.

Histology is the only way to diagnose the presence of sarcocysts, although these are almost invariably incidental findings.

Microsporidia – general characteristics

All are obligate intracellular parasites. The vast majority of species are in invertebrates, especially insects, lower vertebrates and fish. Only a few have been reported from warm-blooded vertebrates.

They are considered to be primitive organisms. Their evolutionary history has been predicted from their prokaryote-like ribosomal characteristics — the absence of a separate 5.8S rRNA and the nucleotide sequence of the small subunit (16S) rRNA. They have no mitochondria. The infective stages are highly-resistant spores. These are very uniform in size for a given species.

When spores are ingested by a new host, the cells are penetrated by means of an apparatus known as the polar tube. When this is fully extended, the sporoplasm passes through the tube, to be inoculated into the cytoplasm of the host cell.

Following infection, there follows a phase of multiplication by binary or multiple fission (merogony). The transition to the spore-producing stage (sporogony) is heralded by the secretion of an electron dense surface coat — this will form the future exospore layer of the spore wall. The primary sporogonic cells are **sporonts**, which divide into **sporoblasts**, which mature into **spores**, which are released when the host cell ruptures.

Common species of microsporidia reported from humans. Most are AIDS associated.

Species	Localization	Pathogenesis
<i>Encephalitozoon cuniculi</i>	Generalized, brain, etc.	Convulsions, etc.
<i>Encephalitozoon hellem</i>	Corneal epithelia	Keratopathy
<i>Enterocytozoon bieneusi</i>	Enterocytes – gut	Diarrhoea
<i>Encephalitozoon (Septata) intestinalis</i>	Enterocytes – gut	Diarrhoea
<i>Nosema connori</i>	Generalized	Multi-organ
<i>Nosema corneum</i>	Corneal stroma	Keratitis
<i>Microsporidium africanum</i>	Corneal stroma	Keratitis
<i>Pleistophora</i> sp.	Muscle fibres	Myositis

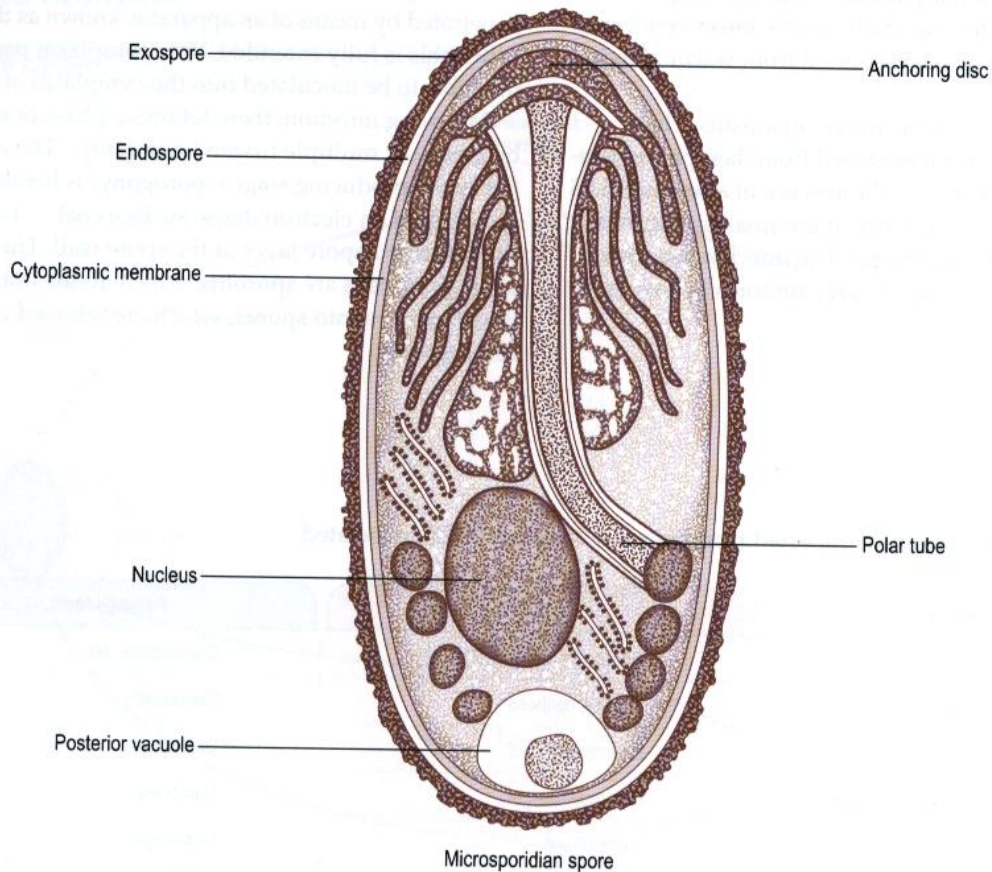
Infections of the gastrointestinal tract and urinary system can be detected by the presence of spores in faeces or urine. Spores from these sites can be visualized by staining them with the modified trichrome stain.

The spores of microsporidia are very small – $1 \times 0.5 \mu\text{m}$ (See below)



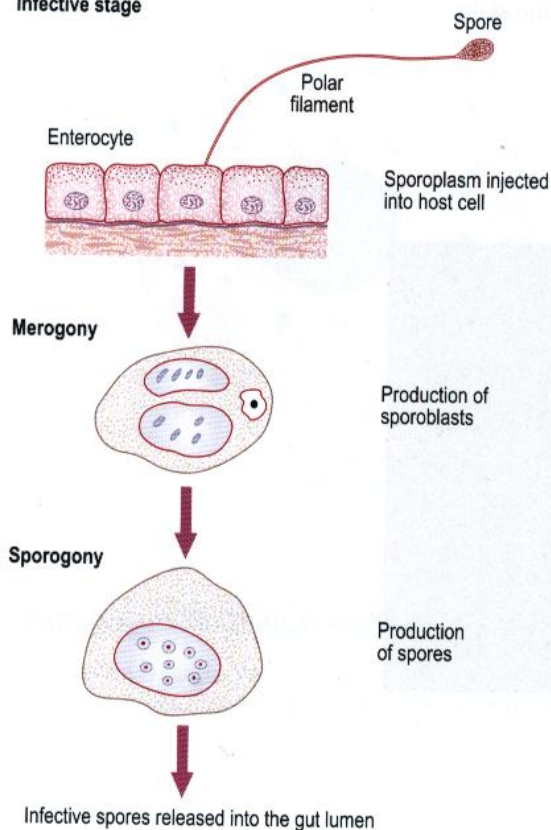
Enterocytozoon bieneusi spores

Microsporidia (continued)



Life cycle

Infective stage




Laboratory diagnosis

Alternative staining methods for microsporidial spores in stool samples are modified trichrome stain and uvitex 2B or calcofluor fluorescence.

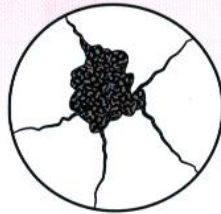Entamoeba

- Generally one nucleus in trophozoite
- Small karyosome at or near centre
- Nuclear membrane lined with chromatin granules
- Forms cysts



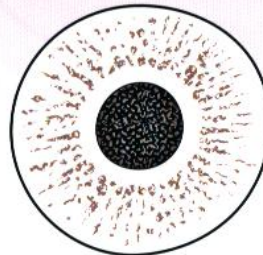
Endolimax

- Generally one nucleus in trophozoite
- Large irregular karyosome attached to nuclear membrane
- No peripheral chromatin
- Forms cysts




Iodamoeba

- Generally one nucleus in trophozoite
- Large karyosome surrounded by achromatic granules
- No peripheral chromatin
- Forms cysts



Dientamoeba

- Minute
- Generally binucleate
- Central particulate karyosome
- No peripheral chromatin
- No cystic stage



Species

Entamoeba histolytica/dispar
Entamoeba coli
Entamoeba hartmanni
Entamoeba polecki

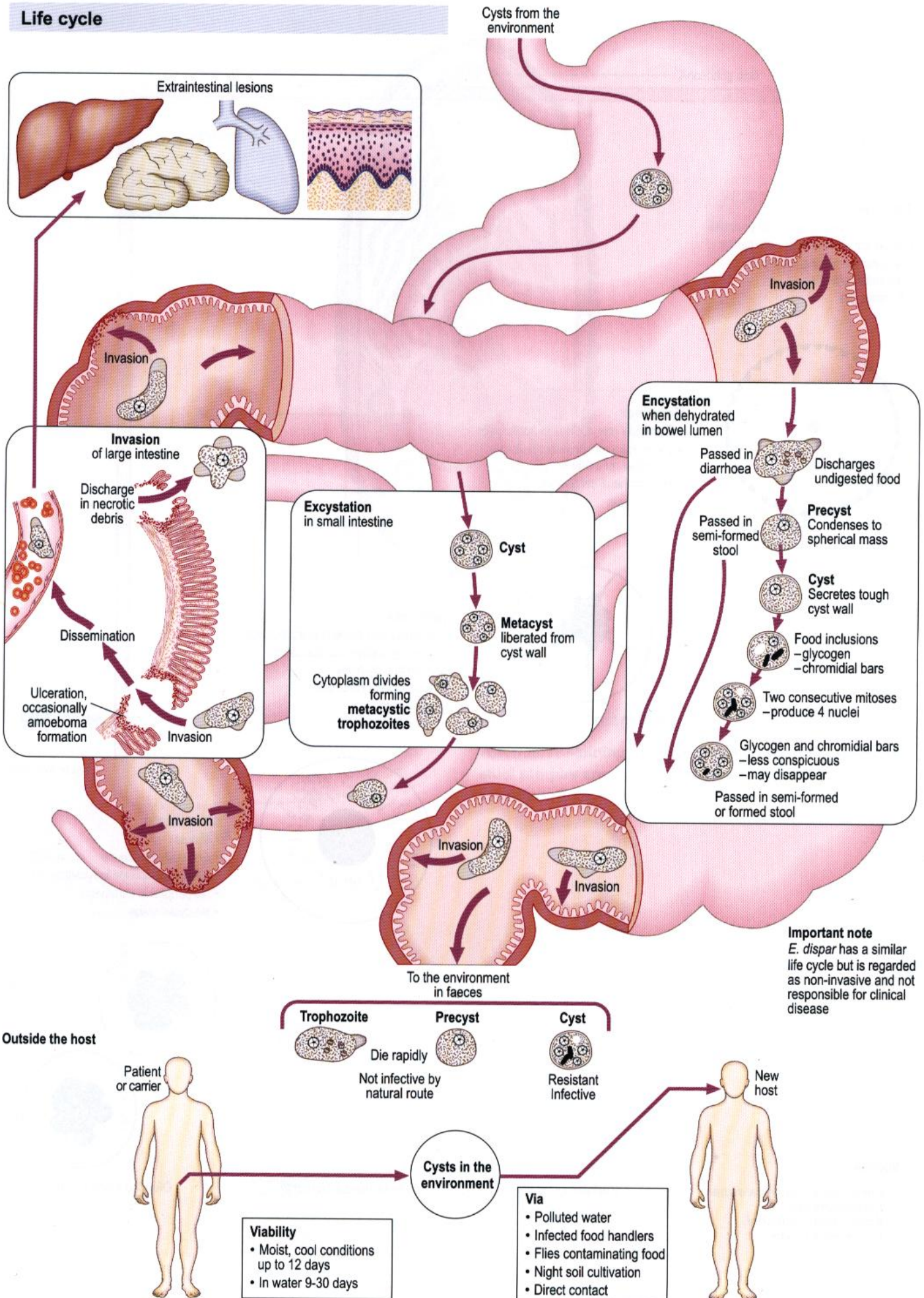
Endolimax nana

Iodamoeba bütschlii

Dientamoeba fragilis

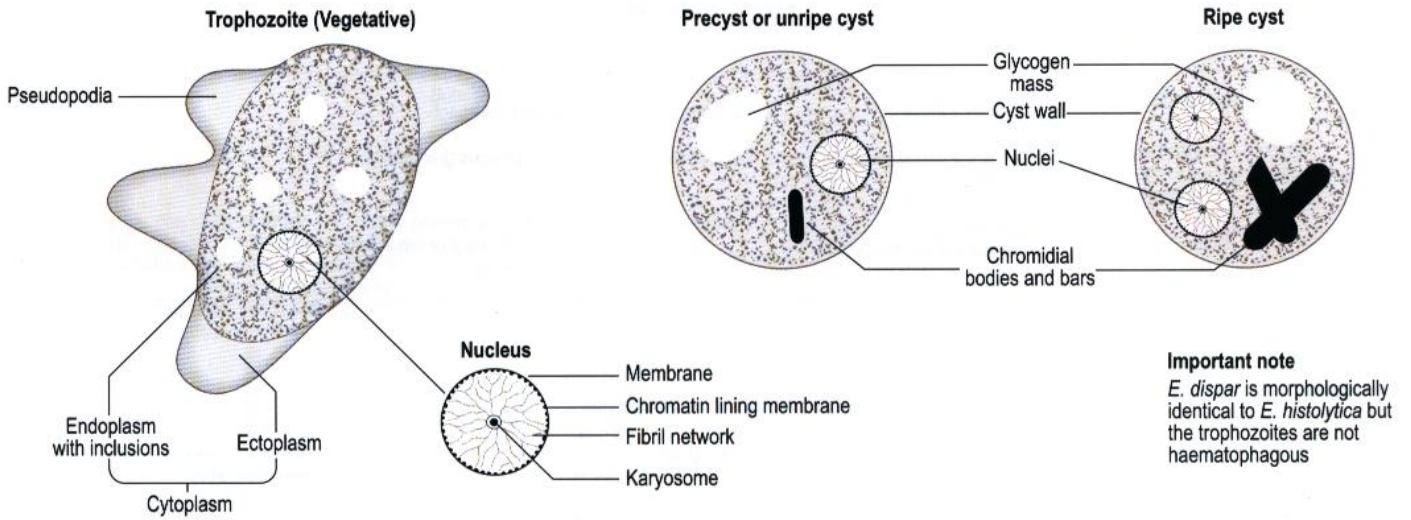
Entamoeba histolytica (causing amoebiasis)

Life cycle



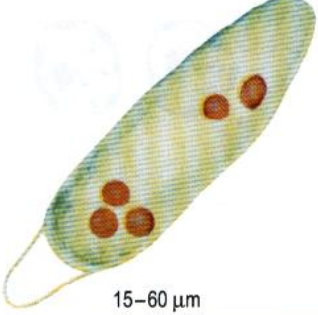





Morphology

General – nomenclature



Particular - Includes differentiation from *Entamoeba coli*, an intestinal commensal.

Unstained preparations

<i>E. histolytica</i>		Trophozoite		<i>E. coli</i>
 15–60 μm	Granular Clear finger-like Active Purposeful Generally invisible Red blood cells (RBCs)	Cytoplasm Pseudopodia Movement Nucleus Inclusions	Conspicuously granular Blunt Sluggish Not purposeful Ring refractile granules with eccentric karyosome Vacuoles, crystals, vegetable cells, bacteria, no RBCs	 15–50 μm
Precyst and unripe cyst				
	Granular May be refractile ring Rod-like refractile chromidial bars Glycogen masses	Cytoplasm Nucleus Inclusions	Granular Visible as refractile ring May be slender refractile chromidial bars Glycogen masses	
Ripe cyst				
 10–20 μm	Round Refractile 1–4 refractile nuclei with central karyosome Refractile chromidial bars often present	Shape Wall Nuclei Inclusions	Round Conspicuous refractile double outline 1–8 refractile nuclei with eccentric karyosomes Only rudimentary slender chromidial bars	 10–33 μm

Invasion of the large intestine

Site of entry
Initially minute then irregular ulcer shape, typically flask-like edges overhanging floor; necrotic lysed tissue; amoebae invading around discharge; necrotic debris, mucus and amoebae

Invasion elsewhere in large bowel

Mucosa
Muscularis mucosae
Submucosa
Muscle layers
Subserosa

The primary ulcer Invasion of mucosa via crypts
Repair may:
-overtake necrosis with healing
-keep pace with necrosis causing persistent superficial lesions

'Flask-shaped' Lag behind-extension

Extension in mucosa Muscularis mucosae relatively resistant
Accumulation of amoebae superficial to it
Lateral extension of lytic necrosis

Formation of sinuses Abscesses may coalesce under intact mucosa
Later mucosa may slough with widespread ulceration

Deep extension Muscularis mucosae eventually pierced (directly or via vessels)
Deep necrosis of sub-mucosa, even muscle and sub-serosa

Complications and sequelae

Perforation
Haemorrhage (rare)

Secondary infection

Amoeboma (rare)
(Clinically simulates neoplasm)
-intussusception
-obstruction

Invasion of blood vessels
Direct extension outside bowel

Peritonitis
Haemorrhage

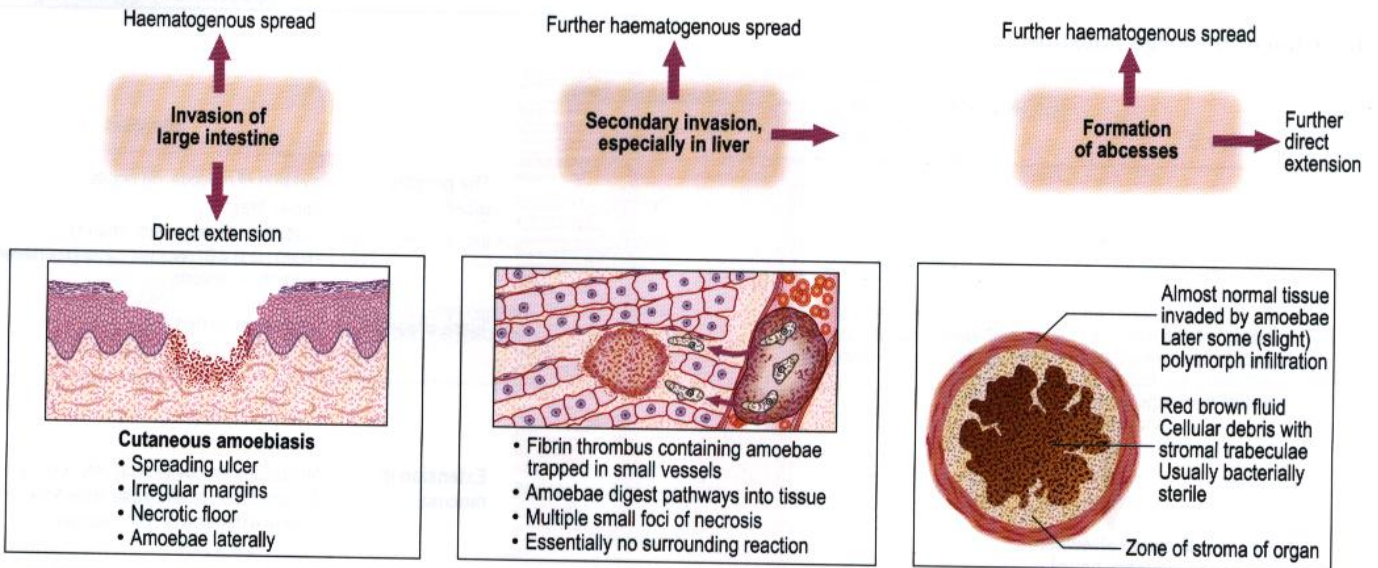
Surrounding inflammatory reaction and fibroblastic proliferation

A mass under oedematous mucosa with
-internal abscesses of necrotic tissue and amoebae
-surrounding granulomatous tissue zone with eosinophils, lymphocytes and fibroblasts
-outer firm nodular fibrous tissue

Extraintestinal lesions-page 52

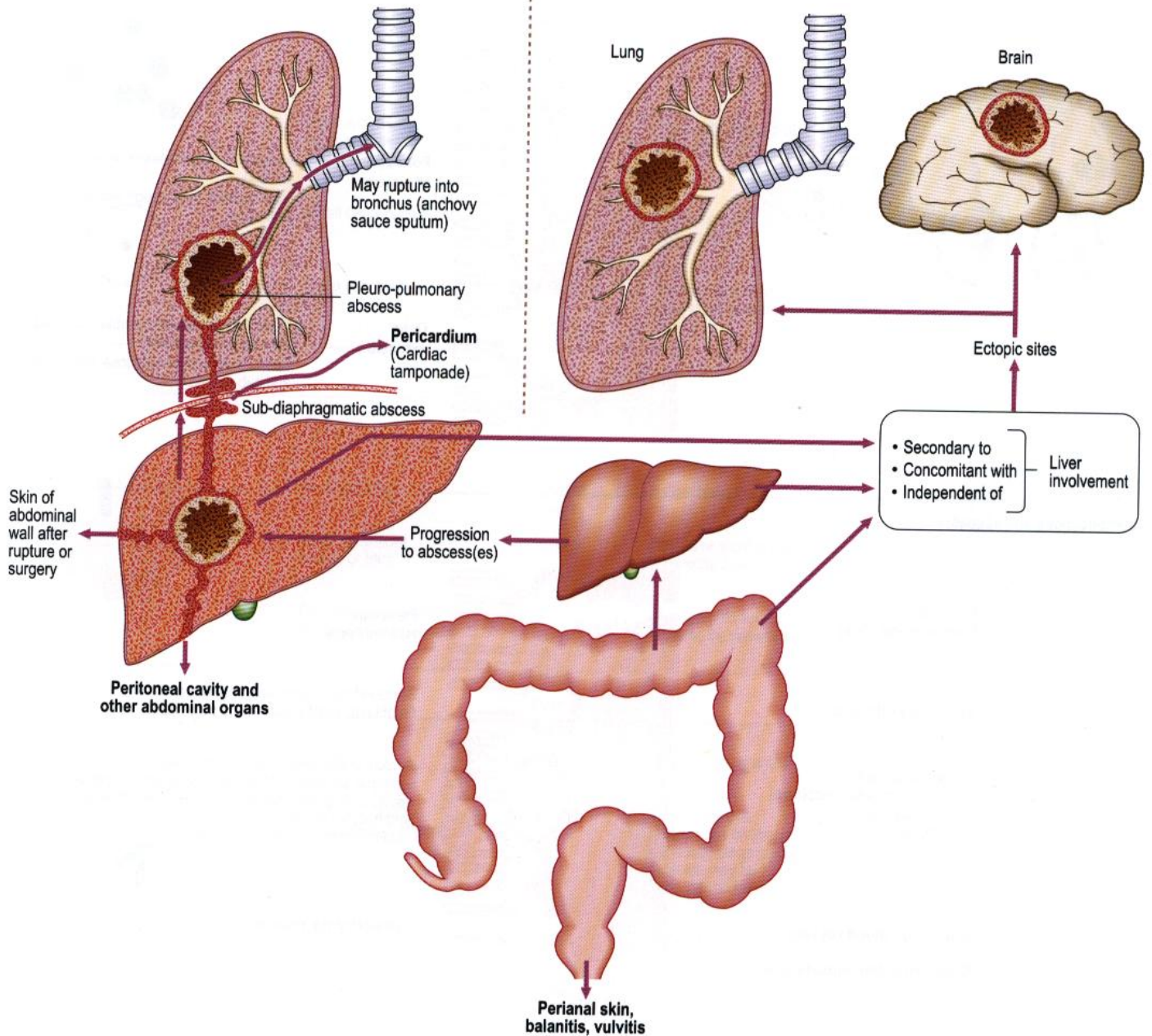
Entamoeba histolytica (causing amoebiasis) (continued)

Extraintestinal lesions in amoebiasis



Direct extension

Haematogenous spread



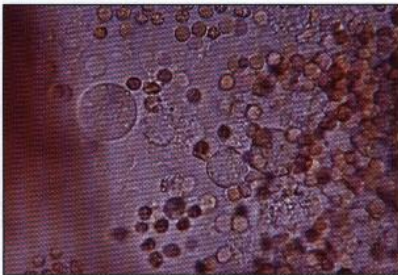
Laboratory diagnosis

Diagnosis depends primarily on demonstration of haematophagous trophozoites of *E. histolytica* in stool samples, aspirates from intestinal and other organs, biopsy material (pinch biopsy at proctoscopy or sigmoidoscopy and surgical biopsy from elsewhere) and in mucus from rectal ulcers. ELISAs are available for the detection of *Entamoeba* antigen and specific *E. histolytica* lectin antigen in faecal samples. Serology is the method of choice for diagnosis of amoebic liver disease.

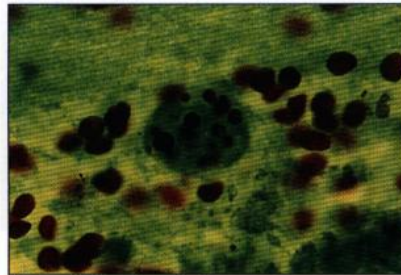
Faecal appearances in amoebic dysentery

		Character
Naked eye	Faecal matter Mucus	Always present Not tenacious Not abundant
Microscopic	1. Bacteria 2. Pus cells 3. Red blood cells 4. Large macrophages 5. Charcot-Leyden crystals 6. Haematophagous trophozoites of <i>E. histolytica</i>	Numerous Scanty, well preserved Often in rouleaux Not a feature May be present but are non-specific Present
Culture	Usually limited to reference or research laboratories; lectin ELISA is used for specific identification of <i>E. histolytica</i> from cyst or trophozoite. Enzyme electrophoresis from cultured trophozoite is an alternative.	

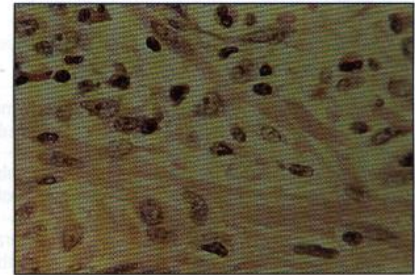
Haematophagous amoebic trophozoites.



(a) Direct microscopy



(b) Trichrome stain



(c) H&E stain

Notes

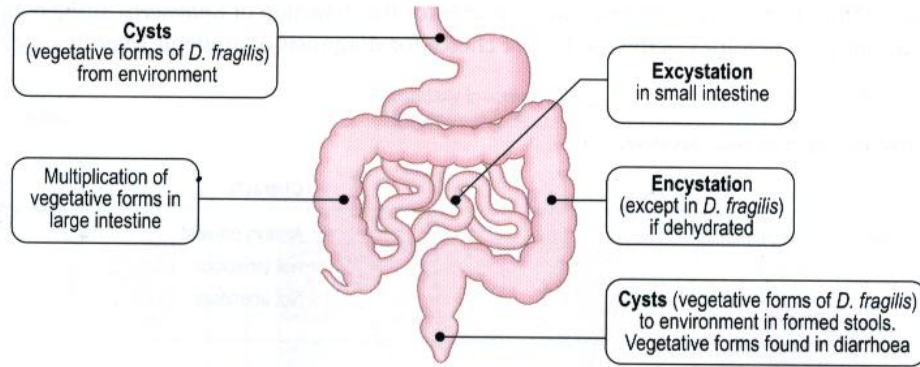
Vegetative *E. histolytica* when seen is actively motile and moves purposefully. There are finger-like, clear pseudopodia and ingested red cells. No nucleus can be seen. Precysts or cysts found in semi-formed or solid stool have typical nuclear characteristics (1–4 nuclei) and glycogen and chromidial bars can be demonstrated.

Diagnostic tests

Polymorph leucocytosis. Examination of stool samples may show cysts and trophozoites of *E. histolytica*. Serological tests (IFAT, ELISA, cellulose acetate precipitin, latex agglutination) but serology is positive in no more than 75% of cases of amoebic colitis. Examine aspirated material for *E. histolytica*. Histology of rectal and colon biopsy material.

Other intestinal amoebae








Life cycle

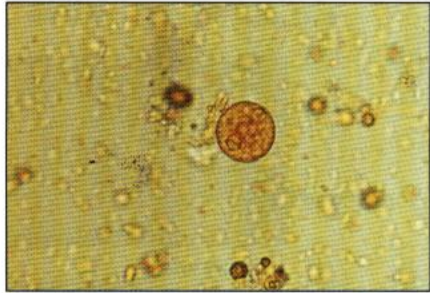


Morphology

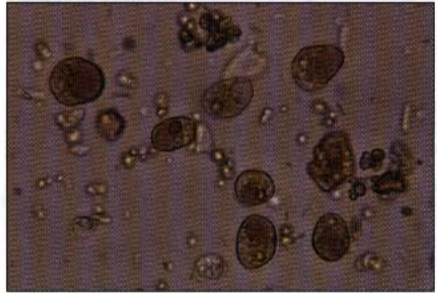
Unstained

	Vegetative forms (trophozoites)						
	<i>Entamoeba coli</i>	<i>Endolimax nana</i>	<i>Iodamoeba bütschlii</i>	<i>Dientamoeba fragilis</i>	<i>Entamoeba histolytica</i>	<i>Entamoeba dispar</i>	<i>Entamoeba hartmanni</i>
Size	15–50 µm	8–10 µm	8–20 µm	5–12 µm	15–60 µm	15–60 µm	15–60 µm
Motility	Sluggish	Sluggish	Fairly active	Very active	Very active	Active	Active
Ectoplasm	Little	Little	Little	Abundant	Abundant	Abundant	Abundant
Pseudopodia	Blunt, mainly granular	Blunt, mainly granular	Blunt, clear	Leaf-like, clear	Finger-like, clear	Finger-like, clear	Finger-like, clear
Endoplasm	All have granular cytoplasm with food particles, bacteria, crystals, vegetable cells, often in vacuoles. No ingested RBCs				Ingested RBCs	No ingested RBCs	No ingested RBCs
Nucleus	Ring of refractive dots	Generally invisible	Generally invisible	Two, collection of dots	Generally invisible	Generally invisible	Generally invisible
	Precyst (round up, discharge food particles, bacteria, etc.)						
Glycogen	Often prominent vacuole	Rare	Conspicuous	None	Diffuse, soon disappears	Diffuse, soon disappears	Diffuse, soon disappears
Chromidial bars	Rarely seen	Rare	None	None	Large refractile bars	Large refractile bars	Large refractile bars
	Cysts						
Size	10–33 µm	5–14 µm	5–18 µm	None	10–20 µm	10–20 µm	8–10 µm
Shape	Spherical or oval	Oval	Irregular	None	Spherical	Spherical	Spherical
Wall	Thick	Thin	Thin	None	Thin	Thin	Thin
Glycogen	Diffuse central	None	Well-defined vacuoles	None	Sometimes persists	Sometimes persists	Sometimes persists
Chromidial bars	Not usual	None	None	None	Sometimes present	Sometimes present	Sometimes present
Nuclei numbers	1–8	4 (at one end)	1 only	None	1–4	1–4	1–4

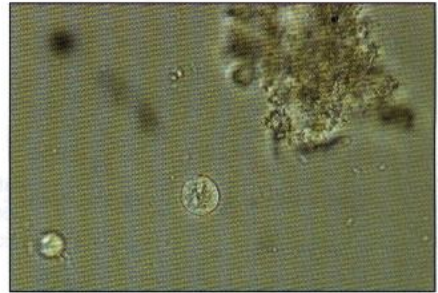
Stained							
	<i>Entamoeba coli</i>	<i>Endolimax nana</i>	<i>Iodamoeba bütschlii</i>	<i>Dientamoeba fragilis</i>	<i>Entamoeba histolytica</i>	<i>Entamoeba dispar</i>	<i>Entamoeba hartmannii</i>
Cytoplasm inclusions	With haematoxylin, stains bluish-grey Stain black except glycogen as clear area				RBCs also stain black		
Nuclear characteristics							
Membrane	Thick	Thin	Thick	Very delicate		Delicate	
Chromatin on membrane	Coarse	None	Sometimes granular	None		Fine granules	
Karyosome	Coarse, generally eccentric	Large irregular	Large lateral	Central granules		Small central	
Fibril network	May be chromatin particles	No chromatin	No chromatin	Delicate fibrils		Not often seen	
Pathogenicity	Harmless commensal	Harmless commensal	Harmless commensal	Disputed	Invasive	Harmless commensal Non-invasive	Harmless commensal Non-invasive



Entamoeba coli cysts



Iodamoeba bütschlii cysts



Entamoeba histolytica/dispar cysts

Intestinal flagellates

Diagnosis

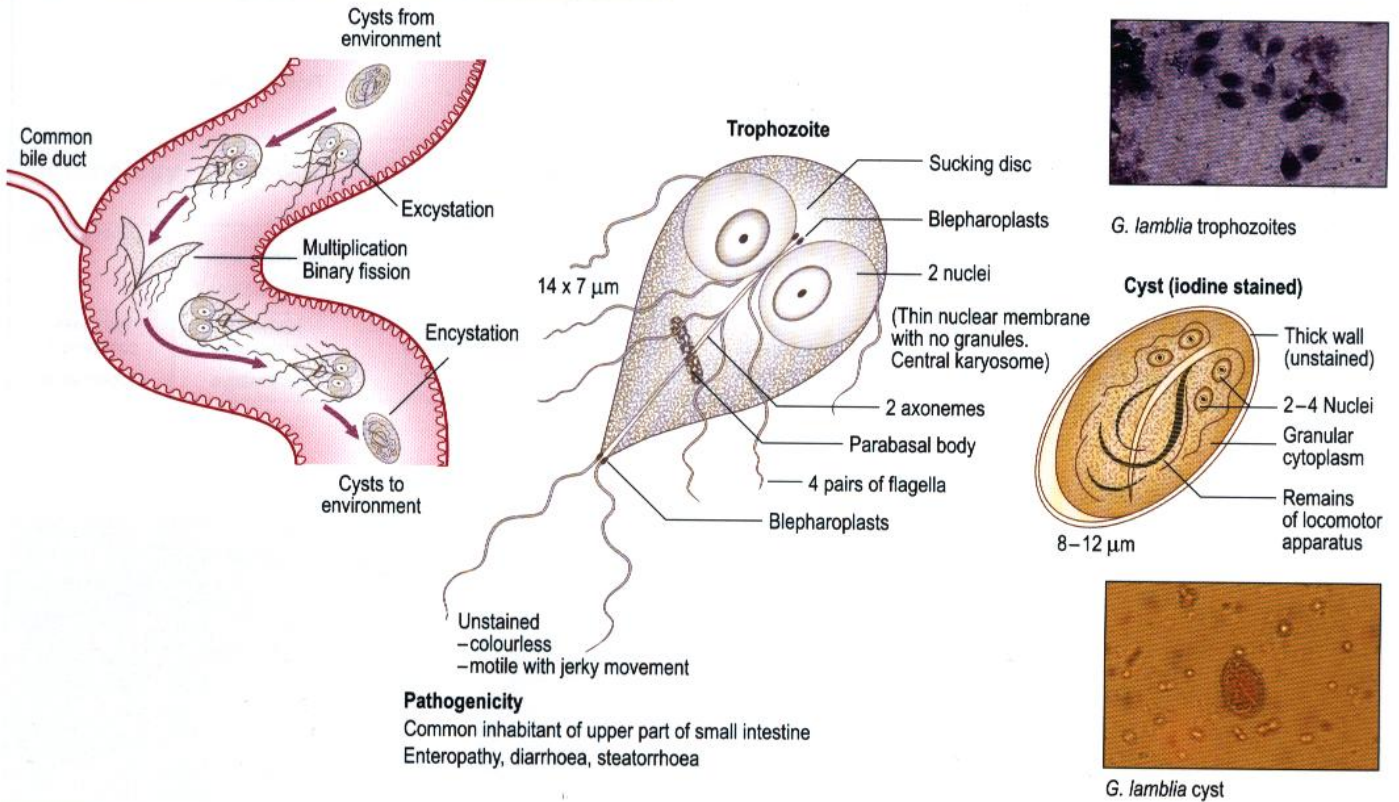
Trophozoites or cysts are found in stool samples or duodenal aspirates. Duodenal string test and stool antigen detection ELISA are also possible for the detection of *Giardia*.

Distribution

These protozoa have a worldwide distribution.

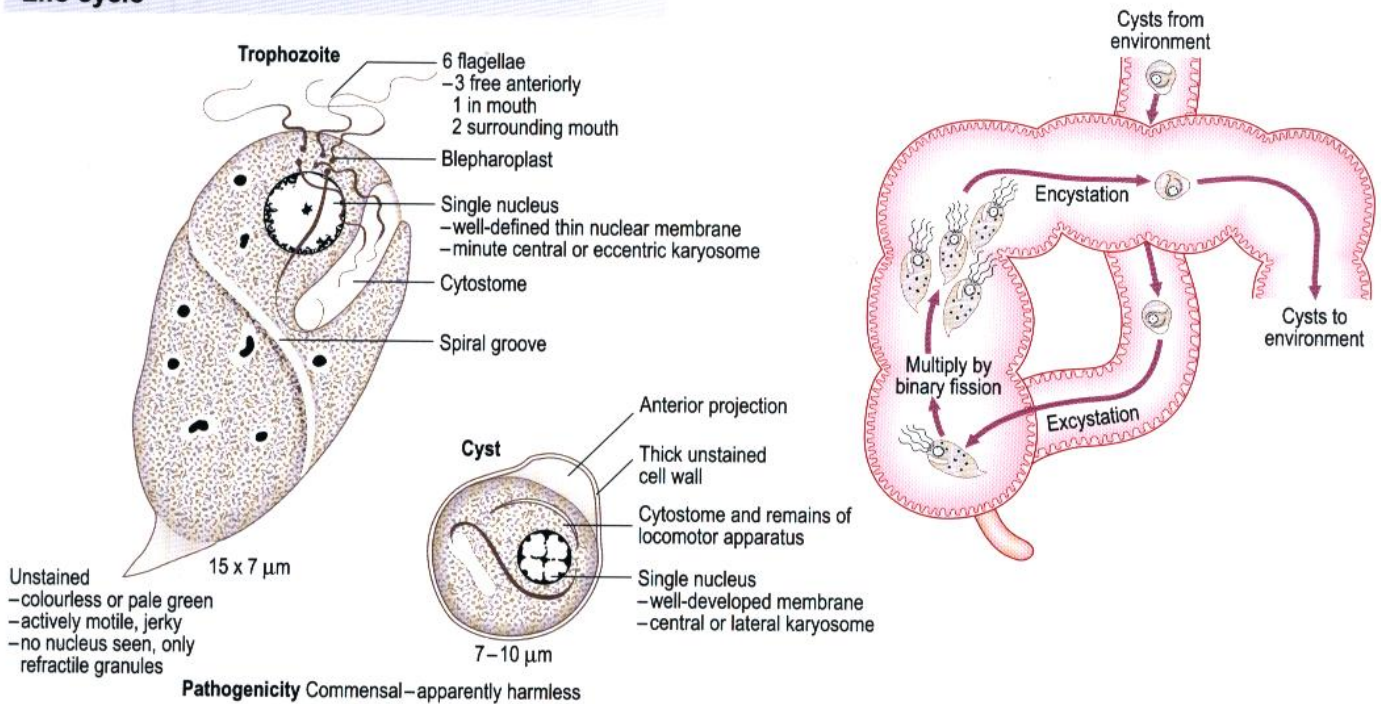
Giardia intestinalis (*G. lamblia*)

Life cycle

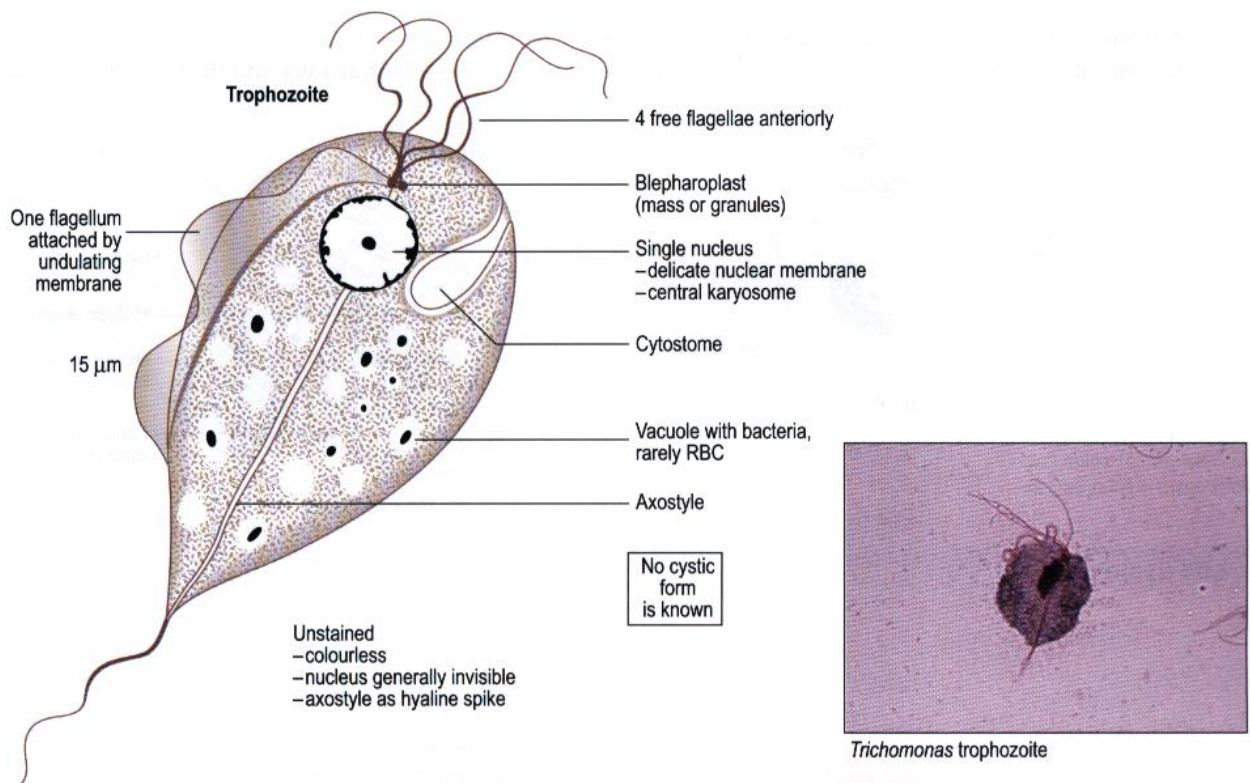


Chilomastix mesnili

Life cycle



Trichomonas species



T. hominis

This is illustrated above. The trophozoite inhabits the small and large intestine. There is no proof as yet that it has any pathogenicity.

T. vaginalis

Morphologically this is the same as *T. hominis* (above) but there is no free posterior flagellum beyond the undulating membrane. There is a marked parabasal body. It inhabits the urethra in the male and the vagina in the female, and is a cause of urethritis and vaginitis.

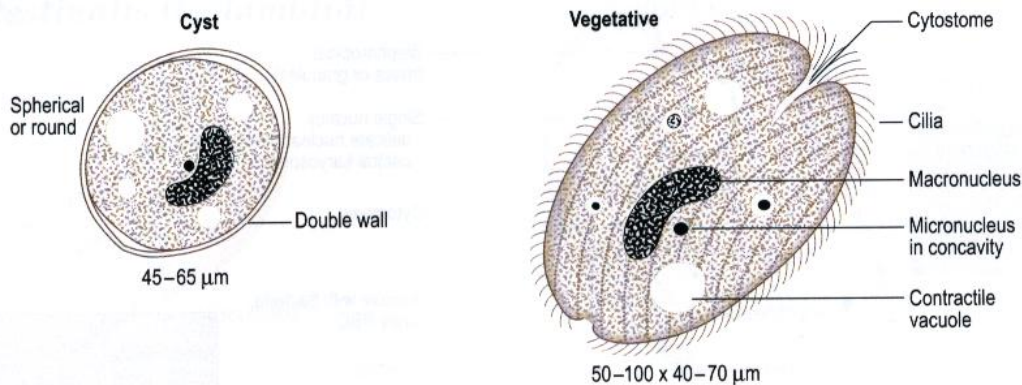
Demonstration of *T. vaginalis* is made by direct microscopy or after staining with acridine orange fluorescence stain. Cultures can be made using Feinberg-Whittington or Diamond's medium.

Intestinal ciliates

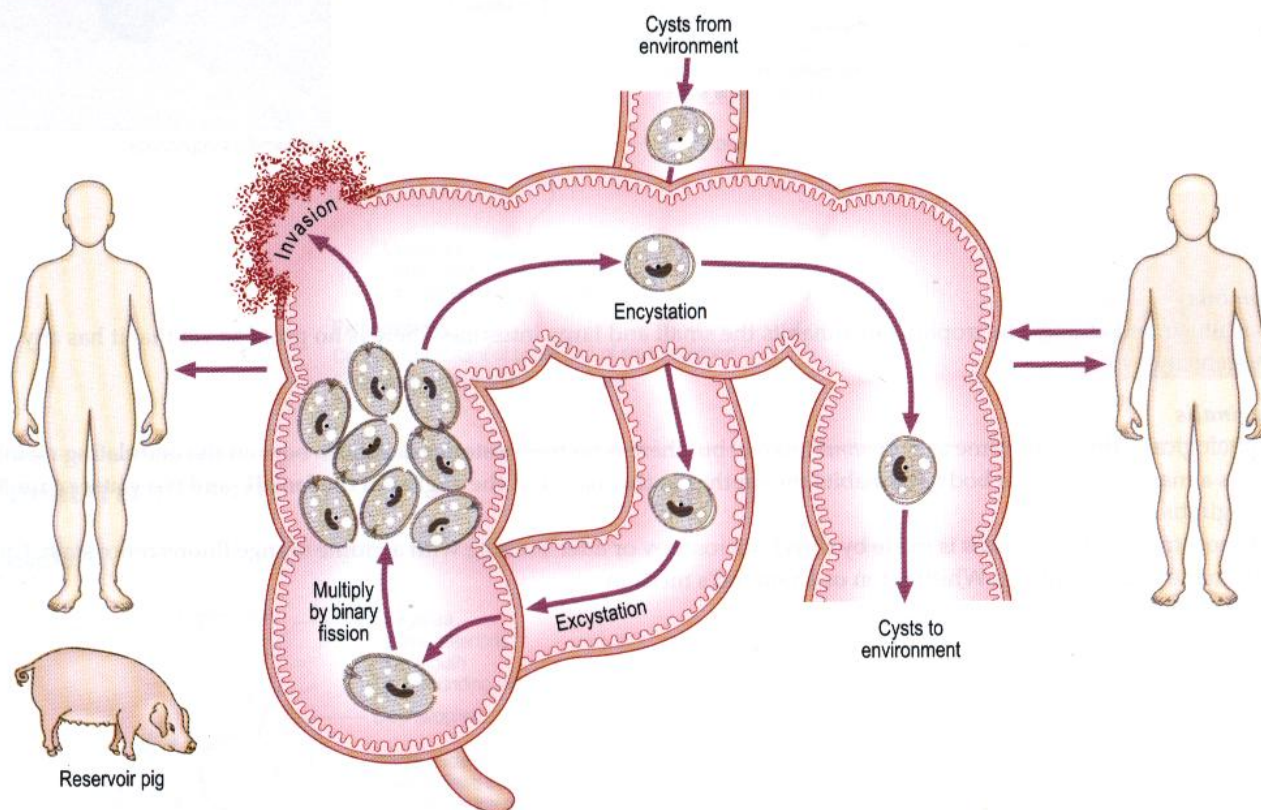
Balantidium coli

Found in South and Central America, parts of Asia and some Pacific islands.

In its vegetative state, recognizable by the oval shape, coarse cilia, contractile vacuoles and the horseshoe- or kidney-shaped macronucleus. Reproduction is by binary fission.



Life cycle

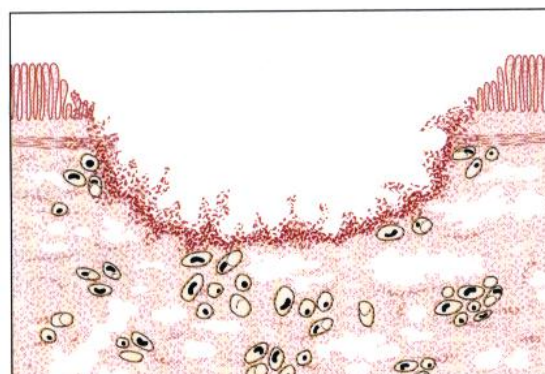


Pathology and Clinical features

Problems occur in the ileum, colon and rectum but there is no extraintestinal spread. The parasite is a cause of dysentery, although the ulcers are wider mouthed than those of amoebic dysentery. Secondary infection is frequent. The main complication is perforation.

Laboratory diagnosis

Trophozoites are found in diarrhoea and, in a fresh specimen, can be seen in active rotational movement. Cysts are found in semi-formed and formed stools.



Tissue protozoa

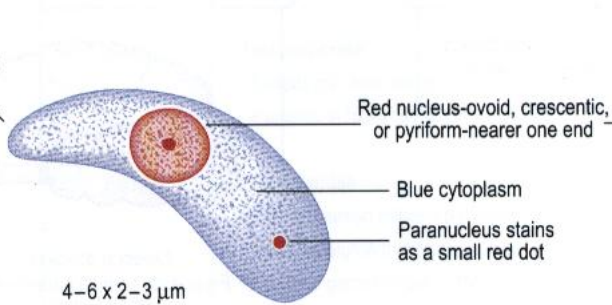
Toxoplasma gondii

Toxoplasma has a very wide mammalian host range.

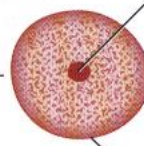
Morphology

Tachyzoite

Pointed end



Central karyosome



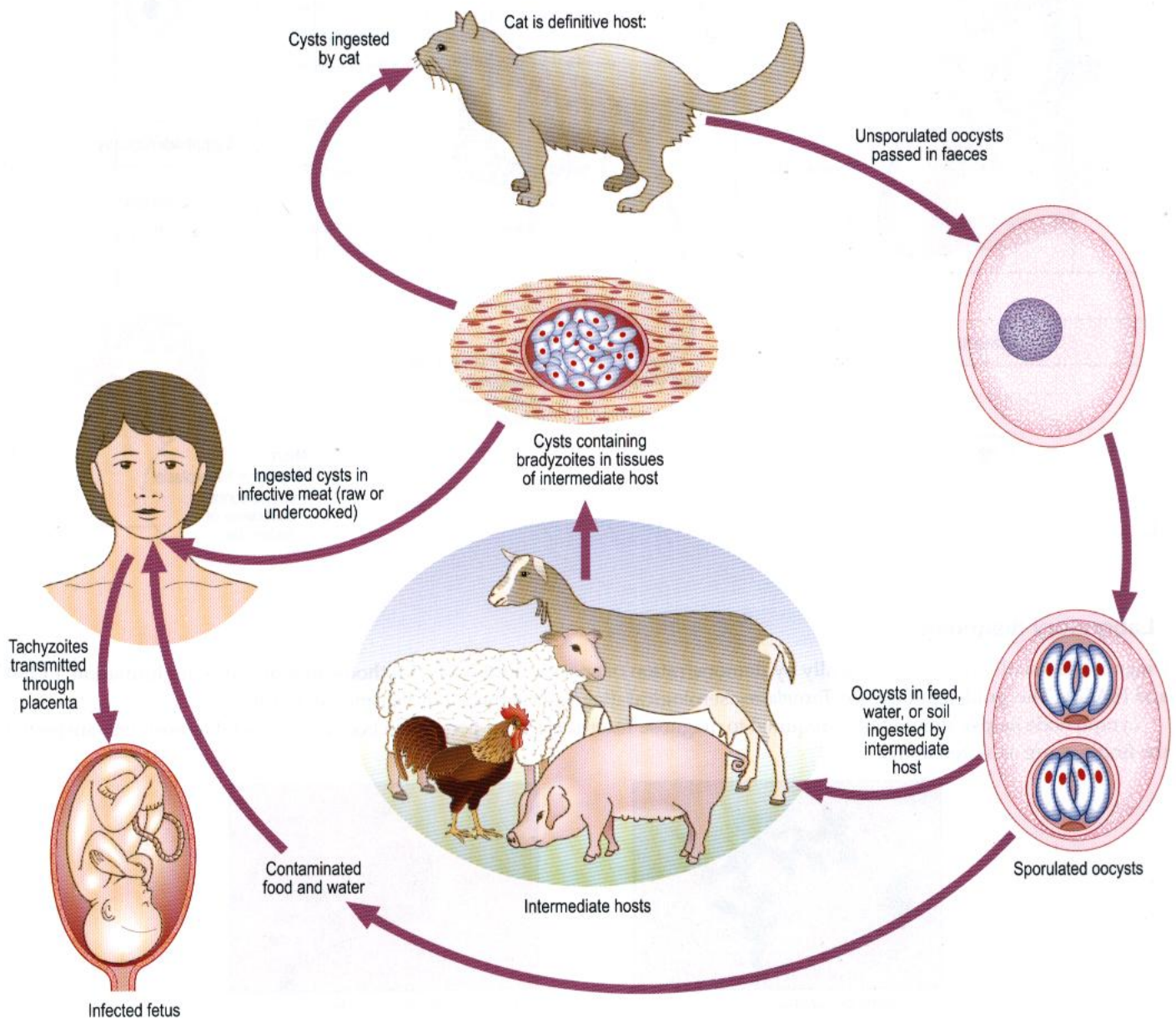
Habitat

Tachyzoites: single (free or intracellular) or in masses (pseudocysts)

In nucleated cells, especially macrophages

Bradyzoites (similar to tachyzoites but less active metabolically) in tissue cysts

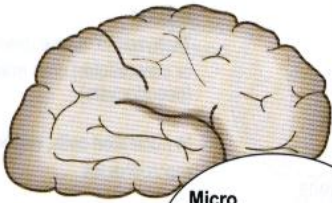
Life cycle



Pathology and Clinical features

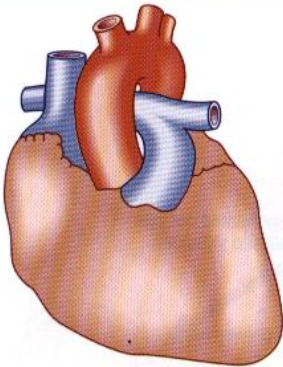
Congenital infection

**Marked calcification
Hydrocephalus or microcephaly**

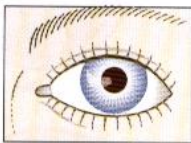


- Micro**
- Minute necrotic areas
 - Minute granulomata
 - Parasites in cells
 - Calcification

Myocarditis



Chorioretinitis

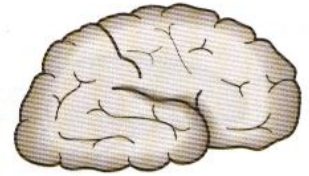


Other routes of infection

Inapparent effect

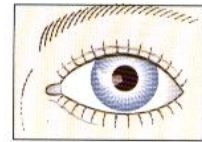
Woman may have affected child though herself shows no signs of disease

Acute encephalitis

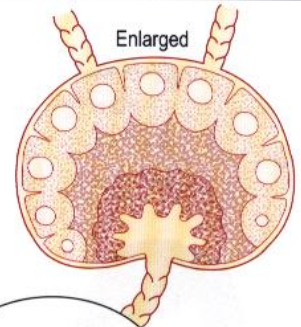


Cerebral abscess
Frequently seen in patients with HIV infection

Chorioretinitis



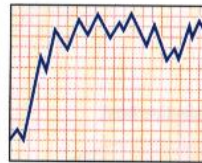
Lymphadenopathy



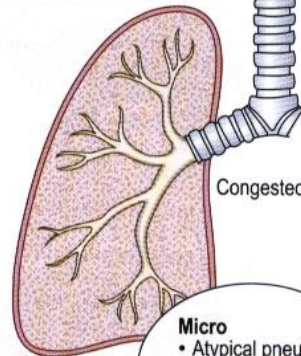
- Micro**
- Reactive hyperplasia
 - Conspicuous collections of histiocytes

'Glandular-fever-like' syndrome

Acute fever



Atypical pneumonia



Serous effusions

- Micro**
- Atypical pneumonia
 - Parasitized mononuclears in bronchi

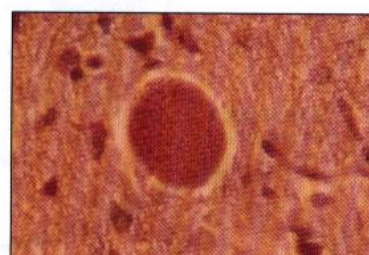
Laboratory diagnosis

Diagnosis is usually made serologically by demonstration of specific antibodies. Methods include Latex agglutination, ELISA and ISAGA. The 'gold standard' for *Toxoplasma* serological diagnosis is the Sabin-Feldman dye test.

Lymph node biopsy should not be required to diagnose *Toxoplasma* but if performed because another diagnosis was suspected, the findings are as stated above.



Toxoplasma tachyzoites



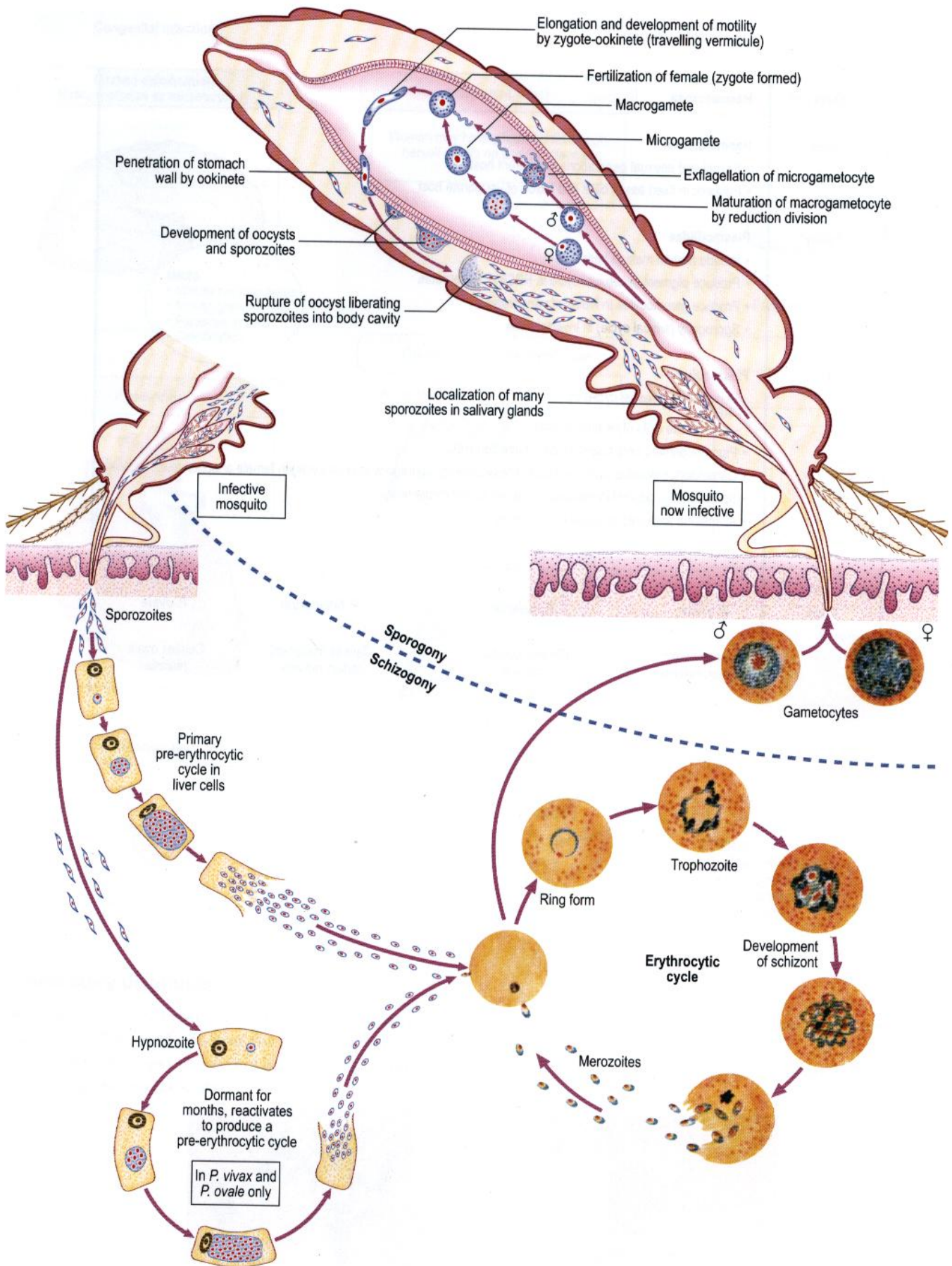
Toxoplasma pseudocyst (brain)

Malaria parasites

Classification

Class	Haematozoa								
Order	Haemosporida <ul style="list-style-type: none"> • Sexual and asexual generations in different hosts • Parasitic in fixed tissue cells and RBCs of vertebrate host 								
Family	Plasmodiidae <ul style="list-style-type: none"> • Include human malaria parasites • Produce pigment in asexual cycle in RBCs of vertebrates • Produce gametocytes in RBCs of vertebrates • Sporogony (sexual cycle) in invertebrates 								
Genus	Plasmodium <ul style="list-style-type: none"> • Schizogony (asexual cycle) in: <ul style="list-style-type: none"> – RBCs – other tissue cells of vertebrate host • Pigment derived from haemoglobin of infected RBC • Gametocytes develop in some RBCs. These undergo sporogony (sexual cycle) in female anopheline mosquitoes • Sporozoites produced in mosquito, infective to vertebrate host • All malaria parasites included in this genus 								
Class	<table border="0" style="width: 100%; text-align: center;"> <tr> <td style="border: none;"><i>P. vivax</i></td> <td style="border: none;"><i>P. malariae</i></td> <td style="border: none;"><i>P. falciparum</i></td> <td style="border: none;"><i>P. ovale</i></td> </tr> <tr> <td style="border: none;">Causes benign tertian malaria</td> <td style="border: none;">Causes quartan malaria</td> <td style="border: none;">Causes malignant tertian malaria</td> <td style="border: none;">Causes ovale malaria</td> </tr> </table>	<i>P. vivax</i>	<i>P. malariae</i>	<i>P. falciparum</i>	<i>P. ovale</i>	Causes benign tertian malaria	Causes quartan malaria	Causes malignant tertian malaria	Causes ovale malaria
<i>P. vivax</i>	<i>P. malariae</i>	<i>P. falciparum</i>	<i>P. ovale</i>						
Causes benign tertian malaria	Causes quartan malaria	Causes malignant tertian malaria	Causes ovale malaria						

Life cycle

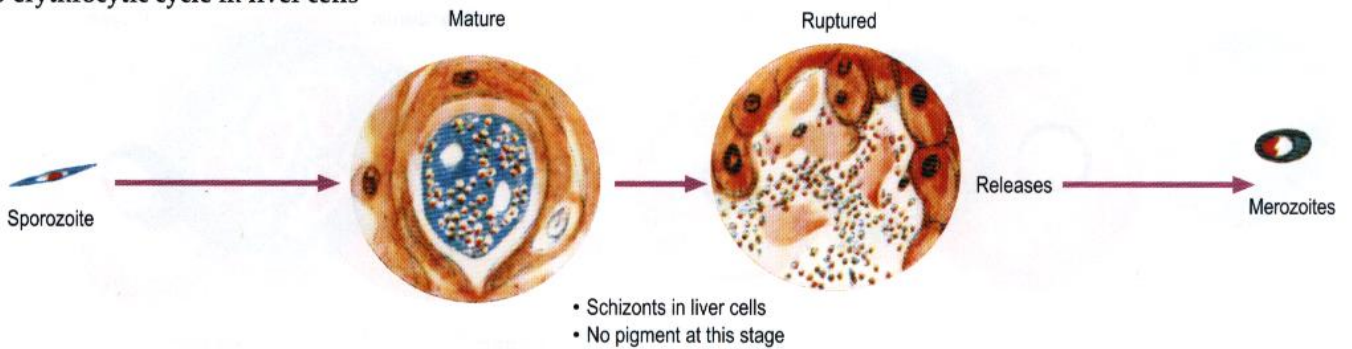


Morphology

Stained by Leishman or Giemsa

Schizogony (asexual cycle)

Pre-erythrocytic cycle in liver cells



Erythrocytic stage in RBCs

The parasite

- Cytoplasm blue
- Chromatin red
- Pigment (from haemoglobin) varies in colour and time of appearance

General features



The red cell

May vary in :

- Size



Normal RBC



- Shape



May contain :

- Schüffner's or James' dots

Pink spots in cytoplasm unoccupied by parasite



- Maurer's clefts



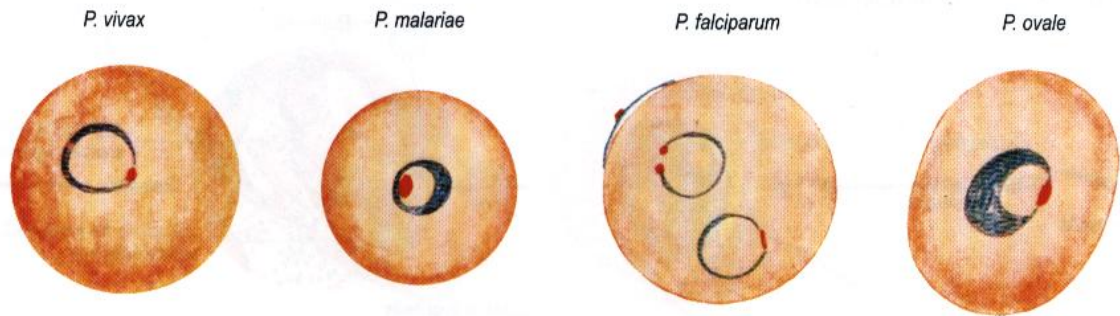
Brick red clefts in cytoplasm

RBC characteristics	<i>P. vivax</i>	<i>P. malariae</i>	<i>P. falciparum</i>	<i>P. ovale</i>
Size	Larger than mature RBC	Smaller, older RBC	Mature RBC	Larger than mature RBC
Colour	Pale	Normal	Normal	Pale
Shape	Round	Round	Round May be crenated	Oval May be fimbriated
Cytoplasmic inclusions	Schüffner's dots present	None	Maurer's clefts may be present in late trophozoites	James' dots conspicuous

Morphology (continued)

Stages in thin films

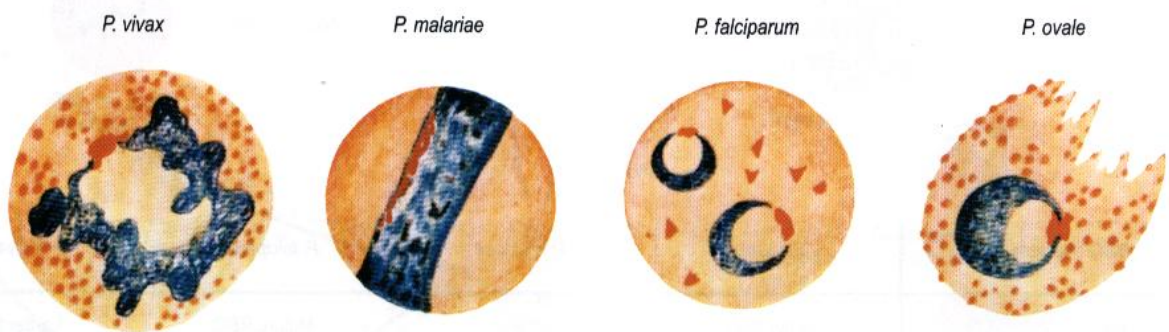
Ring forms (early trophozoites)



	<i>P. vivax</i>	<i>P. malariae</i>	<i>P. falciparum</i>	<i>P. ovale</i>
Size	1/3 RBC	Up to 1/3 RBC	1/3 RBC	1/3 RBC
Shape	Delicate ring	Compact ring	Very delicate ring	Dense ring
Chromatin	Fine dot	One mass often inside ring	Fine dots Frequently two	Dense, well-defined mass
Accolé forms*	Sometimes	None	Frequent	None
Pigment	None at this stage	May be present	None at this stage	None at this stage
Multiple parasitized cells	Sometimes	Rare	Frequently with high parasitaemia	Rare

* Forms situated on margin of RBC

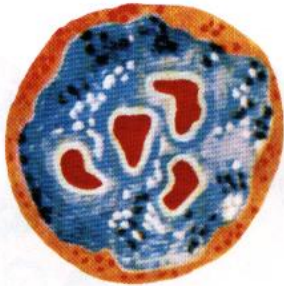Developing trophozoites



	<i>P. vivax</i>	<i>P. malariae</i>	<i>P. falciparum</i>	<i>P. ovale</i>
Size	Large	Small, but appears large relative to size of RBC	Small	Small
Shape	Very irregular, amoeboid	Compact, often band forms	Compact, with cytoplasmic vacuolation	Compact
Chromatin	Dots or threads	Prominent, often as a band	Dots or threads	Large irregular clumps
Pigment				
—texture	Fine	Coarse	Coarse	Coarse
—colour	Yellow brown	Dark brown	Black	Dark yellow brown
—quantity	Medium	Abundant	Medium	Medium
—distribution	Scattered fine particles	Scattered clumps and rods	Aggregated in one or two clumps	Scattered coarse particles

Immature schizonts

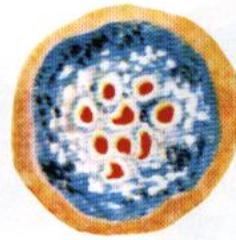
P. vivax



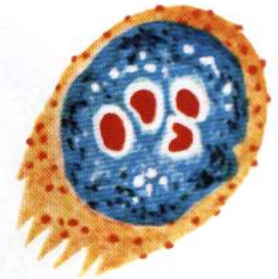P. malariae



P. falciparum



P. ovale

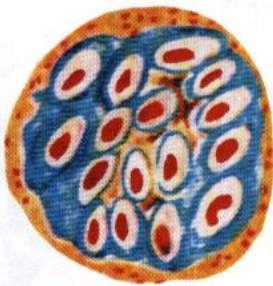


(rarely seen in peripheral blood)

Size	Almost fills RBC	Almost fills RBC	Almost fills RBC	Almost fills RBC
Shape	Somewhat amoeboid	Compact	Compact	Compact
Chromatin	Numerous irregular masses	Few irregular masses	Irregular masses	Few irregular masses
Pigment	Scattered	Scattered	Single clump	Scattered

Mature schizonts

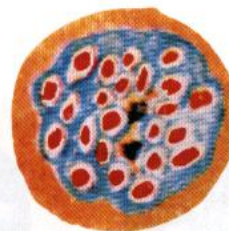
P. vivax



P. malariae



P. falciparum



P. ovale



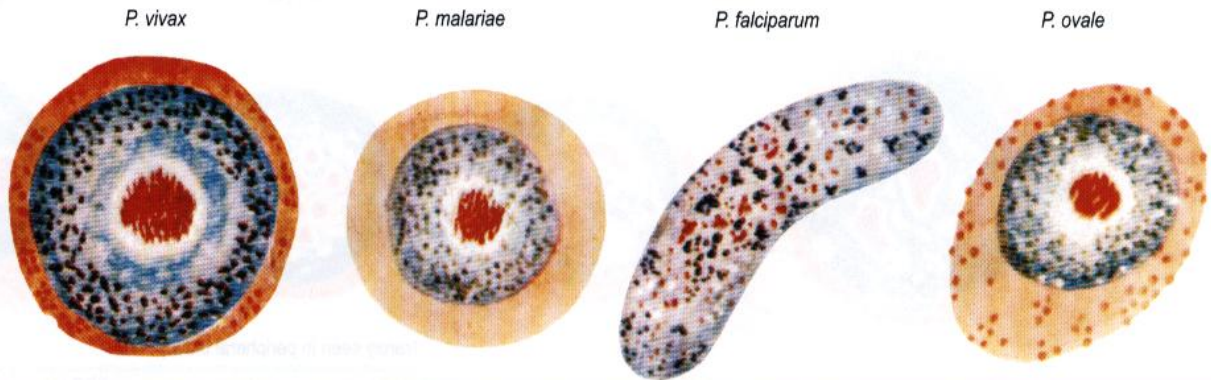
(rarely seen in peripheral blood)

Size	Fills RBC	Nearly fills RBC	Nearly fills RBC	Fills 3/4 RBC
Shape	Segmented	Segmented daisy head	Segmented	Segmented
Merozoites				
— range	14–24	6–12	8–32	6–12
— mean	16	8	24	8
— size	Medium	Large	Small	Large
Pigment	Aggregated in centre (yellow brown)	Aggregated in centre (dark brown)	Aggregated in centre (black)	Aggregated in centre (dark yellow brown)

Morphology (continued)

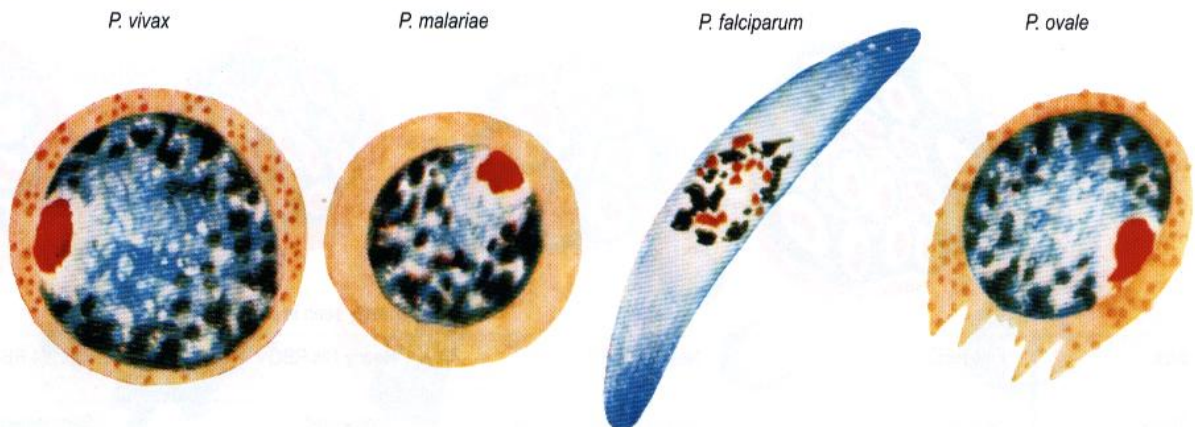
Stages in thin films (continued)

Microgametocytes (male)



	<i>P. vivax</i>	<i>P. malariae</i>	<i>P. falciparum</i>	<i>P. ovale</i>
Time of appearance	3–5 days	7–14 days	7–12 days	12–14 days
Number in bloodstream	Many	Scanty	Many	Scanty
Size	3/4 fills RBC	1/2 to 2/3 fills RBC	Larger than RBC	1/2 to 2/3 fills RBC
Shape	Round or oval compact	Round compact	Kidney-shaped Bluntly round ends	Round compact
Cytoplasm	Pale blue	Pale blue	Reddish blue	Pale blue
Chromatin	Single chromatin mass	As for <i>P. vivax</i>	Fine granules scattered throughout	As for <i>P. vivax</i>
Pigment	Abundant brown granules throughout	As for <i>P. vivax</i>	Dark granules throughout	As for <i>P. vivax</i>

Macrogametocytes (female)

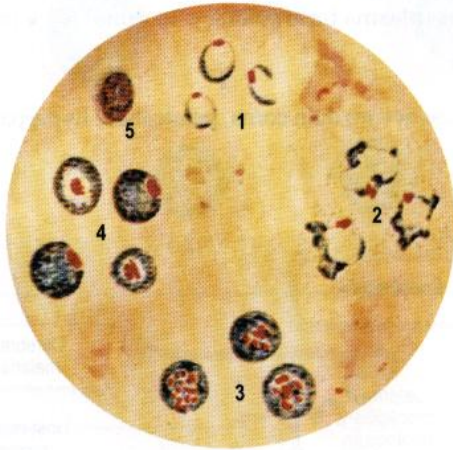


	<i>P. vivax</i>	<i>P. malariae</i>	<i>P. falciparum</i>	<i>P. ovale</i>
Time of appearance	3–5 days	7–14 days	7–12 days	12–14 days
Number in bloodstream	Many	Scanty	Many	Scanty
Size	3/4 fills RBC	1/2 to 2/3 fills RBC	Larger than RBC	1/2 to 2/3 fills RBC
Shape	Round or oval compact	Round compact	Crescentic-sharply rounded or pointed ends	Round compact
Cytoplasm	Dark blue	Dark blue	Dark blue	Dark blue
Chromatin	Compact peripheral mass	As for <i>P. vivax</i>	Compact masses near centre	As for <i>P. vivax</i>
Pigment	Small masses round periphery	As for <i>P. vivax</i>	Black, rod-like granules round nucleus	As for <i>P. vivax</i>

Morphology in stained thick films

Note that the parasites are not flattened in the film and so appear smaller than in thin film. The red cells are haemolyzed in processing so there is no guide to the size, shape or colour of the RBCs. Schüffner's dots are indefinite and there are no Maurer's clefts.

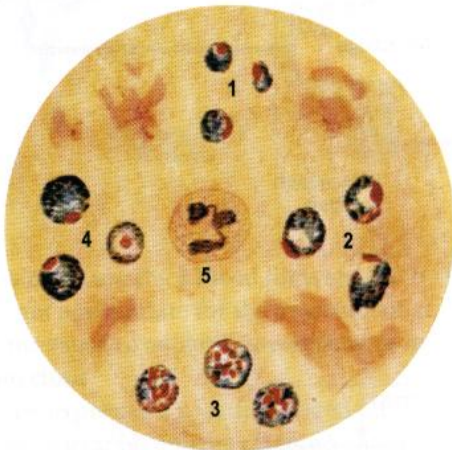
P. vivax



1. Ring forms, small fine rings often broken
2. Trophozoites, markedly irregular cytoplasm
3. Schizonts, many (average 16) small merozoites
4. Gametocytes, compact parasites with features of ♂ and ♀ as described
5. White blood cell

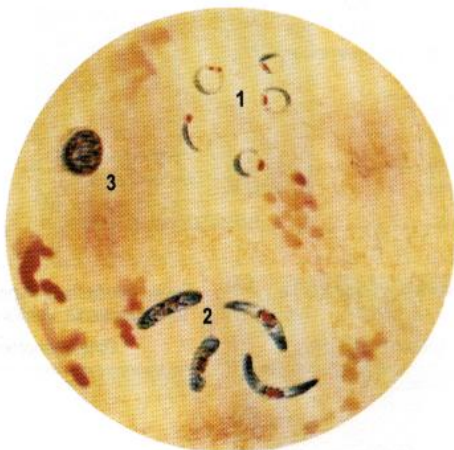P. malariae and *P. ovale*

Almost identical but James' dots may be visible in the latter



1. Ring forms, compact rings
2. Trophozoites, solid regular cytoplasm
3. Schizonts, few (average 8) large merozoites
4. Gametocytes, very difficult to distinguish from *P. vivax*
5. White blood cell

P. falciparum



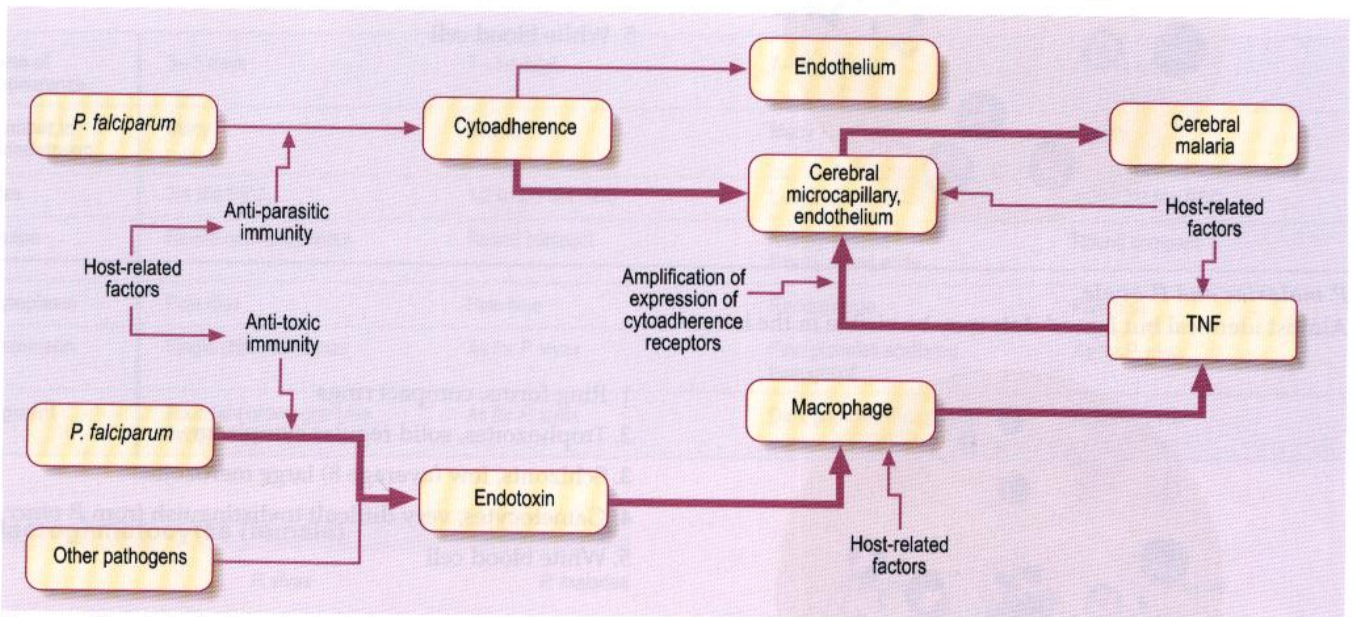
1. Ring forms, very small, fine rings usually unbroken trophozoites (with vacuolated cytoplasm) and schizonts are rarely seen in peripheral blood
2. Gametocytes, characteristic crescentic ♂ and ♀ forms
3. White blood cell

Pathology and Clinical features

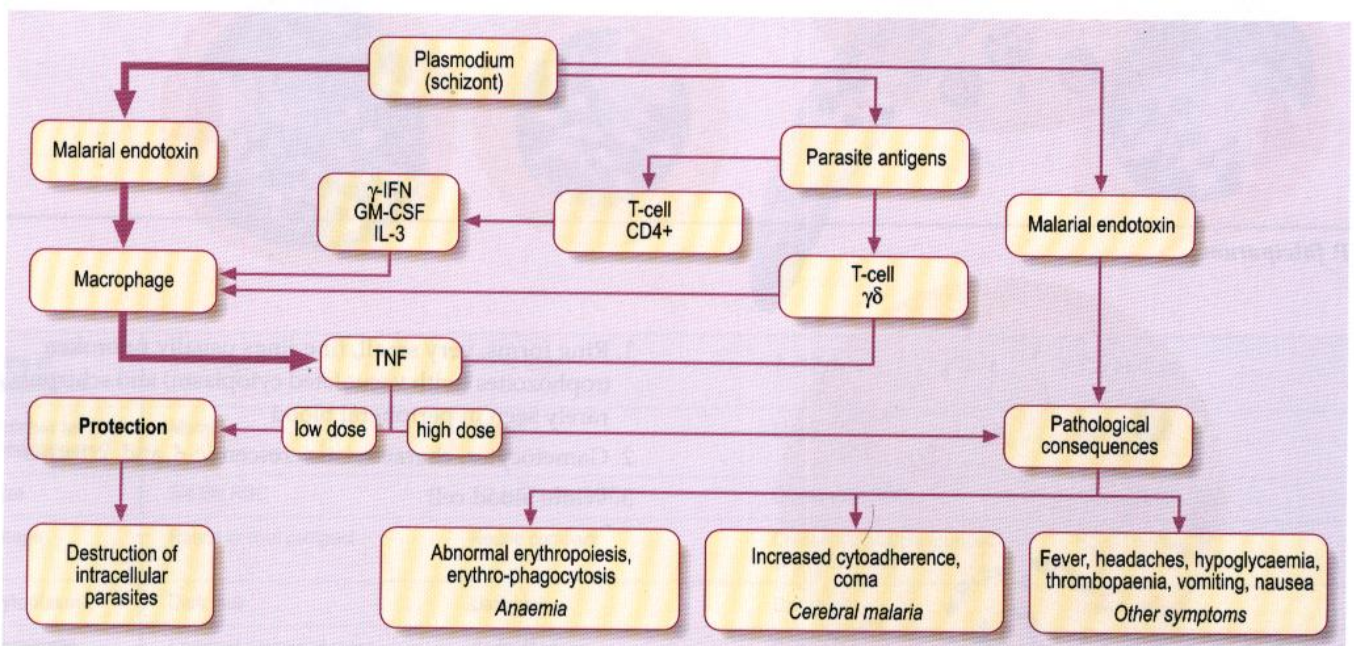
Plasmodium vivax, *P. ovale*, *P. malariae* and uncomplicated *P. falciparum* malaria have similar features with fever, rigors, headache, muscle aches, malaise and anorexia. Anaemia may develop and the liver and spleen may become enlarged. Because the clinical appearances are non-specific, malaria may be misdiagnosed, e.g. as a viral infection, with severe consequences.

Plasmodium falciparum infection can readily progress to severe malaria, the clinical criteria of which have been defined by a World Health Organisation working group. One or more of the following features in the presence of asexual parasitaemia indicate severe falciparum malaria: • cerebral malaria • severe anaemia • renal failure • pulmonary oedema or adult respiratory distress syndrome • hypoglycaemia • circulatory collapse or shock • spontaneous bleeding from the gums, nose, gastrointestinal tract and/or laboratory evidence of disseminated intravascular coagulation • repeated generalised convulsions (more than two in 24 hours despite cooling) • acidaemia (arterial pH < 7.25) or acidosis (plasma bicarbonate < 15 mmol/L) • macroscopic haemoglobinuria.

Other features of severe falciparum malaria include impaired consciousness less severe than coma, prostration, hyperparasitaemia, jaundice and hyperpyrexia.



Sequence of events leading to cerebral malaria

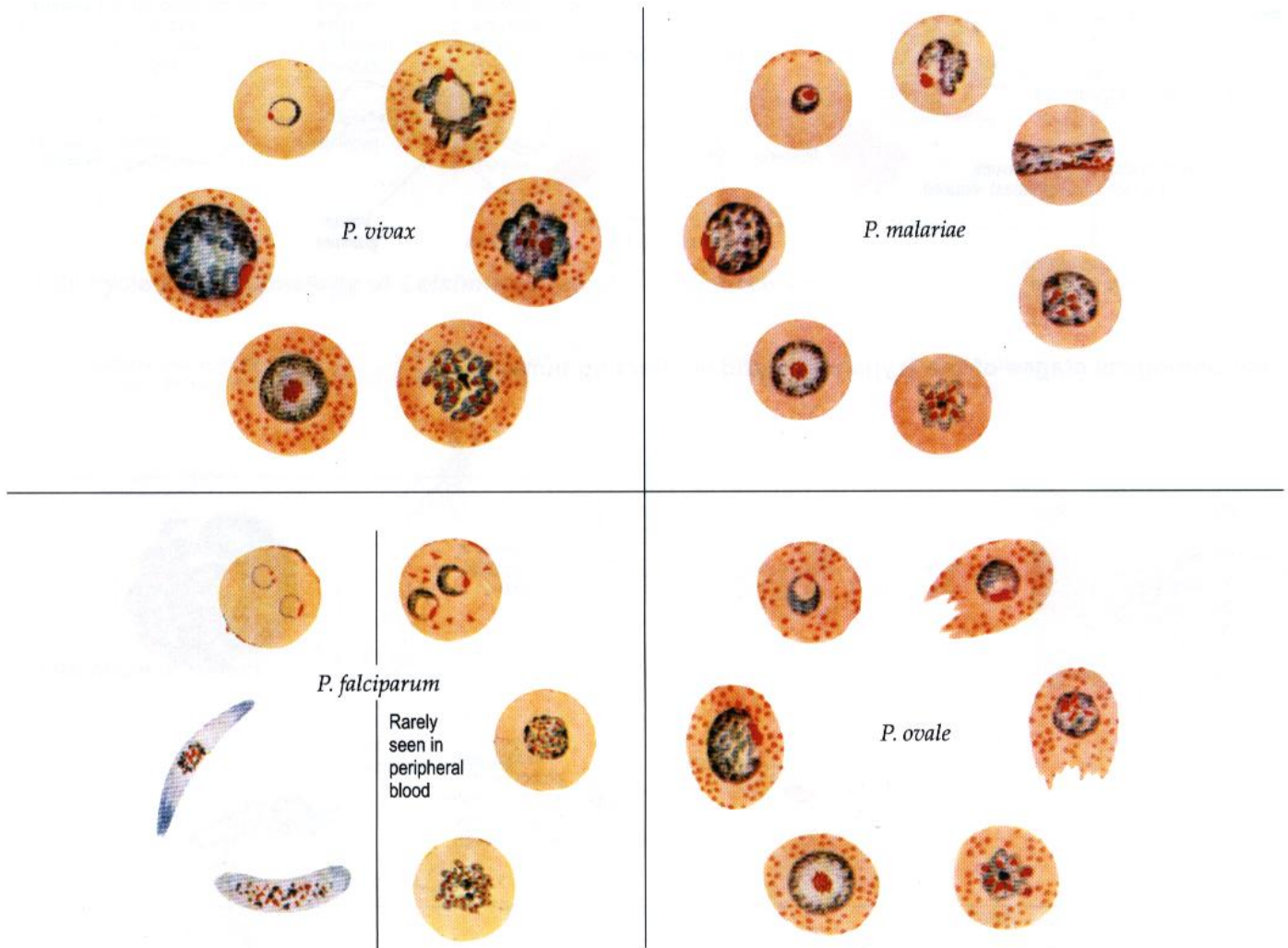


Role of TNF

(Both of the above figures after Figs 20.17 and 20.18 in Hommel M, Gilles H M, *Malaria* (Chapter 20). In Cox E G, Kreier J P, Wakelin D, eds. *Topley and Wilson's Microbiology and Microbial Infections*, Vol 5. Parasitology. London: Arnold; 1998)

Laboratory diagnosis

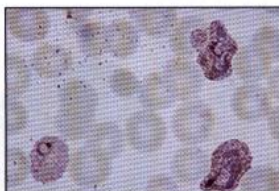Malaria parasites in thin blood film. Stained by Leishman or Giemsa at pH 7.2



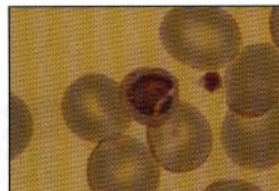It is also possible to use thick blood films stained by Field or Giemsa. Bone marrow films may also be examined. Serology (IFAT or ELISA) is not appropriate for the detection of acute malaria but is deployed as a retrospective test for epidemiological use to establish the cause of nephrotic syndrome or hyperreactive malarial splenomegaly (HMS).

Antigen Detection

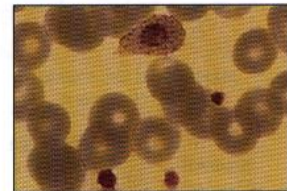
P. falciparum expresses a specific antigen HRP2 on the surface of the parasitized RBC. This can be detected by using immunochromatographic antigen capture techniques (AMRAD ICT, Becton Dickinson ParaSight F). Parasite lactate dehydrogenase (pLDH) is biochemically and antigenically distinct from human LDH and is produced by all *Plasmodium* species. Gold-labelled monoclonal and polyclonal antibodies can be used in an immunochromatographic technique to detect pLDH in whole blood (OptiMAL, Flow Inc., Portland OR).



P. vivax trophozoites



P. malariae: late trophozoite



P. ovale trophozoite



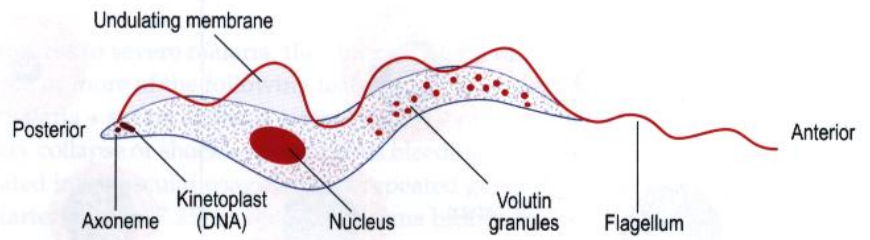
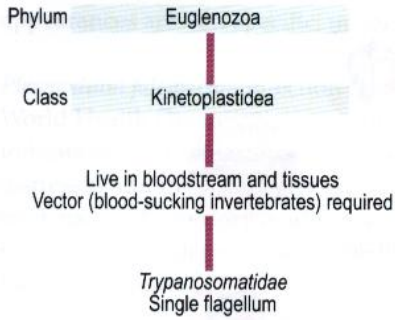
P. falciparum trophozoites



P. falciparum gametocyte

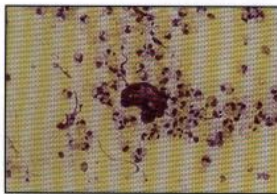
Body-fluid and tissue flagellates

Classification

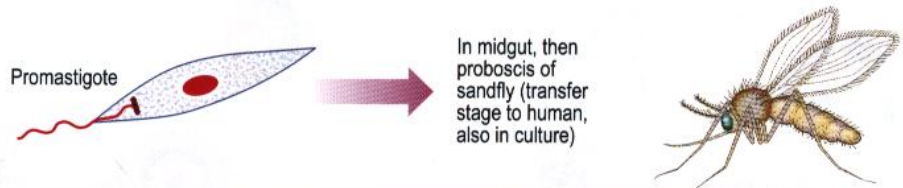
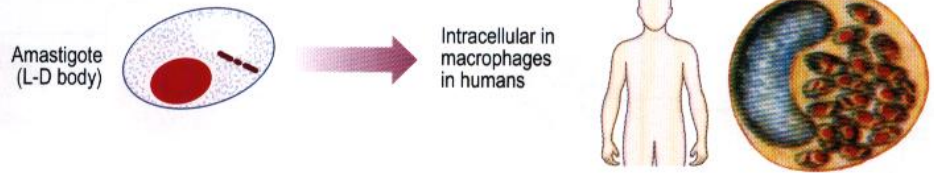


Morphological stages of the Trypanosomatidae affecting humans

Leishmania spp.

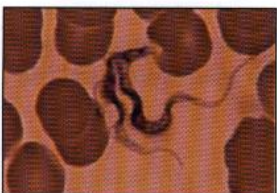

Leishmania amastigotes


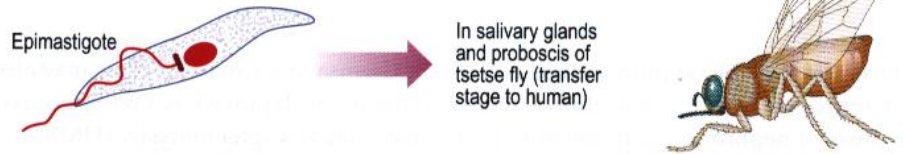


Trypanosoma spp.

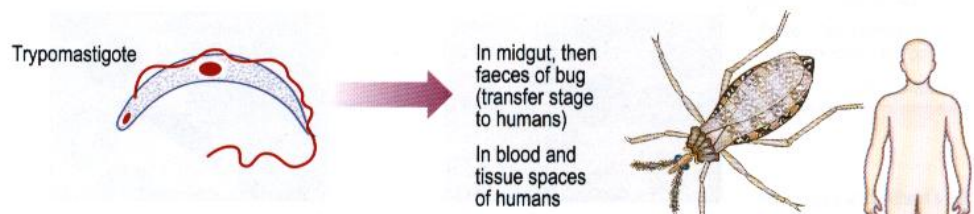
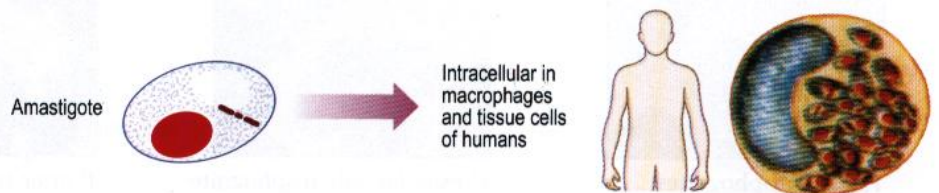
Trypanosoma brucei rhodesiense
Trypanosoma brucei gambiense



Trypomastigote



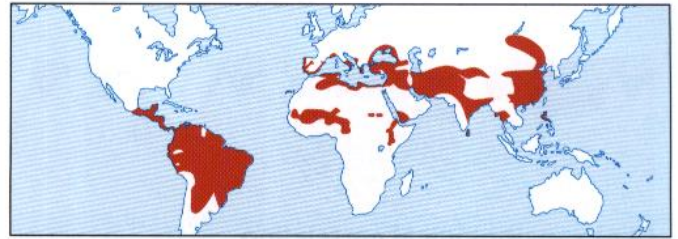
Trypanosoma cruzi



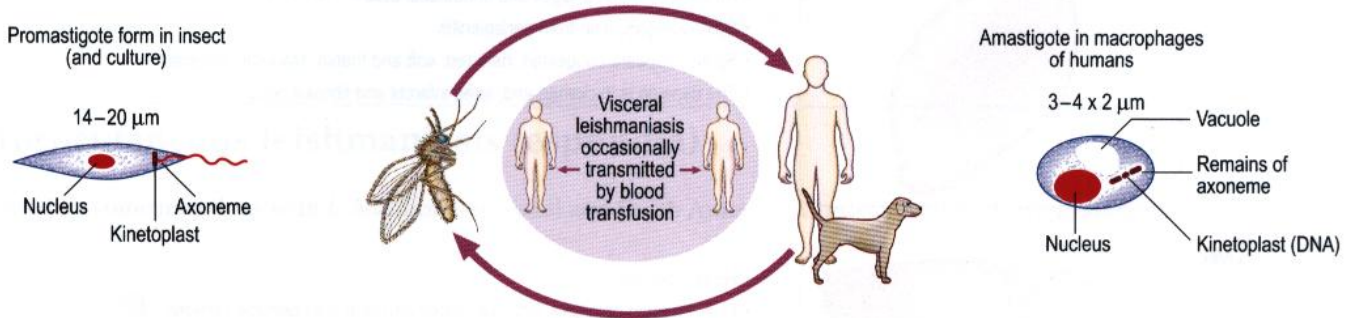
Leishmaniasis

Species	<i>L. donovani</i> complex <i>L. infantum</i> <i>L. donovani</i> <i>L. chagasi</i>	<i>L. tropica</i> <i>L. major</i> <i>L. aethiopica</i> <i>L. infantum</i>	<i>L. braziliensis</i> complex <i>L. amazonensis</i> <i>L. mexicana</i>
Disease	Visceral (kala azar)	Cutaneous	Muco-cutaneous (Espundia)

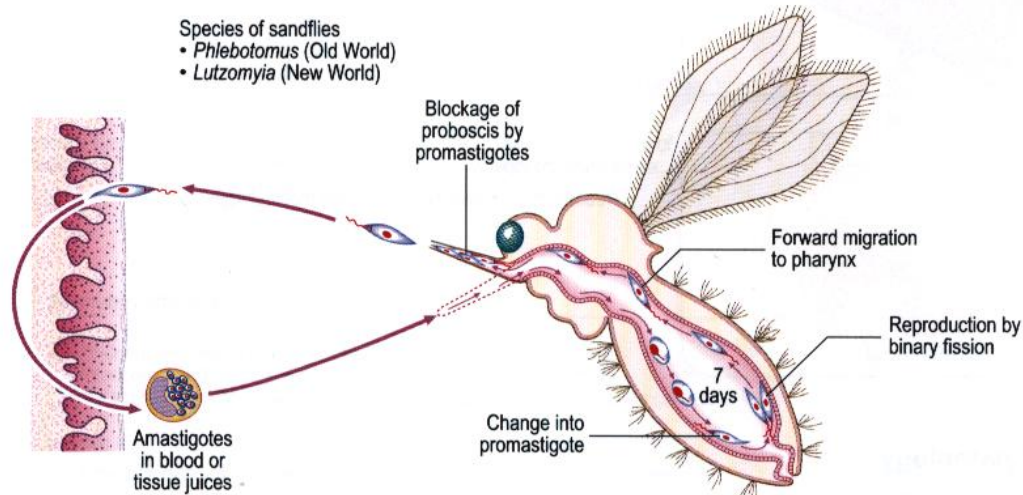
Distribution



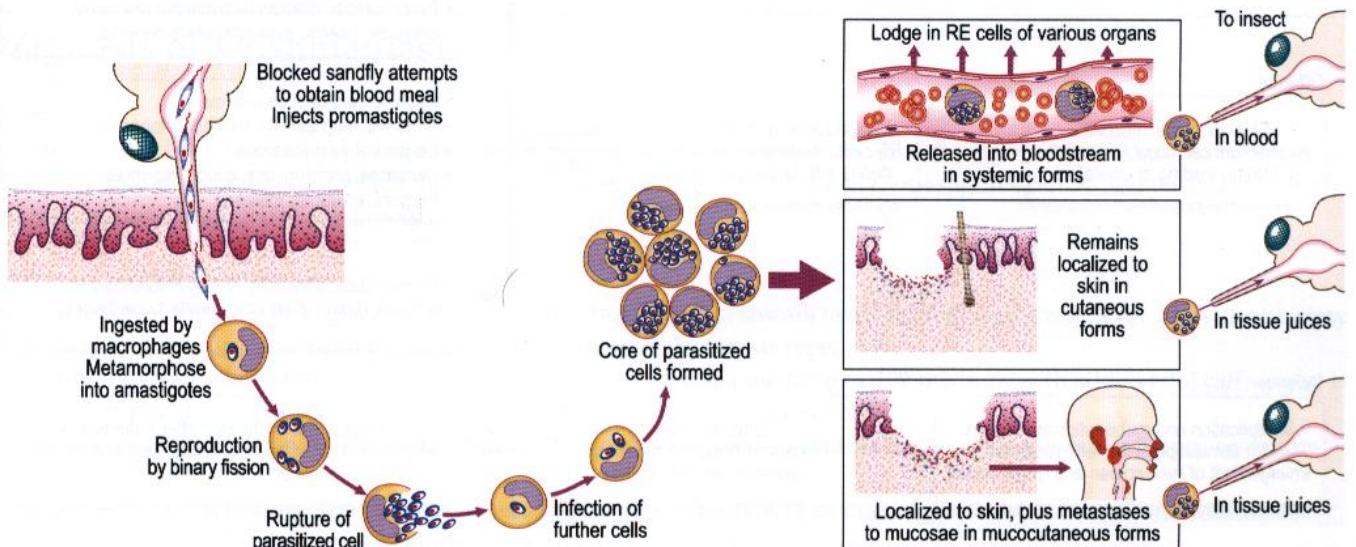
Life cycle and morphology of *Leishmania* (similar in all three species)



Life cycle in insect

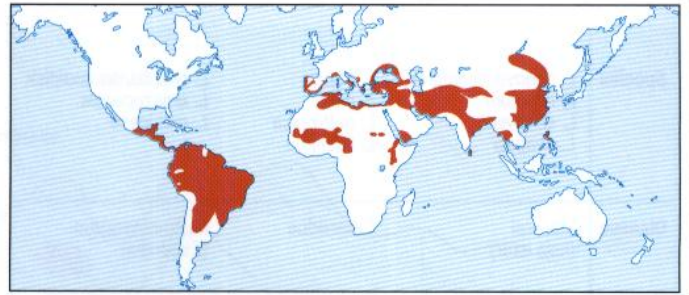


Life cycle in humans and reservoir animals



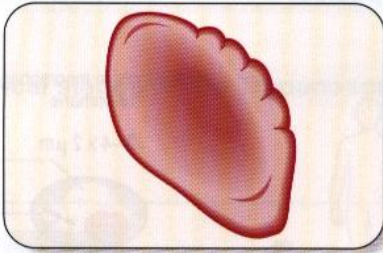
Visceral leishmaniasis (kala azar)

Distribution



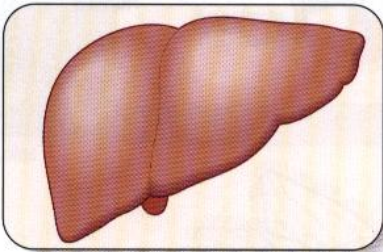
Clinico-pathological correlation

Spleen



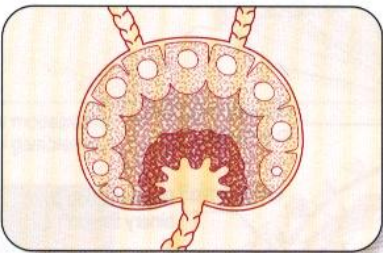
- Parasitized macrophages and endothelial cells
- Splenomegaly, pain from perisplenitis
- Spleen appears congested, dark red, soft and friable. Markedly enlarged
- The capsule is thickened and, later, infarcts and fibrosis occur

Liver



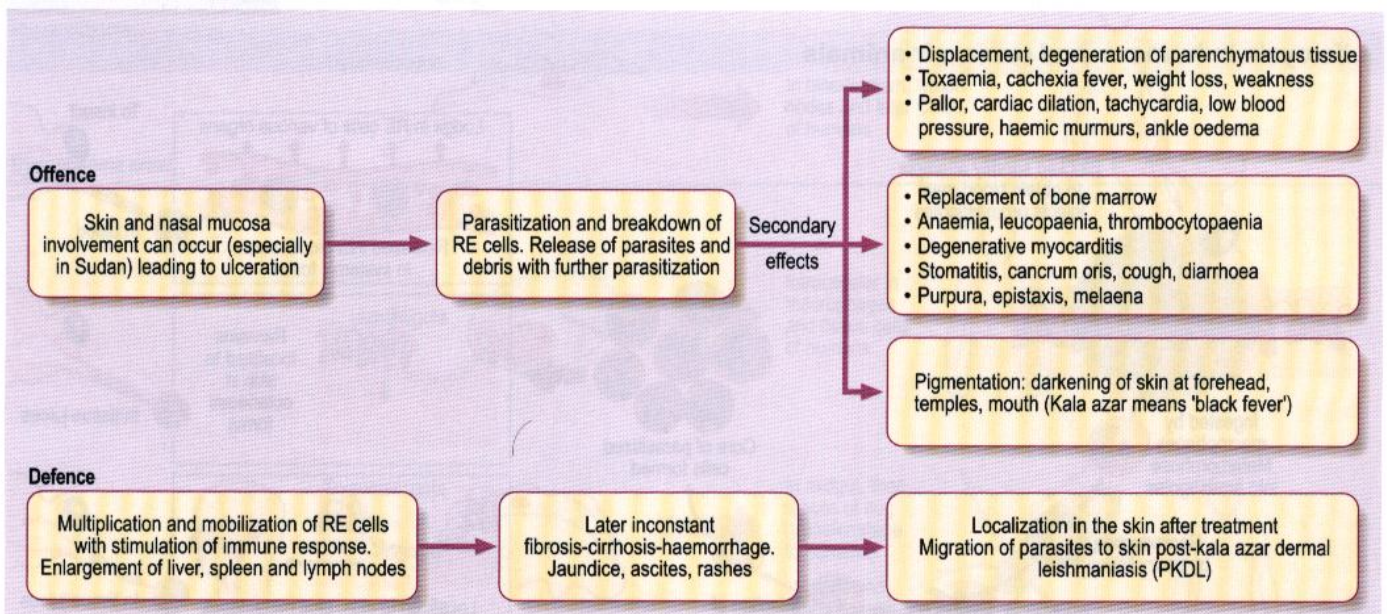
- Hepatomegaly
- Liver appears enlarged, fatty congested and later may become cirrhotic
- Parasitized proliferated Kupffer cells with atrophy of the liver cells and later fibrosis

Lymph nodes



- Lymphadenopathy
- Reactive hyperplasia with parasitized macrophages

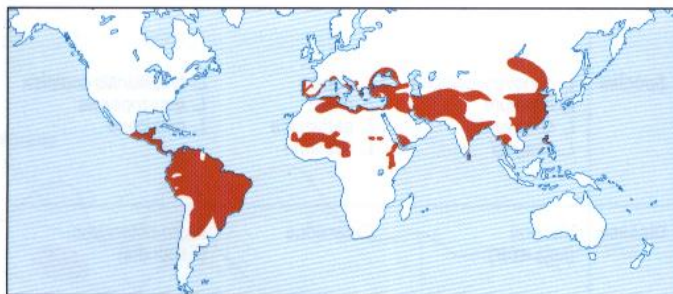
Mechanism of pathology



Both offensive and defensive processes give rise to increased serum globulin and reversal of a/g ratio.

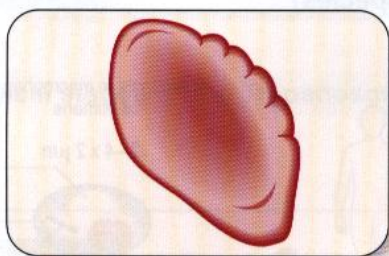
Visceral leishmaniasis (kala azar)

Distribution



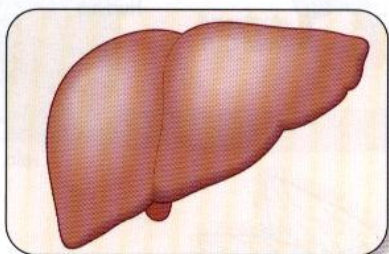
Clinico-pathological correlation

Spleen



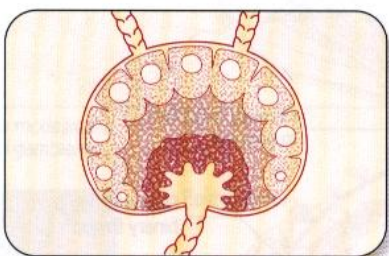
- Parasitized macrophages and endothelial cells
- Splenomegaly, pain from perisplenitis
- Spleen appears congested, dark red, soft and friable. Markedly enlarged
- The capsule is thickened and, later, infarcts and fibrosis occur

Liver



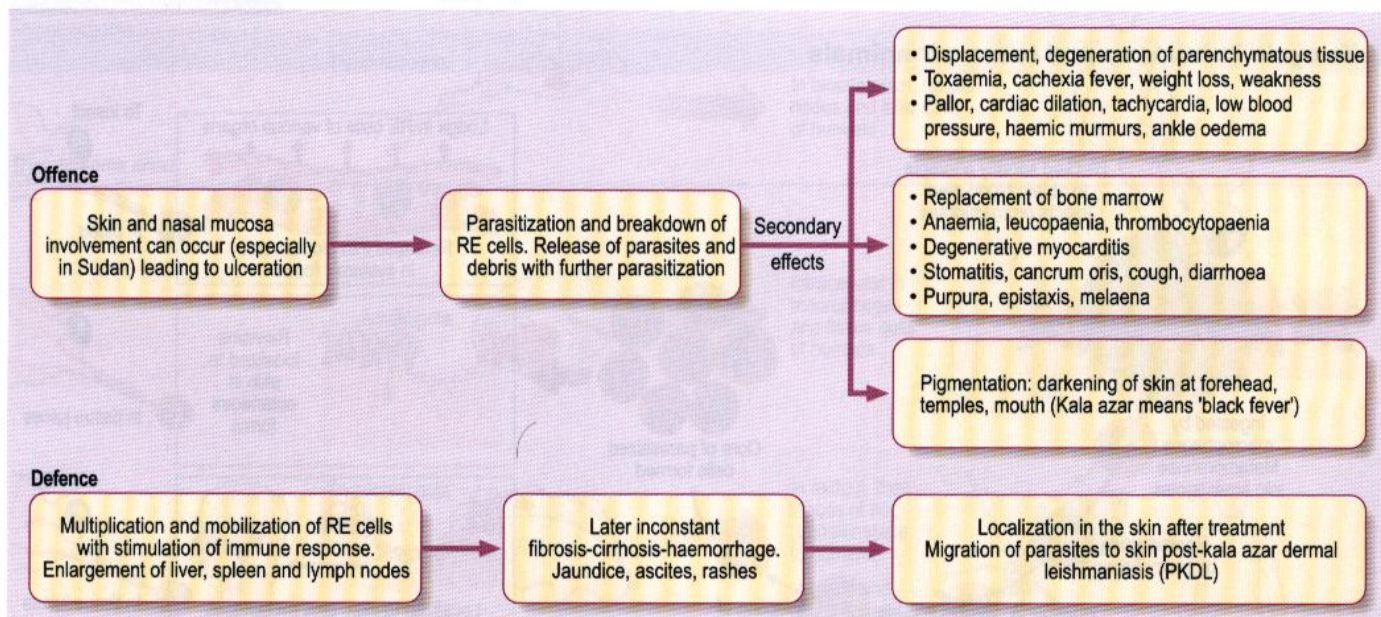
- Hepatomegaly
- Liver appears enlarged, fatty congested and later may become cirrhotic
- Parasitized proliferated Kupffer cells with atrophy of the liver cells and later fibrosis

Lymph nodes



- Lymphadenopathy
- Reactive hyperplasia with parasitized macrophages

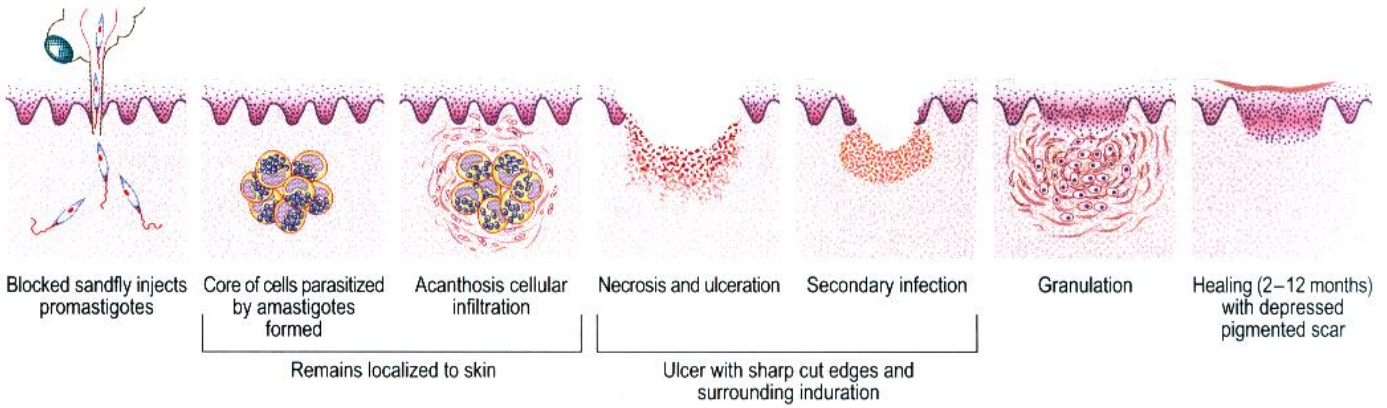
Mechanism of pathology



Both offensive and defensive processes give rise to increased serum globulin and reversal of a/g ratio.

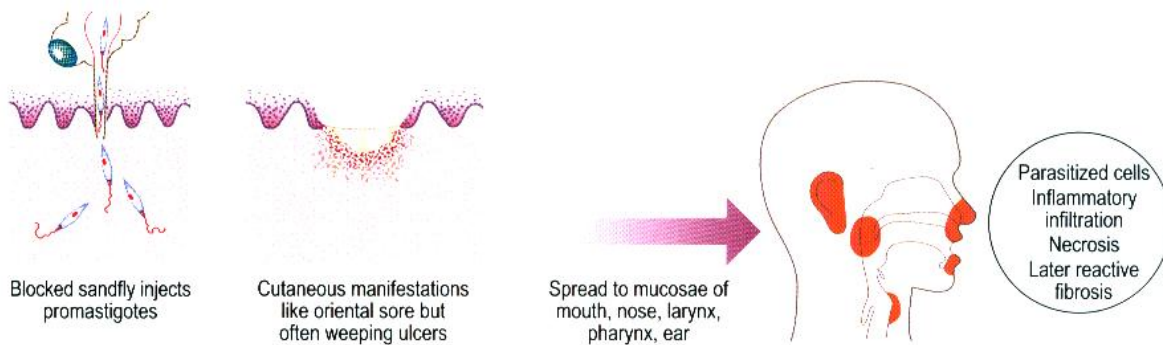
Cutaneous leishmaniasis

Caused by *Leishmania tropica*, *L. major*, *L. aethiopica*, *L. infantum*, *L. braziliensis* complex



Mucocutaneous leishmaniasis (espundia)

Caused by some infections with *L. braziliensis* (Central and South America), *L. aethiopica* (Ethiopia), *L. mexicana*



Secondary effects in loose mucosal tissues

- Oedema and capillary involvement
 - Interference with local blood supply
 - Necrosis - extensive destruction
 - Secondary infection
 - Deep erosion locally
 - Spread of infection to lungs or elsewhere
 - Healing with fibrosis
- Leading to:
- Extensive disfiguring lesions
 - General constitutional upset (fever, pain, anaemia)
 - Bronchopneumonia and septicaemia

Diagnosis of Leishmaniasis

Visceral

Amastigotes can be demonstrated by staining bone marrow, lymph node fluid, nasal scrapings (in the Sudan), liver biopsy or splenic aspiration specimens (although this can be a dangerous procedure). Rarely, amastigotes can be demonstrated in buffy coat preparations from peripheral blood.

Cutaneous and mucocutaneous

Demonstration of the parasite is possible in stained films from slit-skin smears taken from the indurated edge of an ulcer, biopsy of the margin of the ulcer and from mucosal scrapings in mucocutaneous type.

Culture (NNN or a liquid medium such as Schneider's *Drosophila* medium or 199 medium with added fetal calf serum) is used for all types of material for diagnosis. Animal inoculation is rarely used now.

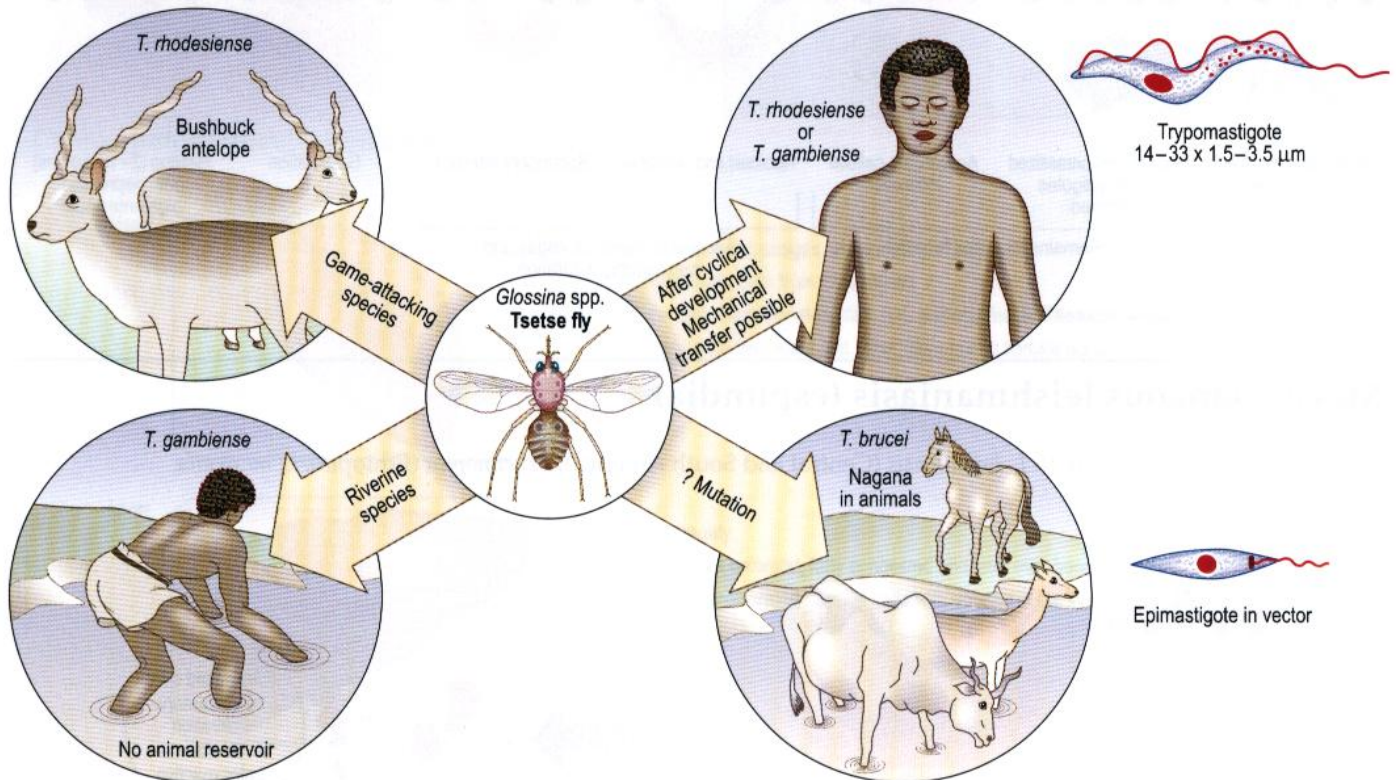
Polymerase chain reaction (PCR) can be used to diagnose and type the species of *Leishmania* present in biopsy or culture material.

Specific serological tests are IFAT, ELISA, direct agglutination test (DAT), or latex agglutination for IgG antibodies. An immunochromatographic test for rK39 antibody detection is also available.

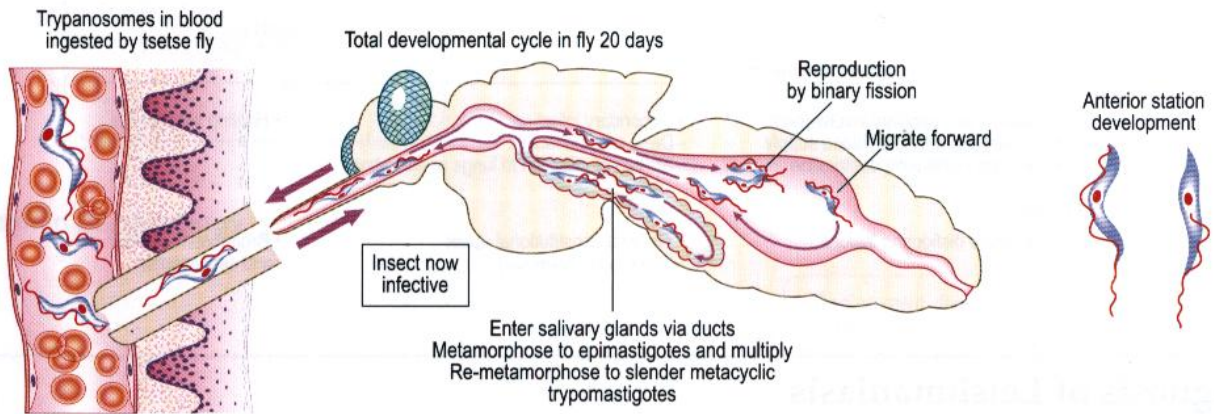
Trypanosomiasis

African type: sleeping sickness

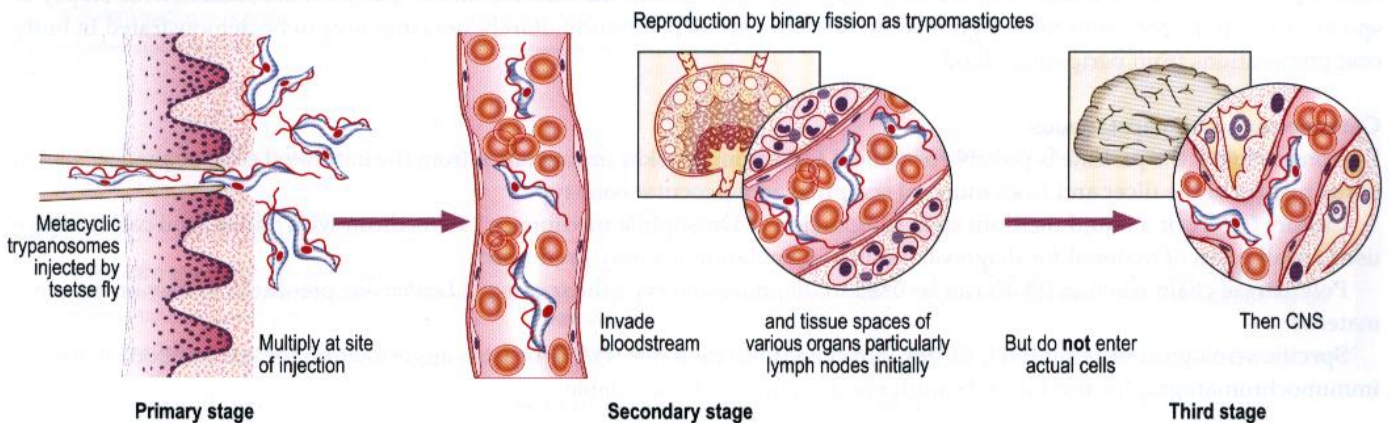
Caused by either *Trypanosoma gambiense* (chronic sleeping sickness, found in West Africa, the Congo, Zaire) or by *T. rhodesiense* (acute sleeping sickness, found in Zimbabwe, Tanzania, Zambia, Angola). Both have similar life cycle and morphology.



Life cycle in insect

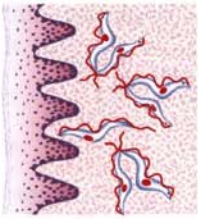


Life cycle in humans



Pathogenesis and pathology

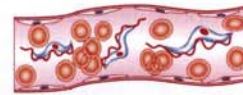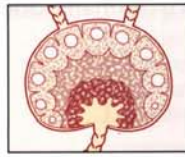
Primary stage



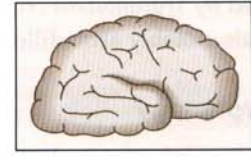
- Multiplication at site of injection
- Surrounding inflammatory reaction

Local inflammatory lesion

Secondary stage



Third stage



- Parasitaemia and toxæmia
- Invasion of tissue spaces (not cells) of various organs

Lymph nodes — Predominantly — CNS

- Damage to endothelial cells of blood vessels, surrounding (perivascular) granulomatous reactions and haemorrhages

Toxic degeneration and pressure atrophy of tissue cells

Chronic sleeping sickness (Due to *T. gambiense*)

Differ only in degree

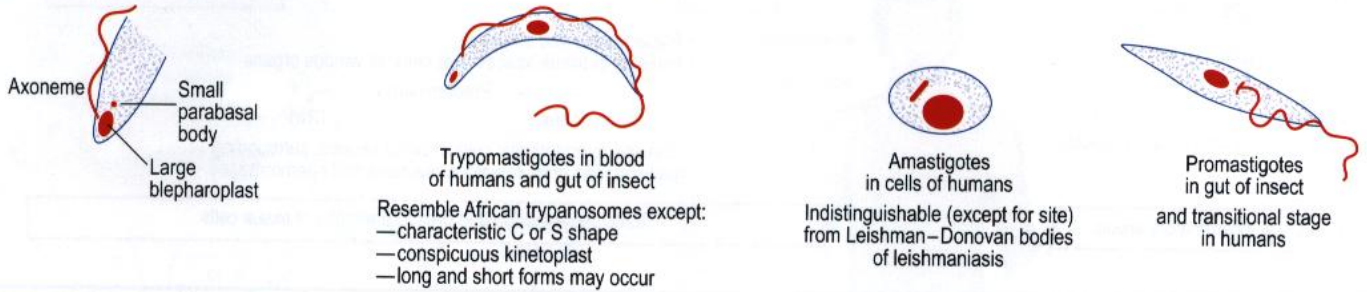
Acute sleeping sickness (Due to *T. rhodesiense*)

Clinico-pathological correlation	Primary stage		Clinico-pathological correlation
Firm, tender, painful red nodule 1–3 weeks	 Trypanosomal chancre	 Trypanosomal chancre	As in chronic
	Secondary stage – predominantly blood and lymph node involvement		
Fever • Low • Irregular • Recurrent	 Congestion Sinus catarrh Perivascular cuffing Enlarged, soft, red. Later regress, fibrotic	 Similar lesions not so pronounced	Fever • High • Persistent
General toxic symptoms • Backache • Headache • Tachycardia • Irregular skin rashes (circinate) • Transient oedema face	 Congested, slightly enlarged	 Slightly enlarged	Severe toxic symptoms • Headache • Vomiting • Shivering • Oedema face • Serous effusion • Bone pain
Lymphadenopathy • Typically post-cervical	 Toxic depression Bone marrow	 Toxic depression Bone marrow	Lymphadenopathy Myocarditis Anaemia Purpura Hepatitis
Later anaemia monocytosis			Often death at this stage
Slight enlargement liver, spleen	Third stage – CNS involvement		
Progressive involvement of the CNS General symptoms of progressive encephalitis Focal signs uncommon Dementia	 Generalized leptomeningitis Dura thickened and adherent Oedema with flat convolutions and dilated ventricles Haemorrhage with softening CSF turbid, increase cells and protein, containing trypanosomes. Perivascular cuffing with round and plasma cells, macrophages and endothelial cells Neuroglial proliferation Pressure atrophy neurones	 Death before CNS involvement or Similar changes but more acute	May have early onset of encephalitis with rapid development of coma
Note on epidemiology – Vectors of <i>T. gambiense</i> are riverine species, hence disease often epidemic: • <i>G. palpalis</i> • <i>G. tachinoides</i>	Vectors of <i>T. rhodesiense</i> are game-attacking species, hence disease more often sporadic: • <i>G. morsitans</i> • <i>G. pallidipes</i> • <i>G. swynnertoni</i>		

South American type: Chagas' disease

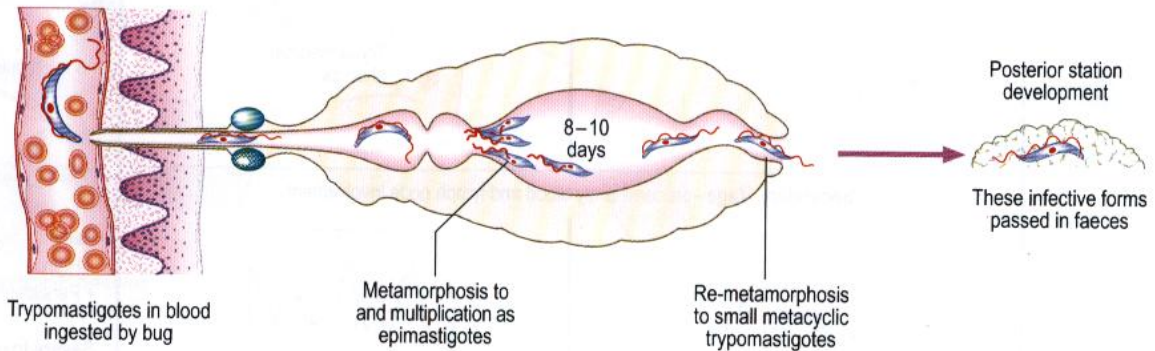
Caused by *Trypanosoma cruzi*. The parasite is harboured in humans, domestic animals such as cats and dogs, and some wild animals, notably armadillos and opossums.

Morphology

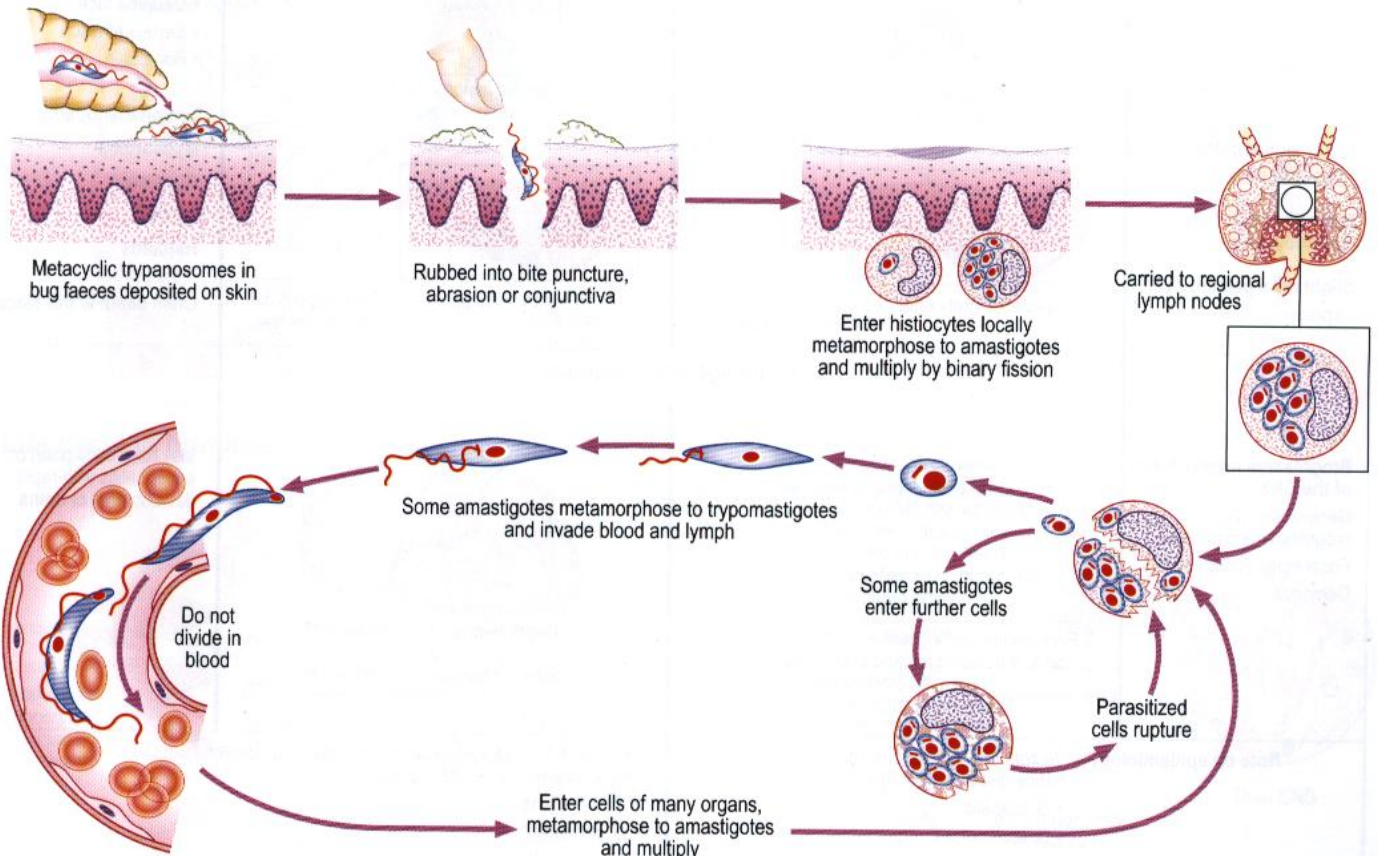


Life cycle in insect

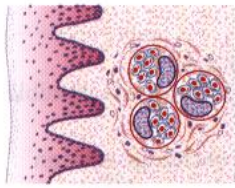
Triatoma spp: the cone bug



Life cycle in humans



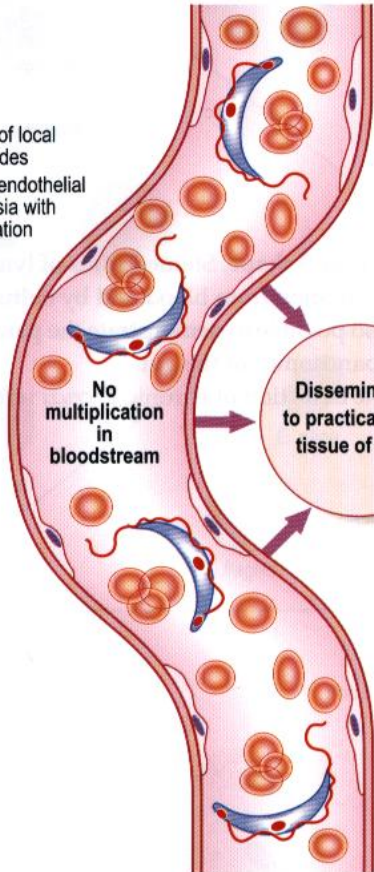
Pathogenesis and pathology



Local invasion of histocytes
Inflammatory reaction
Fibrosis: lymph blockage
Oedema

Chagoma

Invasion of blood and lymph vessels by trypanosomal forms



No multiplication in bloodstream

Dissemination to practically any tissue of body

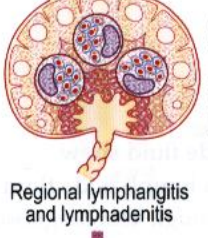
Fundamental pathogenesis
Invasion and destruction of tissue cells by multiplying amastigote forms with functional disability

Parasitization of reticulo-endothelial and parenchymatous cells by amastigote forms which multiply and destroy cells

Recurring re-invasion of the blood by trypanosomal forms and further dissemination

Acute symptoms
• Fever
• Swelling of eyelids (Romana's sign)

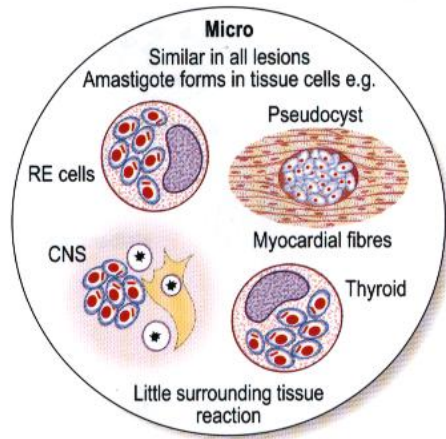
- Myocarditis
• Tachycardia
• Heart block
• Emboli
• Aneurysms
- Generalized lymphadenopathy
- Encephalitis
• General or focal CNS signs and symptoms
- Splenomegaly
- Hepatomegaly
- Toxic depression of bone marrow
• Anaemia
- Destruction of intestinal nerve plexus
• Megaesophagus
• Megacolon



Invasion of local lymph nodes
Reticulo-endothelial hyperplasia with parasitization

Regional lymphangitis and lymphadenitis

Systemic manifestations



Micro

Similar in all lesions
Amastigote forms in tissue cells e.g.

- RE cells
- Pseudocyst
- CNS
- Myocardial fibres
- Thyroid

Little surrounding tissue reaction

Acute form (often in children)
• Blood and reticulo-endothelial cells predominantly involved
• Fever
• Oedema
• Lymphadenopathy
• Enlargement of liver and spleen
• Sometimes encephalitis

Death or

Chronic form
• General toxic symptoms and focal signs depending on localization
• Predominantly cardiac and CNS manifestations
• May be asymptomatic

Laboratory diagnosis of trypanosomiasis

African type (sleeping sickness)

Demonstration of the parasite.

Microscopy of thin and thick blood films and buffy coat preparations.

Trypanosomes can also be seen in smears from bone marrow and centrifuged cerebrospinal fluid (CSF). Culture is possible but difficult.

Microscopic detection of trypanosomes in peripheral blood may be improved by the use of a mini-anion-exchange column or by the use of the QBC11[®] (Becton Dickinson) to concentrate the parasite.

The CSF might show increased protein and lymphocytes.

South American type (Chagas' disease)

Demonstration of the parasite.

Stained smears of peripheral blood show trypanosomal forms in C or S shape. Stained films of lymph node fluid show amastigotes. It is possible to show trypomastigotes by animal inoculation from blood and by culture from lymph node fluid. Histological methods from biopsy or post-mortem material. It is also possible to demonstrate the parasite through xenodiagnosis: clean bred triatomid bugs fed on the patient's blood develop trypanosomes in the gut.

Serology (e.g. by ELISA or IFAT) is the method of choice for the detection of chronic *T. cruzi* infection.

Laboratory diagnosis of trypanosomiasis

African type (sleeping sickness)

Demonstration of the parasite.

Microscopy of thin and thick blood films and buffy coat preparations.

Trypanosomes can also be seen in smears from bone marrow and centrifuged cerebrospinal fluid (CSF). Culture is possible but difficult.

Microscopic detection of trypanosomes in peripheral blood may be improved by the use of a mini-anion-exchange column or by the use of the QBC11[®] (Becton Dickinson) to concentrate the parasite.

The CSF might show increased protein and lymphocytes.

South American type (Chagas' disease)

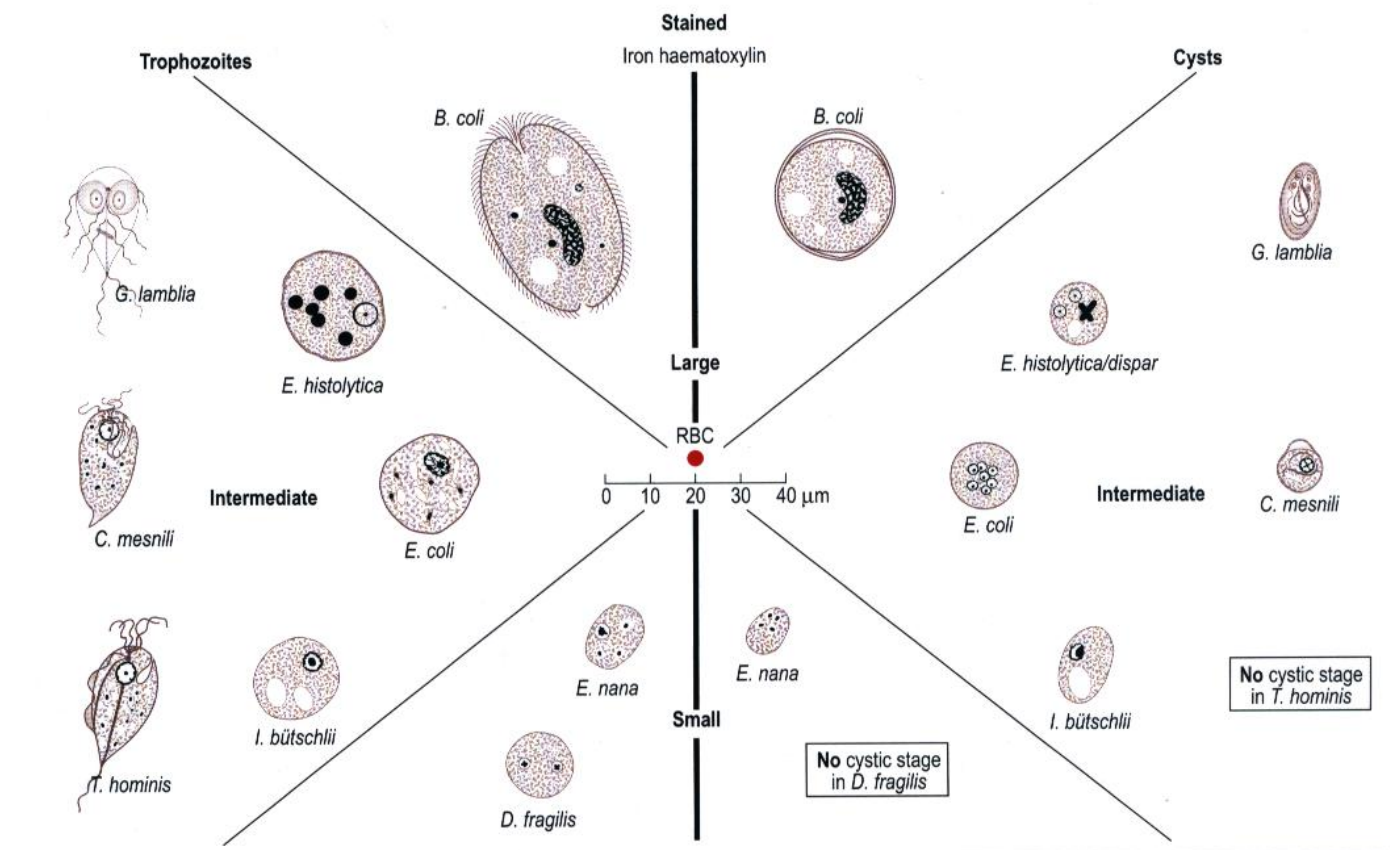
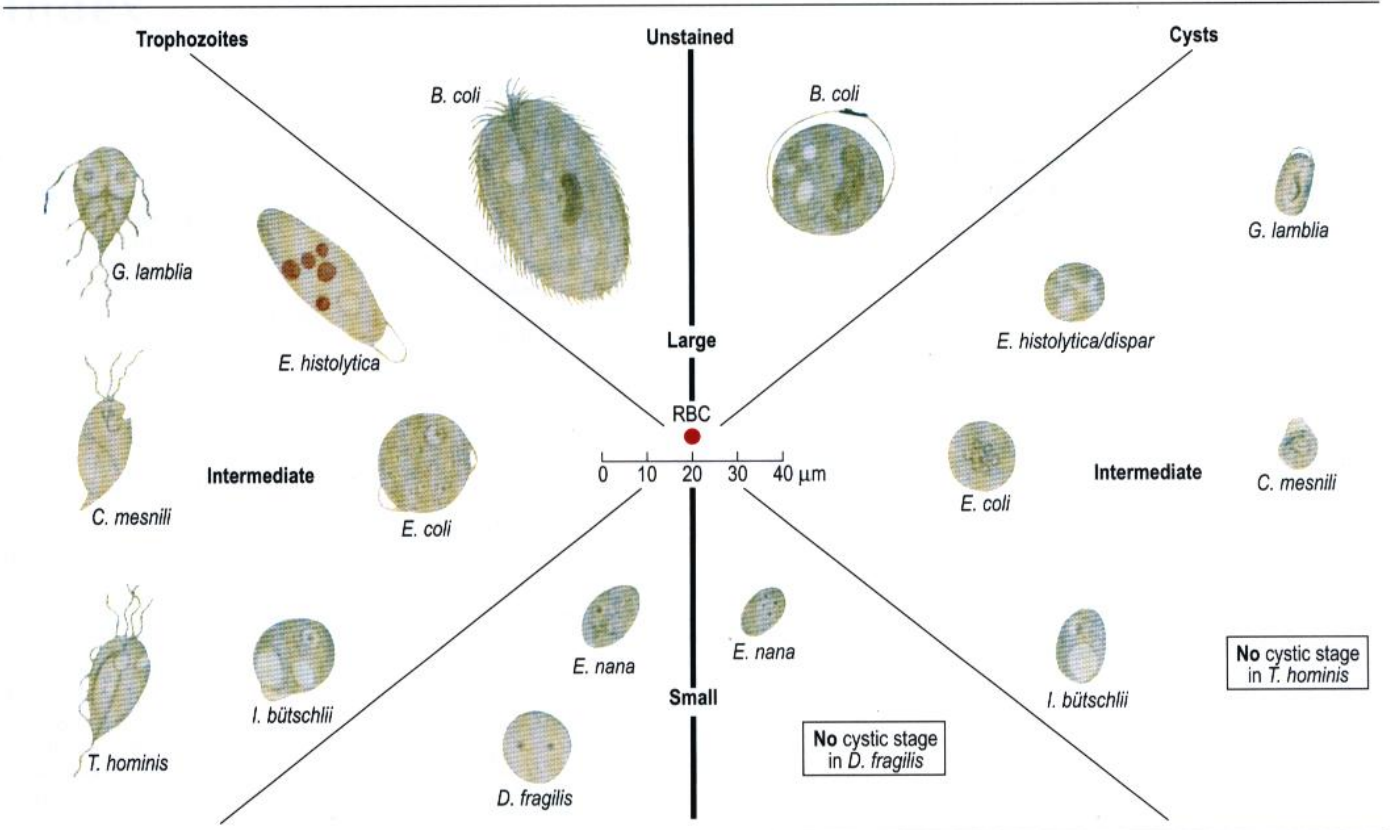
Demonstration of the parasite.

Stained smears of peripheral blood show trypanosomal forms in C or S shape. Stained films of lymph node fluid show amastigotes. It is possible to show trypomastigotes by animal inoculation from blood and by culture from lymph node fluid. Histological methods from biopsy or post-mortem material. It is also possible to demonstrate the parasite through xenodiagnosis: clean bred triatomid bugs fed on the patient's blood develop trypanosomes in the gut.

Serology (e.g. by ELISA or IFAT) is the method of choice for the detection of chronic *T. cruzi* infection.

Recapitulation

Luminal intestinal protozoa



Refer to text for the following additional stained appearances:

- trichrome stain for coccidia and microsporidia spp.
- modified Ziehl-Neelsen for *Cyclospora*, *Isospora* and *Cryptosporidium* spp.

Index

- A**
African trypanosomiasis, 74-5, 78
Allergic reaction, hydatid disease, 26
Alveolar hydatid cyst, 26
Amoebae, 47-56
Amoeboma, 51
Ancylostoma spp., *see also* Hookworm
 braziliense, 19
 caninum, 19
 duodenale, 8
 ova, 8
Ascaris lumbricoides, 7
 ova, 7, 36, 37
Ascites, *S. mansoni*, 29
- B**
Balantitis, *E. histolytica*, 52
Balantidium coli, 58
 trophozoites and cysts, 58, 79
Bancroftian filariasis (*W. bancrofti*), 12
Beef tape worm, 21
Blackwater fever, 68
Blinding worm, 15
Blood flukes, 27-9
Body-fluid flagellates, 70-8
Bone, hydatid (osseous) cyst, 25, 26
Bronchiectasis, *P. westermani*, 35
Brugia malayi, 13
- C**
Calabar swelling, 14
Cancer/malignancy, schistosomiasis, 29
Cat liver fluke, 31
Cat round worm, 18
Cercariae
 Fasciola hepatica, 32
 Fasciolopsis buski, 33
 H. heterophyes, 34
 M. yokogawai, 34
 O. felinus, 31
 O. felinus/O. viverrini, 31
 O. sinensis (*C. sinensis*), 30, 31
 Schistosoma spp., 27
 skin penetration, 29
Cestodes (tapeworms), 20-6
 general characteristics, 4
 larval forms, 24
Chagas' disease, 76-7, 78
Chilomastix mesnili, 56
 cysts and trophozoites, 56, 79
Chrysops (vector), 14
Chyluria
 B. malayi, 13
 W. bancrofti, 12
Ciliates, intestinal, 58
Classification
 helminths, 4
 protozoa, 40
 body-fluid and tissue flagellates, 70
 malaria parasite, 61
Clonorchis sinensis (*Opisthorchis sinensis*), 30-1
 ova, 30, 31, 36
Coccidia, 41-4
Cone bug (vector), 76
Conjunctiva, *L. loa* under, 14
Cutaneous larva migrans (creeping eruption)
 A. braziliense, 19
 A. caninum, 19
 G. spinigerum, 19
 U. stenocephala, 19
Cutaneous leishmaniasis, 73, 74
Cyclospora cayentanensis, 43
Cyst
 helminths
 hydatid cysts, 25, 26
 P. westermani, 35
 protozoa, 79
 amoeba other than *Entamoeba*
 spp., 54, 55, 79
 B. coli, 58, 79
 C. mesnili, 56, 57
 Entamoeba spp., 48, 49, 50, 55, 79
 G. lamblia, 56, 79
 S. hominis, 44
 T. gondii, 59
 Cysticercoid, *H. nana/H. diminuta*, 22
 Cysticercus bovis, 21
 Cysticercus cellulosae, 20
 Cystitis, schistosomiasis, 29
- D**
Diagnosis, methods, 1
Dientamoeba fragilis, 47
 life cycle, 54
 morphology, 54-5, 79
Diphyllobothrium latum, 23
 ova, 23, 36
Disease mechanisms, 1
Dog round worm, *see Toxocara canis*
Dog tape worm, 25
Dracunculus medinensis, 17
Dwarf tape worms, 22
Dysentery
 amoebic, faecal appearance, 53
 balantidial, 58
 T. trichiura, 6
- E**
Echinococcus granulosus, 25
Echinococcus multilocularis, 26
Eggs, *see* Ova
Elephantiasis
 O. volvulus, 15
 W. bancrofti, 12
Encephalitozoon spp., 45
Endolimax nana, 47
 morphology, 54-5, 79
Endophthalmitis, *T. canis*, 18
Entamoeba coli, 47
 morphology (vs *E. histolytica*), 49-50,
 54-5, 79
Entamoeba dispar, 48
 morphology, 54-5, 79
Entamoeba hartmanni, 47
 morphology, 54-5
Entamoeba histolytica, 47, 48-53
 laboratory diagnosis, 53
 life cycle, 48
 morphology, 49-50, 54-5, 79
 pathology, 51-2
Entamoeba polecki, 47
Enterobius vermicularis, 5
 ova, 5, 36
- Enterocytozoon bieneusi*, 45
Eosinophilia, tropical pulmonary, 12
Erythrocytic stage in RBCs (*Plasmodium*
 spp.), 63
Espundia, 73
Eye worm, 14
- F**
Fasciola hepatica (sheep liver fluke), 32, 32
 ova, 36, 37
Fasciolopsis buski, 33
 ova, 33, 36
Filariasis, 12-16
 Bancroftian (*W. bancrofti*), 12
 Filariform larvae, *S. stercoralis*, 9
Fish tape worm, *see Diphyllobothrium latum*
Flagellates
 body-fluid and tissue, 70-8
 intestinal, 56-7
Flukes, *see* Trematodes
- G**
Gametocytes, *Plasmodium* spp., 64, 65
Giardia intestinalis (*G. lamblia*), 56
 cysts and trophozoites, 58, 79
Gnathostoma spinigerum, 19
Granuloma(ta)
 M. yokogawai, 34
 Schistosoma spp., 29
Gravid segment, *T. saginata*, 21
Ground itch, 8
Growth effects, trichuriasis, 6
Guinea worm, 17
- H**
Haemoptysis, *P. westermani*, 35
Halzoun, 32
Helminths (worms), 3-37
 classification, 4
 definition, 1
Hematophagous trophozoites,
 E. histolytica, 53
Heterophyes heterophyes, 34
Hoepli reaction, 29
Hookworms, 8, *see also* *Ancylostoma* spp.
 ova, 8, 36, 37
Host, definitive vs intermediate, 1
Hydatid disease, 25-6
Hydrocele
 B. malayi, 13
 W. bancrofti, 12
Hymenolepis diminuta (rat tape worm), 22
 ova, 22, 36
Hymenolepis nana, 22
 ova, 22, 36, 37
Hypoglycaemia in malaria, 68
- I**
Intraosseous cyst, 25, 26
Iodamoeba bütschlii, 47
 morphology, 54-5, 79
Iron deficiency anaemia, *T. trichiura*, 6
Isopora belli, 41

- J**
- Jaundice
C. (O.) sinensis, 30
F. hepatica, 32
P. falciparum, 68
- K**
- Kala azar (visceral leishmaniasis), 72, 73
Katayama fever, 29
- L**
- Larva currens, 9
Larva migrans, *see* Cutaneous larva migrans; Visceral larva migrans
Larval forms of cestodes, 24
Leishmania spp., 71-3
morphology, 70, 71
Leucopenia, *P. falciparum*, 68
Liver fluke
cat, 31
oriental, 30-1
sheep, *see Fasciola hepatica*
Loa loa, 14
- M**
- Macrogametocytes, *Plasmodium* spp., 64
Malaria parasite, *see Plasmodium* spp.
Mansonella spp., 16
Megaloblastic anaemia, *D. latum*, 23
Microfilariae
B. malayi, 13
L. loa, 14
O. volvulus, 15
W. bancrofti, 12
other filarial worms, 16
Microgametocytes, *Plasmodium* spp., 64
Microsporidia, 45-6
Mosquito as vector
B. malayi, 13
Plasmodium spp., 62
W. bancrofti, 12
Mucocutaneous leishmaniasis, 73
Multilocular cyst, 26
- N**
- Necator americanus*, 8
Nematodes (round worms), 5-19
general characteristics, 4
Nosema spp., 45
- O**
- Oesophageal varices, *S. mansoni*, 29
Onchocerca volvulus, 15
Opisthorchis felineus, 31
Opisthorchis sinensis, *see Clonorchis sinensis*
Opisthorchis viverrini, 31
Oriental liver fluke, 30-1
Oriental schistosomiasis, 29
Osseous cyst, 25, 26
Ova (eggs), helminth, 36-7
Schistosoma spp., 36, 37, 38
damage caused by, 29
- P**
- Papillitis (optic), *T. canis*, 18
Paragonimus westermani, 35
ova, 35, 36
Periorbital oedema, *T. spiralis*, 11
Pharynx, *F. hepatica*, 32
Phasid nematodes, 18-19
Pin worm, 5
Placenta in malaria, 68
Plasmodium spp., 61-9
classification, 61
laboratory diagnosis, 69
- Plasmodium* spp., 61-9 (continued)
life cycle, 62
morphology, 63-7
pathophysiology, 68
Plasmodium falciparum, 61
laboratory diagnosis, 69
morphology, 63-7
Plasmodium malariae, 61
laboratory diagnosis, 69
morphology, 63-7
Plasmodium ovale, 61, 62
laboratory diagnosis, 69
morphology, 63-7
Plasmodium vivax, 61, 62
laboratory diagnosis, 69
morphology, 63-7
Pleistophora spp., 45
Pork tape worm, 20
Portal vein, *S. mansoni*, 29
Pre-erythrocytic stage, *Plasmodium* spp., 63
Pregnancy, placenta in malaria, 68
Proglottid, *T. solium*, 20
Protozoa, 39-79
classification, *see* Classification
definition, 1
- R**
- Rat tape worm, *see Hymenolepis diminuta*
Red blood cells (RBCs), malaria parasite
erythrocytic stage, 63
pathophysiology, 68
Renal involvement, *see* Kidney
Rhabditiform larvae
hookworms, 8
S. stercoralis, 9
Ring form, *Plasmodium* spp., 64, 67
Round worms, *see* Nematodes
- S**
- Sandfly (vector), 70, 71
Sarcocystis hominis, 44
Schistosoma spp., 27-9
haematobium, 28, 29, 36, 37
japonicum, 28, 29, 36
mansoni, 28, 29, 36, 37
ova, *see* Ova
Schizogony, *Plasmodium* spp., 63
Schizonts, *Plasmodium* spp., 64, 67
Scolex
D. latum, 23
T. saginata, 21
T. solium, 20
Sheep liver fluke, *see Fasciola hepatica*
Sleeping sickness, 74-5, 78
Snail fever, 29
Snail host
Fasciola hepatica, 32
Fasciolopsis buski, 33
H. heterophyes, 34
M. yokogawai, 34
O. felineus, 31
O. sinensis (*C. sinensis*), 30
P. westermani, 35
Schistosoma spp., 27, 28
South American trypanosomiasis, 76-7, 78
Sparganosis, 24
Sparganum proliferum, 24
Spirometra spp., 24
Squamous cell carcinoma of bladder, 29
Strobila
D. latum, 23
T. saginata, 21
T. solium, 20
Strongyloides stercoralis, 9
Subconjunctival location, *L. loa*, 14
Subungual haemorrhage, *T. spiralis*, 11
Swimmer's itch, 29
- T**
- Taenia* spp.
ova, 20, 21, 36
T. saginata, 21
T. solium, 20
Tapeworms, *see* Cestodes
Thread worm, 5
Thrombocytopenia, *P. falciparum*, 68
Tissue protozoa, 59-60
flagellates, 70-8
TNF and malaria, 68
Toxocara canis, 18
ova, 18, 37
Toxocara cati, 18
Toxoplasma gondii, 59-60
Transmission of parasites, 1
Trematodes (flukes), 27-37
general characteristics, 4
Triatoma spp. (vector), 76
Trichinella spiralis, 10-11
Trichomonas spp., 57
hominis, 57, 79
vaginalis, 57
Trichuris trichiura (whip worm), 6
ova, 6, 36, 37
Trophozoites, 79
amoebae other than *Entamoeba* spp.,
morphology, 54
I. bütschlii, 54, 79
B. coli, 58, 79
C. mesnili, 56, 79
Entamoeba spp., 48, 49, 50, 79
hematophagous, 53
morphology, 54
G. lamblia, 56, 79
Plasmodium spp., 64, 67
Trichomonas spp., 57, 79
Tropical pulmonary eosinophilia, 12
Trypanosoma spp., 74-8
laboratory diagnosis, 78
morphology, 70
Trypanosoma cruzi, 76-7
morphology, 70, 76
Trypanosoma gambiense, 74
morphology, 70
pathology, 75
Trypanosoma rhodesiense, 74
morphology, 70
pathology, 75
Trypanosomatidae, morphological
stages, 70
Tsetse fly (vector), 70, 74
Tumour necrosis factor and malaria, 68
- U**
- Uncinaria stenocephala*, 19
Unilocular cyst, 26
Urethra, *Trichomonas vaginalis*, 57
Urinary tract infection
E. vermicularis, 5
S. haematobium, 29
- V**
- Visceral larva migrans
G. spinigerum, 19
T. canis, 18
Visceral leishmaniasis, 72, 73
- W**
- Whip worm, *see Trichuris trichiura*
Worms, *see* Helminths
Wuchereria bancrofti, 12

Fourth edition

Atlas of Medical Helminthology and Protozoology



In this fourth edition provides a unique diagnostic reference source for the microbiologist, tropical disease physician and medical scientist. The entire contents has been revised and re-structured and illustrated with new full colour diagrams and photomicrographs. For each organism there is a schematic life cycle, range map, morphological drawing and microscopic appearance. No diagnostic laboratory should be without this valuable resource.



An Imprint of Elsevier Science



Visit our website for
additional outstanding
products

www.elsevierhealth.com



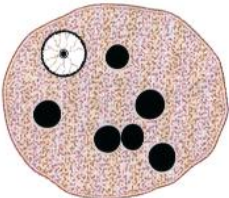
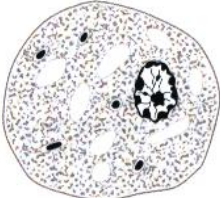



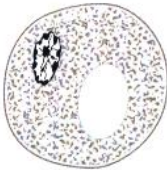

ISBN 0-443-06268-4



9 780443 062681

Entamoeba histolytica (causing amoebiasis) (continued)

Morphology (continued)

		Iodine preparations			
<i>E. histolytica</i>		Precyst			<i>E. coli</i>
	Brown, diffuse Finely granular yellow green Yellow ring with central yellow dot (karyosome)	Glycogen Cytoplasm Nucleus	Brown, compact Conspicuous granularity Nuclear membrane with eccentric karyosome easily recognised		
		Stained by iron haematoxylin			
		Trophozoite			
	Purplish brown Faintly granular RBC black Lined with minute black granules Small black central dot Trace only seen	Cytoplasm Inclusions Nucleus: Membrane Karyosome Fibril network	Greyish blue Coarsely granular Vacuoles black, as are bacteria etc. Thick with plaques of black chromatin Eccentric black dot or plaque More conspicuous; may have chromatin plaques		
					
		Precyst			
	Round As trophozoite Black chromidial bodies or bars Glycogen (dissolved) replaced by vacuoles	Shape Cytoplasm Nucleus Inclusions	Round As trophozoite May have slender black chromidial bars Glycogen (dissolved) replaced by vacuoles		
		Cyst			
	Grey-blue As precyst, less conspicuous or absent Unstained, hyaline As trophozoite 1-4	Cytoplasm Inclusions Wall Nuclei	Greyish-blue, granular As precyst, less conspicuous or absent In 2 nuclei stage glycogen vacuoles may be dumb-bell-shaped Unstained, hyaline As trophozoite 1-8		