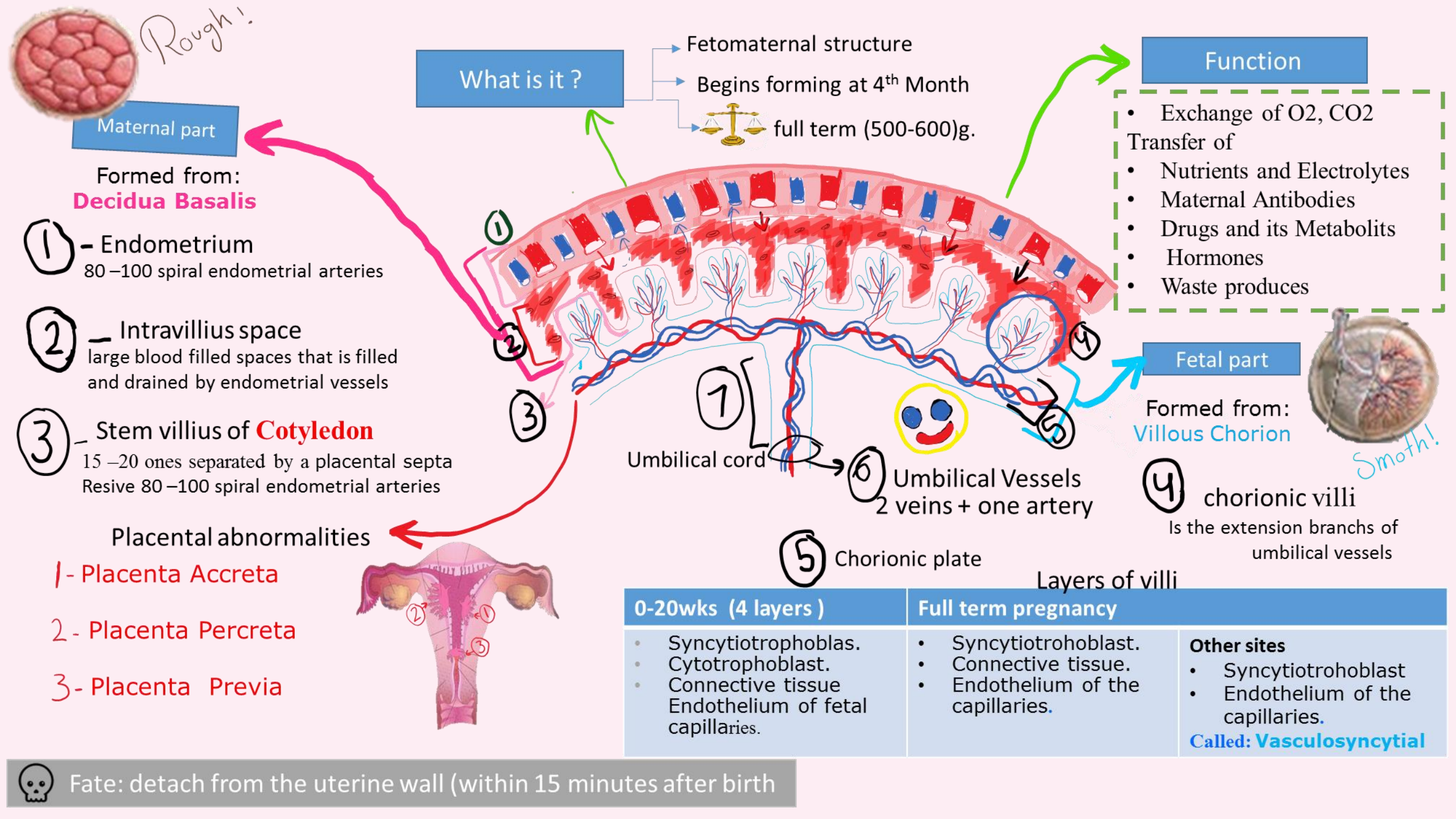
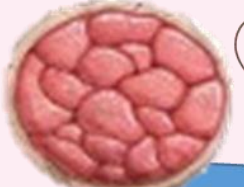
*Rough!*



**Maternal part**

Formed from:  
**Decidua Basalis**

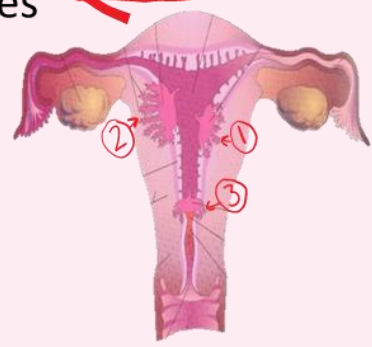
① - Endometrium  
80-100 spiral endometrial arteries

② - Intravillous space  
large blood filled spaces that is filled and drained by endometrial vessels

③ - Stem villus of **Cotyledon**  
15-20 ones separated by a placental septa  
Resive 80-100 spiral endometrial arteries

Placental abnormalities

- 1- Placenta Accreta
- 2- Placenta Percreta
- 3- Placenta Previa



**What is it ?**

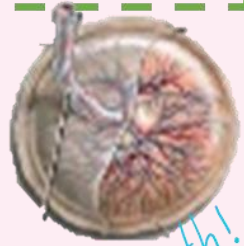- Fetomaternal structure
- Begins forming at 4<sup>th</sup> Month
- full term (500-600)g.

**Function**

- Exchange of O<sub>2</sub>, CO<sub>2</sub>
- Transfer of
- Nutrients and Electrolytes
- Maternal Antibodies
- Drugs and its Metabolites
- Hormones
- Waste produces

**Fetal part**

Formed from:  
**Villous Chorion**



*Smooth!*

④ chorionic villi  
Is the extension branches of umbilical vessels

① [ ⑦ ]  
Umbilical cord

⑥ Umbilical Vessels  
2 veins + one artery

⑤ Chorionic plate

Layers of villi

0-20wks (4 layers)	Full term pregnancy	Other sites
<ul style="list-style-type: none"> <li>• Syncytiotrophoblas.</li> <li>• Cytotrophoblast.</li> <li>• Connective tissue</li> <li>• Endothelium of fetal capillaries.</li> </ul>	<ul style="list-style-type: none"> <li>• Syncytiotrohoblast.</li> <li>• Connective tissue.</li> <li>• Endothelium of the capillaries.</li> </ul>	<ul style="list-style-type: none"> <li>• Syncytiotrohoblast</li> <li>• Endothelium of the capillaries.</li> </ul> <p><b>Called: Vasculosyncytial</b></p>

Fate: detach from the uterine wall (within 15 minutes after birth)