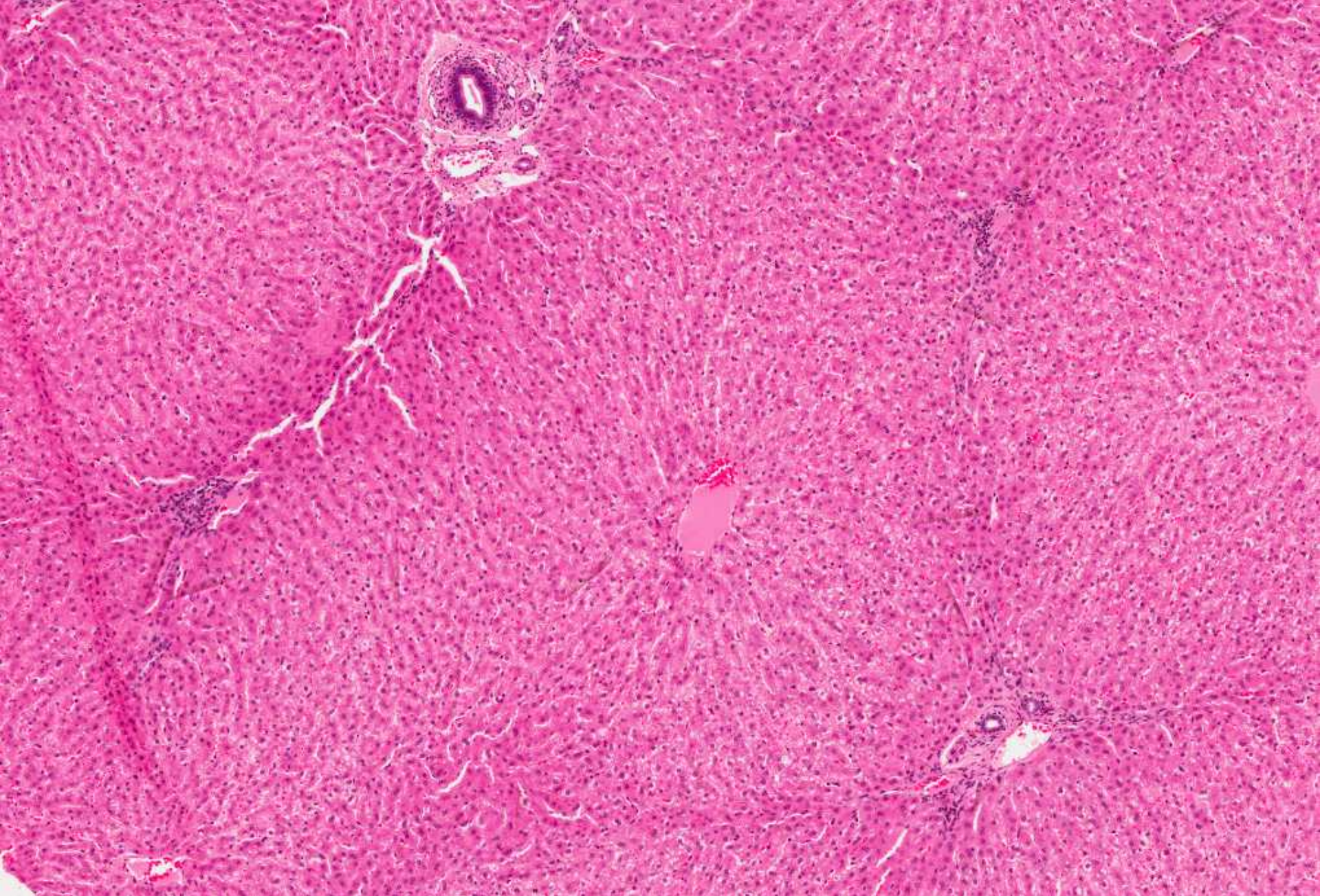
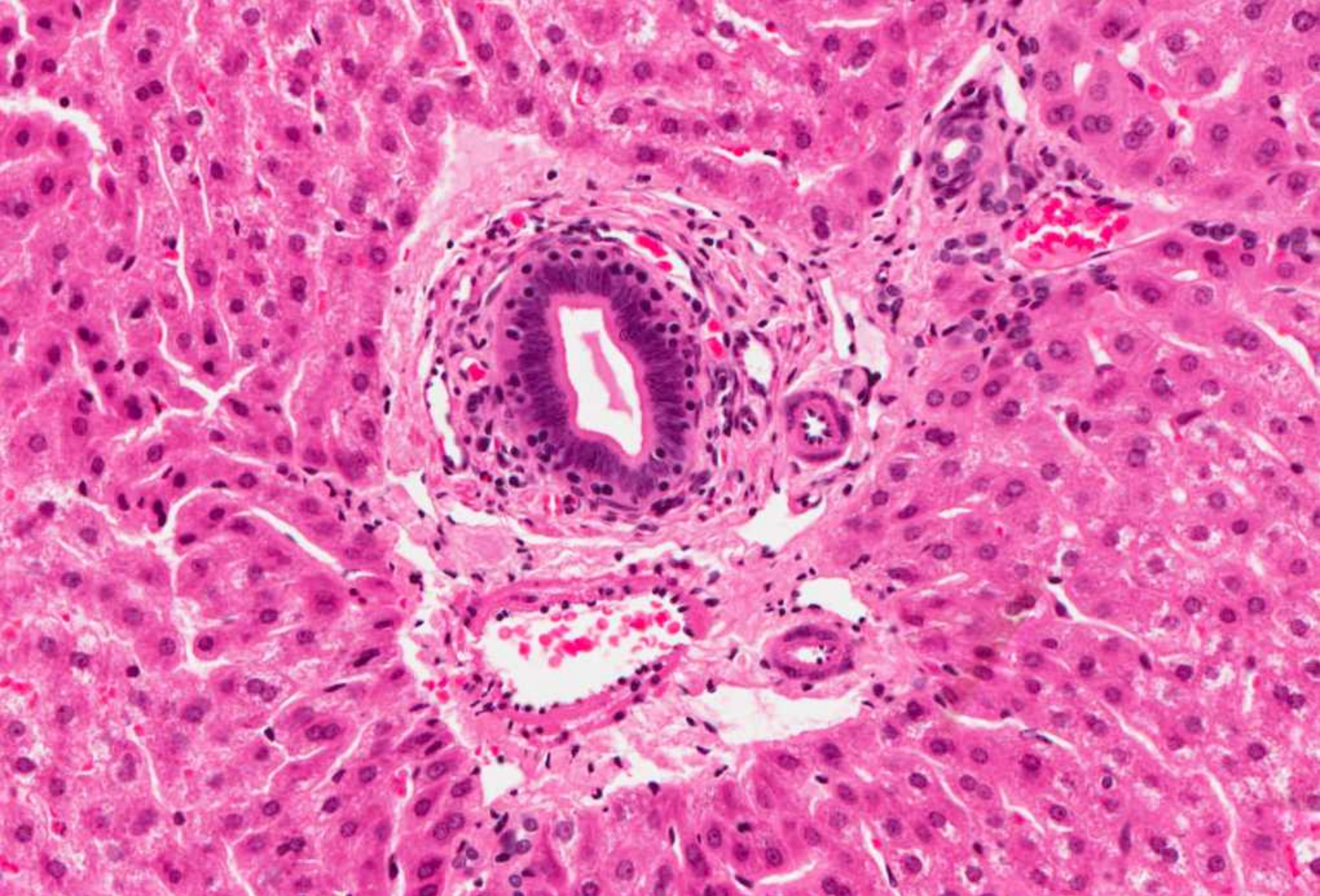


Liver, Pancreas, gall bladder and Spleen

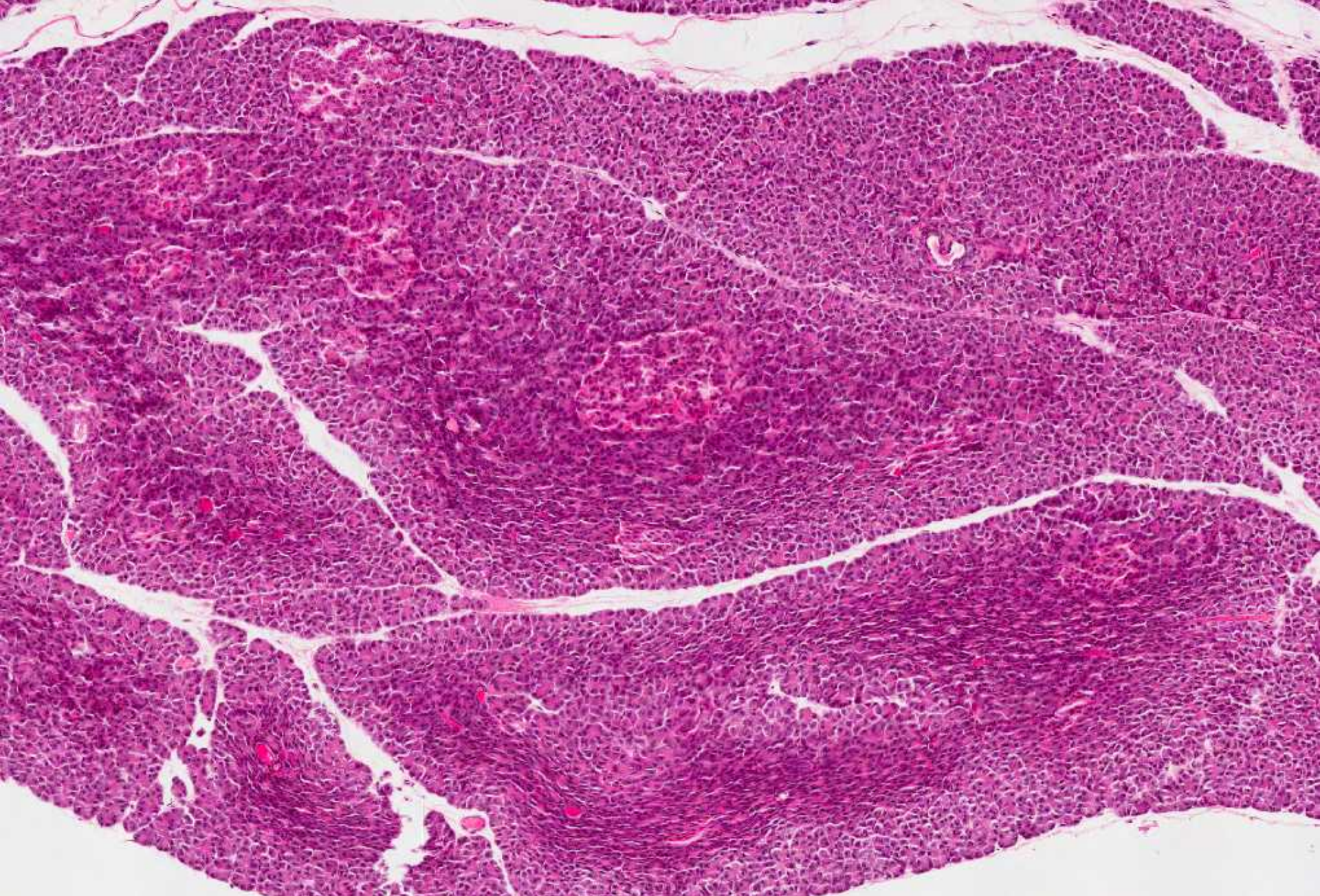
Practical Pictures



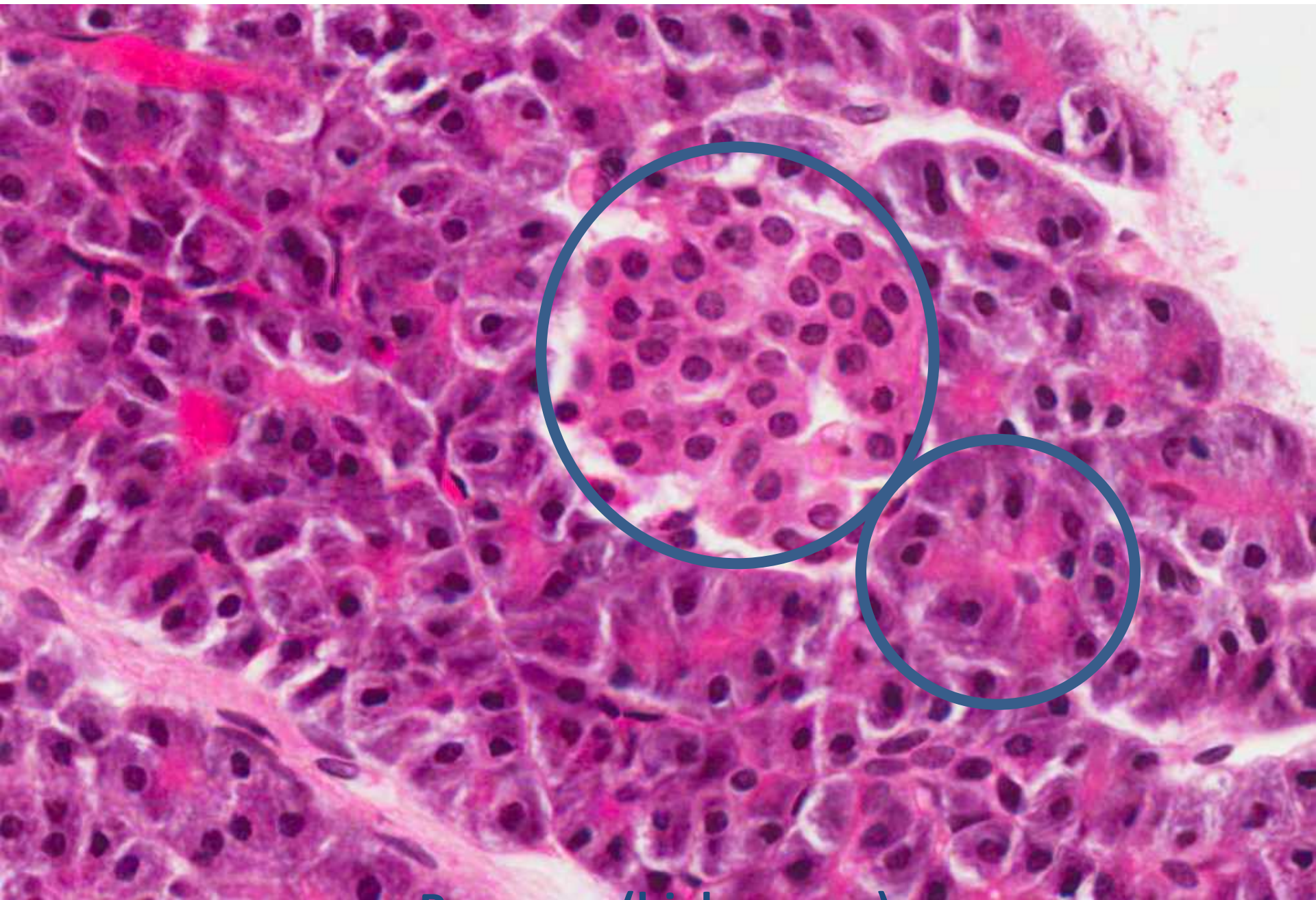
Liver (classic hepatic lobule)



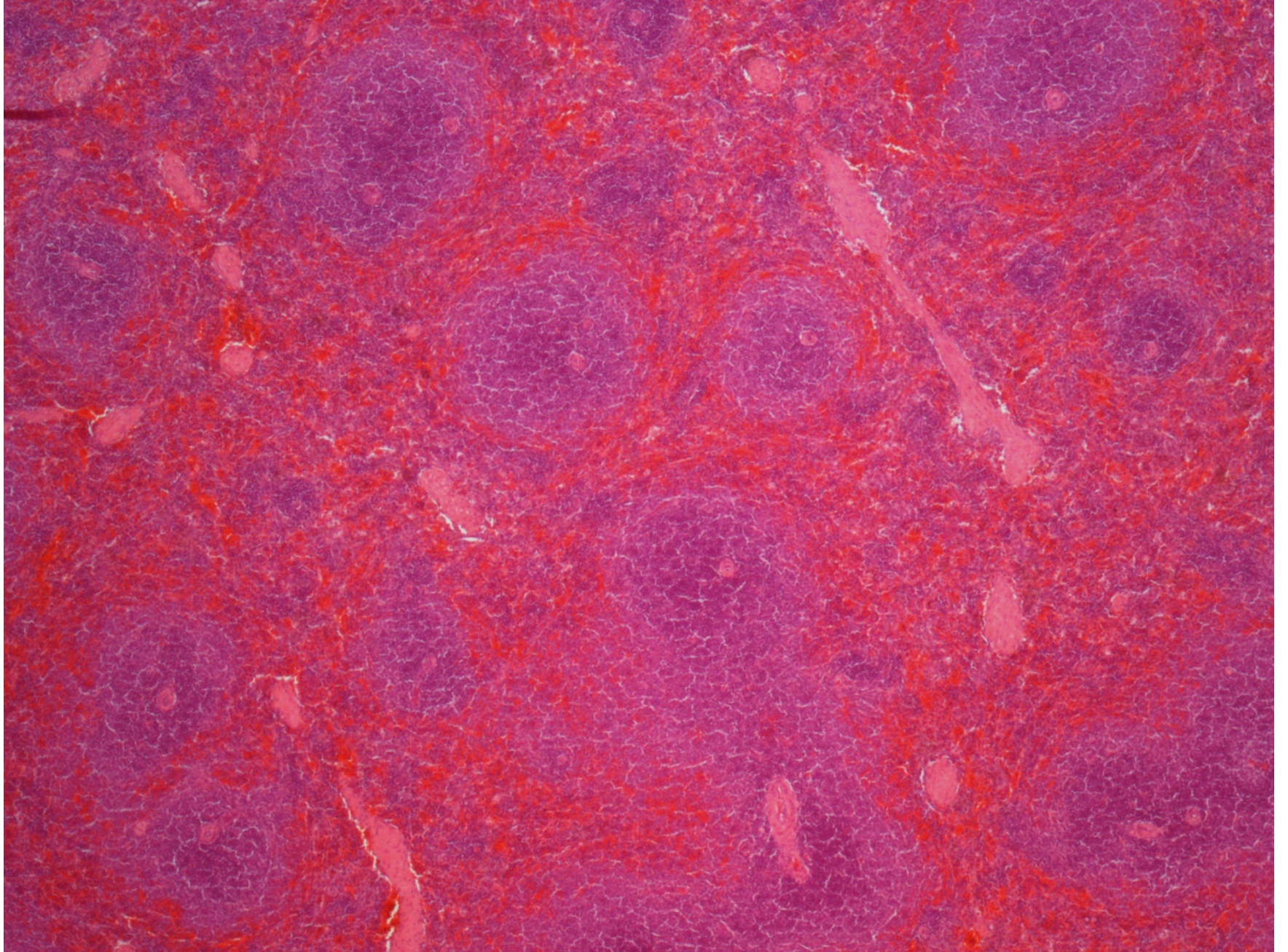
Liver (portal area)



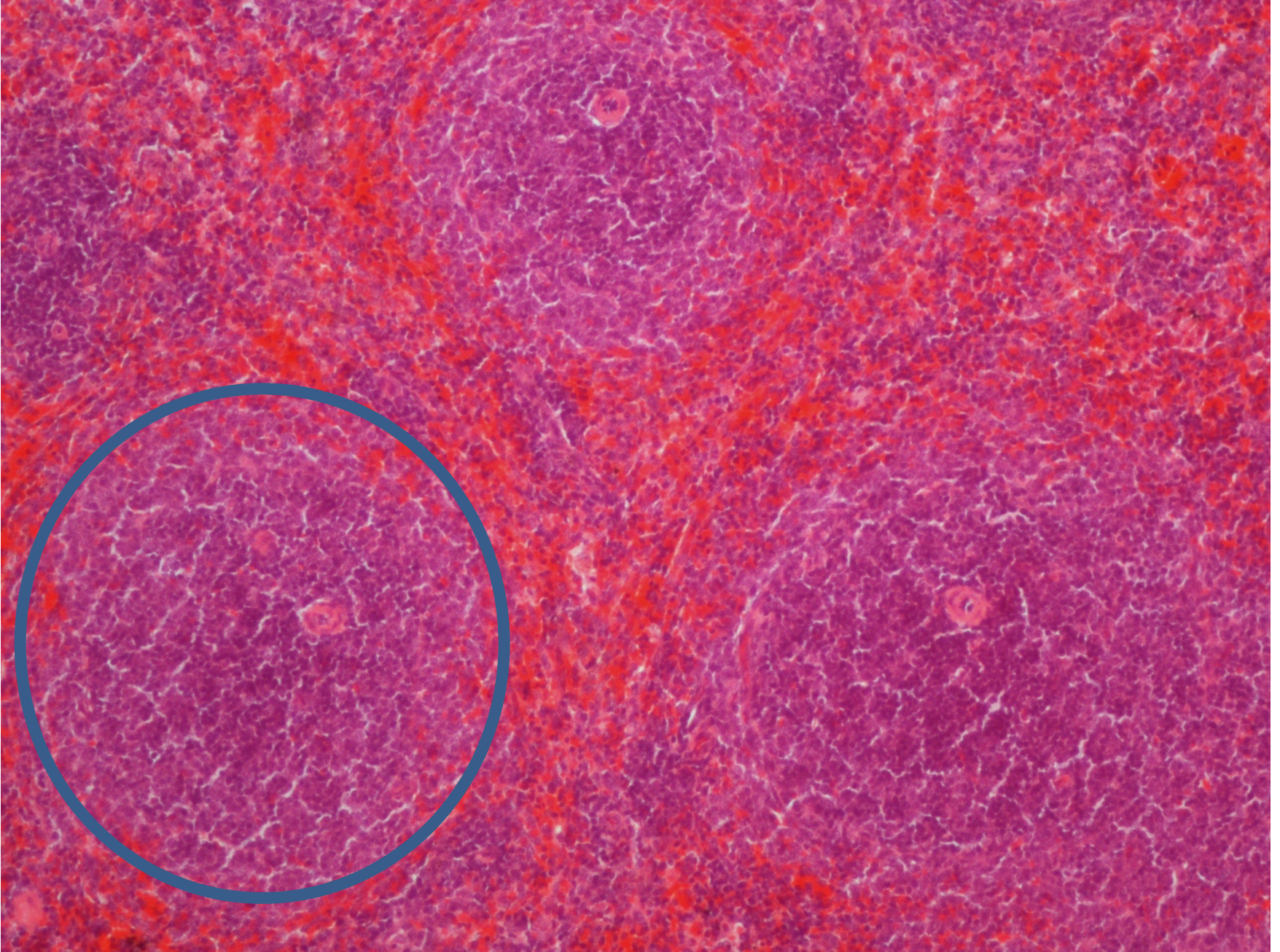
Pancreas (low power)



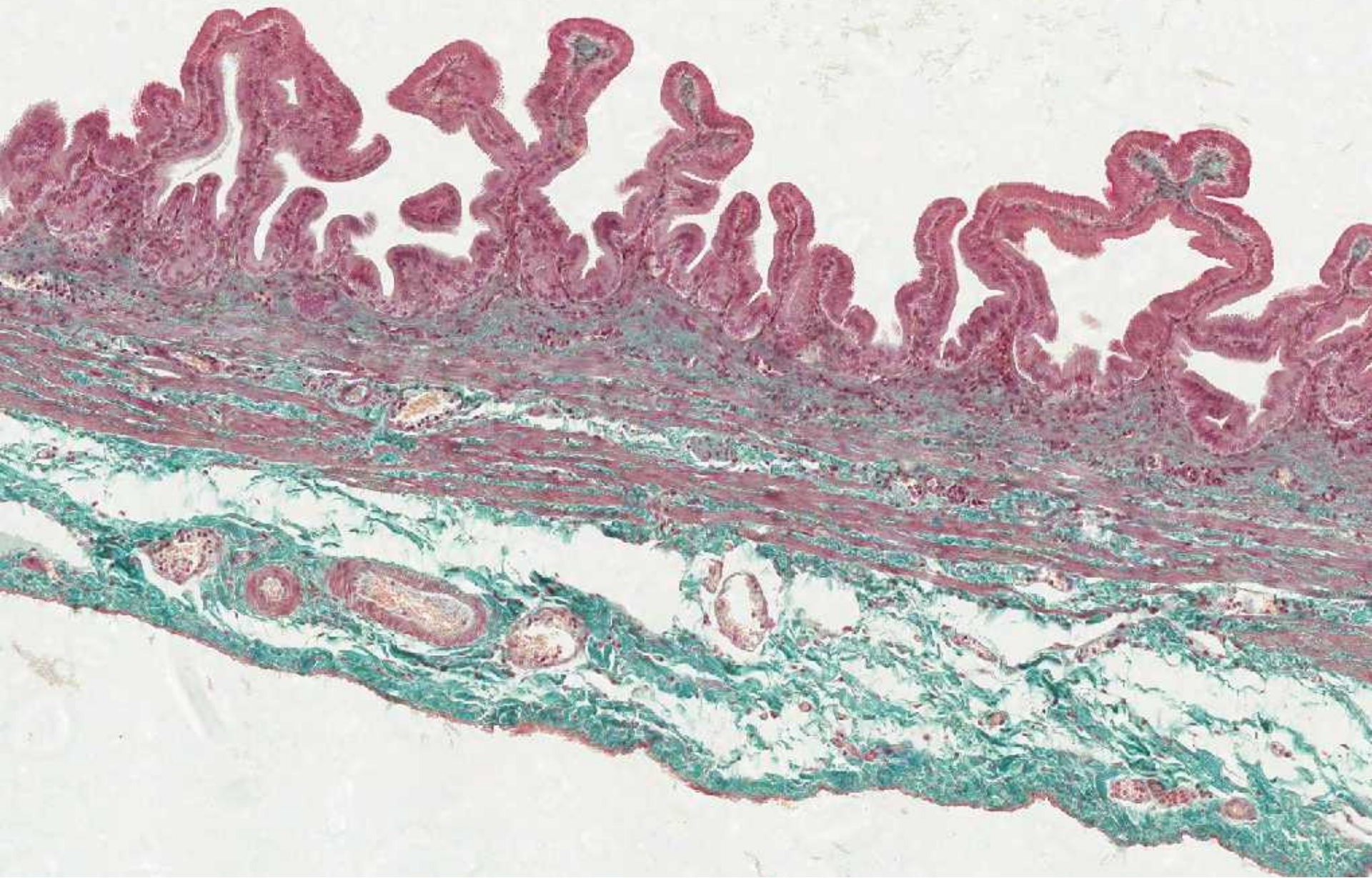
Pancreas (high power)



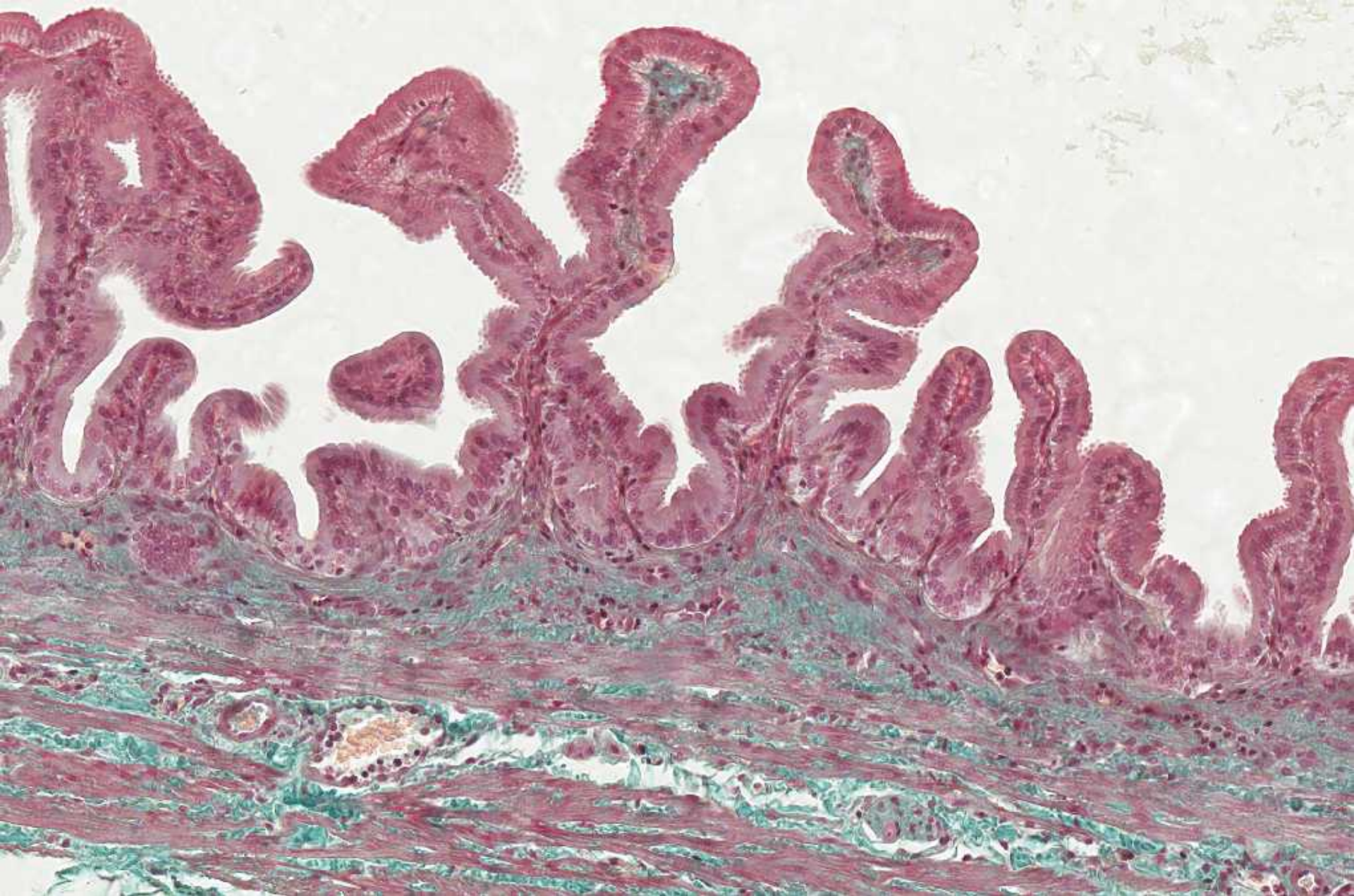
Spleen (low power)



Spleen (high power)



Gall bladder (low power)



Gall bladder (high power)