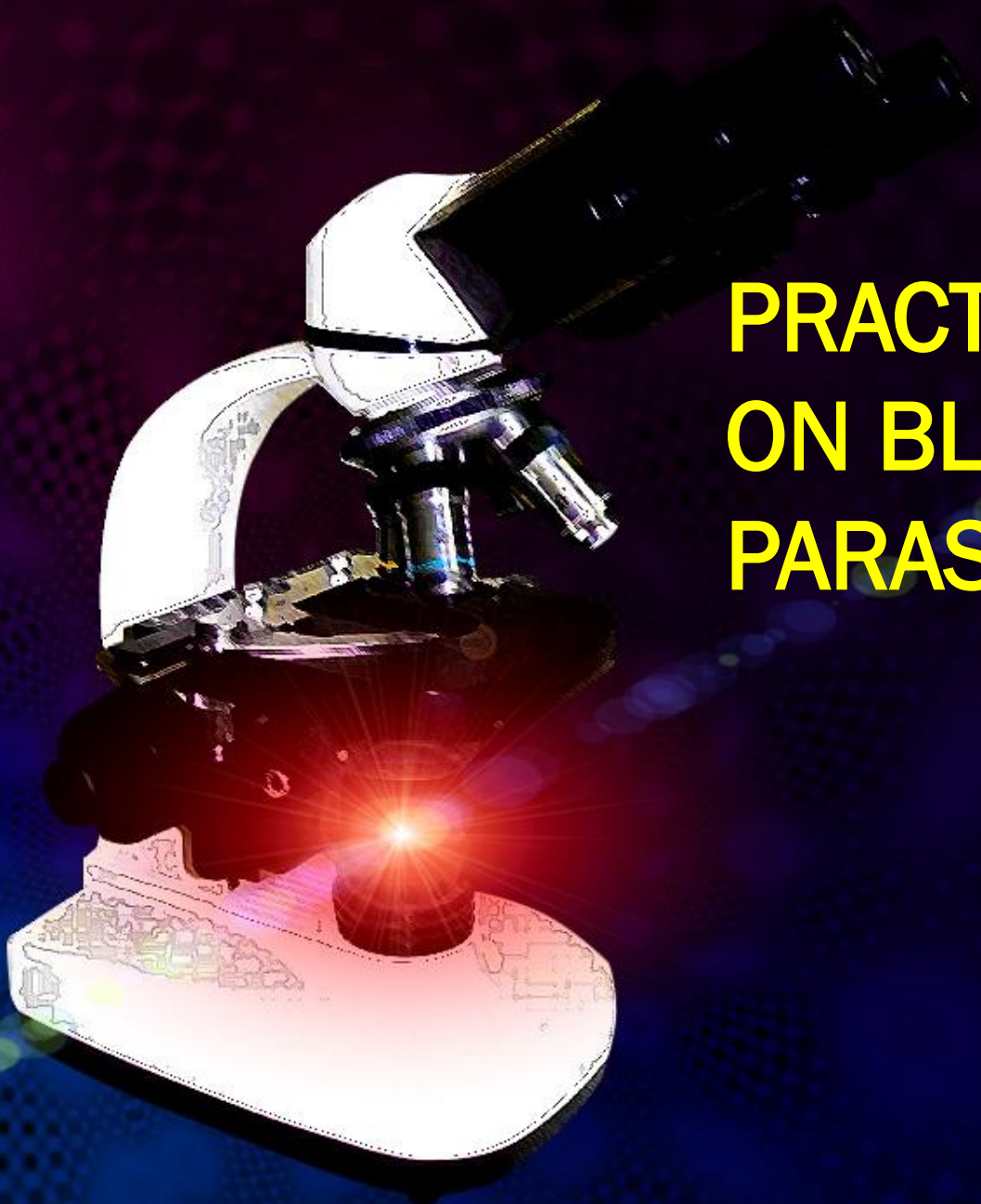




PRACTICAL ON BLOOD PARASITES

Common methods for parasitological diagnosis of malaria

The two methods common in use :

1: Light microscopy

2: Rapid diagnostic tests (RDTs).

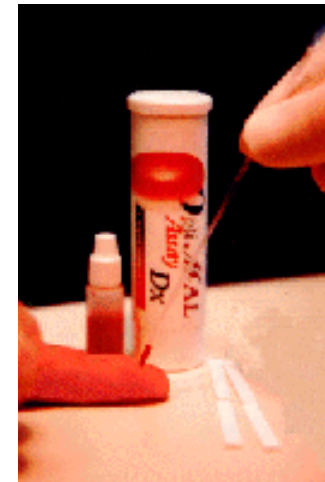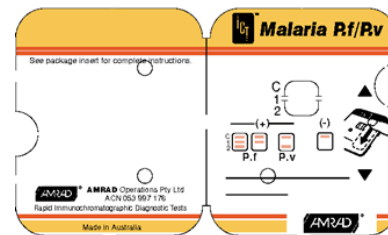

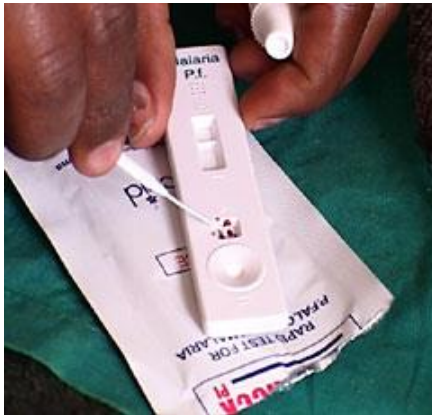
Laboratory diagnosis of malaria

Rapid diagnostic tests detect malaria antigens

The products come in a number of formats:

- Plastic cassette
- Card
- Dipstick
- Hybrid cassette-dipsticks




Malaria P.f. RDT Results

NEGATIVE RESULTS



Wait 15 minutes
before reading
results.

POSITIVE RESULTS

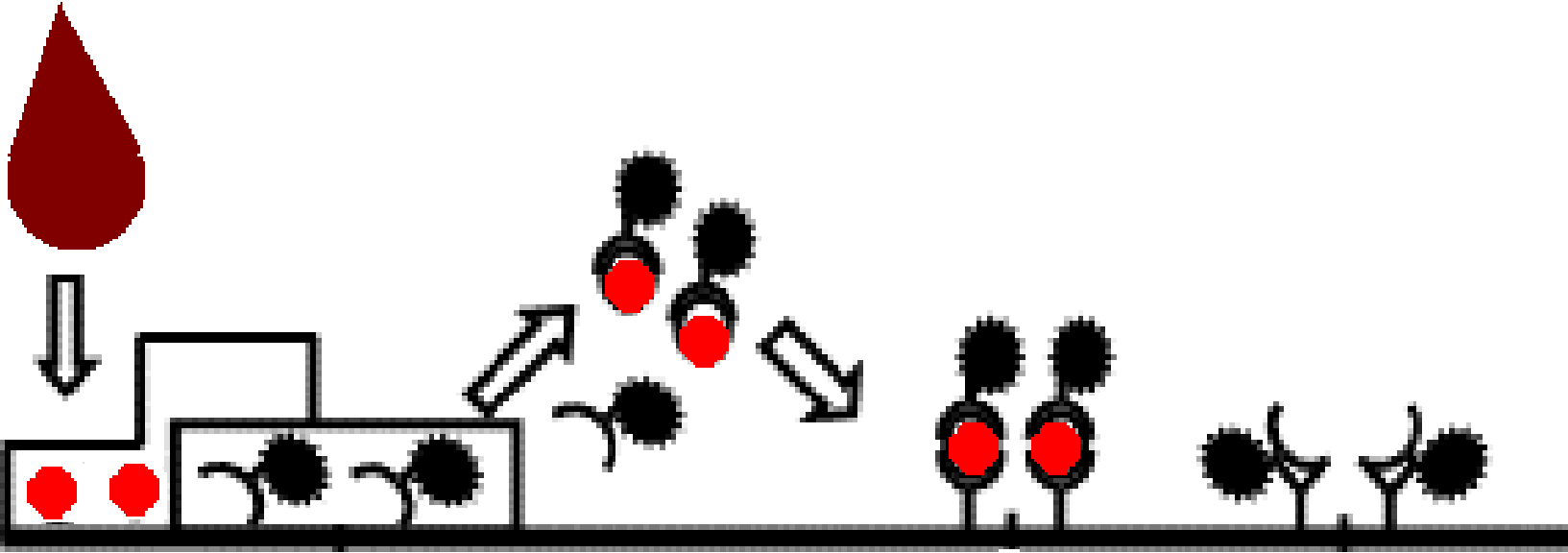


INVALID RESULTS *



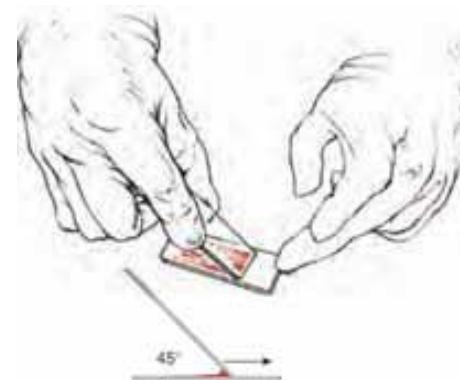
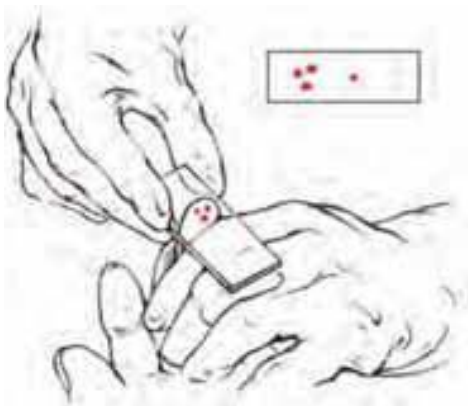
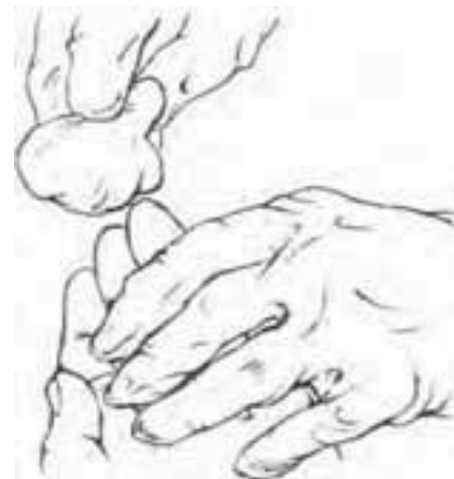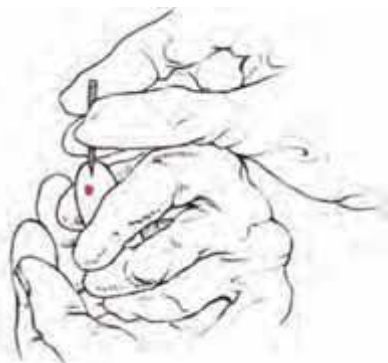* No Control Lines (repeat tests)

RDT procedure

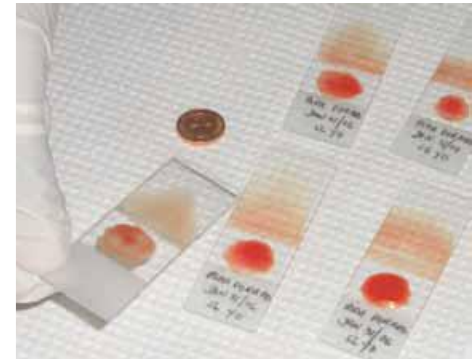
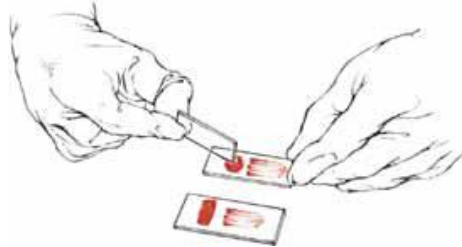
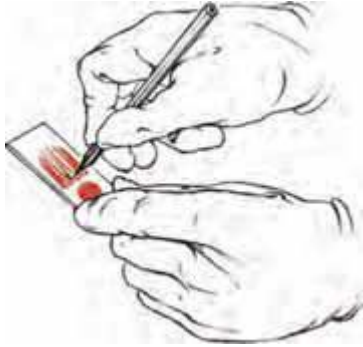


Laboratory diagnosis of malaria

Light microscopy:1: Preparing blood film



Laboratory diagnosis of malaria



Laboratory diagnosis of malaria

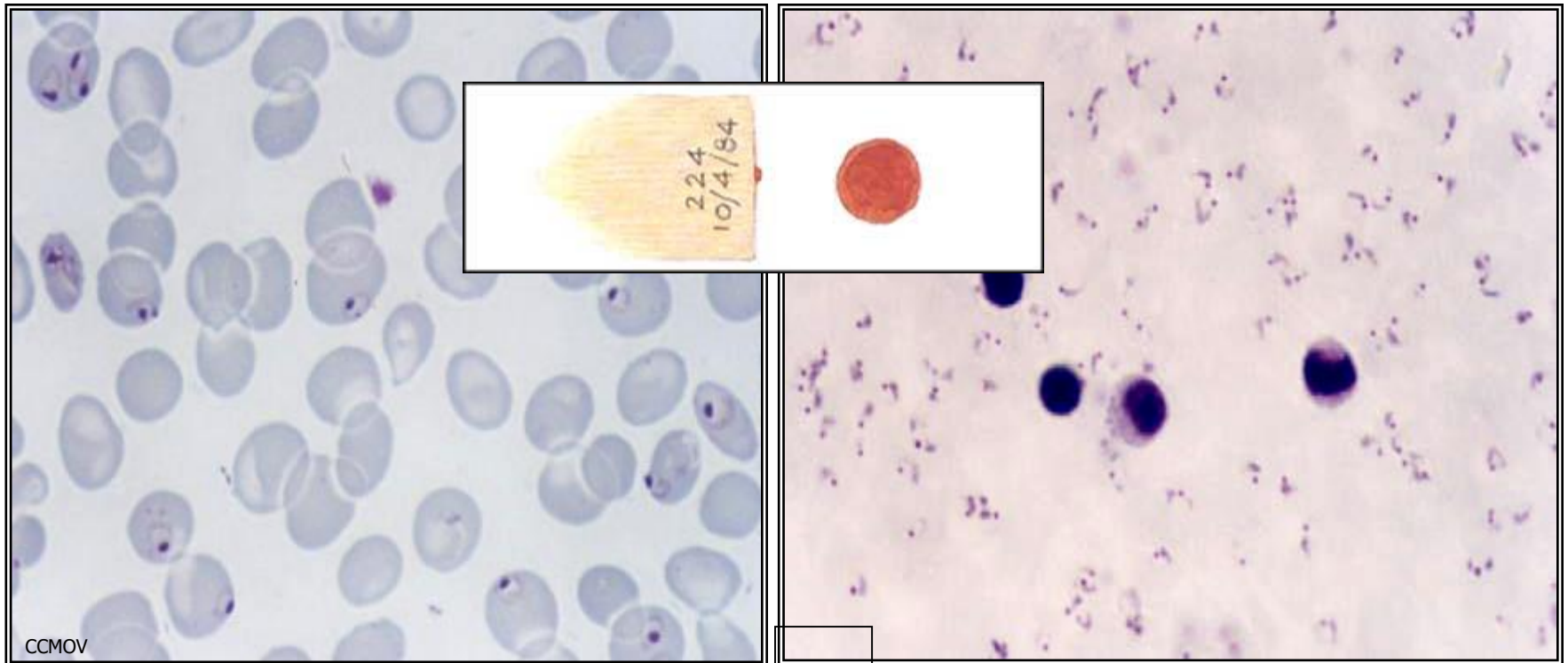
Light microscopy: Thick and thin films



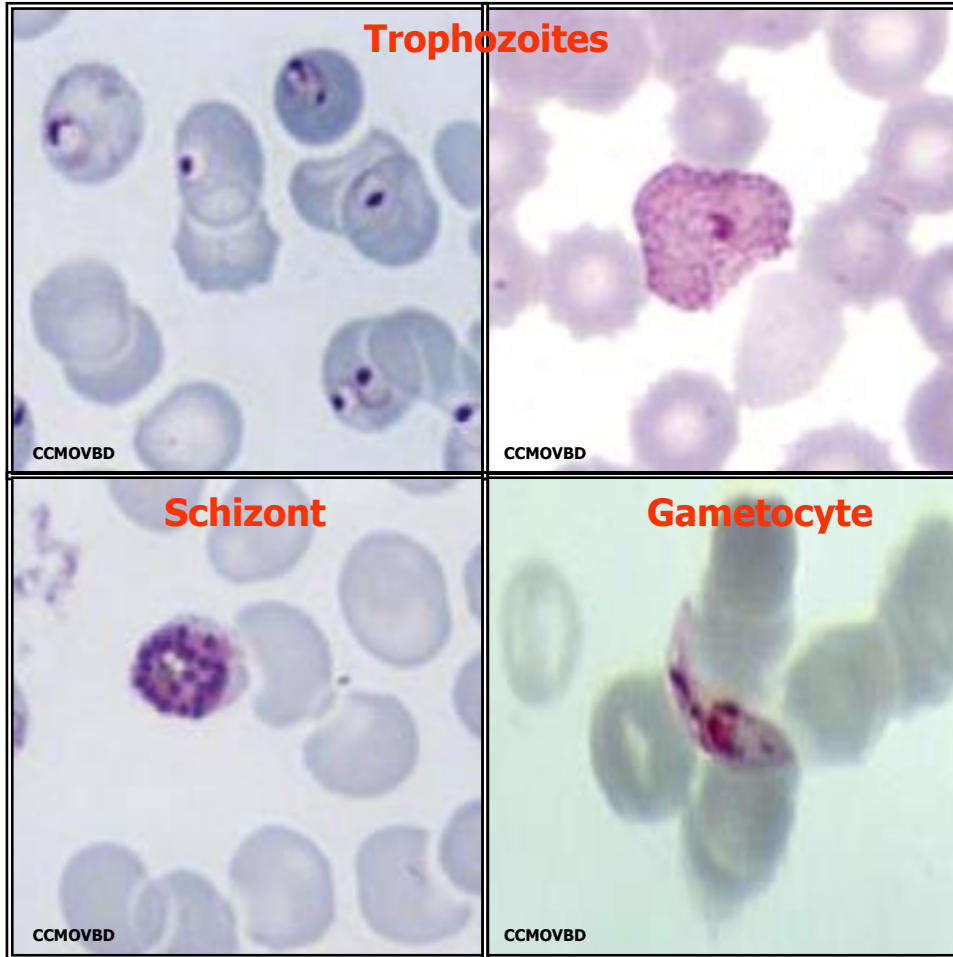
Laboratory diagnosis of malaria

Plasmodium falciparum (trophozoite stage in thin smear)

Plasmodium falciparum (trophozoite stage in thick smear)

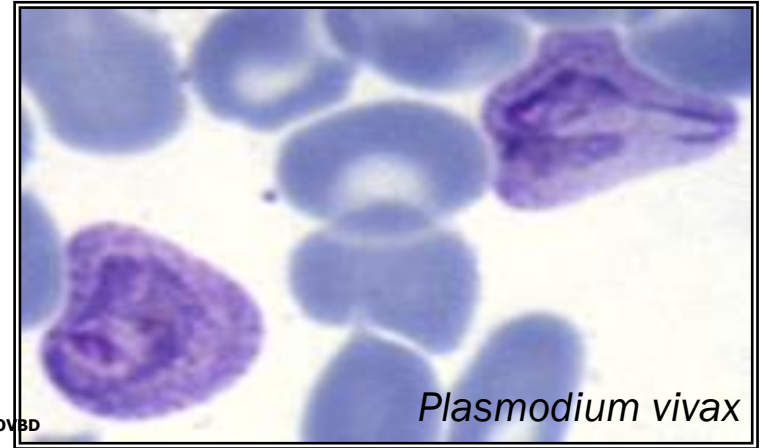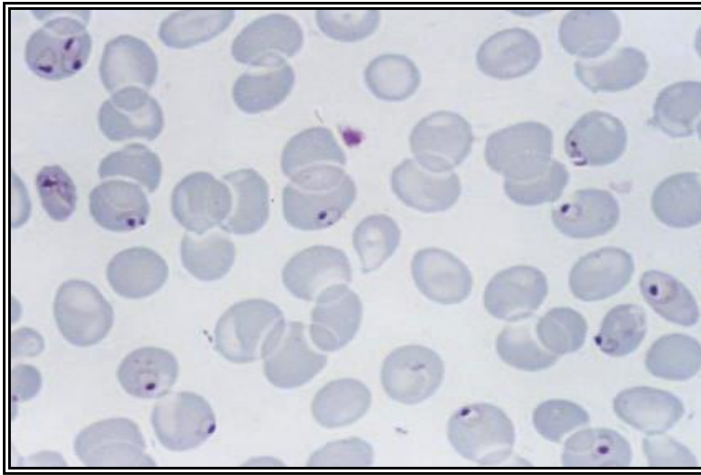


The Malaria Parasite



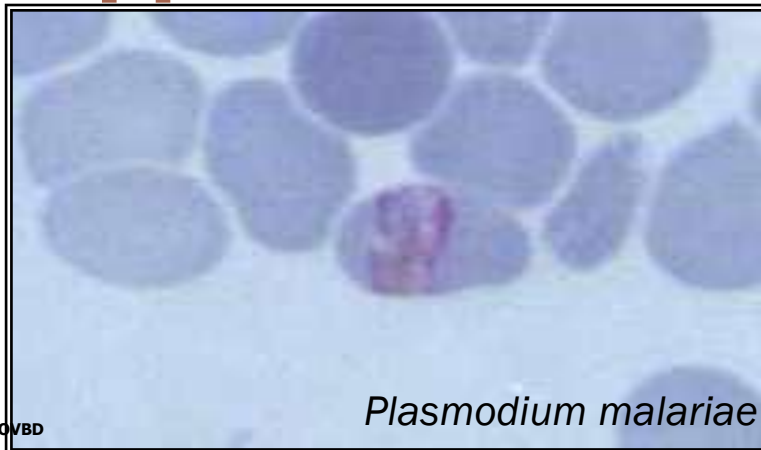
Three developmental stages seen in blood films:

1. Trophozoite
2. Schizont
3. Gametocyte

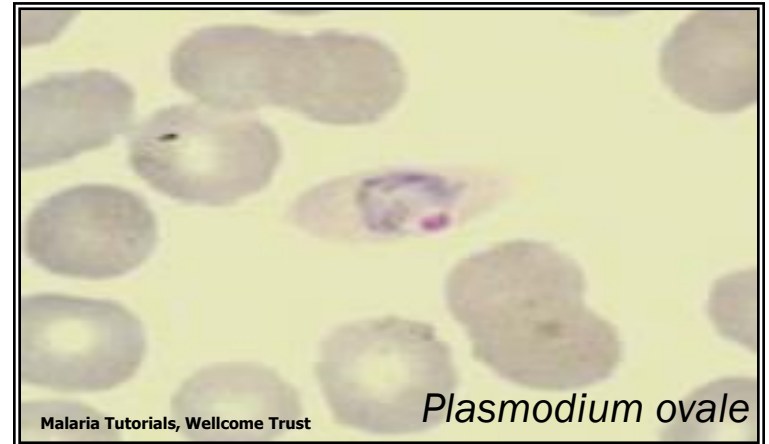

CCMOVBD

Species of malaria is identified by its characteristic microscopic appearance:

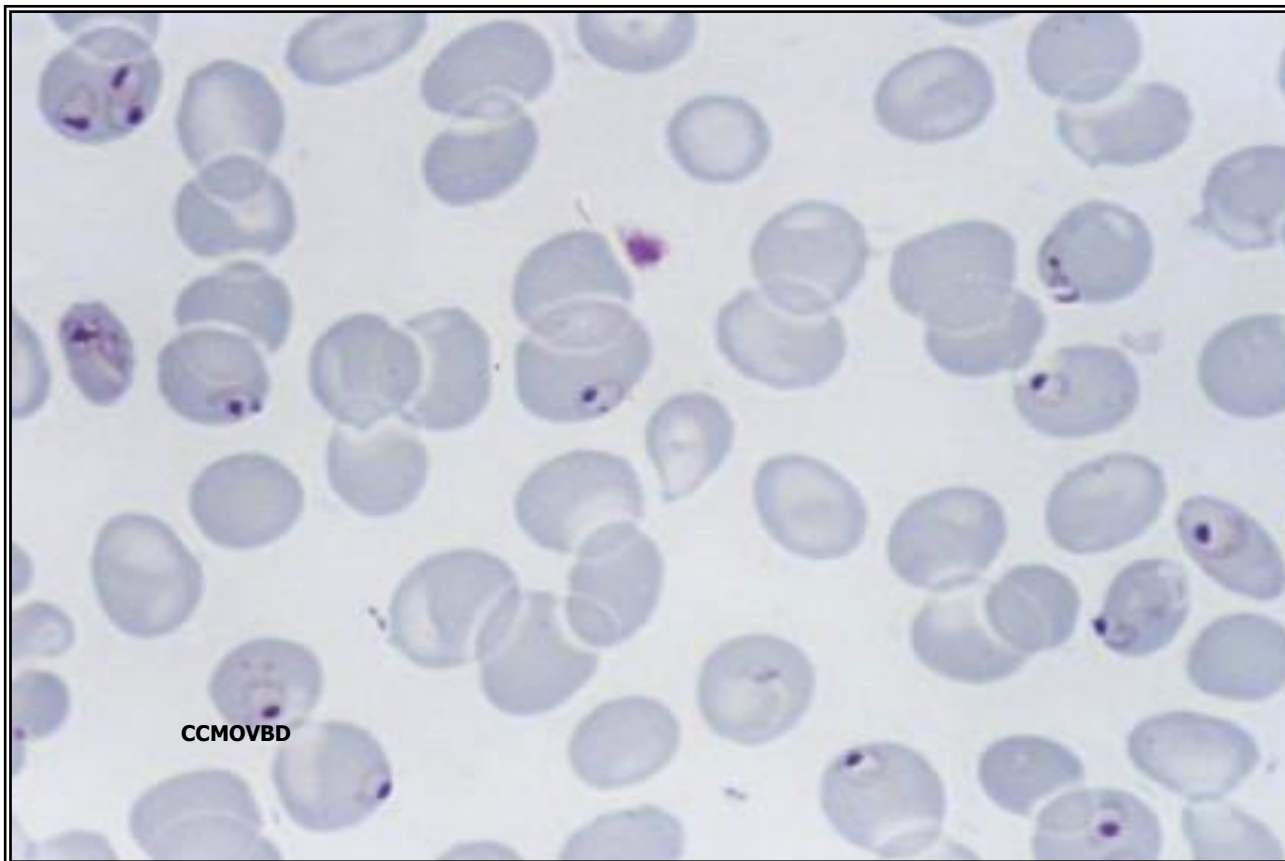


CCMOVBD

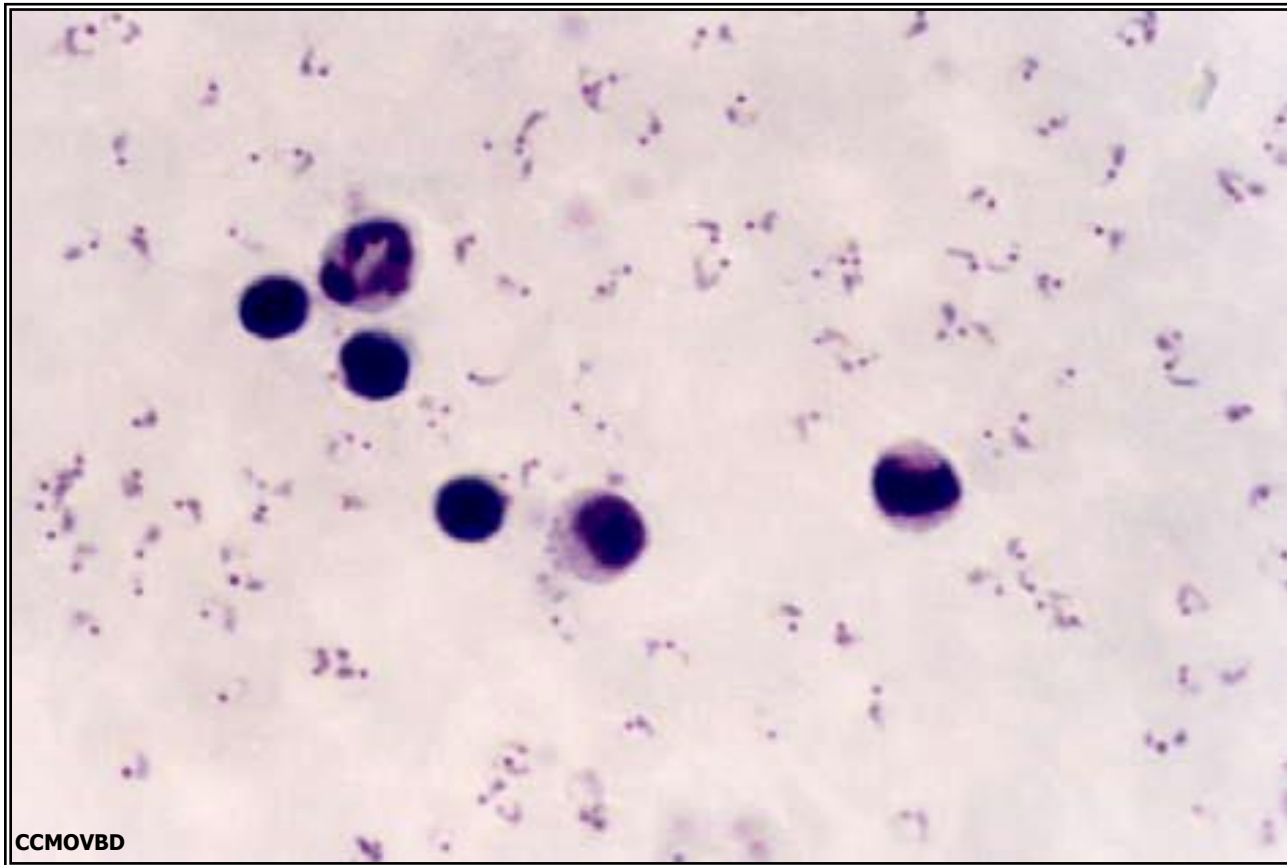


Malaria Tutorials, Wellcome Trust

Plasmodium falciparum
(trophozoite stage in thin smear)

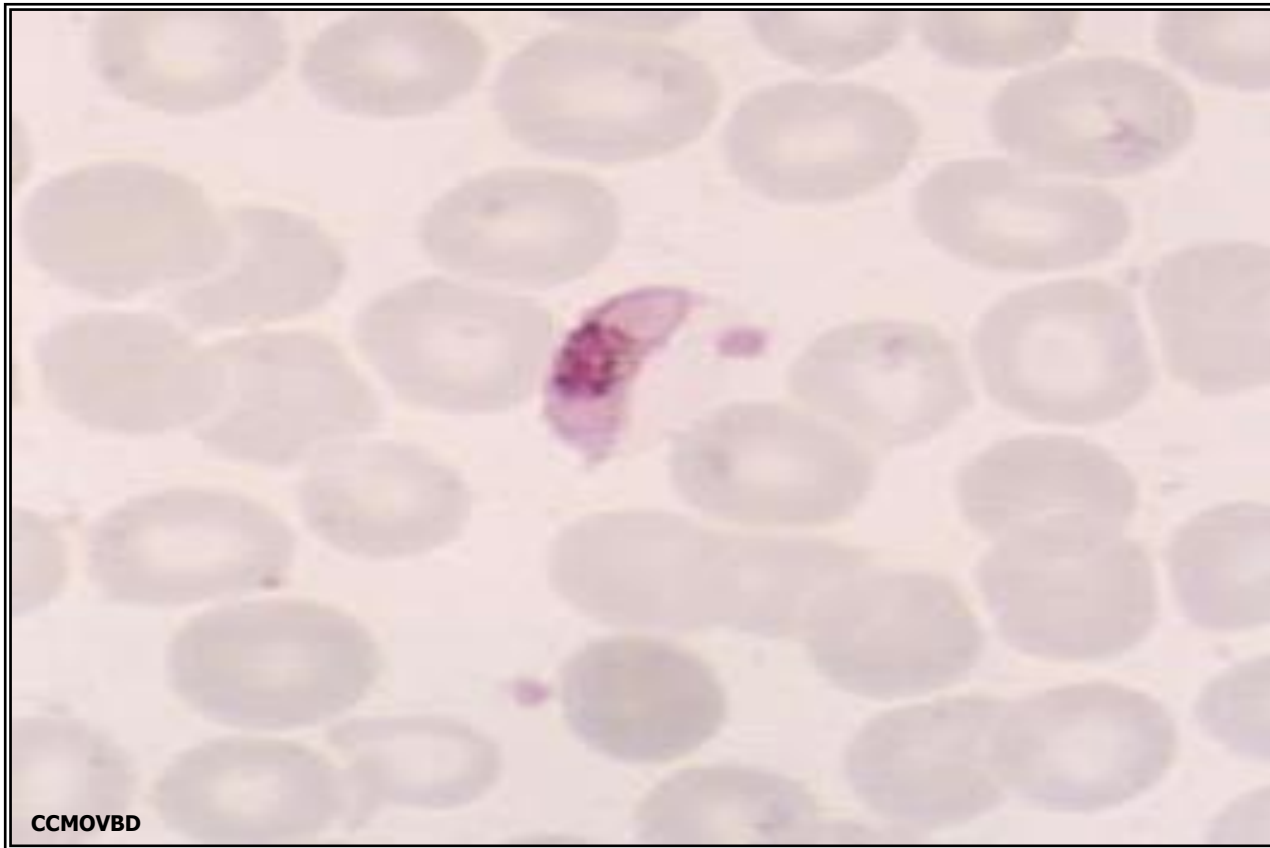


Plasmodium falciparum
(trophozoite stage in thick smear)



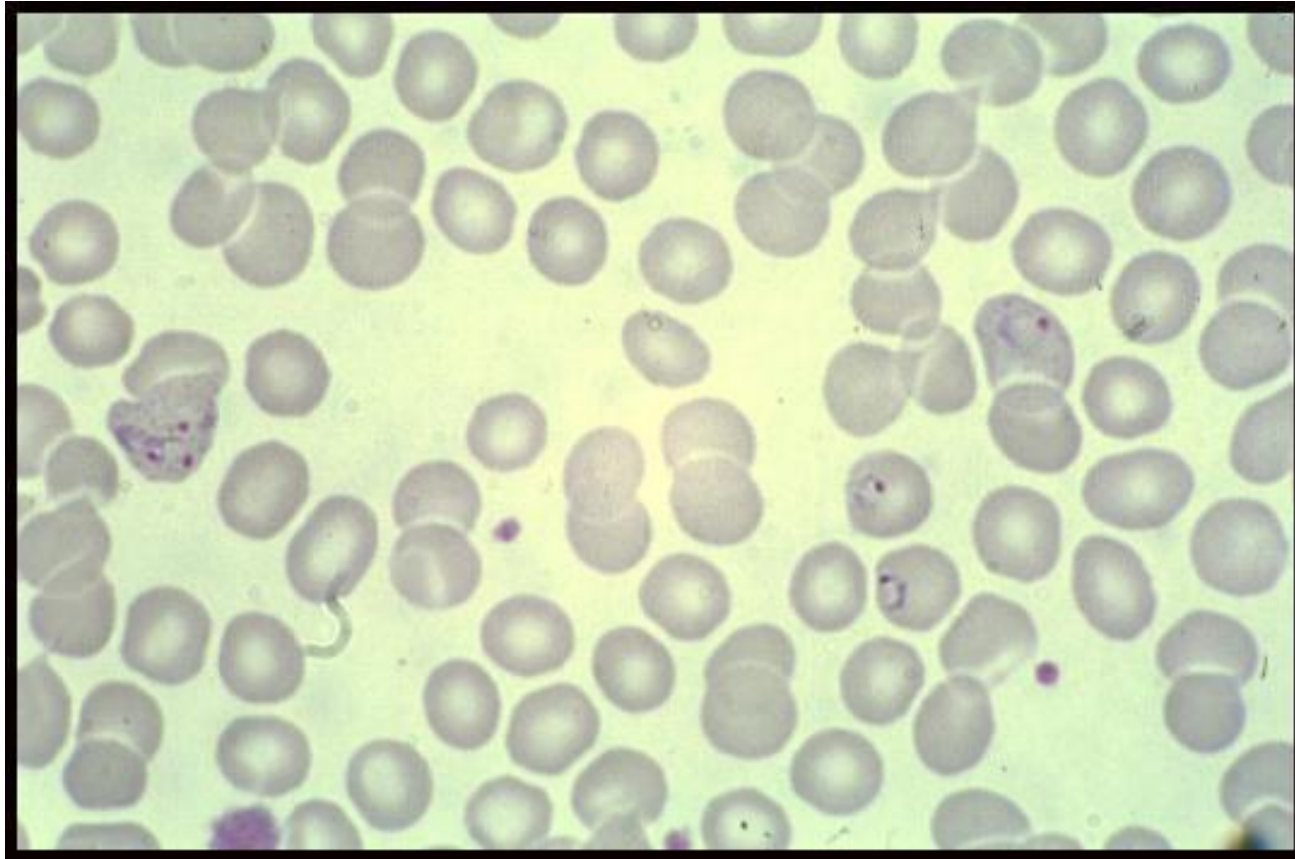
Plasmodium falciparum

(characteristic banana-shaped or crescent –
shaped gametocyte stage in thin smear)



A 25 year-old male from India, who came 3 months ago was admitted in KKUH with a history of severe anaemia and intermittent high grade fever for the last two months not responding to antibiotics.

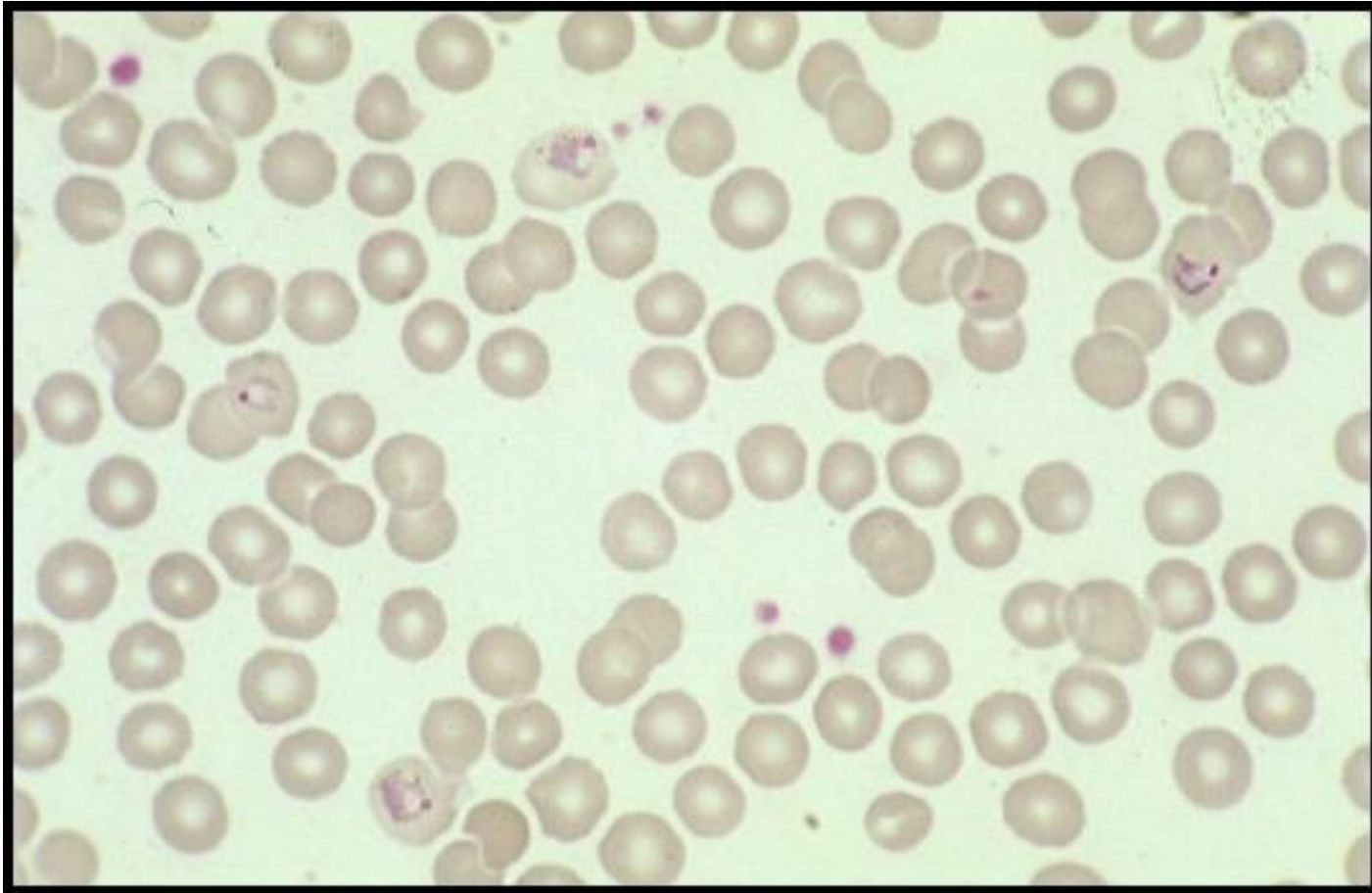
WHAT IS THE DIAGNOSIS?



Diagnosis: malaria or Plasmodium vivax

A businessman who makes frequent trips to Thailand , presents with intermittent fever .

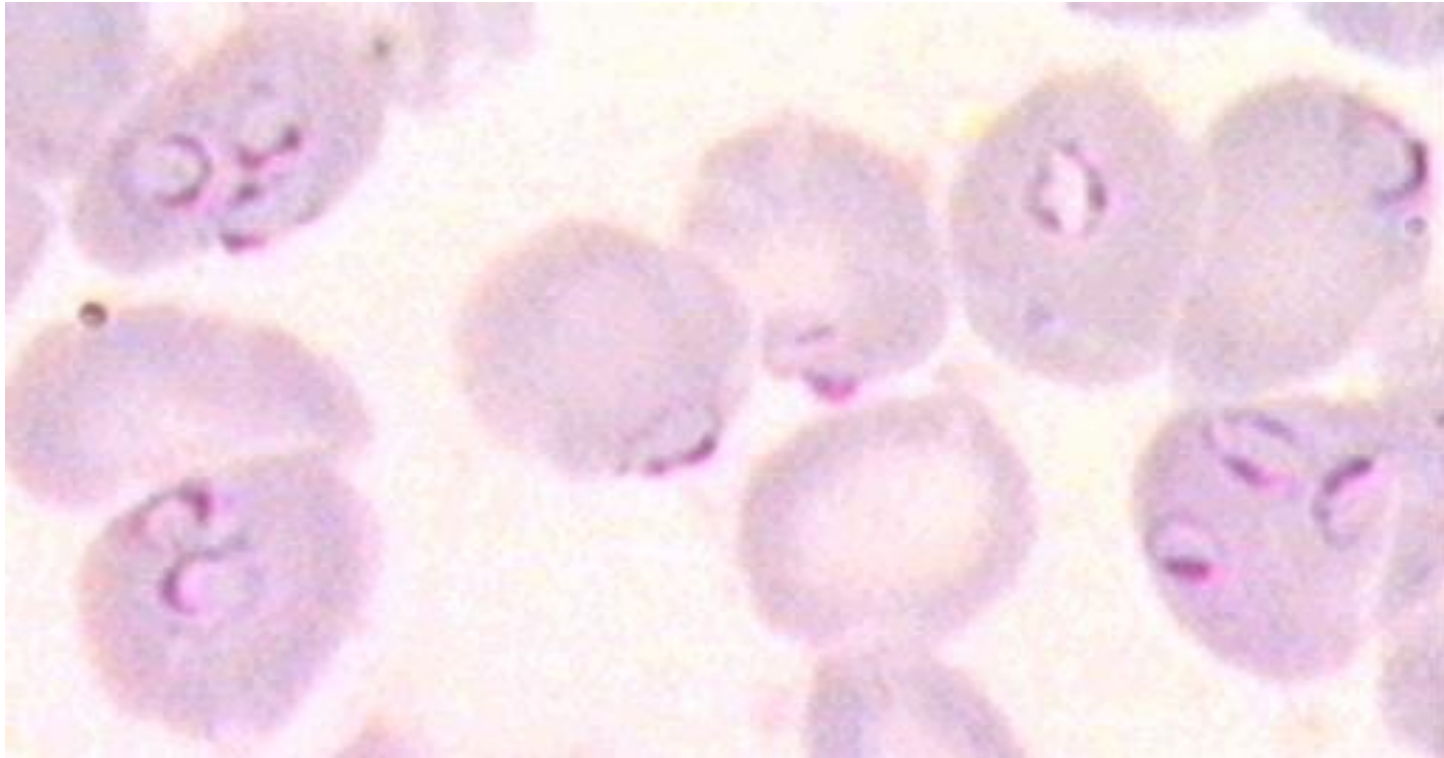
WHAT IS THE DIAGNOSIS?



Diagnosis: malaria or Plasmodium vivax

A student in KSU who returned three weeks from vacation in Africa , he developed intermittent fever last week and lost consciousness a short time ago.

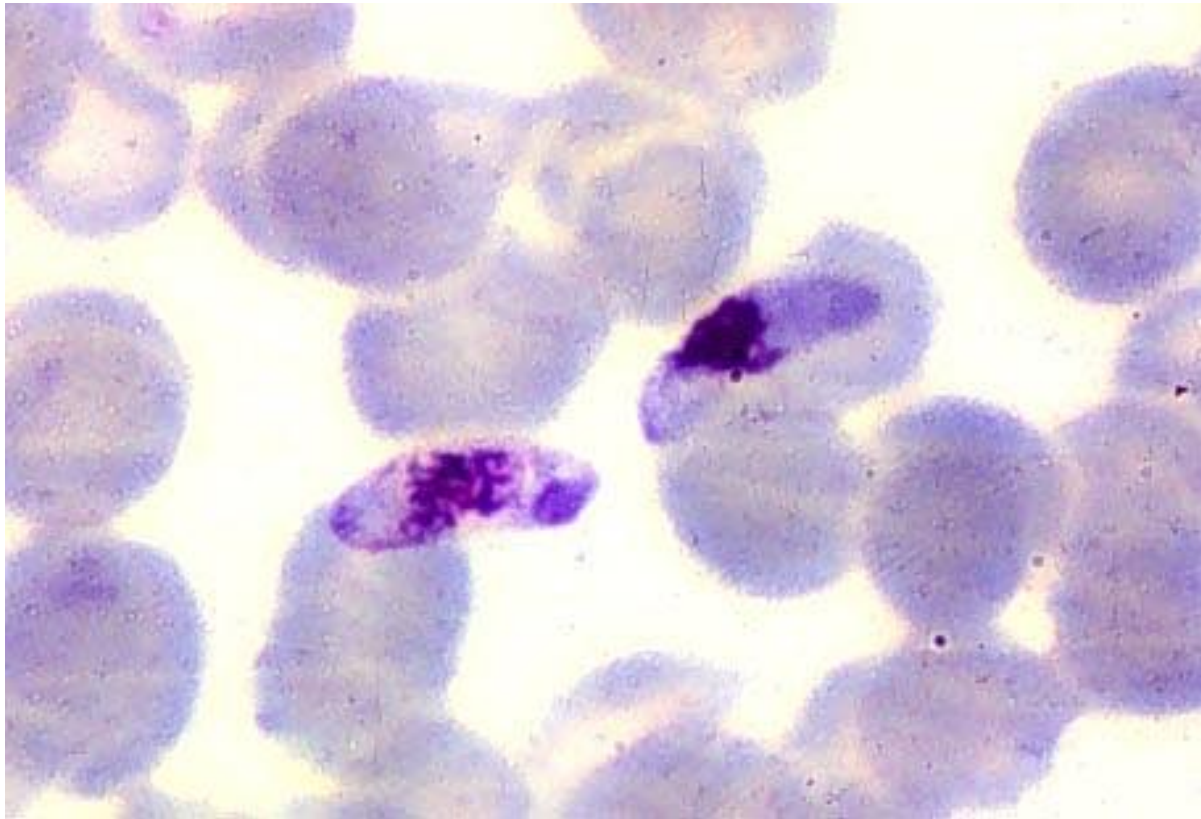
WHAT IS THE DIAGNOSIS?



Diagnosis: malaria or Plasmodium falciparum

The patient was then treated with schizontocidal antimalarial drugs, a follow-up blood film is shown .

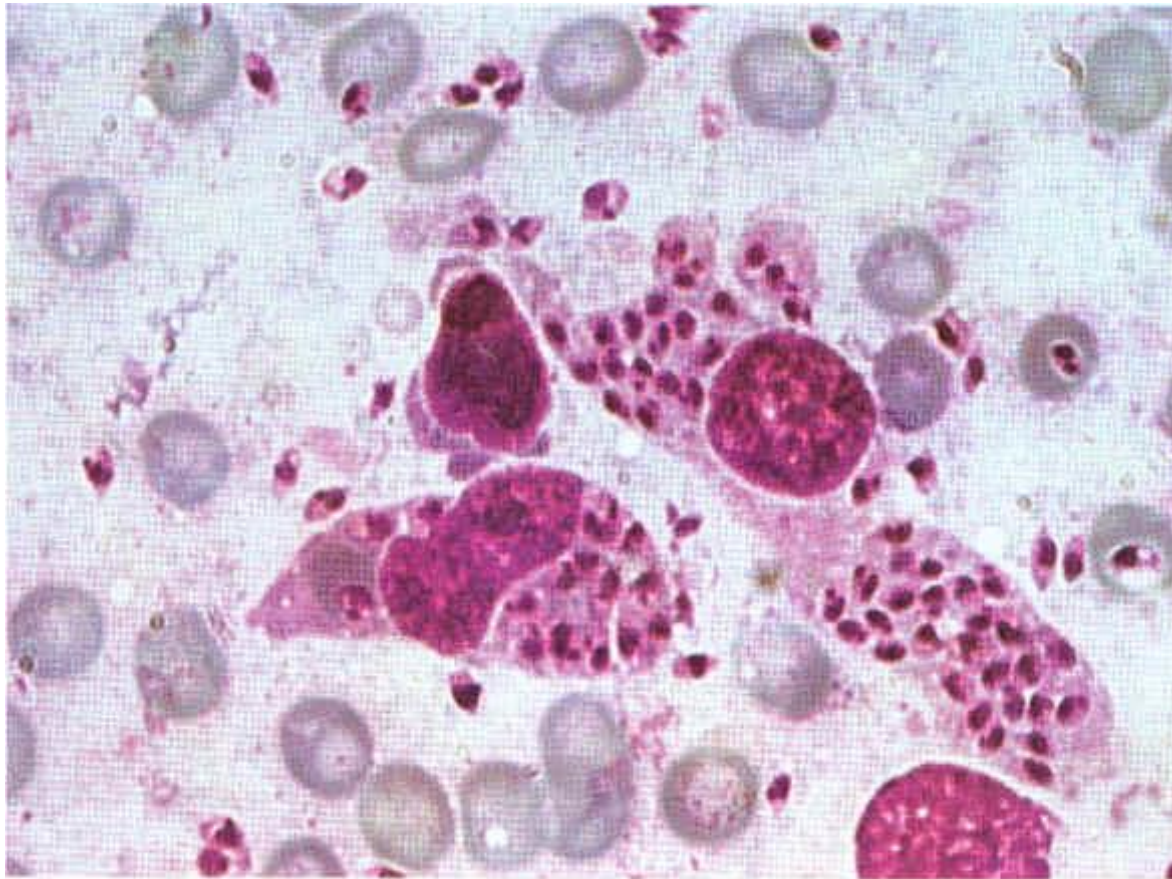
ARE THERE ANY PARASITES? WHAT STAGE ?



Plasmodium falciparum , gametocyte stage

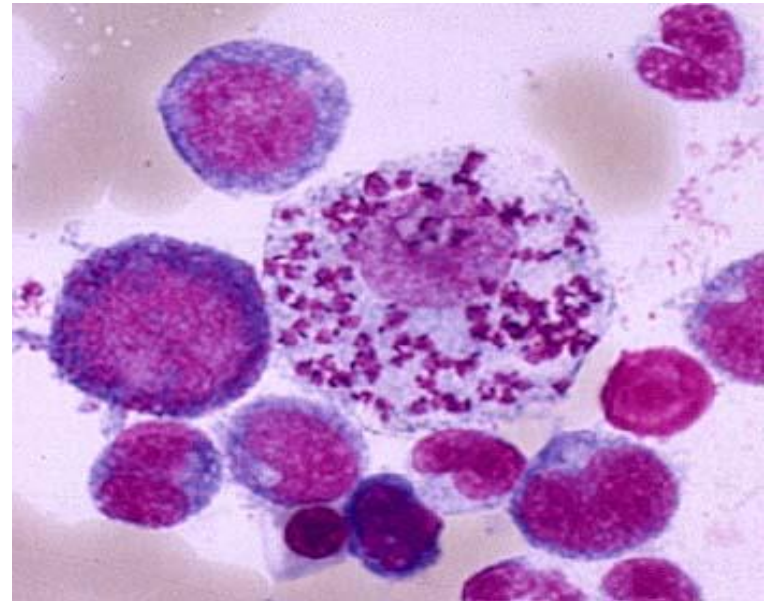
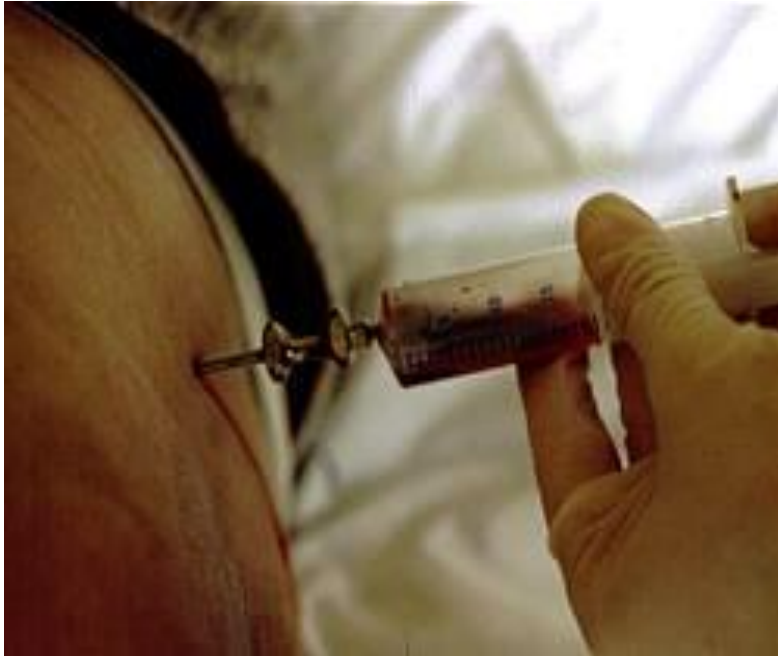A 7 year old child presented with anemia , hepatospenomegaly and fever .Not responding to antimalarials and antibiotics . Bone marrow smear is shown

ARE THERE ANY PARASITES? WHAT STAGE ?



Leishmania , amastigote stage

Bone marrow aspiration



Bone marrow amastigotes