

# Cancers of the liver and pancreas

# Cancers of the liver and pancreas

- Describe hepatocellular and cholangiocarcinoma.
- Understand the frequency of metastatic disease to the liver.
- Recognize the rarity of primary liver neoplasms in children.
- Recognize all aspects of pancreatic carcinoma.

# Malignant tumors of the liver

- The liver and lungs are the visceral organs that are most often involved by metastatic tumors.
- Primary carcinomas of the liver are relatively uncommon.
- Most arise from hepatocytes and are termed *hepatocellular carcinoma* (HCC). Much less common are carcinomas of bile duct origin, *cholangiocarcinomas*.
- There are two rare forms of primary liver cancer: hepatoblastomas and angiosarcomas.

# *Hepatocellular Carcinomas*

- Male predominance
- *More than 85% of cases of HCC occur in countries with high rates of chronic HBV infection.* In these regions, the HBV carrier state begins in infancy following vertical transmission of virus from infected mothers, conferring a 200-fold increased risk for HCC by adulthood

# *Hepatocellular Carcinomas*

- In the Western world where HBV is not prevalent, cirrhosis is present in 85% to 90% of cases of HCC, usually in the setting of other chronic liver diseases;

# Pathogenesis of HCC

The following have been implicated in human hepatocarcinogenesis:

- 1) viral infection (HBV, HCV): Extensive studies link chronic HBV and chronic HCV infection with liver cancer.
- 2) Cirrhosis: the development of cirrhosis appears to be an important, but not requisite, contributor to the emergence of HCC.
- 3) Chronic alcoholism.

# Pathogenesis of HCC

- 4) Food contaminants (primarily aflatoxins from aspergillus). High exposure to dietary aflatoxins derived from the fungus *Aspergillus flavus*. These highly carcinogenic toxins are found in "moldy" grains and peanuts.
- 5) Other conditions include tyrosinemia and hereditary hemochromatosis.

# Morphology of HCC

- Grossly it may be
- (1) a **unifocal** mass
- (2) **multifocal**, multiple nodules of variable size;
- (3) a **diffusely infiltrative** cancer.
- All three patterns may cause liver enlargement. **All patterns of hepatocellular carcinomas have a strong propensity for invasion of vascular channels.**



# Morphology of HCC

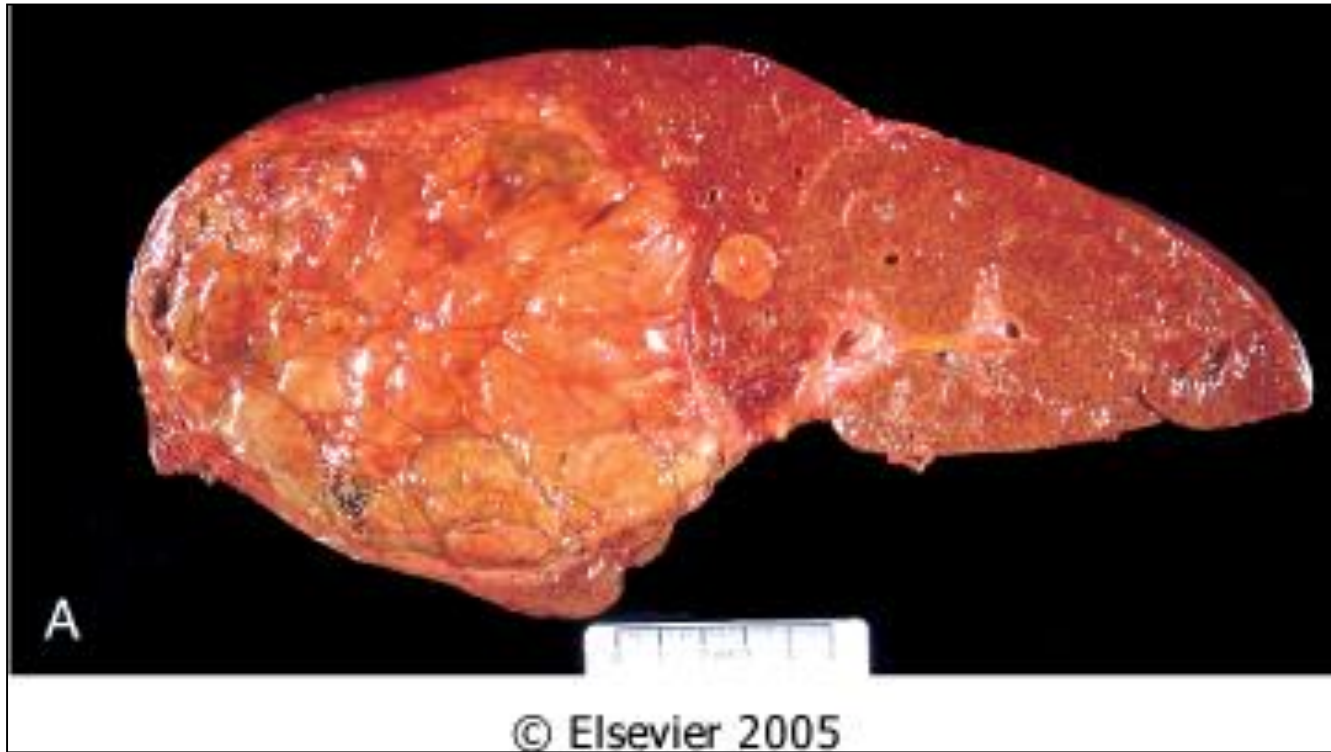
- Extensive intrahepatic metastases may occur
- Tumor may invade the portal vein (with occlusion of the portal circulation) or inferior vena cava, extending even into the right side of the heart.
- Lymph node metastases to the perihilar, peripancreatic, and para-aortic nodes above and below the diaphragm can be present.
- Hepatocellular carcinomas range from well-differentiated to highly anaplastic undifferentiated lesions.

# Morphology of HCC

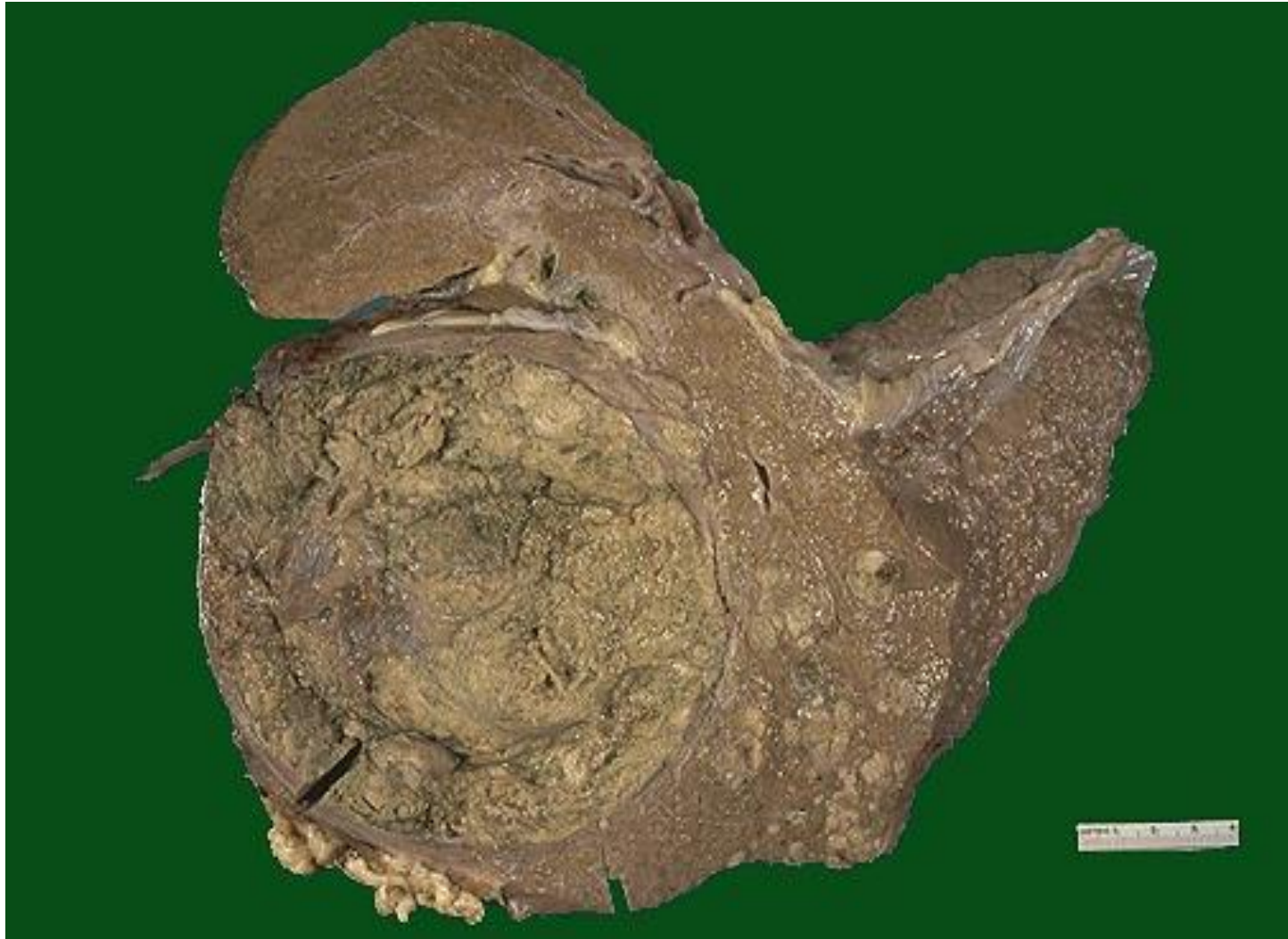- In well-differentiated and moderately well-differentiated tumors, cells that are recognizable as hepatocytic in origin. Bile pigment is usually present. The malignant cells may be positive for alpha-fetoprotein.
- In poorly differentiated forms, tumor cells can take on a pleomorphic appearance with numerous anaplastic giant cells, can become small and completely undifferentiated cells.

# fibrolamellar carcinoma

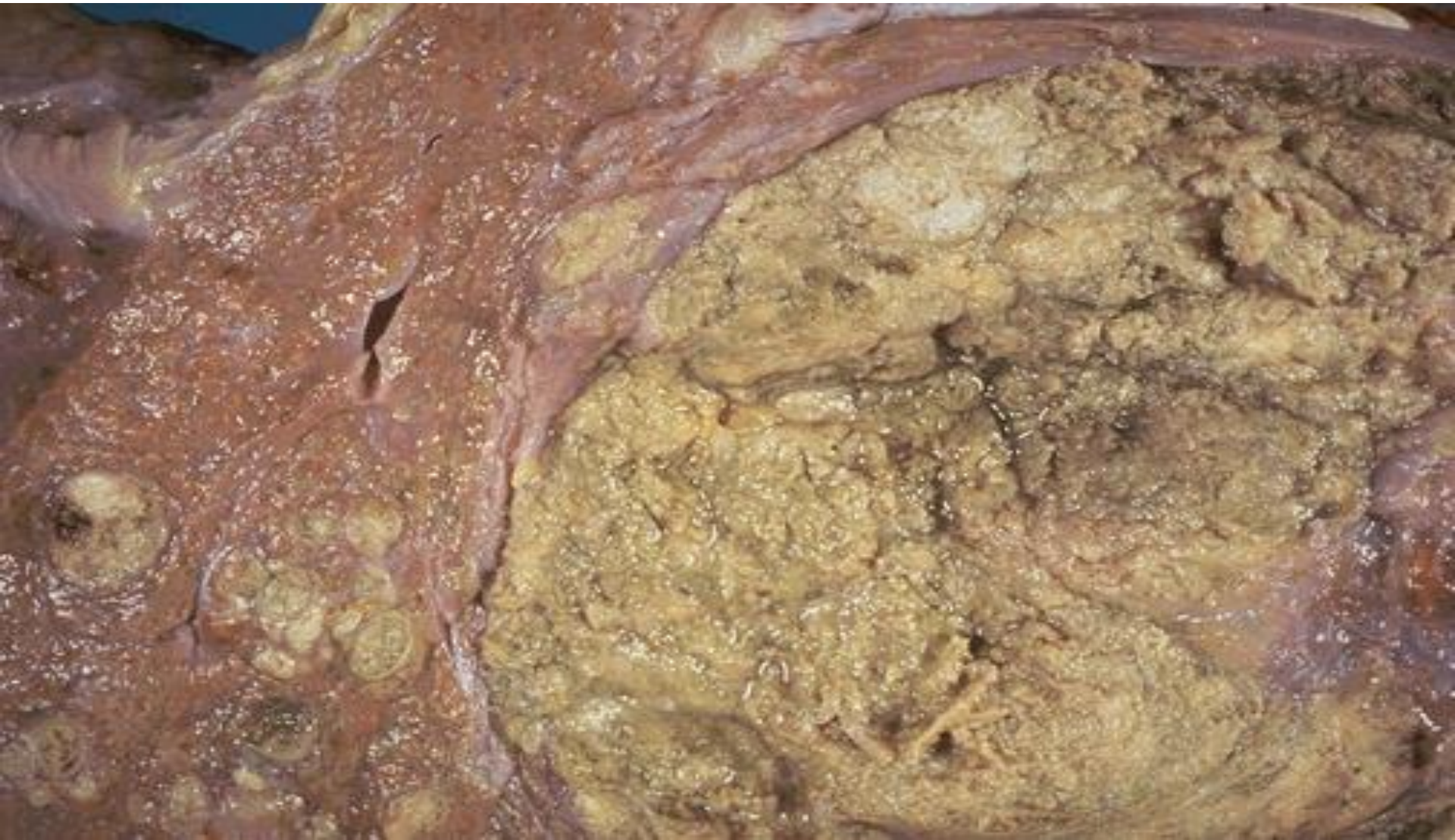
- A distinctive variant of hepatocellular carcinoma is the **fibrolamellar carcinoma**.
- This tumor occurs in young male and female adults (20 to 40 years of age), has no association with HBV or cirrhosis, and often has a better prognosis.
- It usually presents as single large, hard "scirrhous" tumor with fibrous bands coursing through it. On microscopic examination, it is composed of well-differentiated polygonal cells growing in nests or cords and separated by parallel lamellae of dense collagen bundles

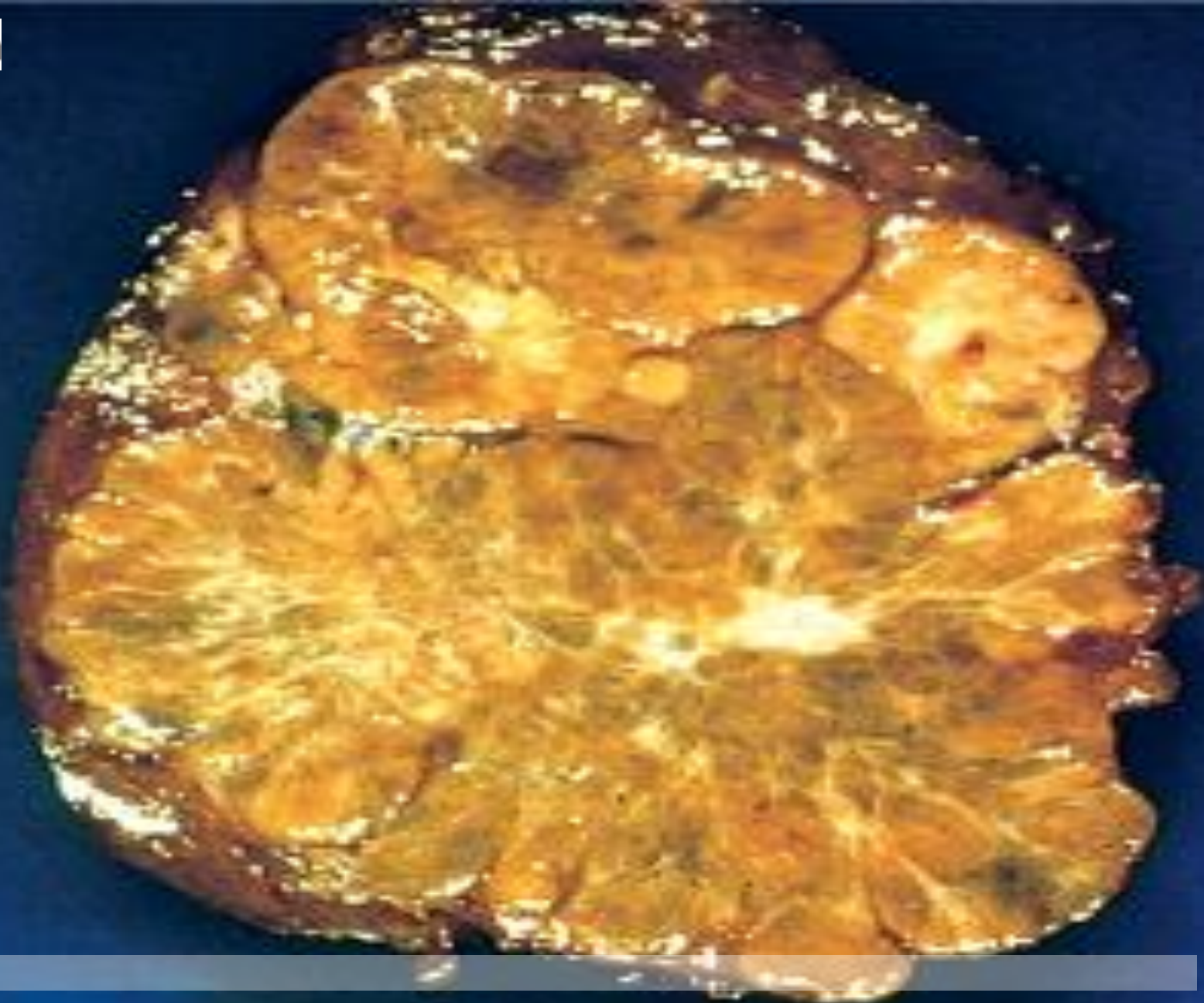

Hepatocellular carcinoma. Such liver cancers arise in the setting of cirrhosis. Worldwide, viral hepatitis is the most common cause, but in the U.S., chronic alcoholism is the most common cause. The neoplasm is large and bulky and has a greenish cast because it contains bile. To the right of the main mass are small satellite nodules.

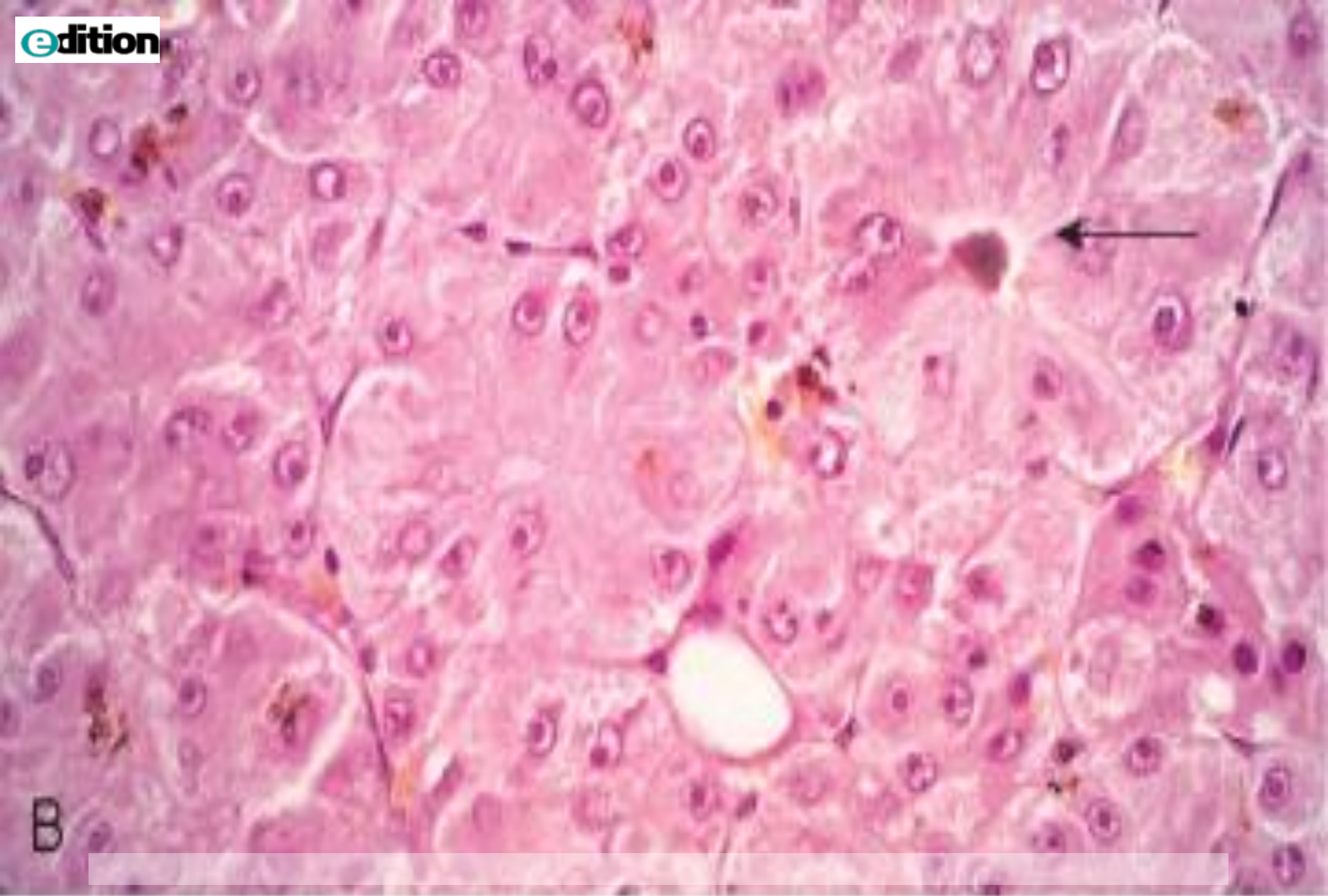


The satellite nodules of this hepatocellular carcinoma.



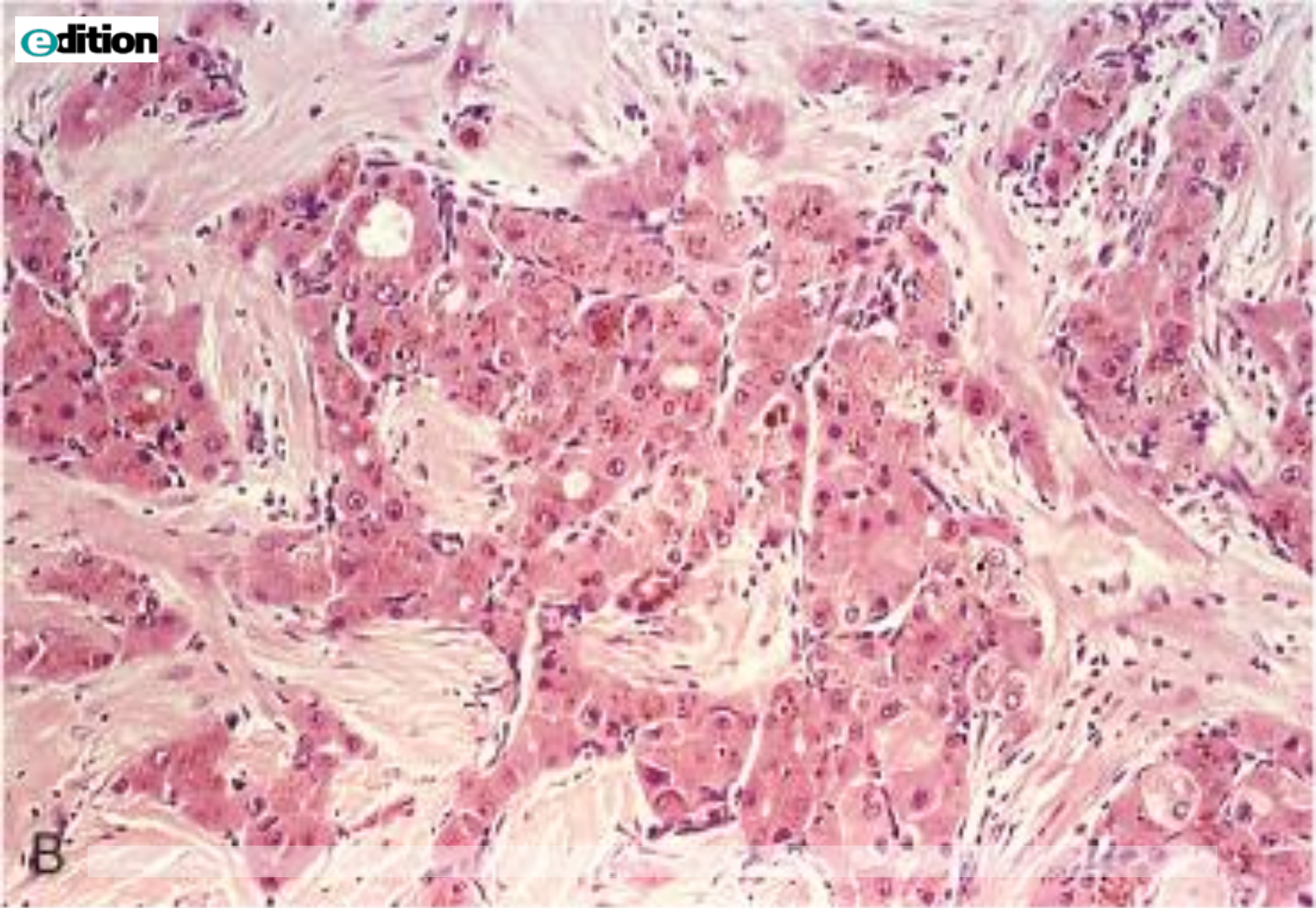


A

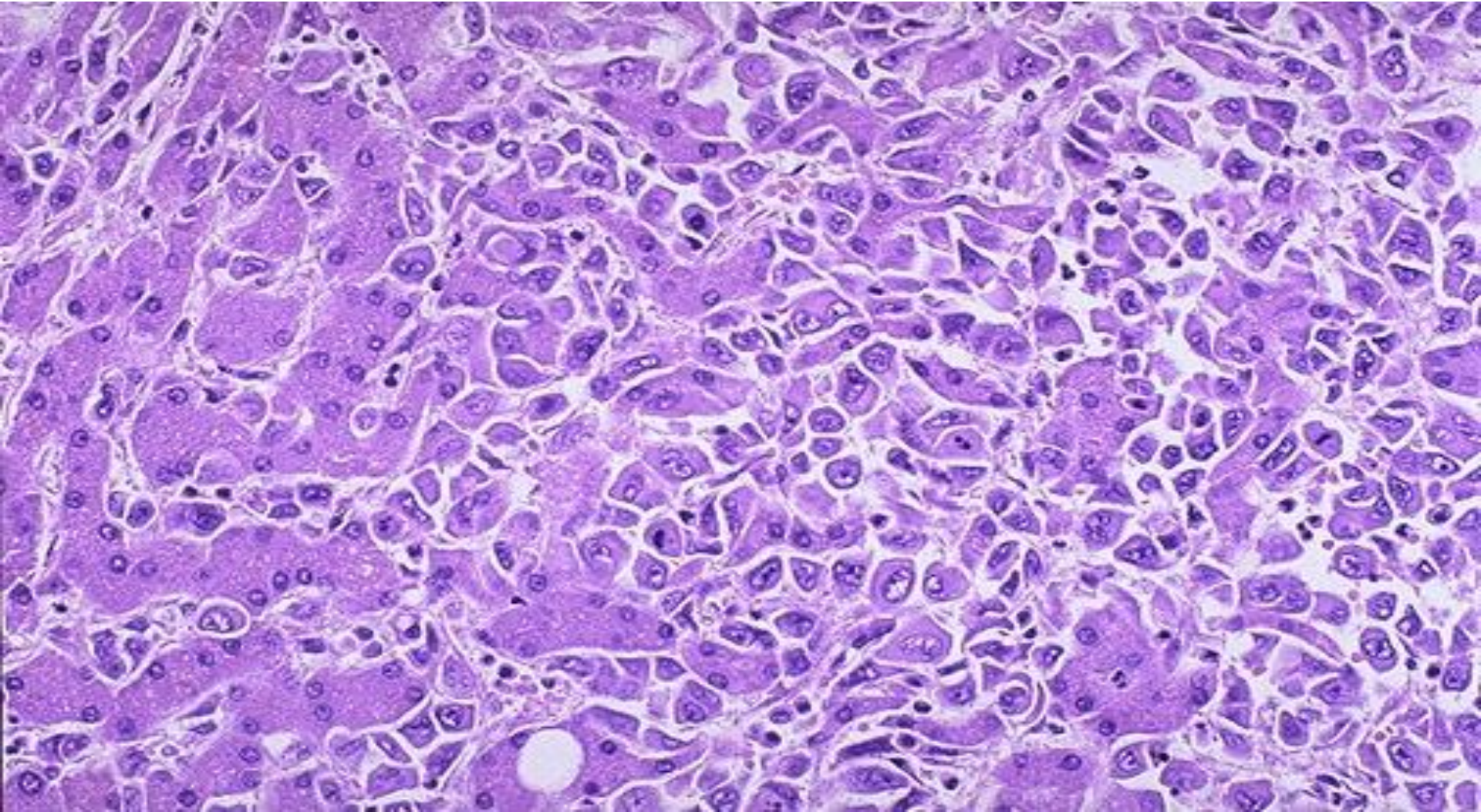


B





Malignant cells of HCC (seen mostly on right) are well differentiated and interdigitate with normal, larger hepatocytes (seen mostly at left).



# Clinical Features

- Ill-defined upper abdominal pain, malaise, fatigue, weight loss, and feeling of abdominal fullness.
- In many cases, the enlarged liver can be felt on palpation. Jaundice and fever are uncommon.
- Laboratory studies: Elevated levels of serum  $\alpha$ -fetoprotein are found in 50% to 75% of patients with HCC.

# Hepatocellular Carcinoma

- Overall, death usually occurs from
- (1) cachexia
- (2) gastrointestinal or esophageal variceal bleeding
- (3) liver failure with hepatic coma
- (4) rupture of the tumor with fatal hemorrhage.

# Cholangiocarcinoma

- Cholangiocarcinoma is a malignancy of the biliary tree, arising from bile ducts within and outside of the liver.

## The risk conditions for development of cholangiocarcinoma include

- Primary sclerosing cholangitis,
- Congenital fibropolycystic diseases of the biliary system (particularly Caroli disease and choledochal cysts),
- Previous exposure to Thorotrast (formerly used in radiography of the biliary tract).
- In the Orient, the incidence rates are higher, and it is due to chronic infection of the biliary tract by the liver fluke *Opisthorchis sinensis*.

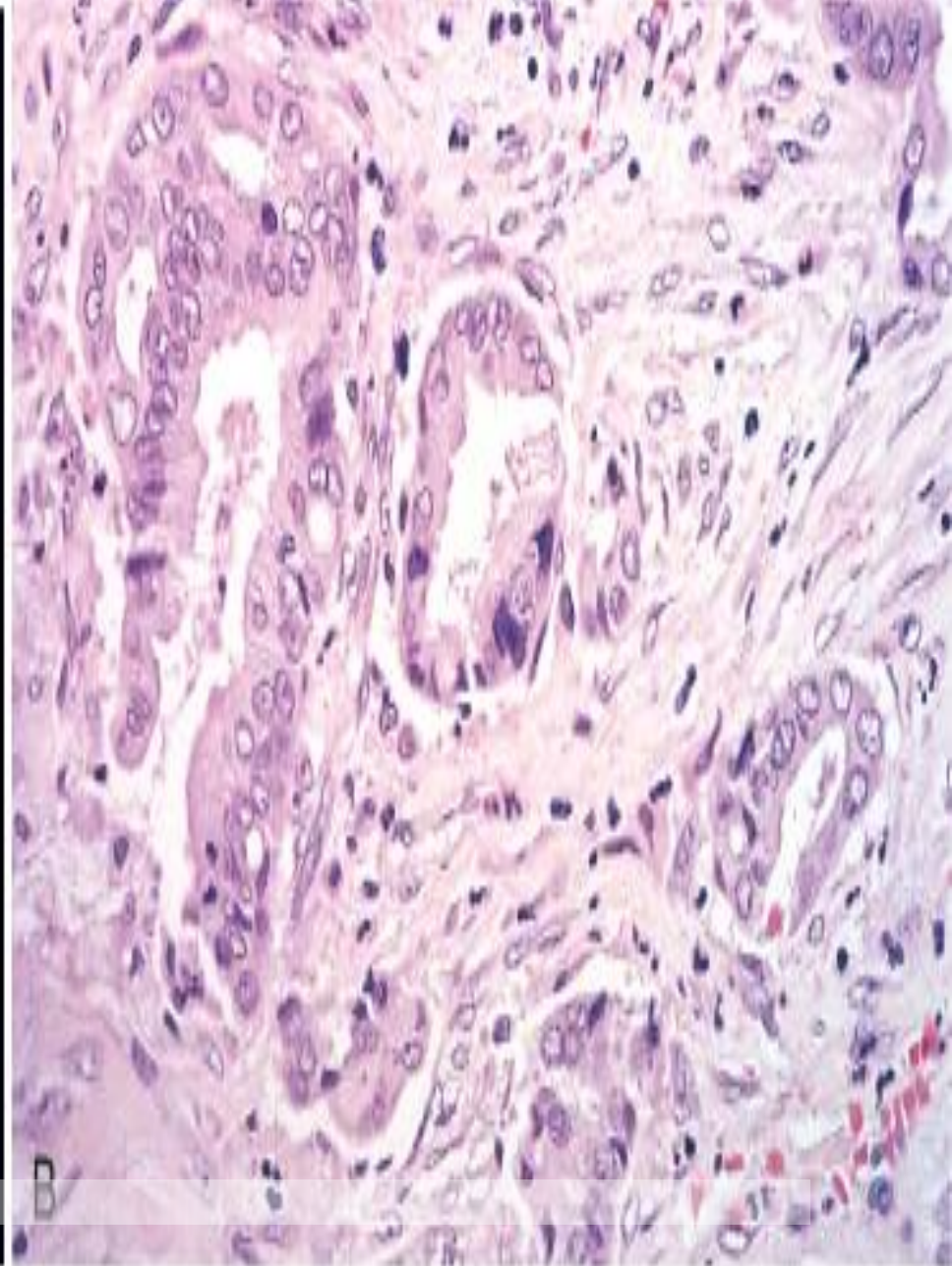
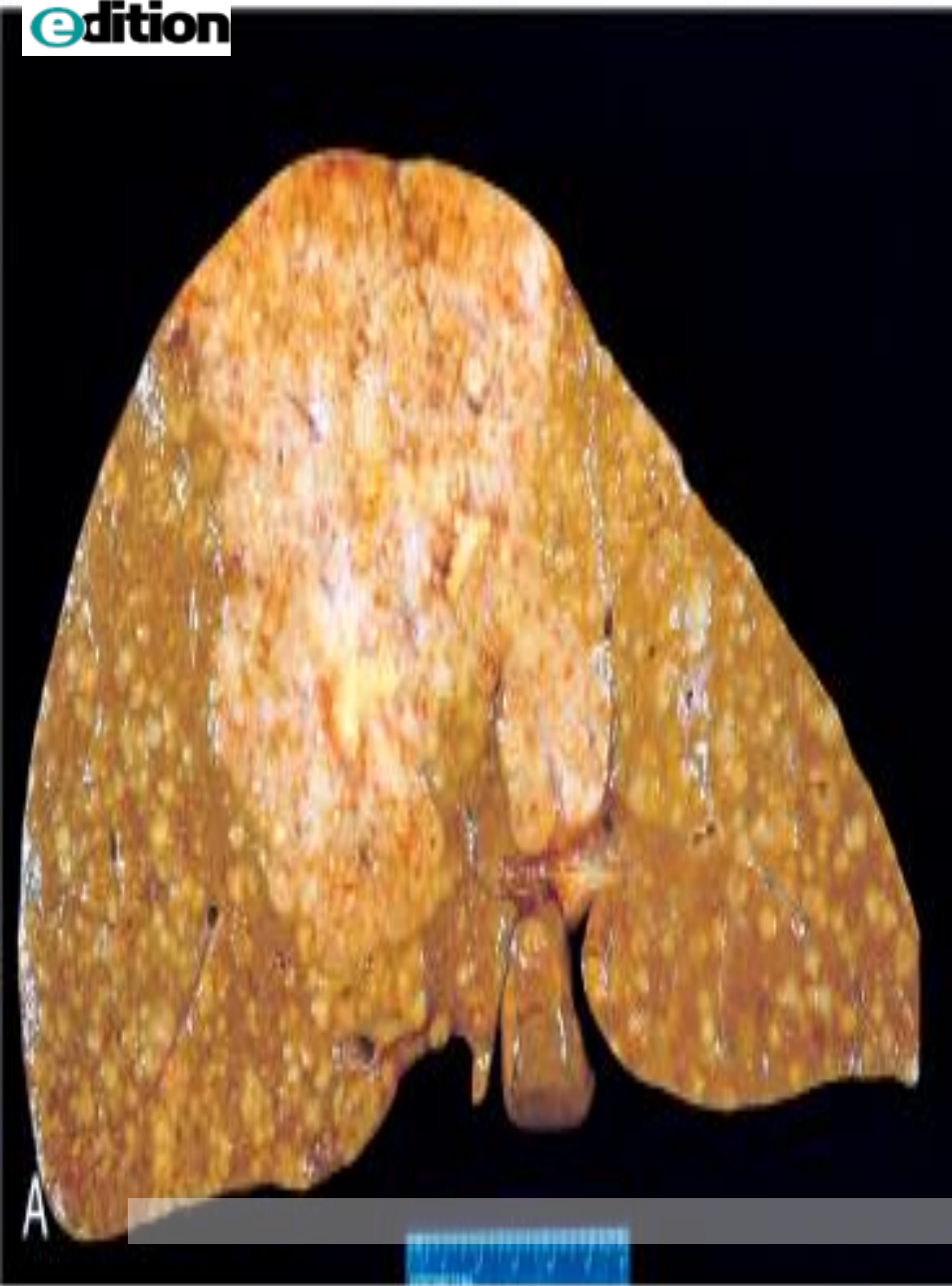# Morphology

- **Intrahepatic cholangiocarcinomas** occur in the non-cirrhotic liver and may track along the intrahepatic portal tract system to create a treelike tumorous mass within the liver or a massive tumor nodule. Lymphatic and vascular invasion are common.
- By microscopy, cholangiocarcinomas resemble adenocarcinomas arising in other parts of the body. Most are well to moderately differentiated.  
**Cholangiocarcinomas are rarely bile stained,** because differentiated bile duct epithelium does not synthesize bile.

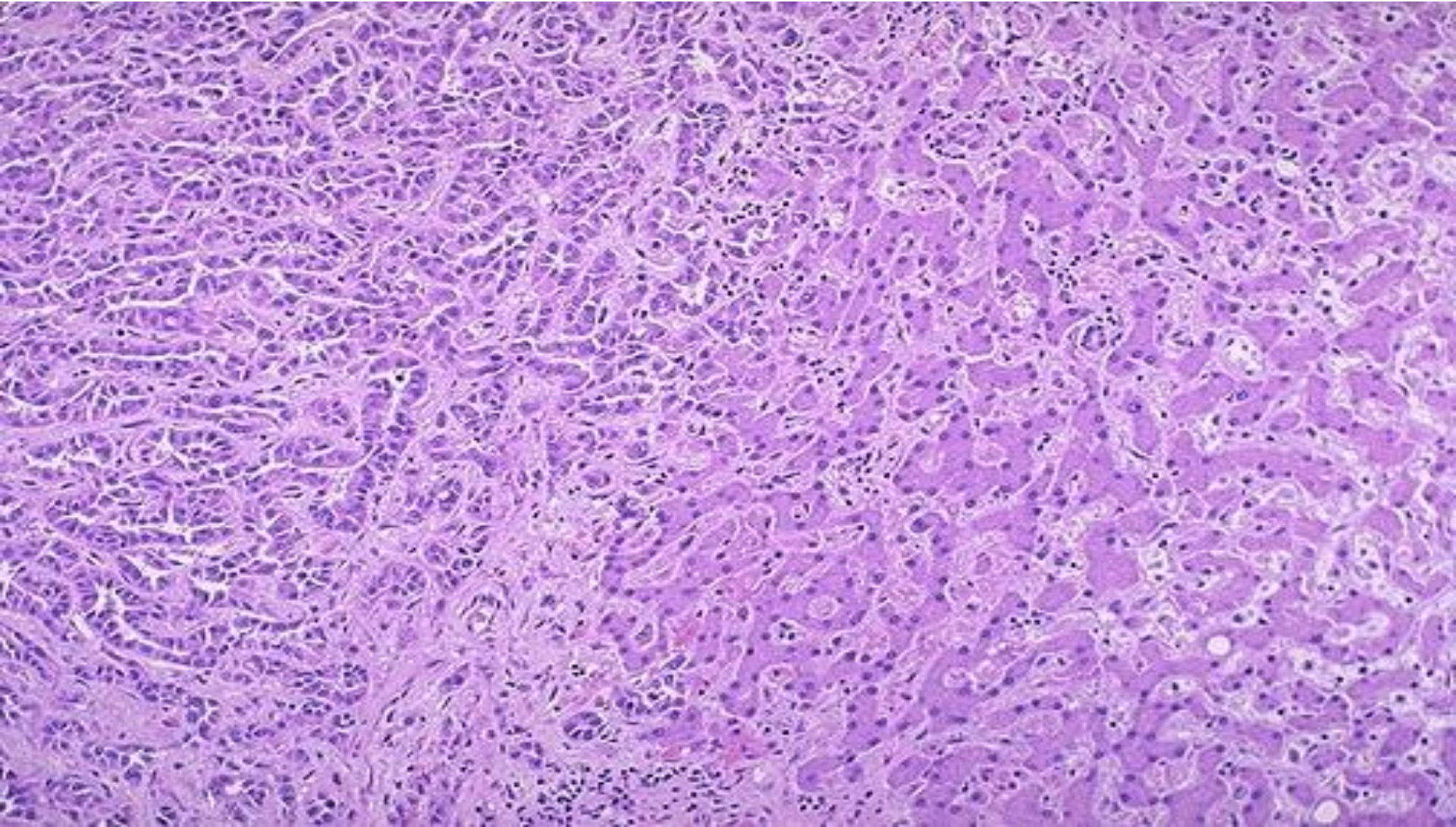
# Morphology

- Mixed variants occur, in which elements of both hepatocellular carcinoma and cholangiocarcinoma are present.
- Hematogenous metastases to the lungs, bones (mainly vertebrae), adrenals, brain. Lymph node metastases to the regional lymph nodes are also found





The carcinoma at the left has a glandular appearance. Cholangiocarcinomas do not make bile, but the cells do make mucin, and they can be almost impossible to distinguish from metastatic adenocarcinoma on biopsy or fine needle aspirate

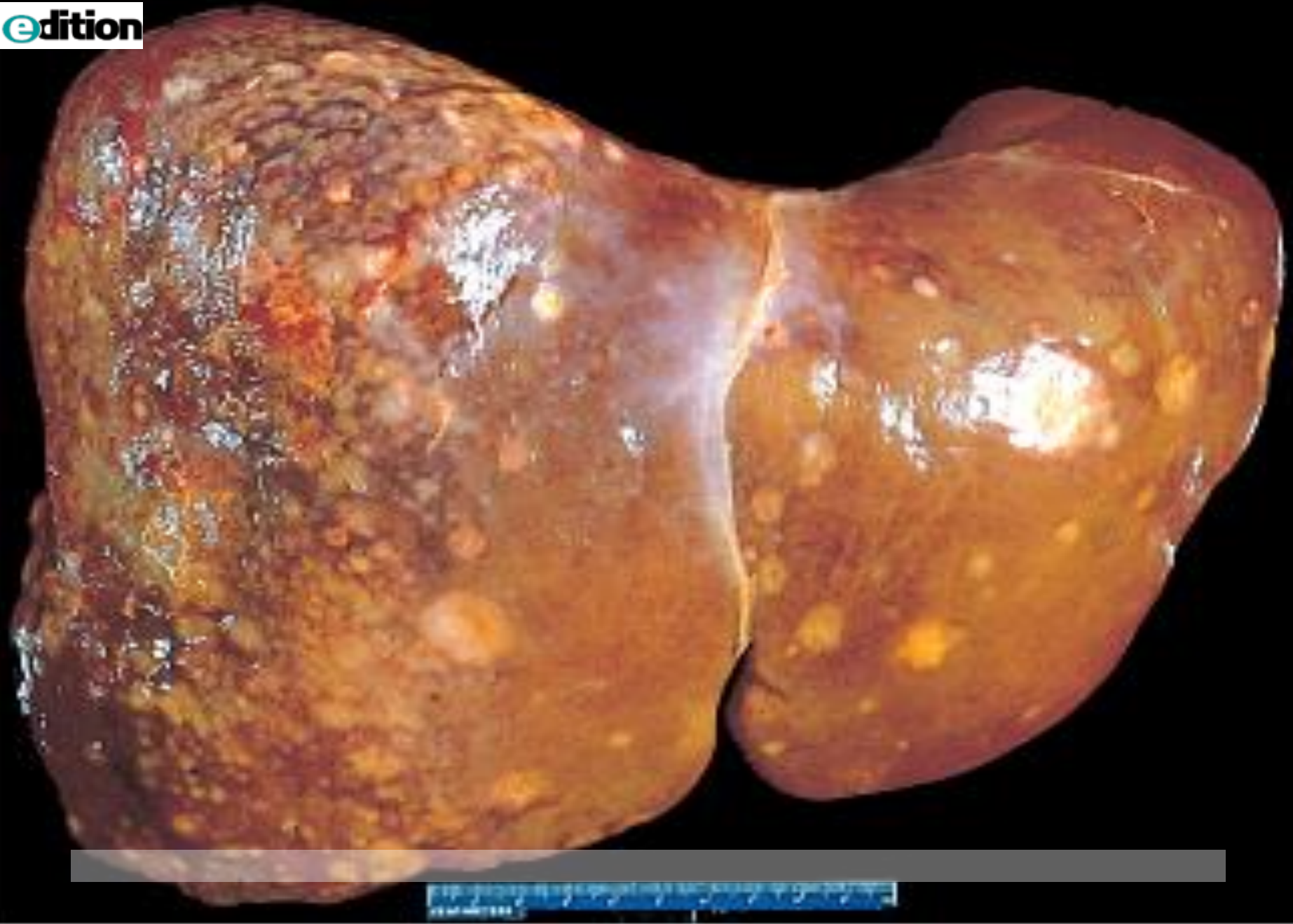


# Clinical Features

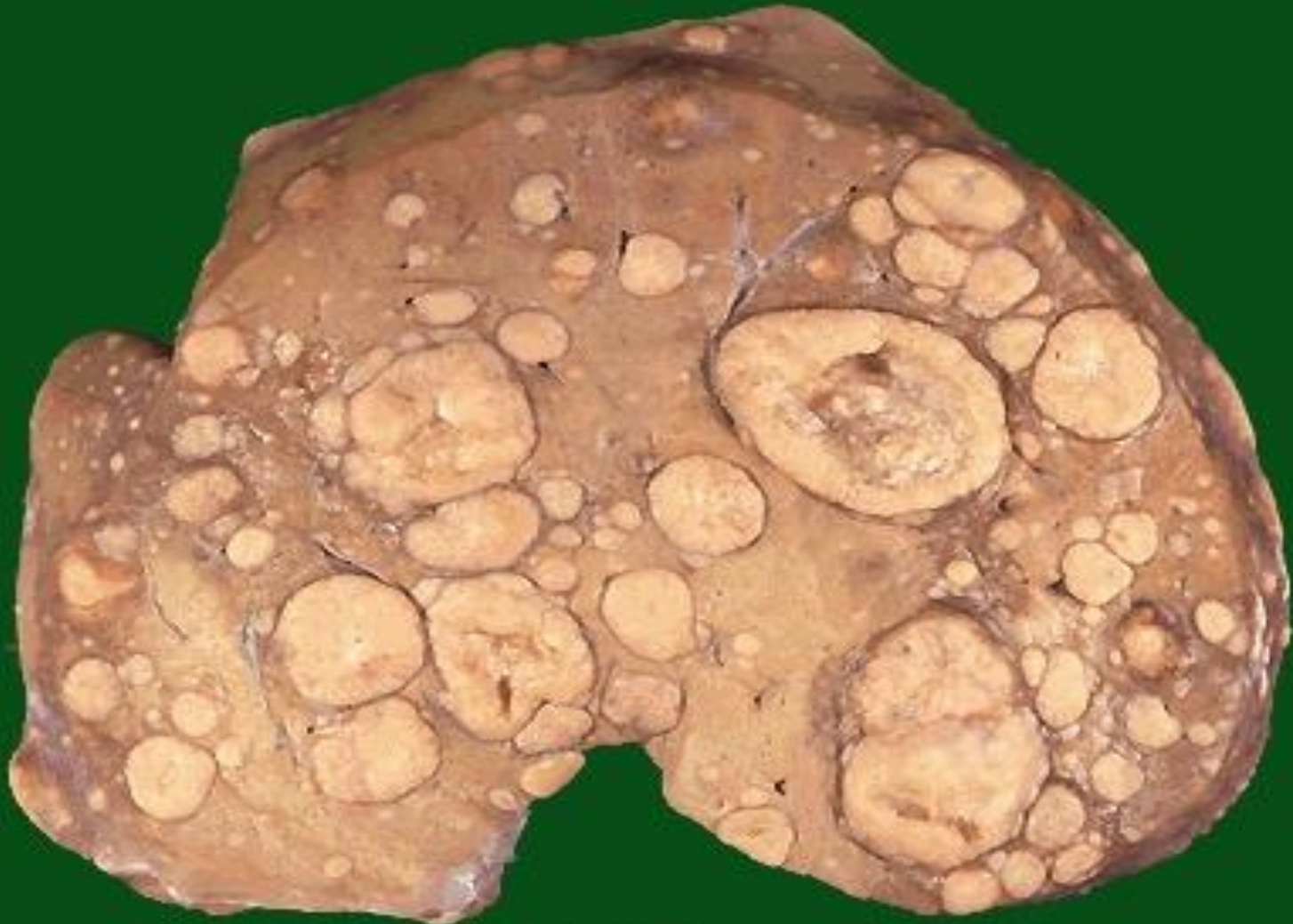- Intrahepatic cholangiocarcinoma is usually detected late in its course, either as the result of obstruction to bile flow through the hilum of the liver or as a symptomatic liver mass.
- Prognosis is poor. The median time from diagnosis to death is 6 months. Aggressive surgery remains the only treatment offering hope for long-term survival.
- Alpha-fetoprotein is not elevated.

# Metastatic tumors

- Metastatic involvement of the liver is far more common than primary neoplasia.
- Although the most common primaries producing hepatic metastases are those of the breast, lung, and colon, any cancer in any site of the body may spread to the liver, including leukemias and lymphomas.
- Typically, multiple nodular metastases are found that often cause striking hepatomegaly and may replace over 80% of existent hepatic parenchyma. The liver weight can exceed several kilograms.



Numerous mass lesions of variable size. Some of the larger ones demonstrate central necrosis. The masses are metastases to the liver.



# ANGIOSARCOMA

- This consists of pleomorphic endothelial cells with large hyperchromatic nuclei, giant cells in frequent mitosis and irregular anastomosing vascular channels. The cells may appear spindle shaped and cirrhosis is present in 20% to 40% of the cases. These have also been linked to vinyl chloride and thorostrast exposure.

# *PANCREATIC CARCINOMA*

- Pancreatic cancer has one of the highest mortality rates of any cancer. It is carcinoma of the exocrine pancreas. It arises from ductal epithelial cells.
- It occurs in the 6<sup>th</sup> to 8<sup>th</sup> decade, blacks more than whites, males more than females, diabetics more than non-diabetics.



# *PANCREATIC CARCINOMA* Morphology

- Approximately 60% of cancers of the pancreas arise in the head of the gland, 15% in the body, and 5% in the tail; in 20%, the neoplasm diffusely involves the entire gland.
- Carcinomas of the pancreas are usually hard, stellate, gray-white, poorly defined masses.

# *PANCREATIC CARCINOMA* Morphology

- Majority of carcinomas are ductal adenocarcinomas. Two features are characteristic: It is highly invasive, and it elicits an intense non-neoplastic host reaction called a "desmoplastic response".

# *PANCREATIC CARCINOMA* Morphology

- Peripancreatic, gastric, mesenteric, omental, and portahepatic lymph nodes are frequently involved. Distant metastases occur, principally to the lungs and bones.
- Less common variants of pancreatic cancer include **acinar cell carcinomas, adenosquamous carcinomas, and undifferentiated carcinomas with osteoclast-like giant cells.**

# *PANCREATIC CARCINOMA: CLINICAL FEATURES*

- Jaundice, weight loss, pain ,massive metastasis to liver and migratory thrombophelebitis

# *PANCREATIC CARCINOMA*

