

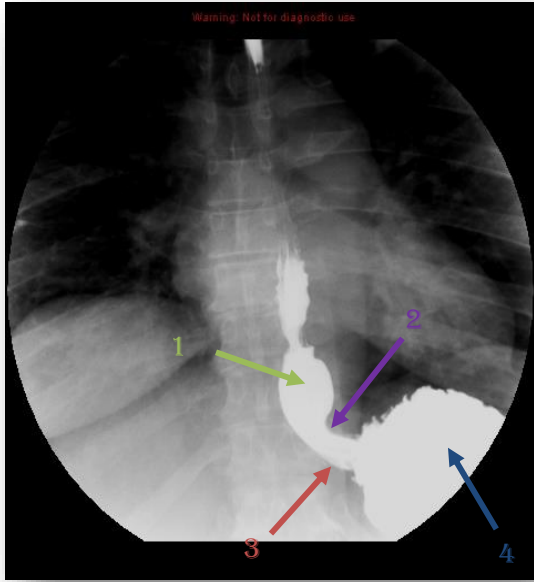


GIT Practical

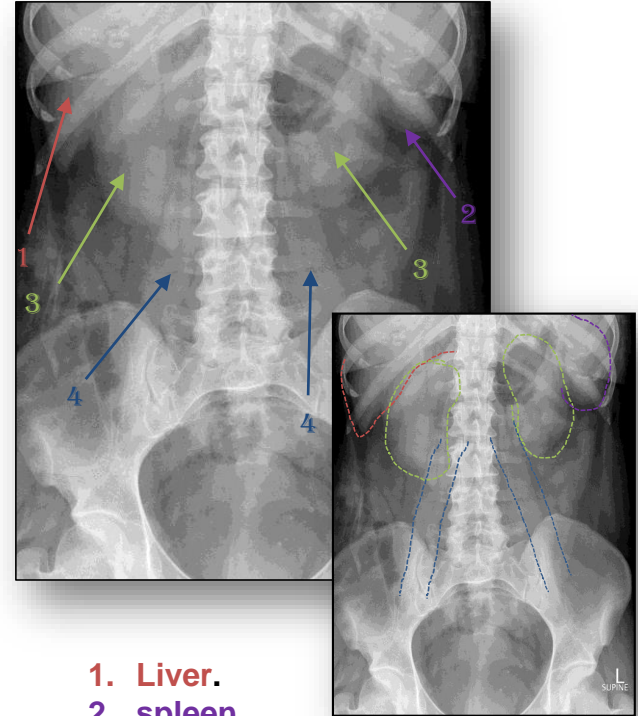
Please check this [link](#) frequently for any additions or corrections.



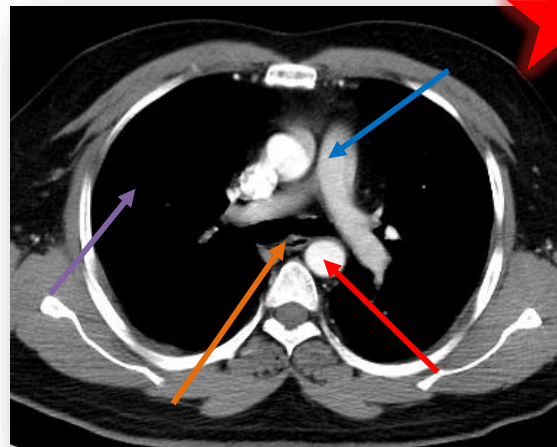
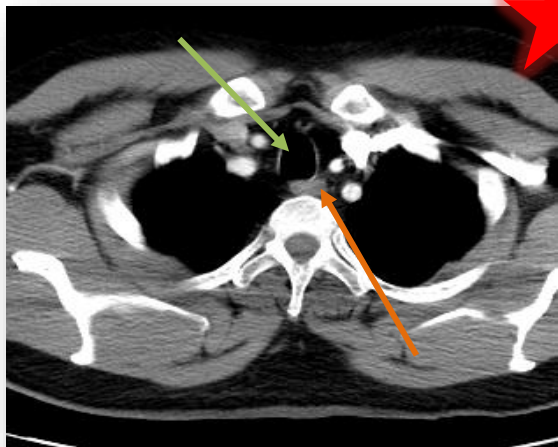
IMPORTANT



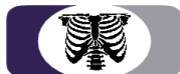1. Esophageal vestibule (ampulla).
2. B ring.
3. Gastroesophageal junction.
4. Stomach (gastric fundus).



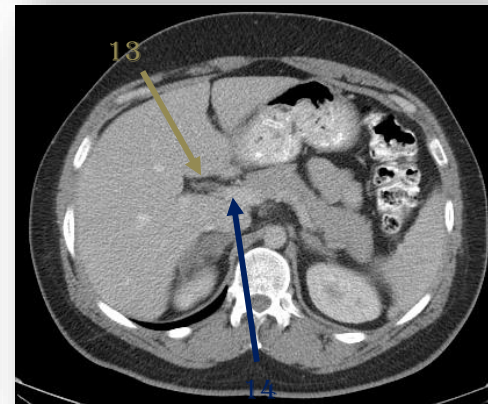
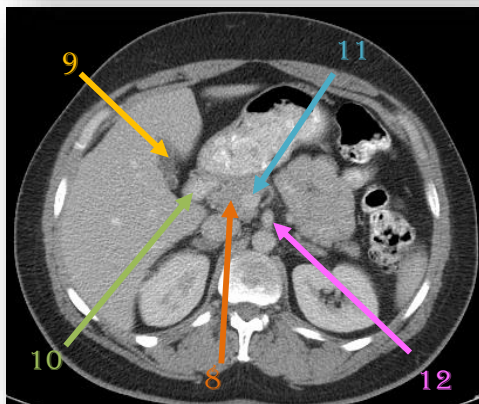
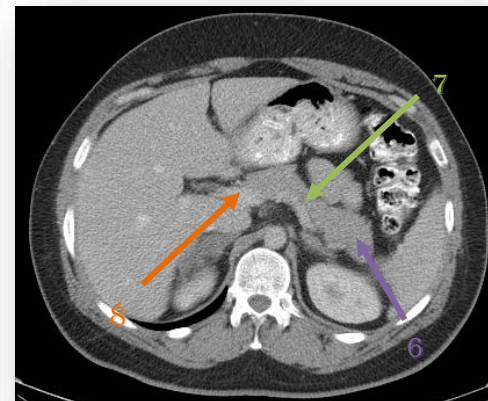
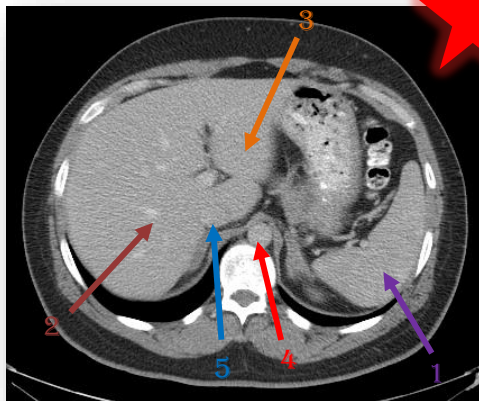
1. Liver.
2. spleen.
3. R & L kidney.
4. R & L psoas muscle.

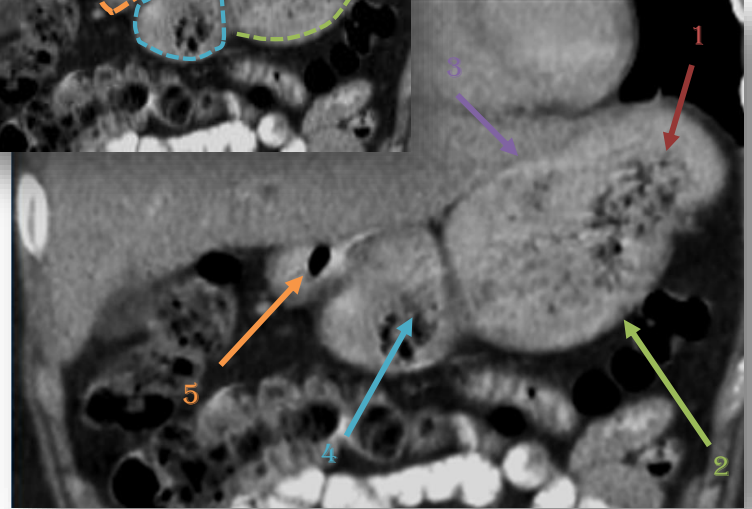
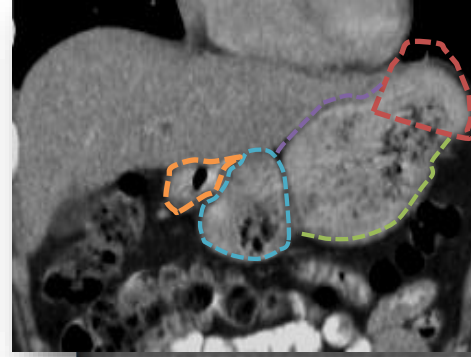
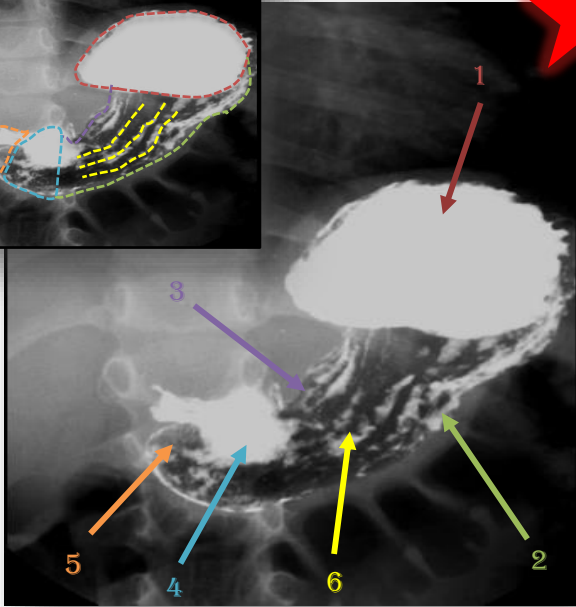
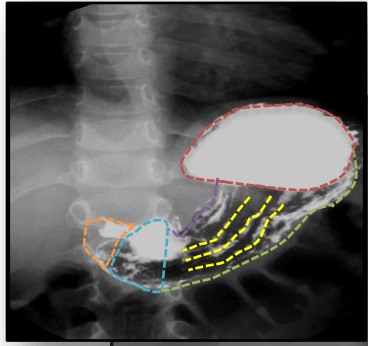


1. Esophagus.
2. Trachea.
3. Aorta.
4. Lung.
5. Pulmonary artery.

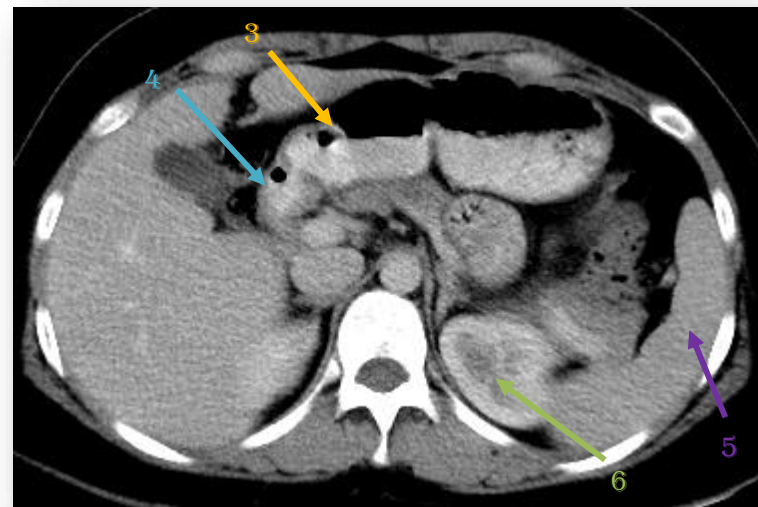
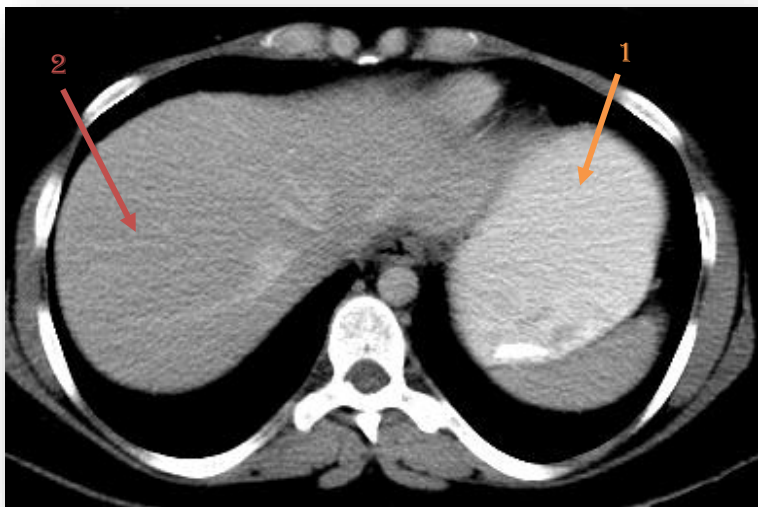


1. Spleen.
2. R liver lobe.
3. L liver lobe.
4. Abdominal aorta.
5. Inferior vena cava.
6. Pancreatic tail.
7. Pancreatic body.
8. Pancreatic head.
9. Gallbladder.
10. Duodenum.
11. Superior mesenteric Vein (SMV).
12. Superior mesenteric Artery (SMA).
13. Common bile duct (CBD).
14. Portal vein (PV).

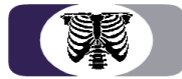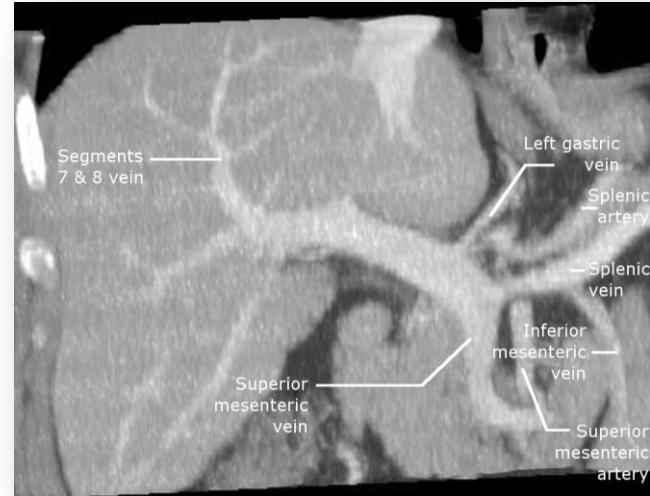
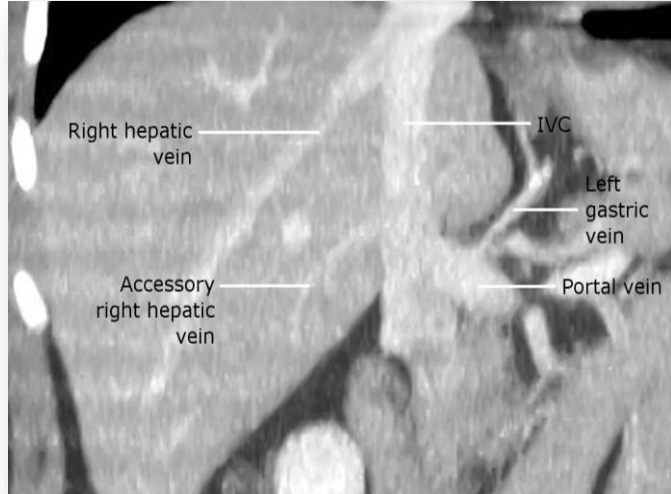



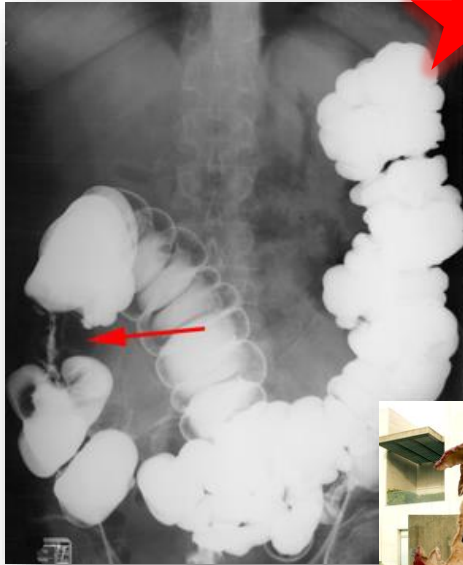
1. **Stomach fundus.**
2. **Greater curvature.**
3. **Lesser curvature.**
4. **Antrum.**
5. **Pylorus.**
6. **Mucosal folds.**

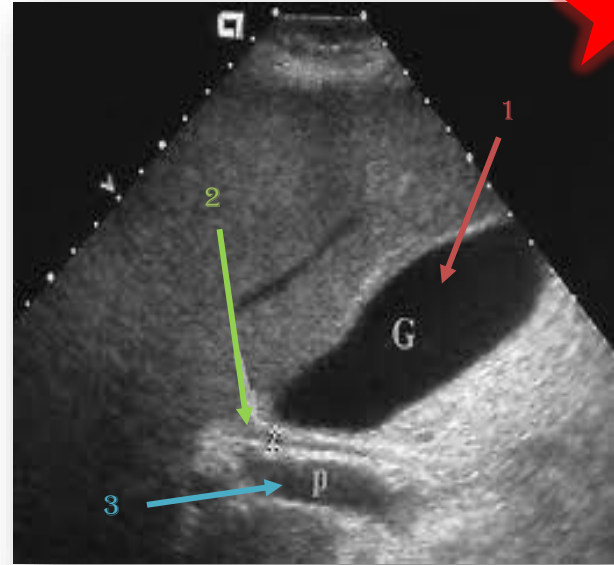


1. Stomach.
2. Liver.
3. Antrum.
4. Pylorus.
5. Spleen.
6. Kidney .





Colon Cancer (apple core sign)



- 1. Gallbladder.
- 2. Common bile duct.
- 3. Portal vein.

Thanks for checking our team!

For any suggestions or questions please don't hesitate to contact us on:

Email: radiology435team@gmail.com

Twitter: [@radiology_435](https://twitter.com/radiology_435)

Team members :

- **Abdullah Aljunaydil.**
- **Monirah Alsalouli.**
- **Lamia Alsaghan.**

