

# Radiological Anatomy of the Adrenal Gland

Radiology  
(Practical)

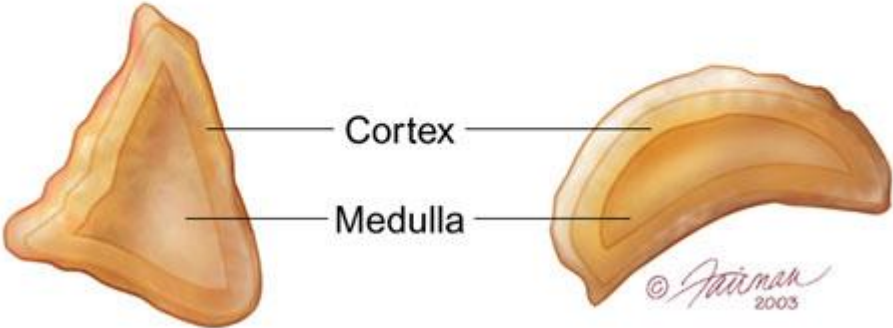
- **Main Objective:**

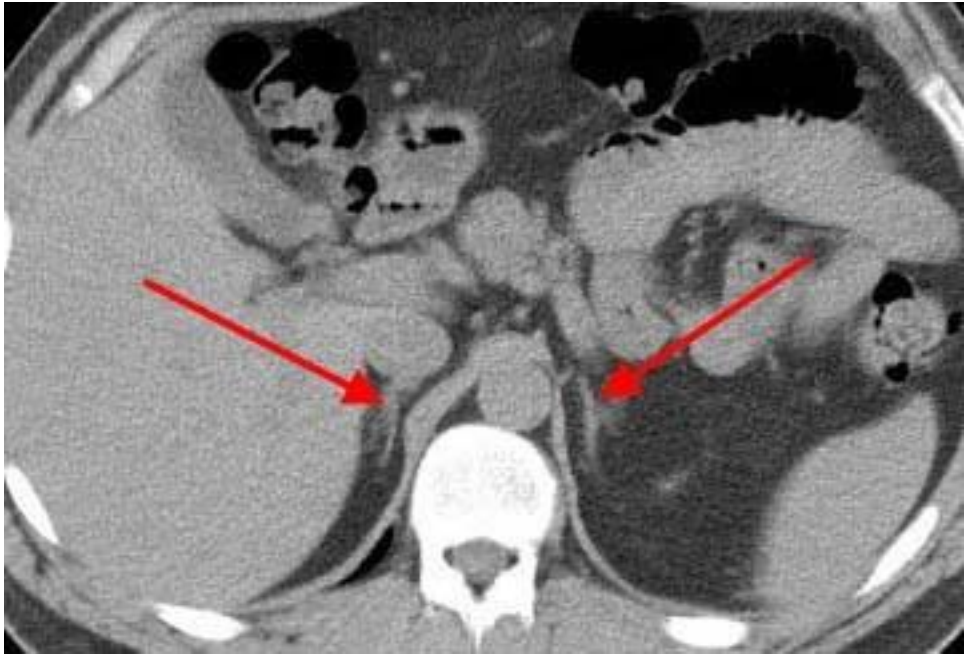Know the anatomy of adrenal gland in real person through medical imaging (Radiology), and correlated with gross sectional anatomy.

- US.
- CT.
- MR.

Right adrenal gland

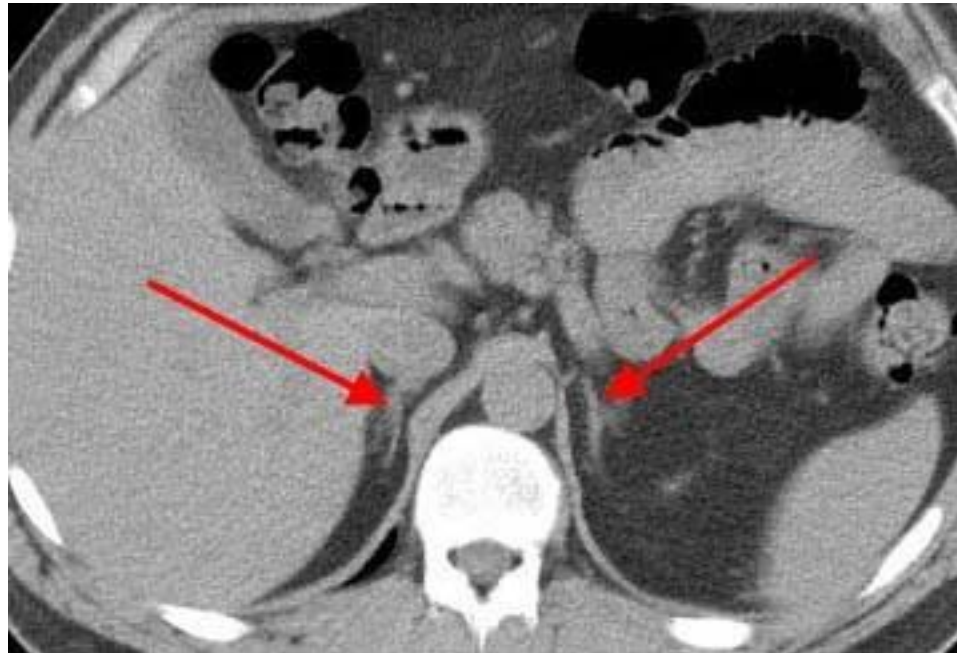Left adrenal gland





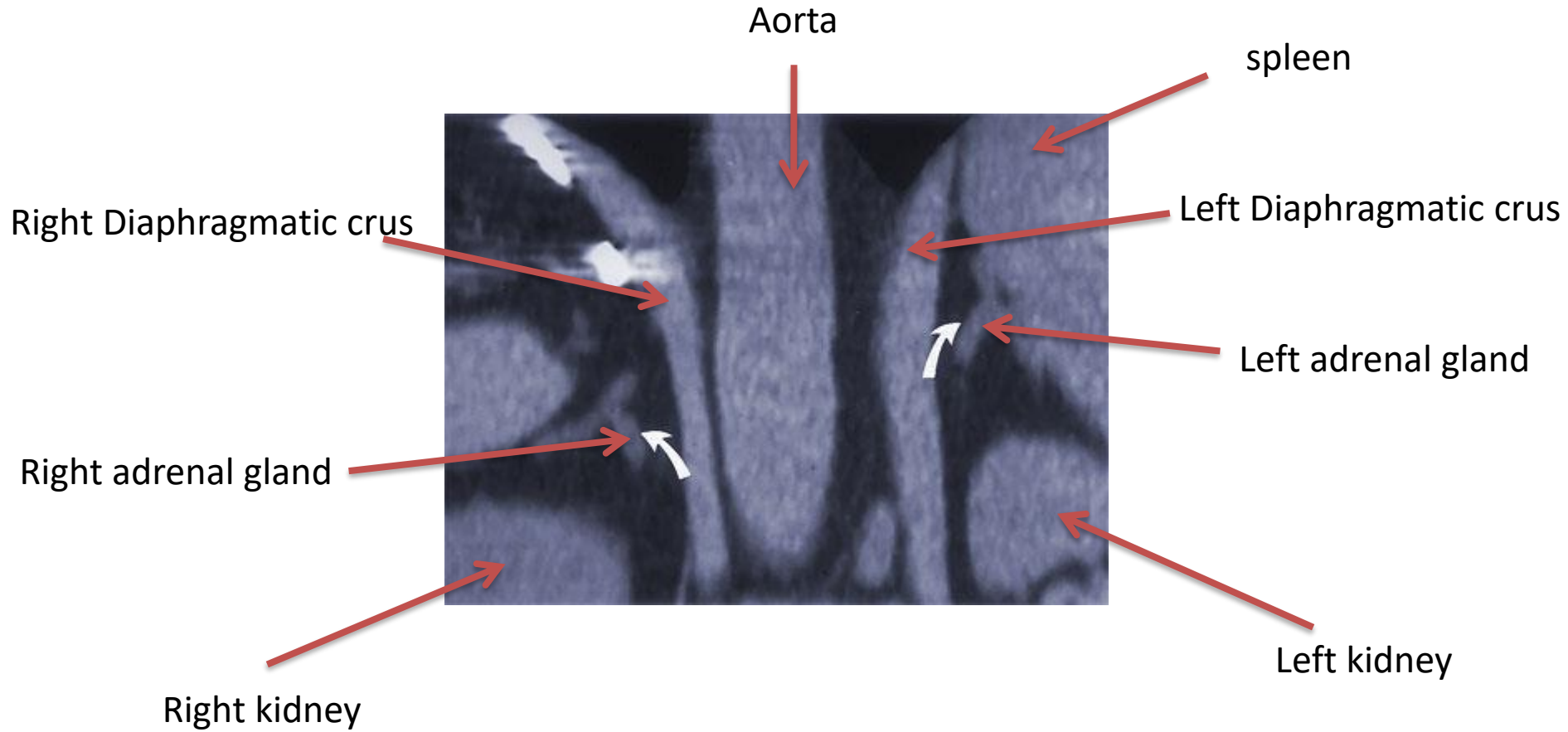# Axial CT Scan

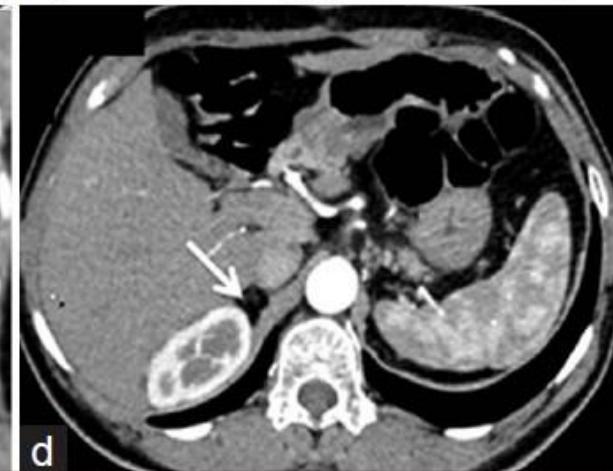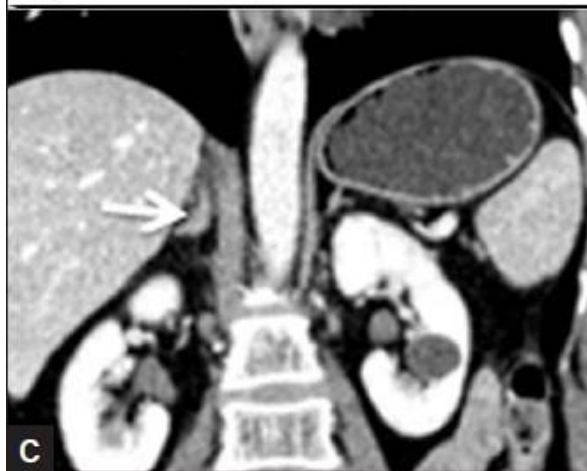
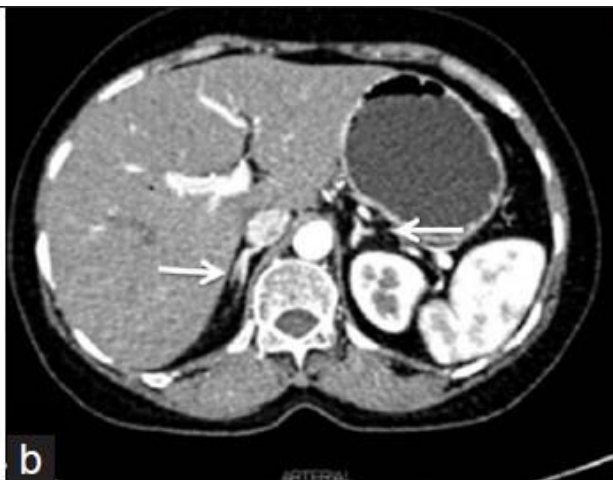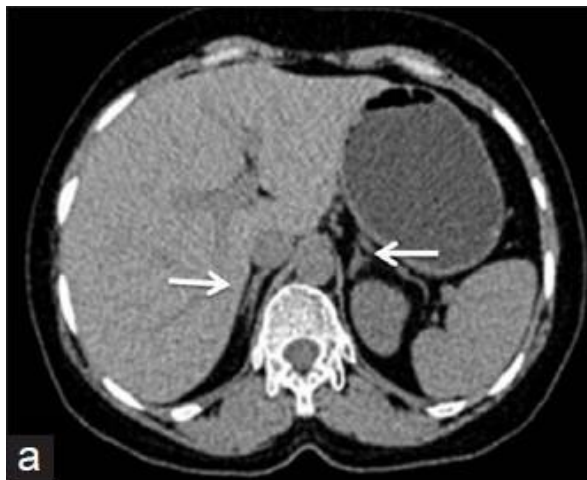Right adrenal



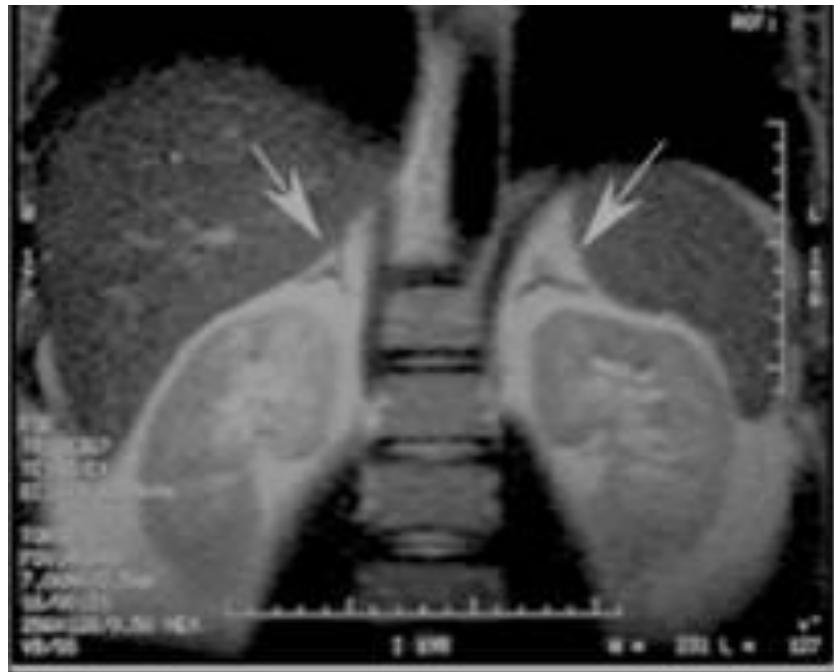Left adrenal

# Coronal CT Scan



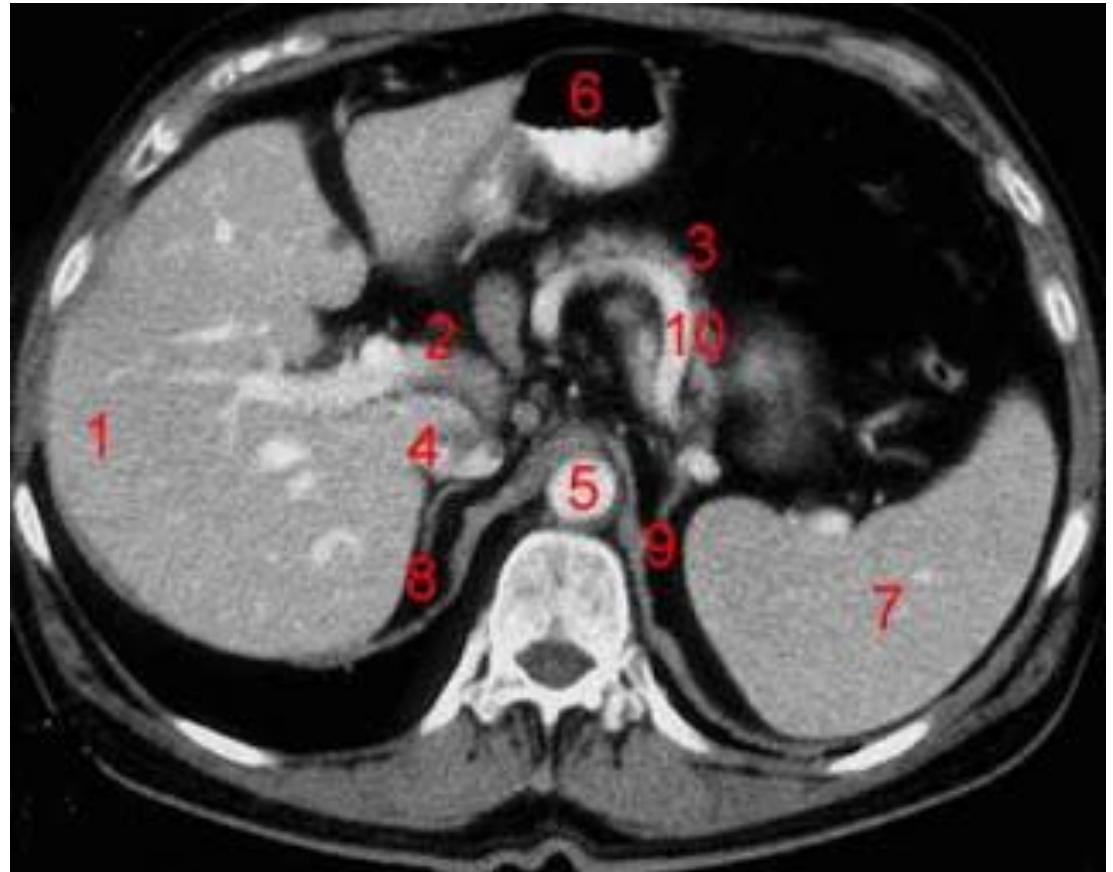






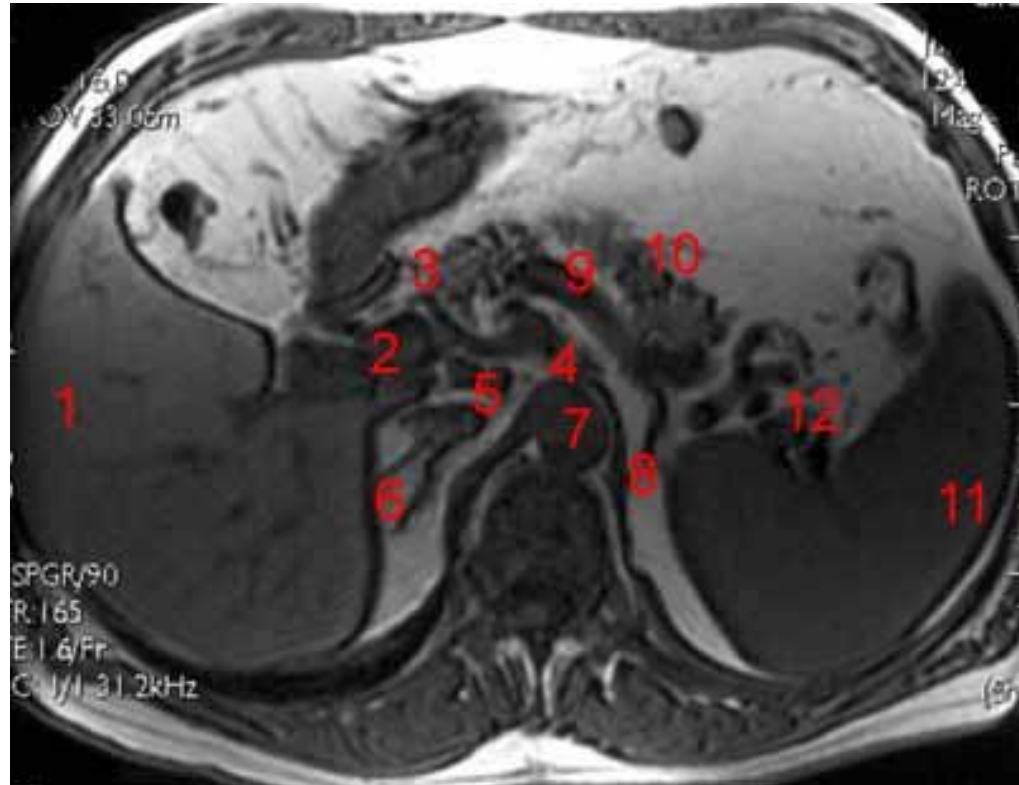
# Axial CT of abdomen

1. Liver
2. Portal Vein
3. Pancreas
4. Inferior Vena Cava
5. Abdominal Aorta
6. Stomach
7. Spleen
8. Right Adrenal
9. Left Adrenal
10. Splenic artery

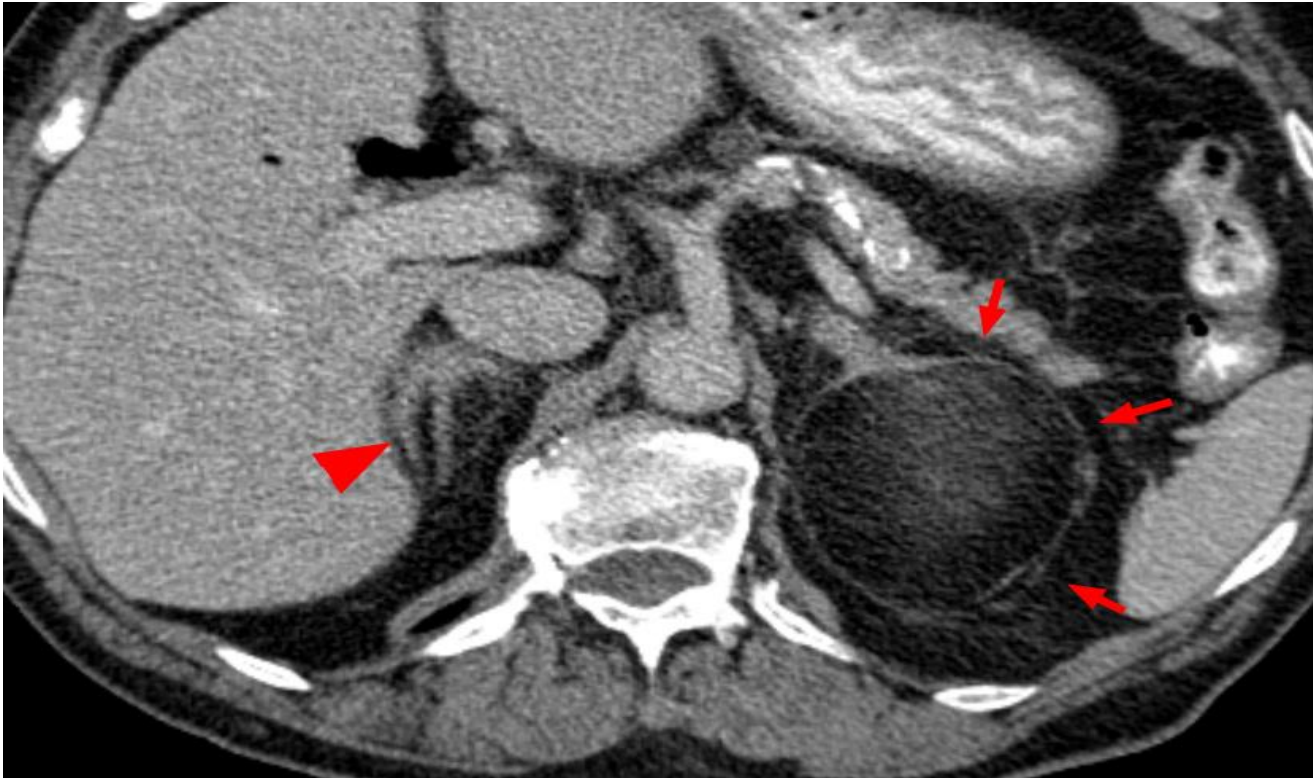

# Axial MRI of abdomen

- 1- Liver**
- 2- portal vein.**
- 3- head of pancreas**
- 4- celiac artery**
- 5- Inferior Vena Cava**
- 6- Right Adrenal**
- 7- Abdominal Aorta**
- 8- Left Adrenal**
- 9- splenic artery**
- 10- body of pancreas**
- 11- Spleen**



# ***Pathology of the adrenal gland***



***Lipoma of the left adrenal gland***