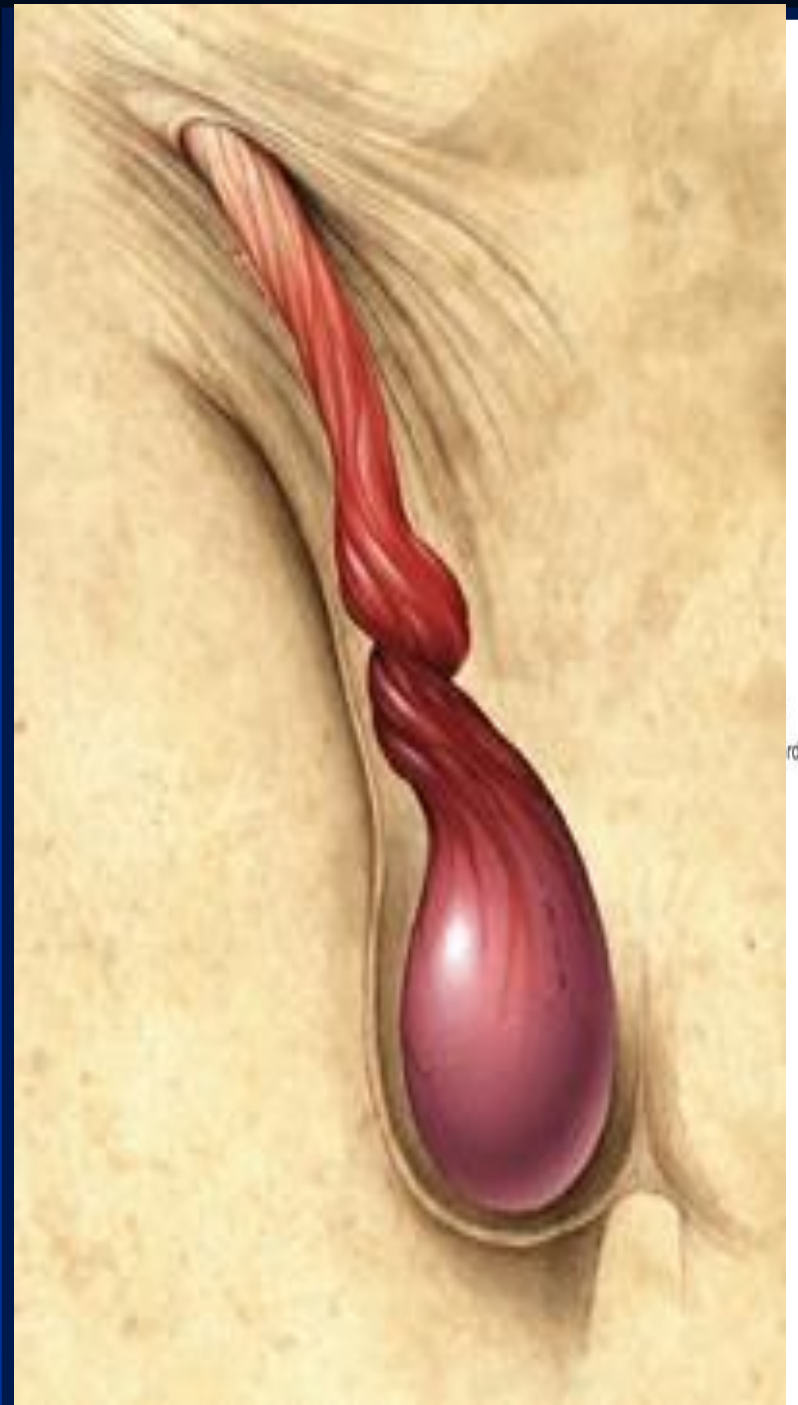

MALE REPRODUCTIVE SYSTEM



OBJECTIVES

- By the end of the lecture, students should be able to:
- List the different components of the male reproductive system.
- Describe the anatomy of the primary & the secondary sex organs regarding (location, function, structure, blood supply & lymph drainage).
- Describe the anatomy of the male external genital organs.

Components of Male Reproductive System

I- Primary Sex Organ:

- *Testis.*

II- Reproductive Conducting Tract:

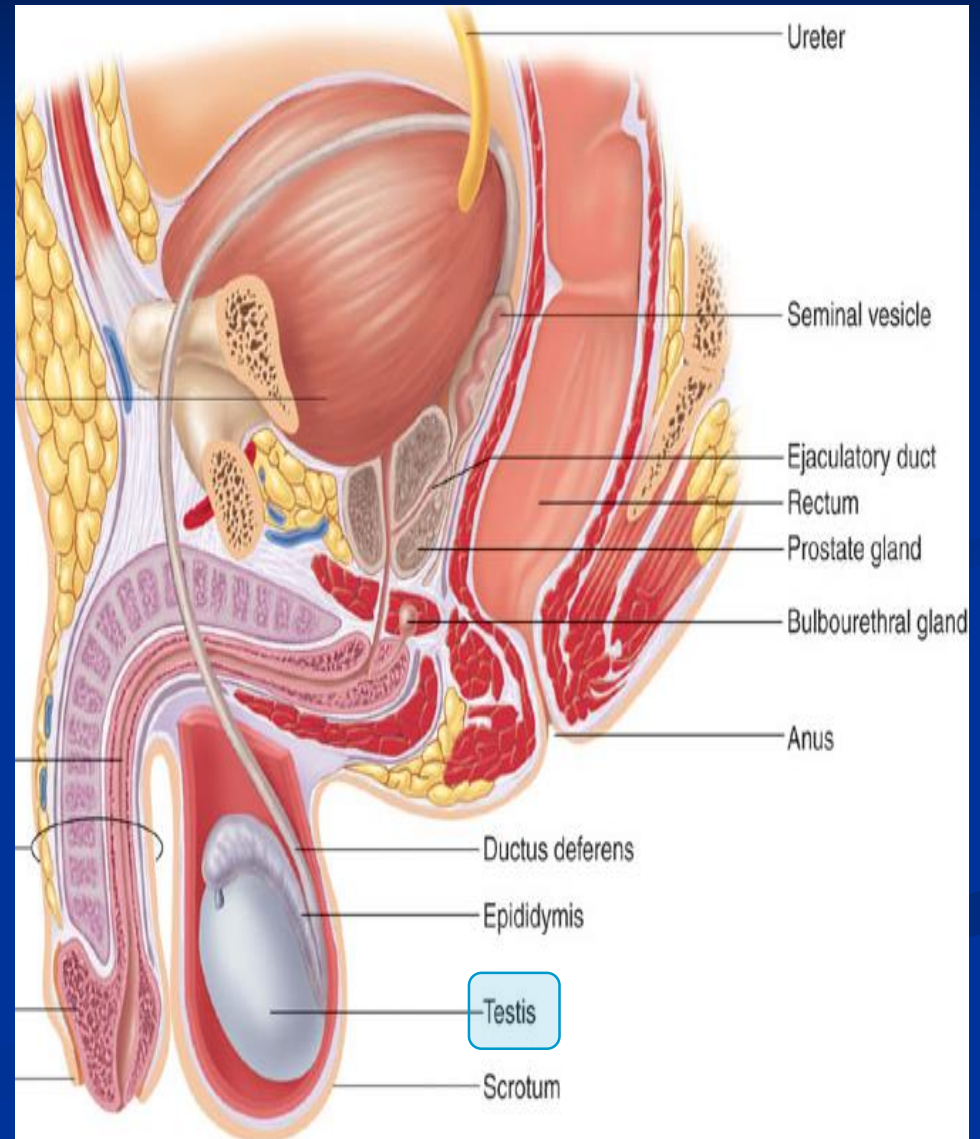
- *Epididymis.*
- *Vas Deferens.*
- *Spermatic cord.*

III- Accessory Sex Glands:

- *Seminal vesicles.*
- *Prostate gland.*
- *Bulbourethral glands.*

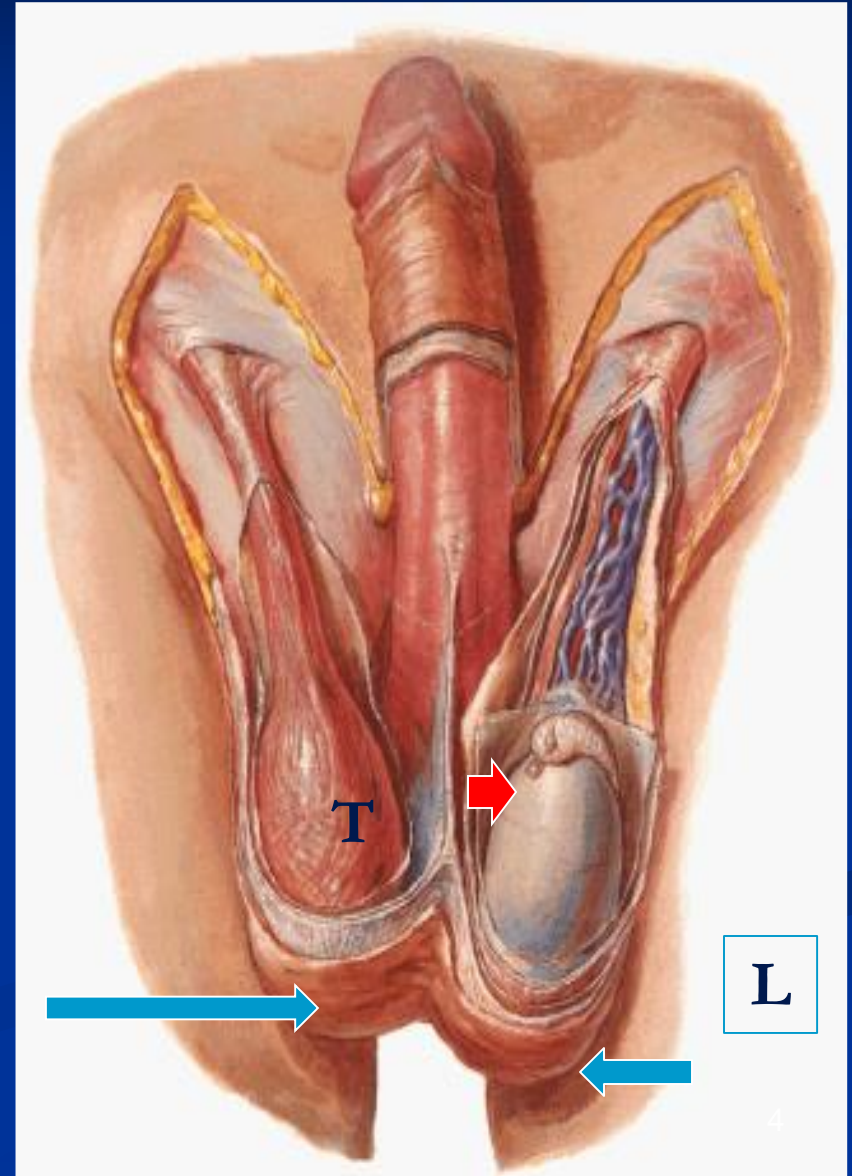
IV- External genitalia:

- *Penis*



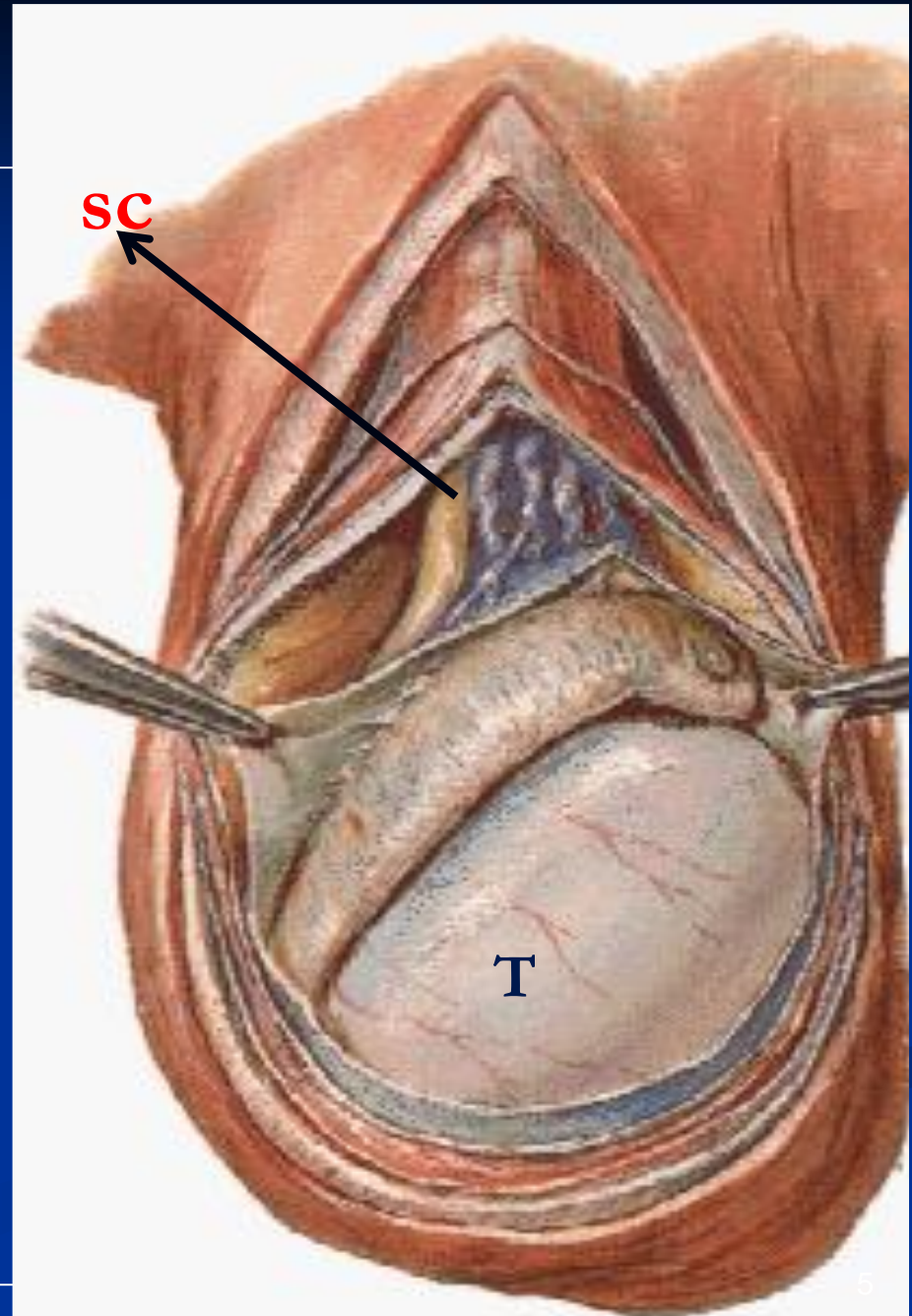
Scrotum

- An out pouching of loose skin & superficial fascia.
The Left scrotum is lower than the right.
- **Functions:**
 - Houses & Protects the testis
 - It has thin skin with sparse hairs and sweat glands.
 - It Regulates testicular temperature (no superficial fat)
 - The Dartos muscle lies within the superficial fascia.
 - & replaces **Scarpa's** fascia



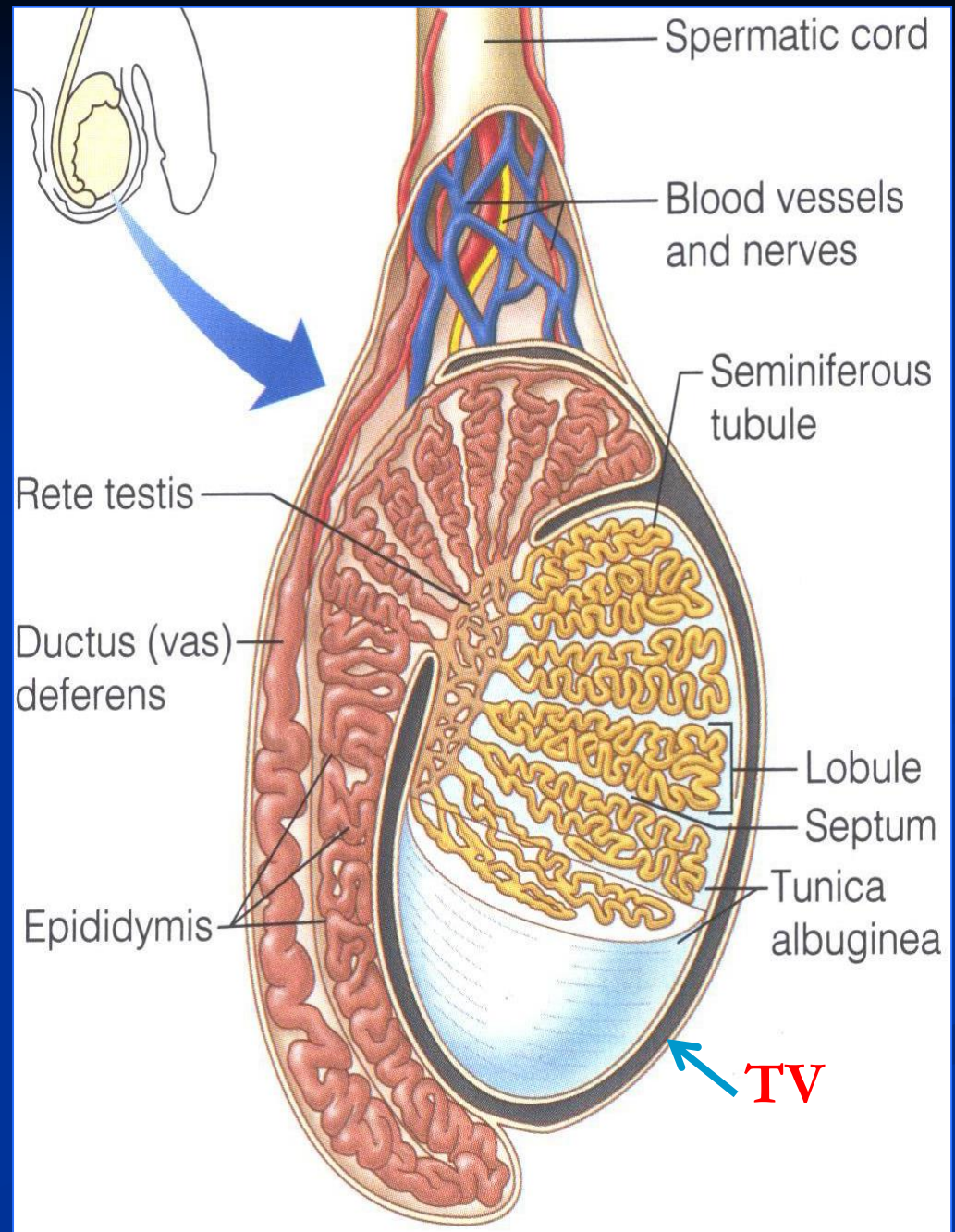
Testis

- Testis or Testicle (singular), Testes (plural).
- Paired almond-shape gonads that suspended in the scrotum by *the spermatic cord*
- 4 - 5 cm long
- Weigh (10.5 – 14) g
- Its volume is about 20-25 ml
- Functions:
 - Spermatogenesis.
 - Hormone production
 - (Androgens- testosterone).



Coverings of the Testis

- Tunica Vaginalis:
- A Peritoneal covering, formed of parietal and visceral layers.
- It surrounds testis & epididymis.
- It allows free movement of testis inside scrotum.
- Tunica albugenia
- It is a whitish fibrous capsule



Internal Structure of Testis

Fibrous septae extend from the capsule, divide the testis into a (200-300) **lobules**.

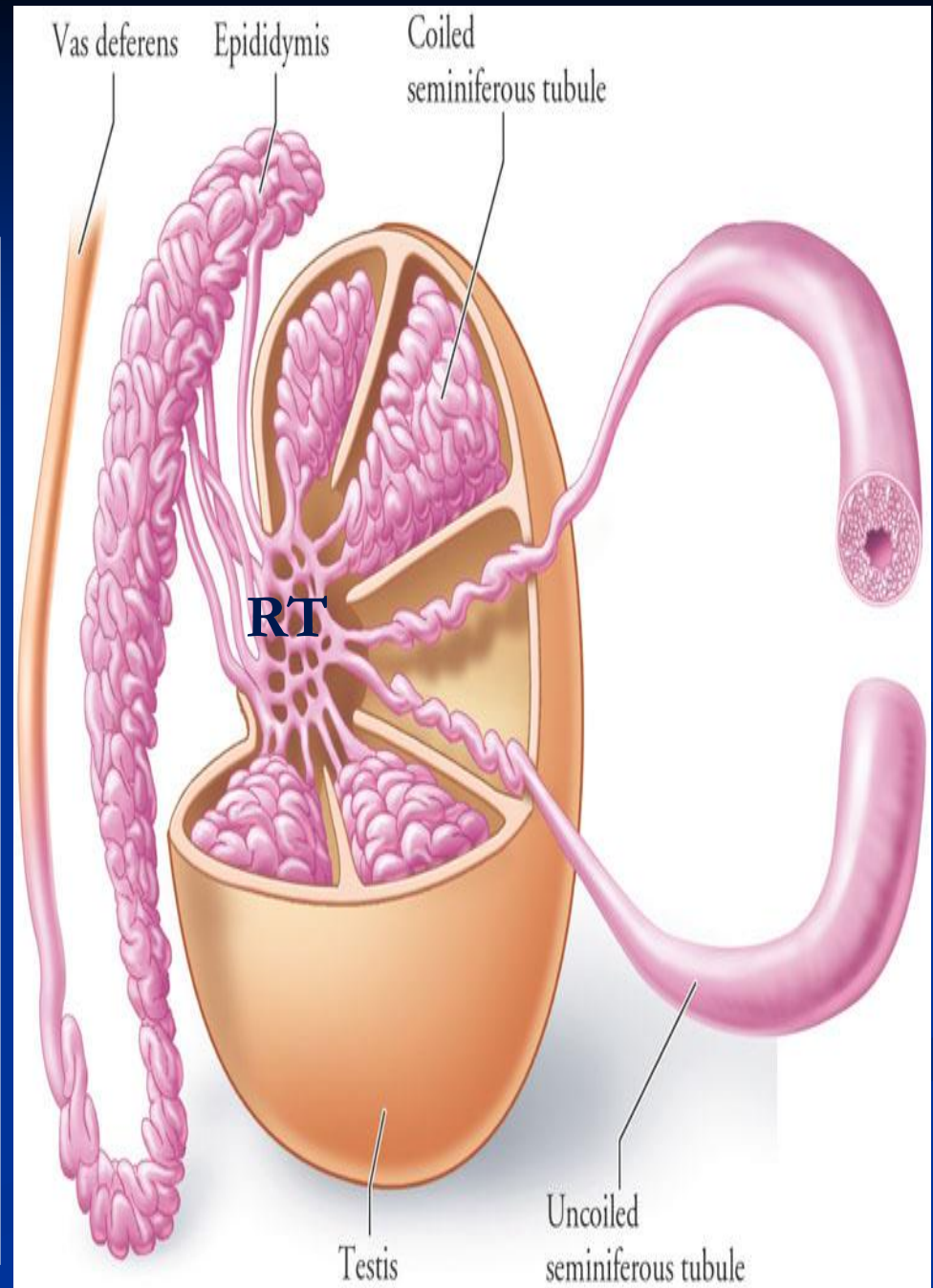
Each lobule contains, (1-3) **seminiferous tubules**.

▪ Seminiferous Tubules:

- They are the site of the spermatogenesis.
- They form the bulk of testicular tissue.

▪ Rete testis:

- *(a network of tubules)*
- *It is the Site of merging of the Seminiferous tubules.*



Blood Supply of Testis

Testicular artery:

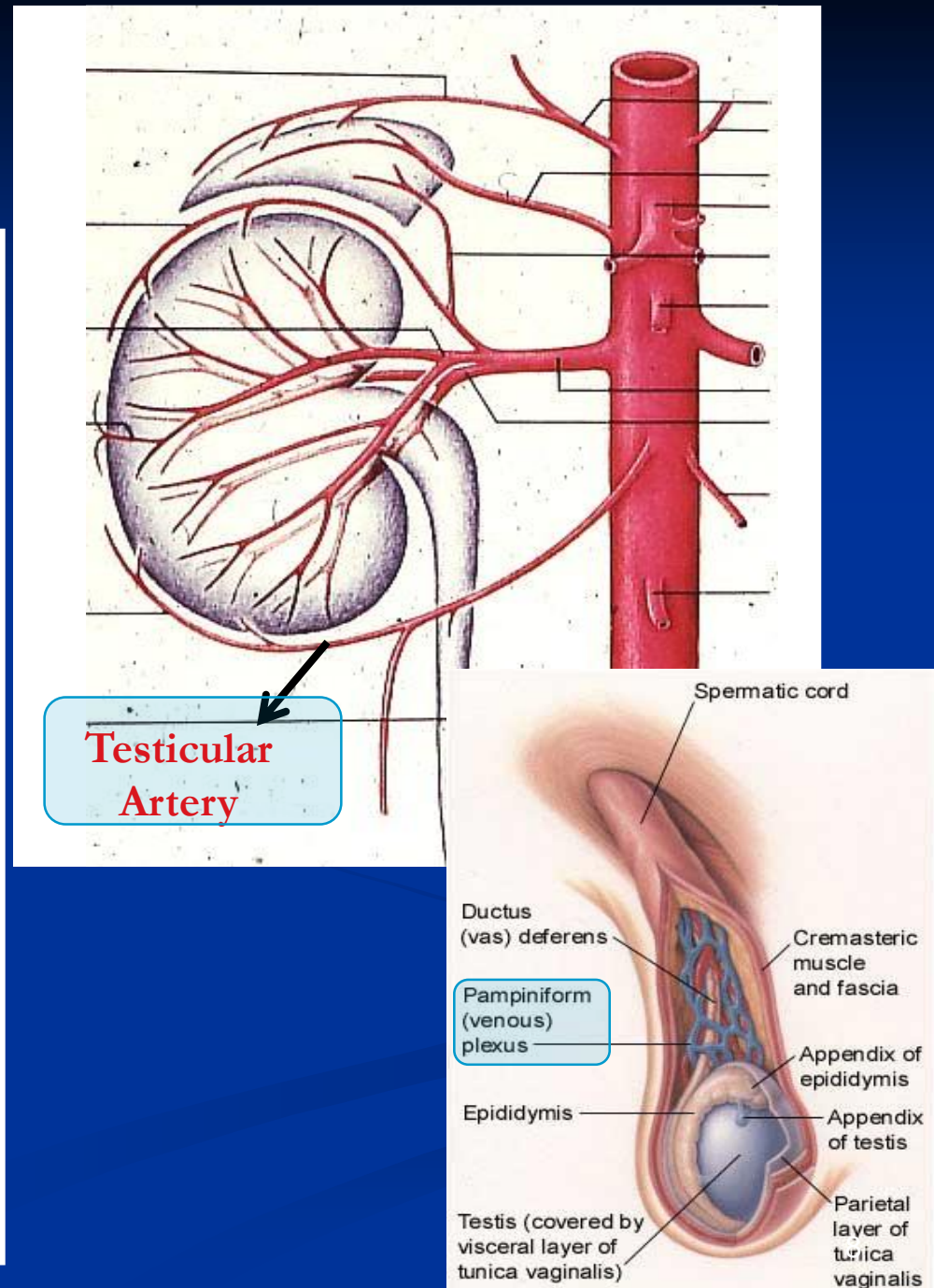
It is a direct branch from the abdominal aorta.

Venous drainage :

(Pampiniform plexus of veins.

Approximately a dozen veins which forms a network in the spermatic cord.

- They become larger, converge as it approached the inguinal canal and form the **Testicular vein**.
- **Right Vein drains into IVC.**
- **Left Vein drains into Left Renal Vein.**



Testicular Lymphatics:

Follow arteries, veins

End in **Lumbar (par aortic) nodes**

From scrotum, penis, prepuce:

Terminate in **Superficial
Inguinal nodes**

Indication

Evaluation of testicular pain. (Testicular Torsion)

Technique

Examiner strokes or pinches upper medial thigh causes cremasteric muscle contraction

Observe for rise of the Testicle on same side (normal)

Interpretation

Normal:

It is present with Epididymitis

If Cremasteric reflex **absent** (no Testicle rise):

It is Suggestive of Testicular Torsion

Also absent in 50% of boys under age 30 months

Do not use this test under age 30 months

Efficacy.

Test Sensitivity for Testicular Torsion: 99%

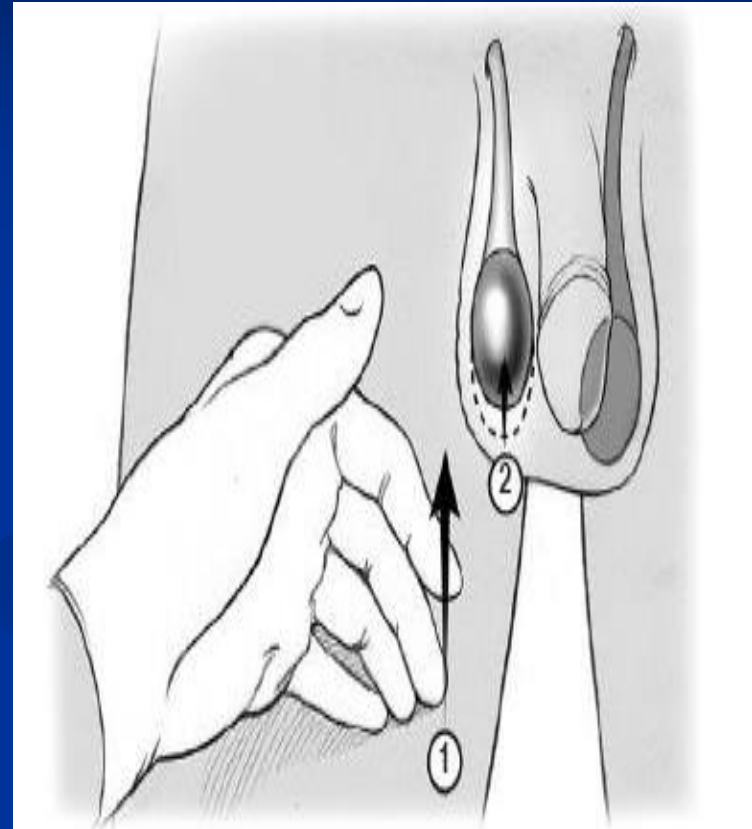
Assumes age over 30 months

Nerve involved: Genitofemoral nerve (GFN), (L1,2)

Sensory: femoral branch of (GFN) & Ilioinguinal N.

Motor: genital branch of (GFN).

Cremasteric reflex



The reflex is elicited by (1) stroking the ipsilateral inner thigh with a tongue depressor or gloved hand, resulting in (2) the elevation of the testicle through contraction of the cremasteric muscle.

Epididymis

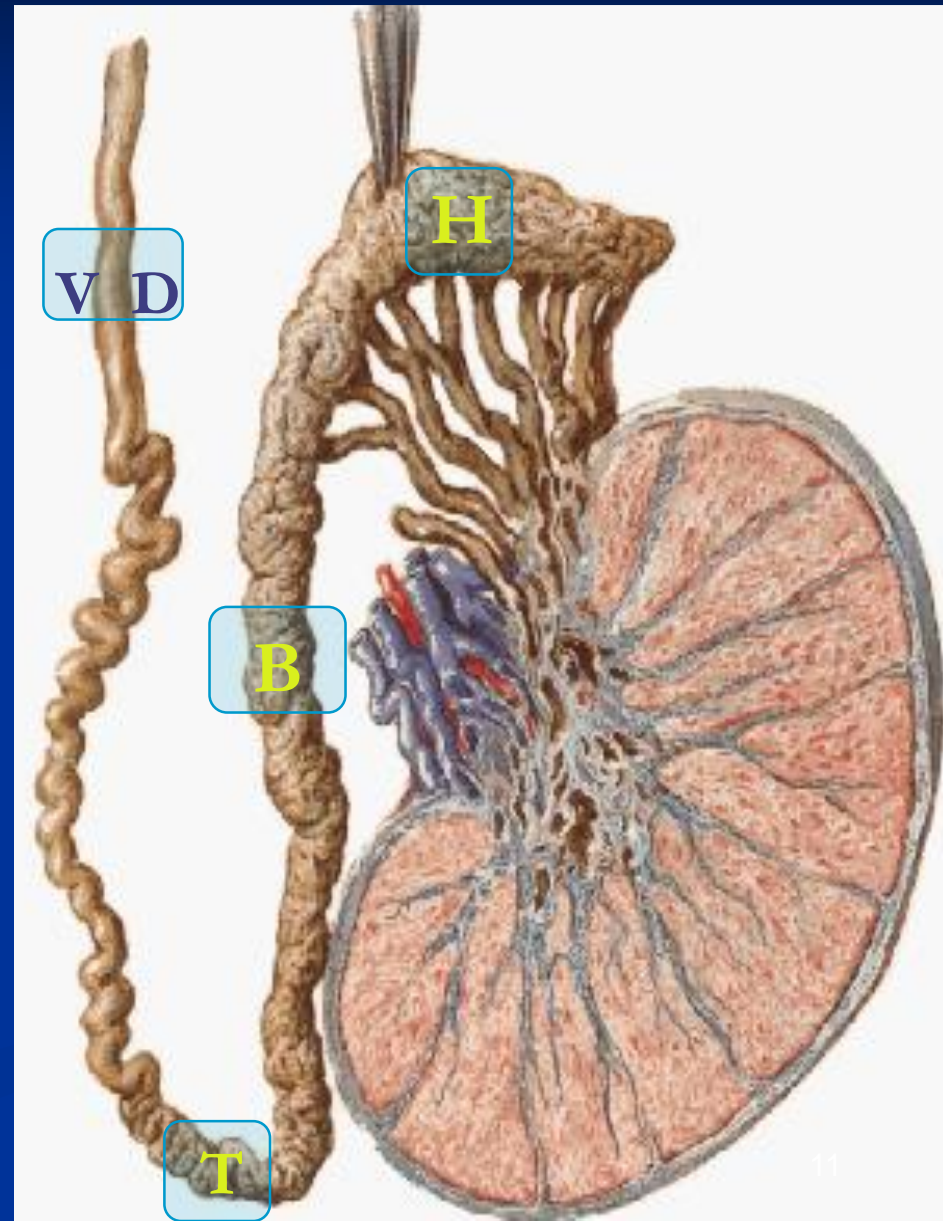
- A Single coiled tubule
 - 6 M long
 - Located on the posterior & superior margins of the testis.
 - It is divided into:
Head, Body and Tail.

The **Head** receives efferent ductules from testis.

▪ The **Tail** is continuous with **Vas Deferens**

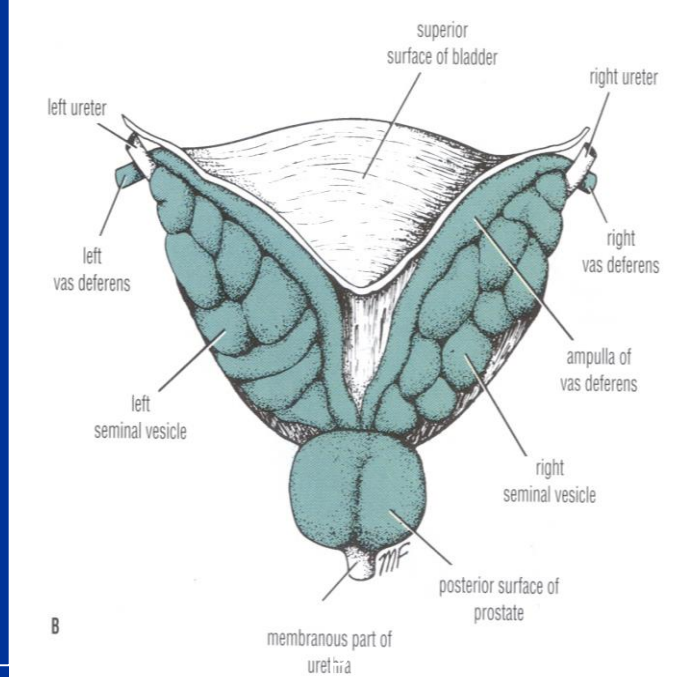
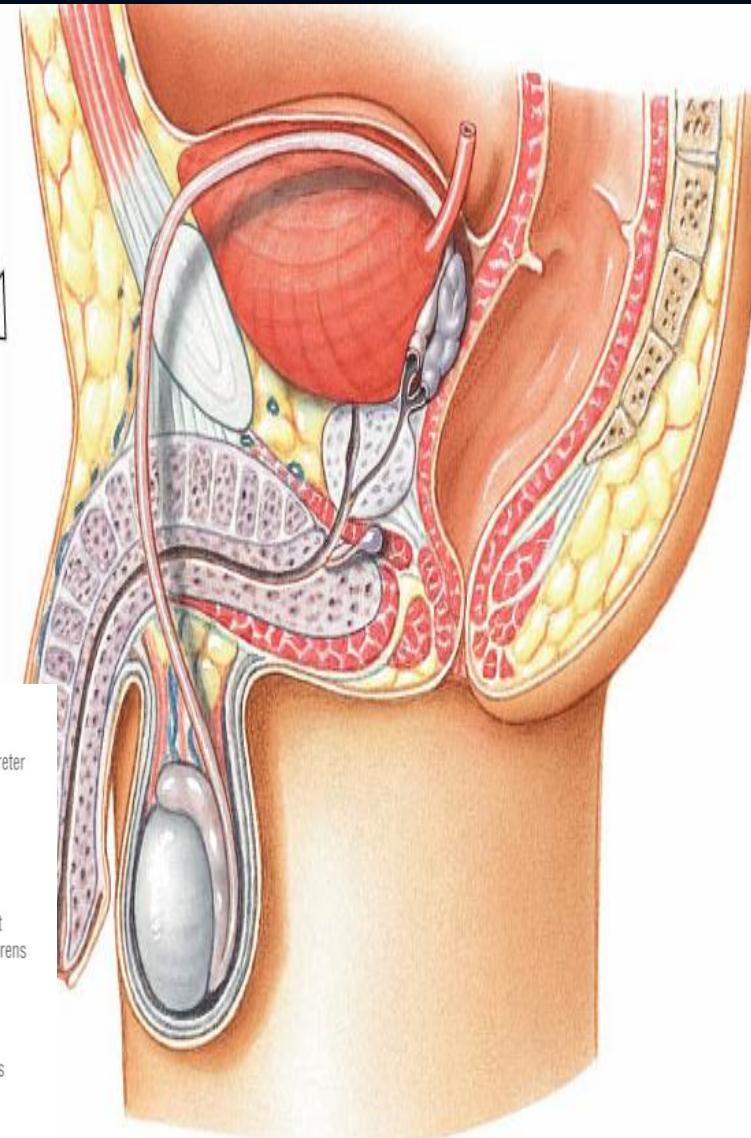
▪ Functions:

1. Secretes/absorbs the nourishing fluid.
2. Recycles damaged spermatozoa.
3. Stores spermatozoa **Up to 2 weeks to allow for maturation.**



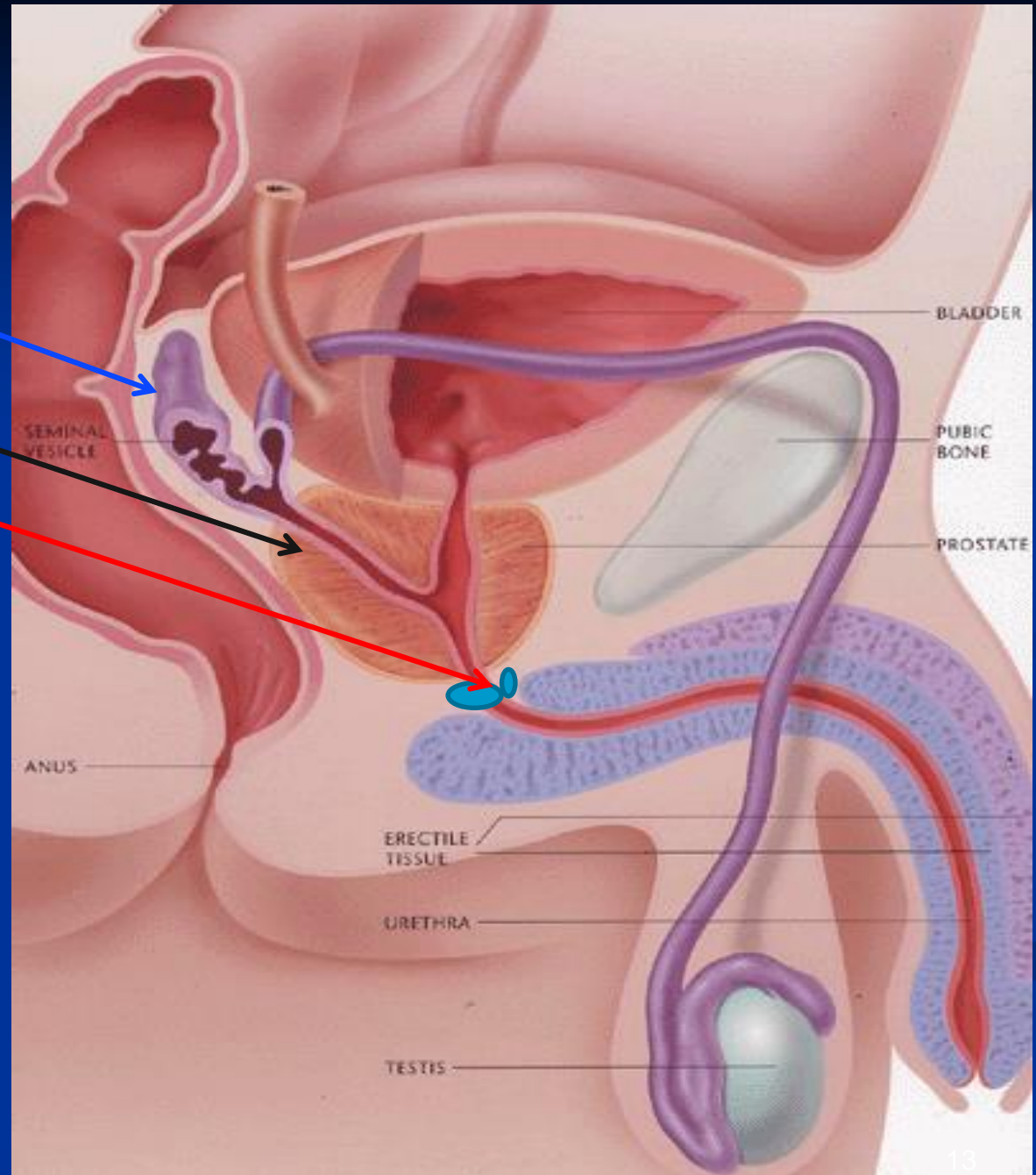
Vas Deferens

- A Muscular tube **45 cm** long.
- Carries sperms from the Epididymis to pelvic cavity.
- Passes through the inguinal canal
- It crosses the ureter
- Its terminal part is dilated to form the **Ampulla of the vas**
- It joins the urethra in the prostate



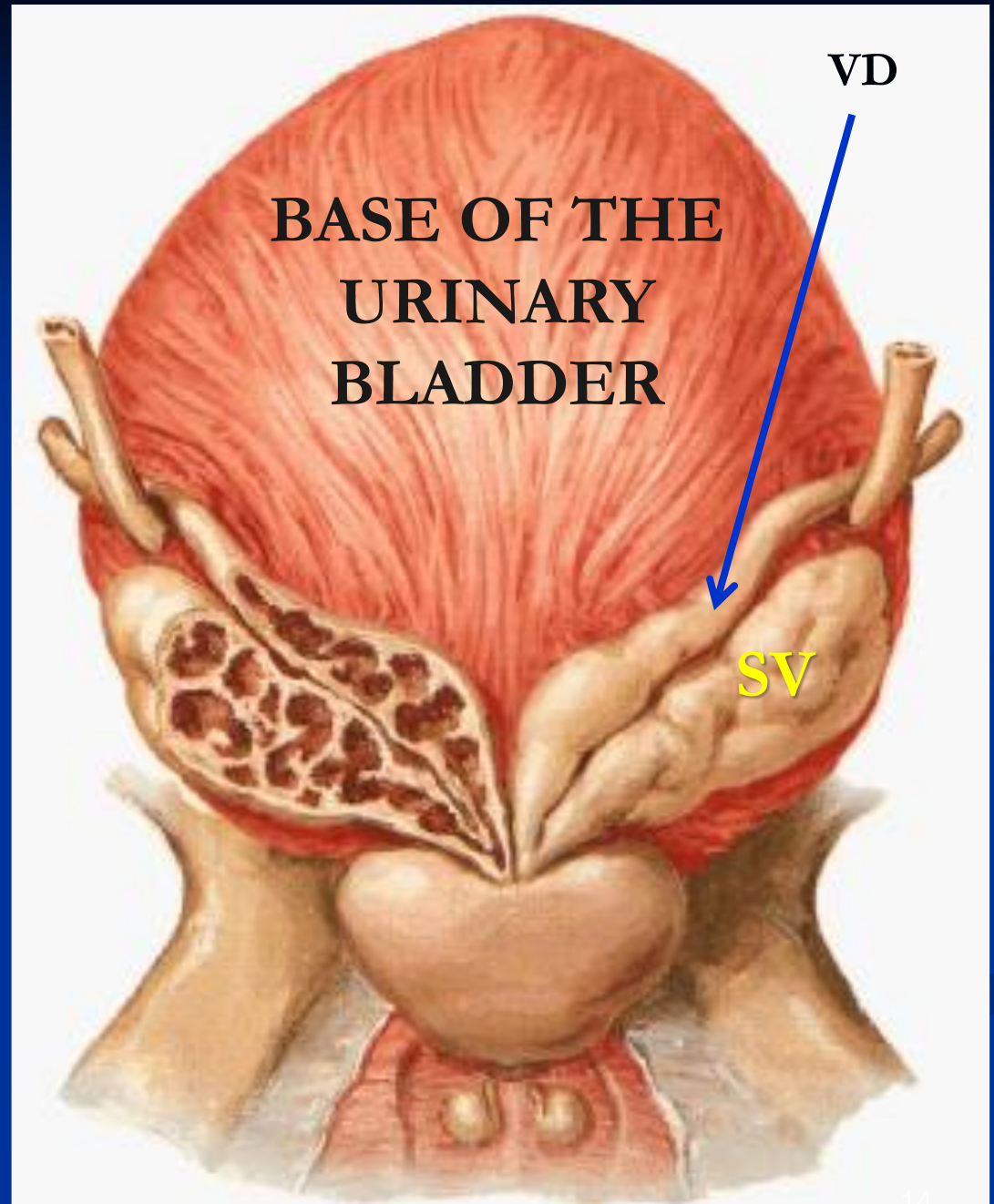
Accessory Glands

- Seminal vesicle.
- Prostate.
- Bulbourethral glands.
- **Functions:**
 1. Secretion of seminal fluid
 2. Nourishing, Activation & Protection of sperms



Seminal Vesicles

- Paired elongated glands.
- Located posterior & inferior to the urinary bladder
- Secrete (60% of Semen)



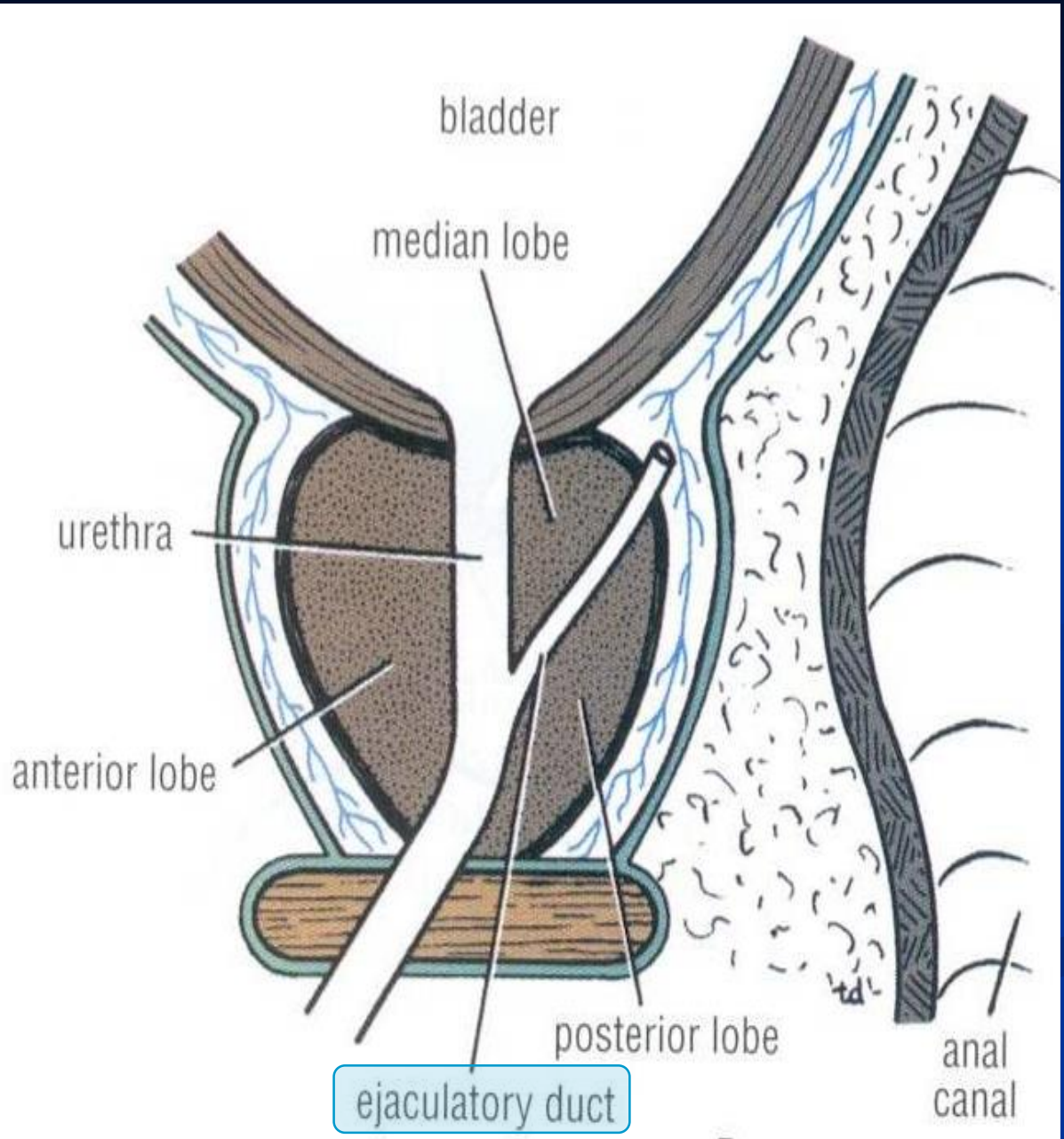
Ejaculatory Ducts

Formed by the union of the lower end of the vas deferens and the duct of the seminal vesicle.

Its length is about 1 inch (2.5) cm

The 2 ejaculatory ducts open into the prostatic urethra.

They drain the seminal fluid into the prostatic urethra.



Prostate Gland

The Largest male accessory gland.

Walnut sized.

Located at the neck of bladder

Houses prostatic urethra

Secretes (20-30% of semen)

Shape: Conical, It has:

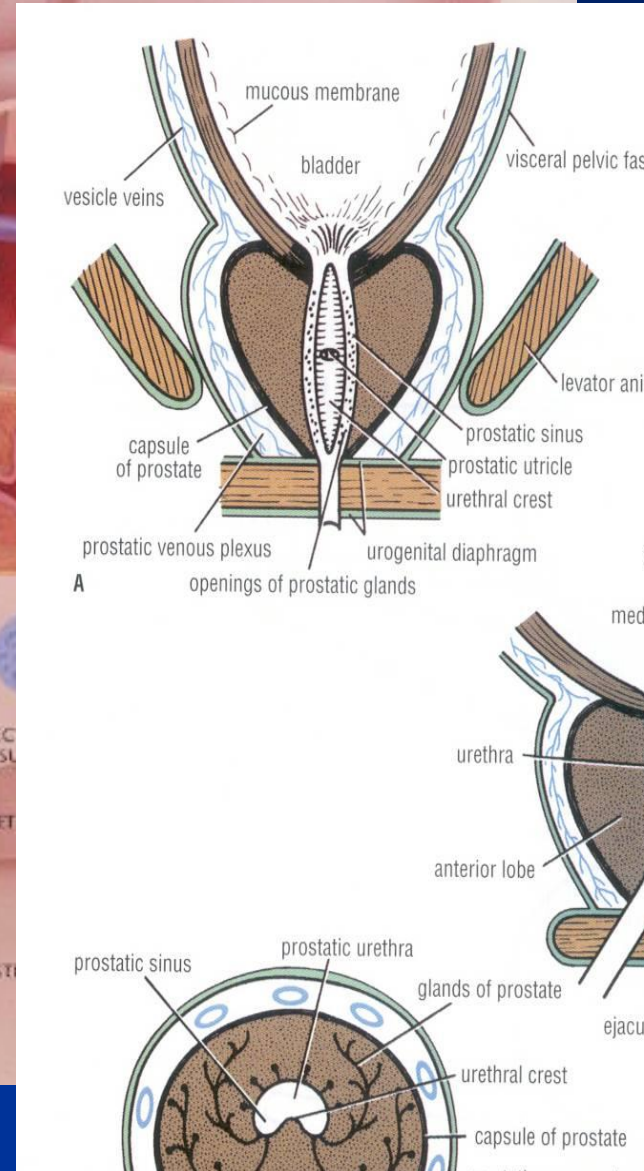
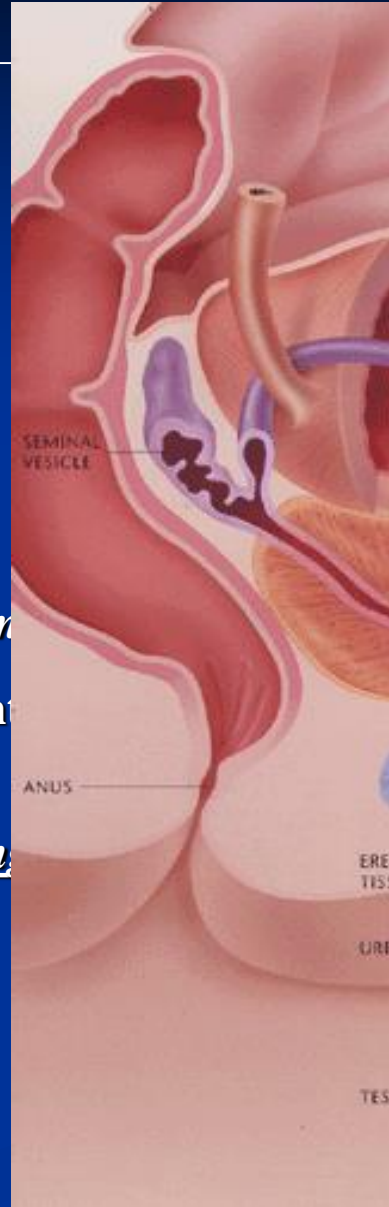
Base (Sup): Attached to neck of urinary bladder

Apex (Inferior): on Urogenital diaphragm

Four Surfaces: Posterior, Anterior, Right & Left.

It Secretes enzymes which has the following functions:

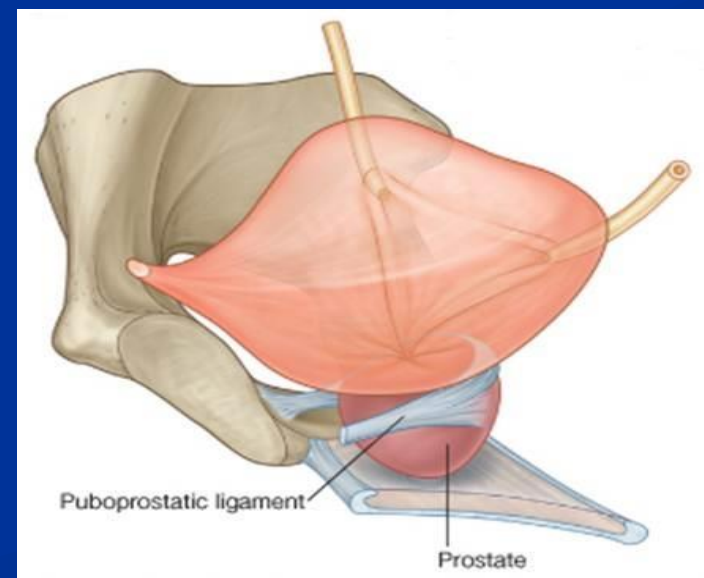
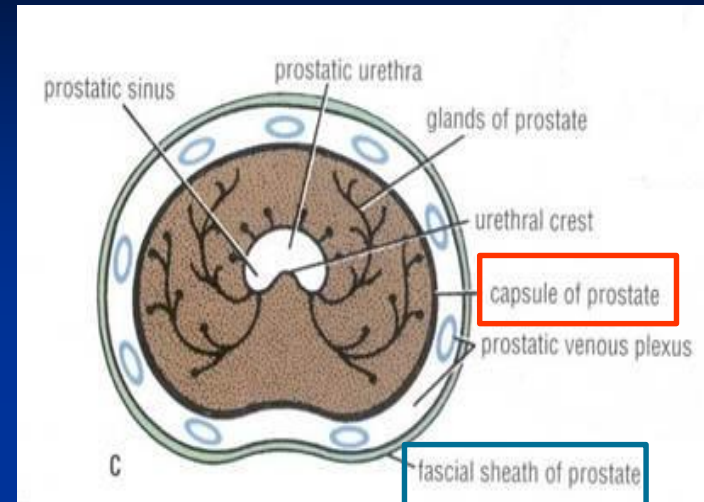
- Aids in activating sperm motility
- Mucus degradation
- Antibiotic
- Neutralizes Alkaline fluid of female reproductive tract



Capsule

Internally, it has a dense fibrous prostatic **Capsule**,

Externally, it is surrounded by a fibrous prostatic **Sheath** which is continuous with the puboprostatic ligaments (levator prostate).



Relations

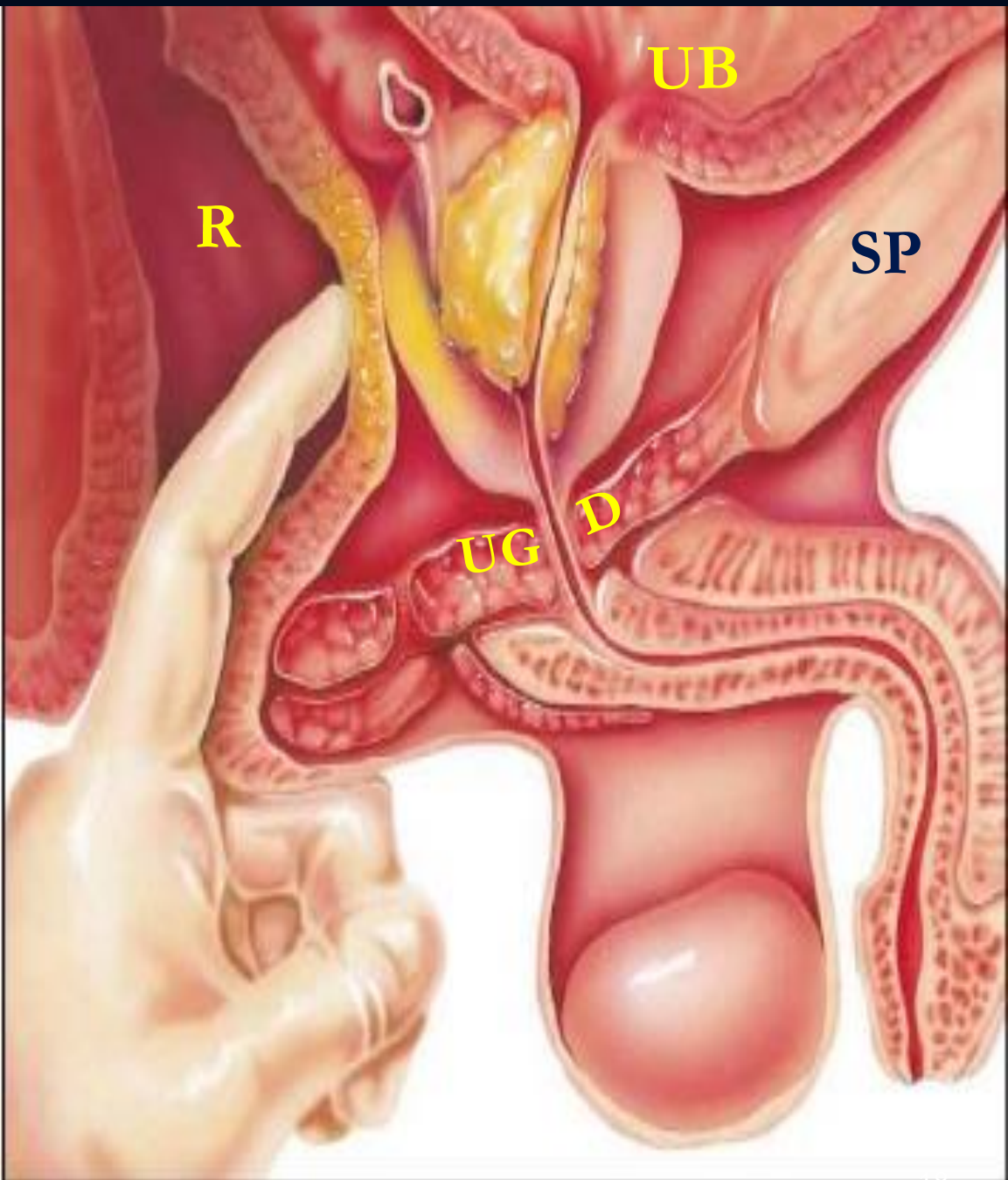
Anterior: Symphysis pubis (SP).

Superior : Neck of urinary bladder.

Posterior : Rectum ® (important for PR Examination)

Inferior: Urogenital diaphragm, (UGD).

Lateral: Medial margins of levator ani muscles (levator prostate)

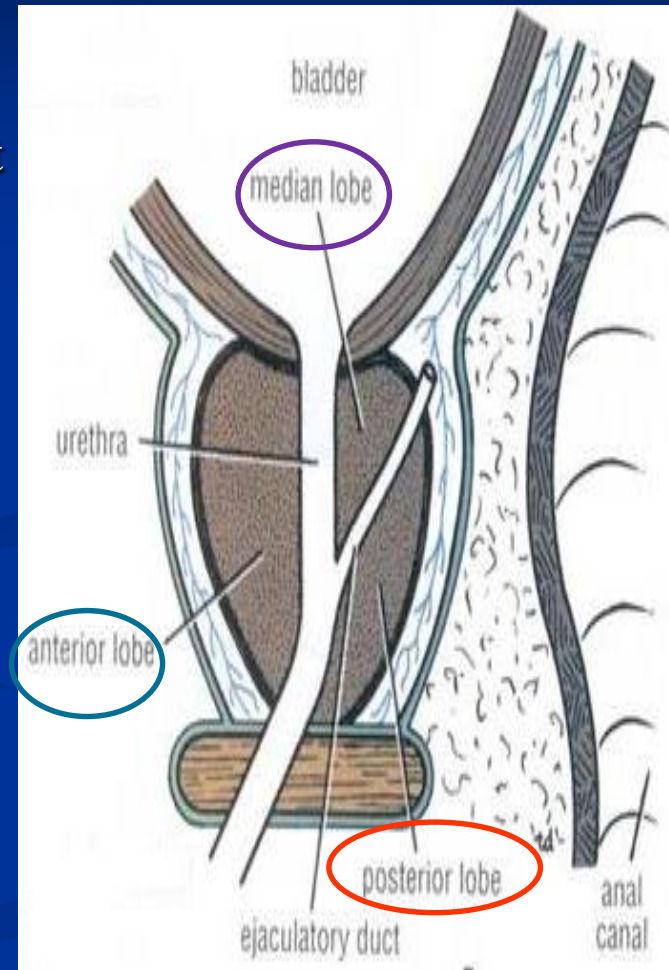


Lobes

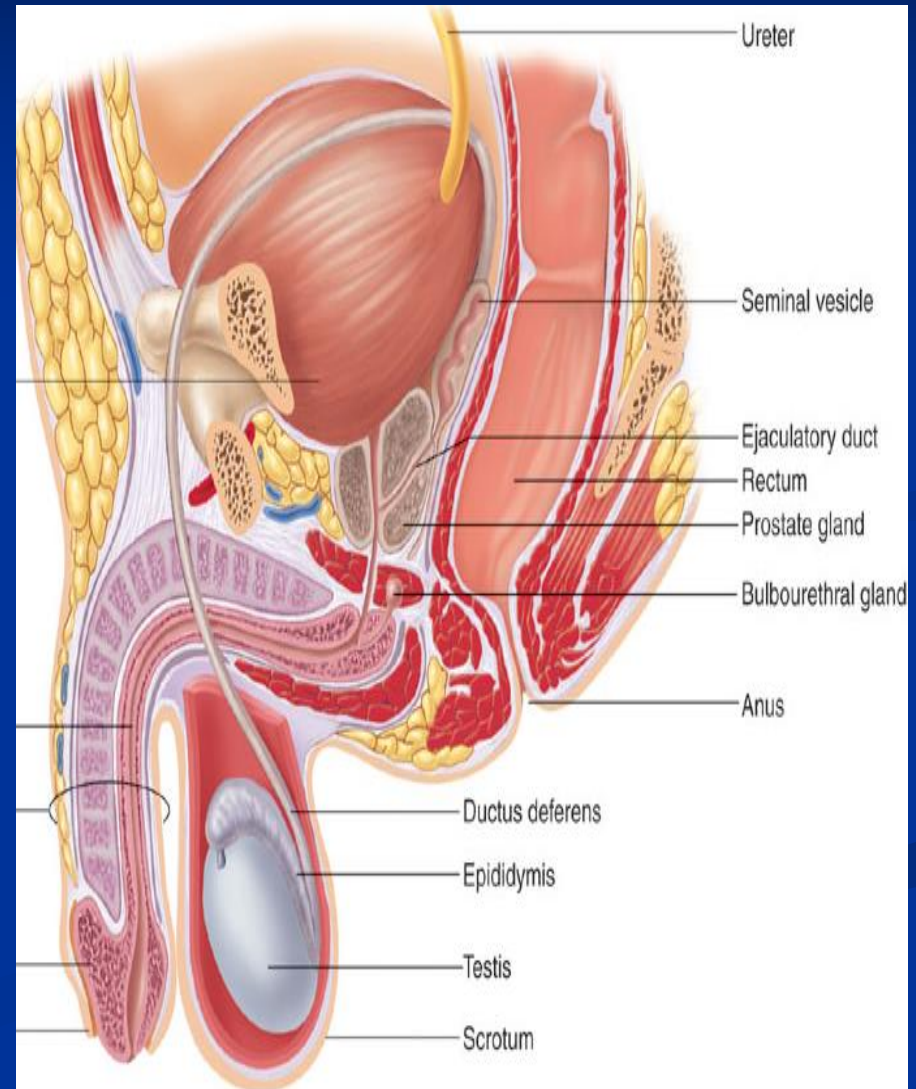
- **Anatomically** :divided according to their relation to the urethra into **(5) lobes**:
- **Anterior (Isthmus)**: lies anterior to the urethra, it is fibromuscular.
- **Posterior** ; posterior to the urethra and inferior to the ejaculatory ducts.
- **Two Lateral** : on each side of the urethra.
- **Middle (Median)** : between the urethra and ejaculatory ducts & closely related to neck of urinary bladder.

It may project into urinary bladder.

The Median & Lateral lobes are rich in glandular tissue.



- **Urologists & Sonographers**, divide the prostate into **Peripheral and Central (Internal) zones**.
- The **Central zone** is represented by the **Middle lobe**.
- Within each lobe are four lobules, which are defined by the ducts and connective tissue



Blood Supply & Lymph Drainage

Arterial Supply: **inferior vesical artery**

Prostatic venous plexus:

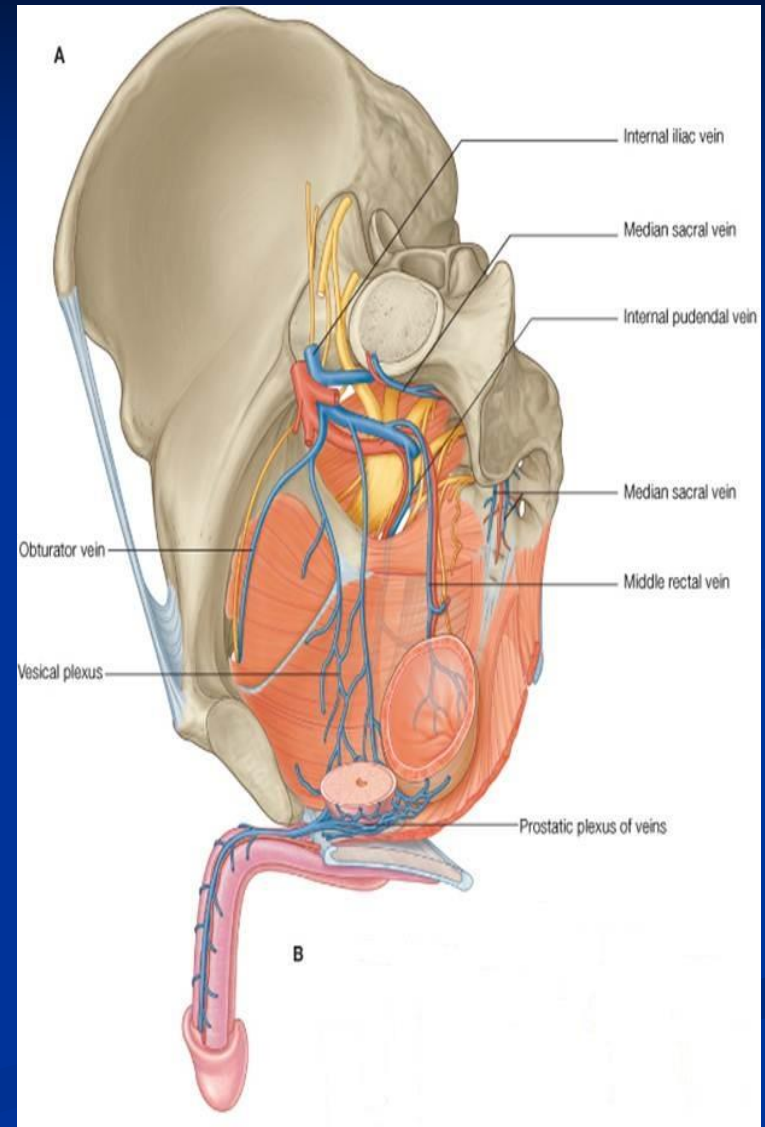
Lies between the prostatic fibrous capsule and the prostatic sheath.

It drains into the **internal iliac veins.**

It is continuous superiorly with the vesical venous plexus and posteriorly to the internal vertebral venous plexus

Lymph drainage:

Internal iliac lymph nodes.



Hypertrophy of the Prostate

■ Benign

- Common after middle age.
- An enlarged prostate projects into the urinary bladder and distorts the prostatic urethra.
- The middle lobe often enlarges the most and obstructs the internal urethral orifice, this leads to nocturia, dysuria and urgency.

■ Malignant:

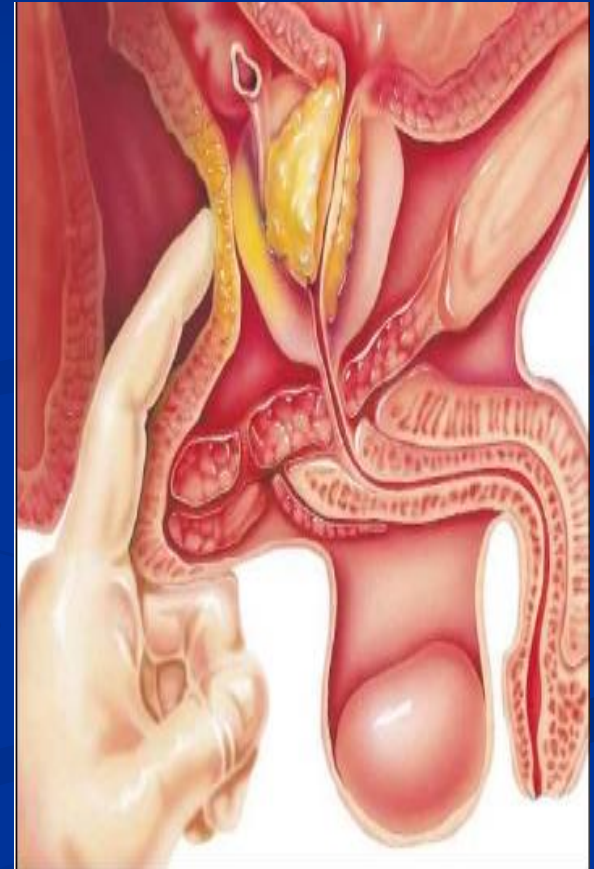It is common after the age of 55

The malignant prostate is felt hard & irregular during PR

The malignant cells metastasize through lymph and veins.

Lymphatic metastasis to Internal iliac & Sacral lymph nodes, Later to distant nodes

Venous metastasis to Bone & Brain through (IVVP)



Prostatic Urethra

■ Structures seen on its posterior wall:

Urethral crest:

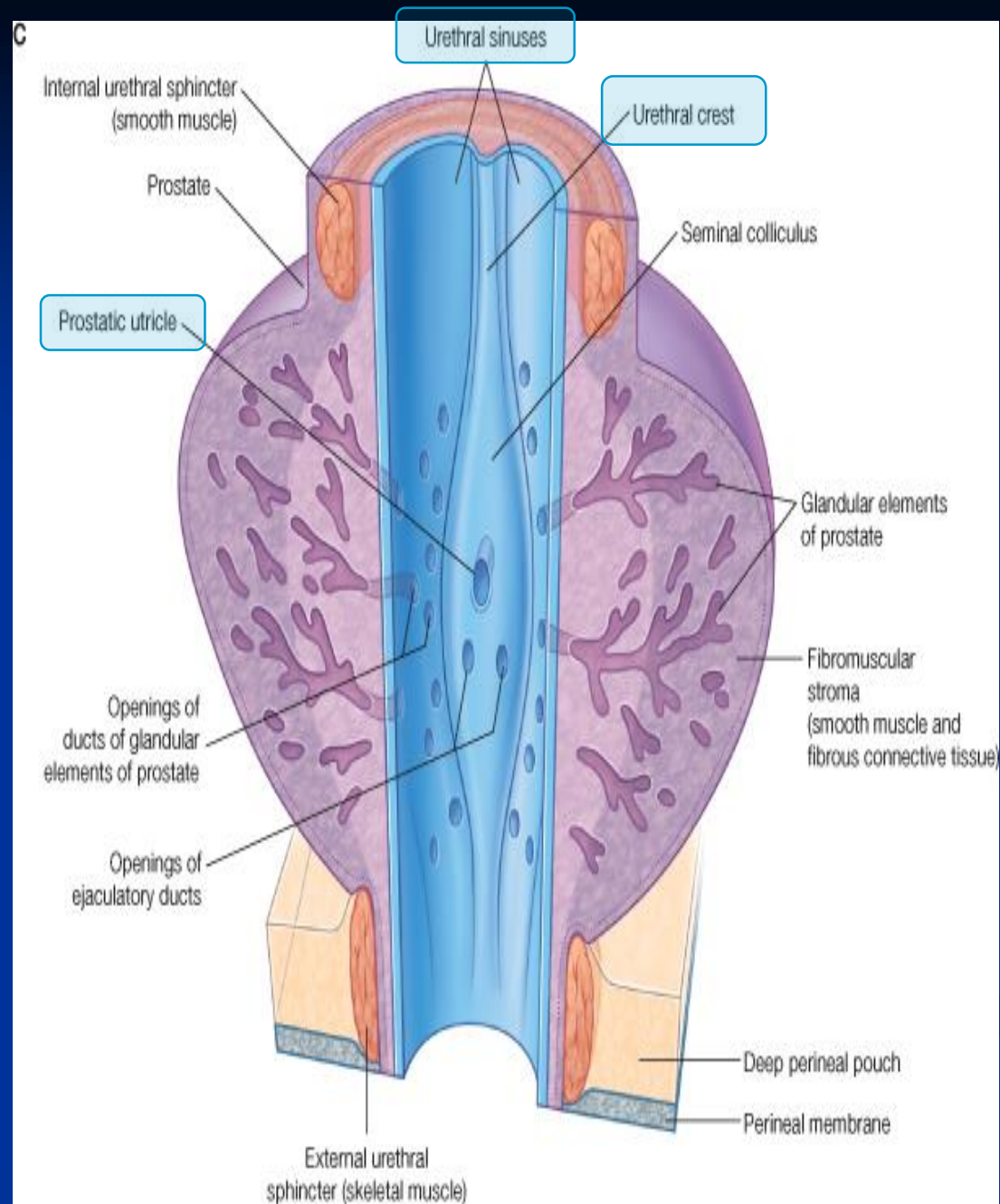
- A longitudinal elevated ridge.

Prostatic sinus:

- A groove on each side of the crest.
- The prostatic gland opens into the sinuses.

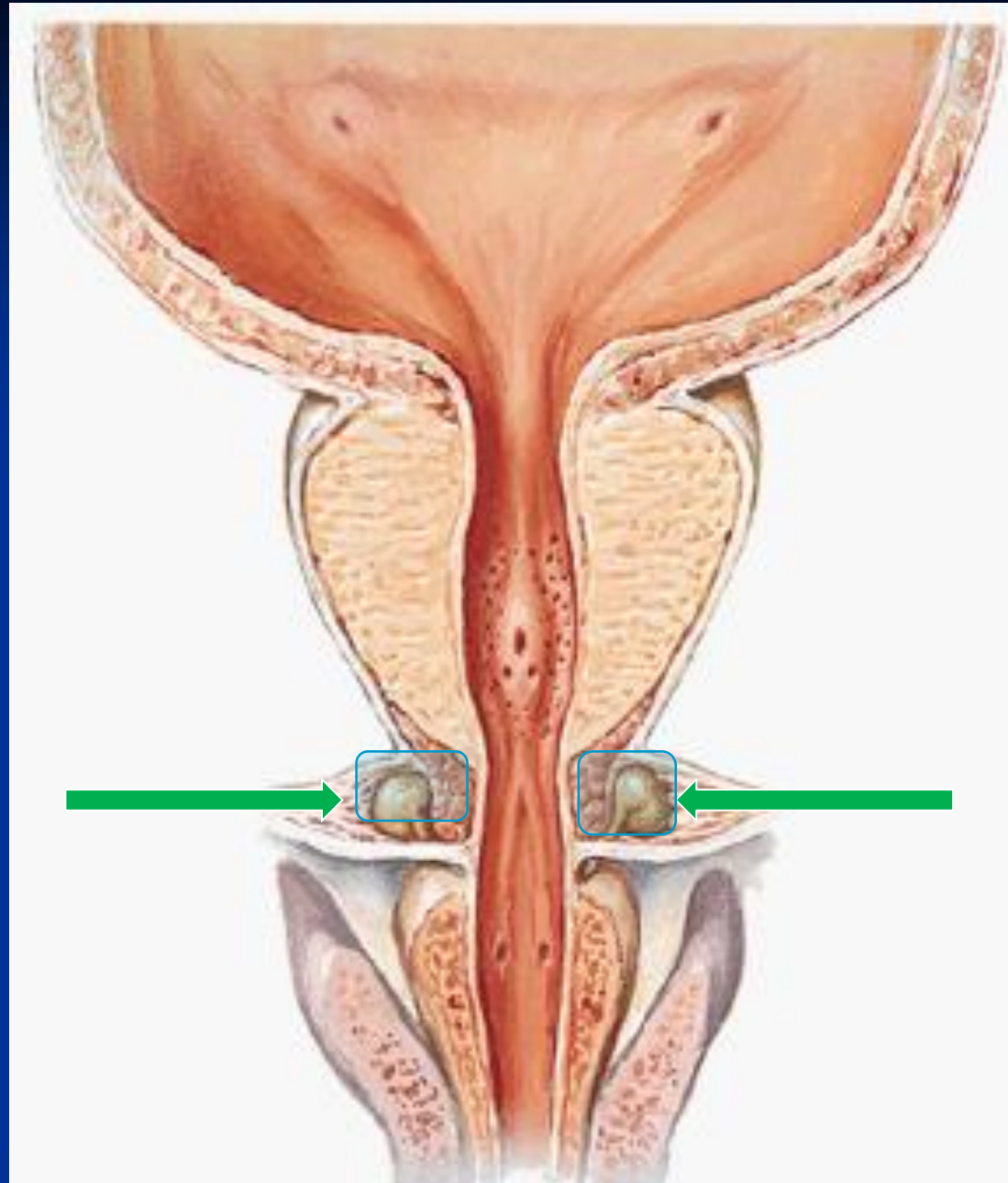
Prostatic utricle :

- A depression on the summit of the urethral crest.
- The ejaculatory ducts open on the sides of the utricle.



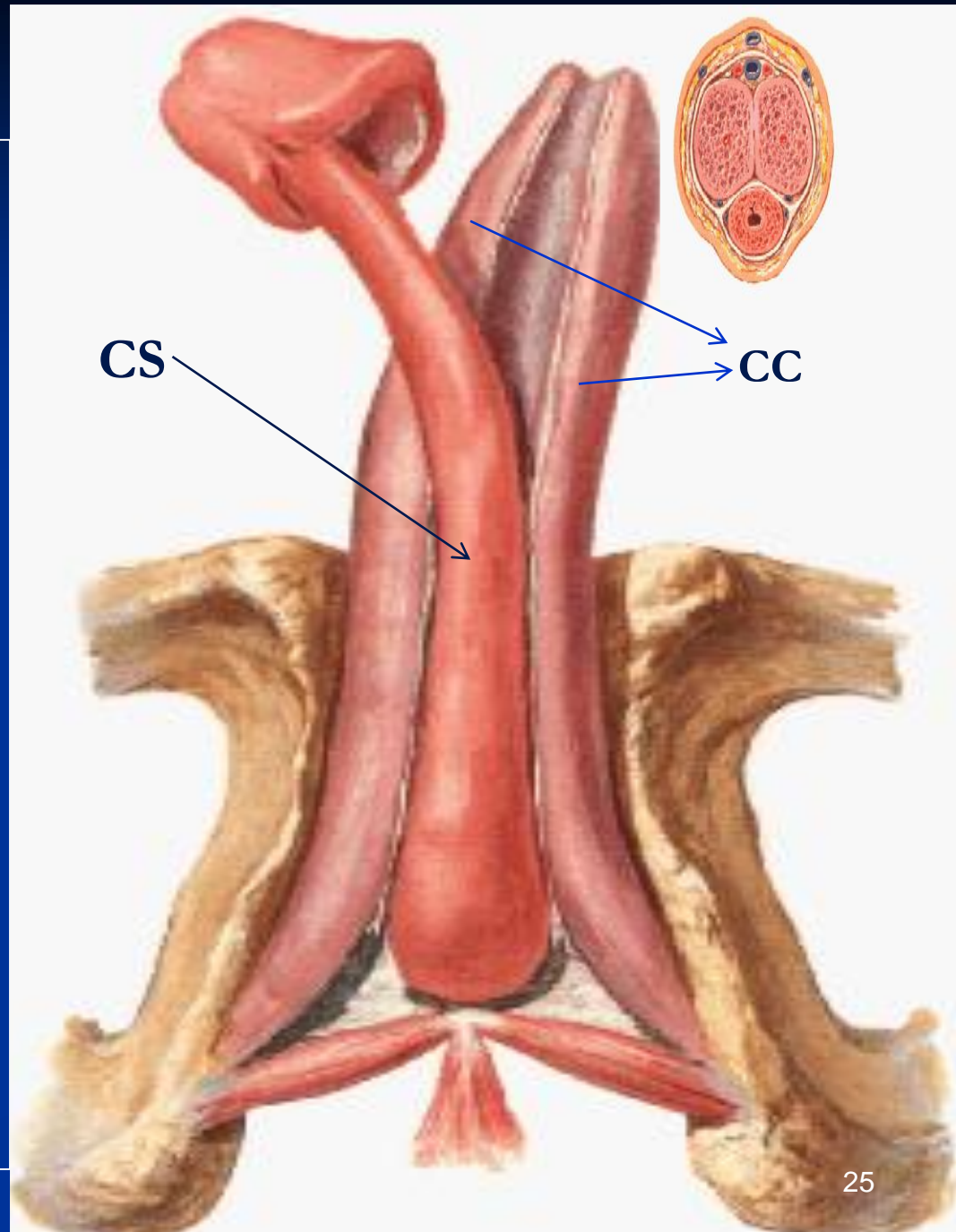
Bulbourethral Glands

- Small paired glands
- Located at the base of the penis
- Secrete alkaline mucus for:
 - Neutralization of urinary acids &
 - Lubrication



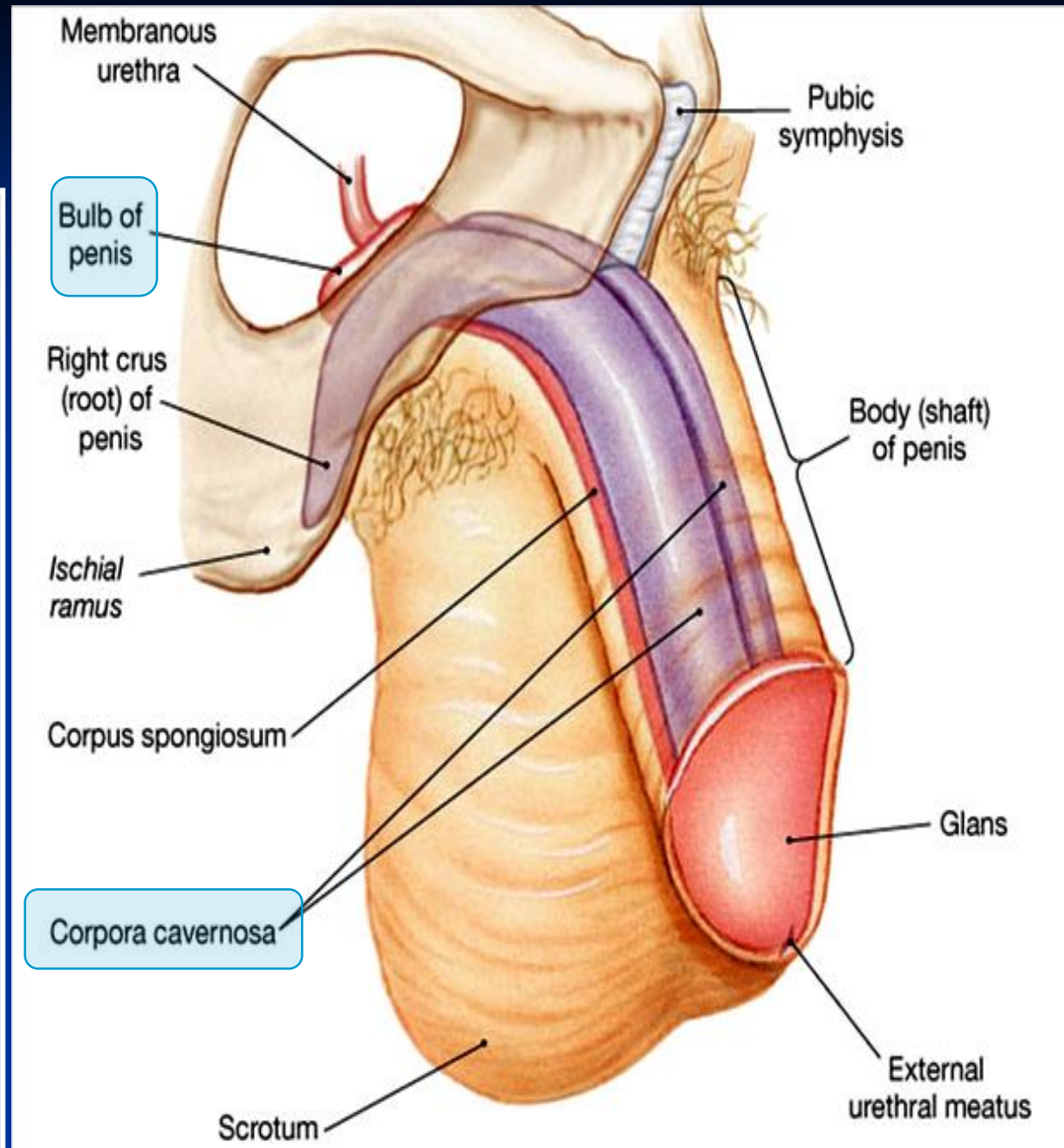
Penis

- A Copulatory & Excretory organ.
- Excretory:
- Penile urethra transmits urine & sperm.
- Copulatory:
- Has (3) cylindrical masses of erectile tissue
 - Two **Corpora Cavernosa**
 - One **Corpus Spongiosum**



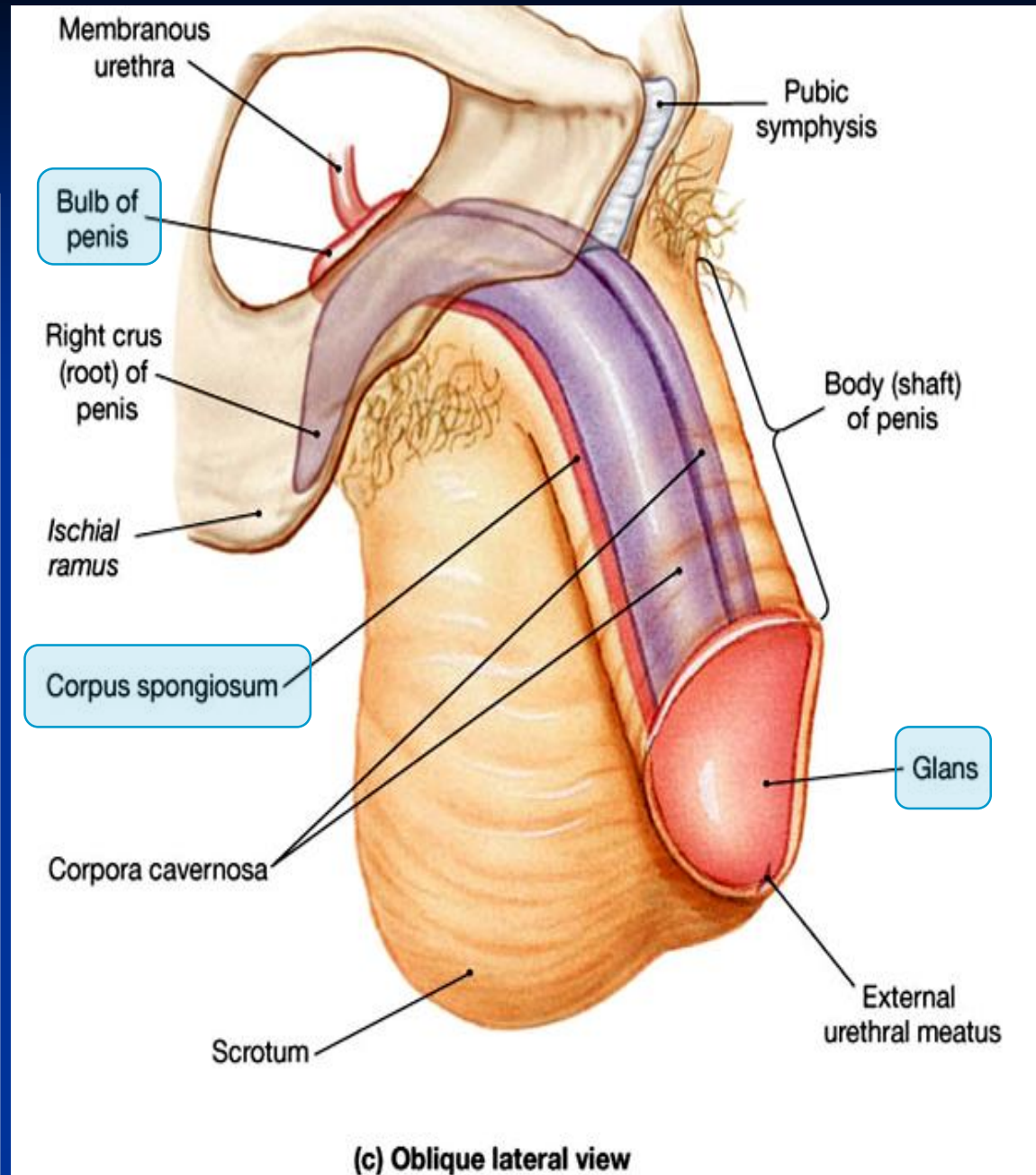
Corpora Cavernosa

- Superior Paired Right & left
- masses of (Primary erectile tissue).
- They Provide the majority of rigidity & length of penis
- Their Posterior Expansions: form **Crura** (anchor” tissue) against pelvic bone



Corpus Spongiosum

- The Inferior mass
 - (A Secondary erectile tissue)
- It is Traversed by the Penile urethra
- Its Anterior expansion forms the Glans
- Its Posterior expansion: forms Bulb of penis
- Prepuce : Fold of skin covering glans (before circumcision)



GOOD LUCK