

A close-up photograph of several vibrant pink roses in full bloom, set against a background of green leaves and some blurred blue flowers. The roses are the central focus, with their petals showing detailed texture and color variations from light pink to deeper magenta.

Pathways of proprioception

posterior column&

Spinocerebellar Pathways

Assess Prof. Fawzia Al-Rouq
Department of Physiology
College of Medicine
King Saud University

<https://www.youtube.com/watch?v=pMEROPOK6v8>

OBJECTIVES

Pathways of proprioception

At the end of this lecture the student should be able to:-

1-Identify the major sensory pathways

Describe the components, processes and functions of the sensory pathways

2-appreciate the dorsal column system in conscious proprioception (anatomy&functions)

3- describe the pathway of spinocerebellar tract in unconscious proprioception from muscles,tendons,and joints

4-differentiate between sensory and motor ataxia

- **Introduction**
- **Sensory receptors**
- **major sensory pathways**
- **dorsal column system**
- **spinocerebellar tract**
- **sensory and motor ataxia**

INTRODUCTION

Organization of the Nervous System

2 big initial divisions:

Central Nervous System

The brain + the spinal cord

The center of integration and control

Peripheral Nervous System

The nervous system outside of the brain and spinal cord

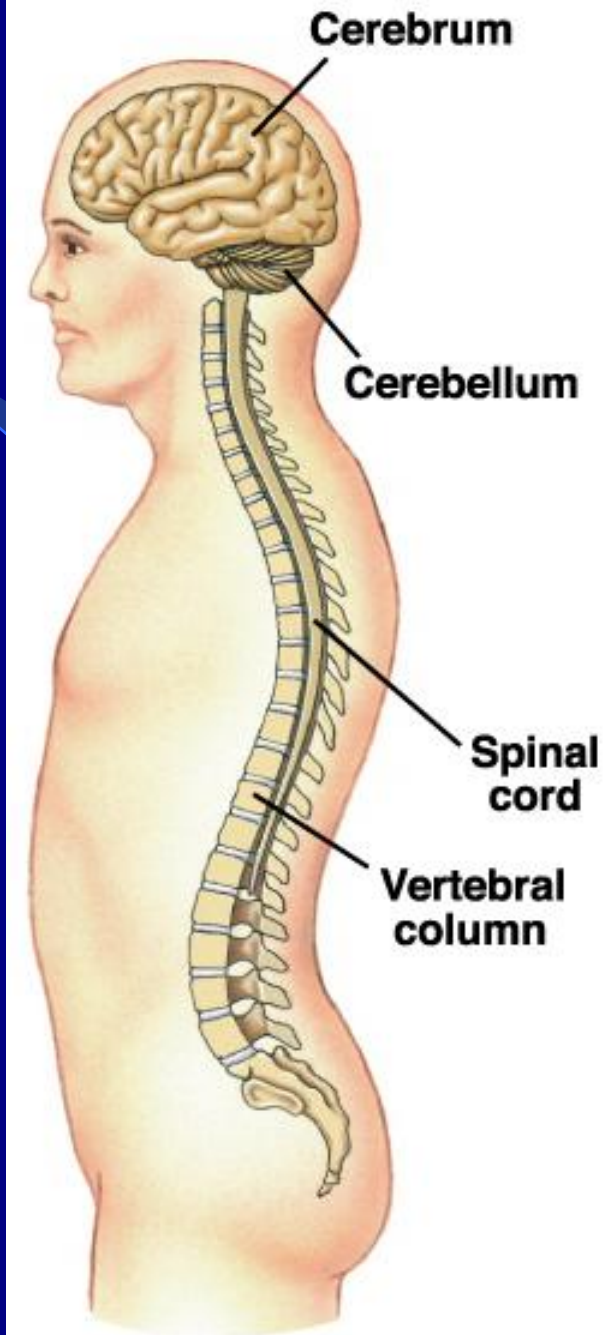
Consists of:

31 Spinal nerves

Carry info to and from the spinal cord

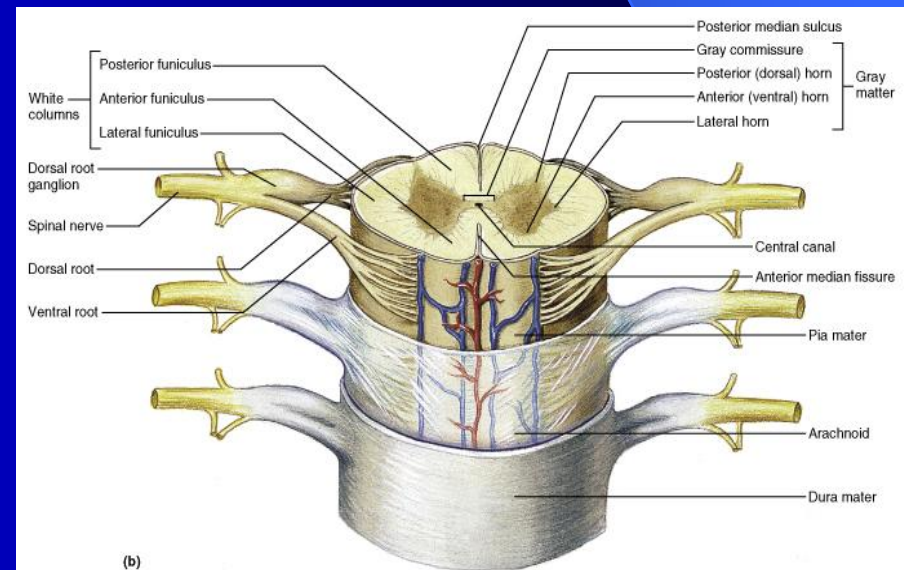
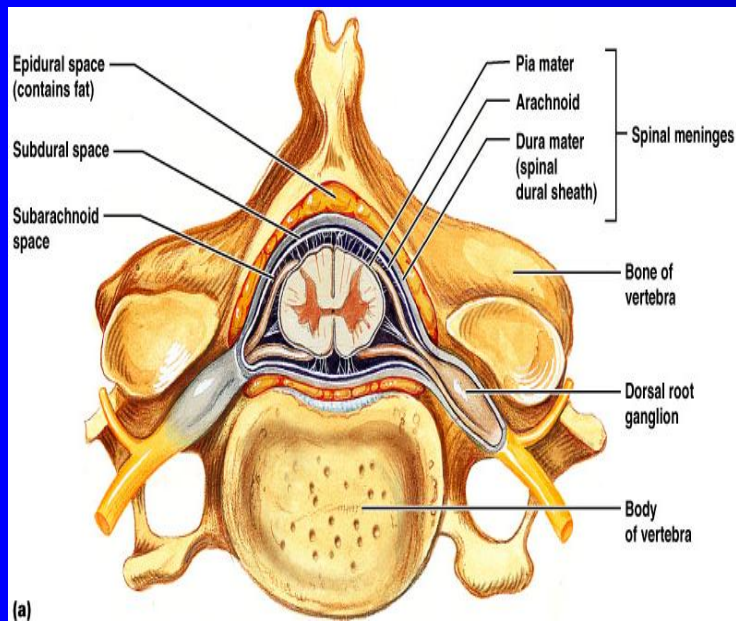
12 Cranial nerves

Carry info to and from the brain



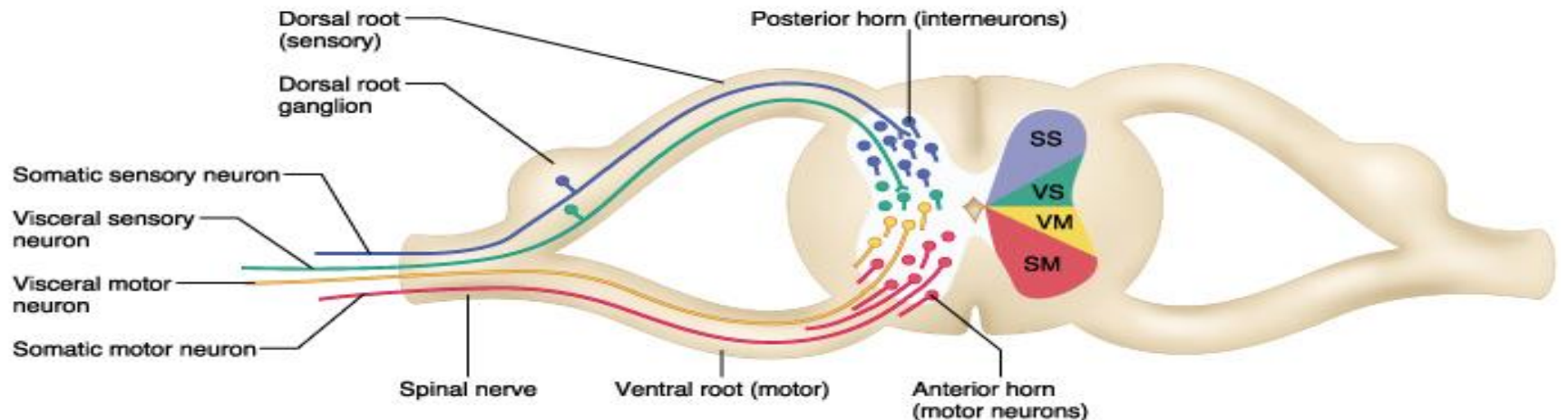
● Spinal cord

- A Cross-section view of spinal cord- wider laterally than anteroposteriorly. In the middle on the dorsal side is a shallow groove called the posterior median sulcus and on the ventral side is the anterior median fissure (deeper).
- center consists of gray matter shaped like a butterfly and there is an opening at the center
- Spinal cord is protected by three layers of meninges. The only difference from the brain is that the dura mater does not attach to bone. The dura mater is surrounded externally by a layer of cushioning fat called epidural space.



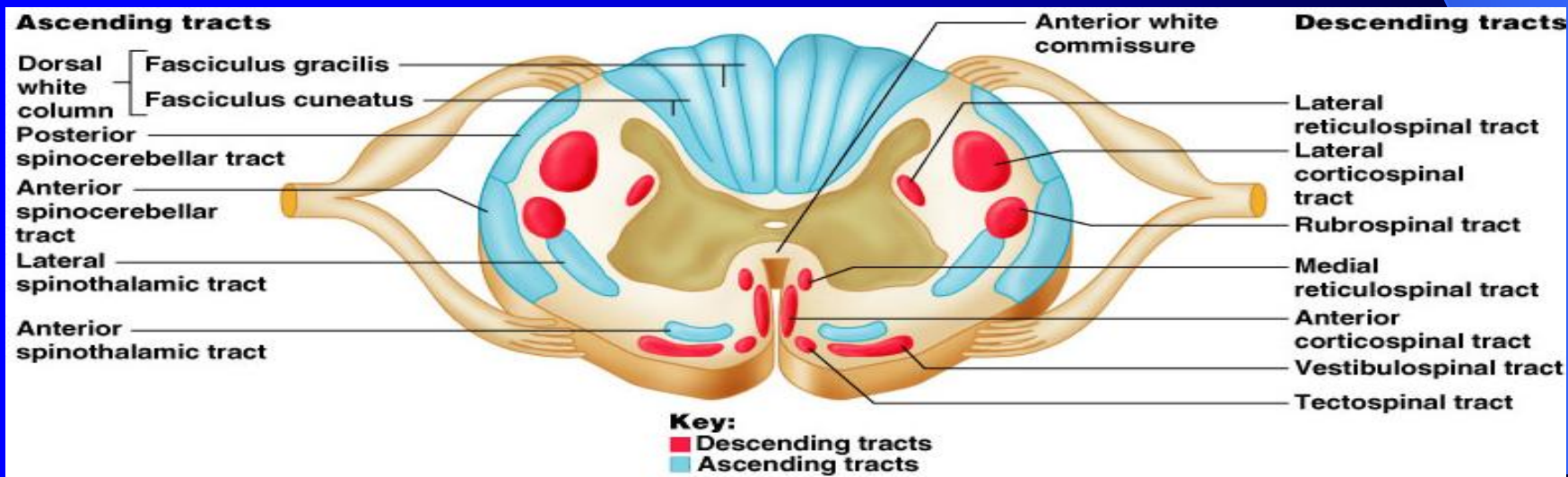
Gray Matter: Organization

- Dorsal half – sensory roots and ganglia
- Ventral half – motor roots
- Dorsal and ventral roots fuse laterally to form spinal nerves
- Four zones are evident within the gray matter – somatic sensory (SS), visceral sensory (VS), visceral motor (VM), and somatic motor (SM)



White Matter in the Spinal Cord

- Fibers run in three directions – ascending, descending, and transversely
- Divided into three funiculi (columns) – posterior, lateral, and anterior
- Each funiculus contains several fiber tracks
 - Fiber tract names reveal their origin and destination
 - Fiber tracts are composed of axons with similar functions



- **Introduction**
- **Sensory receptors**
- **major sensory pathways**
- **dorsal column system**
- **spinocerebellar tract**
- **sensory and motor ataxia**

Sensory Receptors

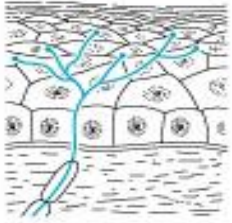

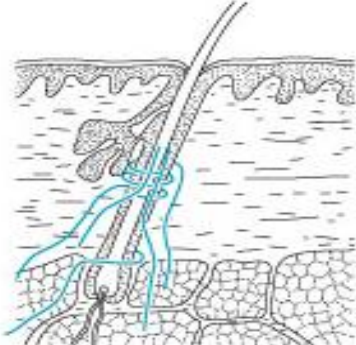
A decorative graphic element consisting of a blue gradient shape that starts as a thin line at the top left and curves downwards and to the right, ending as a solid blue block at the bottom right.

Peripheral Sensory Receptors

- Sensory receptors classified according to:
 - Location
 - Type of stimulus detected
 - Structure

Unencapsulated Nerve Endings

Table 14.1 General Sensory Receptors Classified by Structure and Function (1 of 3)

Anatomical Class (structure)	Illustration	Functional Class According to Location (L) and Stimulus Type (S)	Body Location
UNENCAPSULATED			
Free nerve endings of sensory neurons		L: Exteroceptors, interoceptors, and proprioceptors S: Nociceptors (pain), thermoreceptors (heat and cold), possibly mechanoreceptors (pressure)	Most body tissues; densest in connective tissues (ligaments, tendons, dermis, joint capsules, periosteum) and epithelia (epidermis, cornea, mucosae, and glands)
<i>Modified free nerve endings:</i> Merkel discs		L: Exteroceptors S: Mechanoreceptors (light pressure)	Basal layer of epidermis
Hair follicle receptors		L: Exteroceptors S: Mechanoreceptors (hair deflection)	In and surrounding hair follicles

Encapsulated Nerve Endings

- Consist of one or more end fibers of sensory neurons
- Enclosed in connective tissue
- Include four main types

Encapsulated Nerve Endings

- Meissner's corpuscles
- Pacinian corpuscles
- Ruffini's corpuscles
- Proprioceptors

Proprioceptors

- Encapsulated Nerve Endings
- Monitor stretch in locomotory organs
- Three types of proprioceptors

Three Types of *Proprioceptors*

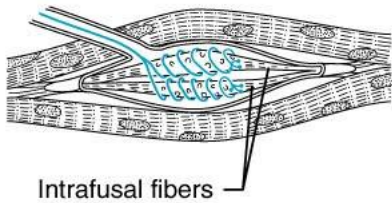
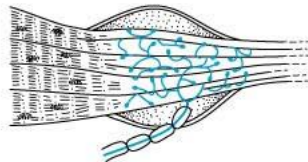
- **Muscle spindles** – measure the changing length of a muscle
 - Imbedded in the perimysium between muscle fascicles
- **Golgi tendon organs** – located near the muscle-tendon junction
 - Monitor tension within tendons
- **Joint kinesthetic receptors**
 - Sensory nerve endings within the joint capsules

Proprioceptors

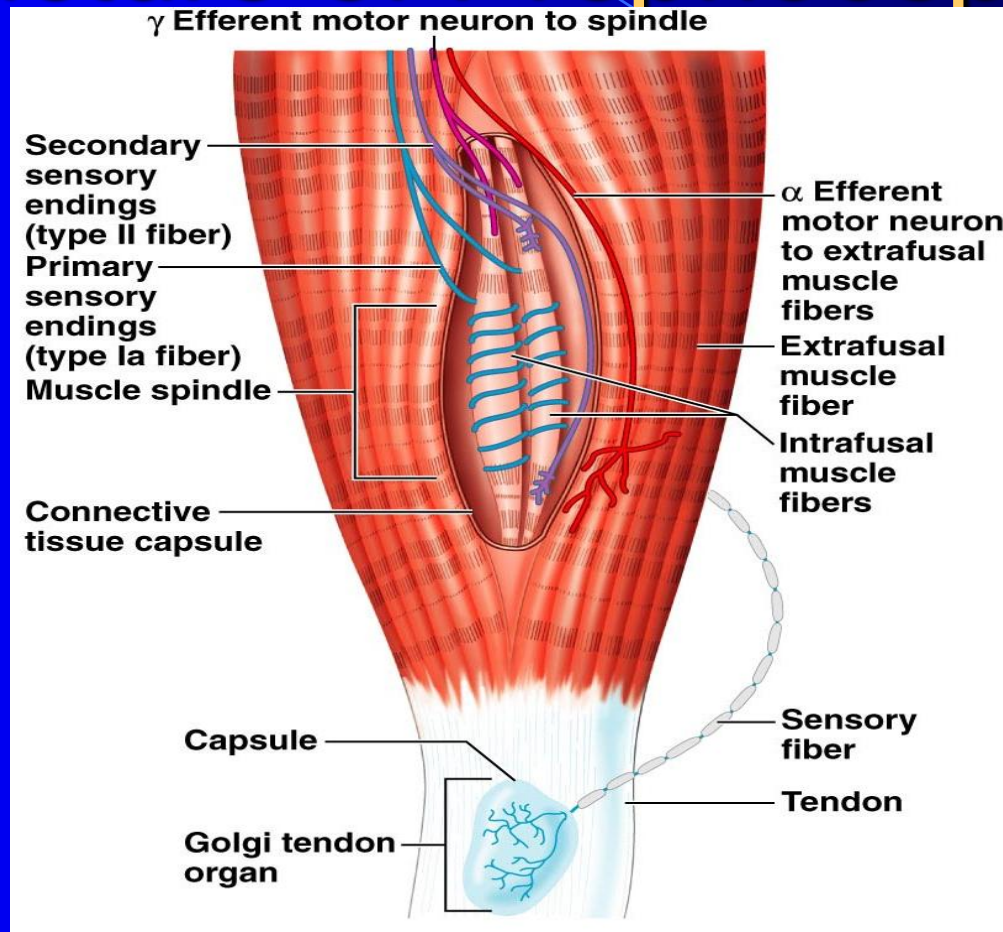
TABLE

14.1

General Sensory Receptors Classified by Structure and Function *(continued)*

Structural Class	Illustration	Functional Class According to Location (L) and Stimulus Type (S)	Body Location
PROPRIOCEPTORS			
Muscle spindles	 <p>Intrafusal fibers</p>	L: Proprioceptors S: Mechanoreceptors (muscle stretch)	Skeletal muscles, particularly those of the extremities
Golgi tendon organs		L: Proprioceptors S: Mechanoreceptors (tendon stretch)	Tendons
Joint kinesthetic receptors (Pacinian and Ruffini endings, free nerve endings, and receptors resembling Golgi tendon organs)		L: Proprioceptors S: Mechanoreceptors and nociceptors	Joint capsules of synovial joints

Structure of Proprioceptors



- **Introduction**
- **Sensory receptors**
- **major sensory pathways**
- **dorsal column system**
- **spinocerebellar tract**
- **sensory and motor ataxia**

An Overview of Sensory Pathways and the Somatic Nervous System

Neural pathways

- Afferent pathways

- Sensory information coming from the sensory receptors through peripheral nerves to the spinal cord and to the brain .

- Efferent pathways

- Motor commands coming from the brain and spinal cord, through peripheral nerves to effector organs .

Sensory pathways

Sensory pathways

- Sensory systems allow us to detect, analyze and respond to our environment
- “ascending pathways”
- Carry information from sensory receptors to the brain
- Conscious: reach cerebral cortex
- Unconscious: do not reach cerebral cortex
- Sensations from body reach the opposite side of the brain

- **Spinal tracts**- These are known as sensory and motor pathways consisting of multineuron pathways connecting the CNS to the PNS. At some point most pathways crossover (decussate),

- A. **Ascending (sensory) Pathways** :-

- 1. **Dorsal column pathway**- carries signal of fine touch, pressure, vibration, stereognosis and **conscious proprioception**, ascends up dorsal white column in fasciculus gracilis or cutaneatus to medulla oblongata to the thalamus to primary somatosensory cortex (post central gyrus).

- 2. **Posterior and anterior spinocerebellar pathways**- carry **subconscious proprioception**. Dorsal gray horn- to lateral column- to medulla oblongata- to pons – to cerebellum.

- 3. **Spinothalamic pathway**- carries signals of pain, temperature, deep pressure, and coarse touch. From posterior gray horn decussate into lateral and anterior funiculi up to the thalamus to primary somatosensory cortex (postcentral gyrus).

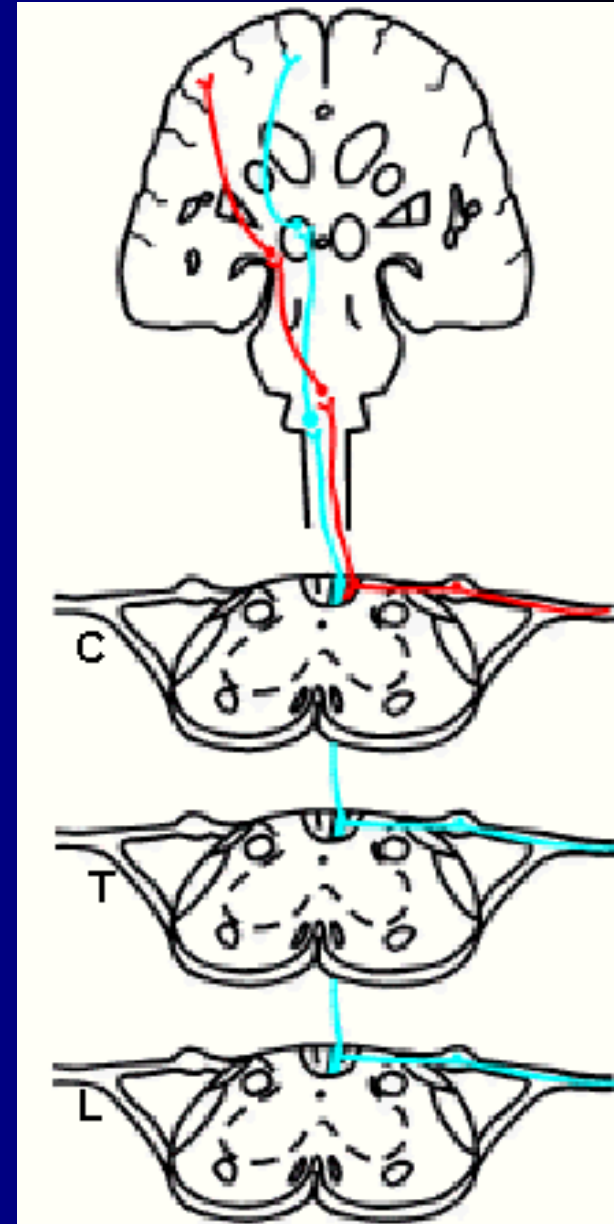
Sensory pathways: 3 neurons

- 1st: enters spinal cord from periphery
- 2nd: crosses over (decussates), ascends
in spinal cord to thalamus
- 3rd: projects to somatosensory cortex

- **Introduction**
- **Sensory receptors**
- **major sensory pathways**
- **dorsal column system**
- **spinocerebellar tract**
- **sensory and motor ataxia**

Dorsal column pathway

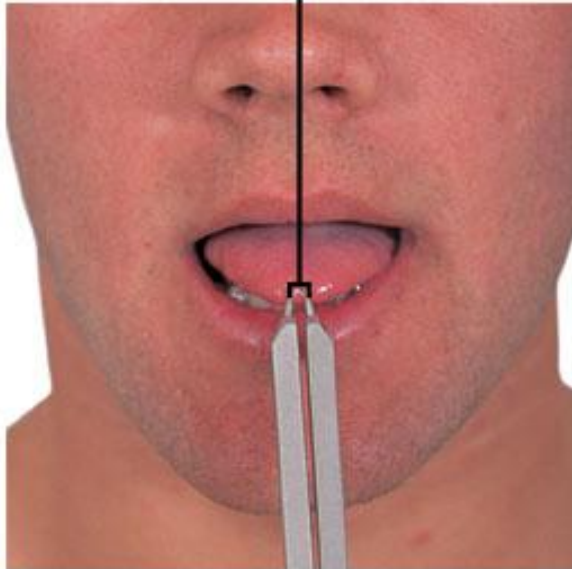
- Carries fine touch, two point discrimination, pressure, vibration, stereognosis and conscious proprioception signals
- 1st neuron enters spinal cord through dorsal root; ascends to medulla (brain stem)
- 2nd neuron crosses over in medulla; ascends to thalamus
- 3rd neuron projects to somatosensory cortex



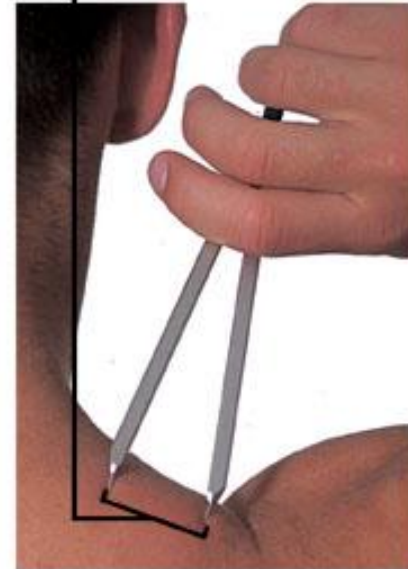
Two-Point Discrimination

Copyright © The McGraw-Hill Companies, Inc. Permission required for reproduction or display.

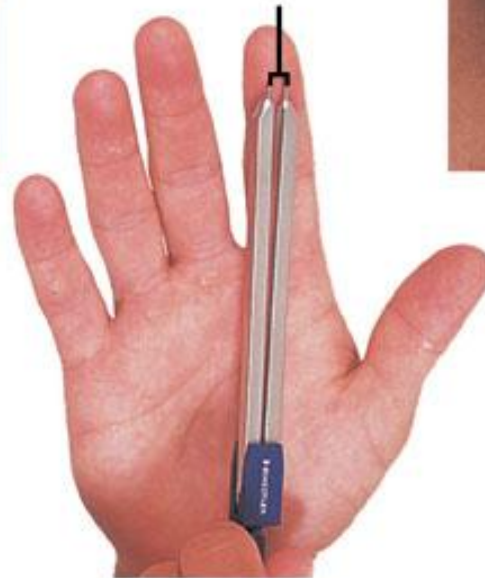2 mm



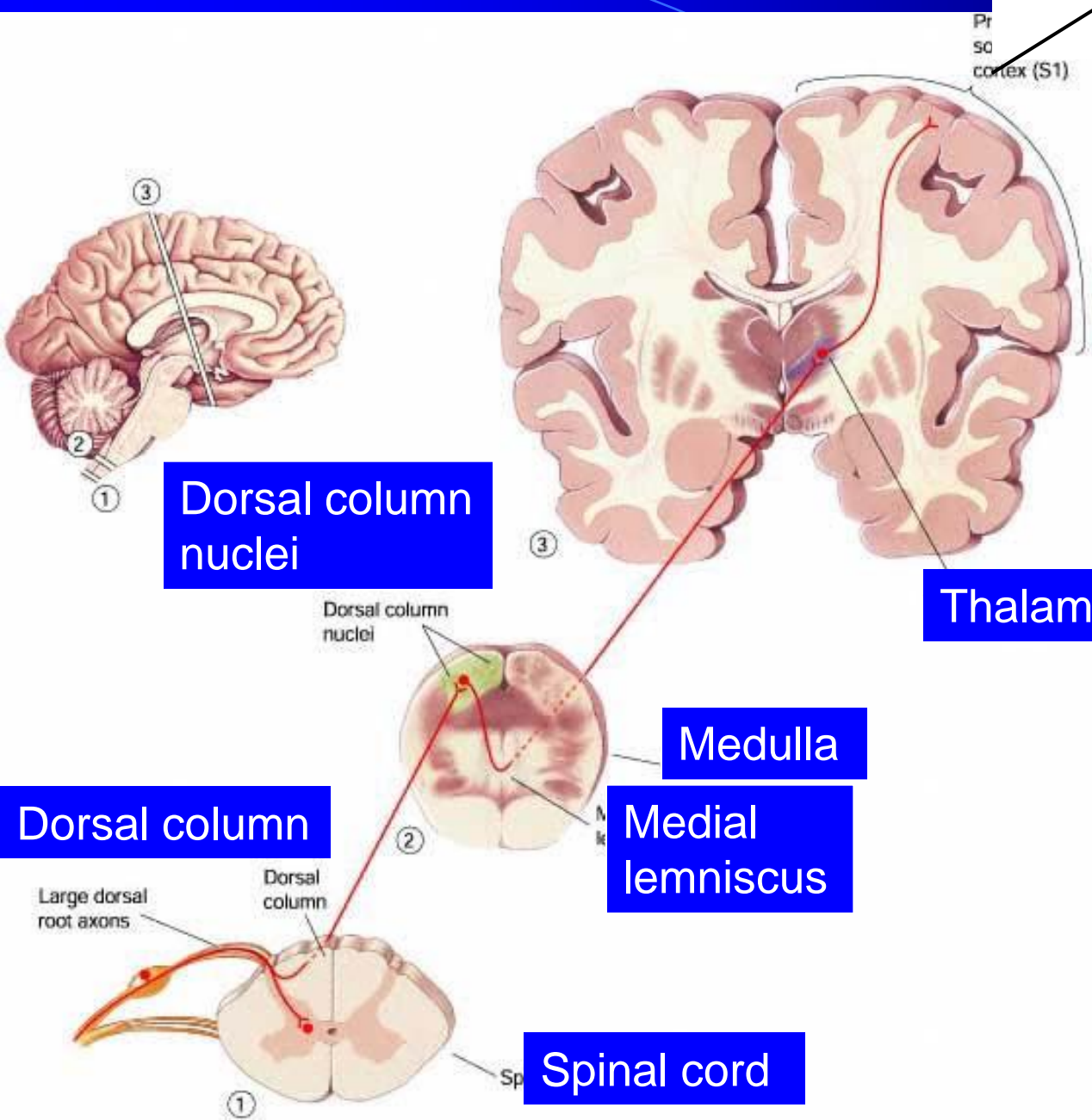
64 mm



4 mm



Dorsal column pathway



Primary somatosensory cortex (S1) in parietal lobe

Dorsal column nuclei

Thalamus

Dorsal column nuclei

Medulla

Medial lemniscus

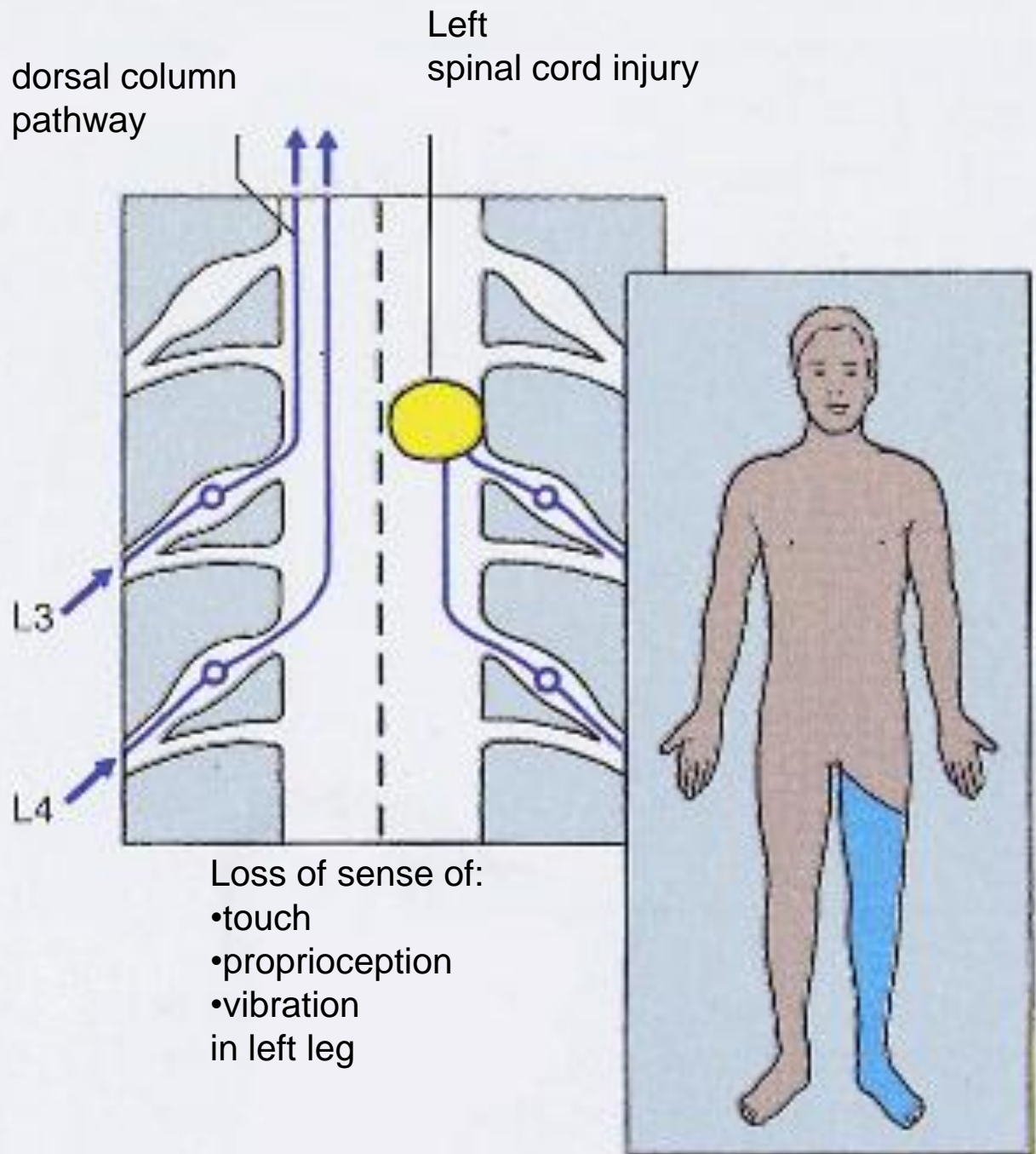
Dorsal column

Large dorsal root axons

Dorsal column

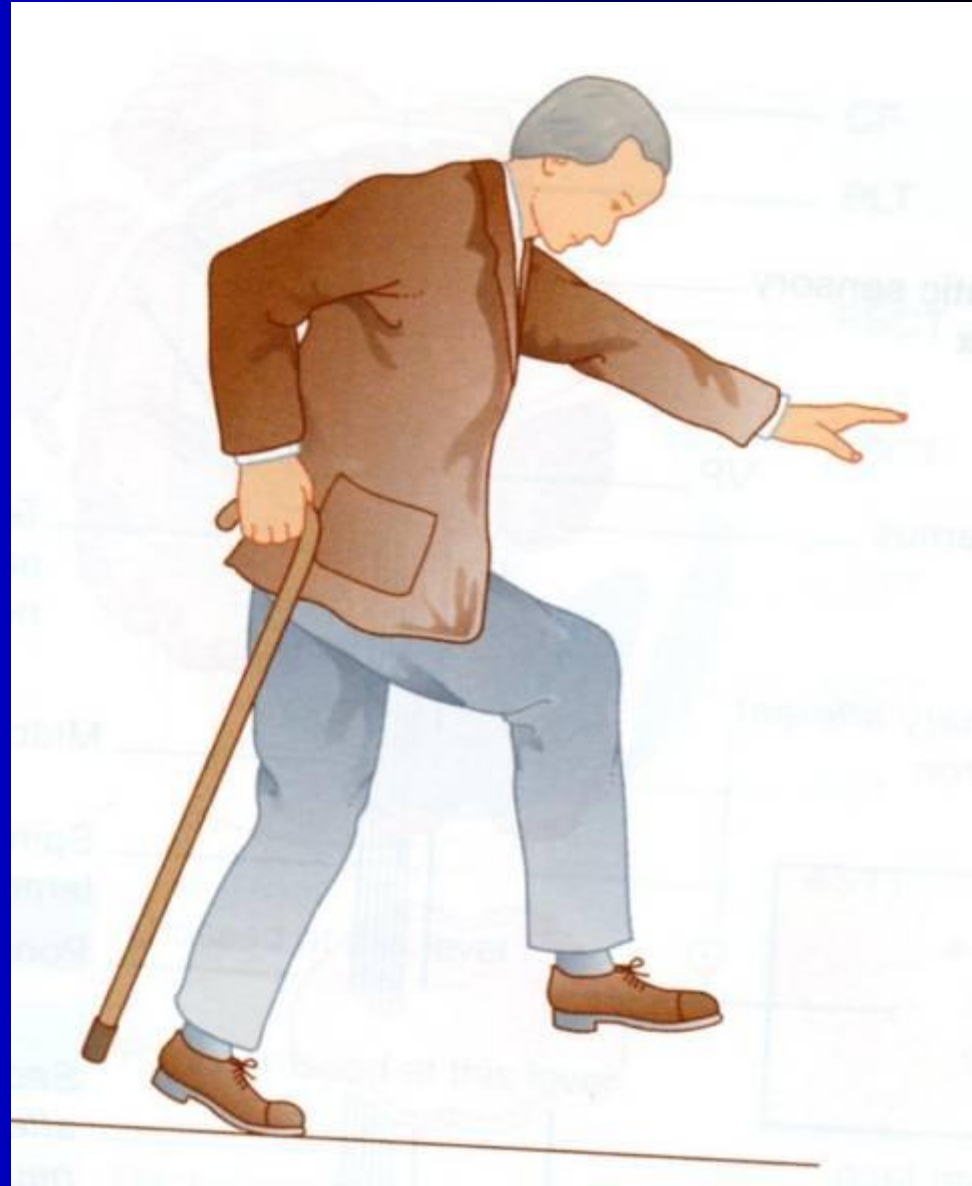Spinal cord

Dorsal column damage



Dorsal column damage

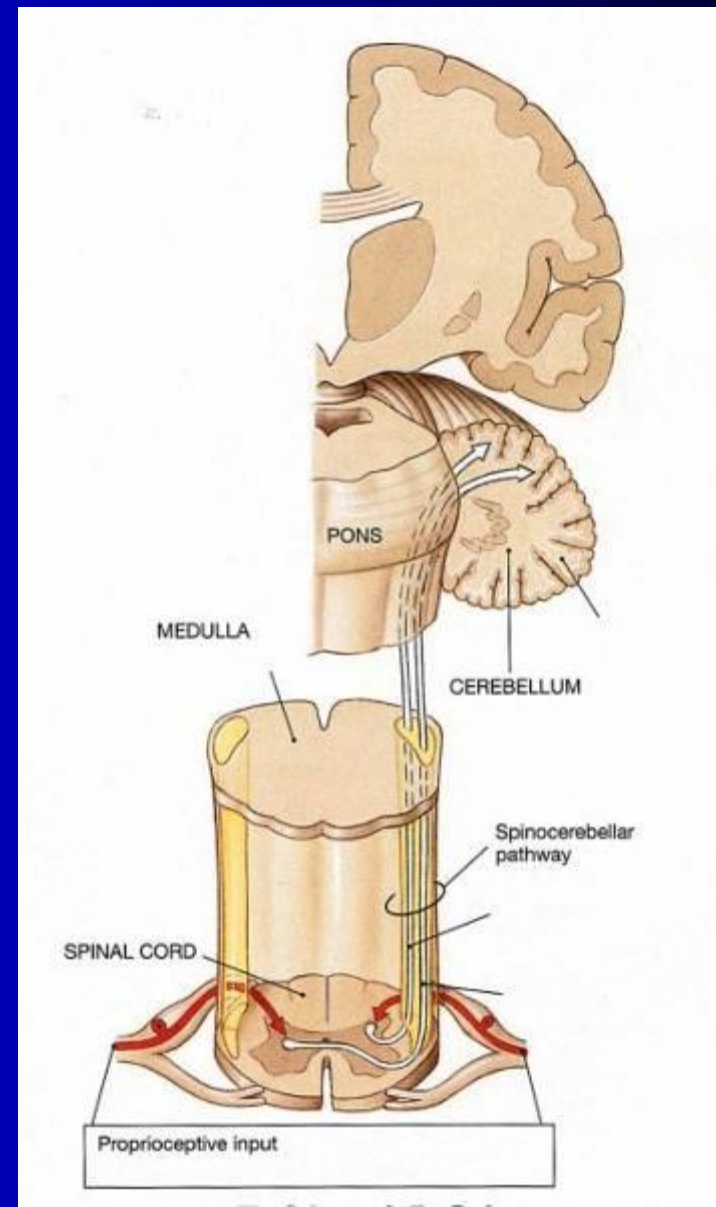
- Sensory ataxia
- Patient staggers; cannot perceive position or movement of legs
- Visual clues help movement



- Introduction
- Sensory receptors
- major sensory pathways
- dorsal column system
- **spinocerebellar tract**
- sensory and motor ataxia

Spinocerebellar pathway


- Carries unconscious proprioception signals
- Receptors in muscles & joints
- 1st neuron: enters spinal cord through dorsal root
- 2nd neuron: ascends to cerebellum
- No 3rd neuron to cortex, hence **unconscious**



Spinocerebellar tract damage

- Cerebellar ataxia
- Clumsy movements
- Incoordination of the limbs (intention tremor)
- Wide-based, reeling gait (ataxia)
- Alcoholic intoxication produces similar effects!

- Introduction
- Sensory receptors
- major sensory pathways
- dorsal column system
- spinocerebellar tract
- **sensory and motor ataxia**



Motor
&
Sensory
Ataxia

Ataxia and Gait Disturbances

- Pathophysiology
 - Result from any condition that affects the central and peripheral nervous systems

 - Ataxia: Types
 - Motor ataxia
 - Sensory ataxia

Ataxia and Gait Disturbances

- Motor Ataxia

- Caused by cerebellar disorders

- Intact sensory receptors and afferent pathways
- Integration of proprioception is faulty
- Midline cerebellar lesions cause truncal ataxia
- Lateral cerebellar lesions cause limb ataxia
- Thalamic infarcts may cause contra lateral ataxia with sensory loss
- N.B cerebellar ataxia will discussed later with cerebellum lecture.

Ataxia and Gait Disturbances

- Sensory Ataxia
 - Failure of proprioceptive information to the CNS
 - May be due to disorders of spinal cord or peripheral nerves
 - Can be compensated for by visual inputs

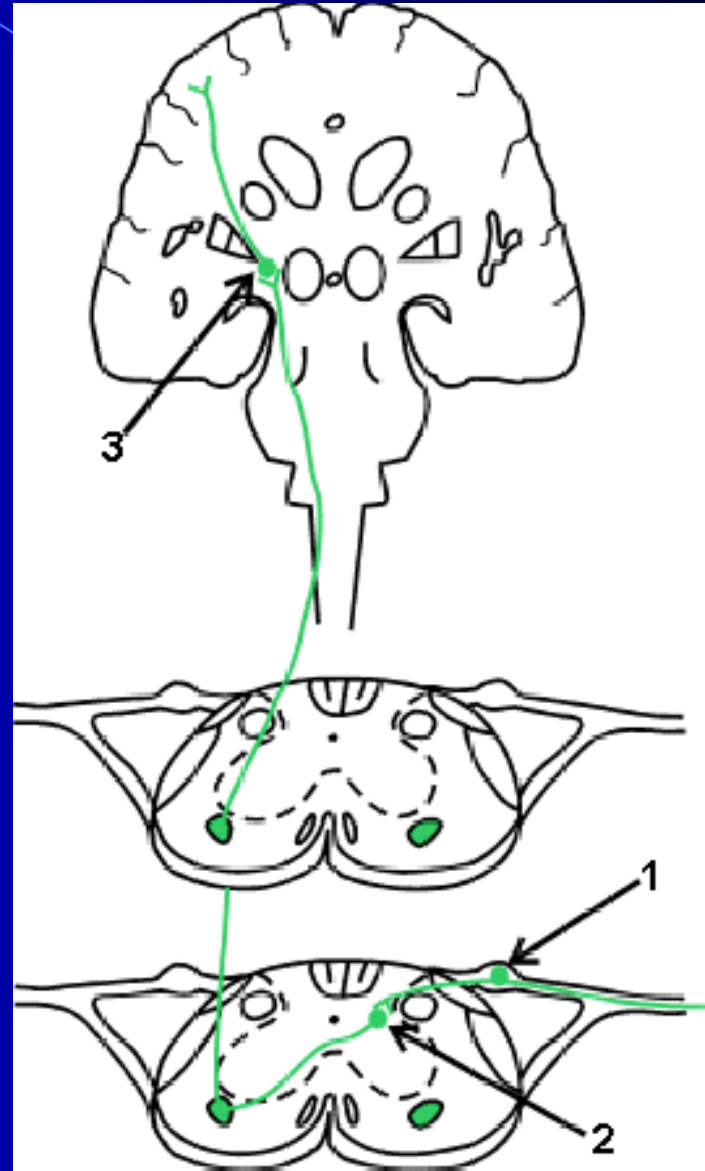
Thank you

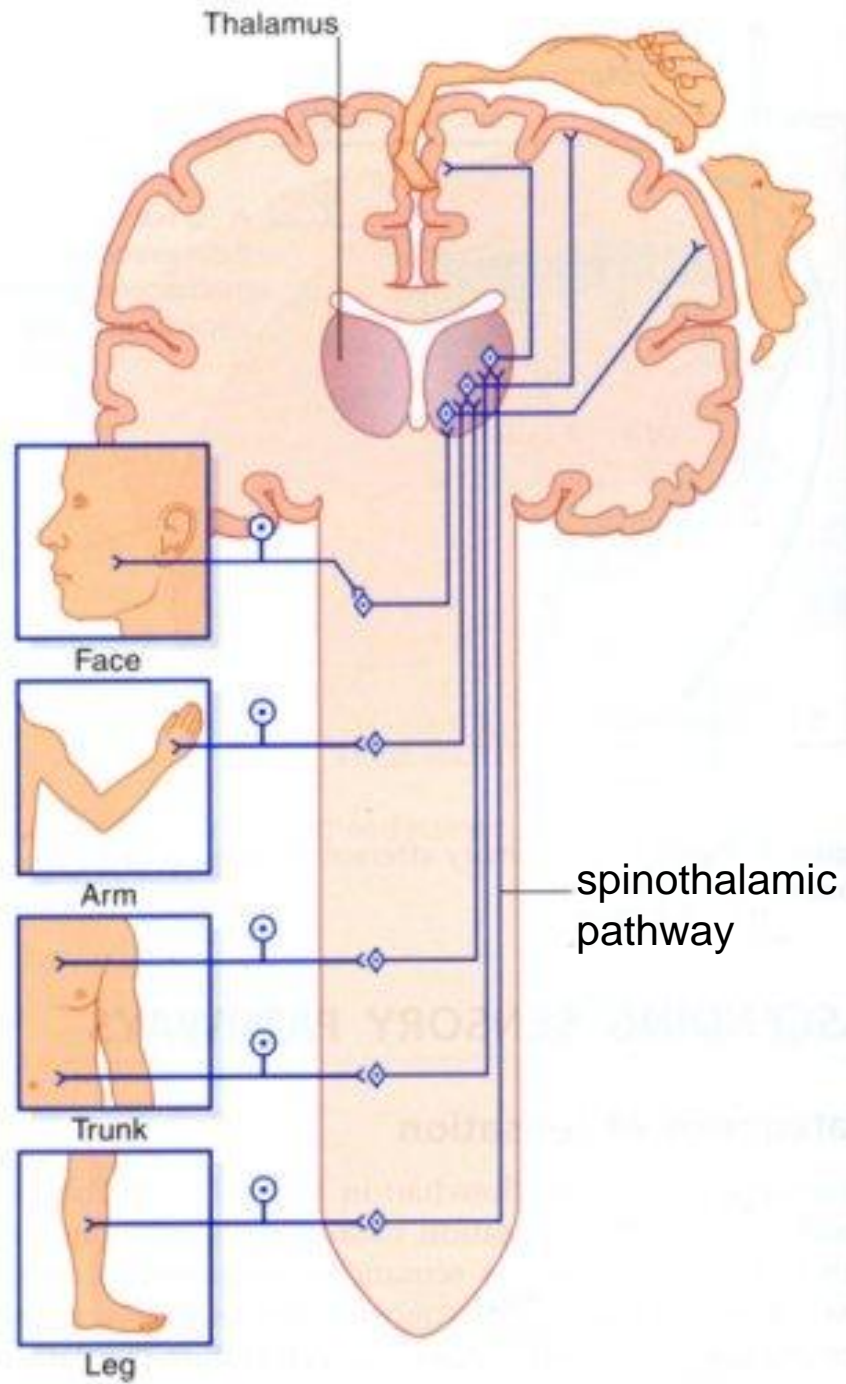
Extra informations

A decorative graphic consisting of a light blue arc that starts at the top left and curves towards the bottom right. A darker blue, semi-transparent shape follows the curve of the arc, extending from the top right towards the bottom right corner of the slide.

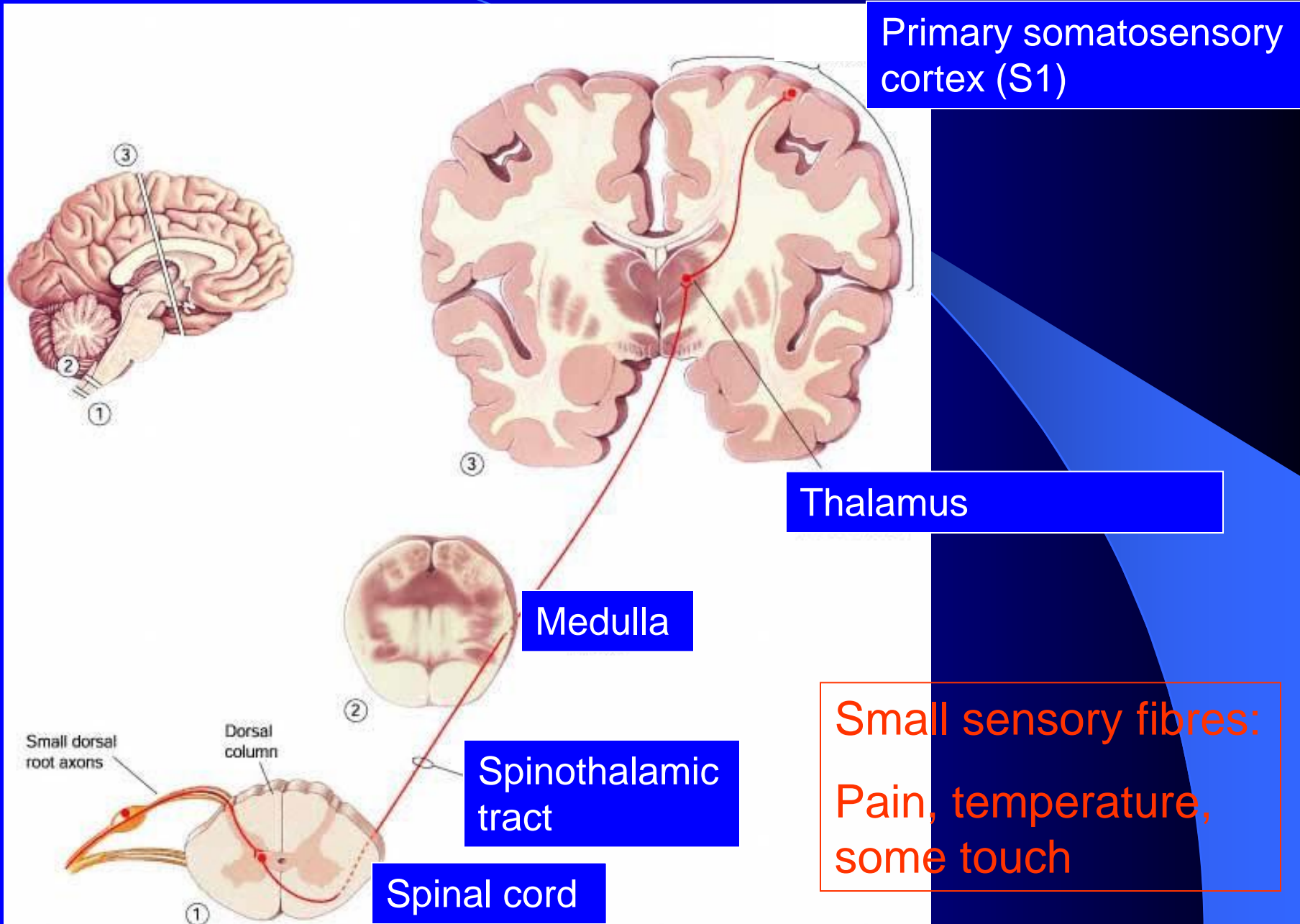
Spinothalamic pathway

- Carries pain, temperature, touch and pressure signals
- 1st neuron enters spinal cord through dorsal root
- 2nd neuron crosses over in spinal cord; ascends to thalamus
- 3rd neuron projects from thalamus to somatosensory cortex

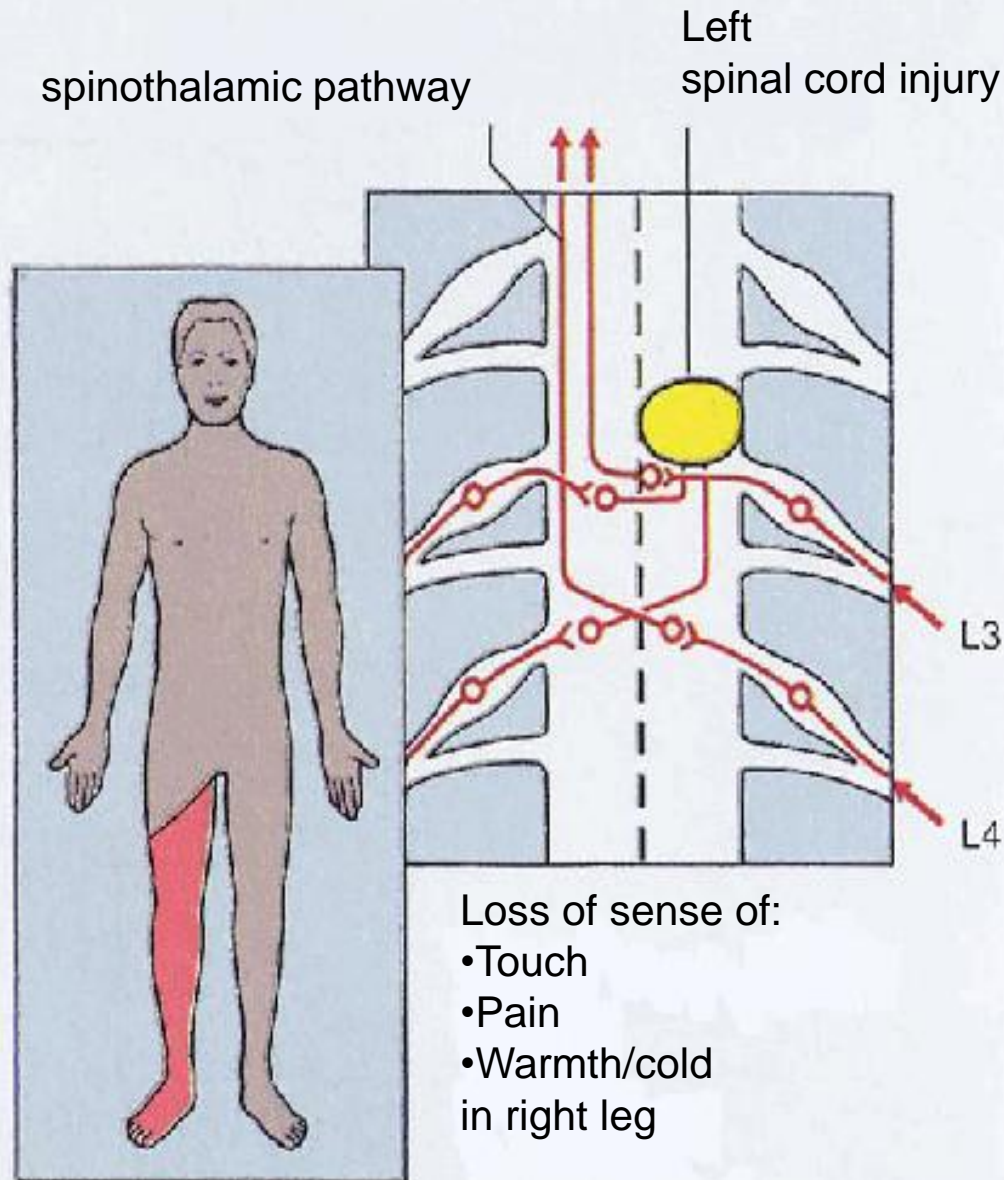




Spinothalamic Pathway


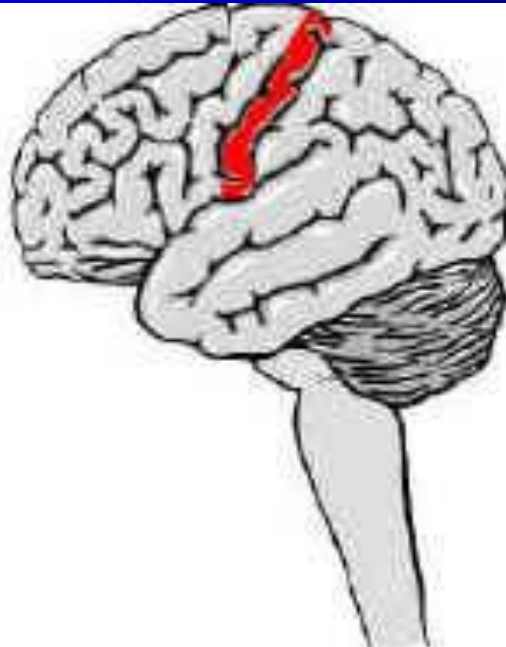
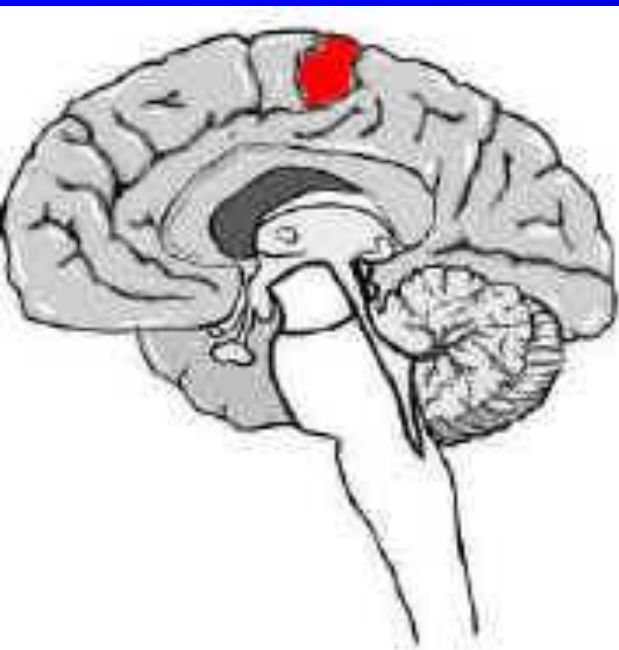


Spinothalamic damage



4. Somatosensory cortex

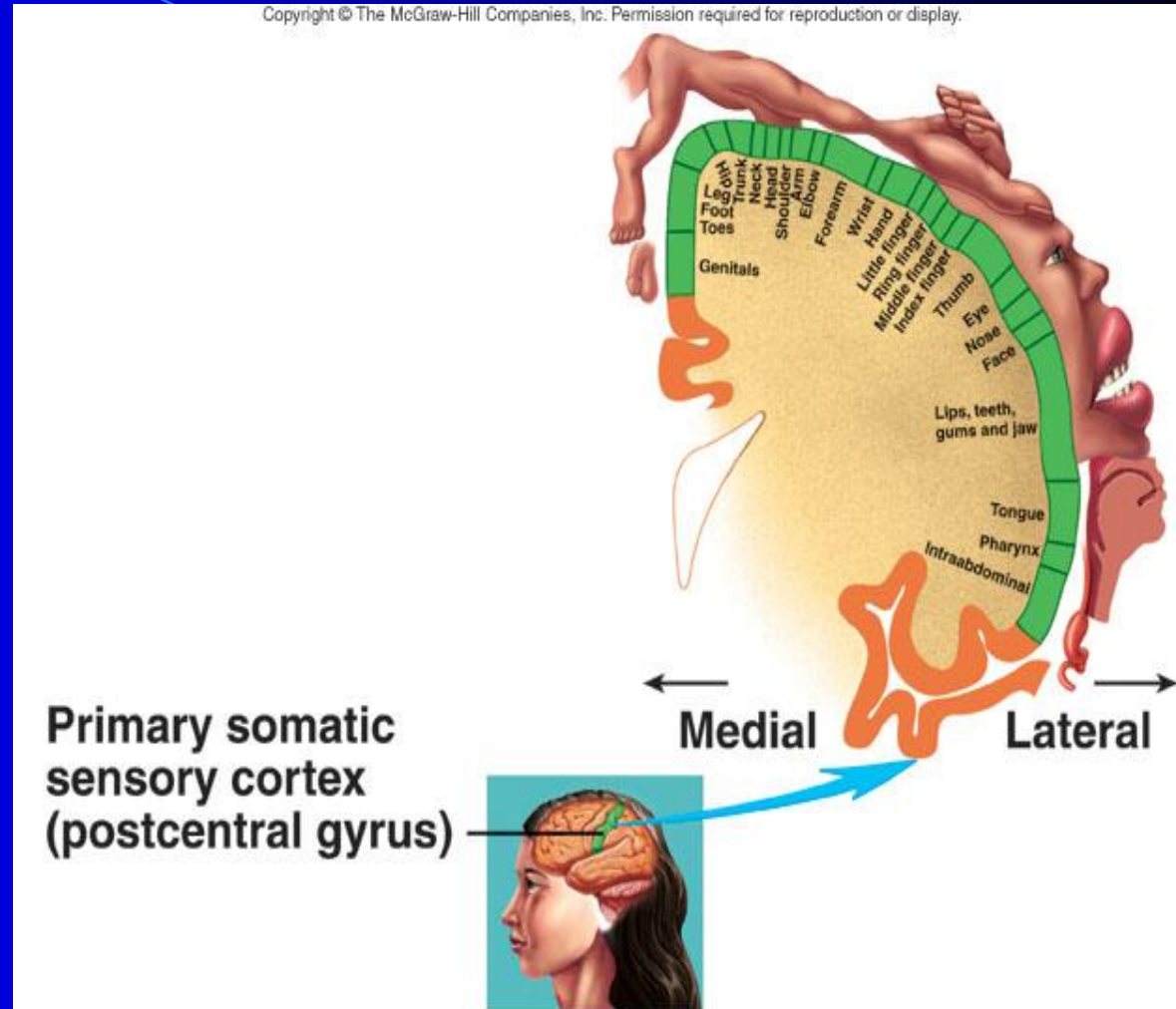
Located in the postcentral gyrus of the human cerebral cortex.



Spatial orientation of signals.

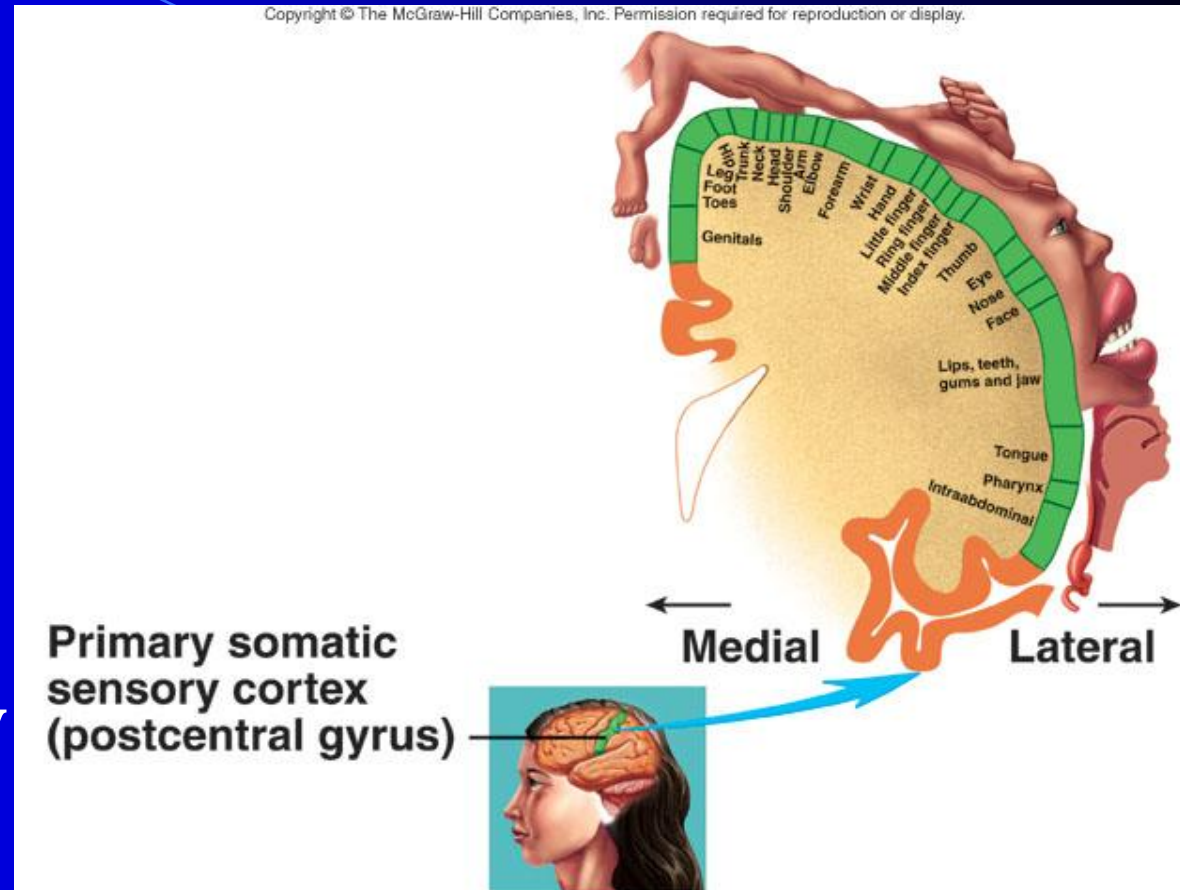
1) Each side of the cortex receives sensory information exclusively from the opposite side of the body

(the exception: the same side of the face).



Spatial orientation of signals.

2) The lips, face and thumb are represented by large areas in the somatic cortex, whereas the trunk and lower part of the body, relatively small area.



3) The head is in the most lateral portion, and the lower body is presented medially