



THE CRANIAL NERVES ACCESSORY AND HYPOGLOSSAL (11TH & 12TH)

DR. JAMELA ELMEDANY

DR. ESSAM ELDIN SALAMA

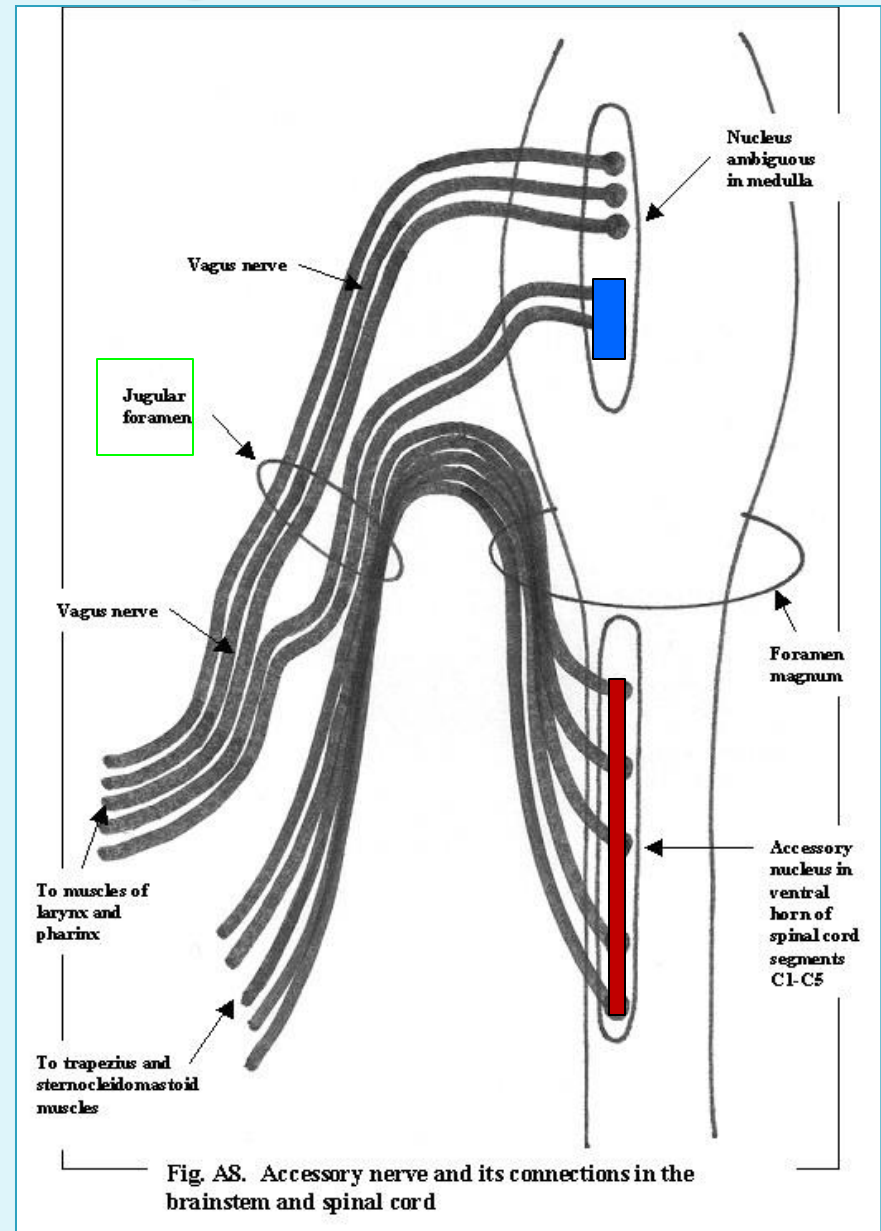
Objectives

At the end of the lecture, the students should be able to:

- List the nuclei related to accessory and hypoglossal nerves in the brain stem.
- Describe the type and site of each nucleus.
- Describe site of emergence and course of accessory and hypoglossal nerves.
- Describe important relations of accessory and hypoglossal nerves in the neck.
- List the branches of accessory and hypoglossal nerves.
- Describe the main motor effects in case of lesion of accessory and hypoglossal nerves.

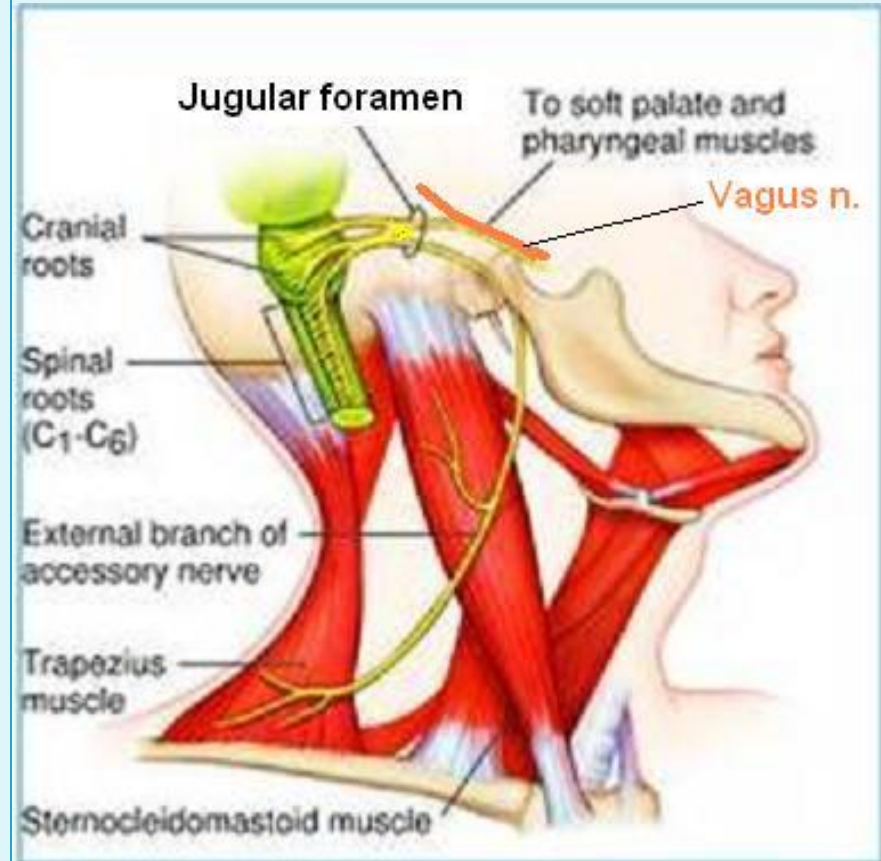
11th CN: Accessory Nerve

- Type: **Motor**
- Has two parts (roots):
 - **Cranial part** carries fibres that originate in the caudal part of **nucleus ambiguus**.
 - **Spinal part** arises from motor neurones in ventral horn of the spinal gray matter at levels **C1-C5 (spinal nucleus)**
- Foramen of exit from skull: **Jugular foramen**



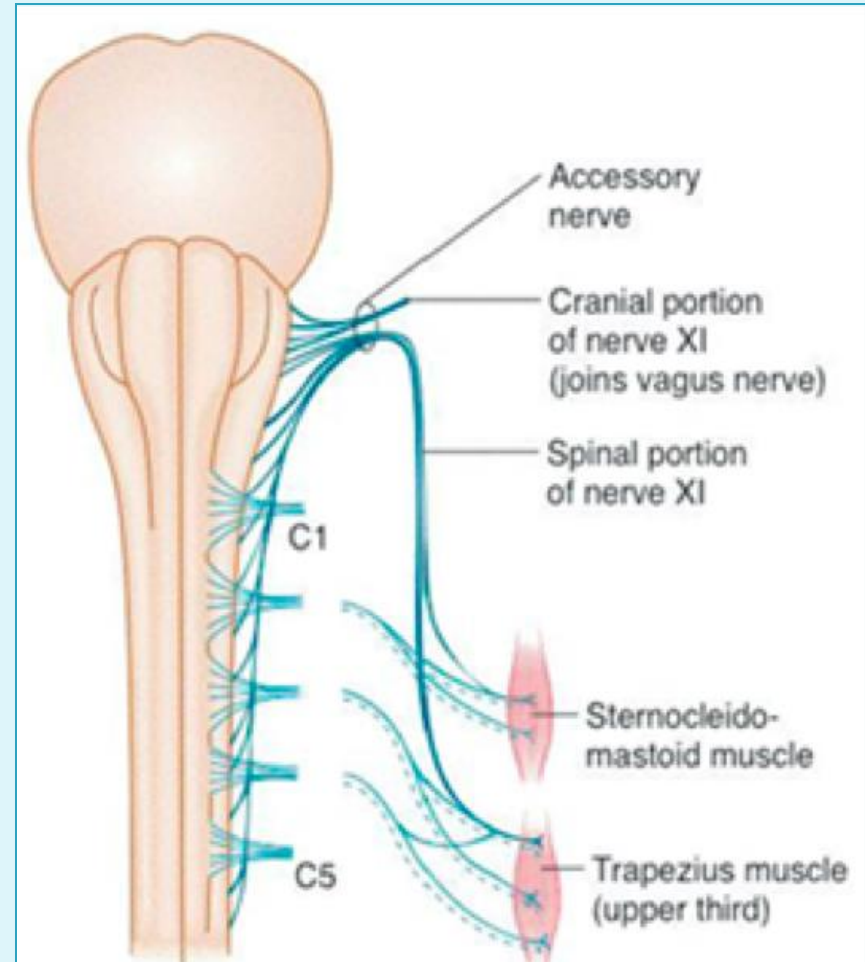
The Cranial Part

- Emerges from lateral aspect of the medulla between olive and inferior cerebellar peduncle, as a linear series of rootlets caudal to rootlets of the vagus nerve.
- At the side of medulla it joins the spinal root briefly
- It separates once again as the nerve leaves the cranial cavity through the **Jugular foramen**.
- At the level of jugular foramen these fibres join the **vagus nerve** and distribute with it to muscles of the soft plate, esophagus, pharynx and larynx

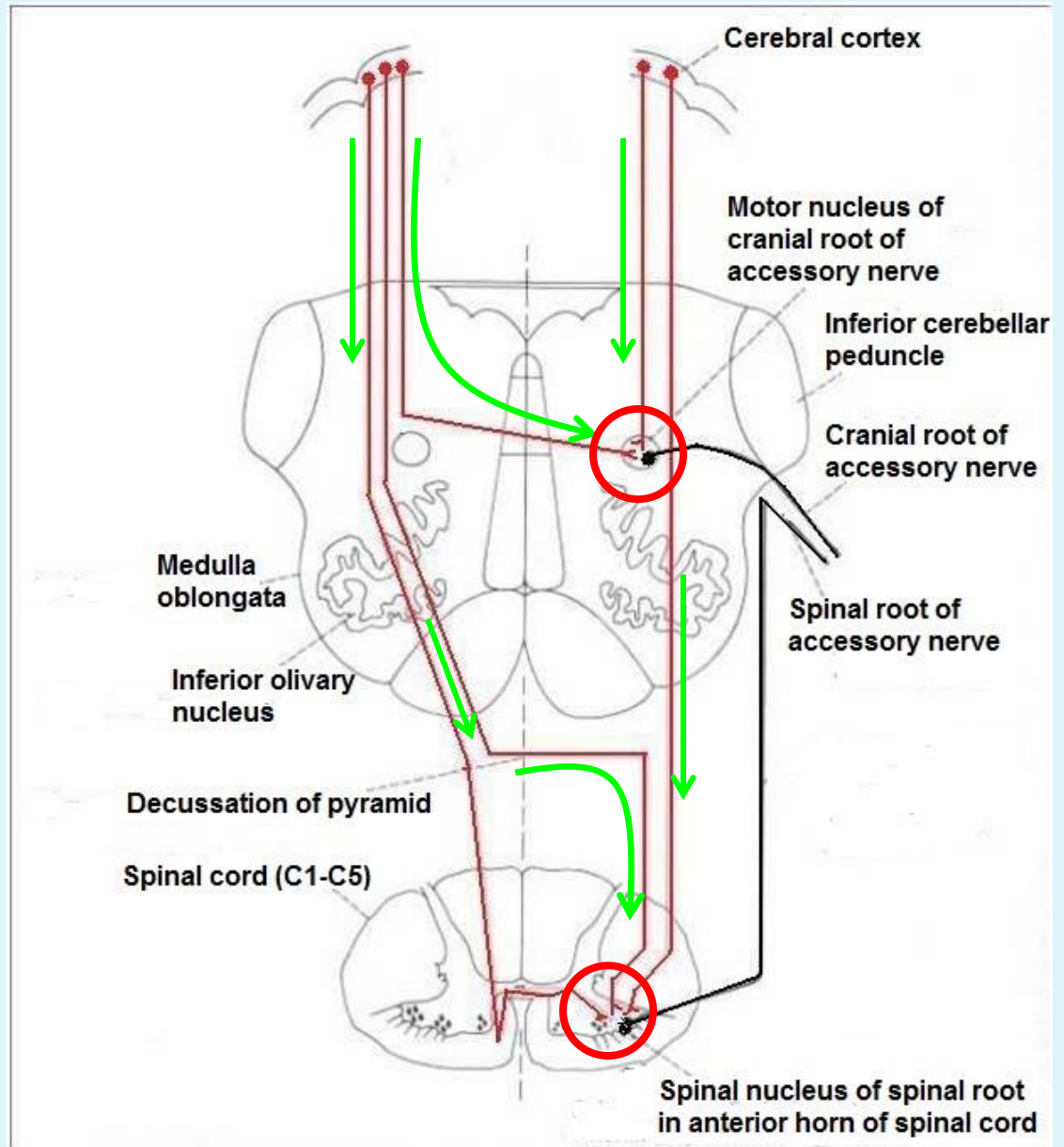


The Spinal Part

- The axons leave the cord via series of rootlets, emerge laterally midway between the dorsal and ventral roots of the spinal nerves.
- Courses rostrally and enter the cranial cavity through the **foramen magnum**, and joins the cranial root briefly
- Separate once again as the nerve leaves the cranial cavity through the **Jugular foramen**.
- Supplies the **sternomastoid** and **trapezius** muscles

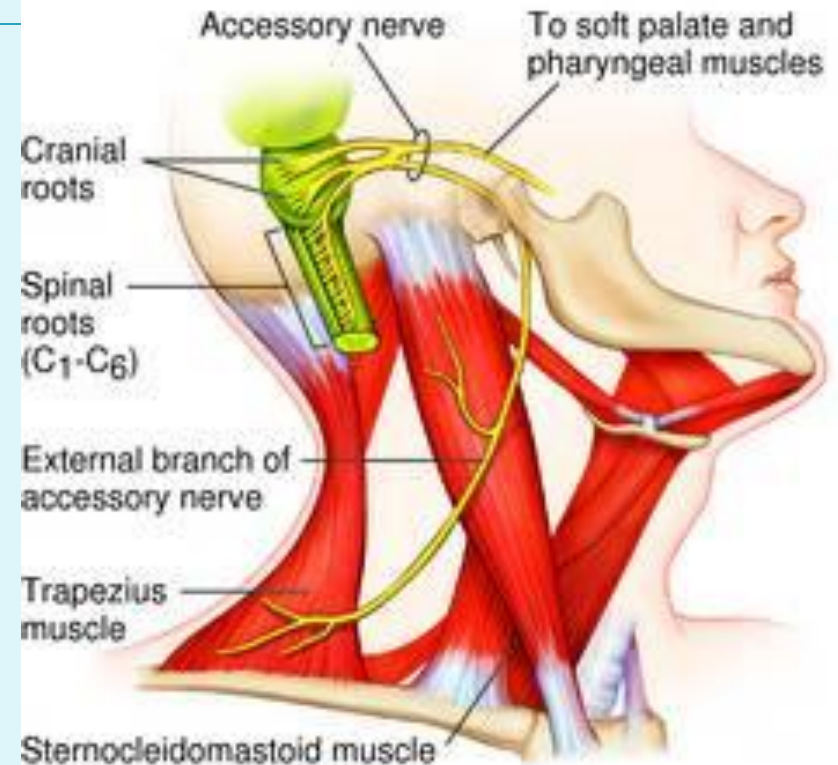


The nucleus ambiguus and the spinal nucleus receive bilateral **corticospinal fibers** (from both cerebral hemispheres)

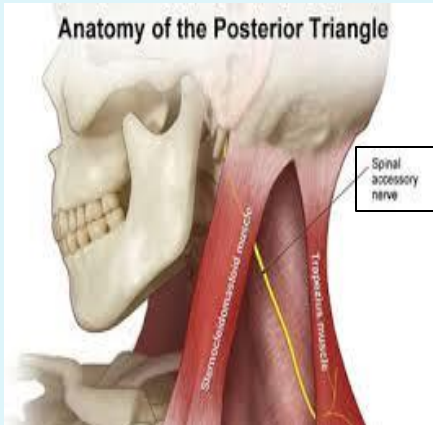


Function:

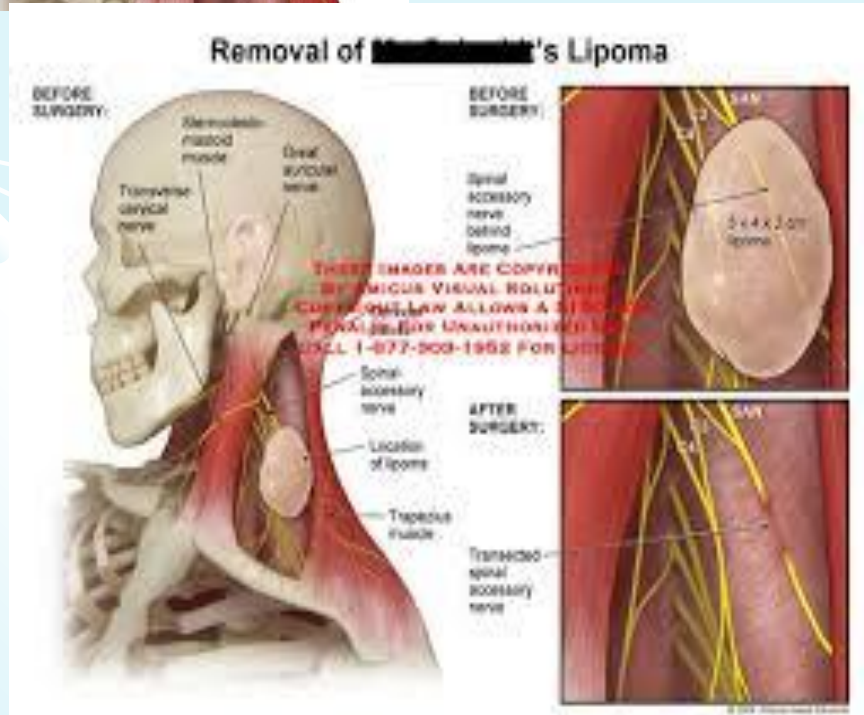
- Movements of the soft palate, larynx, pharynx.
- Controls the movements of neck

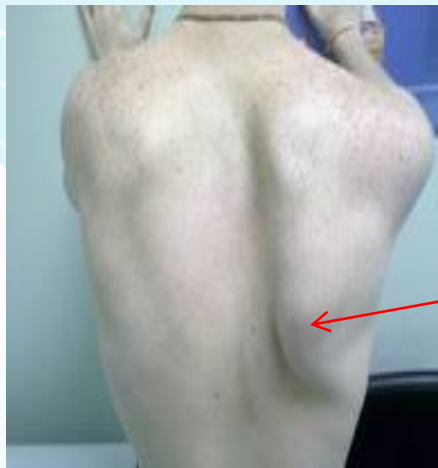
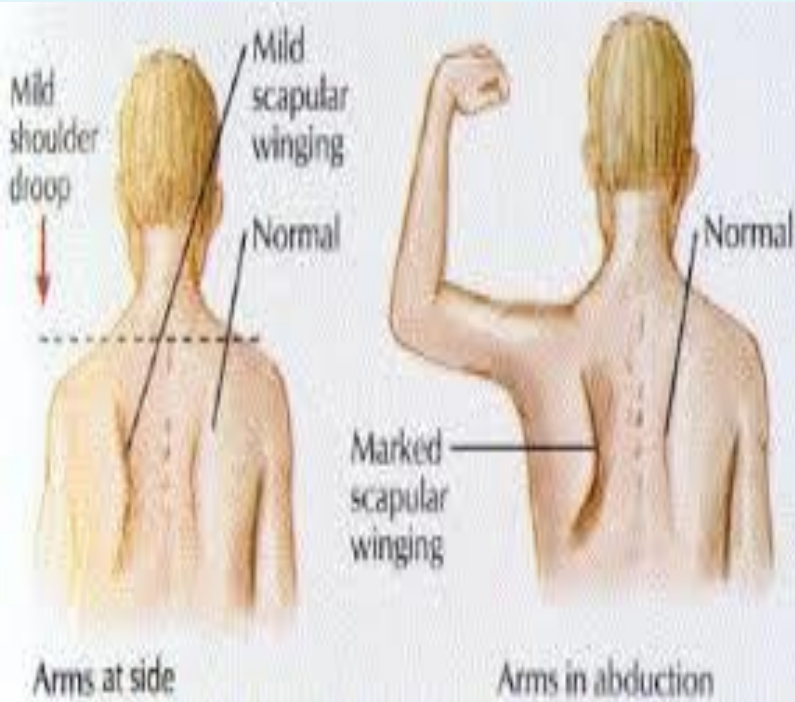
Injury of the Spinal Root of Accessory Nerve



- Causes:
- Because of the relatively superficial position of the nerve in the posterior triangle, it may be damaged by penetrating trauma as stab wounds.
- It is considered the most commonly **iatrogenically** injured nerve as during removal of malignant lymph nodes in the posterior triangle.

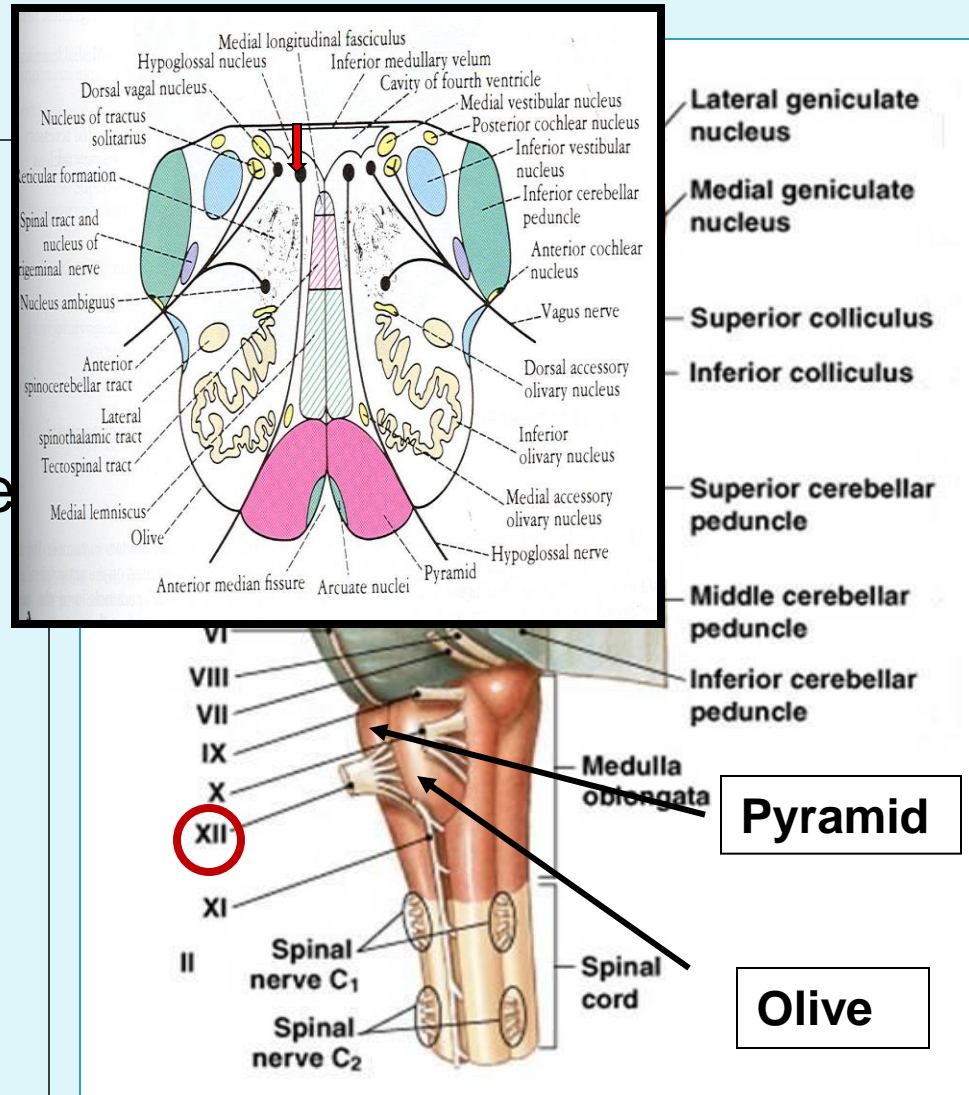




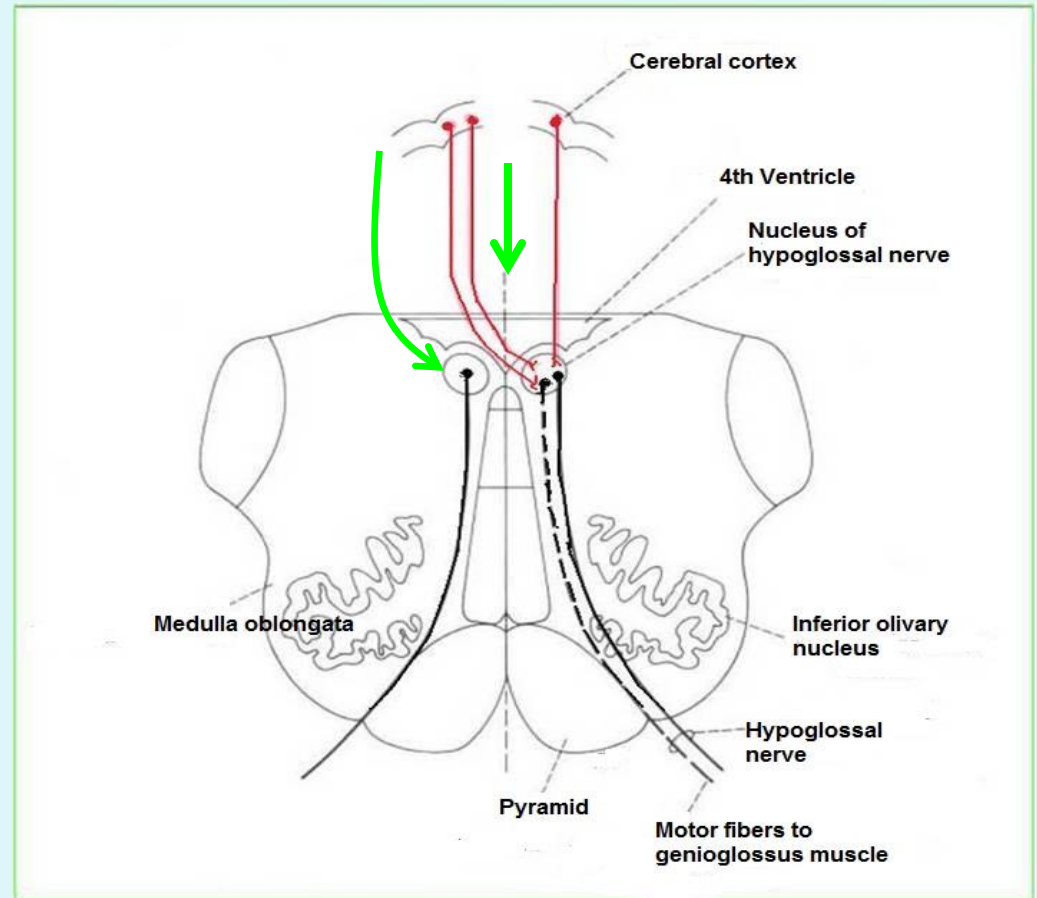
- **Manifestations:**
- It produces atrophy and weakness of trapezius.
- Unilateral paralysis of trapezius is evident by inability to elevate & retract the shoulder, difficulty in elevating the arm.
- Dropping of the shoulder is an obvious sign of injury of the nerve.
- The lesion also causes difficulty in swallowing and speech &
- Inability to turn the head

12th CN: Hypoglossal Nerve

- Type: **Motor**
- Origin: **Hypoglossal nucleus** of the medulla (in the floor of 4th ventricle)
- The fibers emerge from the anterior surface of the medulla oblongata through the **sulcus between the pyramid and the olive**.
- Foramen of exit from skull: **Hypoglossal canal**



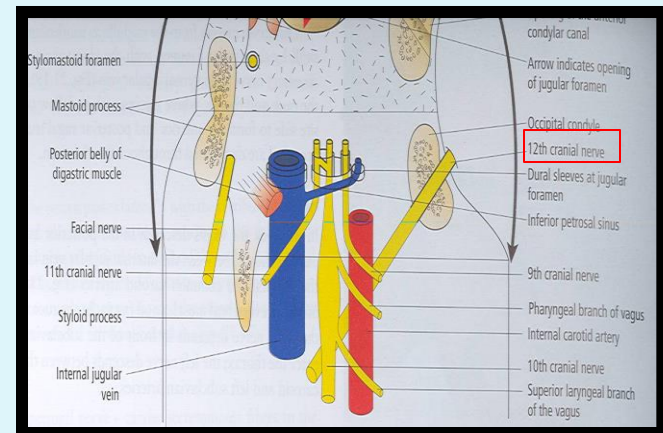
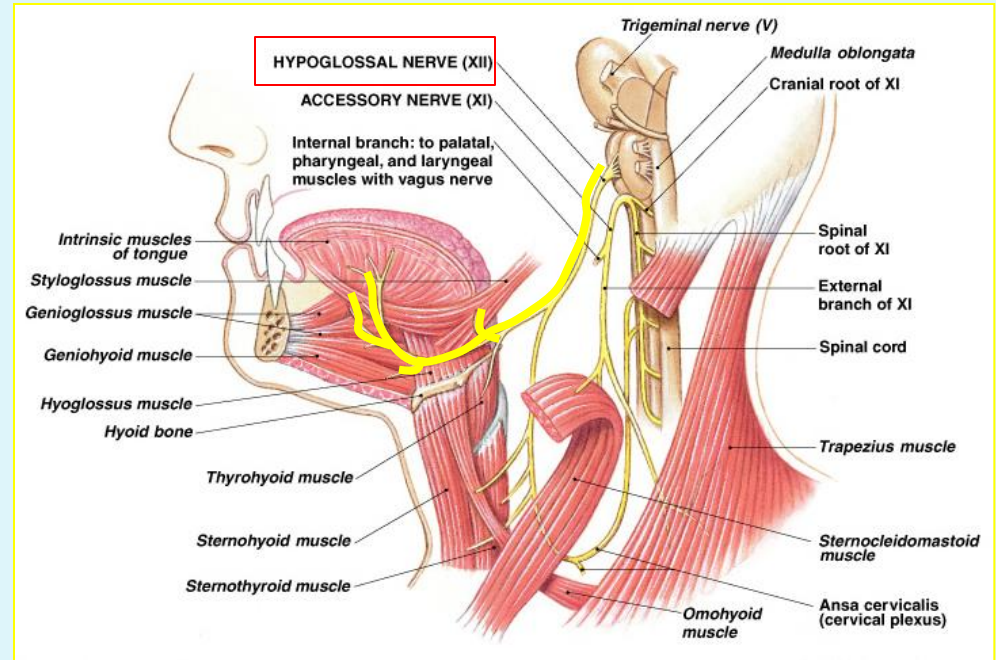
The hypoglossal nucleus receives **corticonuclear** fibers from both cerebral hemispheres **EXCEPT** the region that supplies **genioglossus** muscle (receives contralateral supply only)



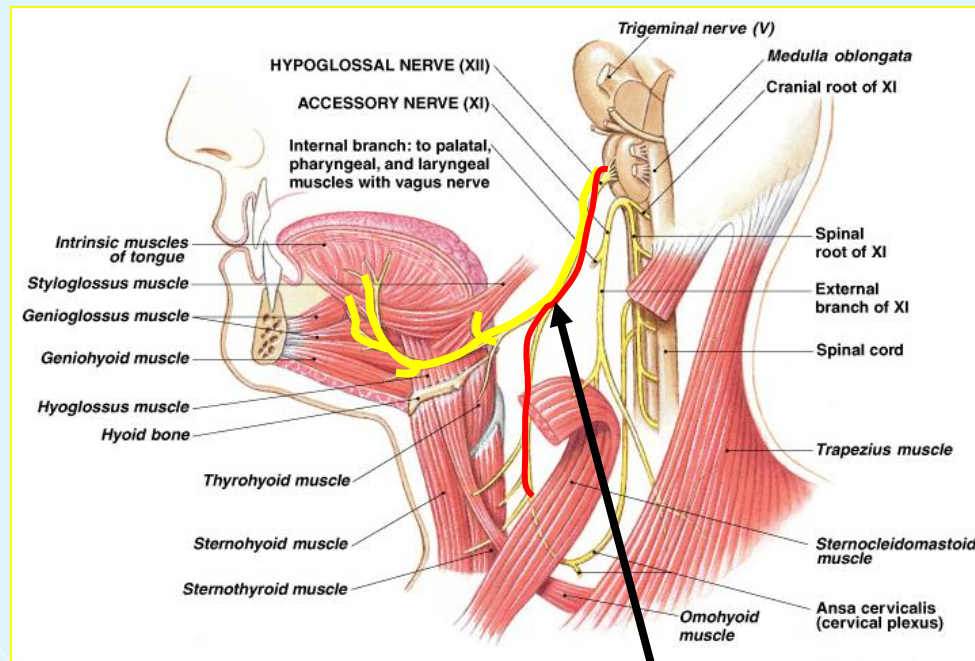
Also receives afferent fibers from **nucleus solitarius** and **trigeminal sensory nucleus**.

Course:

- The nerve courses downward with cervical neuro-vascular bundle (internal carotid artery, internal Jugular vein, vagus nerve)
- Then curves forward behind mandible to supply the tongue



During its initial course, it carries **C1 fibers** which leave in a branch to take part in the formation of **ansa cervicalis** (a loop of nerves supplying neck muscles)



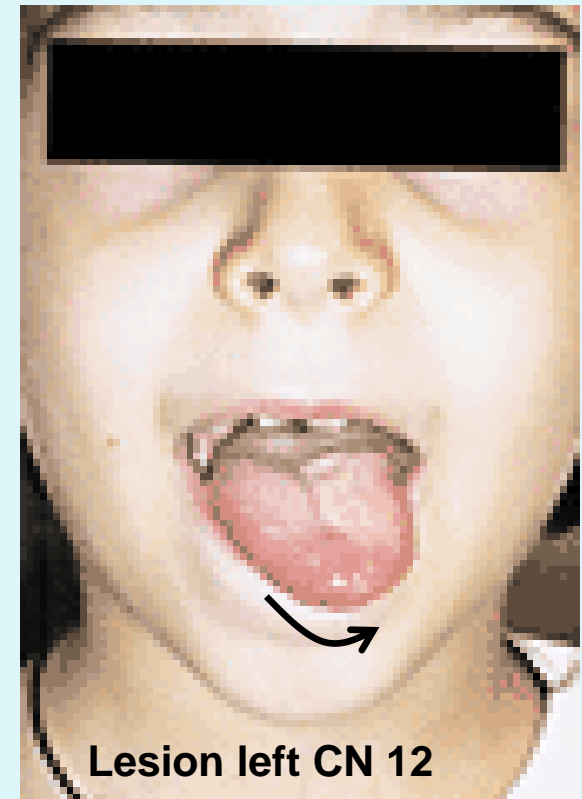C1 fibers

- **Function:**

- 1. Supplies motor innervation to all of the muscles of the tongue except the **palatoglossus** (which is supplied by the vagus nerve).
- So, it **Controls the movements and shape of the tongue during speech and swallowing**
- 2. Carries proprioceptive afferents from the tongue muscles.

- Manifestations of Lesion of the nerve (LMN) :

- Loss of tongue movements
- Difficulty in chewing and speech
- The tongue paralyses, atrophies, becomes shrunken and furrowed on the affected side (LMN paralysis)
- On protrusion, tongue **deviates to the affected side**
- If both nerves are damaged, person can't protrude tongue



THANK U & GOOD LUCK

