

Degenerative brain disease

- The term “Degenerative”:
 - an underlying cellular degeneration of neurons in the brain
- Cause symptoms that depend on the pattern of involvement of the brain

Causes and pathology of dementia

Dementia

- Dementia:
 - The development of memory impairment and other cognitive deficits with preservation of a normal level of consciousness
 - One of the most important public health issues in the industrialized world
 - There are many causes of dementia
 - Regardless of etiology, dementia is not part of normal aging and always represents a pathologic process

Major causes of dementia with examples

- **Primary Neurodegenerative Disorders**
 - Alzheimer disease
 - Lewy body dementia
 - Huntington disease
- **Infections**
 - Prion-associated disorders (e.g. Creutzfeldt-Jakob disease)
 - HIV encephalopathy (AIDS dementia complex)
 - Progressive multifocal leukoencephalopathy

Major causes of dementia with examples

- **Vascular and Traumatic Diseases:**
 - Multi-infarct dementia
 - Global hypoxic-ischemic brain injury
 - Chronic subdural hematomas
- **Metabolic and Nutritional Diseases:**
 - Thiamine deficiency (Wernicke-Korsakoff syndrome)

Major causes of dementia with examples

- **Miscellaneous:**
 - Brain tumors
 - Neuronal storage diseases
 - Toxic injury (e.g. mercury)

So remember !

- While Alzheimer's disease is considered as "degenerative"-that is, reflecting an underlying cellular degeneration of neurons in the brain- not all forms of dementia are degenerative

Alzheimer Disease

- The most common cause of dementia in the elderly
- The disease usually becomes clinically apparent as insidious impairment of higher intellectual function, with alterations in mood and behavior
- Later, severe cortical dysfunction:
 - Progressive disorientation
 - Memory loss
 - Aphasia
 - Over the next 5 to 10 years, the patient becomes profoundly disabled, mute, and immobile
- Death usually occurs from intercurrent pneumonia or other infections

Alzheimer Disease

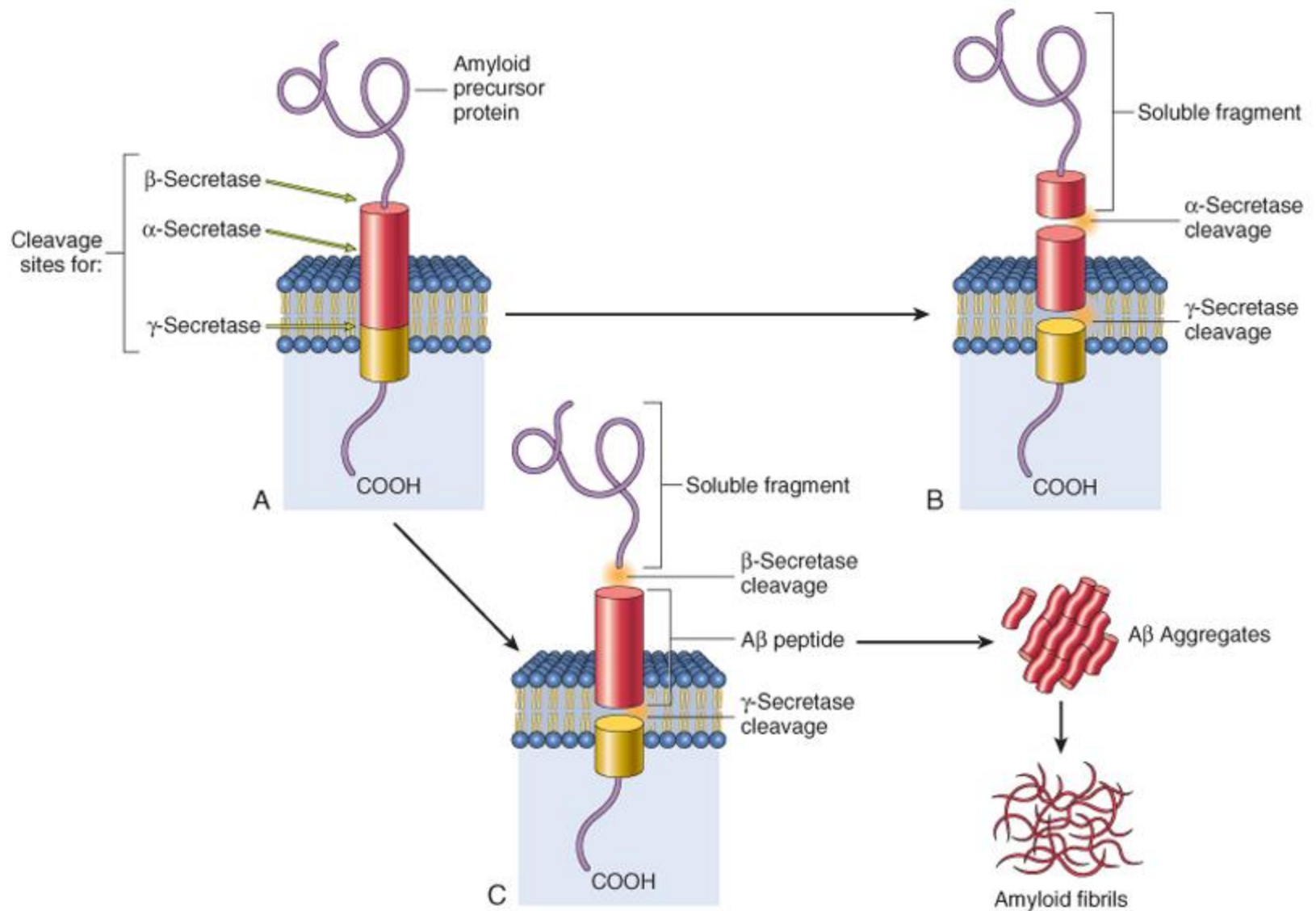
- When considered by age groups, the incidence of Alzheimer disease:
 - 3% for individuals 65 to 74 years old
 - 19% for 75 to 84 years
 - 47% for 85 years or more
- This increasing incidence with age has given rise to major medical, social, and economic problems in countries with a growing number of elderly

Alzheimer Disease

- Although pathologic examination of brain tissue remains necessary for the definitive diagnosis of Alzheimer disease, the combination of clinical assessment and modern radiologic methods allows accurate diagnosis in 80% to 90% of cases

Alzheimer Disease

- Most cases are sporadic
- At least 5% to 10% are familial
- In general, patients rarely become symptomatic before 50 years of age, but early onset can be seen with some of the heritable forms
- Evidence from familial forms of the disease indicates that the accumulation of a peptide (β amyloid, or $A\beta$) in the brain initiates a chain of events that result in the morphologic changes of Alzheimer disease and dementia



Alzheimer Disease

- A β peptide is derived from a larger membrane protein known as amyloid precursor protein (APP), which is processed in either of two ways
 - It can be cleaved by two enzymes, α -secretase and γ -secretase, in a process that prevents formation of A β
 - It can be cut by β -site APP-cleaving enzyme and γ -secretase to generate A β
- Generation and accumulation of A β occur slowly with advancing age

Alzheimer Disease

- **Mutations** in APP or in components of γ -secretase (presenilin-1 or presenilin-2) lead to early onset familial Alzheimer disease by increasing the rate at which $A\beta$ accumulates
- Alzheimer disease occurs in almost all patients with trisomy 21 (Down syndrome)-where the gene encoding APP is located-who survive beyond 45 years (due to APP gene **dosage** effects)

Alzheimer Disease

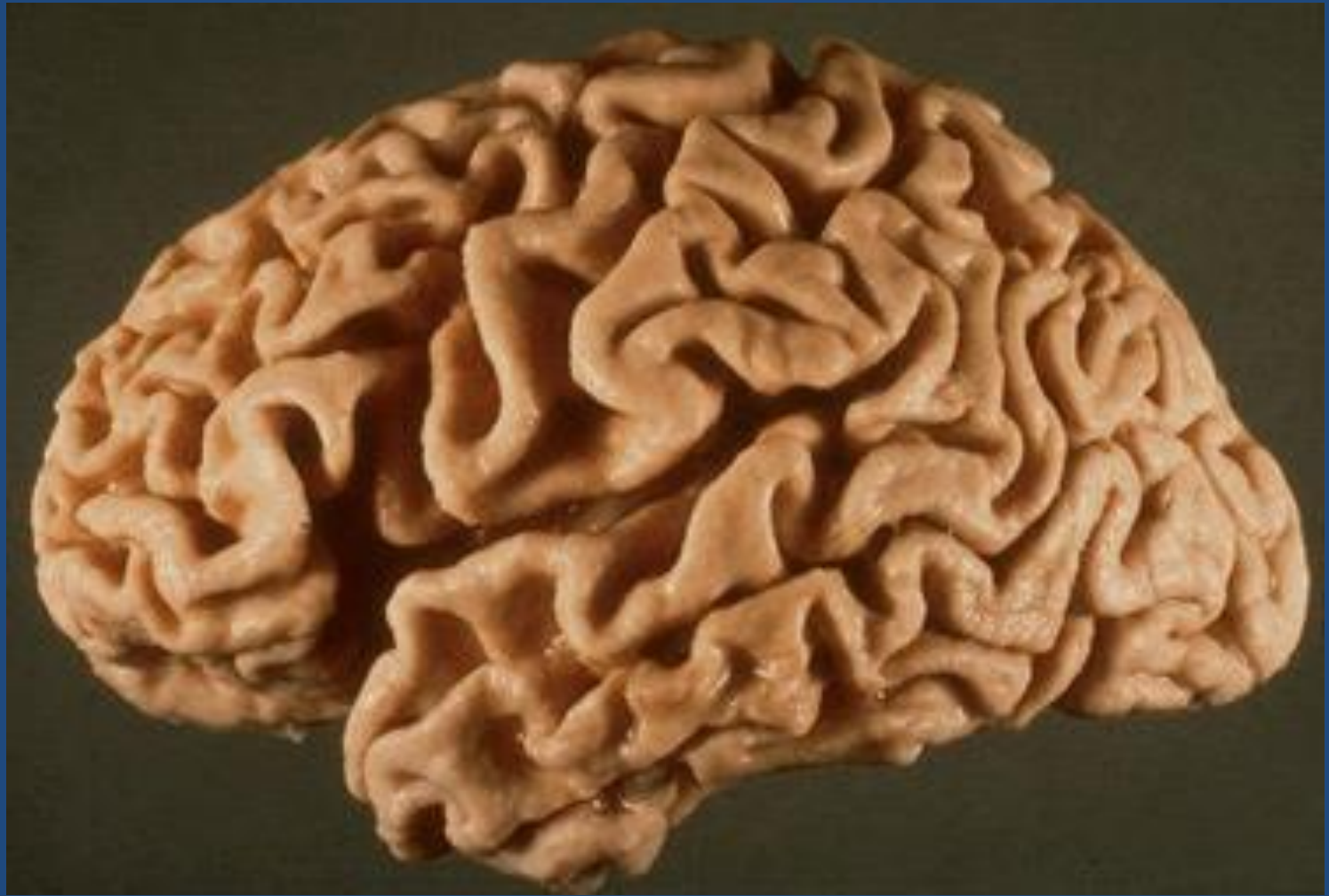
- The search for genes associated with **typical**, sporadic Alzheimer disease is beginning to identify genetic associations that may provide new clues about the pathogenesis of the disease:
 - An allele of apolipoprotein, called $\epsilon 4$ (ApoE4), is associated with as many as 30% of cases, and is thought to both increase the risk and lower the age of onset of the disease
 - ApoE4 may contribute to the deposition of $A\beta$, but how it does so is not known
 - Another gene, called *SORL1*, has recently been found to also be associated with late-onset Alzheimer disease
 - Deficiency of the SORL1 protein may alter the intracellular trafficking of APP, shuttling it to a compartment where the $A\beta$ peptide is generated by enzymatic cleavage, the net result being increased generation of this pathogenic peptide

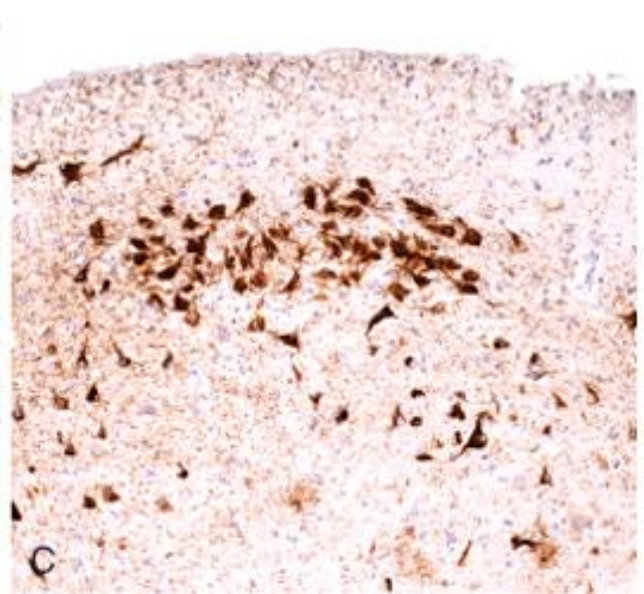
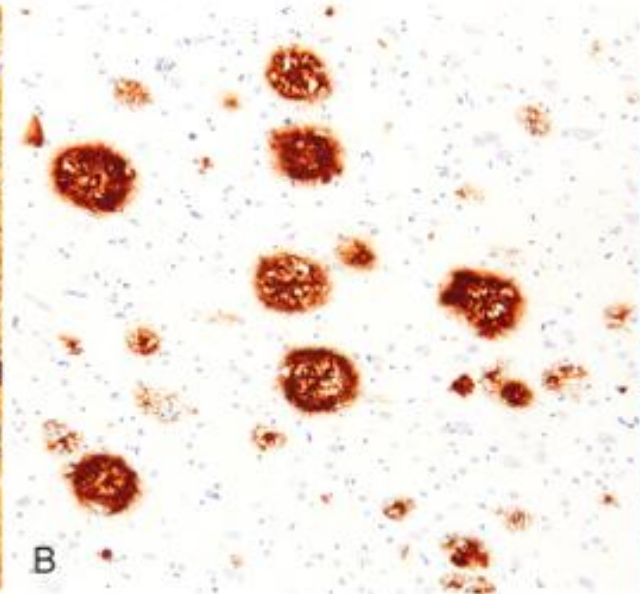
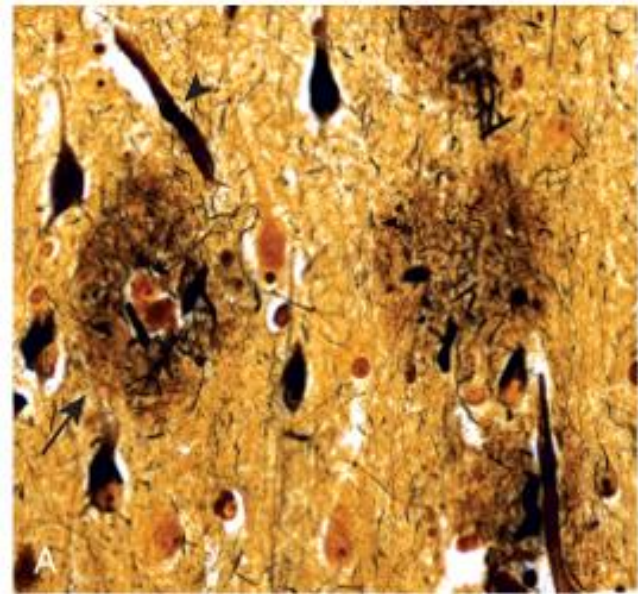
Alzheimer Disease

- Accumulation of $A\beta$ has several effects on neurons and neuronal function:
 - Small aggregates of $A\beta$ can alter **neurotransmission**, and the aggregates can be toxic to neurons and synaptic endings
 - Larger deposits, in the form of **plaques**, also lead to neuronal death, elicit a local inflammatory response that can result in further cell injury, and may cause altered region-to-region communication through mechanical effects on axons and dendrites

Alzheimer Disease

- The presence of $A\beta$ also leads neurons to hyperphosphorylate the microtubule binding protein “tau”
 - With this increased level of phosphorylation, tau redistributes within the neuron from the axon into dendrites and cell body and aggregates into tangles
 - This process also results in neuronal dysfunction and cell death
 - The anatomic distribution of these changes, which occur roughly in parallel, are responsible for the clinical signs and symptoms; they appear to develop well in advance of clinical presentation





Alzheimer Disease

- Macroscopic:
 - a variable degree of cortical atrophy with widening of the cerebral sulci that is most pronounced in the frontal, temporal, and parietal lobes
 - With significant atrophy, there is compensatory ventricular enlargement (hydrocephalus ex vacuo)

Alzheimer Disease

- Microscopic:
 - **plaques** (a type of extracellular lesion)
 - **neurofibrillary tangles** (a type of intracellular lesion)
 - Because these may also be present to a lesser extent in the brains of elderly nondemented individuals, the current criteria for a diagnosis of Alzheimer disease are based on a combination of clinical and pathologic features

Alzheimer Disease

- There is a fairly constant pattern of progression of involvement of brain regions pathologic changes:
 - » earliest in the entorhinal cortex → then spread through the hippocampal formation and isocortex → then extend into the neocortex
- Silver staining methods or immunohistochemistry are extremely helpful in assessing the true burden of these changes in a brain

→ *What is immunohistochemistry?*

Alzheimer Disease

- **Neuritic plaques:**

- » Focal, spherical collections of dilated, tortuous, silver-staining neuritic processes (dystrophic neurites), often around a central amyloid core
- » Plaques can be found in the hippocampus and amygdala as well as in the neocortex, although there is usually relative sparing of primary motor and sensory cortices until late in the course of the disease
- » The amyloid core contains A β
- » A β deposits can also be found that lack any surrounding neuritic reaction, termed *diffuse plaques*

Alzheimer Disease

- **Neurofibrillary tangles:**

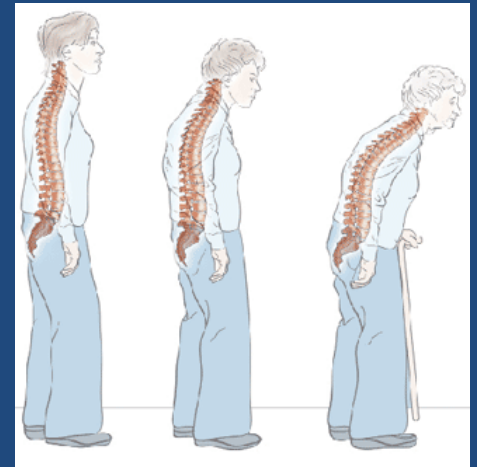
- » Bundles of paired helical filaments visible as basophilic fibrillary structures in the cytoplasm of the neurons that displace or encircle the nucleus
- » Tangles can remain after neurons die, then becoming a form of extracellular pathology
- » They are commonly found in cortical neurons, especially in the entorhinal cortex, as well as in other sites such as pyramidal cells of the hippocampus, the amygdala and the basal forebrain
- » A major component of paired helical filaments is abnormally hyperphosphorylated forms of the protein **tau**
- » Tangles are not specific to Alzheimer disease, being found in other degenerative diseases as well.

Pathogenesis and pathology of parkinsonism

Pathology

Parkinsonism

- A clinical syndrome characterized by:
 - diminished facial expression (masked facies)
 - stooped posture
 - slowness of voluntary movement
 - festinating gait (progressively shortened, accelerated steps)
 - rigidity
 - "pill-rolling" tremor



Parkinsonism

- Motor disturbance that is seen in a number of conditions that share damage to dopaminergic neurons of the substantia nigra or their projection to the striatum

Parkinsonism

- Parkinsonism can be induced by:
 - drugs that affect these neurons, particularly dopamine antagonists and toxins
 - post-encephalitic parkinsonism (associated with the influenza pandemic)
 - *Idiopathic Parkinson disease (the most common neurodegenerative disease associated with parkinsonism)*
 - other neurodegenerative diseases
 - *rare: head trauma, stroke*

Parkinson's disease

- Diagnosis:
 - progressive parkinsonism
 - absence of a toxic or other known underlying etiology
 - clinical response to L-dihydroxyphenylalanine (L-DOPA) treatment

Parkinson's disease

- 6-8 decades
- more than 2% in North America develop disease
- men more than women
- $22/100,000$ = crude prevalence rate in Saudi population

Parkinson's disease

- While most Parkinson disease is sporadic, there are both autosomal dominant and recessive forms of the disease
- Genetic analysis has identified specific causal mutations, For example α -synuclein mutations cause autosomal dominant Parkinson disease as can gene duplications and triplications

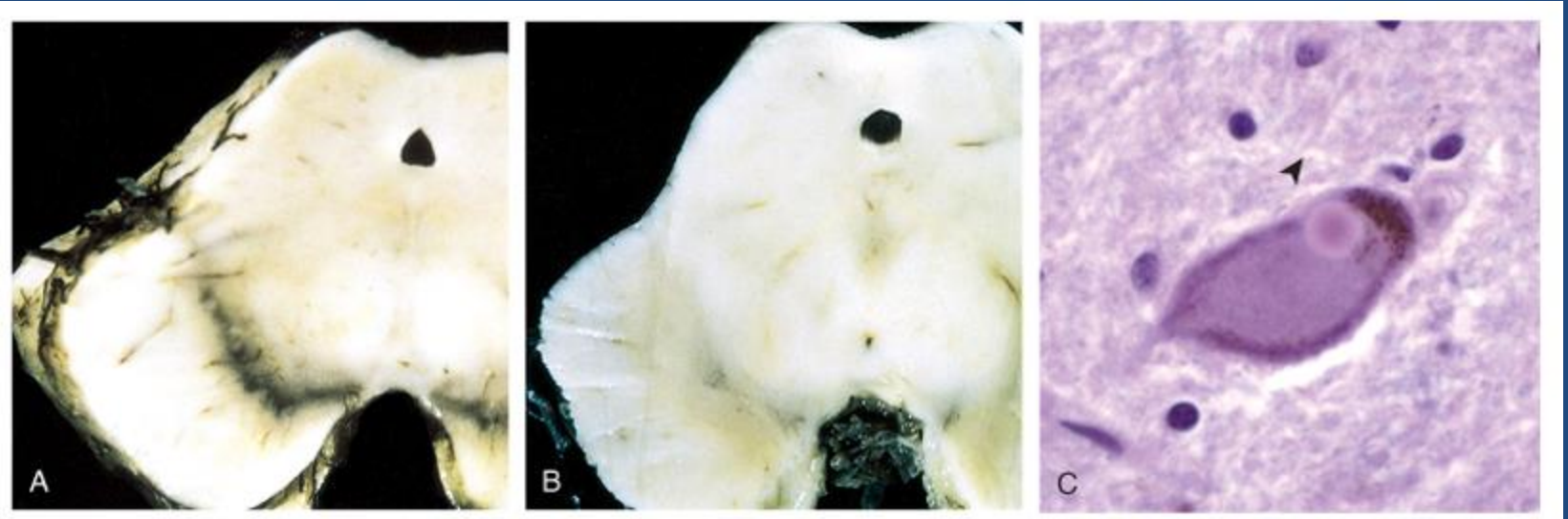
Parkinson's disease

- Even in cases of Parkinson disease not caused by mutations in this gene, the diagnostic feature of the disease-the Lewy body-is an inclusion containing α -synuclein
- This is a widely expressed neuronal protein that is involved in synaptic transmission and other cellular processes

Parkinson's disease

- How the alterations in sequence or protein levels result in disease is unclear
- The presence of α -synuclein in the Lewy bodies has suggested that defective degradation of the protein in the proteasome might play a role
- This is supported by the identification of two other genetic loci for Parkinson disease:
 - which involve genes encoding parkin (an E3 ubiquitin ligase)
 - UCHL-1 (an enzyme involved in recovery of ubiquitin from proteins targeted to the proteasome)

Parkinson's disease



Parkinson's disease

- Macroscopic:
 - pallor of the substantia nigra and locus ceruleus
- Microscopic:
 - loss of the pigmented, neurons in these regions
 - associated with gliosis
 - **Lewy bodies** may be found in some of the remaining neurons

Lewy bodies

- Single or multiple, intracytoplasmic, eosinophilic, round to elongated inclusions that often have a dense core surrounded by a pale halo
- Ultrastructurally, Lewy bodies are composed of fine filaments, densely packed in the core but loose at the rim
- These filaments are composed of α -synuclein, along with other proteins

Parkinson's disease

- Clinical Features
 - L-DOPA therapy is often extremely effective in symptomatic treatment, but it does not significantly alter the progressive nature of the disease
 - Over time, L-DOPA becomes less effective at providing the patient with symptomatic relief and begins to cause fluctuations in motor function on its own

Parkinson's disease

- usually progresses over 10 to 15 years
- eventual severe motor slowing to the point of near immobility
- death is usually the result of intercurrent infection or trauma from frequent falls caused by postural instability

Parkinson's disease

- About 10% to 15% of individuals with Parkinson disease develop dementia, with the incidence increasing with advancing age
- Characteristic features of this disorder include a fluctuating course and hallucinations
- While many affected individuals also have pathologic evidence of Alzheimer disease, the dementia in other Parkinson disease patients is attributed to widely disseminated Lewy bodies in the cerebral cortex
- When dementia arises within 1 year of the onset of motor symptoms, it is referred to *Lewy body dementia*

Parkinson disease

- Parkinson disease has been targeted for many novel therapeutic approaches
- Currently used neurosurgical approaches to Parkinson disease include the placement of lesions in the extrapyramidal system to compensate for the loss of nigrostriatal function or placement of stimulating electrodes - deep brain stimulation

