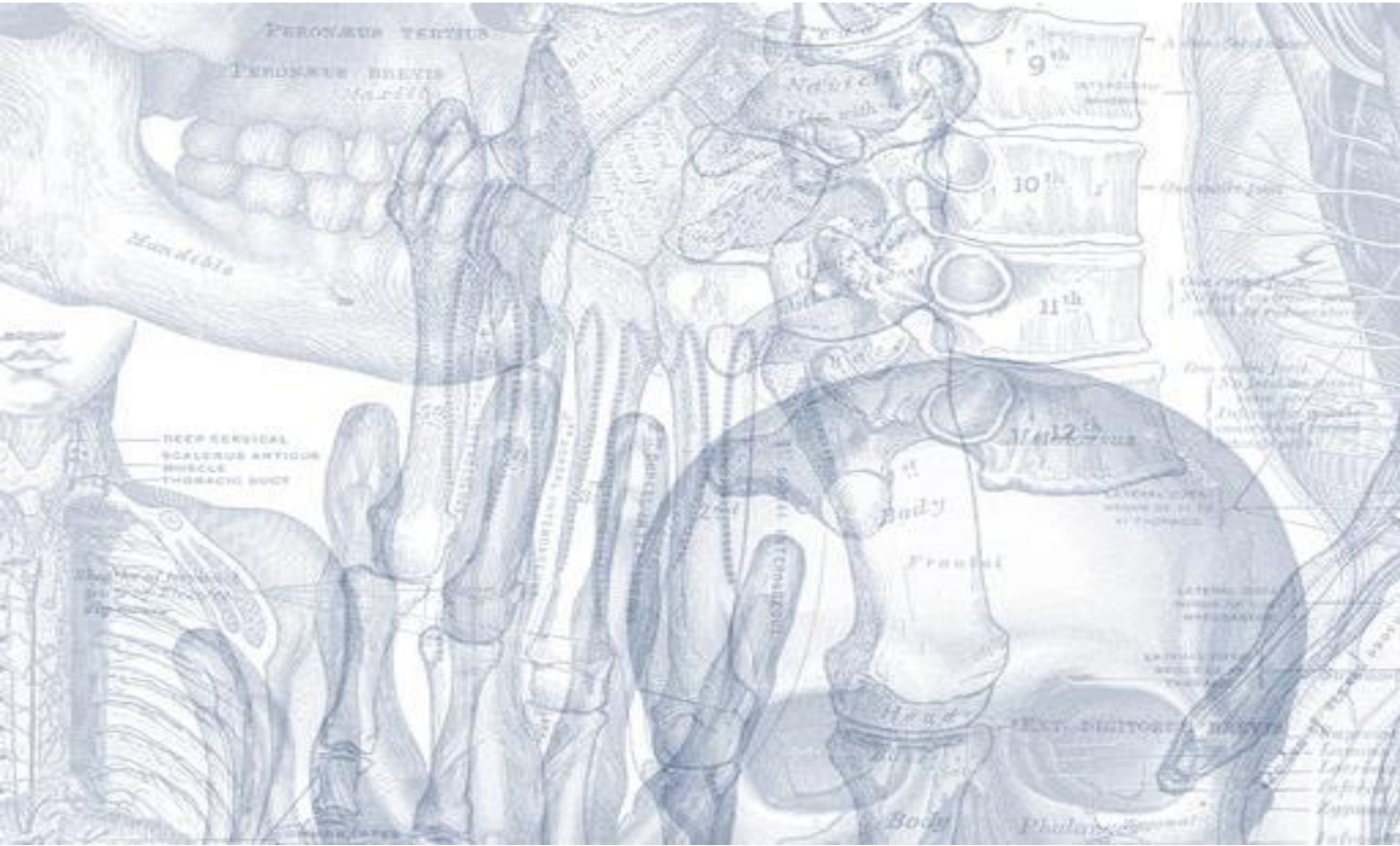


بِسْمِ اللَّهِ الرَّحْمَنِ الرَّحِيمِ



Cranial Nerves XI-XII (Accessory & Hypoglossal Nerves)

Please view our [Editing File](#) before studying this lecture to check for any changes.

Color Code

- **Important**
- **Doctors Notes**
- **Notes/Extra explanation**

Objectives

At the end of the lecture, the students should be able to:

- ✓ List the nuclei related to accessory and hypoglossal nerves in the brain stem.
- ✓ Describe the type and site of each nucleus.
- ✓ Describe site of emergence and course of accessory and hypoglossal nerves.
- ✓ Describe important relations of accessory and hypoglossal nerves in the neck.
- ✓ List the branches of accessory and hypoglossal nerves.
- ✓ Describe the main motor effects in case of lesion of accessory and hypoglossal nerves.

Extra Slide: Mnemonics And Pictures To Help Memorise The Cranial Nerves



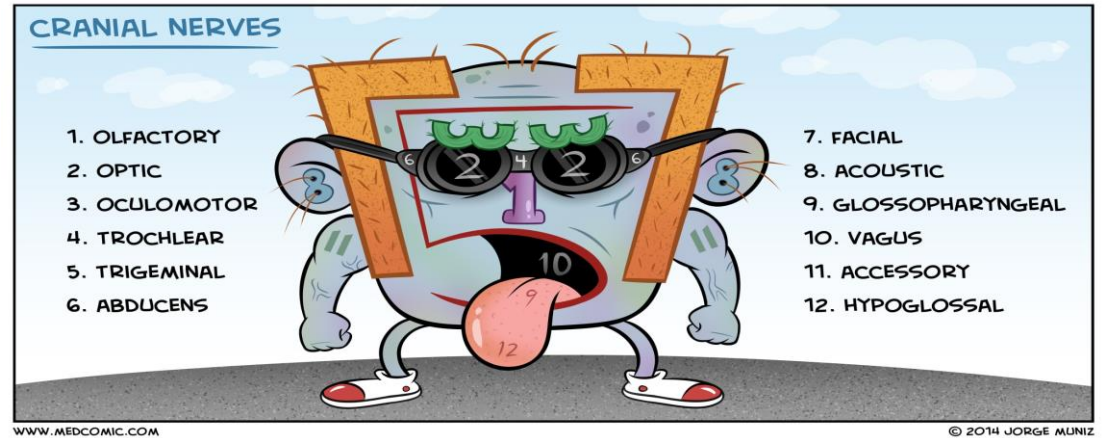
07:32

ON OCCASION OUR TRUSTY TRUCK ACTS
FUNNY, VERY GOOD VEHICLE ANYHOW

O O T T A F V G V A H-

olfactory, optic, oculomotor, trochlear, trigeminal,
abducens, facial, vestibulocochlear, glossopharyngeal,
vagus, accessory, hypoglossal

I Olfactory Smell 	II Optic Vision 	III Oculomotor Upward Medial Downward Up In
IV Trochlear Down and In 	V Trigeminal Touch Forehead and Cheek Clench Teeth 	VI Abducens Look Side to Side
VII Facial Taste for the Anterior 2/3 of Tongue Smile 	VIII Acoustic Hearing Equilibrium 	IX Glossopharyngeal Posterior 1/3 of the Tongue Speech
X Vagus Defecation Slowed Heart Rate 	XI Spinal Accessory Shoulder Shrug 	XII Hypoglossal Tongue Movement



CRANIAL NERVE MNEMONIC

S = Sensory M = Motor B = Both

O Olfactory	O On	S Some
O Optic	O Old	S Say
O Oculomotor	O Olympus	M Marry
T Trochlear	T Towering	M Money
T Trigeminal	T Tops	B But
A Abducens	A A	M My
F Facial	F Finn	B Brother
A Acoustic	A And	S Says
G Glossopharyngeal	G German	B Big
V Vagus Nerve	V Viewed	B Brains
S Spinal	S Some	M Matter
H Hypoglossal	H Hops	M More



Accessory (XI) 11th Cranial Nerve

- Type: **Motor**
- Has two parts (roots)*:

• Cranial part carries fibres that originate in the caudal part of nucleus ambiguus.

• Spinal part arises from motor neurones in ventral horn of the spinal gray matter at levels C1-C5 (spinal nucleus)

- Foramen of exit from skull: Jugular foramen.

* يختلف هذا العصب بأنه الوحيد بين الباقيين إلي يأخذ من جزئيين

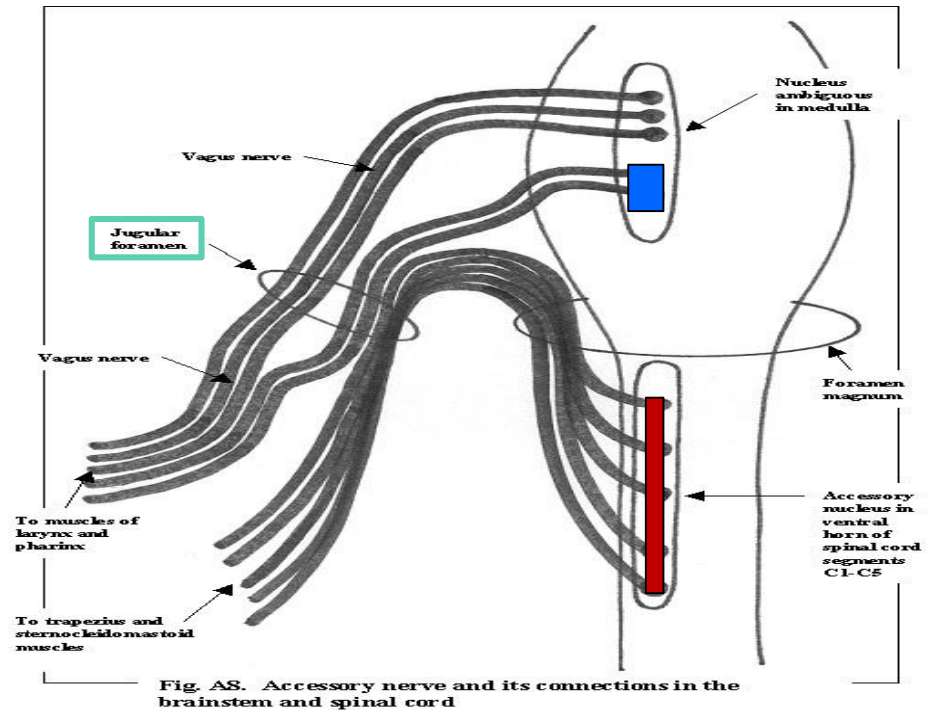
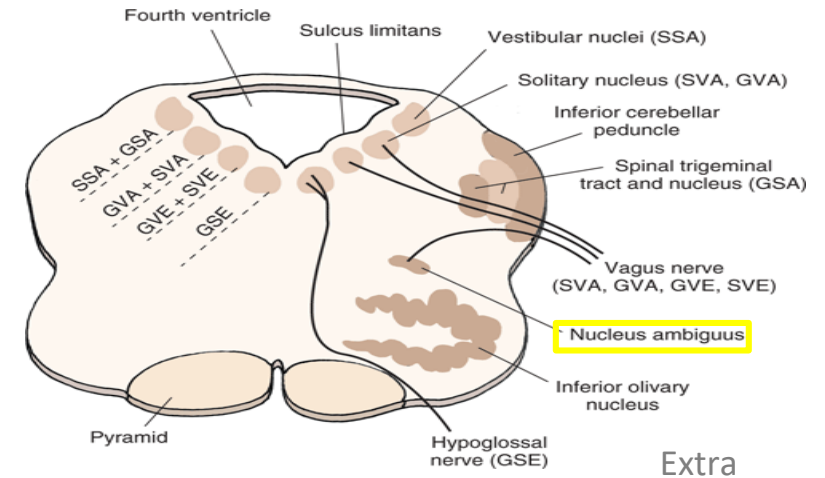
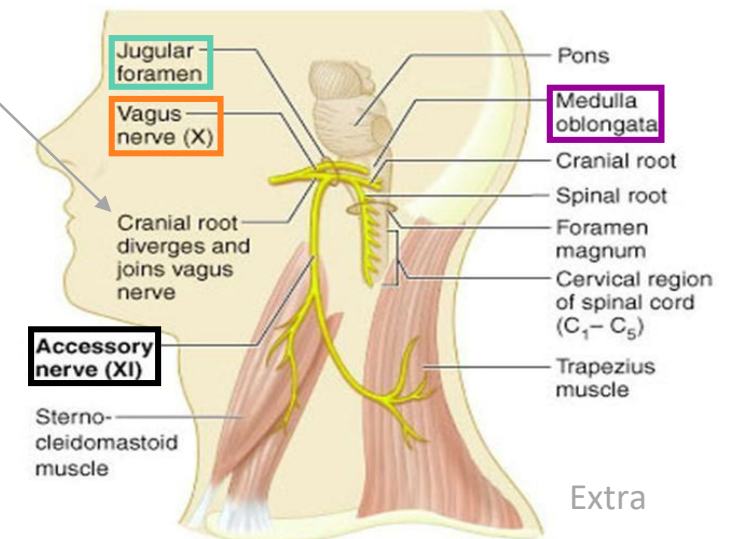
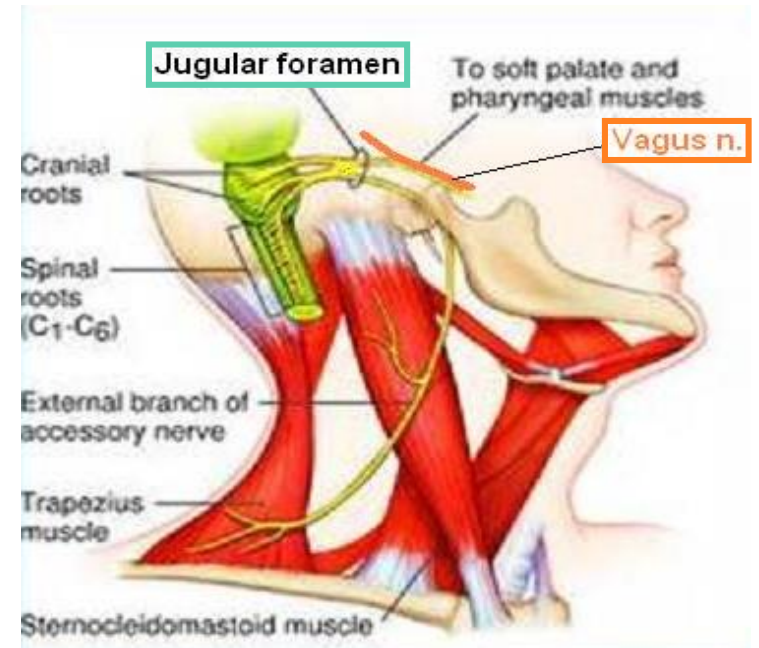


Fig. AS. Accessory nerve and its connections in the brainstem and spinal cord

Accessory (XI) 11th Cranial Nerve Cranial Part

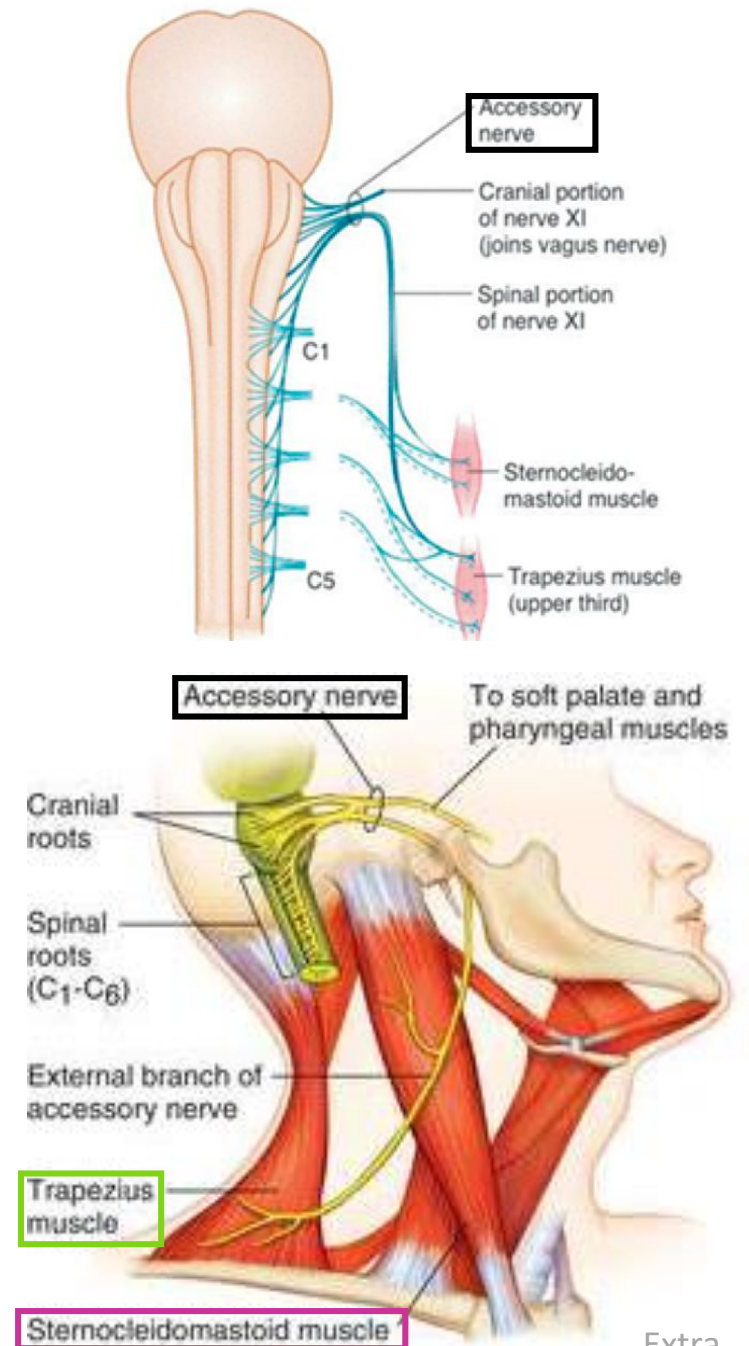
- Emerges from lateral aspect of the medulla as a linear series of rootlets *caudal* to rootlets of the vagus nerve.
- At the side of medulla it *joins the spinal root briefly*.
- It separates once again as the nerve leaves the cranial cavity through the Jugular foramen.
- At the level of jugular foramen these fibres *join the vagus nerve* and distribute with it to muscles of the soft plate, esophagus, pharynx and larynx.



Accessory (XI) 11th Cranial Nerve Spinal Part

- The axons leave the cord via series of rootlets, emerge laterally midway between the dorsal and ventral roots of the spinal nerves.
- Courses rostrally and enter the cranial cavity* through the **foramen magnum**, and joins the cranial root briefly
- Separates once again as the nerve leaves the cranial cavity through the **Jugular foramen**. Then descend to the posterior triangle of neck
- Supplies the sternomastoid and trapezius muscles

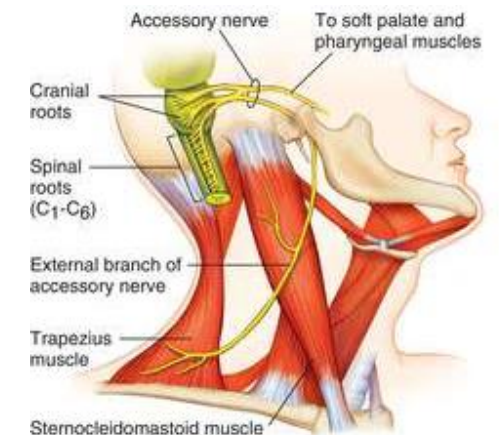
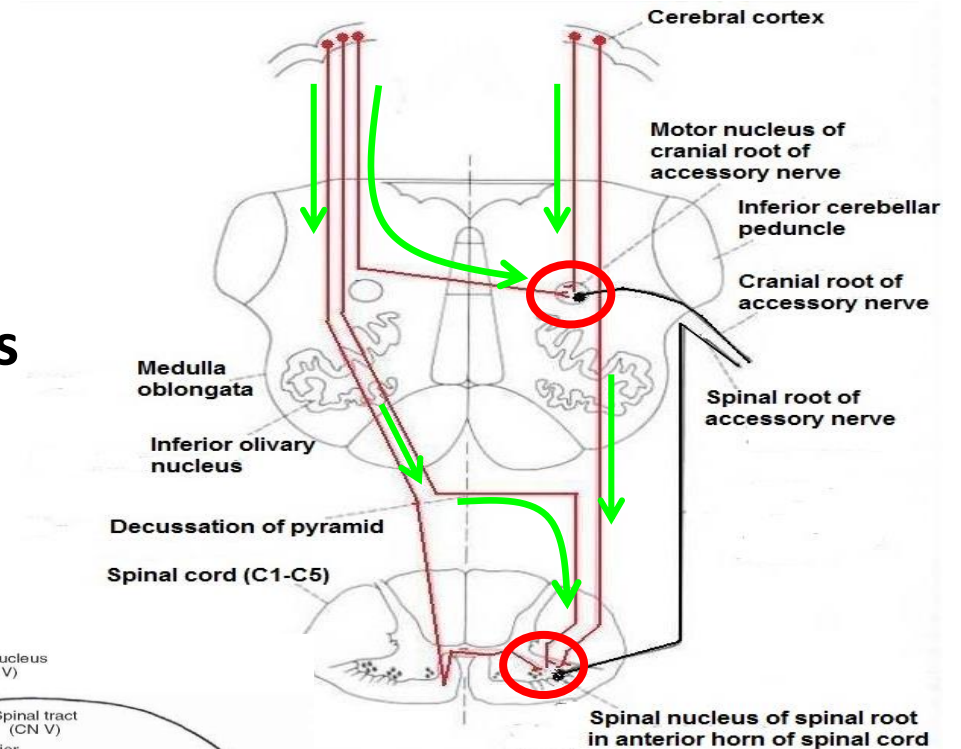
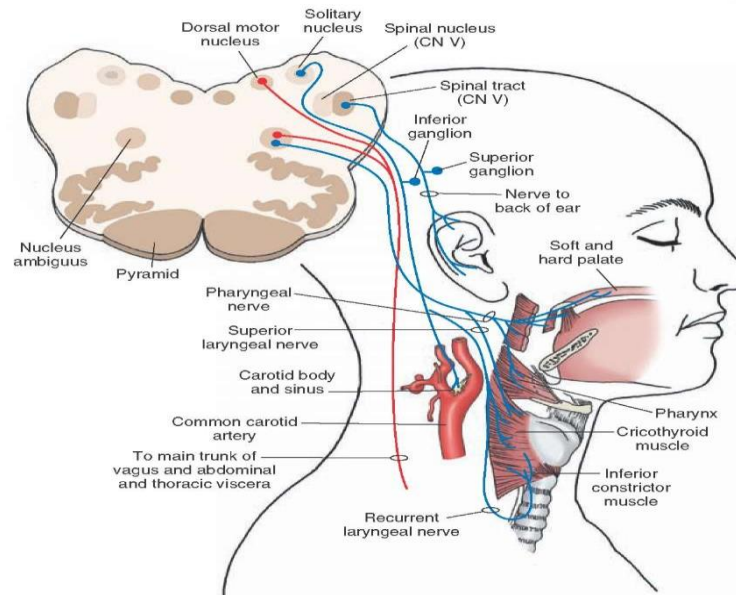
*It is the only nerve that enters the cranial cavity, all others exit.



Accessory (XI) 11th Cranial Nerve

- The nucleus ambiguus and the spinal nucleus receive **bilateral corticonuclear** or **corticospinal fibers** (from both cerebral hemispheres).

- Function:
 - Movements of the soft palate, larynx, pharynx (cranial part).
 - Controls the movements of neck (spinal part) “via the sternomastoid and trapezius muscles”.

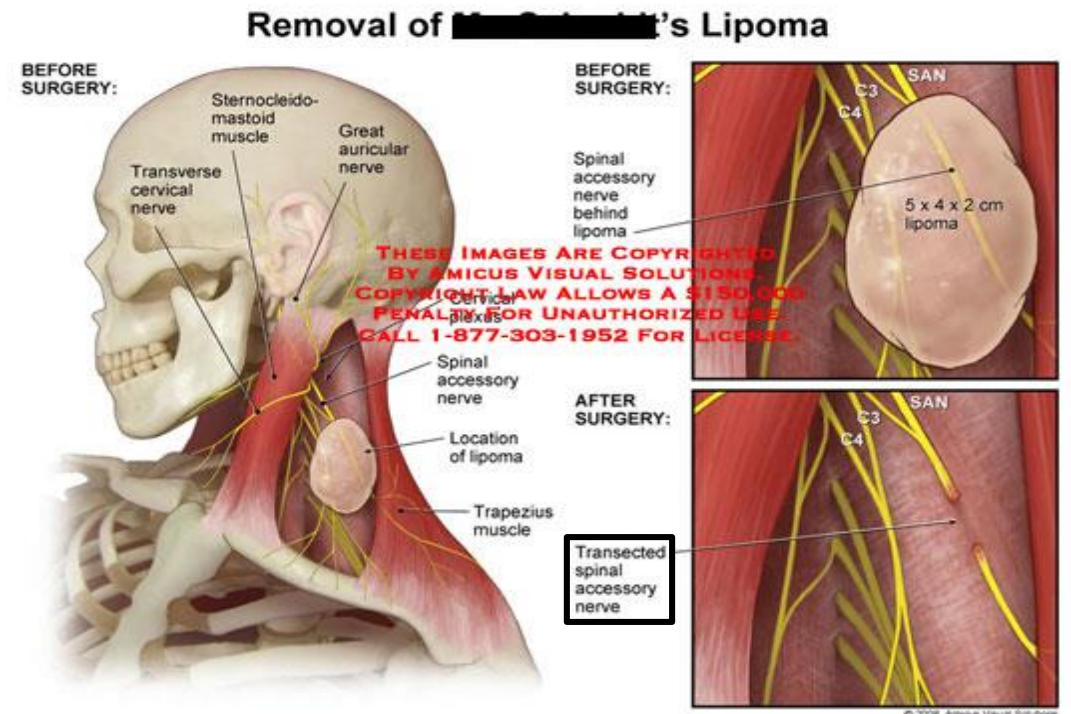
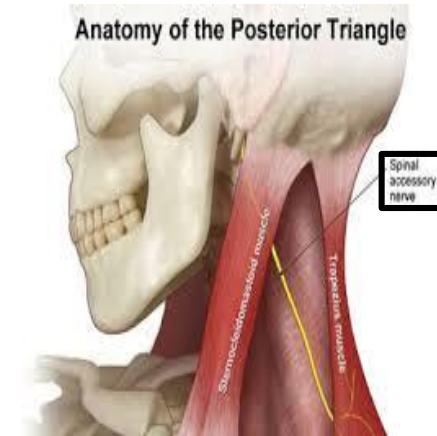


Accessory (XI) 11th Cranial Nerve Injury of Spinal Root

○ Causes:

- Because of the relatively *superficial position* of the nerve in the **posterior triangle**, it may be damaged by penetrating trauma as *stab wounds*.
- It is considered the most commonly iatrogenically* injured nerve as during *removal of malignant lymph nodes* in the posterior triangle.

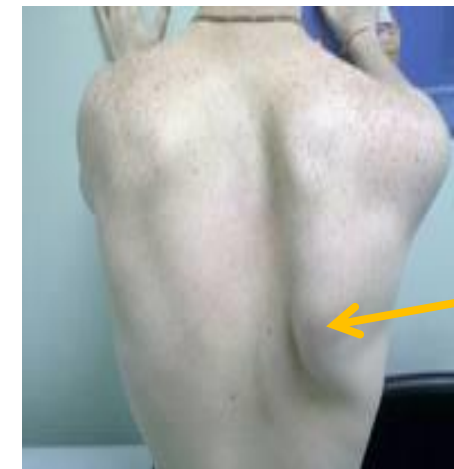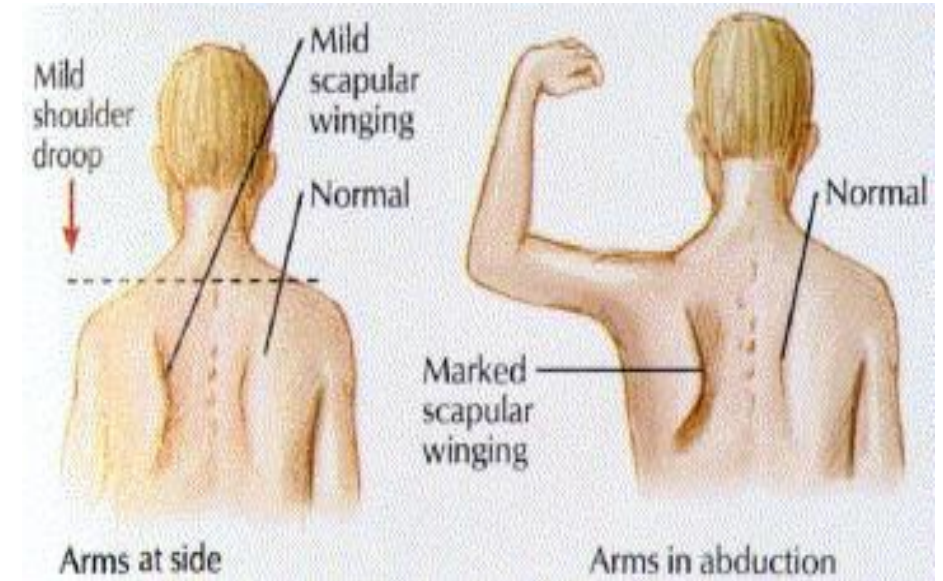
* induced inadvertently by a physician or surgeon or by medical treatment or diagnostic procedures



Accessory (XI) 11th Cranial Nerve Injury of Spinal Root

○ Manifestations:

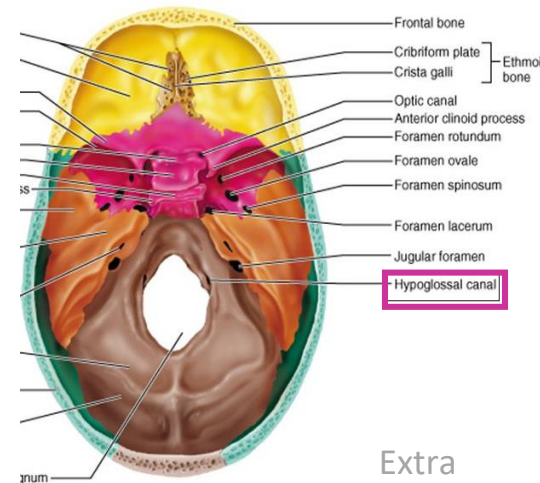
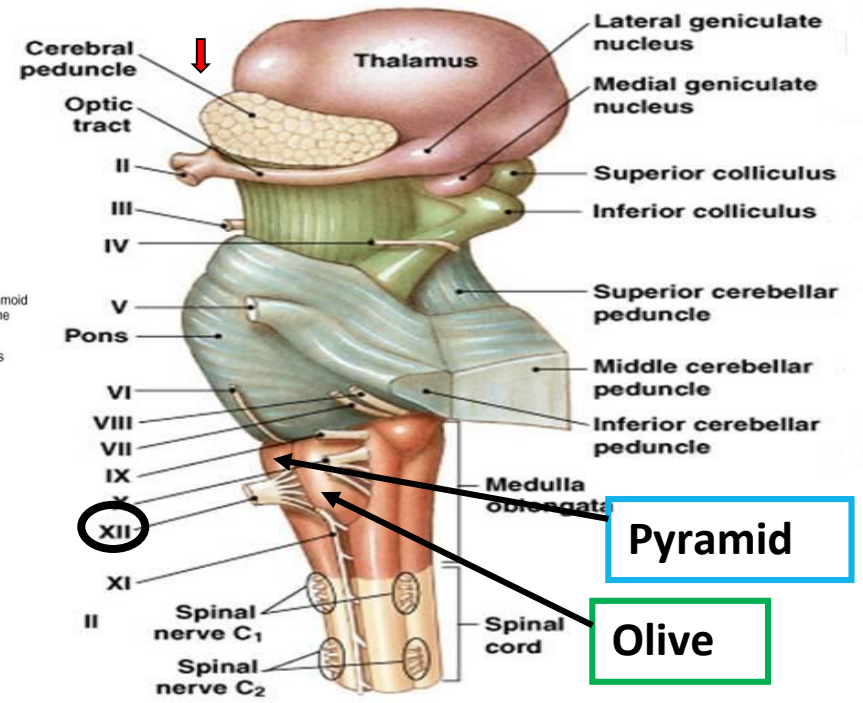
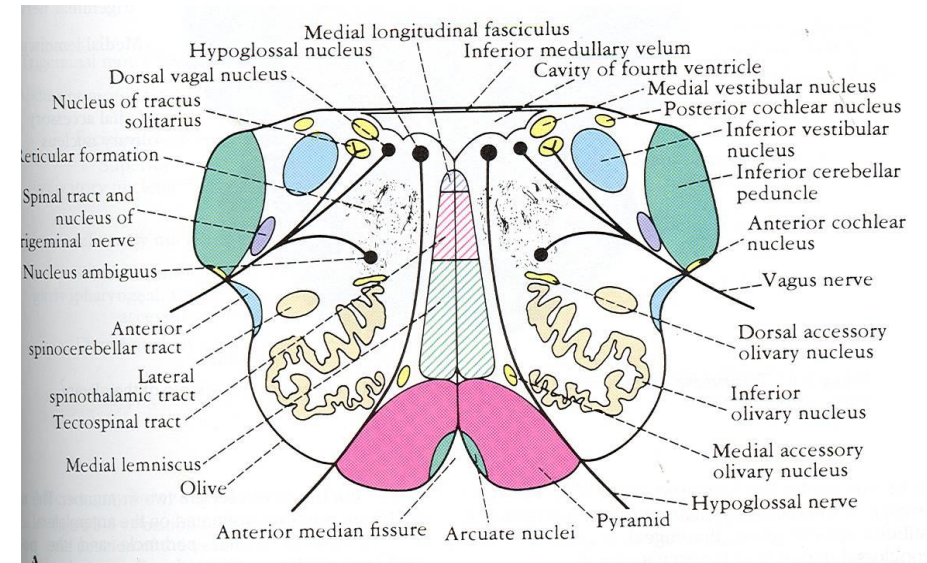
- It produces atrophy and weakness of **trapezius**.
- Unilateral paralysis of trapezius is evident by (1) inability to elevate & (2) retract the shoulder, (3) difficulty in elevating the arm & (4) Winging of scapula.
- Dropping of the shoulder is an obvious sign of injury of the nerve.
- **If the cranial root is also injured:** the lesion also causes difficulty in swallowing and speech, and
- Inability to turn the head.



Hypoglossal (XII) 12th Cranial Nerve

- Type: **Motor**
- Origin: **Hypoglossal nucleus** of the medulla (in the floor of 4th ventricle)*
- The fibers emerge from the anterior surface of the medulla oblongata through the **sulcus between the pyramid and the olive**.
- Foramen of exit from skull: **Hypoglossal canal**

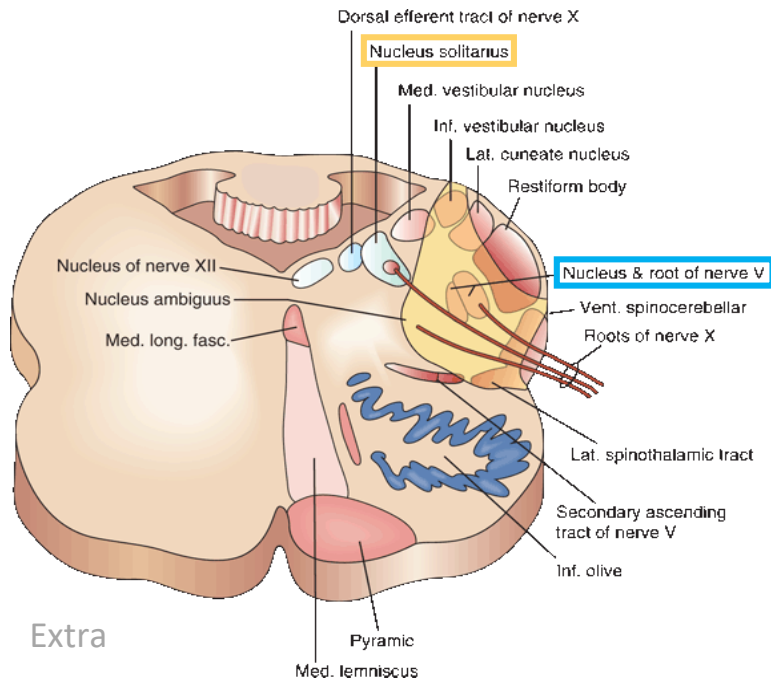
* The most medial nucleus



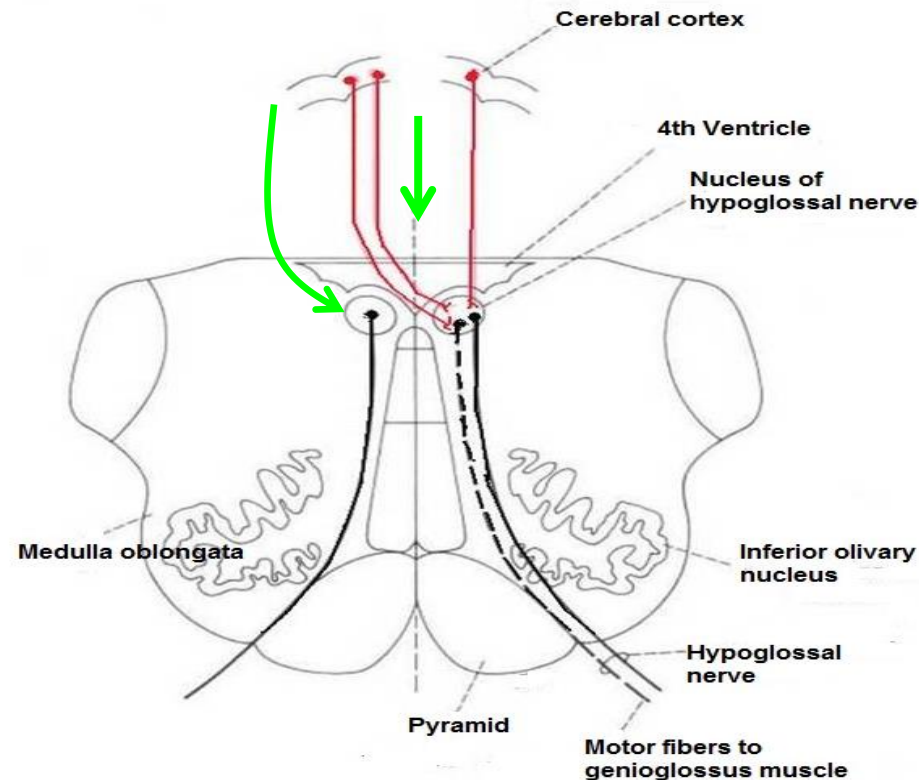
Extra

Hypoglossal (XII) 12th Cranial Nerve

- The hypoglossal nucleus receives **corticocaudal** fibers from **both** (bilateral) cerebral hemispheres **EXCEPT** the region that supplies **genioglossus*** muscle (receives contralateral supply only) unilateral
- Also receives afferent fibers from **nucleus solitarius** and **trigeminal sensory nucleus**.



Extra

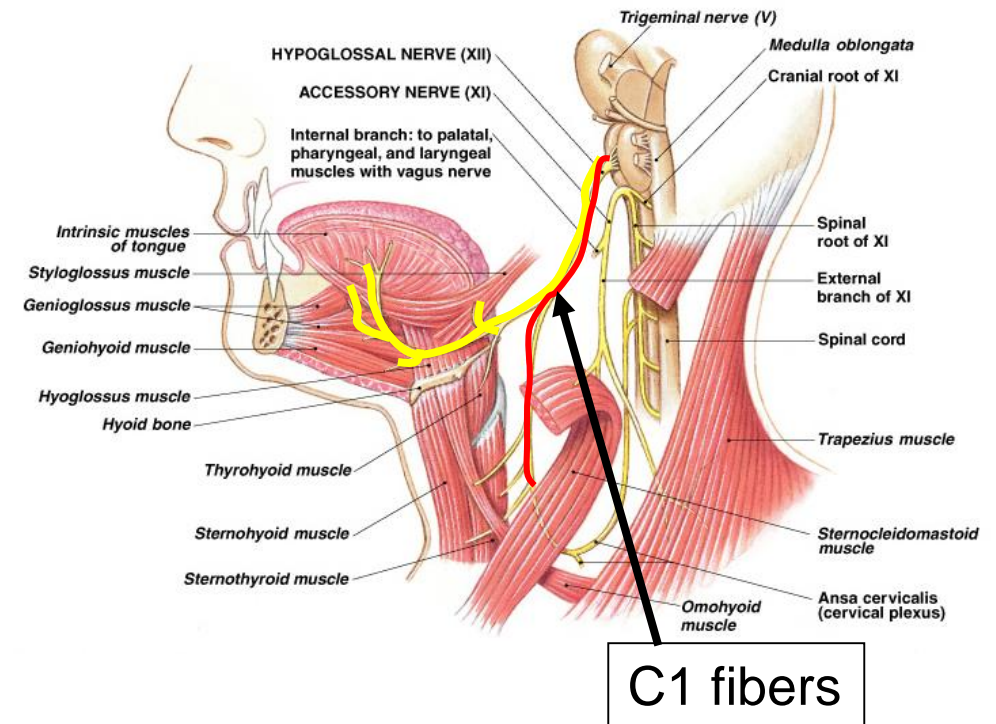
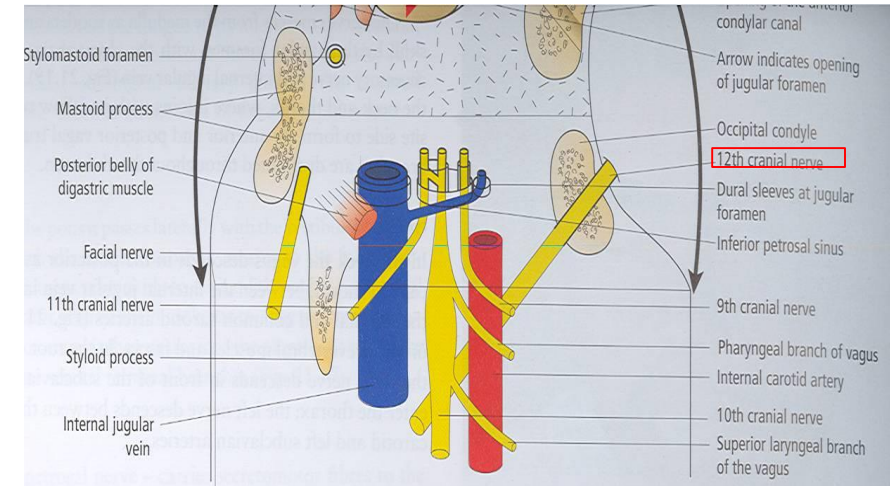


* The only muscle that take fibers from one side, which is the opposite side

Hypoglossal (XII) 12th Cranial Nerve Course

- The nerve courses downward with *cervical neuro-vascular bundle* (**internal carotid artery, internal Jugular vein, vagus nerve**)
- Then curves forward behind mandible to supply the tongue.
- During its initial course, it carries **C1 fibers*** which leave in a branch to take part in the formation of **ansa cervicalis** (a loop of nerves supplying neck muscles)

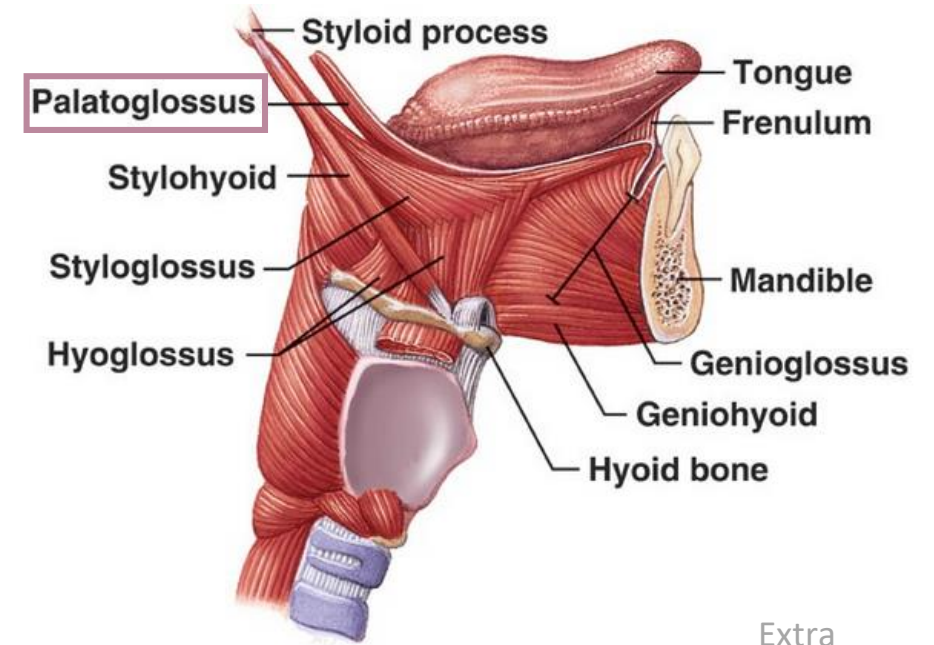
* الـ hypoglossal nerve يعتبر زي التاكسي لـ c1 فايبرز بس ترتبط معاه ويوصلها وبعدين يتركها وتنفصل عنه وترتبط مع فايبرز أخرى عشان يكونوا (Ansa cervicalis)



C1 fibers

Hypoglossal (XII) 12th Cranial Nerve Function

1. Supplies *motor innervation* to all of the muscles of the **tongue** Except the **palatoglossus** (which is supplied by the vagus nerve).
So, it Controls the movements and shape of the tongue during speech and swallowing
2. Carries **proprioceptive** afferents from the tongue muscles.



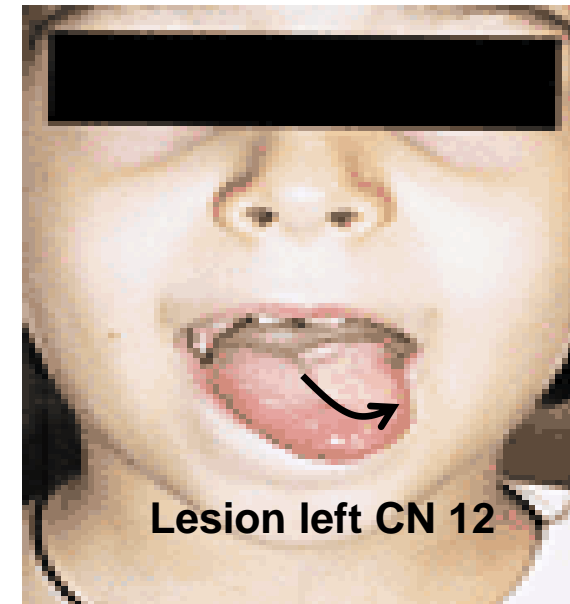
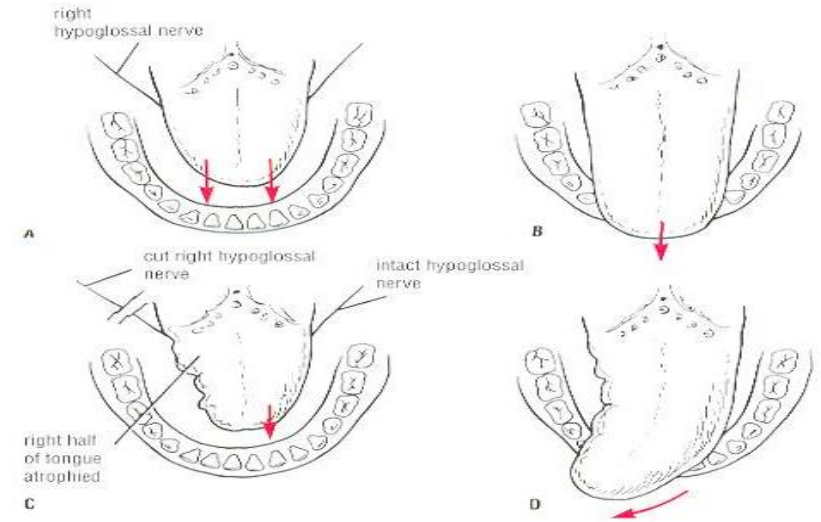
Extra

Hypoglossal (XII) 12th Cranial Nerve Lesion

Manifestations of Lesion of the nerve (LMN) :

- Loss of tongue movements
- Difficulty in chewing and speech
- The tongue paralyses, atrophies, becomes shrunken and furrowed on the affected side (LMN paralysis)
- On protrusion, tongue **deviates to the affected side**. “normally it’s in the middle”
- If both nerves are damaged, person can’t protrude tongue.

*مثلا في الصورة؛ اللسان منحرف إلى الجهة اليسار، معناتو إلي أتأثر هو left hypoglossal nerve، ولو النيرف في الجهتين أتأثر الشخص ما يقدر يمد لسانه لبرا



	Nerve	Type	Origin		Foramen of Exit	Function	Injury
IX	Spinal accessory	motor	Cranial Part	Nucleus Ambiguus	Jugular foramen	Movement of the soft palate, larynx & Pharynx	Trapezius atrophy & weakness
							Trapezius paralysis
							Shoulder drooping
			Spinal Part	C1-C5 (Spinal nucleus)		Movement of the neck	Speech & swallowing difficulty
							Inability to turn head
XII	hypoglossal	motor	Anterior surface of Medulla (hypoglossal nucleus)		Hypoglossal canal	Motor to all tongue muscles except palatoglossus	loss of tongue movement
							Speech & chewing difficulty
						Speech & swallowing	Tongue paralysis
						<u>Carries</u> afferents from tongue muscles	Tongue deviation on protrusion to affected side

MCQs

1. The Accessory Nerve exit from which foramen in the skull ?

- A- Foramen ovale
- B- Foramen Lacerum
- C- Jugular Foramen
- D- Foramen Magnum

Answer: C

2. The spinal part of Accessory Nerve supplies which muscles ?

- A- The sternomastoid and Trapezius
- B- The serratus anterior and Trapezius
- C- The sternomastoid and scalene
- D- The sternomastoid and omohyoid

Answer: A

3. Which of the following nerve commonly injured during removal of malignant lymph nodes in the posterior triangle ?

- A- Vagus Nerve
- B- Hypoglossal Nerve
- C- Cranial root of Accessory Nerve
- D- Spinal root of Accessory Nerve

Answer: D

4. Hypoglossal Nerve is a ?

- A- Motor type
- B- Sensory Type
- C- Both

Answer: A

5. The hypoglossal nucleus of the medulla locate in which ventricle?

- A- The 2nd Ventricle
- B- The 3rd Ventricle
- C- The top of 4th Ventricle
- D- The floor of 4th Ventricle

Answer: D

6. The Hypoglossal Nerve supplies motor innervation of all the muscle of the tongue except ?

- A- superior longitudinal
- B- The palatoglossus
- C- Cranial root of Accessory Nerve
- D- Styloglossus

Answer: B

SAQ

A 12 year boy came to the ER with difficulty in chewing and speech .

1\ Which Nerve is most likely affected ?

The hypoglossal nerve

2\ The tongue shrunken and furrowed in which side ?

The affected side



Leaders:

Nawaf AlKhudairy
Jawaher Abanumy

Members:

Ameera Niazi
Do'aa abdufattah
Nada Aldakheel
Shatha Alghaihb



Feedback



anatomyteam436@gmail.com



@anatomy436



Anatomy Team

References:

- 1- Girls' & Boys' Slides
- 2- Greys Anatomy for Students
- 3- TeachMeAnatomy.com