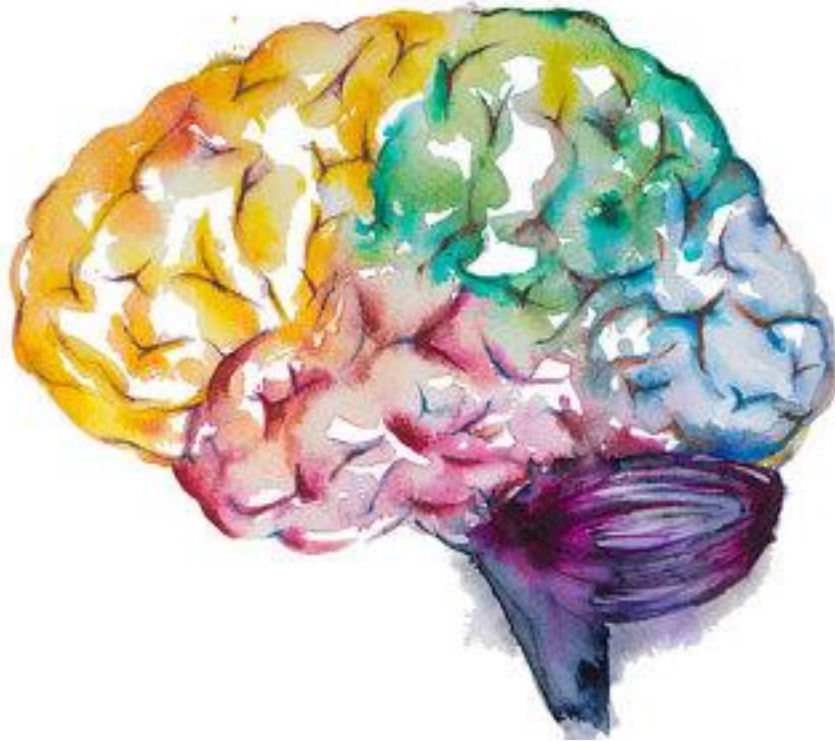

Cerebrovascular accidents



Objectives:

- 1- Explain the concepts of brain "Hypoxia", "Ischemia" and "Infarction".
- 2- Understand the pathogenesis of thrombotic and embolic stroke and be able to identify clinical risk factors.
- 3- Identify the causes and consequences of subarachnoid and intracerebral hemorrhage.
- 4- Build a list of the different causes that can lead to cerebrovascular accident.

Key principles to be discussed:

- 1- The concept of "stroke".
- 2- Thrombotic and embolic stroke: incidence, significance of classification, causes and major clinicopathological features.
- 3- Global Cerebral Ischemia, Border zone ("watershed") infarcts and focal Cerebral Ischemia: definition, causes and main gross and histopathological features.
- 4- Intracerebral and subarachnoid hemorrhage: causes and major clinicopathological features.
- 5- Vascular malformations: definition
- 6- The main possible CNS cerebrovascular complications of hypertension including intracerebral hemorrhage, lacunar infarct, slit hemorrhages and hypertensive encephalopathy: definitions
- 7- Vasculitis: possible causes.



Black: Doctor's slides.

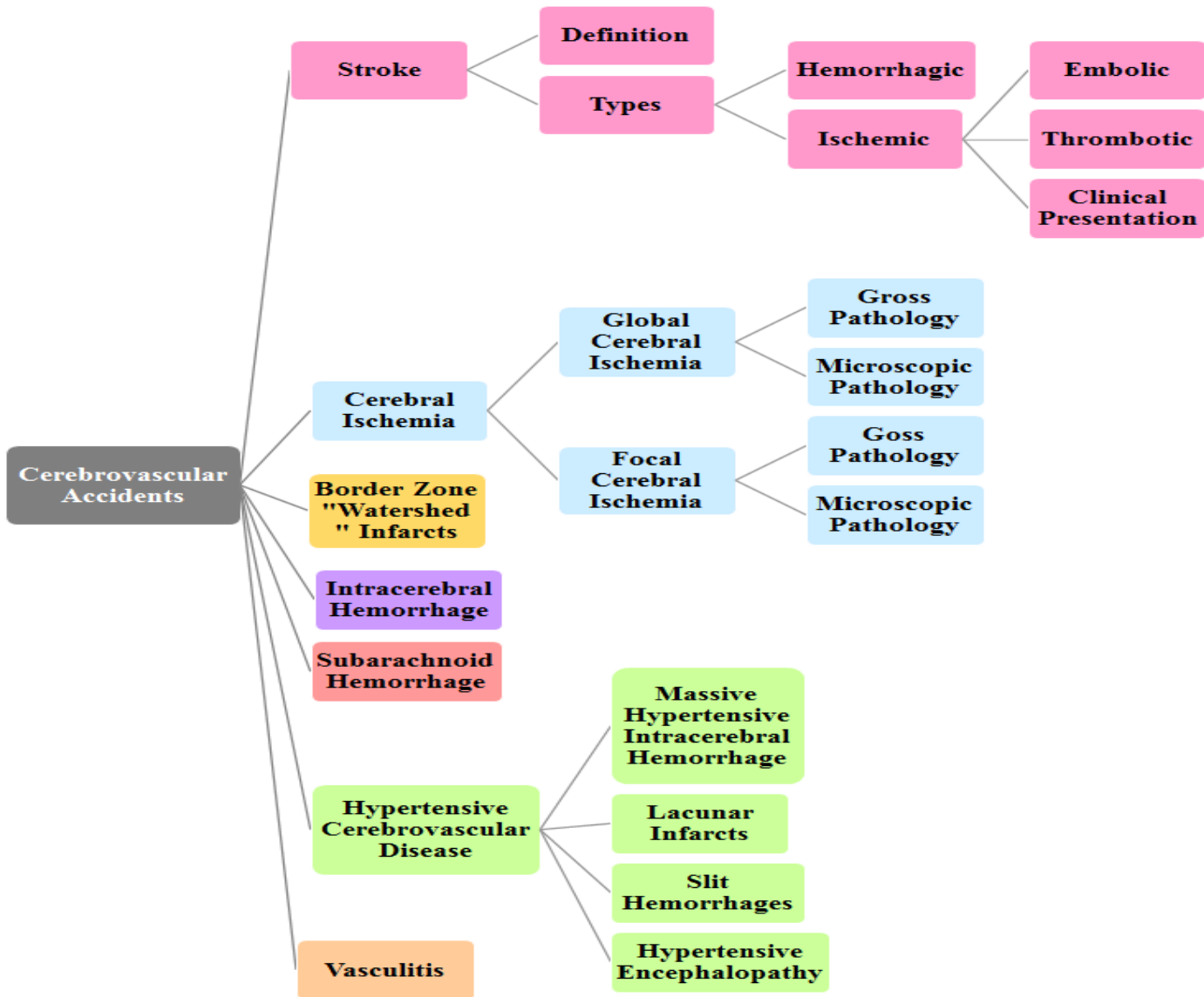
Red or black bold: important!

Green: Doctor's notes.

Grey: Extra.

Italic black: New terminology.

Lecture outlines:



- Introduction:

Review the following terms:

Hypoxia:	Deficiency in the amount of oxygen reaching the tissues.
Ischemia:	An inadequate blood supply to an organ or part of the body. "Can recover"
Infarction:	Obstruction of the blood supply to an organ or region of tissue, causing local death of the tissue. "Necrosis"

The brain may be deprived¹ of oxygen by any of several mechanisms:

1. Functional hypoxia* , in:	2. Ischemia , either <i>transient</i> ² or <i>permanent</i> :
a) A low partial pressure of oxygen. (e.g. High Altitude). b) Impaired oxygen-carrying capacity. (e.g. severe anemia, carbon monoxide poisoning) c) Inhibition of oxygen use by tissue. (e.g. cyanide poisoning)	a) A reduction in perfusion pressure, as in hypotension. b) Vascular obstruction. c) Both.

*For example if someone had a car accident then the spleen ruptured, the blood going extra vascular so, there is hypoxia but not related to an abnormality in arteries, it just decrease in the blood supply.

A) Like in high altitude no enough oxygen → hypoxia → stroke, without hemorrhage or obstruction.

B) مثل حوادث التسمم بالفحم أثناء التدفئة أيام الشتاء اللي تصير بغرفة مسكرة فينكتمون ويتوفون.

الدكتورة طلبت الأمثلة كواجب، الدكتور ذكرها بالمحاضرة :

3. Cerebrovascular disease is the third leading cause of death (after heart disease and cancer) in the United States.

4. It is also the most prevalent neurologic disorder in terms of both morbidity³ and mortality⁴.

This Video was included in the slides →



<https://www.youtube.com/watch?v=TKHB82yOa4>

- **Stroke:**

The definition of stroke is very important.

It is the **clinical term** for a disease with **acute** onset of a neurologic deficit as the result of **vascular lesions**, either hemorrhage or loss of blood supply.

Very important to differentiate if the stroke is due to hemorrhage or due to vascular lesion because they are very different even in the treatment.

¹ يُمنع، يُحرم.

² Short duration.

³ Morbidity refers to the state of being diseased or unhealthy within a population.

⁴ Mortality is the term used for the number of people who died within a population.

a) Embolic stroke:

Embolic infarctions are **more common**.

- Sources of emboli[^] include: ^It's come from the circulation.
 1. Cardiac mural thrombi (frequent);
 - Myocardial infarct.
 - Valvular disease.
 - Atrial fibrillation.
 2. Arteries; (often atheromatous plaques within the **carotid arteries**).
 3. Paradoxical⁵ emboli, particularly in children with cardiac anomalies.

E.g. Deep vein thrombosis (DVT).
 4. Emboli associated with **cardiac surgery**.
 5. Emboli of other material (tumor, fat, or air).

The territory of distribution of the **middle cerebral arteries** most frequently affected by embolic infarction.

WHY? Due to the size and the direct blood flow from **internal carotid artery** into the middle cerebral artery.

b) Thrombotic stroke:

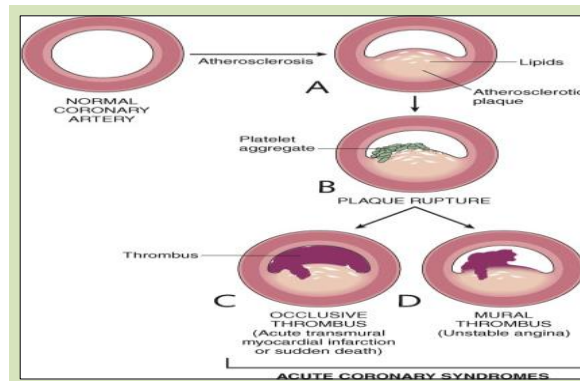
The majority of thrombotic occlusions causing cerebral infarctions are due to **atherosclerosis**.

- The most common sites of primary thrombosis: Remember this!
 - **The carotid bifurcation.**
 - **The origin of the middle cerebral artery.**
 - **At either end of the basilar artery.**

⁵ Form in the artery than came to the vein.

- **Atherosclerotic stenosis** can develop on top a superimposed thrombosis, accompanied by anterograde extension, fragmentation, and distal embolization.

Dr. Hala: Atherosclerosis come in the top of emboli then expands.



Dr. Hisham:

Atherosclerosis هنا يكون عند المريض اساساً

ولكنها ماسدت الشريان بالكامل فتجي فوقها Thrombus

وتسكبه تماماً

- Stroke Clinical presentation:

Like if it is in temporal lobe it will be less danger from brainstem, so depend on site the clinical presentation varies from nothing to death.

Depends on which part of the brain is injured, and how severely it is injured. Sometimes people with stroke have a **headache** "Not always sometimes it painless and no headache", but stroke can also be **completely painless**.

It is very important to recognize the warning signs of stroke and to get immediate medical attention if they occur. If the brain damage sustained has been slight, there is usually complete recovery, but most survivors of stroke require extensive rehabilitation.

▪ Symptoms:

- **Sudden.**

Hemiplegia.



- The most common is weakness or paralysis of one side of the body with partial (in one side) or complete loss of voluntary movement or sensation in a leg or arm.

- There can be speech problems and weak face muscles, causing drooling.

- **Numbness* or tingling is very common.** *it could be the only symptom. Be aware!

- A stroke involving the **base of the brain** (Cerebellum) can affect balance, vision, swallowing, breathing and even unconsciousness. So damage depends on the location.

- In cases of severe brain damage there may be deep coma, paralysis of one side of the body, and loss of speech, followed by death or permanent neurological disturbances after recovery.

- **Global Cerebral Ischemia:** The whole brain suffering and not sufficient blood coming.

Widespread ischemic/hypoxic injury occurs when there is a **generalized reduction** of cerebral perfusion, usually below **systolic** pressures of less than 50mmHg.

▪ Causes include:

1. cardiac arrest.

2. severe hypotension or shock. Hypovolemic shock, septic shock, anaphylactic shock.

▪ The clinical outcome varies with the severity of the insult:

○ If mild → may be only a transient postischemic confusional state, with eventual complete recovery.

○ In severe global cerebral ischemia → widespread neuronal death occurs, irrespective of regional vulnerability⁶. If the patient survives, he could suffer from one of:

1. **Persistent* vegetative state**⁷: Individuals who survive in this state often remain severely impaired neurologically and **deeply comatose**.

It means that the person can't do the Routine function by himself like eating, urination.

2. **Respirator** brain**: Other patients meet the clinical criteria for "**brain death**," including evidence of:

- Diffuse cortical injury (isoelectric, or "flat," electroencephalogram) and
- Brain stem damage, including absent reflexes and respiratory drive.

*There will be a light reflex → patient may wakeup from coma!

** Light reflex is Abscent.

When patients with this pervasive form of injury are maintained on mechanical ventilation, the brain gradually undergoes an **autolytic process**⁸. So Respirator brain also known as "autolysis of the brain."

الإختلاف بين الأثنين أن Persistent تكون غيبوبة أما ال Respirator تكون ميت دماغياً الدماغ تحلل!

⁶ Susceptible to being wounded.

⁷ حالة غيبوبة مستمرة

⁸ necrosis of the cells - عملية التحلل

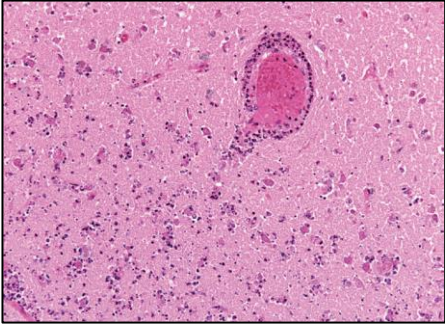
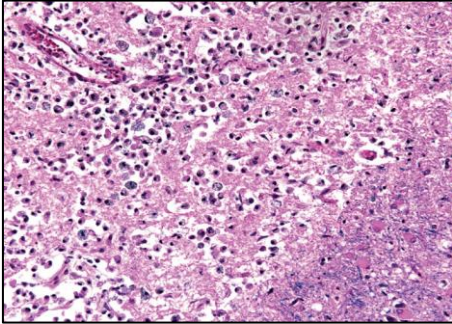
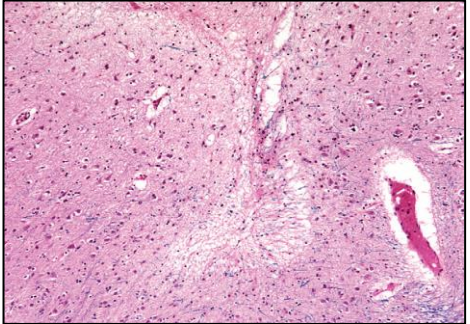
- Sensitivity to ischemia:

- Neurons are **much more** sensitive to hypoxia than are glial cells.
- The most susceptible to ischemia of short duration are:
 - **Pyramidal cells** of the Sommer sector (CA1) of the hippocampus.
 - **Purkinje cells** of the cerebellum.
 - **Pyramidal neurons** in the neocortex.

- Gross pathology: Most important part in the lecture.

- The brain is swollen, with **wide gyri** and **narrowed sulci**. Edema happened.
- The cut surface shows **poor demarcation** between gray and white matter.

- Microscopically, infarction shows:

Early changes	Subacute changes	Repair
12 to 24 hours after the insult	24 hours to 2 weeks	After 2 weeks
Red neurons , characterized initially by microvacuolization → cytoplasmic eosinophilia, and later nuclear pyknosis and karyorrhexis.	<ul style="list-style-type: none"> • The reaction to tissue damage begins with infiltration by neutrophils. • Liquefactive necrosis of tissue, influx of macrophages, vascular proliferation and reactive gliosis. 	Removal of all necrotic tissue, loss of organized CNS structure and gliosis .
		

- Focal Cerebral Ischemia:

الفرق الرئيسي بين الفوكال والقلوبال إنه هنا يتكون بمناطق معينة بالبرين أما القلوبل كامل البرين يتضرر.

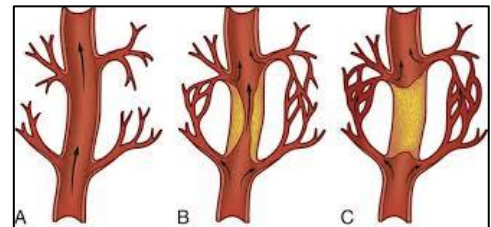
- Cerebral arterial occlusion → focal ischemia.

- The size, location, and shape of the infarct and the extent of tissue damage that results are determined by modifying variables, **most importantly the adequacy of collateral flow:**

- The major source of collateral flow is the circle of Willis.
- Partial collateralization is also provided over the surface of the brain through **cortical-leptomeningeal anastomoses.**
- In contrast, there is little if any collateral flow for the deep penetrating vessels supplying structures such as: **More susceptible to infarction.**

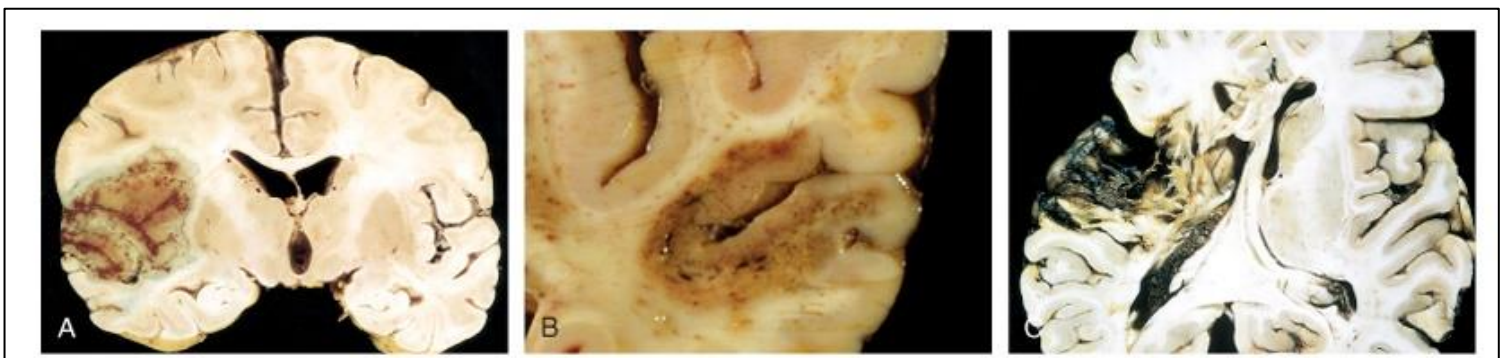
1. **Thalamus.**
2. **Basal ganglia.**
3. **Deep white matter.**

EXTRA: "collateral"



- Gross pathology: (**#Non-hemorrhagic infarct**) "Robbins: Result from acute vascular occlusions"

The first 6 hours	By 48 hours	From 2 to 10 days	From 10 days to 3 weeks
Irreversible injury little can be observed. E.g. if the Patient die and we take biopsy in the first 6h we see nothing.	The tissue becomes pale, soft, and swollen , and the corticomedullary junction becomes indistinct.	The brain becomes gelatinous and friable, and the previously ill-defined boundary between normal and abnormal tissue becomes more distinct as edema resolves in the adjacent tissue that has survived.	The tissue liquefies , eventually leaving a fluid-filled cavity and cyst lined by dark gray tissue, which gradually expands as dead tissue is removed. If fibrosis → Epilepsy.



- Microscopically: The tissue reaction follows a characteristic sequence:

After the first 12 hours	Until 48 hours	Then	After several months
<ul style="list-style-type: none"> • Red neurons and both cytotoxic and vasogenic edema predominate. • There is loss of the usual characteristics of white and gray matter structures. • Endothelial and glial cells, mainly astrocytes, swell, and myelinated fibers begin to disintegrate. Giosis. <div data-bbox="94 663 441 800" style="background-color: #e1f5fe; padding: 5px;"> <p>Like global here also there is red neurons but here it focus in one site.</p> </div>	<ul style="list-style-type: none"> • There is some neutrophilic emigration followed by mononuclear phagocytic cells during the ensuing 2 to 3 weeks. • Macrophages containing myelin breakdown products or blood may persist in the lesion for months to years. 	<ul style="list-style-type: none"> • As the process of phagocytosis and liquefaction proceeds, astrocytes at the edges of the lesion progressively enlarge, divide, and develop a prominent network of protoplasmic extensions. 	<p>The striking astrocytic nuclear and cytoplasmic enlargement recedes.</p>

Dr.hisham: So as summary: first 12hs red neurons → 48hs neutrophil → 2-3weeks macrophages → several months gliosis.

After several months -cont: (Healing process)

- **In the wall of the cavity:** astrocyte processes form a dense feltwork of glial fibers admixed with new capillaries and a few perivascular connective tissue fibers.
- **In the cerebral cortex:** the cavity is delimited from the meninges and subarachnoid space by a gliotic layer of tissue, derived from the molecular layer of cortex.
- **The pia and arachnoid:** are not affected and do not contribute to the healing process.

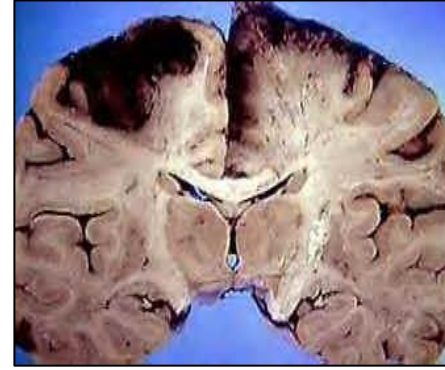
- Microscopic appearance: (**#Hemorrhagic infarct**) "Robbins: Result from reperfusion of ischemic tissue either through collaterals or after dissolution"

It has the same characteristic of "non-hemorrhagic" but with hemorrhagic, so sometimes it difficult to differentiate between them.

1. Parallel ischemic infarction.
2. Blood extravasation and resorption.
3. In persons receiving anticoagulant treatment, hemorrhagic infarcts may be associated with extensive intracerebral hematomas.

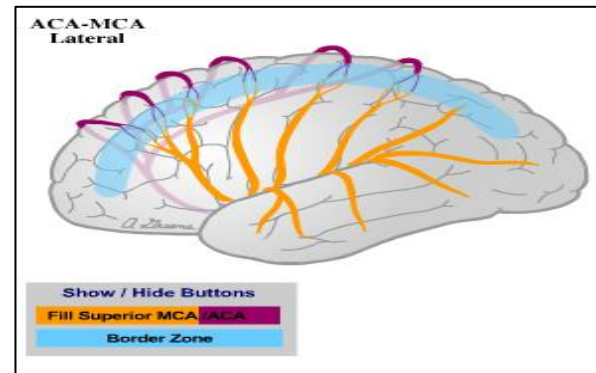
- Border zone ("watershed") infarcts:

لو نبغى نشبهها بشيء فهي زي المنطقة اللي بين نهاية حدود دولتين وما فيها حماية. "بالعافية يوصلها الدم لأنها جاية بنهاية شريانين". فإذا شوية نزل البلود بريسر وهي أصلاً ما كان يجيها كثير فخلاص يوقف الدم عنها.



Wedge-shaped areas of infarction that occur in those regions of the brain and spinal cord that lie at the most distal fields of arterial perfusion.

- In the cerebral hemispheres, the border zone between the **anterior and the middle cerebral artery** distributions is at greatest risk.
- Damage to this region produces a band of necrosis over the cerebral convexity a few centimeters **lateral to the interhemispheric fissure**.
- Border zone infarcts are usually seen after **hypotensive episodes**.



- Intracerebral (Intracranial) hemorrhage:

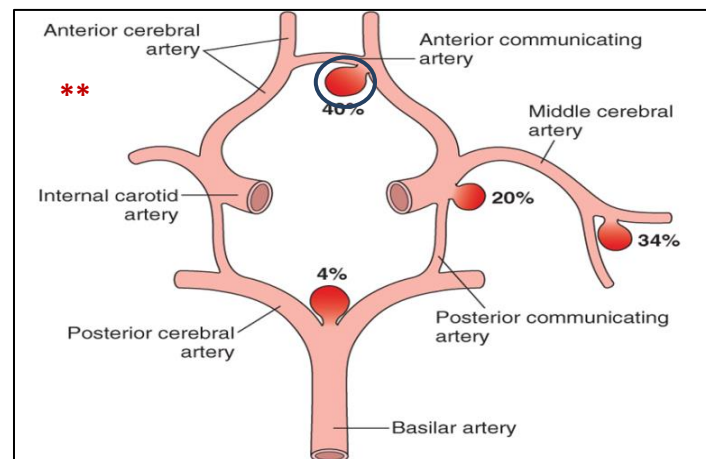
Hemorrhages within the brain (intracerebral) can occur secondary to:

1. **Hypertension.** Most common.
2. Other forms of vascular wall injury (e.g. vasculitis)
3. Arteriovenous malformation.
4. An intraparenchymal tumor.

- Hemorrhages associated with the dura (in either subdural or epidural spaces) make up a pattern associated with trauma (discussed in another lecture).

○ = Aneurysm.

↑ BP → rupture because it has thin walls.



The most areas affected by aneurysm are anterior communicating and anterior cerebral arteries.

- Subarachnoid Hemorrhage:

If very massive, it will go into intracerebral hemorrhage.

- Causes of subarachnoid hemorrhage:
 1. Rupture of a **saccular (berry) aneurysm**** (The most frequent cause of clinically significant).
 2. Vascular malformation.
 3. Trauma (in which case it is usually associated with other signs of the injury).
 4. Rupture of an intracerebral hemorrhage into the ventricular system.
 5. Hematologic disturbances.
 6. Tumors.

- Rupture can occur at any time, but in about one-third of cases it is associated with acute increases in intracranial pressure, such as with straining at stool or sexual orgasm.
- Blood under arterial pressure is forced into the subarachnoid space, and individuals are stricken with sudden, **excruciating headache** (classically described as "the worst headache I've ever had") and **rapidly lose consciousness**.
- Between 25% and 50% of individuals die with the first rupture, although those who survive typically improve and recover consciousness in minutes.
- Recurring bleeding is common in survivors; it is currently not possible to predict which individuals will have **recurrences of bleeding**. The prognosis worsens with each episode of bleeding.

- About 90% of saccular aneurysms occur in the anterior circulation near major arterial branch points. **Multiple aneurysms** exist in 20% to 30% of cases. Although they are sometimes referred to as **congenital**, they are not present at birth but develop over time because of underlying defects in the vessel media.
 - The probability of aneurysm rupture increases with the size of the lesion, such that aneurysms greater than 10 mm have a roughly 50% risk of bleeding per year.

In the early period after a subarachnoid hemorrhage, there is a risk of additional ischemic injury from **vasospasm** involving other vessels.

It may be area with hemorrhage and area with ischemic infarct.

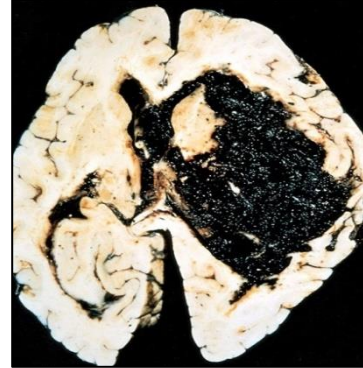
- In the healing phase of subarachnoid hemorrhage, occur:
 1. Meningeal fibrosis.
 2. Scarring.

These sometimes leading to **obstruction of CSF flow** as well as interruption of the normal pathways of CSF resorption lead to hydrocephalus⁹.

- Hypertensive Cerebrovascular Disease: Very common. Silent killer.

The most important effects of hypertension on the brain include:

1. Massive hypertensive intracerebral hemorrhage (discussed earlier, most important).
2. Lacunar¹⁰ infarcts.
3. Slit¹¹ hemorrhages.
4. Hypertensive encephalopathy.



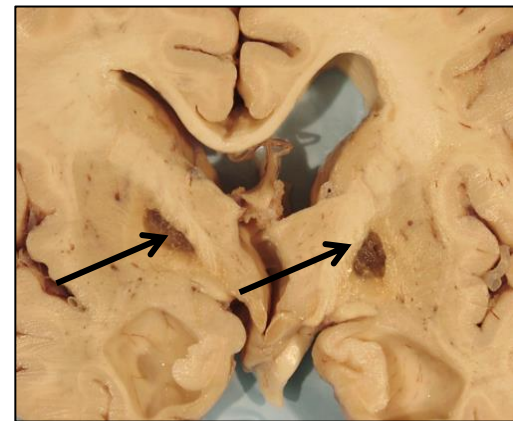
Hypertension **affects** the deep penetrating arteries and arterioles that supply the **basal ganglia and hemispheric white matter** and the brain stem. So at the base of the brain.

- Hypertension causes several changes, including **hyaline arteriolar sclerosis** in arterioles → weaker than normal vessels and are more vulnerable to rupture.

In some instances, chronic hypertension is associated with the development of minute aneurysms in vessels that are less than 300 μm in diameter → **Charcot-Bouchard microaneurysms**¹², which can rupture.

❖ Lacunar infarcts:

- Small **cavitary** infarcts.
- Most commonly in **deep gray matter** (basal ganglia and thalamus), internal capsule, deep white matter, and pons.
- Consist of cavities of tissue loss with scattered lipid-laden **macrophages** and surrounding **gliosis**.
- Depending on their location in the CNS, lacunes can either be clinically silent or cause significant neurologic impairment.



⁹ Is the buildup of SCF in brain.

¹⁰ Empty space, small cavity.

¹¹ Long narrow cut or opening.

¹² Small aneurysms in small blood vessels.

❖ Slit hemorrhage:

- Rupture of the small-caliber penetrating vessels and the development of small hemorrhages.
- In time, these hemorrhages resorb, leaving behind a slitlike cavity surrounded by **brownish discoloration**. لأنه كان فيه نزييف و جوا الماكروفيجز و أكلوا خلايا الدم و بقى الأيرون فصار بني.

❖ Acute hypertensive encephalopathy:

A clinicopathologic syndrome:

- Diffuse cerebral dysfunction, including headaches, confusion, vomiting, and convulsions, sometimes leading to coma.
- Does not usually remit spontaneously. May be associated with an edematous brain, with or without transtentorial or tonsillar herniation.

It becomes very large → compress the brain stem → death.

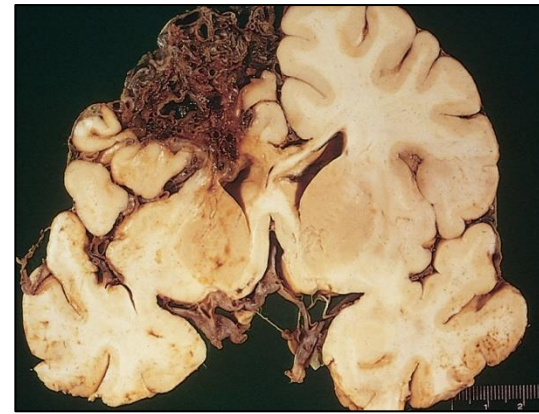- Petechiae¹³ and **fibrinoid necrosis** of arterioles in the gray and white matter may be seen microscopically.

- Vasculitis:

Could be:

Infectious arteritis of small and large vessels:

- Previously in association with syphilis¹⁴ and tuberculosis (**infections**). Now more commonly occurs in the setting of immunosuppression and opportunistic infection¹⁵ (such as toxoplasmosis¹⁶, aspergillosis¹⁷, and CMV encephalitis¹⁸).



Arteriovenous malformation

¹³ صديد صغير

¹⁴ A chronic bacterial disease that is contracted chiefly by infection during sexual intercourse, but also congenitally by infection of a developing fetus.

¹⁵ Typically happen when the immune system is depressed.

¹⁶ A disease caused by toxoplasmas, transmitted through undercooked meat, or in soil or cat feces.

¹⁷ A condition in which certain fungi infect the tissues.

¹⁸ Cytomegalovirus (CMV) encephalitis: Is one of several central and peripheral nervous system infections seen in late-stage disease.

Or **Systemic* forms of vasculitis**, such as polyarteritis nodosa, may involve cerebral vessels and cause single or multiple infarcts throughout the brain.

Autoimmune. يعني*

- Primary angiitis of the CNS: We don't know from where it comes.
 - An inflammatory disorder that involves multiple small to medium-sized parenchymal and subarachnoid vessels.
 - Affected individuals manifest a diffuse encephalopathic clinical picture, often with cognitive dysfunction.
 - Improvement occurs with steroid and immunosuppressive treatment.

Because it's an autoimmune disease and arteriovenous malformation.

→ So what can cause or contribute to a stroke?

- Hypertension.
- Embolic diseases.
- Vascular malformations.
- Venous thrombosis.
- Vasculitis.
- Amyloid angiopathy¹⁹ (leptomeningeal and cortical vessels).
- Systemic hypoperfusion/ Global hypoxia, e.g. shock.
- Atherosclerosis.
- Thrombophilia, e.g. Sickle cell anemia.
- Tumors.

→ **Did you know?** Brain tissue ceases to function if deprived of oxygen for more than **60 to 90 seconds** and after approximately **three minutes**, will suffer irreversible injury possibly leading to death of the tissue.

*Homework

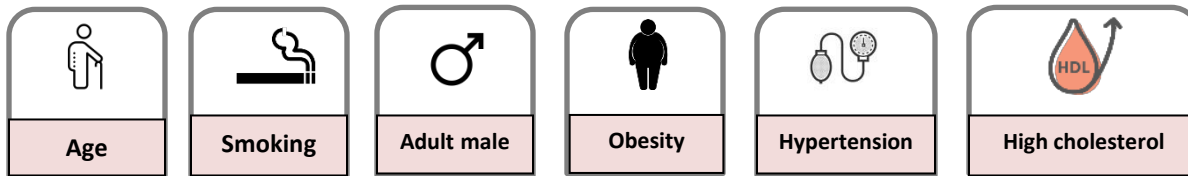
It can be in the EXAM.

- *Define: Transient ischemic attack.*

Is like a stroke, producing similar symptoms, but usually lasting only a few minutes and causing no permanent damage.

¹⁹ Is a form of angiopathy in which amyloid deposits form in the walls of the blood vessels of the central nervous system. We don't know why this happen.

- What are the risk factors of stroke?



*Questions:

Q1: Which one of the following functional hypoxia is due inhibition of oxygen use by tissue?

- A. High altitude.m B. Severe Anemia. C. Cyanide poisoning.
D. Carbon monoxide poisoning.

(C) Is the correct answer.

Q2: A woman presented with nystagmus, difficulty breathing and swallowing, after clinical examination she was diagnosed with a stroke, which one of the following sites are most likely to be involved by the stroke?

- A. Cerebellum. B. Frontal lobe. C. Medulla. D. Temporal lobe.

(A) Is the correct answer.

Q3: The glial cells are much more sensitive to hypoxia than neurons:

- A. True. B. False.

(B) Is the correct answer.

Q4: The major source of collateral flow is:

- A. cortical-leptomeningeal anastomoses. B. Circle of willis. C. Basal artery.

(B) Is the correct answer.

Q5: In the healing phase of subarachnoid hemorrhage, occur:

- A. Scarring. B. Necrosis. C. Inflammation.

(A) Is the correct answer.

Q6: The watershed infarct happens in the cerebral hemisphere in:

- A. Between the anterior and the middle cerebral artery.
- B. Between the lateral and middle cerebral arteries.
- C. At the basal ganglia.
- D. At the occipital lobe only.

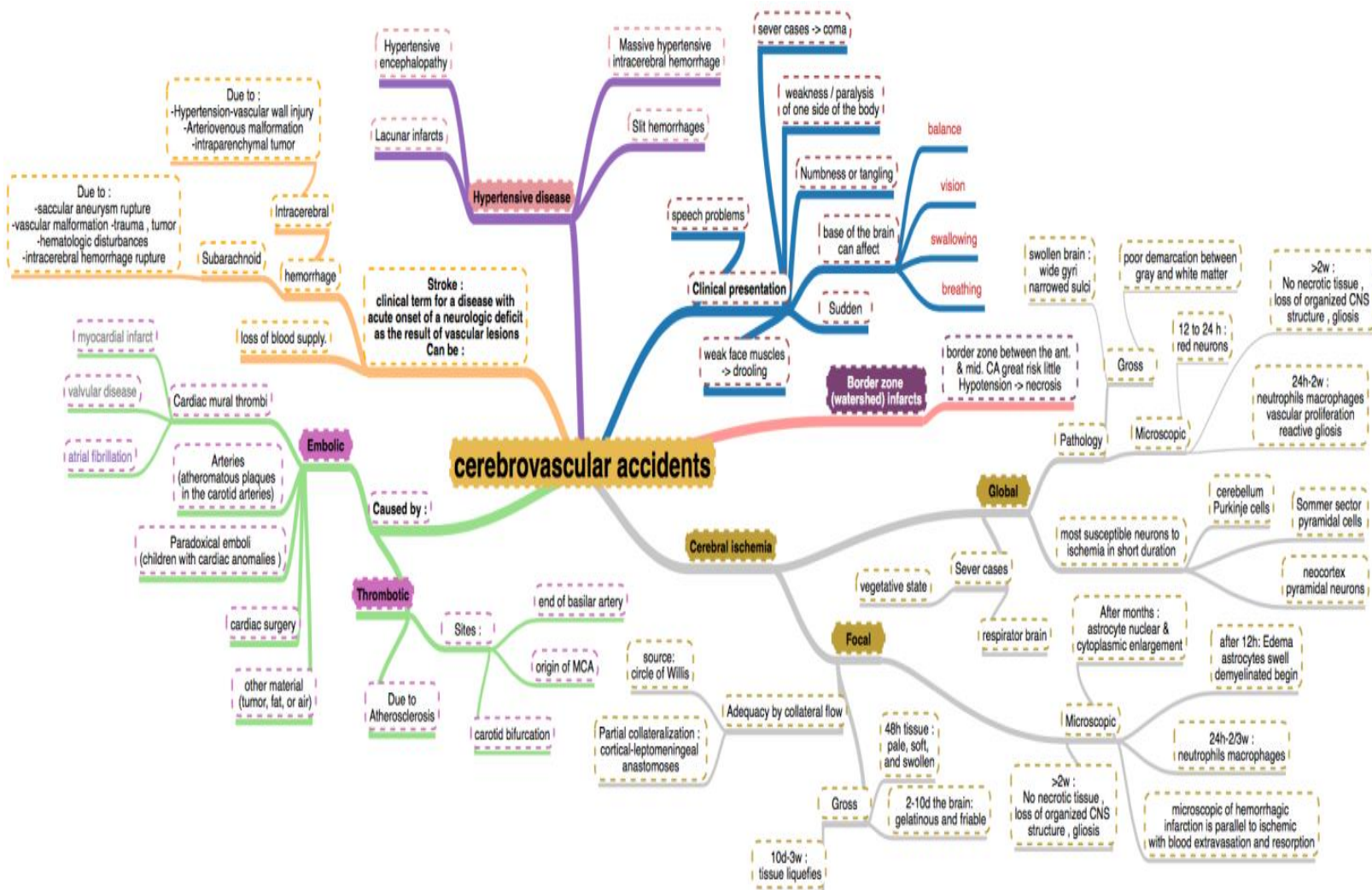
(A) Is the correct answer.

Q7: When dose the brain will suffer from irreversible injury?

- A. after 1 minute.
- B. after 15 seconds.
- C. after 3 minutes.

(C) Is the correct answer.

***Summary** for full, clear mind map: <http://app.mindmapmaker.org/#m:mm6f391cdde83e4c0880d60e88ead30fc4>



#Pathoma:

Cerebrovascular accidents:

I. BASIC PRINCIPLE:

A. Neurologic deficit clue to cerebrovascular compromise; major cause of morbidity and mortality.

B. Due to ischemia (85% of cases) or hemorrhage (15% of cases)

I. Neurons are dependent on serum glucose as an essential energy source and are particularly susceptible to ischemia (undergo necrosis within 3 - 5 minutes).

I. GLOBAL CEREBRALISCHEMIA

A. Global ischemia to the brain

B. Major etiologies:

1. Low perfusion (e.g., atherosclerosis)

2. Acute decrease in blood flow (e.g., cardiogenic shock)

3. Chronic hypoxia (e.g., anemia)

4. Repeated episodes of hypoglycemia (e.g., insulinoma)

C. Clinical features are based on duration and magnitude of the insult.

1. Mild global ischemia results in transient confusion with prompt recovery.

2. Severe global ischemia results in diffuse necrosis; survival leads to a "vegetative state".

3. Moderate global ischemia leads to infarcts in watershed areas (e.g., area lying between regions fed by the anterior and middle cerebral artery) and damage to highly vulnerable regions such as:

i. Pyramidal neurons of the cerebral cortex (layers 3, 5, and 6)—leads to laminar necrosis.

ii. Pyramidal neurons of the hippocampus (temporal lobe)—important in longterm memory.

iii. Purkinje layer of the cerebellum—integrates sensory perception with motor control.

II. Ischemic stroke

A. Regional ischemia to the brain that results in focal neurologic deficits lasting > 24 hours:

i. If symptoms last < 24 hours, the event is termed a transient ischemic attack (TIA).

B. Subtypes include thrombotic, embolic, and lacunar strokes.

1. Thrombotic stroke is due to rupture of an atherosclerotic plaque:

i. Atherosclerosis usually develops at branch points (e.g., bifurcation of internal carotid and middle cerebral artery in the circle of Willis).

ii. Results in a pale infarct at the periphery of the cortex.

2. Embolic stroke is due to thromboemboli:

i. Most common source of emboli is the left side of the heart (e.g., atrial fibrillation).

ii. Usually involves the middle cerebral artery.

iii. Results in a hemorrhagic infarct at the periphery of the cortex.

3. Lacunar stroke occurs secondary to hyaline arteriosclerosis, a complication of hypertension:

i. Most commonly involves lenticulostriate vessels, resulting in small cystic areas of infarction.

ii. Involvement of the internal capsule leads to a pure motor stroke.

iii. Involvement of the thalamus leads to a pure sensory stroke.

C. Ischemic stroke results in liquefactive necrosis:

1. Eosinophilic change in the cytoplasm of neurons (red neurons) is an early microscopic finding (12 hours after infarction).

2. Coagulative necrosis (24 hours), infiltration by neutrophils (days 1-3) and microglial cells (days 4-7), and granulation tissue (weeks 2-3) then ensue.

3. Results in formation of a fluid-filled cystic space surrounded by gliosis.

IV. Intra cerebral hemorrhage

A. Bleeding into brain parenchyma

B. Classically due to rupture of Charcot-Bouchard microaneurysms of the lenticulostriate vessels

1. Complication of hypertension; treatment of hypertension reduces incidence by half.

2. Basal ganglia is the most common site.

C. Presents as severe headache, nausea, vomiting, and eventual coma.

V. Sub arachnoid hemorrhage

A. Bleeding into the subarachnoid space.

B. Presents as a sudden headache ("worst headache of my life") with nuchal rigidity.

C. Lumbar puncture shows xanthochromia (yellow hue due to bilirubin breakdown).

D. Most frequently (85%) due to rupture of a berry aneurysm; other causes include AV malformations and an anticoagulated state:

1. Berry aneurysms are thin-walled saccular outpouchings that lack a media layer, increasing the risk for rupture.

2. Most frequently located in the anterior circle of Willis at branch points of the anterior communicating artery

3. Associated with Marfan syndrome and autosomal dominant polycystic kidney disease

"اللهم لا سهل إلا ما جعلته سهلاً و أنت تجعل الحزن إذا شئت سهلاً"



Editing File

Email: pathology436@gmail.com

Twitter: [@pathology436](https://twitter.com/pathology436)

[For your suggestions & complaints](#)

القادة

طراد الوكيل

نوره السهلي

الأعضاء

شروق الصومالي

سمية الغامدي

سمر القحطاني

وجدان الزيد

دعاء وليد

منيرة الضفيان

بشرى قوقندي

لينا الوكيل