

8 LECTURES

Gastro-esophageal reflux disease

Peptic Ulcer Disease

Diarrhea

Malabsorption

Inflammatory bowel disease-1

Inflammatory bowel disease-2

Colonic polyps and carcinoma-1

Colonic polyps and carcinoma-2

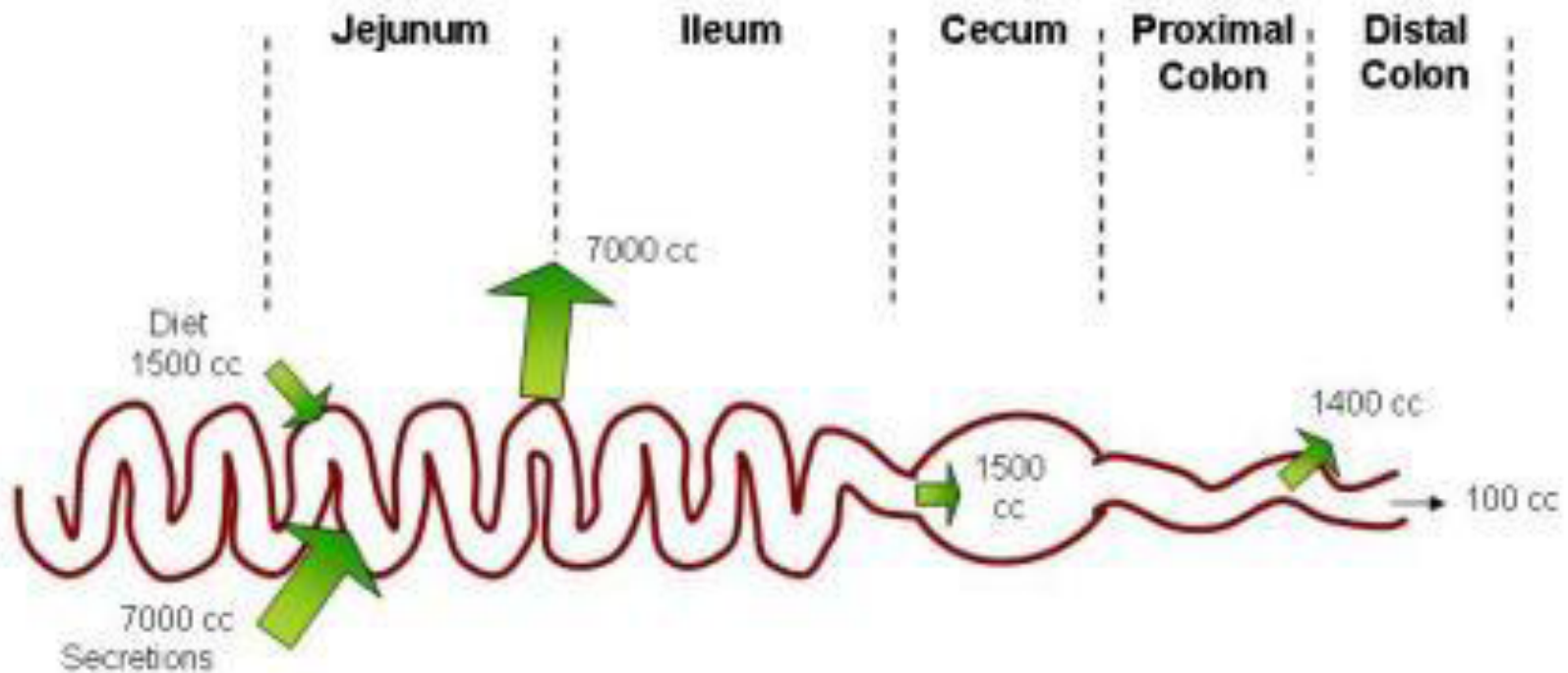
8 LECTURES

Diarrhea

Malabsorption

DIARRREAHA

Physiology of Fluid and small intestine



DIARRHEA

DEFINITION

- World Health Organization
 - 3 or more loose or liquid stools per day
- Abnormally high fluid content of stool
 - > 200-300 gm/day

Fecal osmolarity

- As stool leaves the colon, fecal osmolality is equal to the serum osmolality i.e. 290 mosm/kg.
- Under normal circumstances, the major osmoles are Na^+ , K^+ , Cl^- , and HCO_3^- .

Fecal Osmotic Gap

$$290 \text{ mosm/kg H}_2\text{O} - 2 ([\text{Na}^+] + [\text{K}^+])$$

Osmotic diarrhea: > 125

CLASSIFICATION

1.Acuteif 2 weeks,

2.Persistent if 2 to 4 weeks,

3.Chronicif 4 weeks in duration.

Why important?

- The loss of fluids through diarrhea can cause dehydration and electrolyte imbalances
- Easy to treat but if untreated, may lead to death especially in children

Why important?

More than 70 % of almost 11 million child deaths every year are attributable to 6 causes:

1. Diarrhea
2. Malaria
3. neonatal infection
4. Pneumonia
5. preterm delivery
6. lack of oxygen at birth.

Pathophysiology

Categories of diarrhea

- 1. Secretory**
- 2. Osmotic**
- 3. Exudative (inflammatory)**
- 4. Motility-related**

Secretory

- There is an increase in the active secretion
- High stool output
- Lack of response to fasting
- Normal stool osmotic gap < 100 mOsm/kg
- The most common cause of this type of diarrhea is a bacterial toxin (*E. coli* , cholera) that stimulates the secretion of anions.
- Also seen in Endocrine tumours

Osmotic

- Excess amount of poorly absorbed substances that exert osmotic effect.....water is drawn into the bowels.....diarrhea
- Stool output is usually not massive
- Fasting improve the condition
- Stool osmotic gap is high, > 125 mOsm/kg
- Can be the result of
 1. Malabsorption in which the nutrients are left in the lumen to pull in water e.g. lactose intolerance
 2. osmotic laxatives.

Exudative (inflammatory)

- Results from the outpouring of blood protein, or mucus from an inflamed or ulcerated mucosa
- Presence of blood and pus in the stool.
- **Persists on fasting**
- Occurs with inflammatory bowel diseases, and invasive infections.

Motility-related

- Caused by the rapid movement of food through the intestines (hypermotility).
- **Irritable bowel syndrome (IBS)** – a motor disorder that causes abdominal pain and altered bowel habits with diarrhea predominating

Pathophysiology

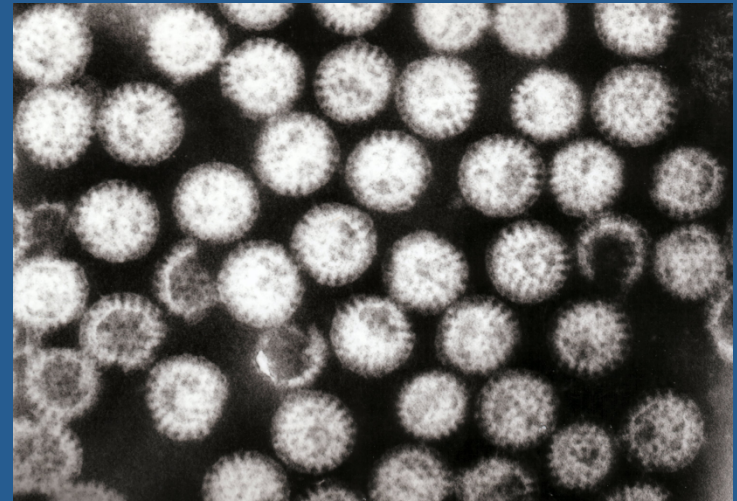
Categories of diarrhea

- 1. Secretory**
- 2. Osmotic**
- 3. Exudative (inflammatory)**
- 4. Motility-related**

Aetiology

Acute diarrhea?

- Approximately 80% of acute diarrheas are due to infections (viruses, bacteria, helminths, and protozoa).
- **Viral gastroenteritis** (viral infection of the stomach and the small intestine) is the most common cause of acute diarrhea worldwide.
- **Food poisoning**
- **Drugs**
- **Others**



Rotavirus the cause of nearly 40% of hospitalizations from diarrhea in children under 5

Antibiotic-Associated Diarrheas

- Diarrhea occurs in 20% of patients receiving broad-spectrum antibiotics; about 20% of these diarrheas are due to *Clostridium difficile*

Aetiology

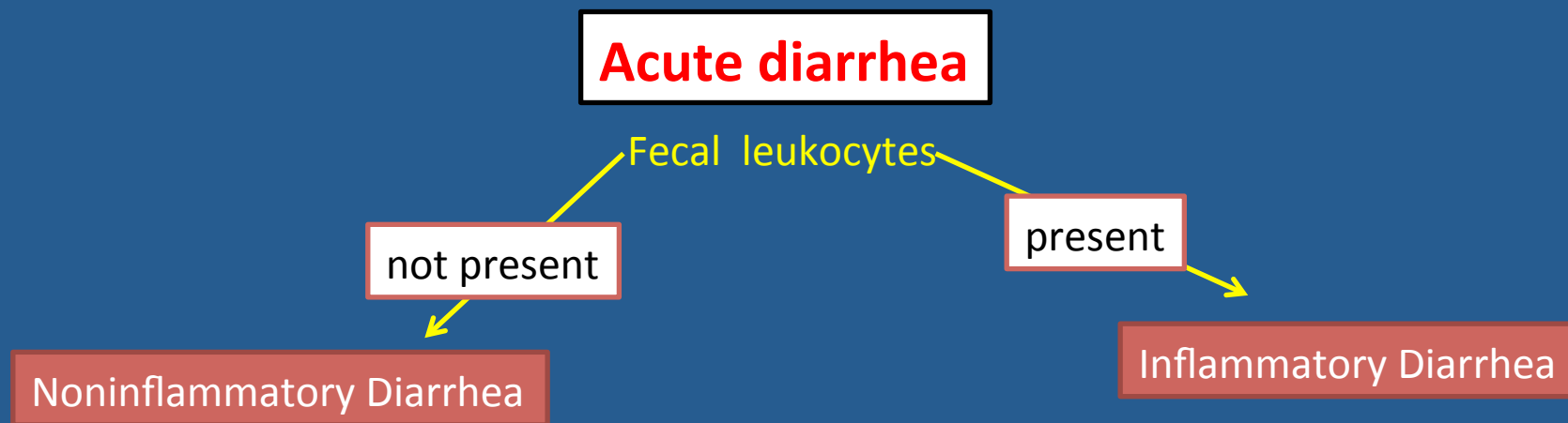
- **Chronic diarrhea?**

1. **Infection** ----- e.g. *Giardia lamblia* . AIDS often have chronic infections of their intestines that cause diarrhea.
2. **Post-infectious.** Following acute viral, bacterial or parasitic infections
3. **Malabsorption**
4. **Inflammatory bowel disease (IBD)**
5. **Endocrine diseases.**
6. **Colon cancer**
7. **Irritable bowel syndrome.**

Complications

1. FluidsDehydration
2. Electrolytes Electrolytes imbalance
3. *Sodium bicarbonate*..... Metabolic acidosis
4. If persistentMalnutrition

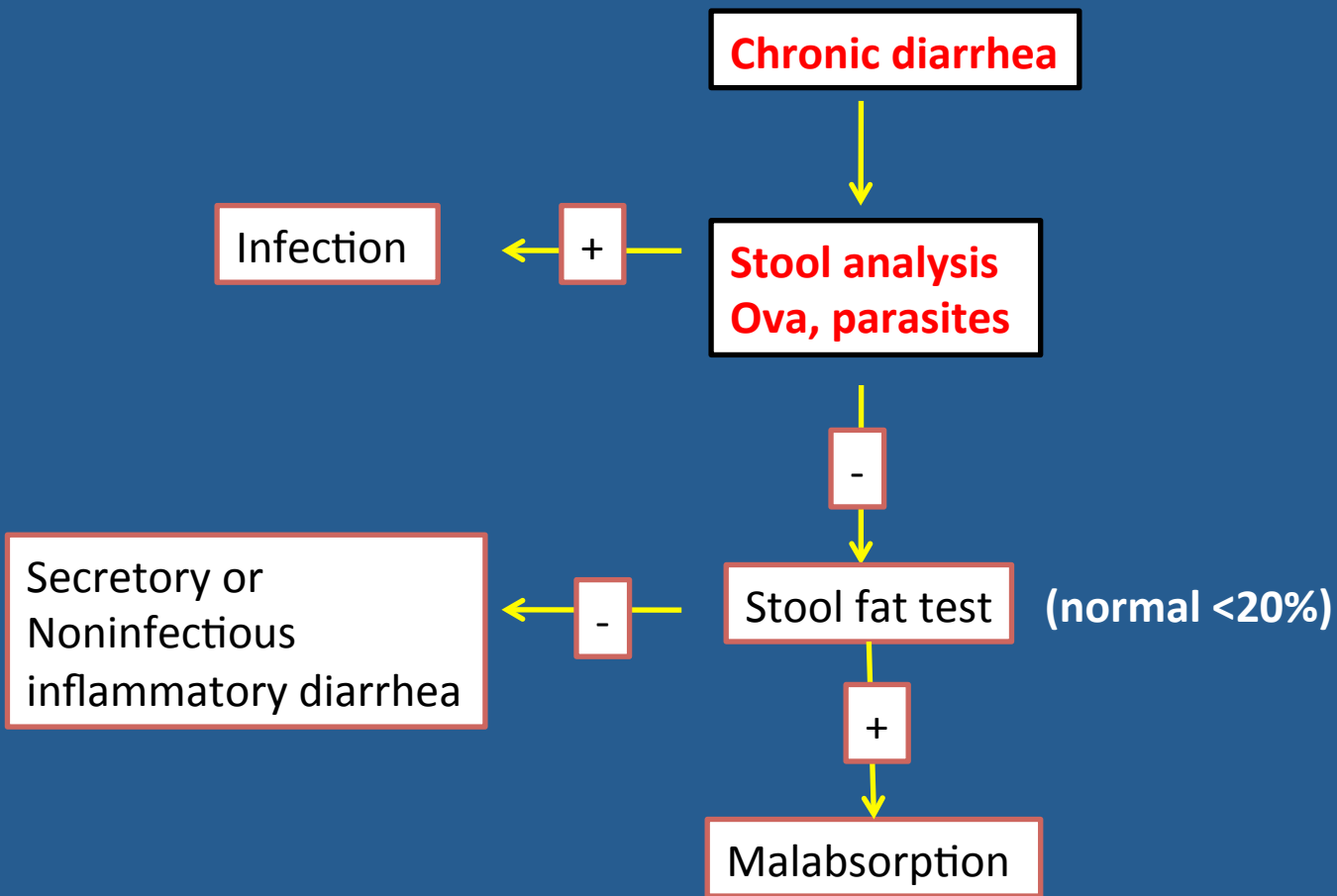
Tests useful in the evaluation of diarrhea



Suggests a **small bowel source**
Or colon but without mucosal injury

Suggests colonic mucosa damage
caused by invasion

- shigellosis, salmonellosis, *Campylobacter* or *Yersinia* infection, amebiasis)
- toxin (*C difficile*, *E coli* O157:H7).
- Inflammatory bowel diseases



8 LECTURES

Diarrhea

Malabsorption

Malabsorption Syndrome

Inability of the intestine to absorb nutrients adequately into the bloodstream.

Impairment can be of single or multiple nutrients depending on the abnormality.

Physiology

- The main purpose of the gastrointestinal tract is to digest and absorb nutrients (fat, carbohydrate, and protein), micronutrients (vitamins and trace minerals), water, and electrolytes.

Mechanisms and Causes of Malabsorption Syndrome

Inadequate digestion

- Postgastrectomy
- Deficiency of pancreatic lipase
- Chronic pancreatitis
- Cystic fibrosis
- Pancreatic resection
- Zollinger-Ellison syndrome

Deficient bile salt

- Obstructive jaundice
- Bacterial overgrowth
- Stasis in blind loops, diverticula
- Fistulas
- Hypomotility states (diarrhea)
- Terminal ileal resection
- Crohn's disease
- Precipitation of bile salts (magnesium)

Primary mucosal abnormalities

- Celiac disease
- Atrophic gastritis
- Whipple's disease
- Giardiasis
- Intestinal lymphangiectasia
- Intestinal eosinophilic enteritis
- Abetalipoproteinemia
- Giardiasis

Inadequate small intestine

- Intestinal resection
- Crohn's disease
- Mesenteric vascular disease with infarction
- Jejunioileal bypass

Lymphatic obstruction

- Intestinal lymphangiectasia
- Malignant lymphoma
- Macroglobulinemia

Many causes

Pathophysiology

Inadequate digestion

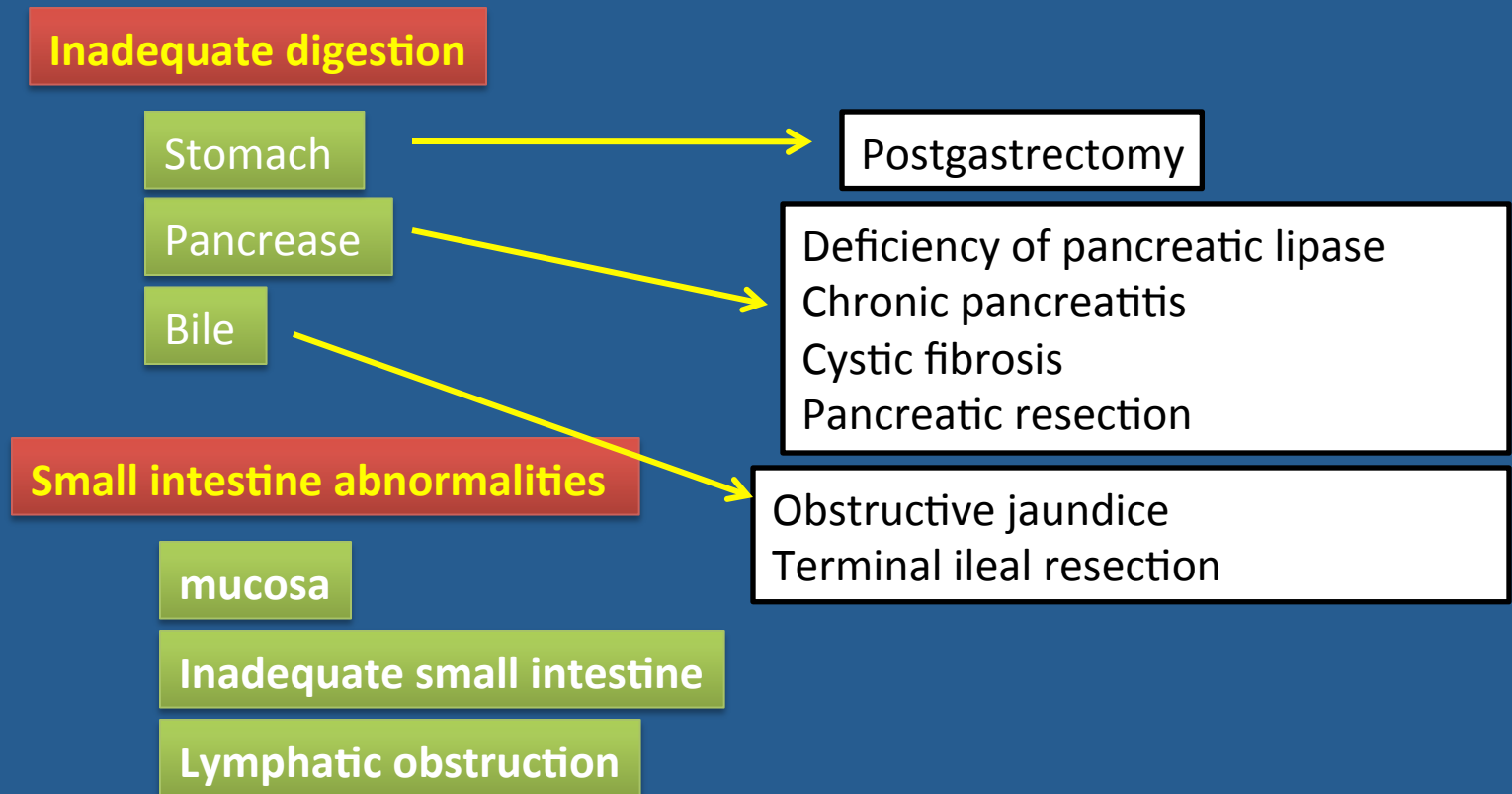
Or

Small intestine abnormalities

=

Malabsorption

Pathophysiology



Pathophysiology

Inadequate digestion

Stomach

Pancreas

Bile

Small intestine abnormalities

mucosa

Inadequate small intestine

Lymphatic obstruction

Celiac disease
Tropical sprue
Whipple's disease
Giardiasis

Intestinal resection
Crohn's disease

Intestinal lymphangiectasia
Malignant lymphoma

Pathophysiology

Pancrease

Bile

mucosa

Malabsorption Syndrome

Clinical features

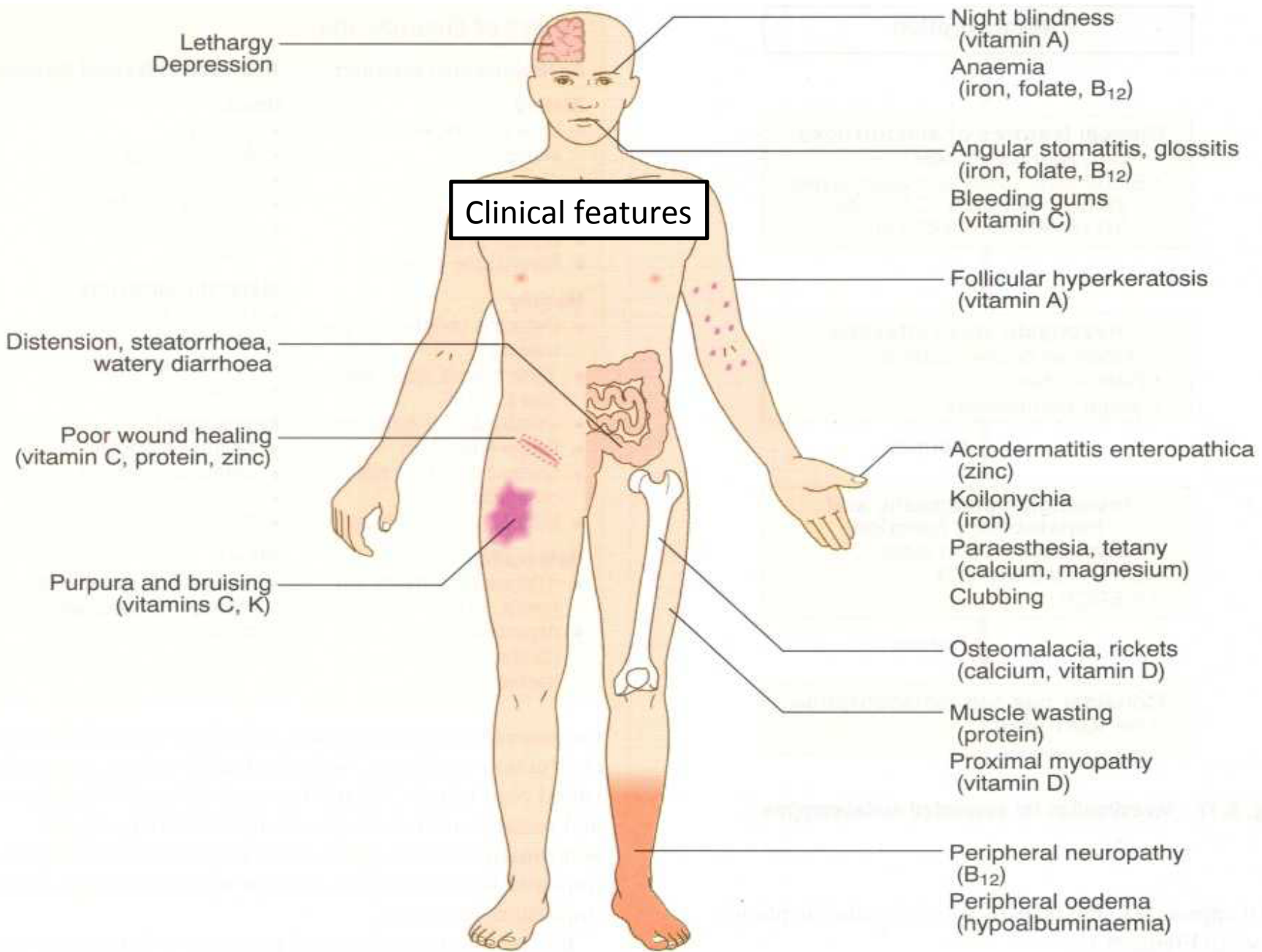
There is increased fecal excretion of fat (**steatorrhea**) and the systemic effects of deficiency of vitamins, minerals, protein and carbohydrates.

Steatorrhea is passage of soft, yellowish, greasy stools containing an increased amount of fat.

Growth retardation, failure to thrive in children

Weight loss despite increased oral intake of nutrients.

Clinical features



Malabsorption Syndrome

Clinical features

Depend on the deficient nutrient

Protein



Swelling or oedema

B₁₂, folic acid and iron deficiency



Anaemia (fatigue and weakness)

vitamin D, calcium



Muscle cramp

Osteomalacia and osteoporosis

vitamin K and other coagulation factor



Bleeding tendencies

Diagnosis

There is no specific test for malabsorption.

Investigation is guided by symptoms and signs.

1. Fecal fat study to diagnose steatorrhoea
2. Blood tests
3. Stool studies

4. Endoscopy

Biopsy of small bowel

Malabsorption Syndrome

Celiac disease

An immune reaction to **gliadin** fraction of the **wheat** protein **gluten**

Usually diagnosed in childhood – mid adult.

Patients have raised antibodies to gluten autoantibodies

Highly specific association with class II HLA DQ2 (haplotypes DR-17 or DR5/7) and, to a lesser extent, DQ8 (haplotype DR-4).

Clinical features

Celiac disease

Typical presentation

GI symptoms that characteristically appear at age 9-24 months.

Symptoms begin at various times after the introduction of foods that contain gluten.

A relationship between the age of onset and the type of presentation;

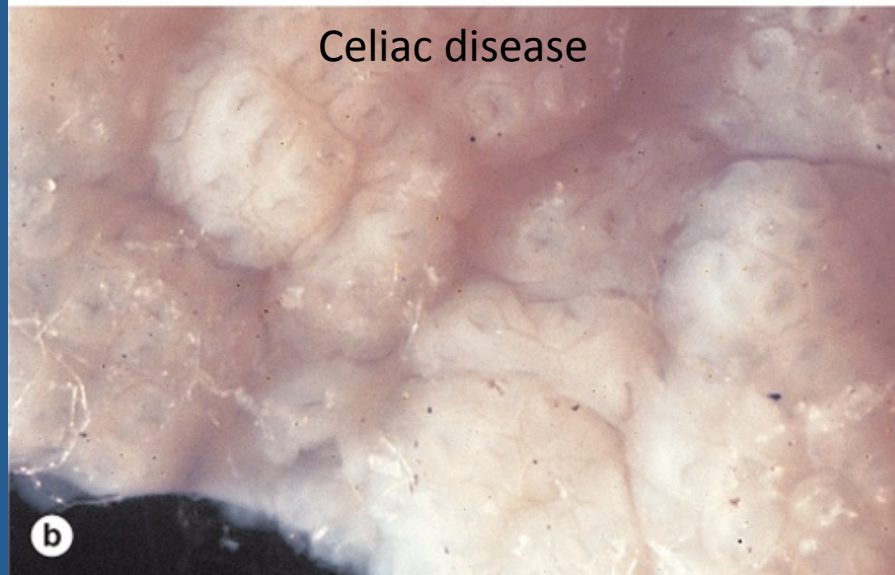
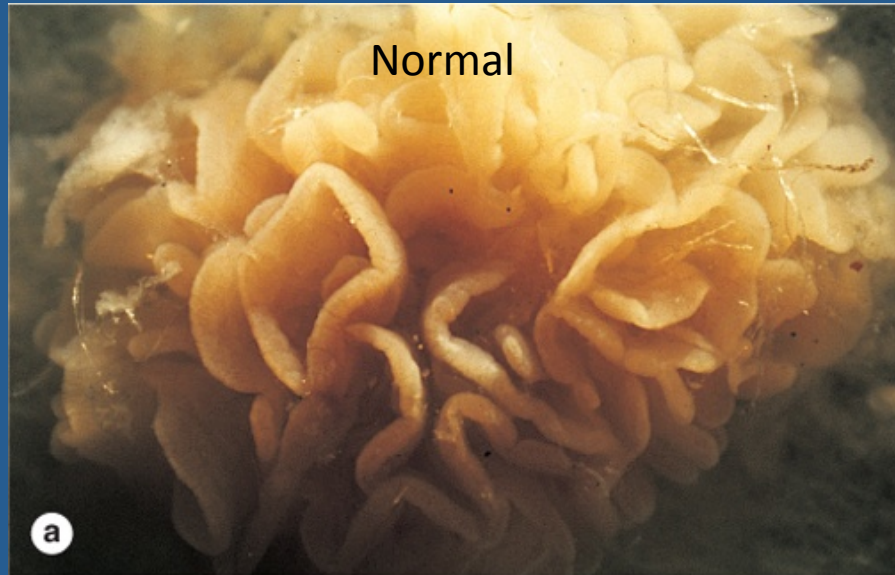Infants and toddlers....GI symptoms and failure to thrive

Childhood.....minor GI symptoms, inadequate rate of weight gain,

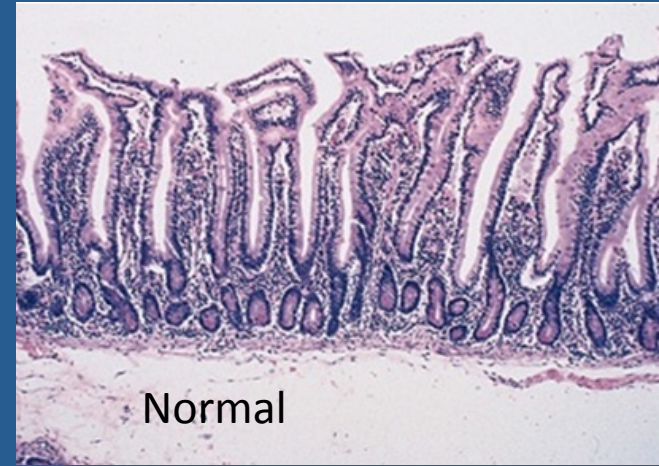Young adults.....anemia is the most common form of presentation.

Adults and elderly.....GI symptoms are more prevalent

Endoscopy

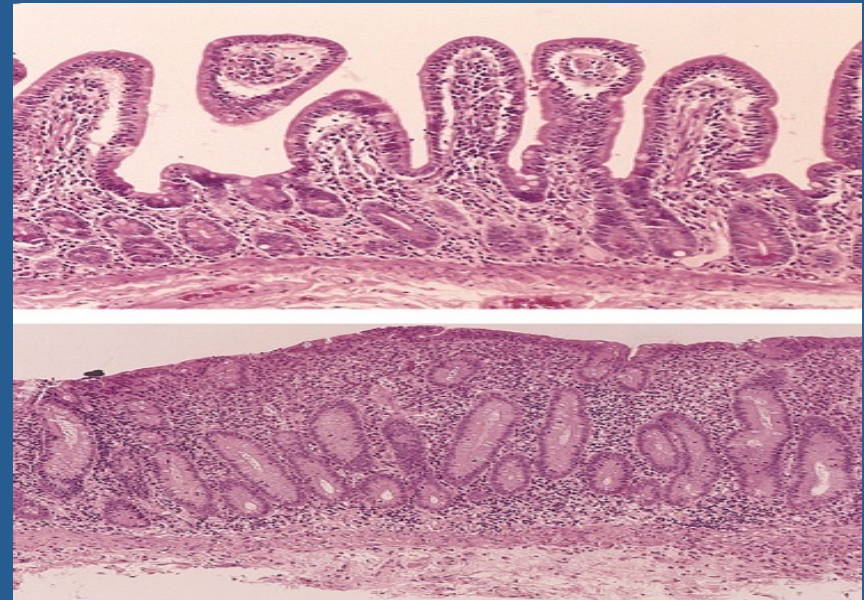


Celiac Disease



Histology

- Mucosa is flattened with marked villous atrophy.
- Increased intraepithelial lymphocytosis



Celiac Disease

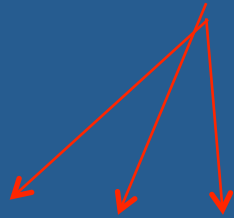
Diagnosis

Clinical documentations of malabsorption.

Stool↑ fat

Small intestine biopsy demonstrate villous atrophy.

Improvement of symptom and mucosal histology on gluten withdrawal from diet.



wheat, barley, flour

Other grains, such as rice and corn flour, do not have such an effect.

Celiac Disease

Complications

Osteopenia , osteoporosis

Infertility in women

Short stature, delayed puberty, anemia,

Malignancies,[intestinal T-cell lymphoma]

10 to 15% risk of developing GI lymphoma.

Lactose Intolerance

Lactose Intolerance

Pathophysiology

lactase

Lactose



glucose + galactose

At the brush border of enterocytes

Lactose Intolerance

Low or absent activity of the enzyme lactase

Lactose Intolerance causes

Inherited lactase deficiency

Congenital lactase deficiency

extremely rare

Childhood-onset and adult-onset lactase deficiency

common

Genetically programmed progressive loss of the activity of the small intestinal enzyme lactase.

Acquired lactase deficiency

Transient

Secondary lactase deficiency due to intestinal mucosal injury by an **infectious, allergic, or inflammatory process**

Gastroenteritis: Infectious diarrhea, particularly viral gastroenteritis in younger children, may damage the intestinal mucosa enough to reduce the quantity of the lactase enzyme.

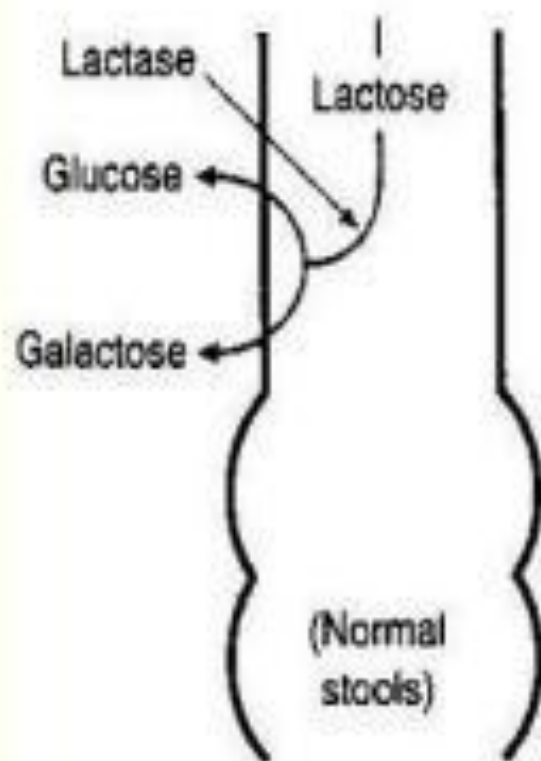
Clinical

Bloating, abdominal discomfort, and flatulence

.....1 hour to a few hours after ingestion of milk products

Lactose Intolerance

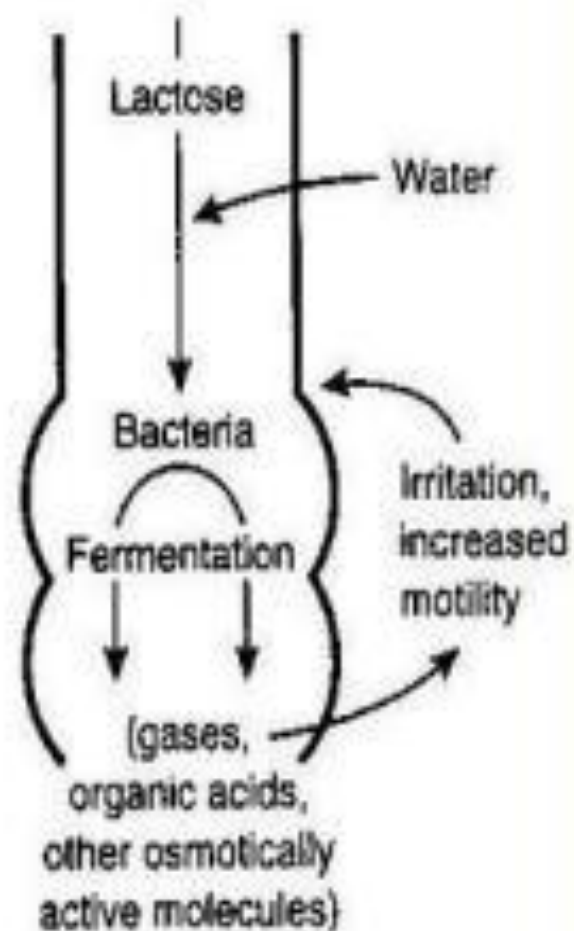
Normal lactose digestion



Lactose intolerance

Small intestine

Large intestine



Lactose Intolerance

Diagnosis

Empirical treatment with a lactose-free diet,
which results in resolution of symptoms;

Hydrogen breath test

Hydrogen breath test .

- An oral dose of lactose is administered
- The sole source of H₂ is bacterial fermentation;
- Unabsorbed lactose makes its way to colonic bacteria, resulting in excess breath H₂.
- Increased exhaled H₂ after lactose ingestion suggests lactose malabsorption.

A 3-week trial of a diet that is free of milk and milk products is a satisfactory trial to diagnose lactose intolerance

Lactose Intolerance

summary

- Deficiency/absence of the enzyme lactase in the brush border of the intestinal mucosa → maldigestion and malabsorption of lactose
- Unabsorbed lactose draws water in the intestinal lumen
- In the colon, lactose is metabolized by bacteria to organic acid, CO₂ and H₂; acid is an irritant and exerts an osmotic effect
- Causes diarrhea, gaseousness, bloating

A

1. Fasting improve the condition
2. inflammatory bowel diseases
3. High stool output
4. Presence of WBC in stool
5. Irritable bowel syndrome
6. bacterial toxin
7. Malabsorption
8. High fecal osmotic gap

B

- a) **Secretory**
- b) **Osmotic**
- c) **Exudative (inflammatory)**
- d) **Motility-related**

A

1. Irritable bowel syndrome
2. Giardia lamblia
3. Viral gastroenteritis
4. Inflammatory bowel disease
5. Food poisoning
6. Antibiotic-Associated Diarrheas
7. Malabsorption

B

- a) **Acute diarrhea**
- b) **Chronic diarrhea**

CLASSIFICATION

diarrhea

1.Acute

2.Persistent

3.Chronic

What are complications of diarrhea?

What are complications of malabsorption?

Pathophysiology of malabsorption ?

Clinical presentation of malabsorption ?

What is Celiac disease?

A 44 year-old man is admitted to the hospital with an acute upper GI bleed due to several gastric and duodenal ulcers seen on an urgent upper endoscopy. One of the duodenal ulcers is in the 3rd portion of the duodenum. The patient also complains of a 1 year history of frequent non-bloody diarrhea. A fecal osmotic gap is very low.

- What type of chronic diarrhea does this patient have?
- What is the most likely cause?
- What is the mechanism to explain the diarrhea?
- What blood test can you check to make the diagnosis?

- A 10-month-old, previously healthy male infant develops a severe, watery diarrhea 2 days after visiting the pediatrician for a routine checkup. The most likely diagnosis is
 - a. Rotavirus infection
 - b. Enterotoxigenic *E. coli* infection
 - c. *Entamoeba histolytica* infection
 - d. Lactase deficiency
 - e. Ulcerative colitis

Scenario

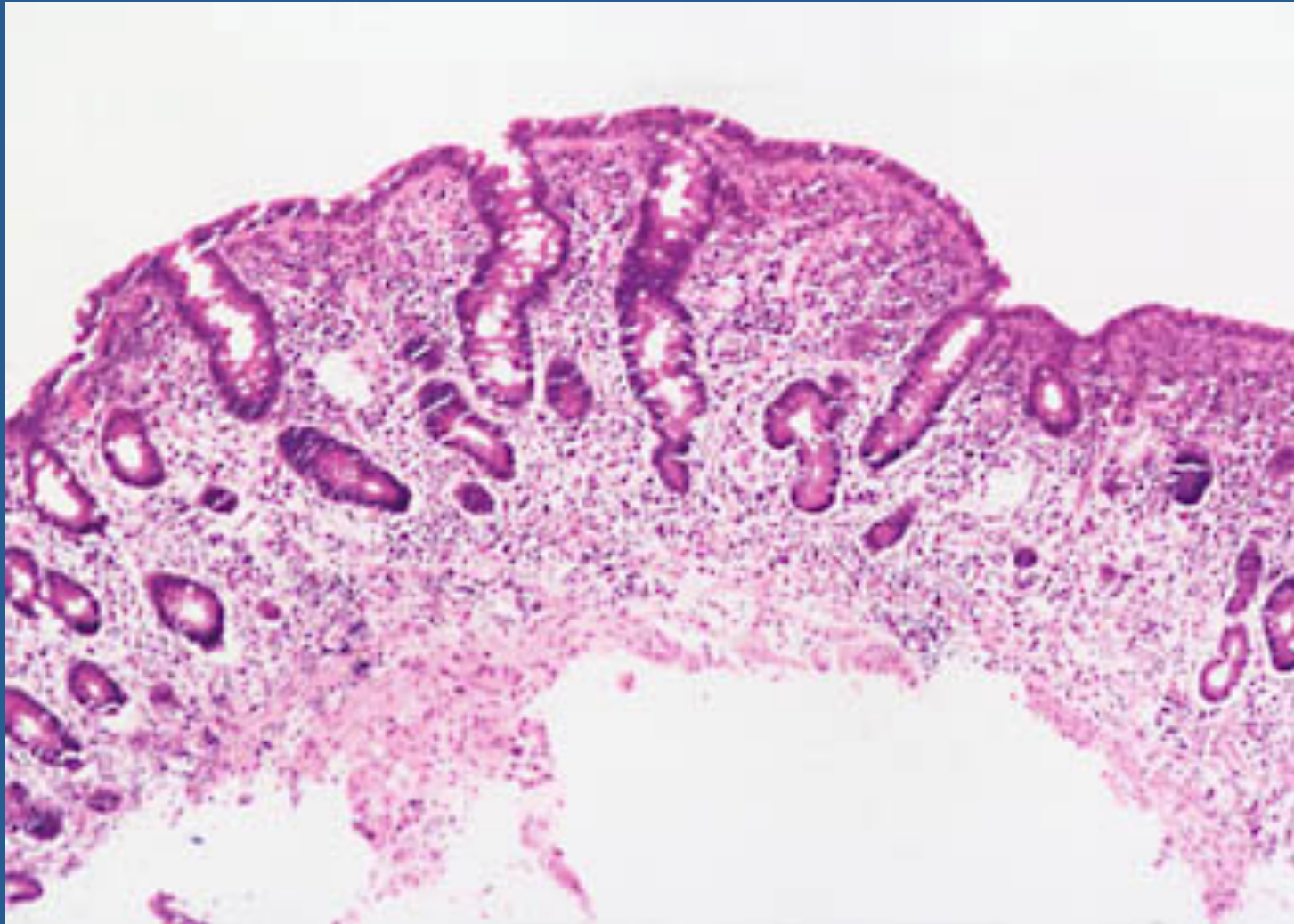
A 44-year-old white male presented with a seven-month history of diarrhea. The frequency of his bowel movements had increased to 5-7 per day, and his stools were yellow and floated at the top of the water in the toilet. He had occasional abdominal cramping, but no tenesmus, melena, or bleeding. His appetite was good, but he had experienced gradual weight loss. His bowel movement frequency would decrease upon fasting and would increase with food intake.

Stool tests revealed a stool output of 4128 g/d (nl 100-200 g/d) with fat excretion of 17 g/d (nl <5 g/d).

Microscopic examination for ova and parasites and cultures for bacterial pathogens and acid-fast bacilli were negative.

Blood testing showed mild anemia , hypoproteinemia (4.9 mg/dL), and hypoalbuminemia (3.4 mg/dL).

Duodenal biopsy



- Exposure to what dietary antigen is thought to be the cause of these changes?

Exposure to gluten (specifically, the gliadin constituent of this protein)

- What food components contain this antigen?

Wheat, barley, flour, and possibly oats contain gluten.

- Would these histologic changes resolve with dietary modification?

yes

A 6-year-old boy has been brought to outpatients by his mother because he has abdominal pain after some meals. This has been getting increasingly frequent and it sounds, from his description, somewhat colicky in nature. You discover that he has always had very smelly, loose, pale bulky stools, which his parents have put down to the fact that he likes milk. On examination, he is pale, underweight, and of short stature.

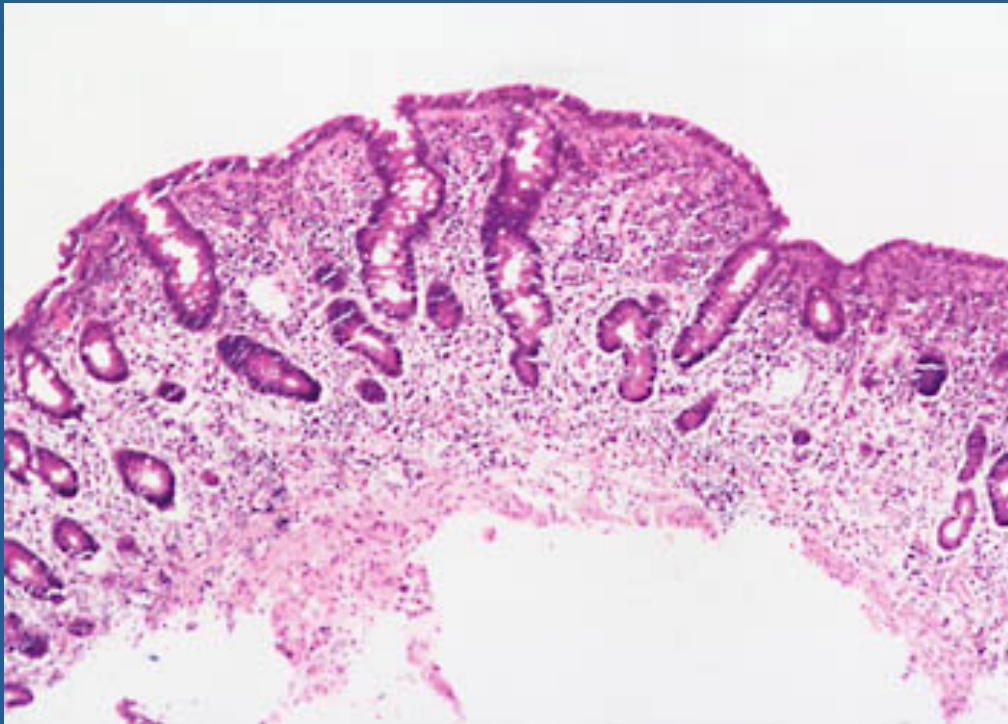
- 1. What are the important differential diagnoses on presentation?

Celiac disease is the most likely diagnosis. Parasitic infection (e.g. giardiasis) and pancreatic insufficiency (e.g. due to chronic pancreatitis or cystic fibrosis) may give rise to a similar presentation, but these are not supported by the results of the investigations.

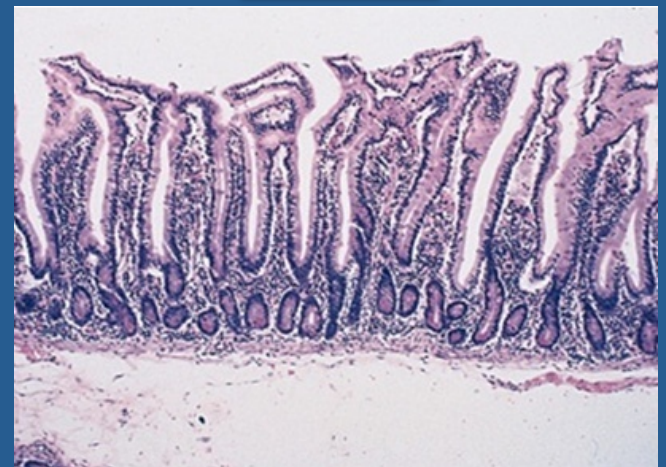- 2. Blood tests reveal a mild macrocytic anemia. There is a low level of vitamin B12, and folate is at the lower end of normal. Autoantibody screens reveal a positive reaction to antigliadin antibodies. Do these tests help to narrow down the diagnosis?

These results are very suggestive of celiac disease due to the low levels of vitamin B¹² and the hypersensitivity reaction to α -gliadin, a component of gluten. The finding of villous atrophy would support the diagnosis, and this is achieved by endoscopic biopsy of the first part of the duodenum.

- 3. A duodenal biopsy shows



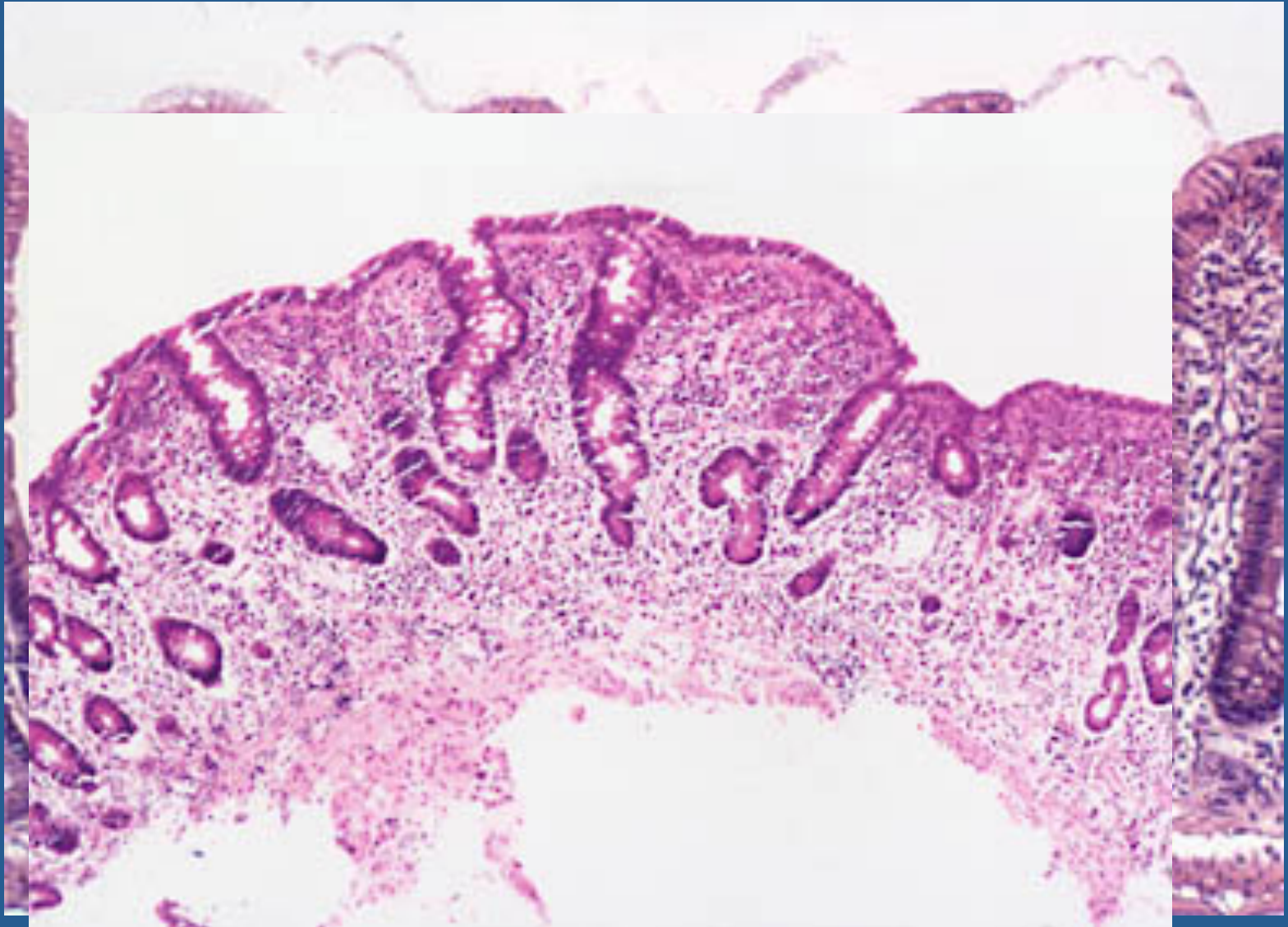
Normal



- The final diagnosis is celiac disease, provided the patient's symptoms respond to a gluten-free diet and the histological changes relapse on re-challenge. Such criteria are necessary before confining a patient to a lifelong gluten-free diet.

- 4. What treatment options are available?

Treatment is by adhering to a strict gluten-free diet.



- How to diagnose lactose intolerance ?

Empirical treatment with a lactose-free diet, which results in resolution of symptoms;

Hydrogen breath test

- How to treat lactose intolerance ?

lactose-free diet