

Cancers Of The Liver & Pancreas



Objectives:

Upon completion of **cancer of the liver & pancreas** lecture students will be able to:

- Describe hepatocellular and cholangiocarcinoma.
- Understand the frequency of metastatic disease to the liver.
- Recognize the rarity of primary liver neoplasms in children.
- Recognize all aspects of pancreatic carcinoma.



Cancers Of The Liver & Pancreas

- Recognize The Rarity Of Primary Liver Neoplasms In Children.

Malignant tumors of the liver:



malignant liver tumors By osmosis (6:56 min)

- The liver and lungs are the visceral organs that are most often involved by **metastasis tumors**.
- Primary carcinomas of the liver are relatively **uncommon**.
- **Most** arise from hepatocytes and are termed *hepatocellular carcinoma (HCC)*.
- Much less common are carcinomas of bile duct origin, *cholangiocarcinomas*¹
- **There are two rare forms of primary liver cancer hepatoblastomas² and angiosarcomas.**

Something you need to know for your entire life: Most common tumors of the liver are metastatic tumors \ Most common primary tumor of the liver is HCC

- Describe Hepatocellular.

Hepatocellularcarcinomas HCC

- Previously called Hepatoma
- **Male predominance.**
- More than 85% of cases of HCC occur in countries with high rates of **chronic HBV infection**. In these regions, the **HBV carrier state begins in infancy** الجنين حامله من الأم following vertical transmission of virus **from infected mothers**, conferring a 200-fold increased risk for HCC by adulthood³.
- In the Western world where HBV is not prevalent, **cirrhosis** is present in 85% to 90% of cases of HCC, usually in the setting of other chronic liver diseases. "Due to alcoholism"

¹ extra&intrahepatic bile ducts.

² (a childhood hepatocellular carcinoma) Blastoma=children tumor and angiosarcomas.

³ Vertical transmission: Passage of a pathogen from mother to baby during the period immediately before and after birth.

Pathogenesis of HCC in human

- 1) **Viral infection (HBV, HCV):** Extensive studies link **chronic** HBV and chronic HCV infection with liver cancer.
- 2) Cirrhosis: The development of cirrhosis appears to be an important, but not requisite, contributor to the emergence of HCC. *Chronic injury then inflammation then fibrosis then cirrhosis*
- 3) Chronic alcoholism.
- 4) Food contaminants (primarily aflatoxins from aspergillus): High exposure to dietary aflatoxins derived from **the fungus Aspergillus flavus**. These highly carcinogenic toxins are found in "moldy" grains and peanuts.

Aflatoxins combined with HBV infection increases the risk for HCC dramatically.

- 5) Other conditions include tyrosinemia⁴ and hereditary hemochromatosis excess iron accumulates in tissues and organs disrupting their normal function. *Due to long standing non-alcoholic fatty liver diseases*
- 6) Metabolic syndrome: e.g. **obesity, diabetes mellitus**, and NAFLD(Non Alcoholic Fatty Liver Disease), all of which increase the risk for HCC. These only increase the risks due to long standing non-alcoholic fatty liver disease which leads to HCC

Morphology of HCC:

Grossly it may be:



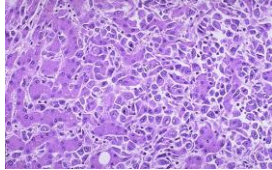
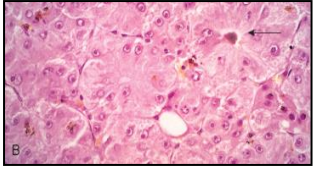
- 1) A **unifocal** mass
- 2) **Multifocal**, multiple nodules of variable size;
- 3) A **diffusely infiltrative** cancer.
 - All three patterns may cause liver enlargement. **All patterns of hepatocellular carcinomas have a strong propensity⁵ for invasion of vascular channels.** *Can be both well or ill differentiated*
 - Extensive **intrahepatic metastases** may occur.
 - Tumor may invade the portal vein (with occlusion of the **portal circulation**) or inferior vena cava, extending even into the right side of the heart.
 - **Lymph node metastases** to the perihilar, peripancreatic, and para-aortic nodes above and below the diaphragm can be present.
 - Hepatocellular carcinomas range from well-differentiated to highly anaplastic undifferentiated lesions.
 - In well-differentiated and moderately well-differentiated tumors, cells that are recognizable as hepatocytic in origin. Bile pigment is usually present. The malignant cells may be positive for alpha-fetoprotein.

⁴ is an error of metabolism, usually inborn, in which the body cannot effectively break down the amino acid tyrosine.

⁵ tendency

- In poorly differentiated forms, tumor cells can take on a pleomorphic appearance with numerous anaplastic giant cells, can become small and completely undifferentiated cells.

Immune stain for alpha feto protein is + in fatty liver.


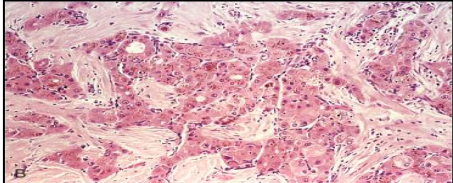
			
<p>Hepatocellular carcinoma Such liver cancers arise in the setting of cirrhosis.</p> <p>Worldwide, viral hepatitis is the most common cause, but in the U.S., chronic alcoholism is the most common cause.</p> <p>The neoplasm is large and bulky and has a greenish cast because it contains bile. To the right of the main mass are small satellite nodules.</p>	<p>The satellite nodules of this hepatocellular carcinoma.</p>	<p>Malignant cells of HCC (seen mostly on right) are well differentiated and interdigitate with normal, larger hepatocytes (seen mostly at left).</p>	

Fibrolamellar carcinoma:

A distinctive variant of hepatocellular carcinoma is the fibrolamellar carcinoma.

- This tumor occurs in **young** male and female adults (20 to 40 years of age), has **no association with HBV or cirrhosis**, and often has a better prognosis.

1. Youngers 2. Better prognosis 3. Not related to HBV or cirrhosis. لأنه هذا النوع يعتبر ماله دخل بالرسكس اللي ذكرناها فوق لأنه
Otherwise it's a HCC

<p>It usually presents as single large, hard "scirrhous" tumor with fibrous bands coursing through it كأنه طبقات من الفايبرس تشبوز strong fibrosis</p>	<p>On microscopic examination, it is composed of well-differentiated polygonal cells growing in nests or cords and separated by parallel lamellae of dense collagen bundles</p>
	

Clinical Features: مثله مثل أي تيومر بالجسم

- **Ill-defined upper abdominal pain, malaise, fatigue, weight loss, and feeling of abdominal fullness.**
- In many cases, the **enlarged liver can be felt on palpation**. Jaundice and fever are uncommon.
- **Laboratory studies: Elevated levels of serum α -fetoprotein + liver mass are found in 50% to 75% of patients with HCC.** Remember in carcinoid syndrome serotonin was high

Overall, death usually occurs from

- 1) **cachexia**⁶
- 2) **gastrointestinal or esophageal variceal bleeding**
- 3) **liver failure** with hepatic coma
- 4) rupture of the tumor with fatal hemorrhage. Biopsy is the gold standard

- Describe Cholangiocarcinoma.

Cholangiocarcinoma:

- It's an **intrahepatic biliary system** which is adenocarcinoma
- Cholangiocarcinoma is a malignancy of the **biliary tree**, arising from bile ducts within (intrahepatic) and outside (extrahepatic) of the liver.
- It is the **second most common primary malignant tumor of the liver** after HCC Maybe extra or intrahepatic

Risk factors:

- **Primary sclerosing cholangitis**.⁷
- Congenital fibropolycystic diseases of the biliary system (particularly **Caroli disease**⁸ and choledochal cysts). Cystic dilation
- Previous exposure to **Thorotrast**⁹ (formerly used in radiography of the biliary tract).
- In the Orient, the incidence rates are higher, and it is due to chronic Infection of the biliary tract by the liver fluke **Opisthorchis sinensis**¹⁰. هذي الباراسيت موجودة بالسوشي
😊وتعيش بالبلياري تري يعني محبين السوشي انتبهوا

⁶ cachexia: general physical wasting and malnutrition usually associated with chronic disease


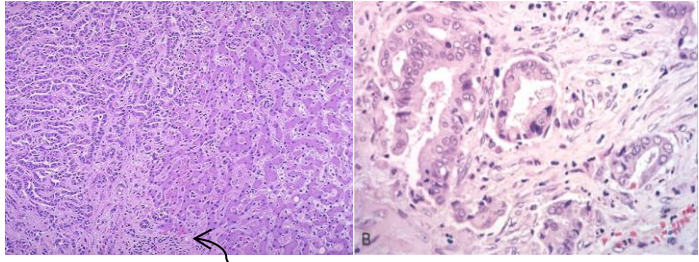
⁷ chronic liver disease characterized by a progressive course of cholestasis with inflammation and fibrosis of the intrahepatic and extrahepatic bile ducts.

⁸ Which is a dilatation of biliary system

⁹ تستخدم في الراديولوجي عشان يشوفوا فيها

¹⁰ ديدان تعيش في biliary tree

Morphology

Gross	Microscopic
	 <p data-bbox="829 632 1516 806">The carcinoma at the left has a glandular appearance. Cholangiocarcinomas do not make bile, but the cells do make mucin, and they can be almost impossible to distinguish from metastatic adenocarcinoma on biopsy or fine needle aspirate.</p>
<ul style="list-style-type: none"> • Intrahepatic cholangiocarcinomas occur in the non-cirrhotic liver and may track along the intrahepatic portal tract system to create a treelike tumorous mass within the liver or a massive tumor nodule. Lymphatic and vascular invasion are common. <p data-bbox="168 1184 467 1220">بالبداية فوكس بعدين تبدأ تنتشر!</p>	<ul style="list-style-type: none"> • Resemble adenocarcinomas arising in other parts of the body. • Most are well to moderately differentiated. • Cholangiocarcinomas are rarely bile stained, because differentiated bile duct epithelium does not synthesize bile. • Mixed variants occur, in which elements of both hepatocellular carcinoma and cholangiocarcinoma are present. • Hematogenous metastases to the lungs, bones (mainly vertebrae), adrenals, brain. • Lymph node metastases to the regional lymph nodes are also found. invasive tumor due to dysplasia

Clinical Features:

- Intrahepatic cholangiocarcinoma is usually **detected late** in its course, either as the result of obstruction to bile flow through the hilum of the liver or as a symptomatic liver mass.
- Prognosis is poor.
- The median time from diagnosis to death is 6 months.
- **Aggressive surgery** remains the only treatment offering hope for long-term survival.

Alpha-fetoprotein is not elevated.

Usually Detected late

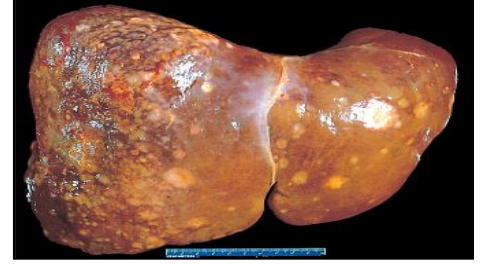- Understand The Frequency Of Metastatic Disease To The Liver.

Metastatic tumors: Metastasis from Colon .lung. Breast

Metastatic involvement of the liver is far more common than primary neoplasia. Although the **most common primaries** producing hepatic metastases are those of **the breast, lung, and colon**, any cancer in any site of the body may spread to the liver, including leukemia's and lymphomas. Typically, multiple nodular metastases are found that often cause striking **hepatomegaly** and may replace over 80% of existent hepatic parenchyma. The liver weight can exceed several kilograms.



Numerous mass lesions of variable size. Some of the larger ones demonstrate central necrosis. The masses are metastases to the liver.
COIN LESION



Angiosarcoma

This consists of **pleomorphic endothelial cells** with **large hyperchromatic nuclei**, giant cells in frequent **mitosis** and irregular anastomosing vascular channels. The cells may appear spindle shaped.

Cirrhosis is present in 20% to 40% of the cases.

These have also been linked to **vinyl chloride¹¹** and **thorotrast¹²** exposure. **Chemical carcinogens.**

Hepatocellular Adenomas¹³

- **Benign neoplasms developing from hepatocytes**
- Sex hormone exposure (e.g., **oral contraceptive pills, anabolic steroids**) markedly increases the frequency of hepatic adenoma
- They may be detected incidentally as a hepatic mass on abdominal **imaging** or when they cause symptoms.
- The **most common symptom is pain**, occasionally rupture, an event that may lead to life-threatening intraabdominal bleeding **Remember risk factors**

¹¹ Vinyl chloride is a gas with a sweet odor. It is highly toxic, flammable, and carcinogenic. It can be formed in the environment when soil organisms break down "chlorinated" solvents. Vinyl chloride that is released by industries or formed by the breakdown of other chlorinated chemicals can enter the air and drinking water supplies.

² Thorotrast is a suspension containing particles of the radioactive compound thorium dioxide, ThO₂, that was used as a radiocontrast agent in medical radiography in the 1930s and 1940s.

¹³ **Adenoma: BENIN TUMOR ORIGINATING FROM GLANDS**

Recognize All Aspects Of Pancreatic Carcinoma

Pancreatic carcinoma

Epidemiology

Pancreatic cancer has one of the **highest mortality** rates of any cancer. It is carcinoma of the **exocrine** pancreas. It arises from **ductal** epithelial cells. **Adenocarcinoma**. It occurs in the 6th to 8th decade, blacks more than whites, males more than females, **diabetics** more than non-diabetics.

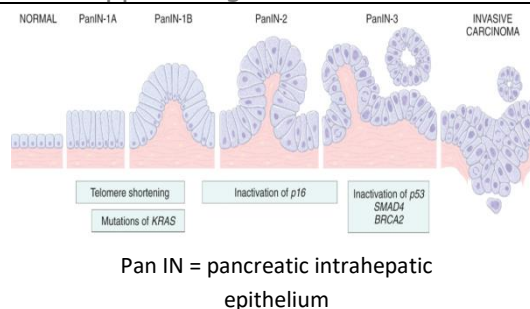
Risk factors

1. **Smoking**, which doubles the risk.
2. **Long-standing chronic pancreatitis** and diabetes mellitus.
3. Germ line mutations of the familial breast/ovarian cancer gene **BRCA2** are seen in approximately 10% of cases arising in individuals of Ashkenazi origin.
Hereditary pancreatic. Bad prognosis

Pathogenesis: genetic mutation (in epithelial cells lining ducts) → either activates oncogenes or inactivates tumor suppressor genes → uncontrolled cell growth

Pancreatic cancer arises as a consequence of inherited and acquired mutations in cancer-associated genes

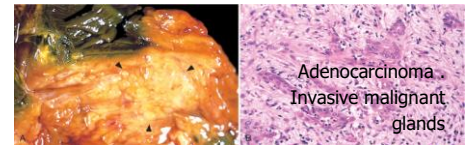
لما ما يكون فيه انفيجن (يعني باقي في حدود الابثيليم) نسيميه Pan in مع كل تغير في phenotype يسبقه تغير في genotype



four genes are most commonly affected by somatic mutations in this neoplasm: **KRAS, CDKN2A/p16, SMAD4, and TP53**

Morphology: Carcinomas of the pancreas are usually hard, stellate, **gray-white, poorly defined masses**.

Starts Benign then hyperplasia and proliferation then atypia then low grade dysplasia then high grade dysplasia then carcinoma in situ then invasive but before all that is molecular changes (kras,p53..etc)



Location	Characterized by	Metastasis	Variation
Approximately 60% of cancers of the pancreas arise in the head of the gland , 15% in the body, and 5% in the tail; in 20%, the neoplasm diffusely involves the entire gland.	Majority of carcinomas are ductal adenocarcinomas. Two features are characteristic: It is highly invasive مثل الكولونيجيوكارسينوما, and it elicits an intense non-neoplastic host reaction called a "desmoplastic response ¹⁴ ."	Peripancreatic, gastric, mesenteric, omental, and portahepatic lymph nodes are frequently involved . Distant metastases occur, principally to the lungs and bones.	Less common variants of pancreatic cancer include acinar cell carcinomas, adenosquamous carcinomas, and undifferentiated carcinomas with osteoclast-like giant cells .
Clinical features			
<p>Jaundice, weight loss, pain, massive metastasis to liver and migratory thrombophlebitis When The tumor in the Head it shows early symptoms but in tail late symptoms Most pancreatic cancers are diagnosed at an advanced stage, accounting for the high mortality rate</p>			

¹⁴ This term refers to the growth of fibrous or connective tissue.

Summary

1. In biochemistry tests, there will be an elevation of alpha-fetoprotein in Hepatocellular carcinoma & Fibrolamellar carcinoma, while there are elevation of alkaline phosphate & aminotransferases in Cholangiocarcinoma.
2. Large hyperchromatic nuclei & pleomorphis endothelial cell & irregular anastomosing vascular channels are characters of angiosacroma.
3. single large, hard "scirrhous are characters of fibrolamellar canciroma.
4. diffusely infiltrative, multi/focal mass are characters of hepatocellular canciroma.
5. treelike tumorous mass within the liver or a massive tumor nodule are characters of cholangiocarcinoma.
6. Common precursors of Malignant tumor of the liver are: Cellular changes and Nodular lesions, Usually found in late-stage disease.
7. An important criterion for indication of malignancy is nodule vascularization, visualized by imaging.
8. It's uncommon of fibrollamellar carcinoma to cause jaundice & fever, put this type has a good prognosis.
9. Lymphatic and vascular invasion are common in Intrahepatic Cholangiocarcinoma.
10. In pacreatic cancers, if the tumor was located in the head it will cause jaundice, if it was located in the body or tail it will remain silent.
11. Ductal adenocarcinomas Is highly invasive & caused reaction called "desmoplastic response".
12. Four genes are most commonly affected by somatic mutations in pancreatic cancers: KRAS, CDKNA2A/p16, SMAD4, and TP53.
13. Jaundice is seen only in pacreatic cancers (head of pancreas) & Cholangiocarcinoma especially extrahepatic Cholangiocarcinoma.

Questions

1. Which of the following is the most common to develop Hepatocellular carcinoma:

- A. a-HAV
- B. b-HBV
- C. c- HCC
- D. d- a+c

answer: B

2. Which of the following is the most common malignant tumor of the liver:

- A. a-cholangiocarcinoma
- B. b- metastatic tumors
- C. c- primary HCC
- D. d- HCC of a viral infection to the liver

answer: B

3. Which one of the following is not from the usually causes of death in Hepatocellular Carcinoma patients?

- A. gastrointestinal bleeding
- B. rupture of the tumor
- C. metastasis to the lungs

answer: C

4. In HCC, the tumor may extend into the right side of the heart.

- A. true
- B. false

answer: A

5. A 70 year old male developed a mass in his liver, on history he said that he had a radiological examination done to him and was exposed to thorostrast. Which one of these tumors is the most likely diagnosis?

- A) Angiosacroma
- B) Hepatocellular adenoma
- C) Hepatocellular carcinoma . answer is A

6. Which one of the following is true about well-differentiated and moderately well-differentiated HCC:

- A. cells that are recognizable as hepatocytic in origin.
- B. Bile pigment is usually present.
- C. The malignant cells may be positive for alpha-fetoprotein.
- D. all of the above

answer: D

حسبي الله لا إله إلا هو عليه توكلت وهو رب العرش العظيم.

الأعضاء

- رنيم الغامدي
- فاطمة الطاسان
- بشرى قوقندي
- شروق الصومالي
- سمر القحطاني
- ليلى البريكان
- أمل القرني
- ابتسام المطيري

القادة

- مها الغامدي
- حنين السبكي
- عبدالله أبو عمارة

Editing File

Email: pathology436@gmail.com

Twitter: @pathology436

