

Radiological Anatomy of the Adrenal Gland

Practical (2)

Radiology

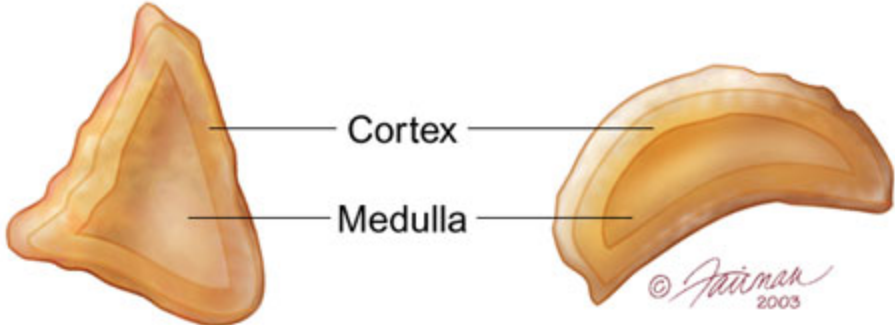
- **Main Objective:**

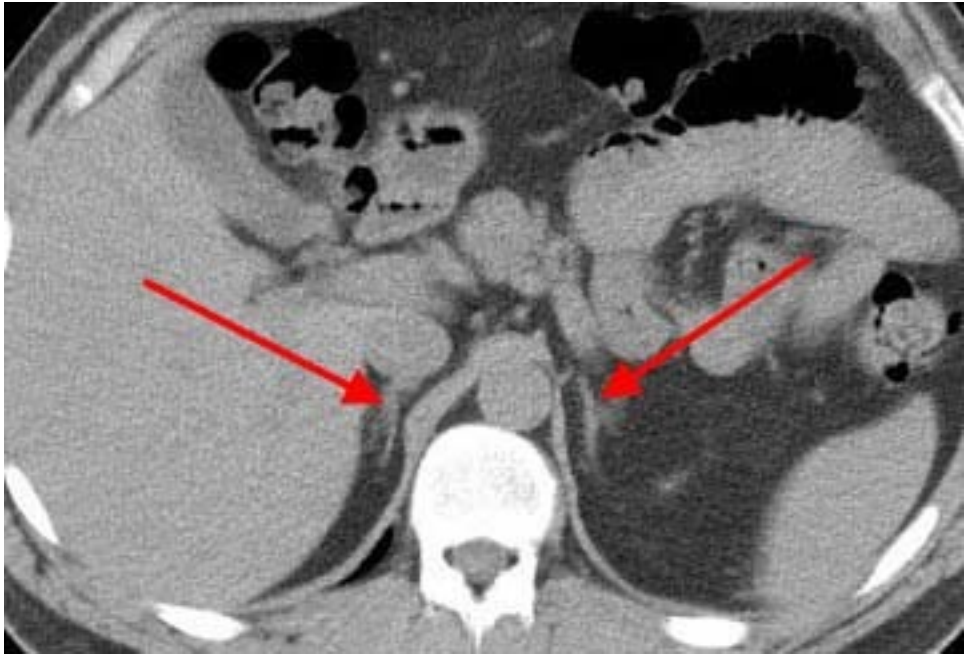
Know the anatomy of adrenal gland in real person through medical imaging (Radiology), and correlated with gross sectional anatomy.

- US.
- CT.
- MR.

Right adrenal gland

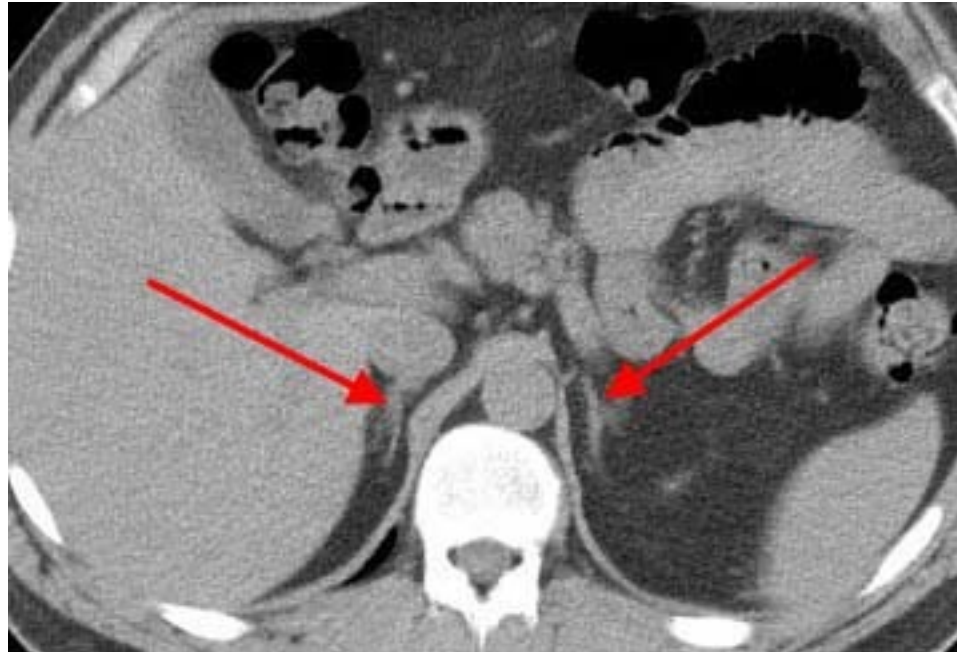Left adrenal gland





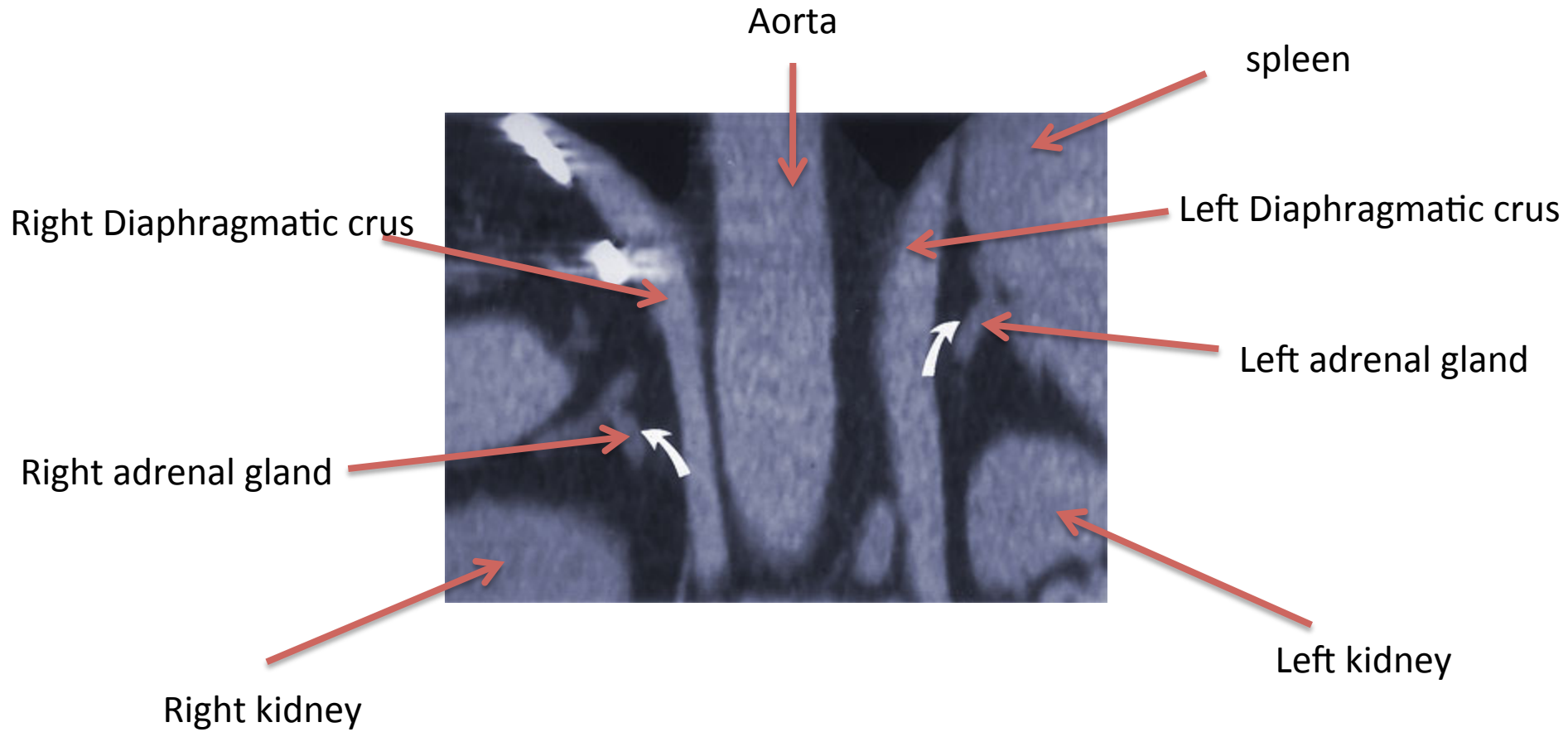
Axial CT Scan

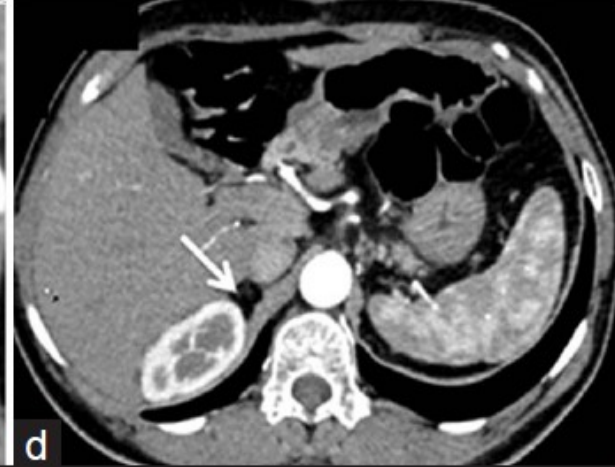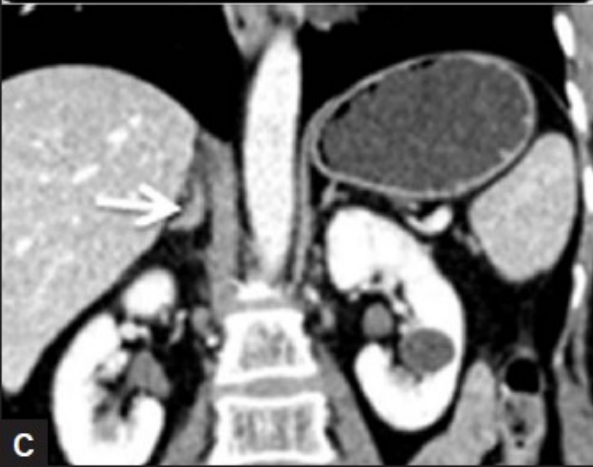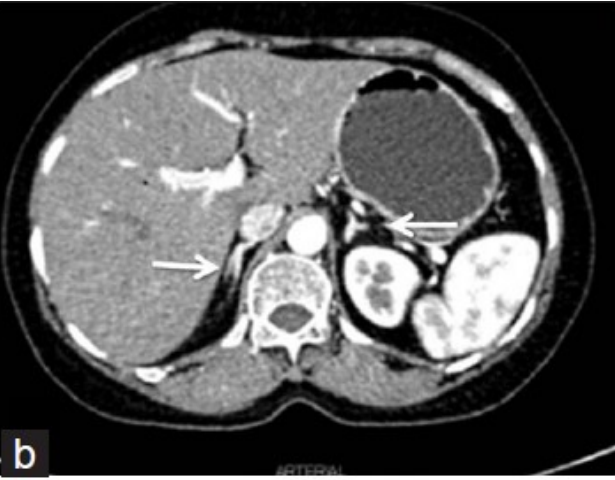
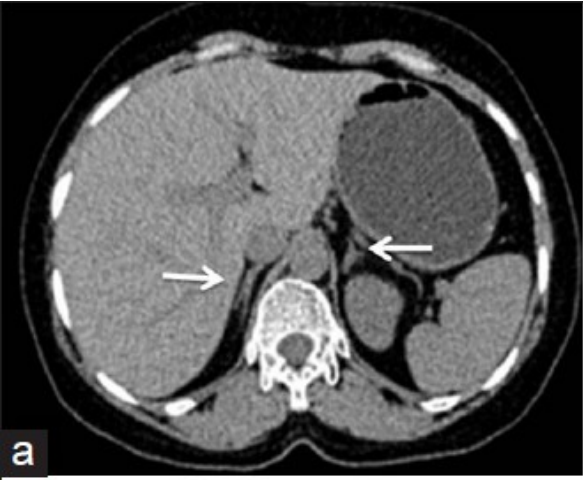
Right adrenal

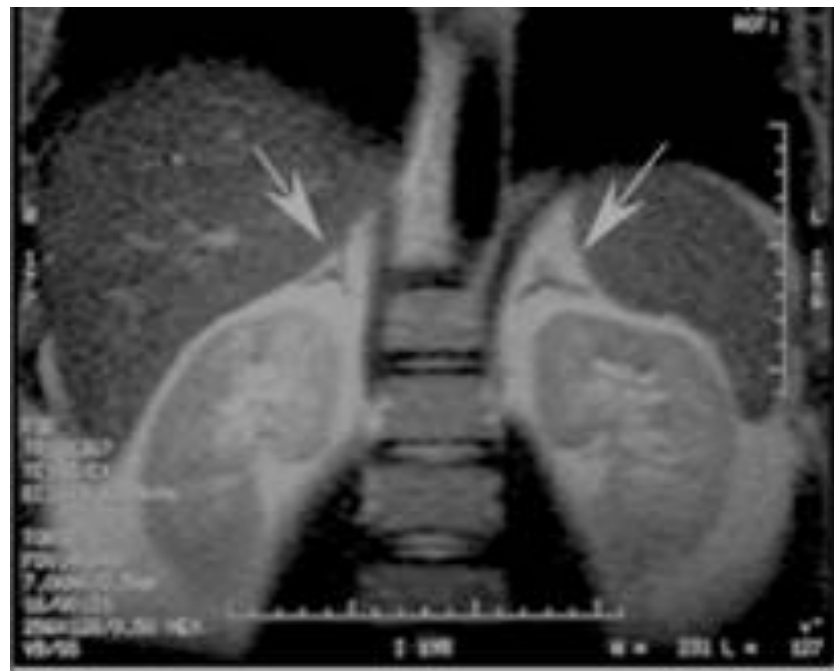

Left adrenal

Coronal CT Scan

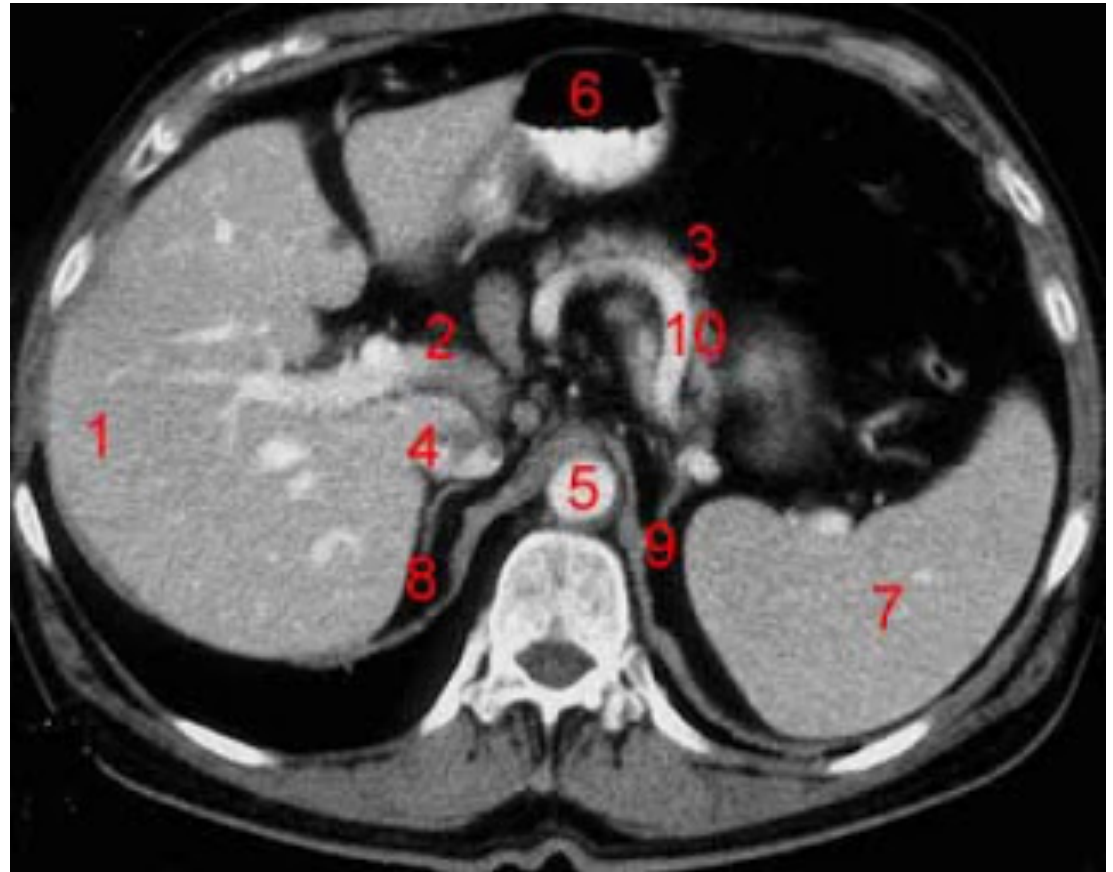






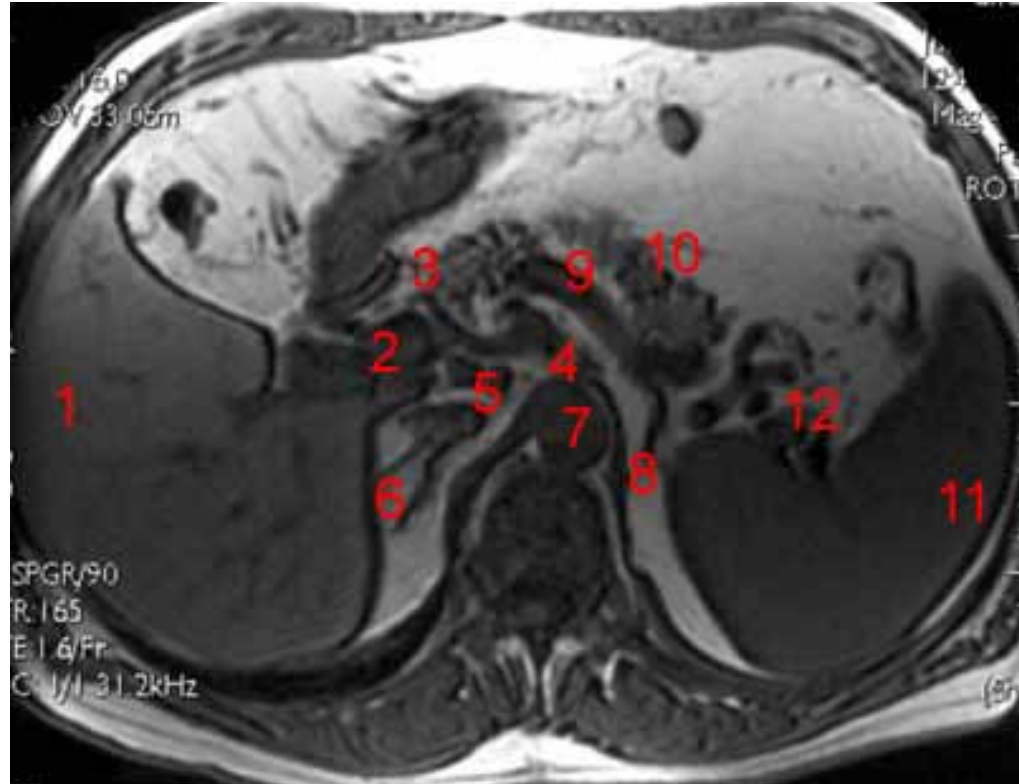
Axial CT of abdomen

- 1. Liver**
- 2. Portal Vein**
- 3. Pancreas**
- 4. Inferior Vena Cava**
- 5. Abdominal Aorta**
- 6. Stomach**
- 7. Spleen**
- 8. Right Adrenal**
- 9. Left Adrenal**
- 10. Splenic artery**

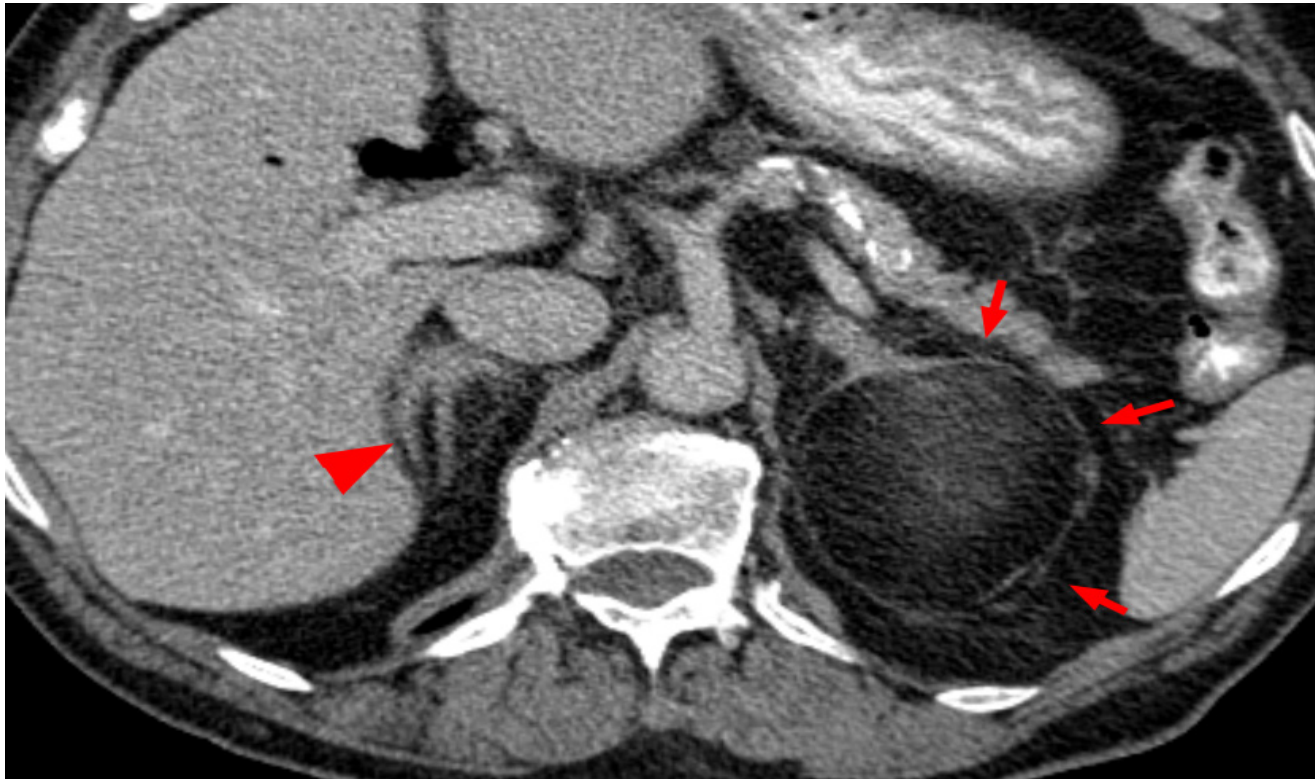

Axial MRI of abdomen

- 1- Liver**
- 2- portal vein.**
- 3- head of pancreas**
- 4- celiac artery**
- 5- Inferior Vena Cava**
- 6- Right Adrenal**
- 7- Abdominal Aorta**
- 8- Left Adrenal**
- 9- splenic artery**
- 10- body of pancreas**
- 11- Spleen**



Pathology of the adrenal gland



Lipoma of the left adrenal gland