

بِسْمِ اللَّهِ الرَّحْمَنِ الرَّحِيمِ

# *Female Perineum and External Genitalia*

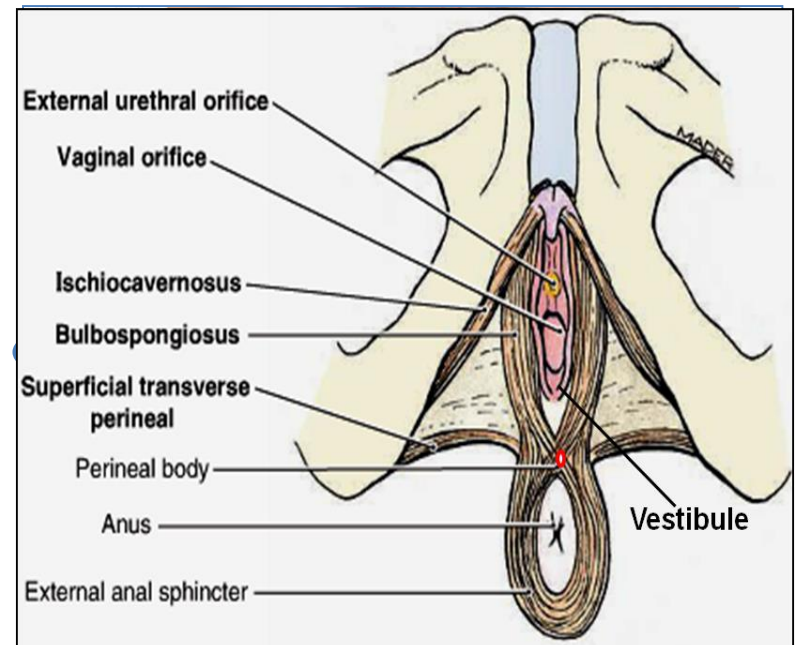
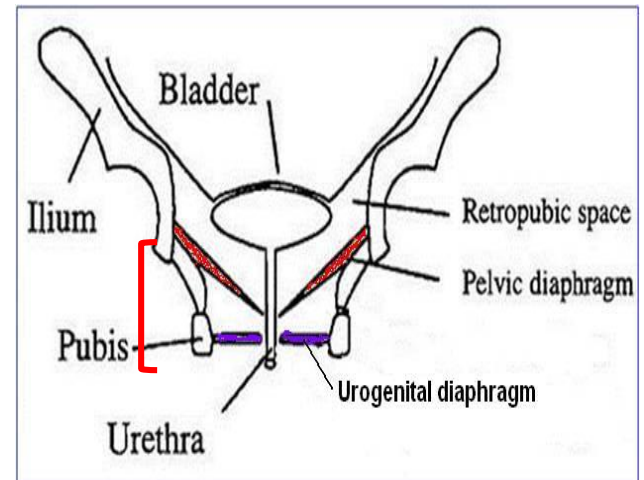
*Drs. Sanaa Alshaarawy & Saeed Vohra*

# OBJECTIVES

- ***At the end of the lecture, the student should be able to describe the:***
- ***Boundaries of the perineum.***
- ***Division of perineum into two triangles.***
- ***Boundaries & Contents of anal & urogenital triangles.***
- ***Lower part of Anal canal.***
- ***Boundaries & contents of Ischiorectal fossa.***
- ***Innervation, Blood supply and lymphatic drainage of perineum.***

# Perineum

- Perineum is the **region of the body below the pelvic diaphragm** (The outlet of the pelvis)
- It is a **diamond shaped area between the thighs**
- **Boundaries:**
  - Anteriorly **Mons pubis**
  - Laterally **Medial surfaces of the thighs**
  - Posteriorly **Intergluteal folds**
- **Contents:**
  - Lower ends of **urethra, vagina & anal canal**
  - **External genitalia**
  - **Perineal body & Anococcygeal body**

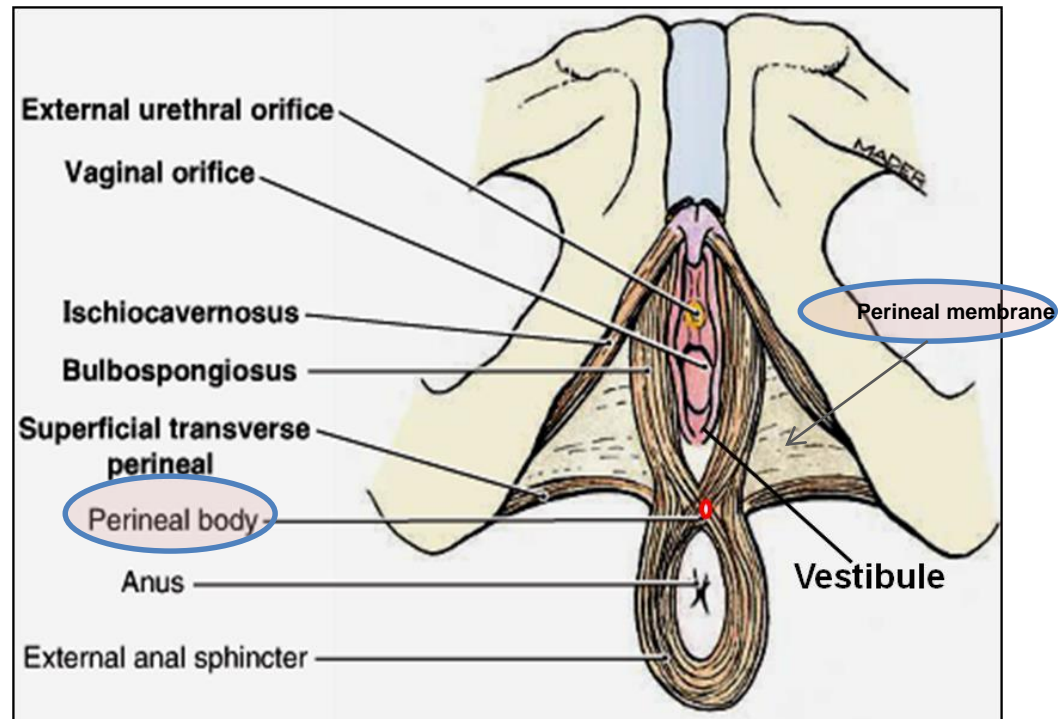


# Perineal Body

- Perineal body is an irregular **fibromuscular mass** of variable size and consistency, **located at** midpoint of the line **between the ischial tuberosities**
- **Lies in** the **subcutaneous tissue**, **posterior to vaginal vestibule** and **anterior to the anal canal & anus**
- Forms the **central point of the perineum** & blends anteriorly with the **perineal membrane**

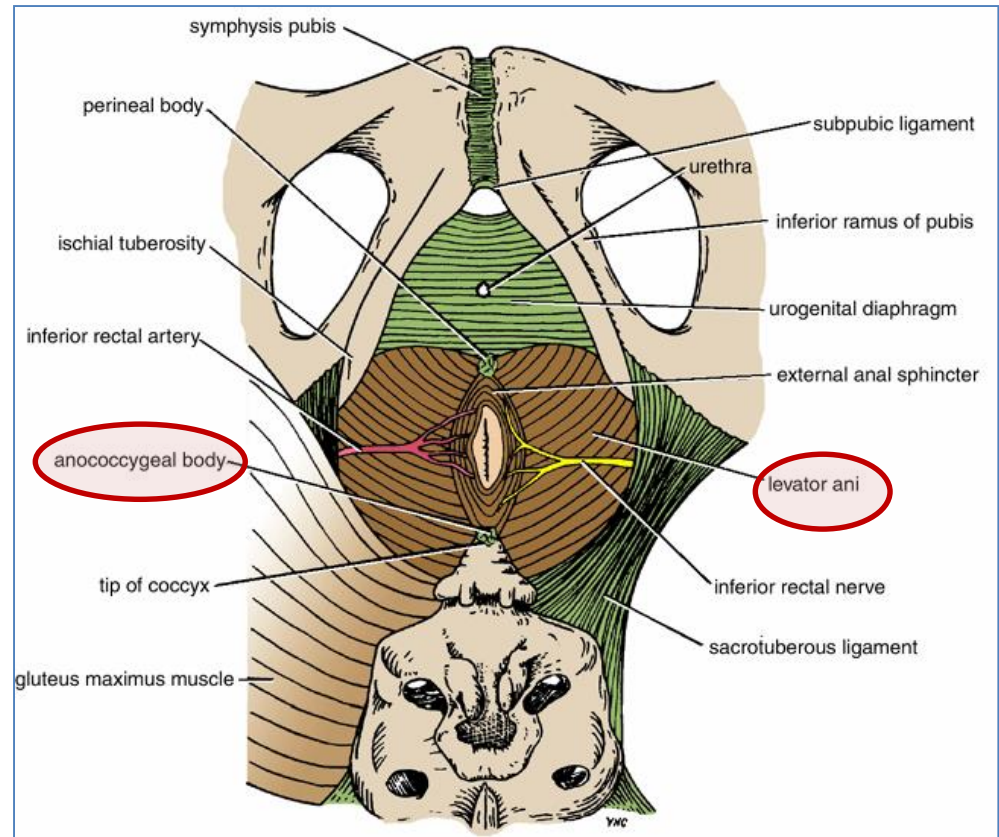
## Function:

- Gives **attachment to perineal muscles**
- Plays an important role in **visceral support** especially in female



# Anococcygeal Body

- The anococcygeal body is a complex **musculotendinous structure**
- **Situated** between the anterior aspect of the **coccyx** and the posterior wall of the **anorectal canal**
- **Receives** insertion of fibers of **levator ani** muscle



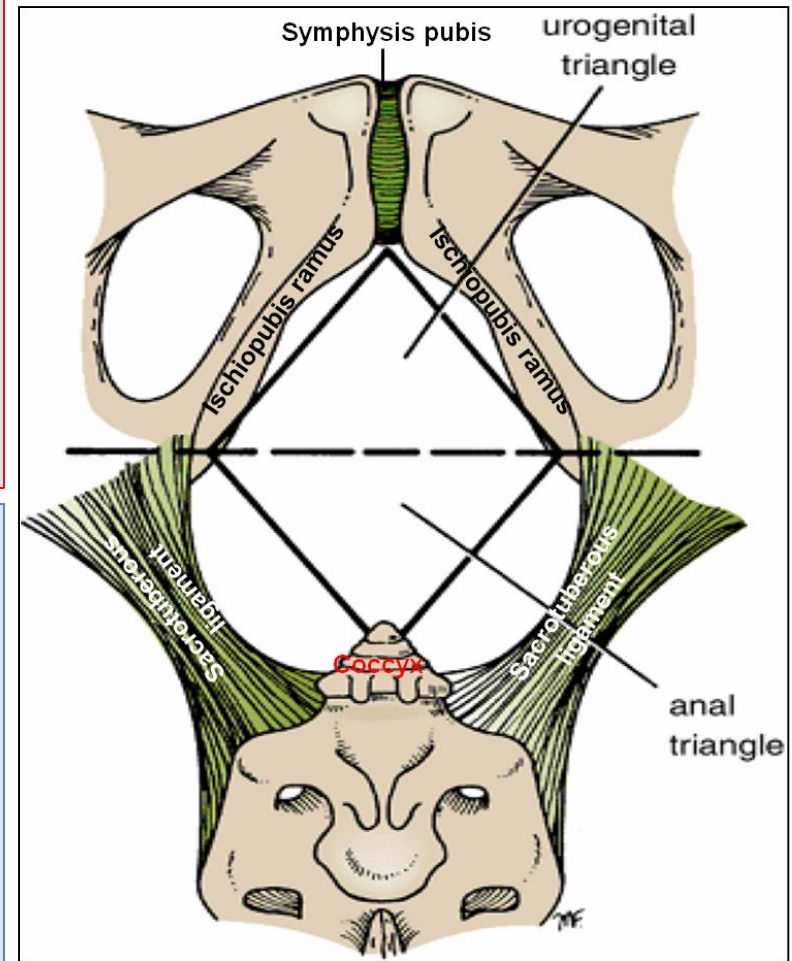
# Boundaries & Division of Perineum

## Boundaries:

- **Its bony boundaries are:**
  - **Anterior:** Symphysis pubis.
  - **Posterior:** Coccyx.
  - **Lateral:** Ischiopubic rami, ischial tuberosities & sacrotuberous ligaments.

## Division:

- By an imaginary line passing through **two ischial tuberosities**, it is divided into:
  - **Urogenital triangle** anteriorly.
  - **Anal triangle** posteriorly.

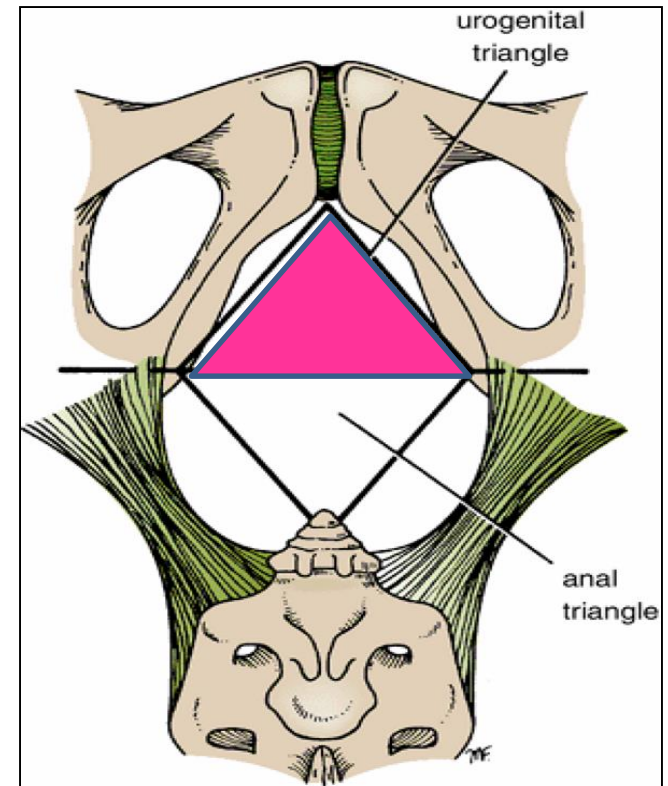
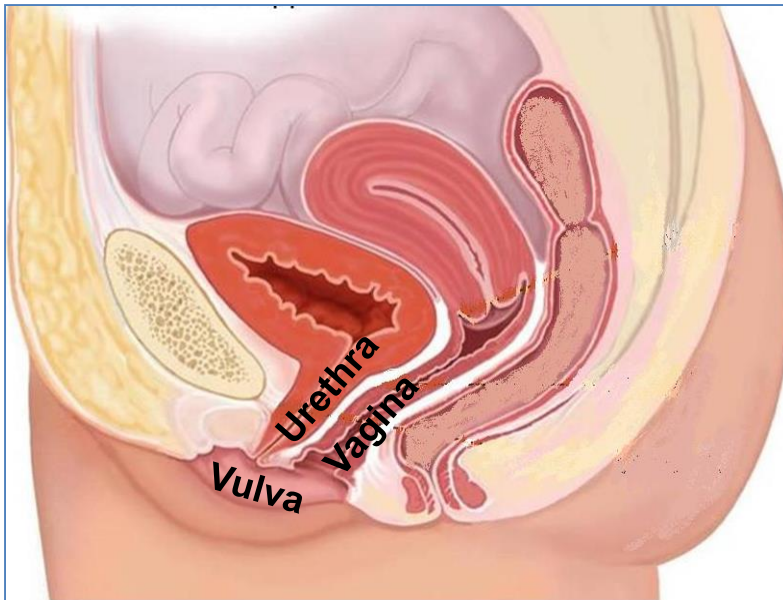




# Urogenital Triangle

## **Boundaries :**

- Anteriorly : **Symphysis pubis**
- Posteriorly : **Transverse line** passing through the 2 ischial tuberosities.
- Laterally : **Ischiopubic rami** & **ischial tuberosities**.

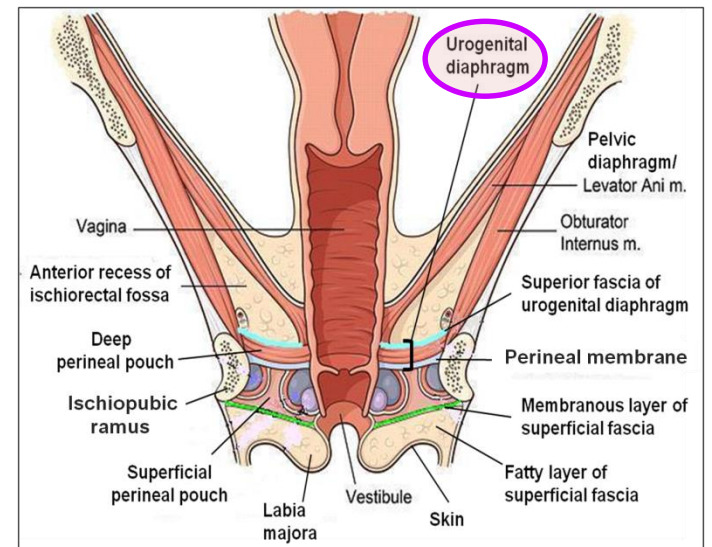
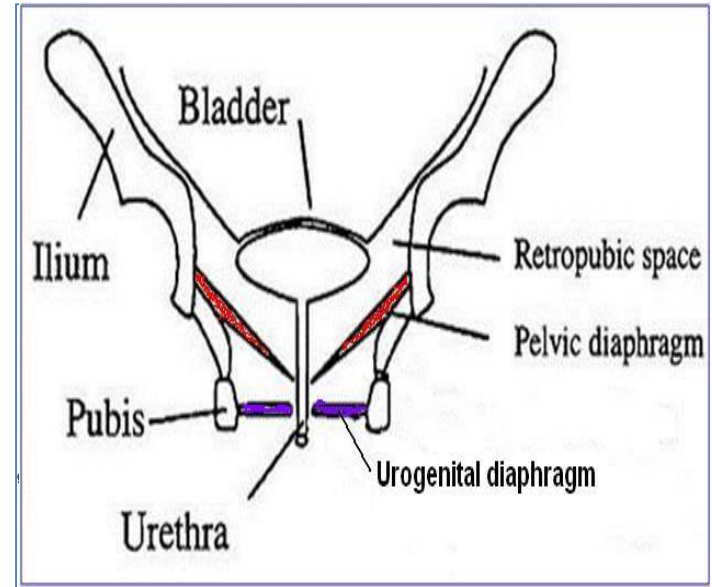


## **Contents :**

- Lower part of **urethra** & **vagina**.
- **External genitalia** (vulva).

# Urogenital Diaphragm

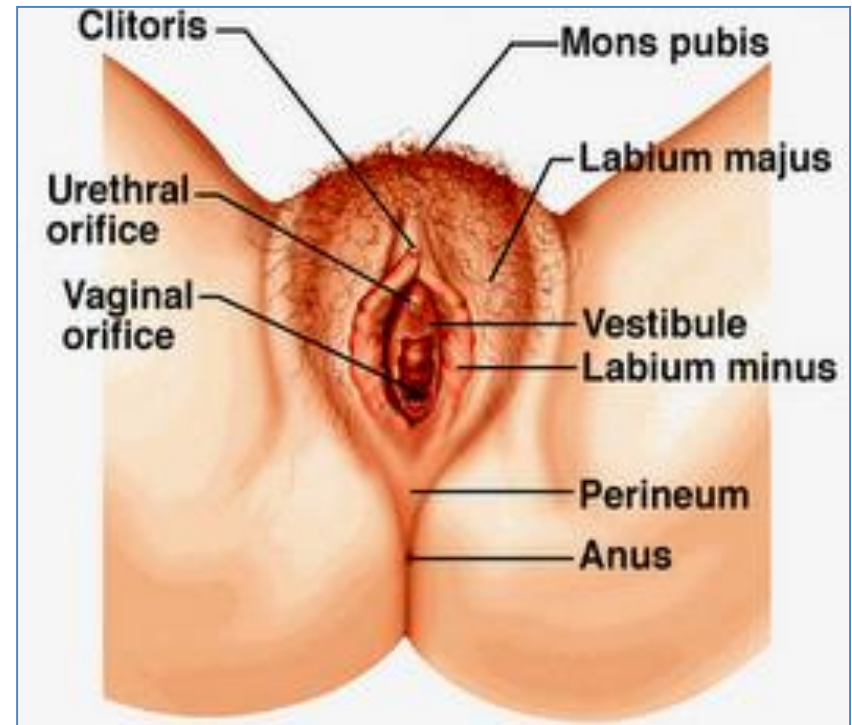
- A **triangular musculofascial diaphragm** located in the anterior part of the perineum (in the urogenital triangle).
- Fills in the gap **between** the **pubic arch**.
- Composed of: **Sphincter urethrae** and the **deep transverse perineal muscles** enclosed within the **superior and inferior** layers of **fascia of the urogenital diaphragm**
- The **inferior layer** of the fascia is formed by the **perineal membrane**





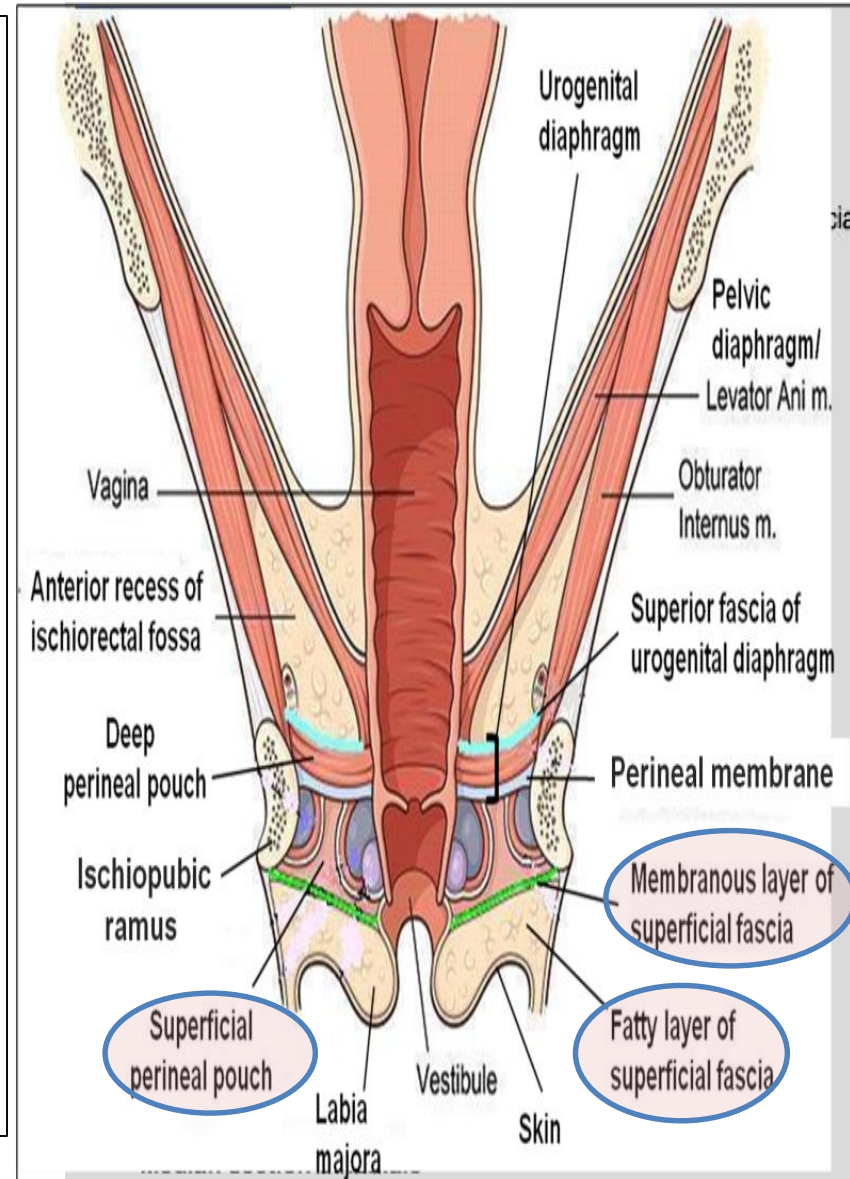
# Female External Genitalia (Vulva)

- **Mons pubis** : a collection of fat overlying the pubes.
- **Labia majora.**
- **Labia minora.**
- **Clitoris.**
- **Vestibule of vagina:** The interval between the two labia minora.
- Vagina & urethra **open into** the **vestibule** through **urethral orifice** anteriorly and **vaginal orifice** posteriorly.



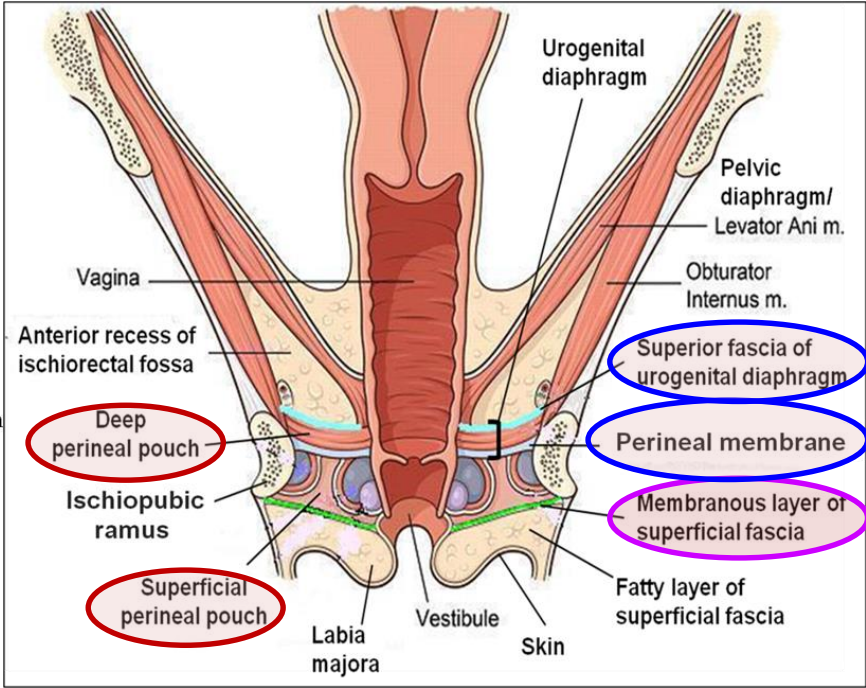
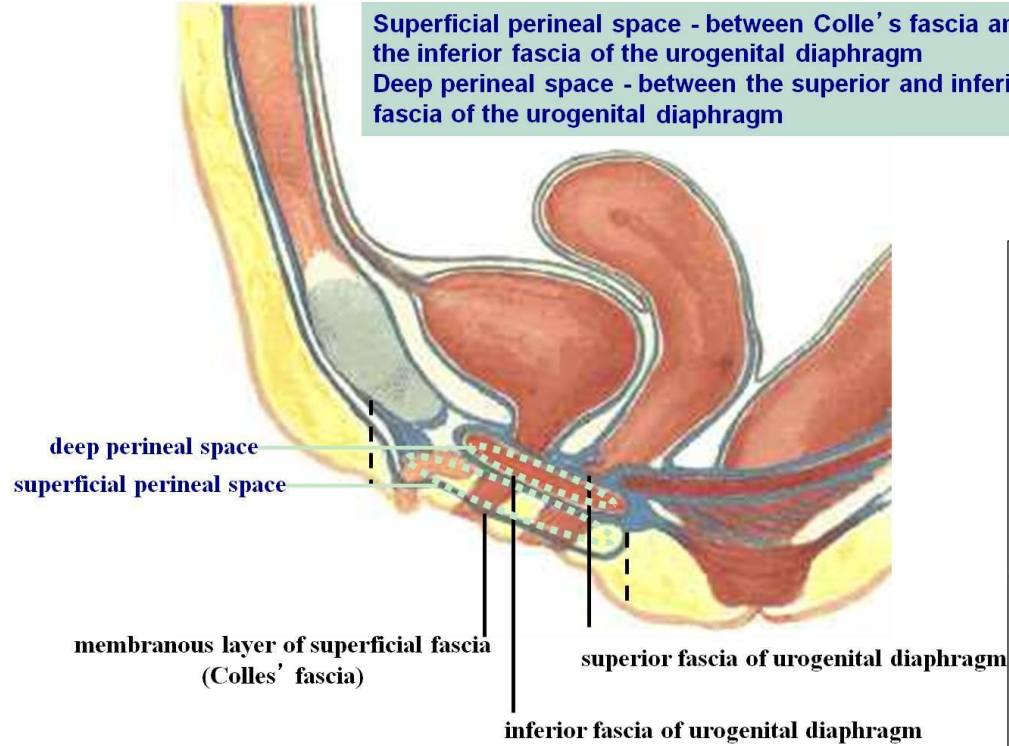
# Fascia of Urogenital Triangle (Perineal Fascia)

- The **perineal fascia** is continuous anteriorly with the fascia of abdomen and consists of **superficial** and **deep** layers
- **Superficial perineal fascia:** consists of:
  - **Superficial fatty layer** (Camper's fascia) **makes up** the substance of **mons pubis & labia majora** and **extends** into the **anal region**
  - **Deep membranous layer (Colle's fascia ):** Does **not extend** to **anal region**. Becomes **fused with** the posterior margin of the **perineal membrane**
- **Deep perineal fascia** invests the muscles in the **superficial perineal pouch**.



# Perineal Pouches

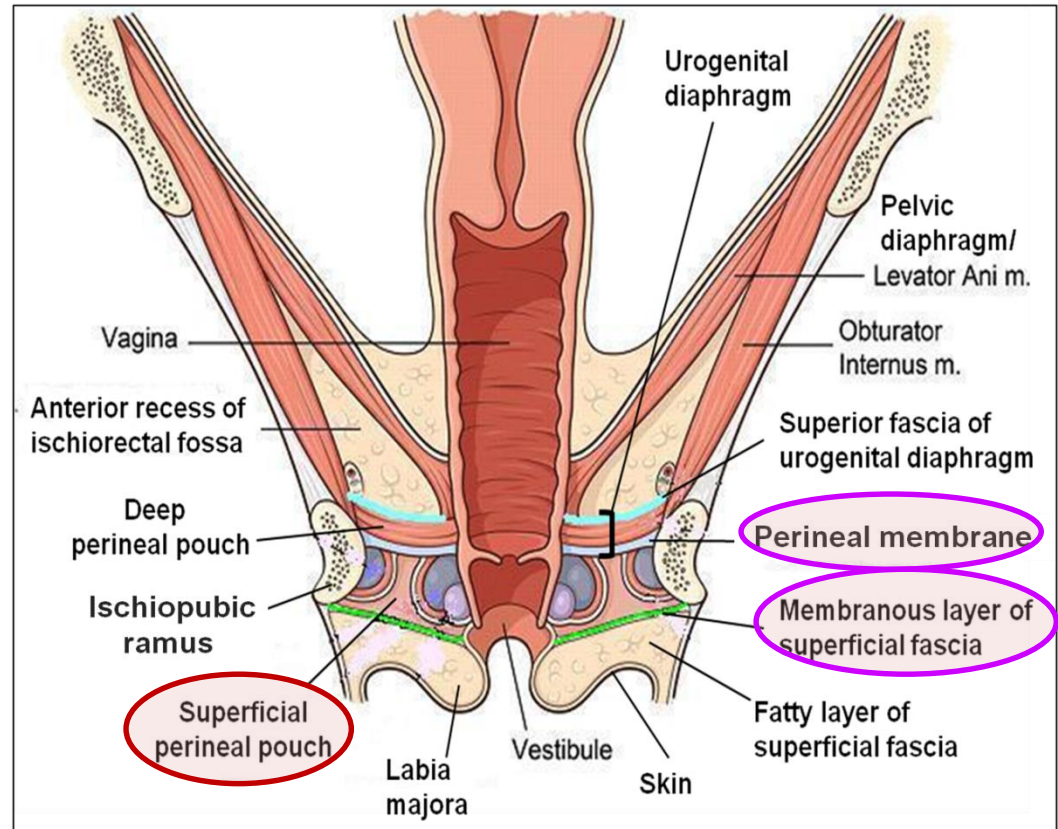
Superficial perineal space - between Colle's fascia and the inferior fascia of the urogenital diaphragm  
 Deep perineal space - between the superior and inferior fascia of the urogenital diaphragm





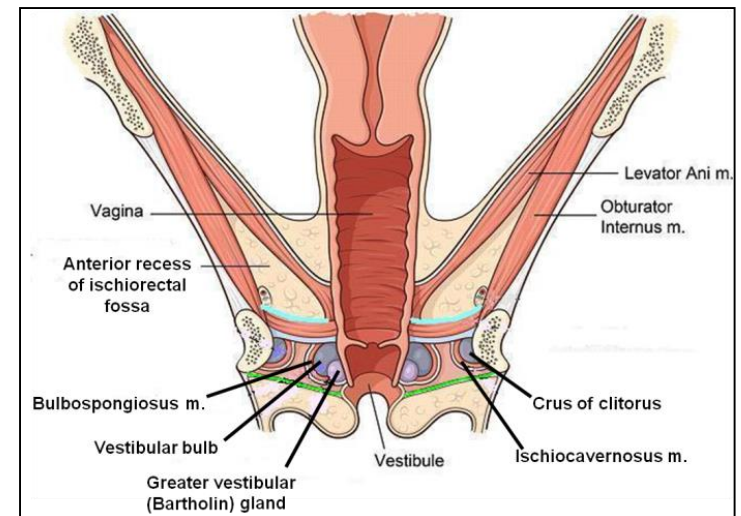
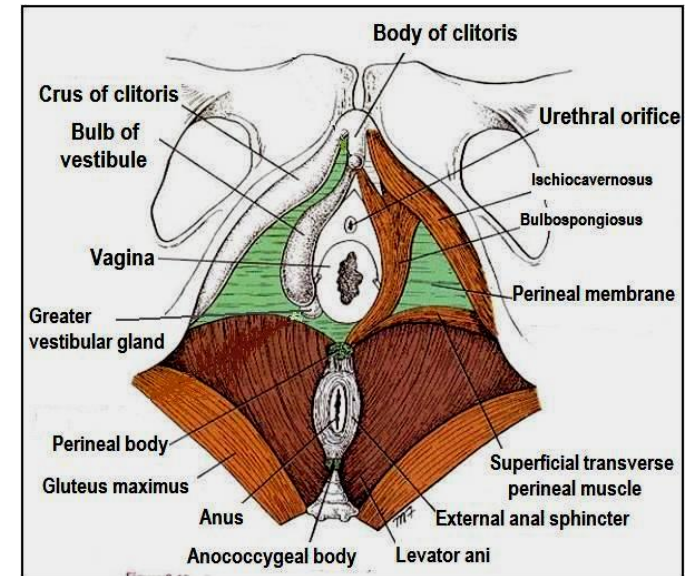
# Superficial Perineal Pouch

- It is the **space between** the **deep membranous layer** of superficial fascia and the **perineal membrane**.
- **BOUNDARIES:**
  - **Inferiorly:** membranous layer of superficial fascia.
  - **Superiorly:** perineal membrane.
  - **Laterally:** ischiopubic rami.



# Contents of Superficial Perineal Pouch

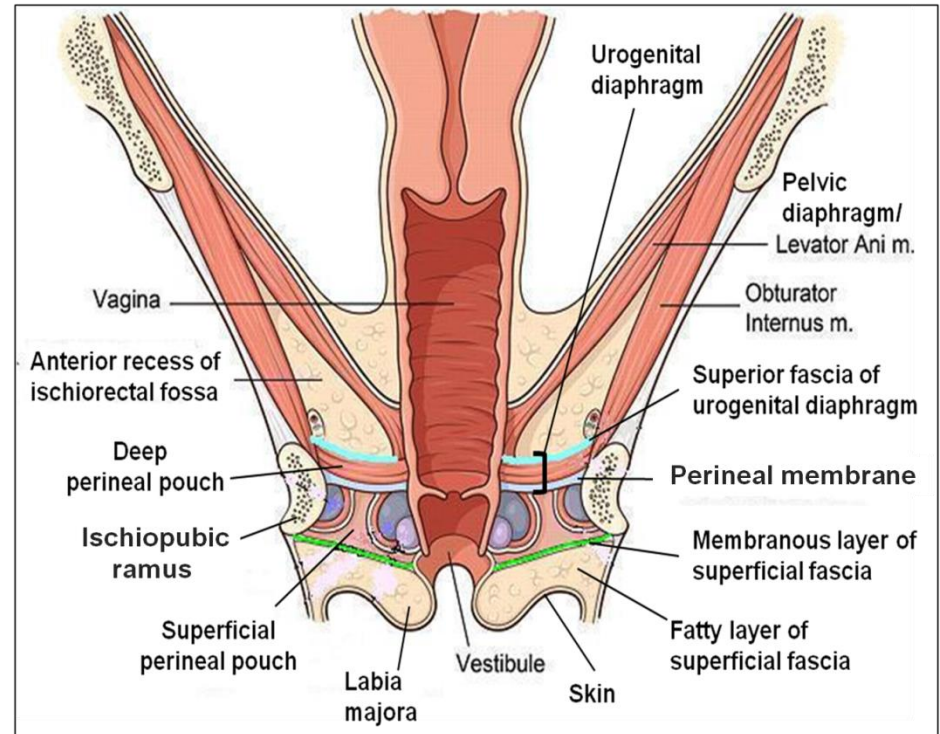
- **Bulbs of vestibule:** on each side of vaginal orifice.
- **Crura of clitoris.**
- **Superficial perineal muscles:**
  - Bulbospongiosus muscle, surrounds orifice of vagina and **covers** vestibular bulb.
  - Ischiocavernosus muscle, **covers** crus of clitoris on each side.
  - Superficial transverse perineal muscles.
- **Greater vestibular glands:** on each side of vaginal orifice.
- **Perineal branch of pudendal nerve** supplying muscles & skin.





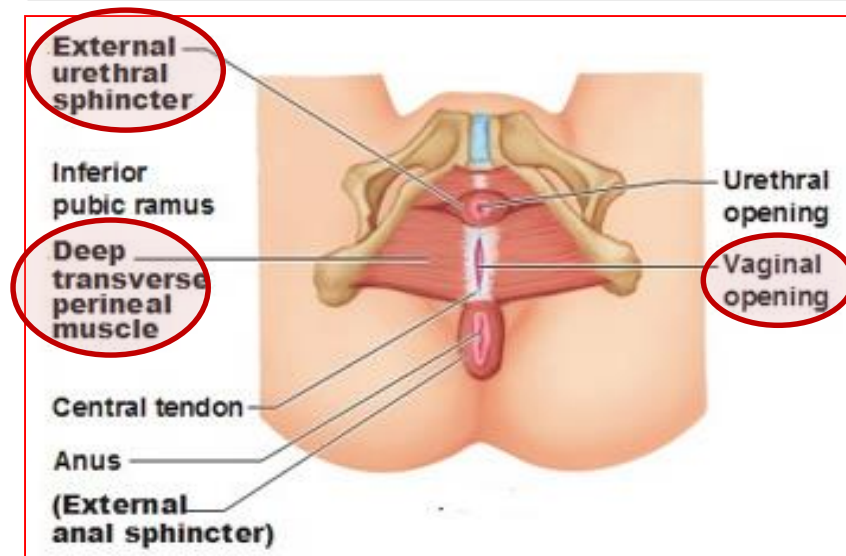
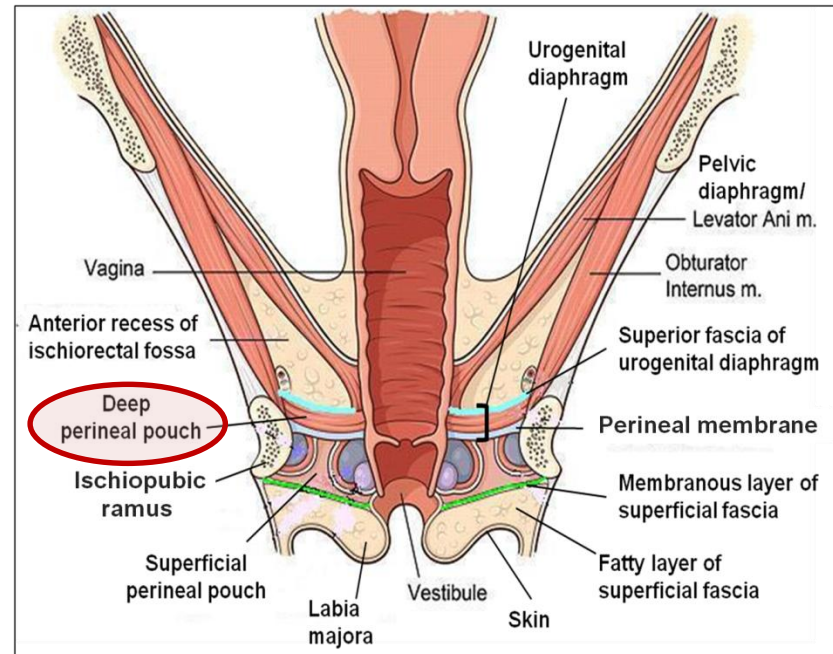
# Deep Perineal Pouch

- It is a **completely closed space** deep to the perineal membrane
- **BOUNDARIES:**
  - **Inferiorly:** Inferior fascia of the urogenital diaphragm (Perineal membrane)
  - **Superiorly:** Superior fascia of the urogenital diaphragm
  - **Laterally:** Inferior portion of **obturator internus fascia**.



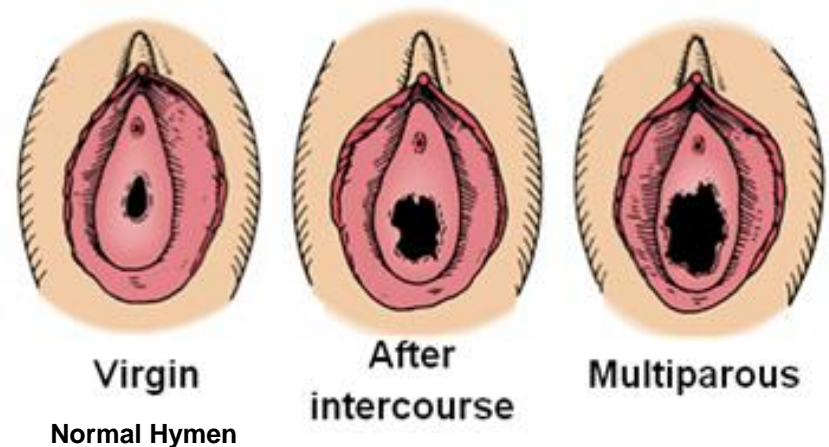
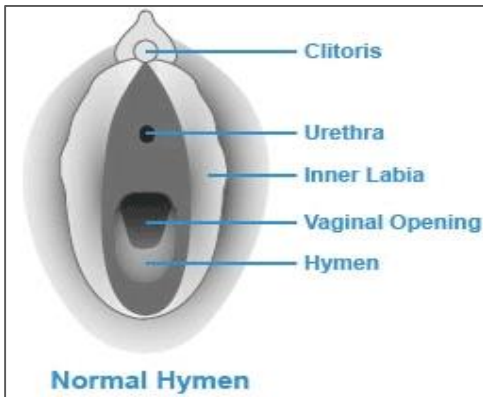
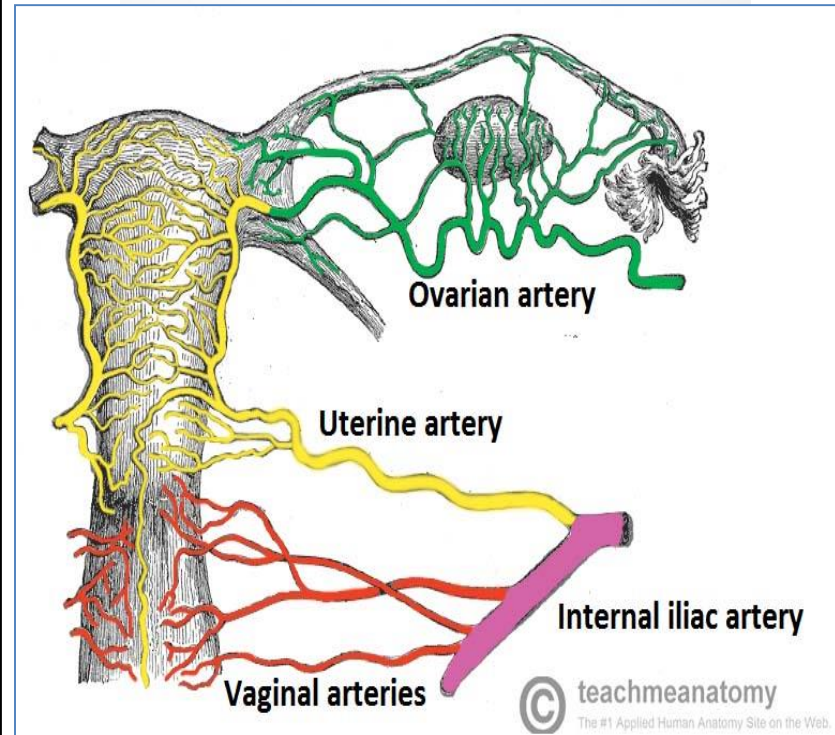
# Contents of Deep Perineal Pouch

- Part of **urethra**
- Part of **vagina**
- **Sphincter urethrae and Sphincter vaginae muscles**, which is pierced by urethra & vagina.
- **Deep transverse perineal muscles**
- **Internal pudendal vessels**
- **Dorsal nerve of clitoris.**



# Vagina

- **The vagina** is a muscular canal that leads from the **uterus** to the **external orifice** of the **genital canal**
- It measures about 3 in. (8 cm) long.
- It serves as the **excretory duct** for the **menstrual flow** & forms part of the **birth canal**.
- **The vaginal orifice** in a **virgin** possesses a **thin mucosal fold**, called the **hymen**, which is perforated at its center.
- **Arteries:**
  - **Vaginal artery**, a branch of the **internal iliac artery**
  - **Vaginal branch** of the **uterine artery**
- **Veins:** drain into the **internal iliac veins**.





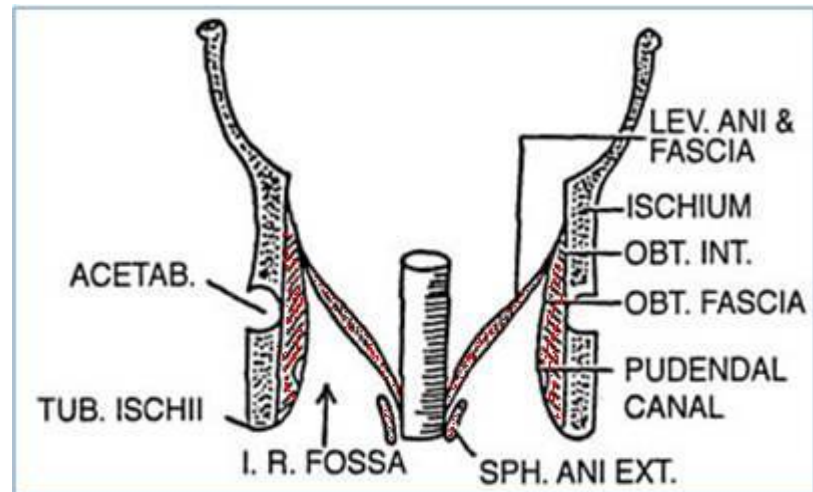
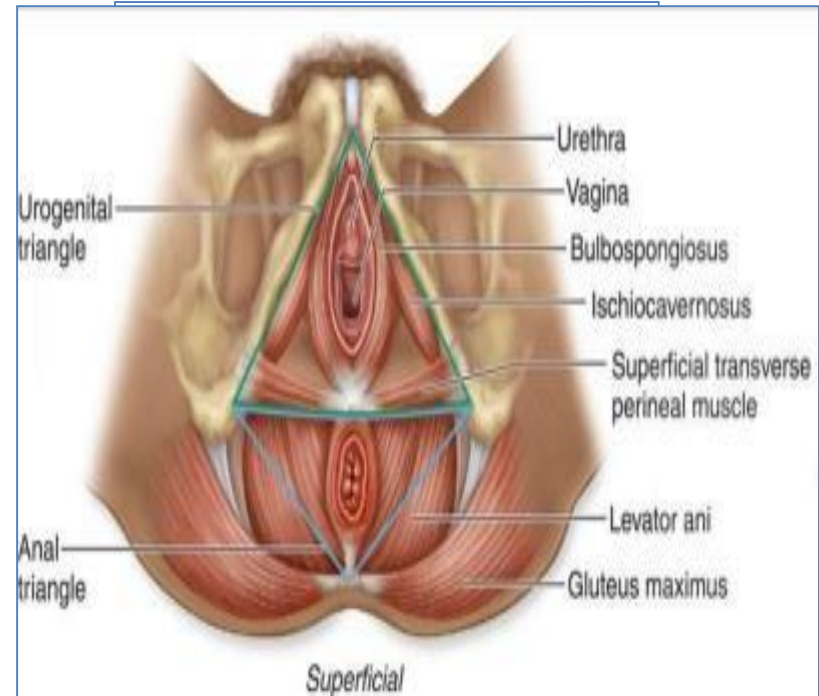
# Anal Triangle

## Boundaries:

- **Anteriorly:** Transverse line passing through the 2 ischial tuberosities.
- **Posteriorly :** **coccyx.**
- **Laterally :** **ischial tuberosity & sacrotuberous lig.**

## Contents:

- **Lower part of Anal canal**
- **Ano-coccygeal body**
- **Ischiorectal fossa** on each side



# Anal Canal

- It is about 1.5 in. long, descending from the **rectal ampulla** to the **anus**.

## **Relations** (In female):

- **Anteriorly:** Perineal body, urogenital diaphragm, and lower part of vagina
- **Posteriorly:** Anococcygeal body.
- **Laterally:** Ischiorectal fossae.

## **Division:** Divided into:

- **Upper half:** derived from hindgut (**endoderm**)
  - **Lower half:** derived from the proctodeum (**ectoderm**)
- **The two parts have different blood supply, nerve supply and lymphatic drainage.**

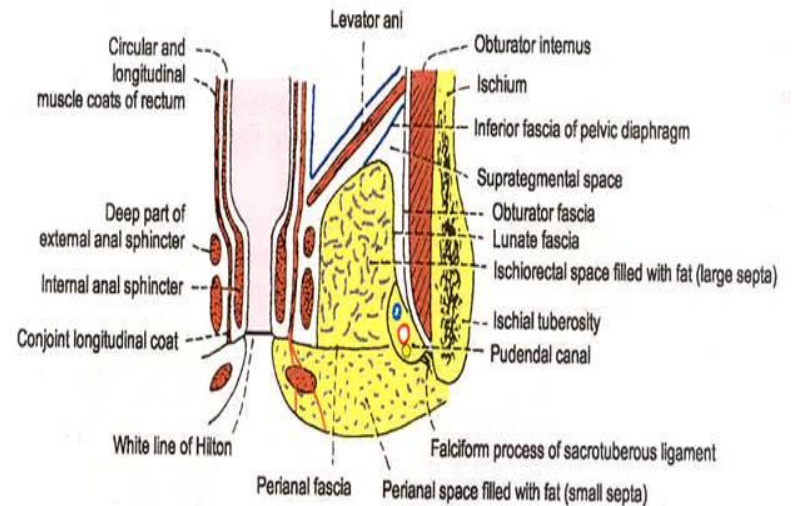
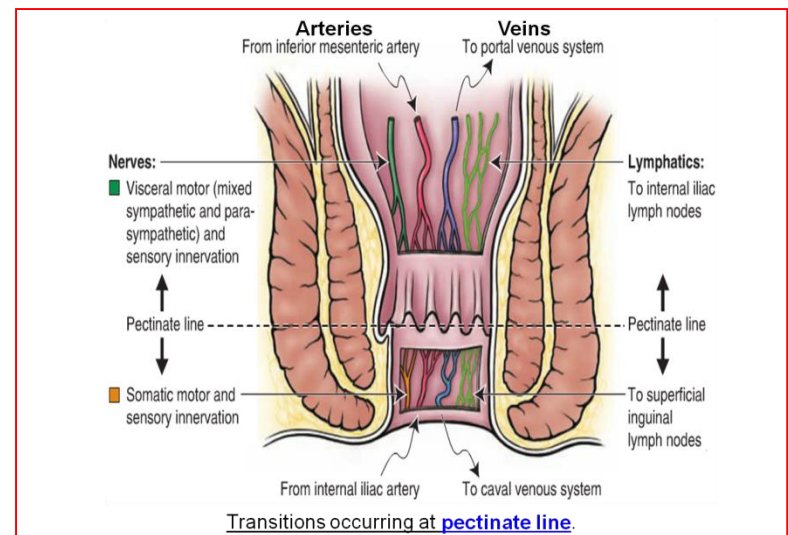
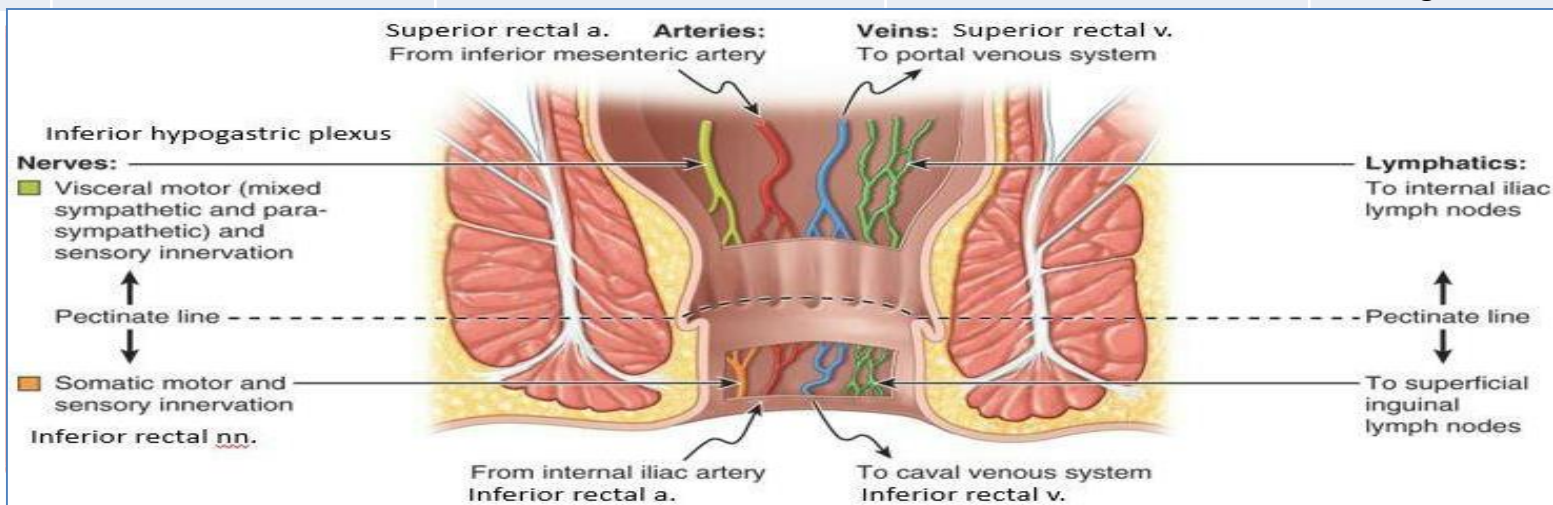


Fig. 28.7: Coronal section through the ischiorectal fossa.





Anal canal	Arterial supply	Venous drainage	Lymphatic drainage	Nerves
Upper half	<b>Superior rectal artery</b> (continuation of the <b>inferior mesenteric artery</b> )	<b>Superior rectal vein</b> drained into the <b>inferior mesenteric vein</b> ( <b>portal circulation</b> ).	<b>Para-rectal nodes</b> drained into <b>inferior mesenteric lymph nodes</b>	(sensitive to stretch). <b>Visceral motor</b> ( <b>Inferior Hypogastric Plexus</b> ) (sympathetic & parasympathetic).
Lower half	<b>Inferior rectal a.</b> (branch of <b>internal pudendal artery</b> )	<b>Inferior rectal vein</b> drained into the <b>internal pudendal vein</b> ( <b>Systemic circulation</b> ).	<b>Superficial inguinal lymph nodes</b>	(sensitive to pain) <b>Somatic motor &amp; sensory nerves</b> - ( <b>Inferior rectal N. branch of pudendal N.</b> ) supplies <b>external sphincter muscle</b> of the anus and <b>the skin of the anal region</b> .



# Ischiorectal Fossa

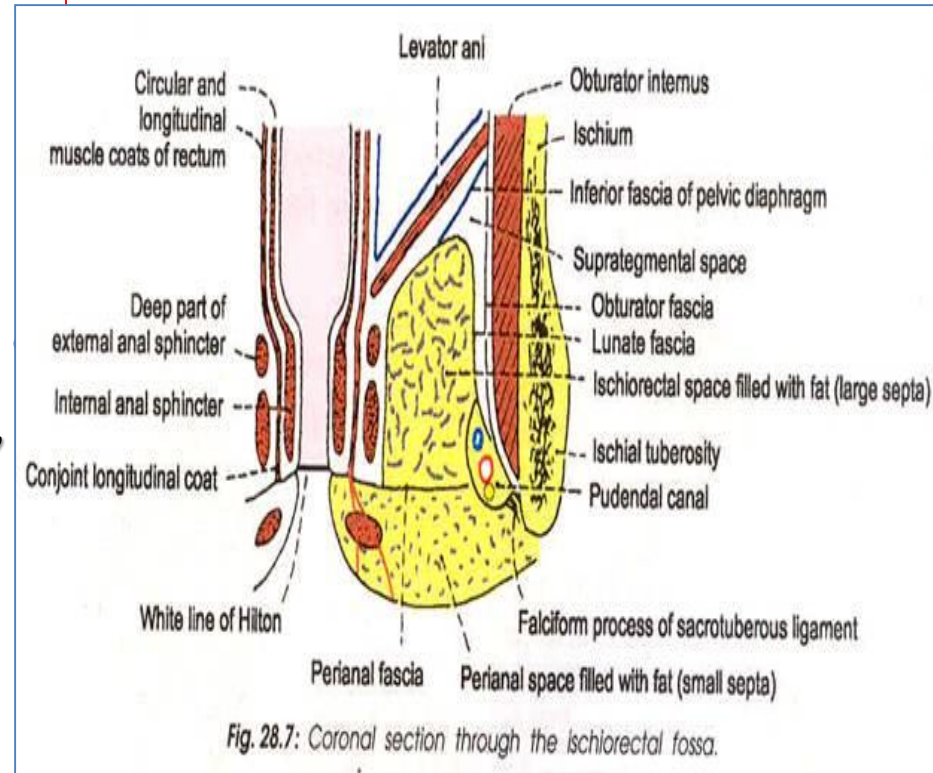
- A fascial lined wedge-shaped space on each side of the anal canal.

## Boundaries:

- **Base:** Skin of the perineum.
- **Medial wall:** Levator ani & anal canal.
- **Lateral wall:** Obturator internus, covered with fascia.

## Contents:

- Dense fat.
- **Pudendal nerve & internal pudendal vessels** within the **pudendal canal**.
- **Inferior rectal nerve & vessels** crossing the fossa to reach anal canal.

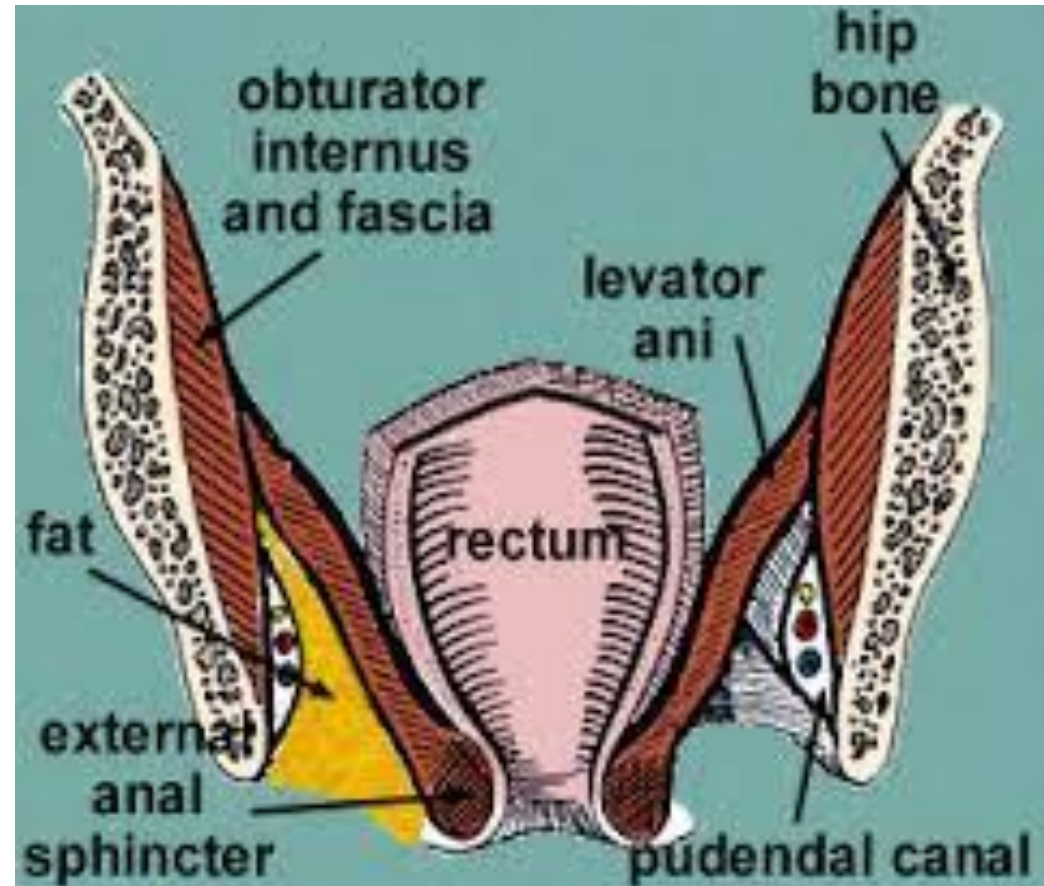


## ***Pudendal Canal:***

- A **fascial canal** formed by **obturator fascia**, located on the **lateral wall of the ischiorectal fossa**

## **Contents:**

- **Pudendal nerve.**
- **Internal pudendal vessels.**





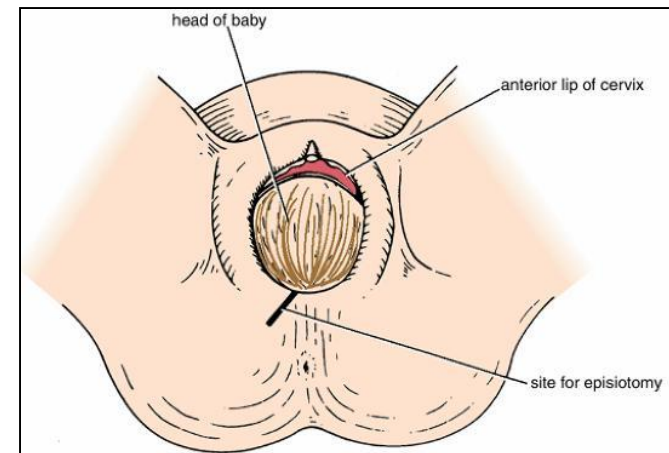
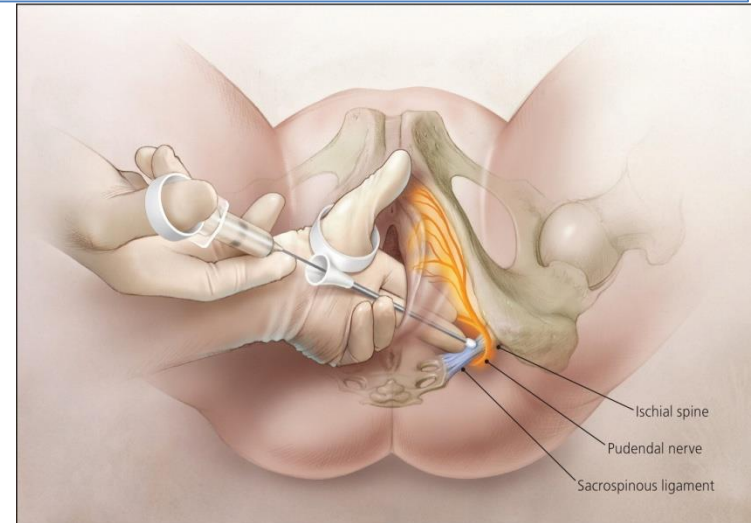# Pudendal Nerve Block

**Pudendal nerve block** is used in providing analgesia for the second stage of labour to provide anesthesia of the perineum in order to create or repair an episiotomy. Can be done by transvaginally or through perineal approach.

**Transvaginal method:** The needle is passed through the vaginal mucous membrane toward the ischial spine. After the needle is passed through the sacrospinous ligament, the anesthetic solution is injected around the pudendal nerve

**Perineal method:** The ischial tuberosity is palpated subcutaneously through the buttock. The needle is inserted on the medial side of the ischial tuberosity to a depth of about 1 in. (2.5 cm) from the free surface of the tuberosity. The anesthetic is injected around the pudendal nerve.

**An episiotomy** is a surgically planned incision on the perineum and the posterior vaginal wall during second stage of labor to prevent perineal tear.



*Thank You*

*&*

*Good Luck*