

Genital Herpes & Genital Warts

By

Dr. Mona Badr

Assistant Professor in Microbiology Unit

College of Medicine & KKUH

Introduction

- Genital Herpes and genital Warts are recognized as the main sexual transmitted viral infections that might be acquired by any types of sexual contact.

Risk groups:

- 1- Adults who have multiple sexual partners.
- 2- Immune compromised individuals.
- 4- Infants who have infected mothers.
- 3- Sexual child abuse.

Genital herpes

Etiology:

- There are two species of herpes virus capable of causing genital herpes:

Herpes simplex virus type 2 (HSV-2)

and **Herpes simplex virus type 1 (HSV-1)**.

- **90%** of genital herpes cases are due to **HSV-2** infection, whereas **10%** are due to **HSV-1**
- Both (**HSV-1** & **HSV-2**) are structurally very similar and share about 70% sequence homology.

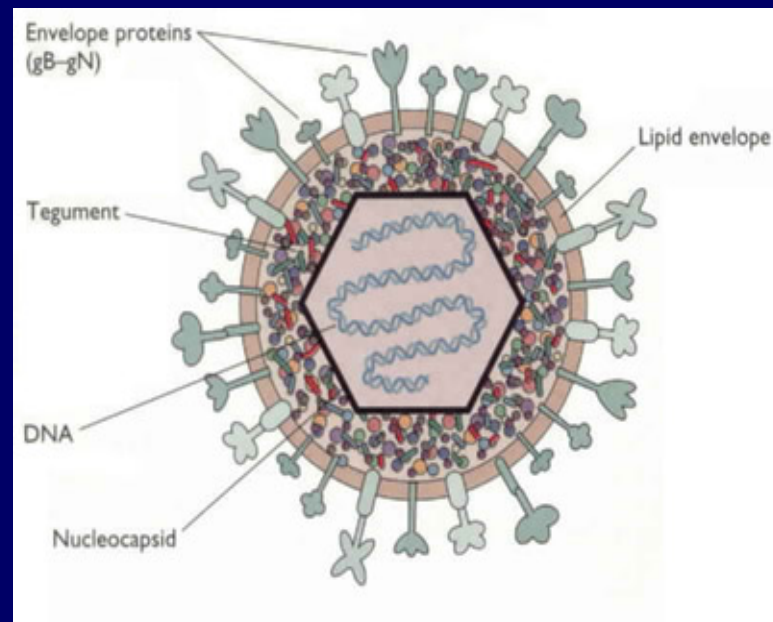
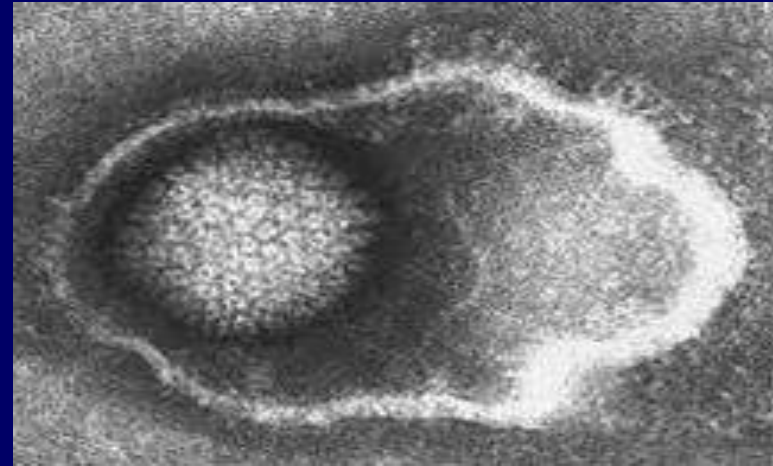
Characteristics Of Herpes Virus

- Family of *herpesviridae*.
- Virion consist of:
 - Glycoprotein envelope
 - Icosahedral capsid.
 - Liner ds-DNA.
- The Herpes viruses has the ability to induce latent infection,

HSV (1&2) → NERVE CELLS.

HSV-1 → Trigeminal ganglia

HSV-2 → Sacral ganglia



Herpes simplex virus

HSV-1

HSV-2

Encephalitis

Keratoconjunctivitis

Oral

Gingivostomatitis

Tonsillitis

Labialis

Pharyngitis

Esophagitis

Tracheobronchitis

Gladiatorum

Meningitis

Oral

Pharyngitis

Genital

Genital

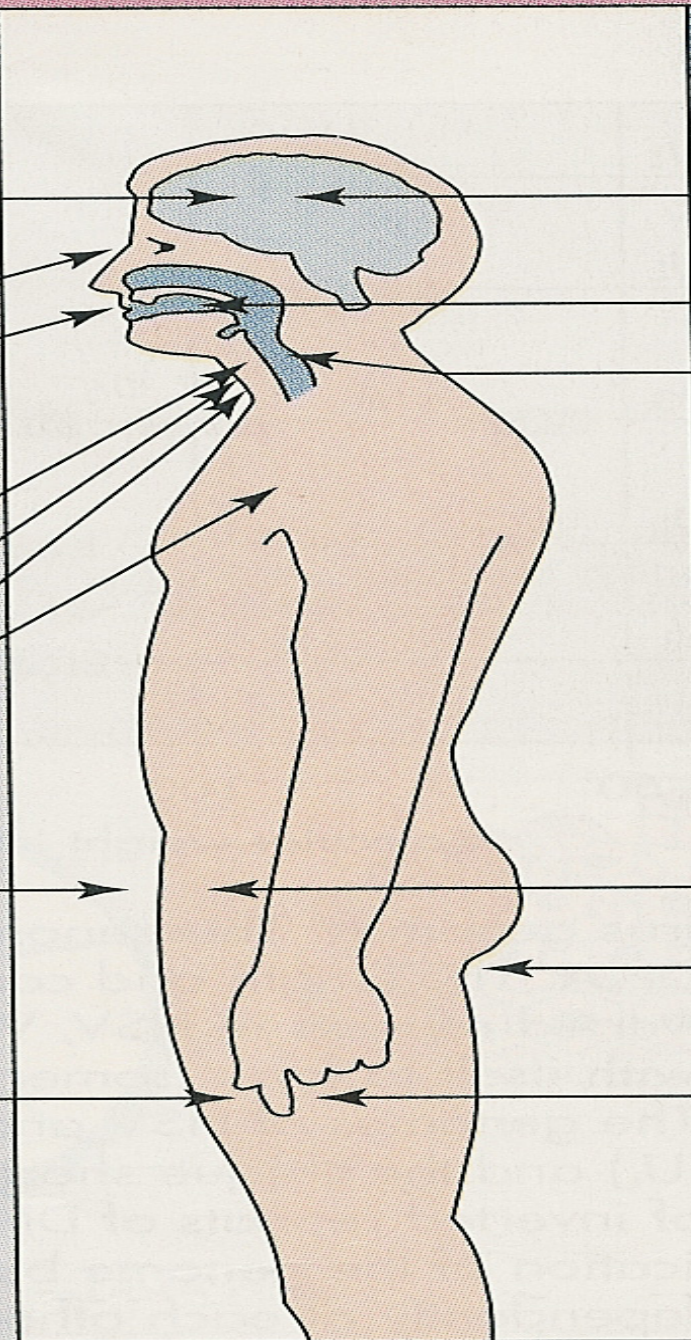
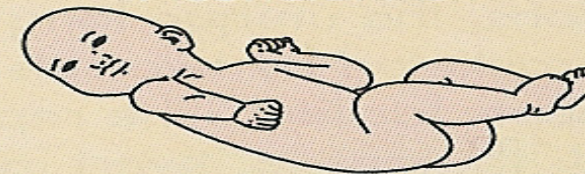Perianal

Whitlow

Whitlow

**Disease syndrome of
HSV1, HSV2**

Neonatal HSV



Transmission of Genital HSV infection

1- Sexual transmission:

- The number of different sexual partners correlates directly with acquisition of **HSV-2** in both male & female.
- **Homosexual men** are more susceptible to **HSV-2** infection.
- Genital infection can be acquired by **auto-inoculation** from lesions elsewhere on the body by touching vesicular fluids from any herpetic lesions (**HSV-1&2**). .
- **HSV-1** can cause genital herpes infection after oral sex, also can be seen in cases of child abuse.

Transmission of Genital HSV infection

2- Perinatal transmission (during delivery):

- The majority of maternal infection (85%) occurs during delivery, due to direct contact between the baby and infected maternal birth canal.
- The risk of perinatal transmission is usually occurred in about 50% of mothers have primary genital herpes, while the risk is 8% if mother have recurrent infection.
- This infection can lead to either massive herpetic skin lesions or generalized infection affecting skin and internal organs e.g; lungs , liver or brain .

To avoid perinatal infection we do **Caesarean section.**

Transmission of Genital HSV infections

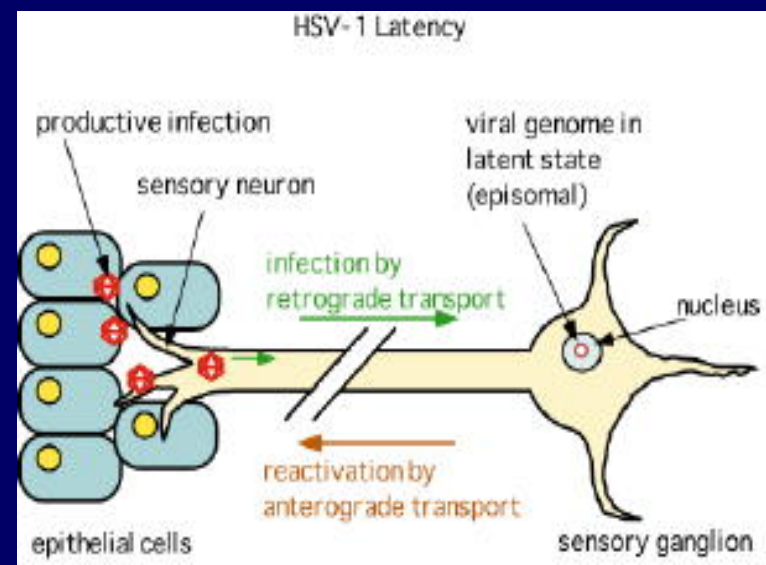
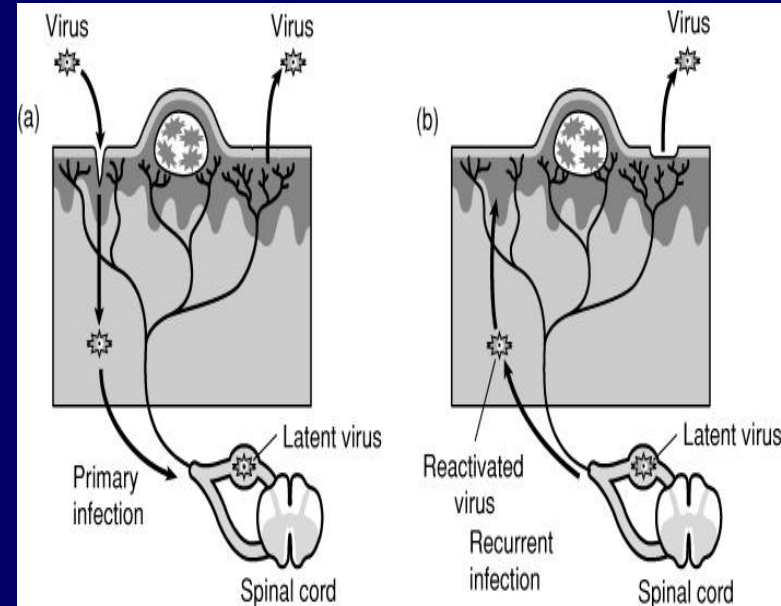
3-Intrauterine(vertical) transmission (10%):

- Maternal **primary** genital HSV-2 infection of the mother during **first trimester** can lead to spontaneous abortion.
- Maternal **primary** genital HSV-2 infection which develops **after 20 weeks of gestation** may induce malformation as; microcephaly, jaundice, hepatosplenomegaly, Chorioretinitis and herpetic vesicles on the skin.

Pathogenesis of HSV-2

Genital herpes infection

- **Primary infection** occurs when HSV-2 infects epithelial cells covering the mucosa.
- The virus then migrates to the nearest ganglion (sacral ganglia) via neurons where it replicates and establish latency for life.
- Once its reactivated, it travels back through neurons to the site of the primary infection and causes **recurrent infection**.
- * Once the virus enters the human body it remains for life (**latency**)

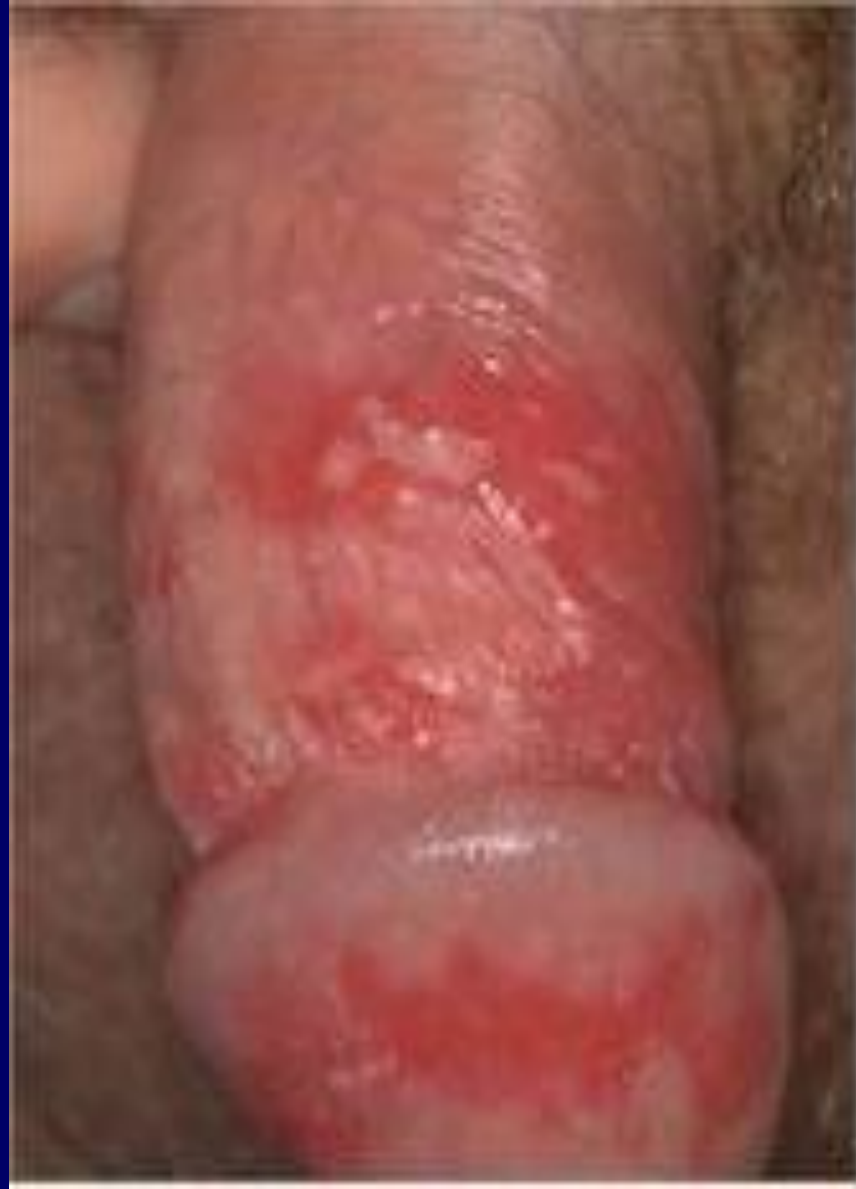
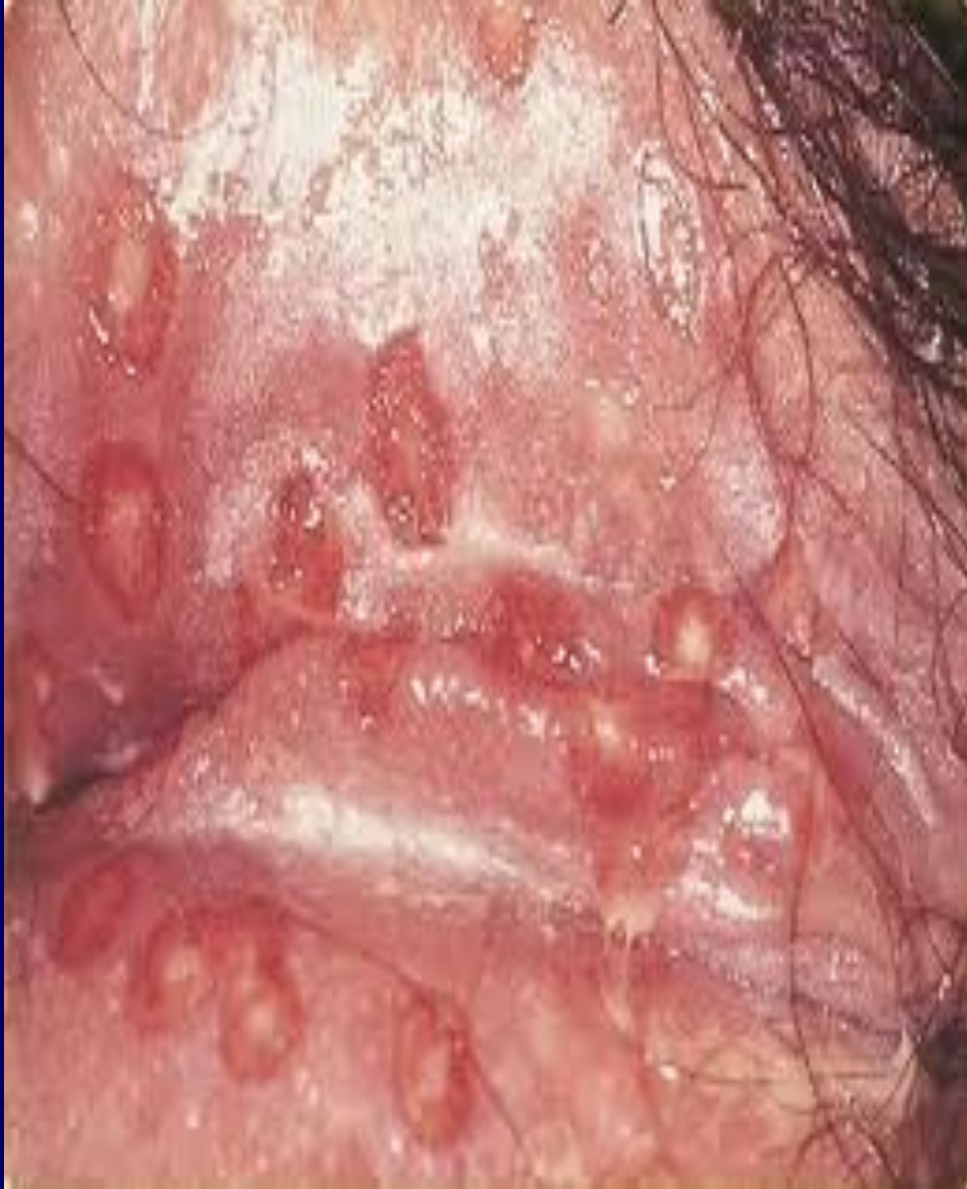
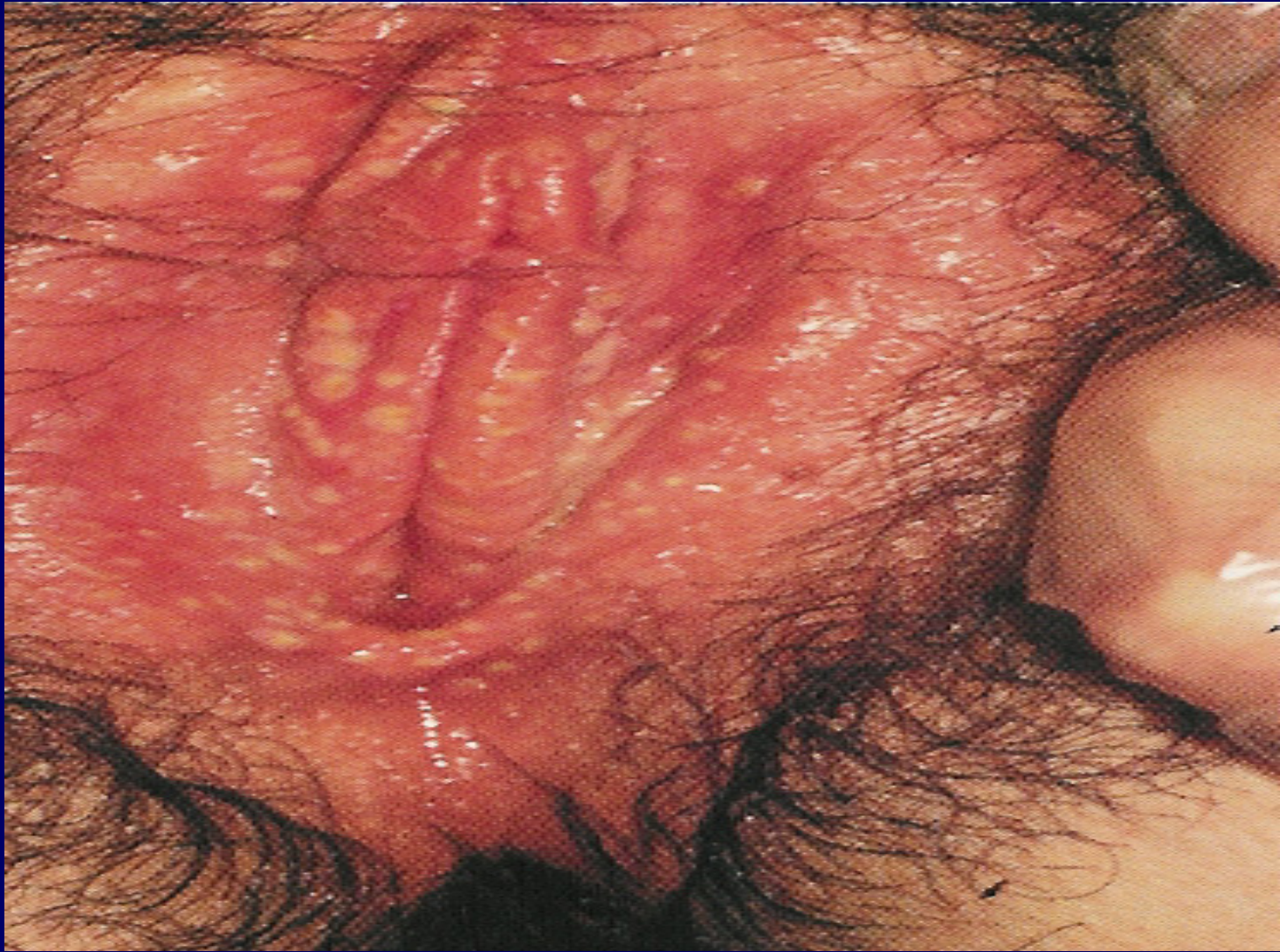Clinical features of HSV-2 infection

Primary genital infection:

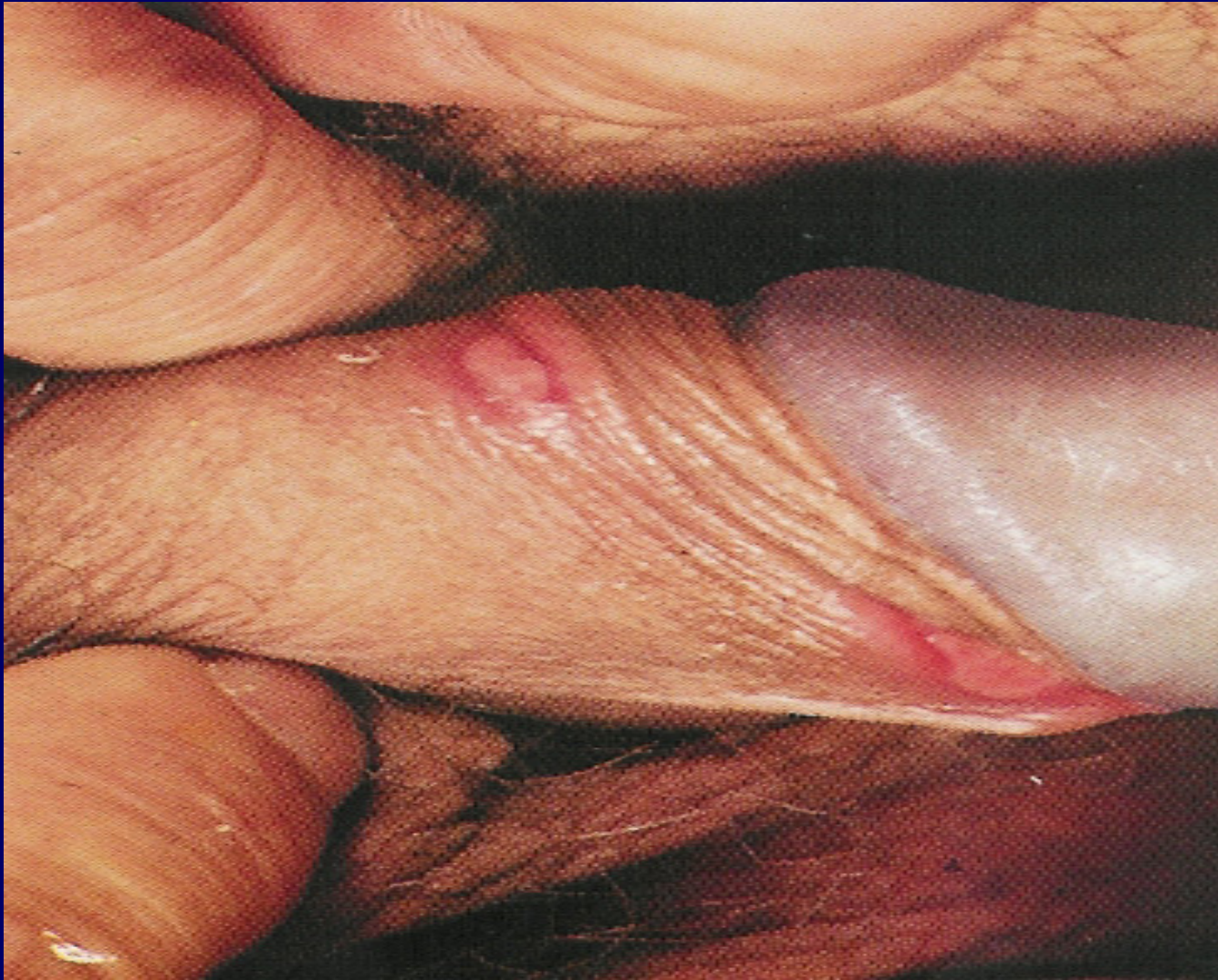- Vary from asymptomatic to mild or severe painful episode.
- If symptoms are present (I.P 2-12 days) they may include;
 - fever, malaise, dysuria,
 - Inguinal lymphadenopathy
 - Vesicular herpetic lesion or ulcer localized to the cervix, vagina, vulva or perineum of the female or the shaft of the penis in the male, Herpetic proctitis can be seen in homosexuals.
 - Aseptic meningitis have been observed in about 10% of cases as extra genital presentation.

Genital herpes



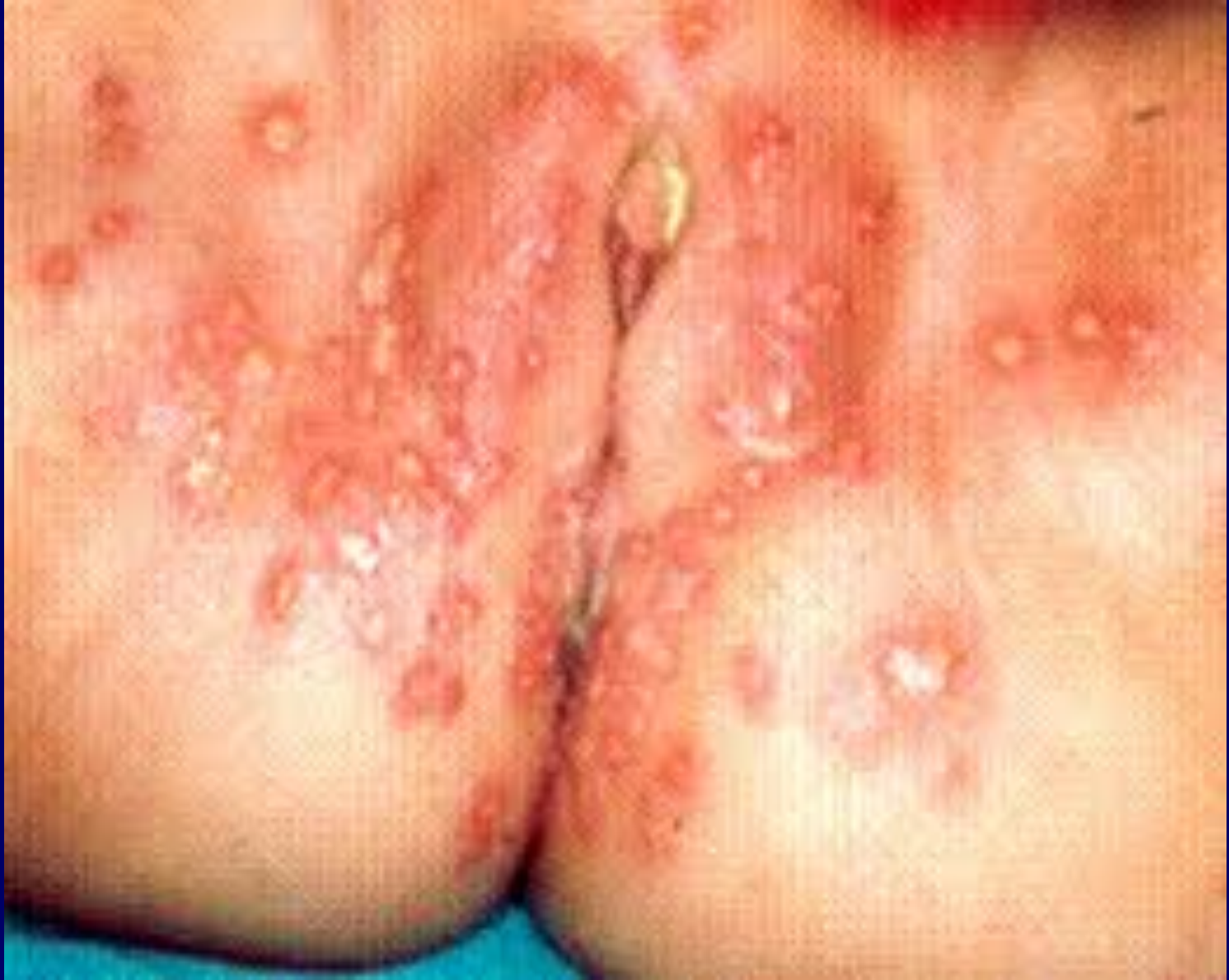

HSV2 on Vulva



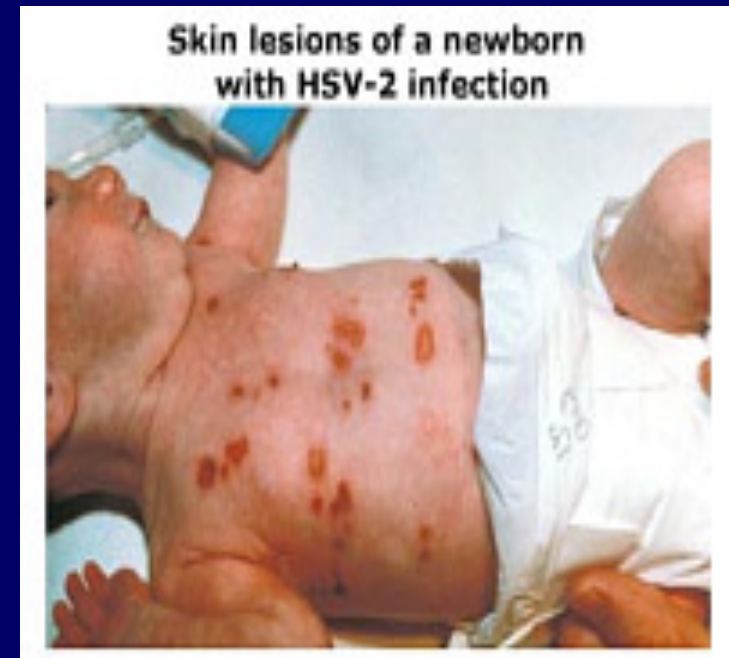HSV2 on Penis

Genital herpes



Neonatal herpes infection

- Is not a common condition, but the mortality is $>70\%$ when it happens.
- It occurs during labor and delivery through the vaginal canal when a mother is having a **primary** active herpetic lesion and shedding the virus, also in small % as vertical transmission during pregnancy.
- It may spread to other organs such as lungs, liver, brain.



Neonatal herpes infection

It has three forms:

1- Localized skin infection.

- limited to massive skin vesicular lesions
- mild infection

2- Localized brain infection.

- limited to CNS invasion causing encephalitis.
- mortality is high

3- Generalized neonatal herpes infection.

- Severe massive infection of the skin accompanied with internal organs infection as lungs (pneumonia), liver (hepatosplenomegally), and brain (encephalitis) with massive skin herpetic lesions.
- usually fatal

Neonatal herpes

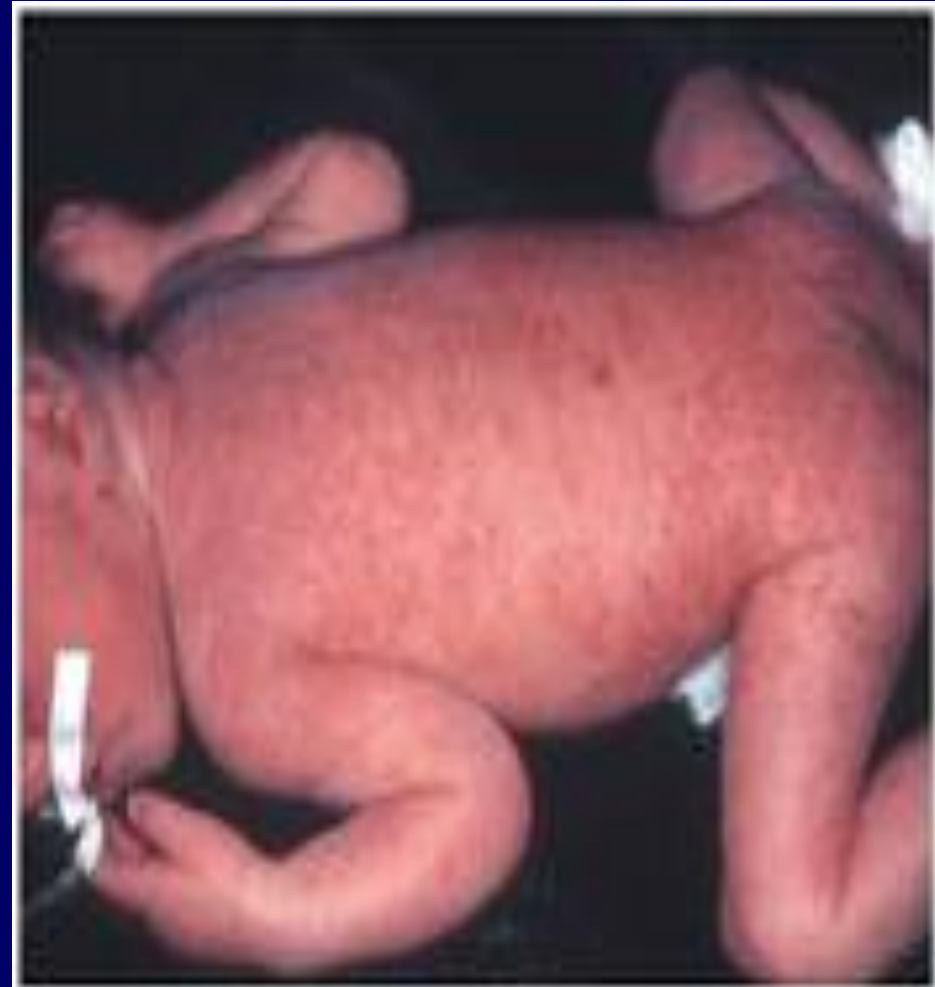
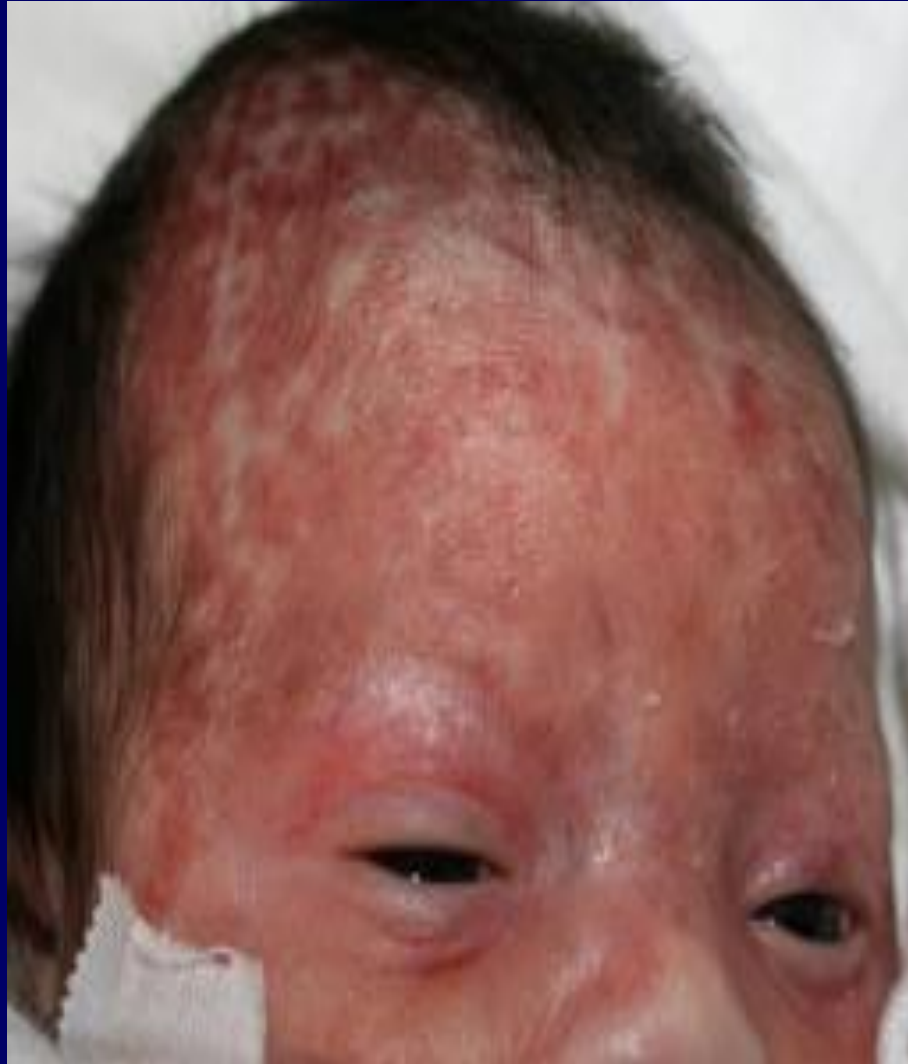
FIGURE 4: Congenital candidiasis

Clinical picture of recurrent genital herpes.

- Occurs after reactivation by environmental or physiological factors such as stress, exposure to U.V. light, menstruation, pregnancy or any condition decreased the immunity.
- This can be as frequent as six or more episode a year ,the attacks are milder and shorter than primary episode.
- Accompanied with the appearance of herpetic vesicles on the external genitalia.
- Symptoms may include pain and itching.

Lab diagnosis

1- ELISA:

serum sample is analyzed for detection the IgM Ab.

2- Immunofluorescence (IF):

lesion scraping or vesicle fluid sample is analyzed for detection the Ag.

3- Polymerase chain reaction (PCR):

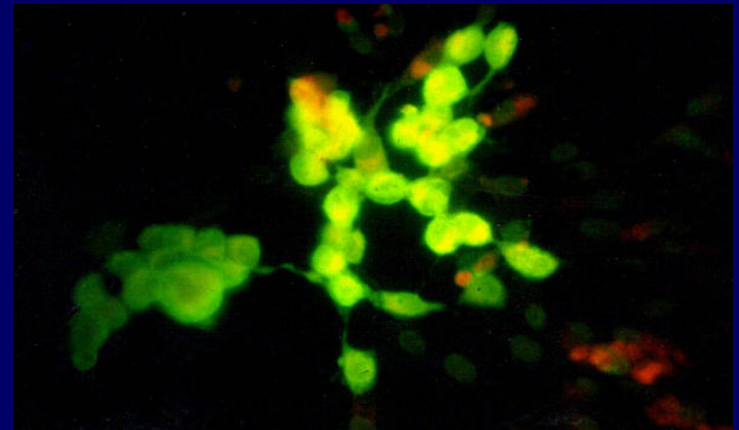
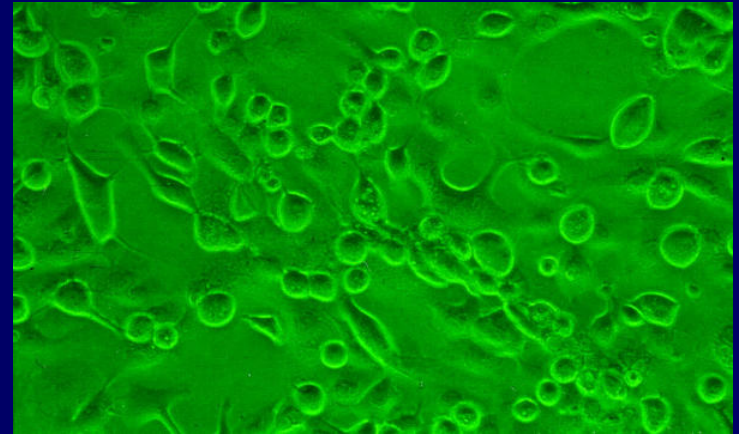
CSF sample in case of neonatal herpes.

Continued..

4- Tissue culture:

vesicle fluid sample is cultured in cell line (Vero or Hep-2 cells) and then identified by the following:

- Observe the viral CPE
- Direct immunofluorescence (IF)



Management

No vaccine is available to prevent HSV-2 infection, and thus the best way to control the HSV infection is by:

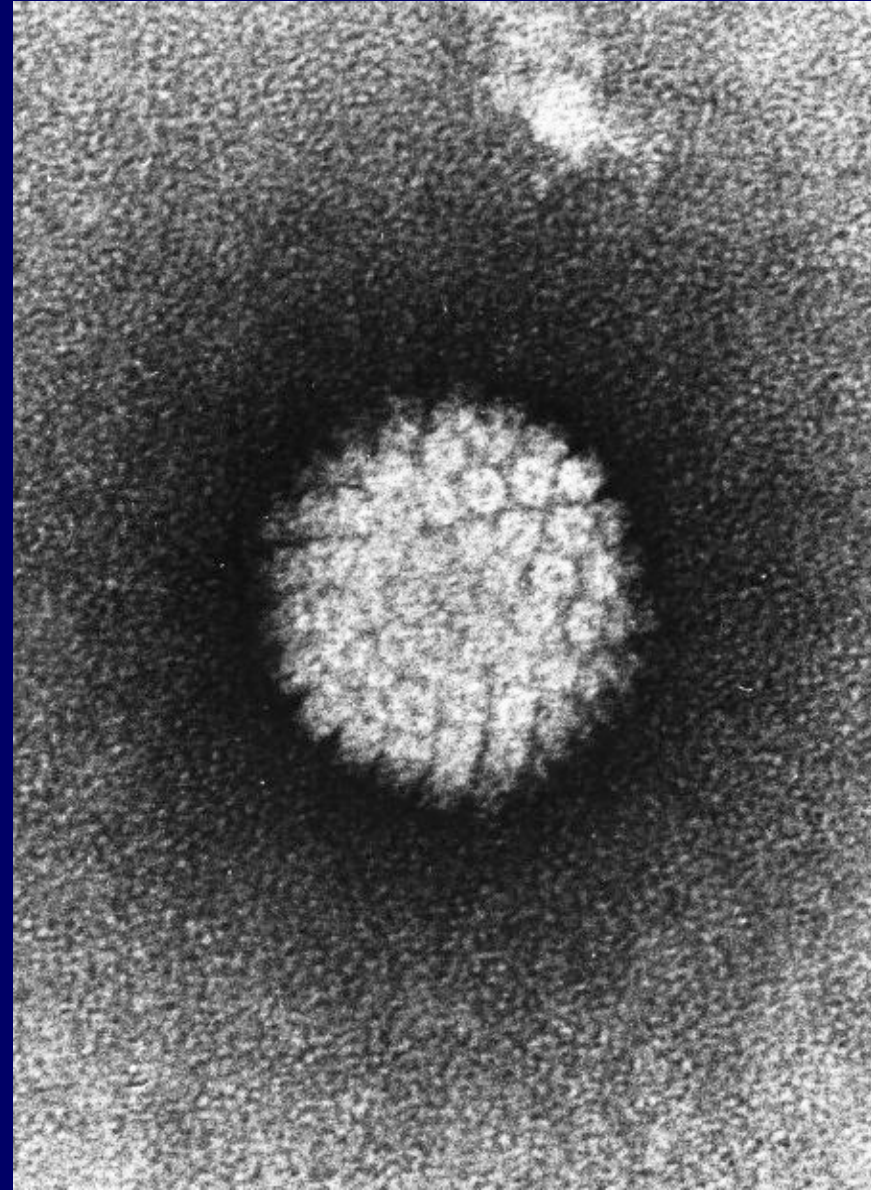
- Avoid sexual contact with infected individuals.
- Abstain from making prohibited relations.
- **Note: Condoms are not 100% protective against genital herpes infection.**

Treatment

- Acyclovir:
 - The 1st choice therapy.
 - Suitable for pregnant women.
- Famciclovir.
- Valacyclovir.

Human Papillomavirus

- Family of *Papillomaviridae*.
- Virion is small non-enveloped, and consist of:
 - Icosahedral capsid.
 - Circular ds-DNA.
 - They cause disease only in skin and mucous membrane.
- Does not grow in tissue culture.
- Resists detergent, and heat and can remain infectious in the environment for long time



Types of warts and HPV genotype

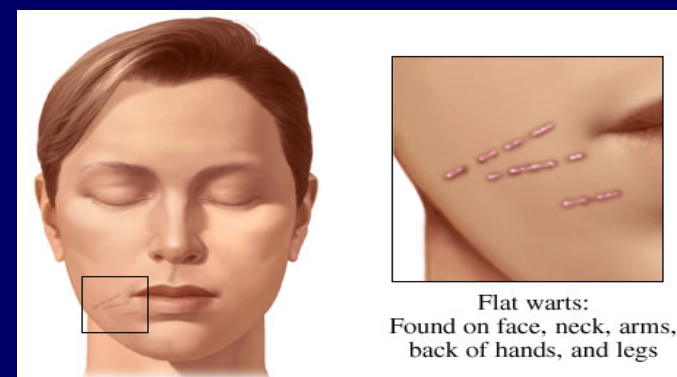
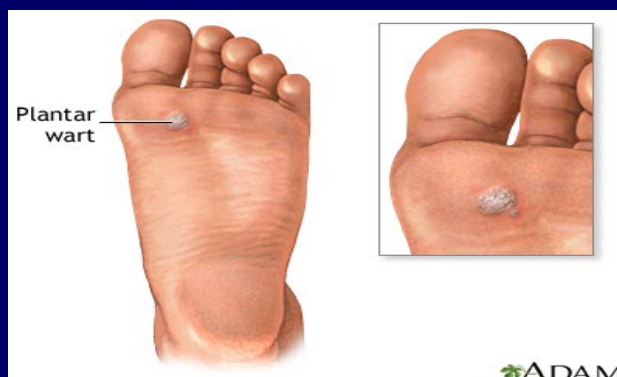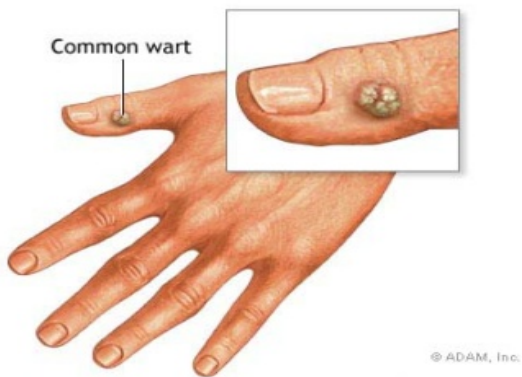1- Cutaneous warts:

The virus is transmitted from infected skin, either by direct contact or through fomites and enter its new host through abrasions. Swimming pools and changing rooms are fertile sources of infection, skin warts are most liable to affect young children.

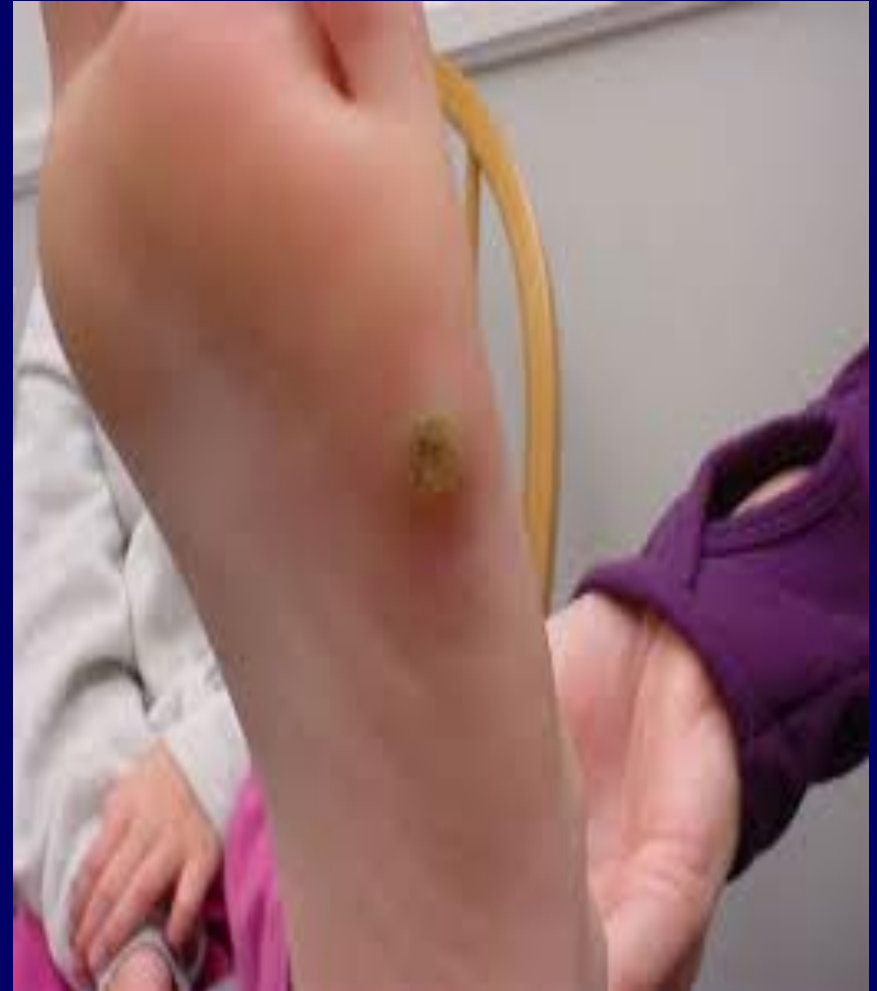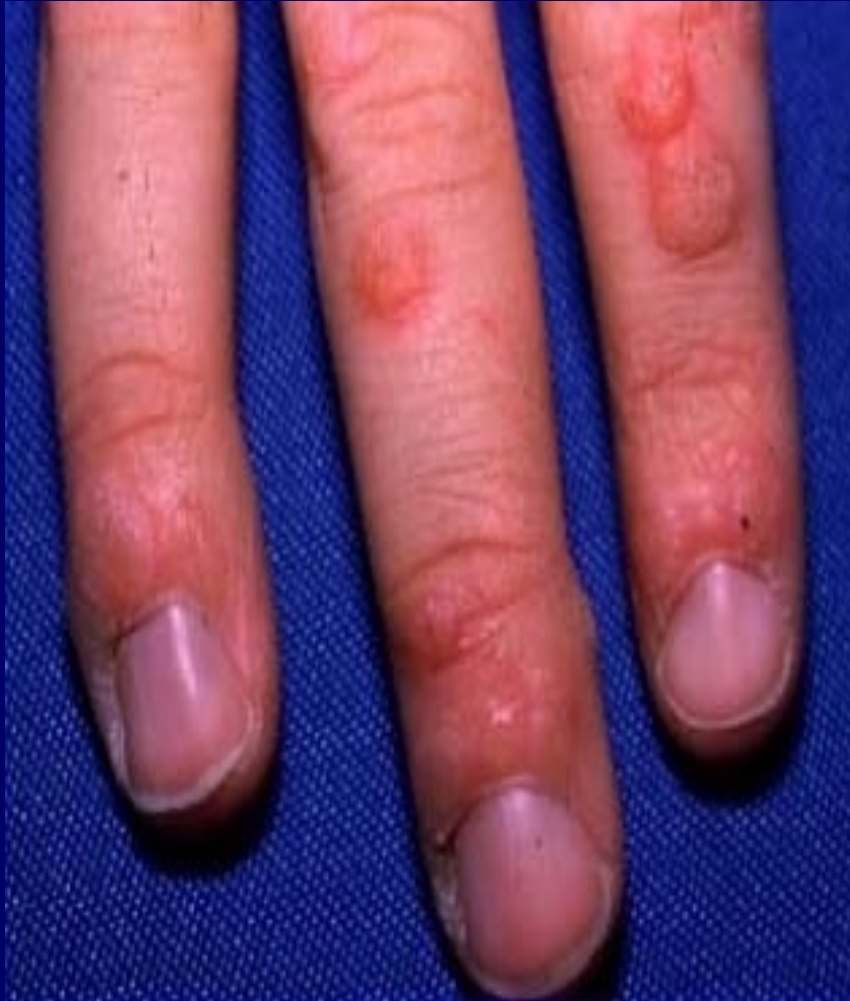Common Warts (HPV 2,4),

Plantar Warts (HPV 1,2,4),

Flat Warts (HPV 3,10)



Common warts and planter warts



2- Genital Warts

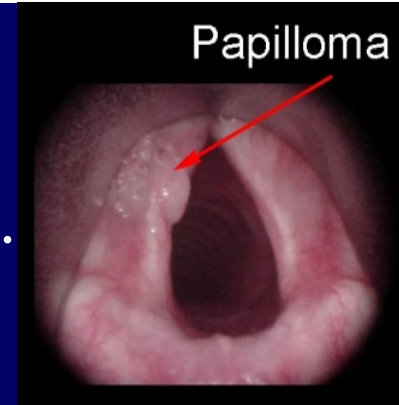
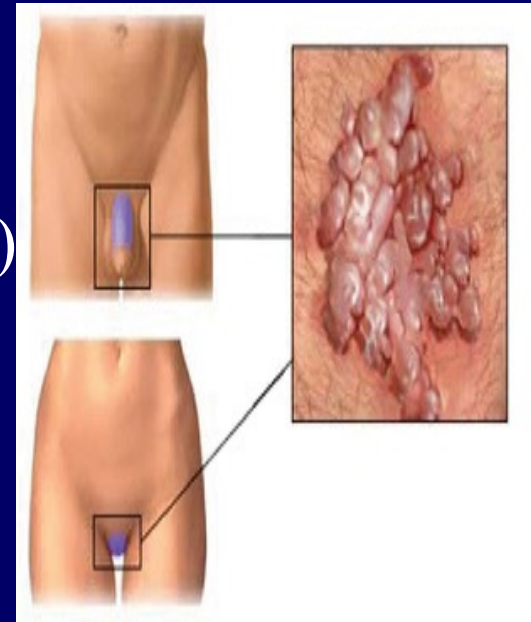
Genital ,Anogenital or mucosal Warts:

These Warts are acquired by sexual contact ,they are in fact one of the most common sexually transmitted diseases, and often occur in association with other sexual diseases as gonorrhoea or chlamydial infection.

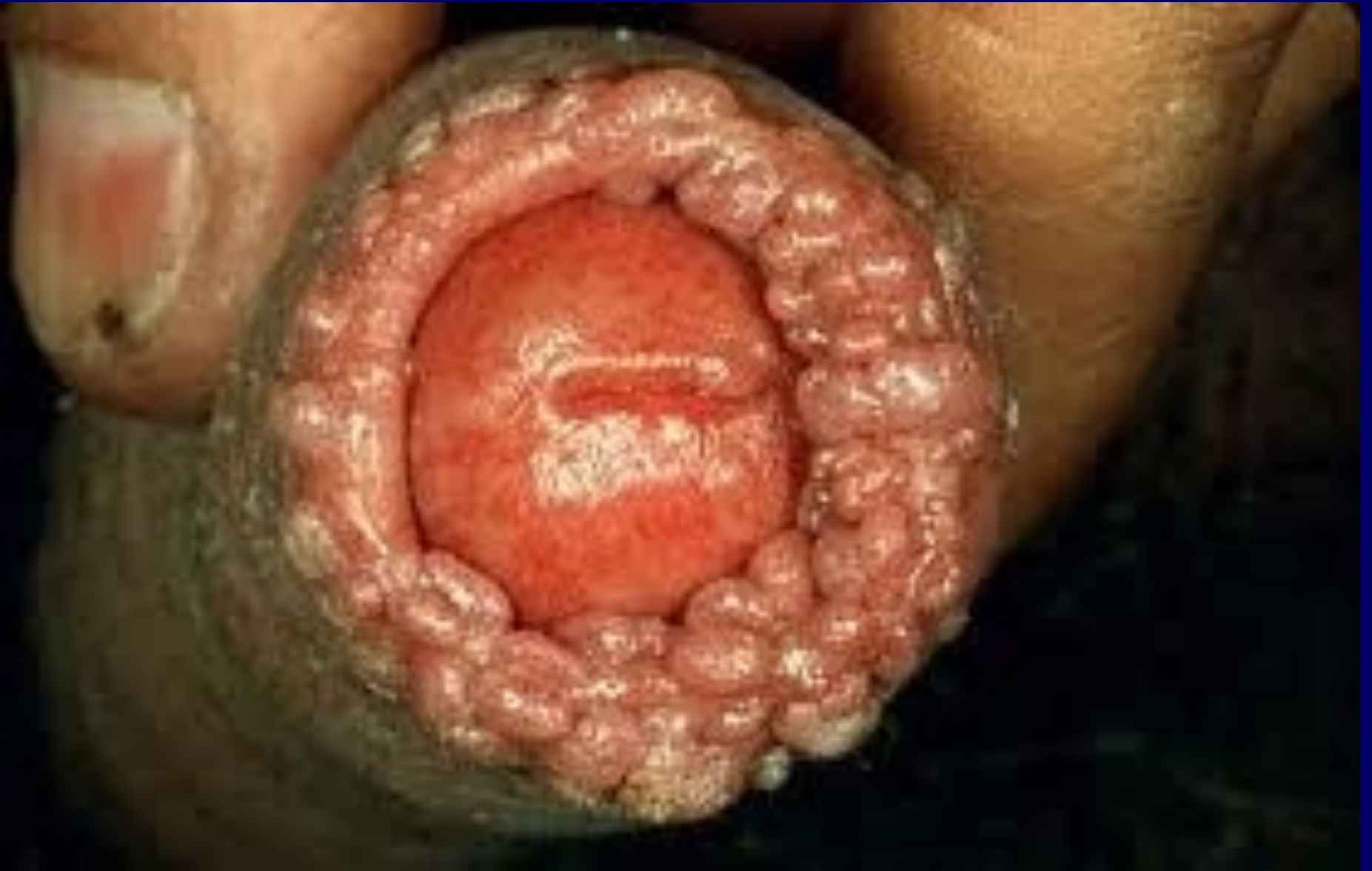- There is strong association between increasing numbers of sexual partners and prevalence of genital HPV infections.
- *Vertical transmission*; from mother to infant or prenatal transmission lesions appear within the first 6 weeks of life have been demonstrated.

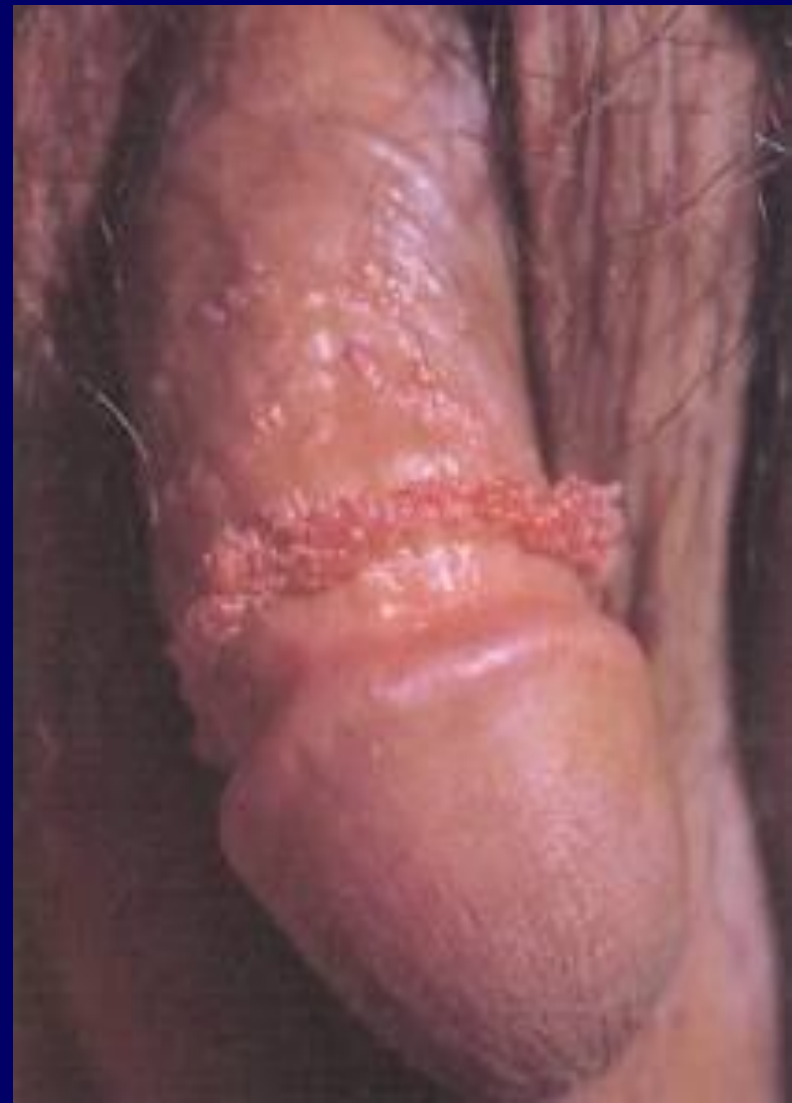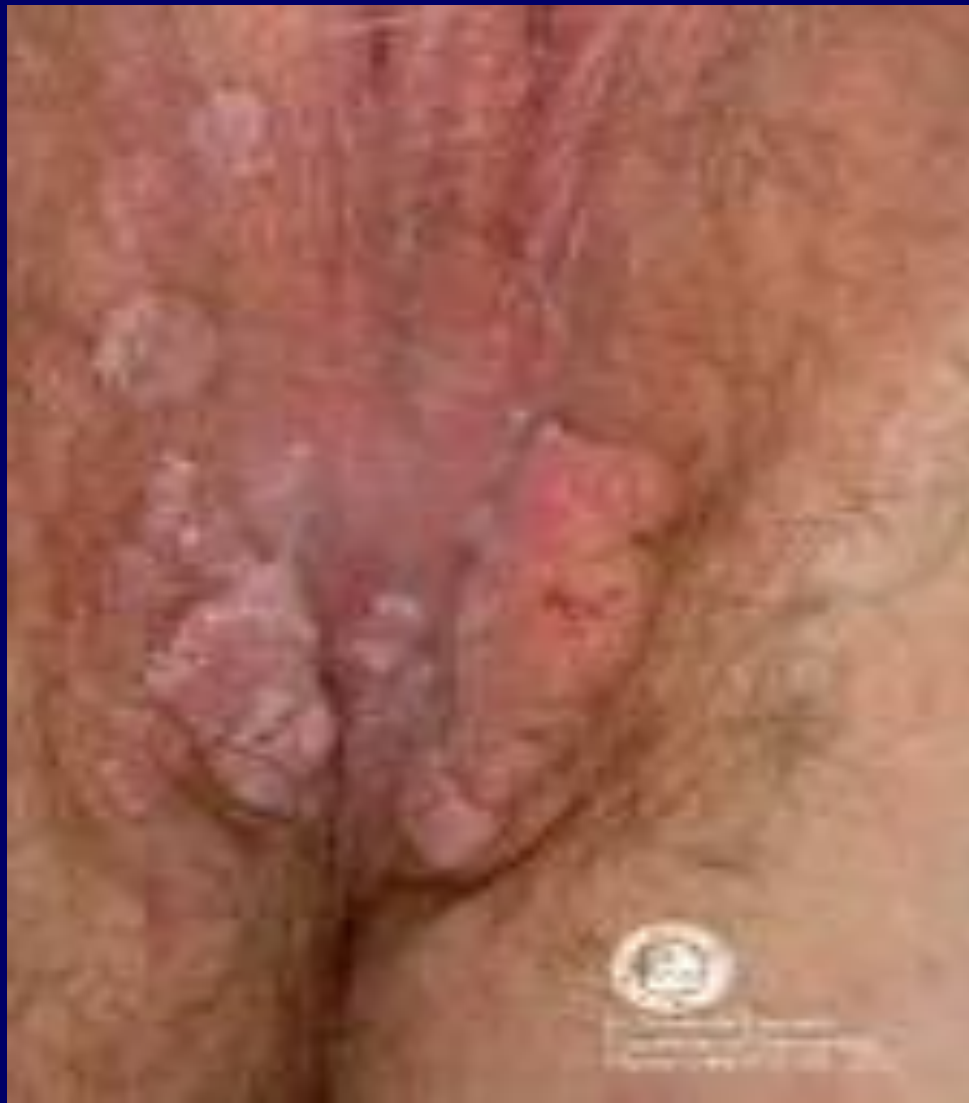Ano-genital or mucosal

- Condyloma acuminata (**benign HPV 6,11**)
- Cervical carcinoma (**HPV 16,18, 31,45**)
- Penile and anal carcinoma (**HPV 16,18**)
in men
- Laryngeal Warts (**benign HPV 6,11**)
- They may be transmitted to baby during delivery.



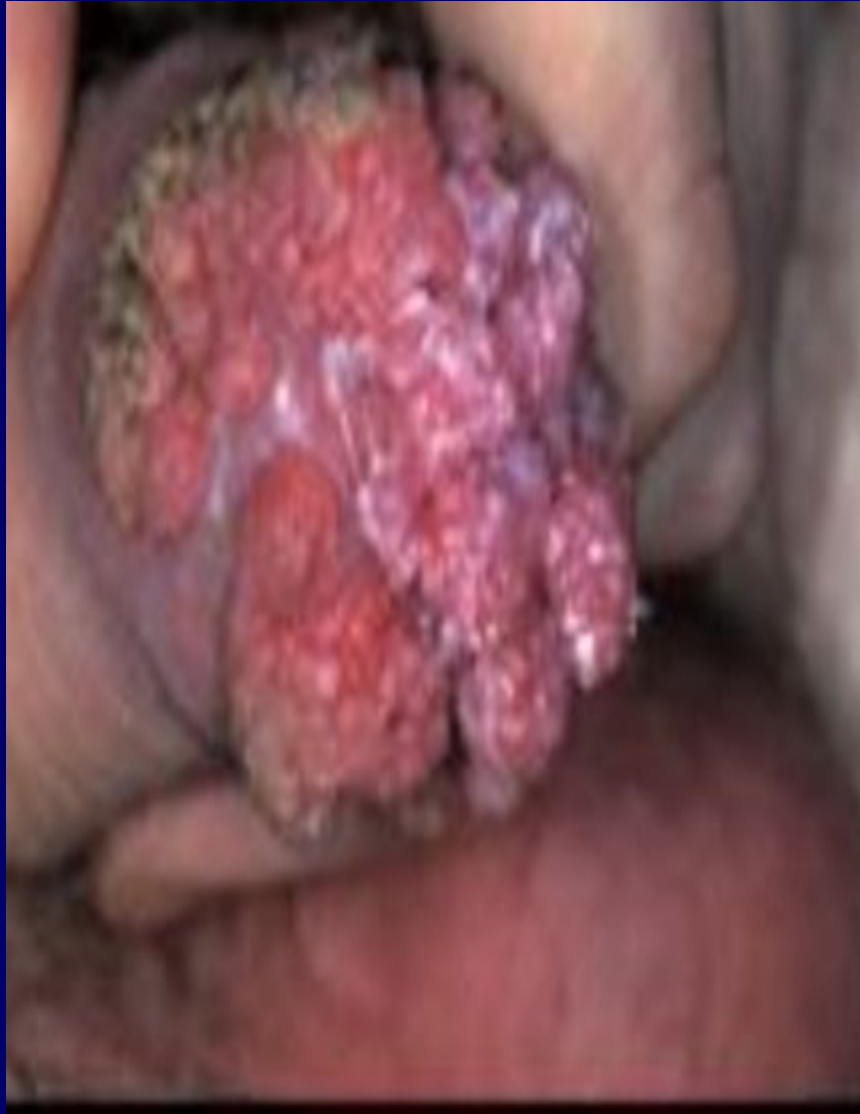Genital warts



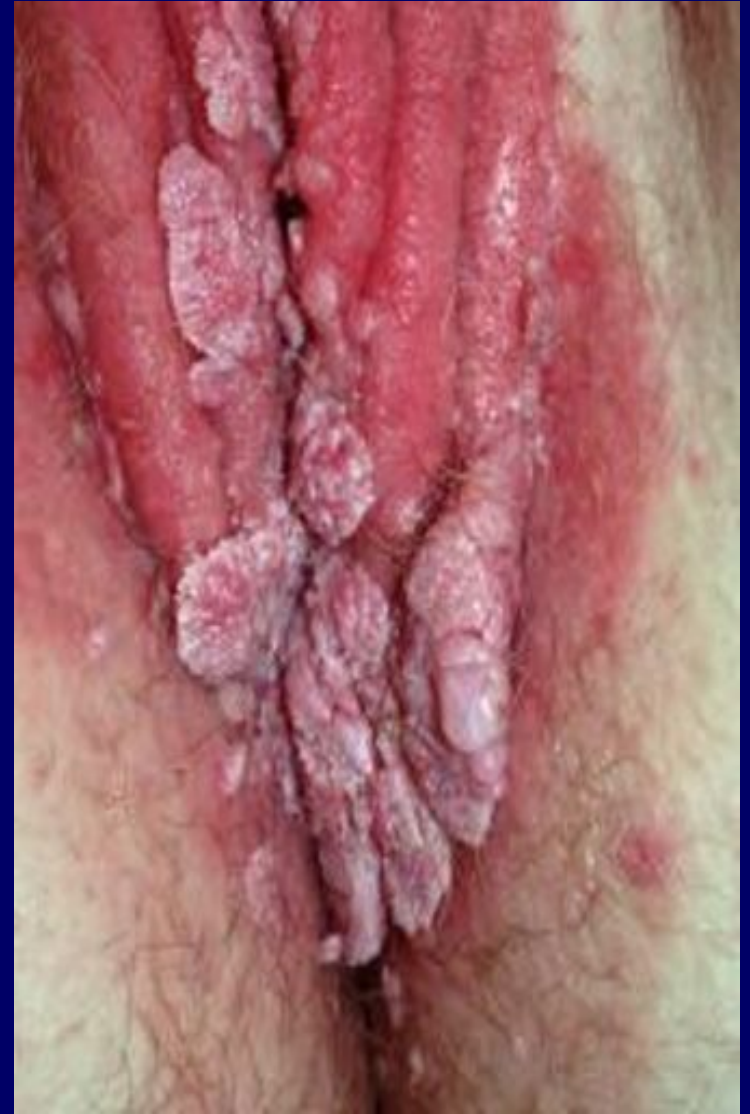

Genital warts

male

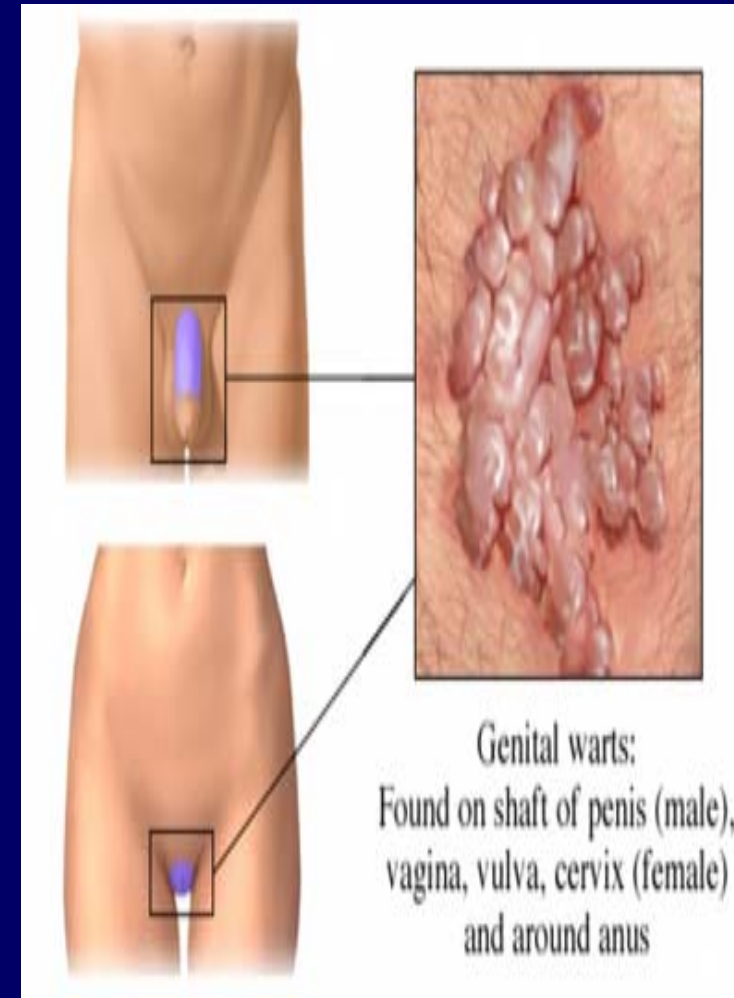


female



Clinical symptoms of genital warts

- Appear after 3-4 months after infection(I.P).
- Warts size vary from small round to large complex mass.
- Found in the anogenital tract (inside or outside the genital and the anal areas of both males and females).
- Localized pain
- Discomfort
- Abnormal vaginal bleeding and discharge.



Link between HPV and cervical cancer

- HPV type 6 and 11 (Condylomata acuminata) is unusual to become malignant, but they occasionally progress to squamous cell carcinoma, while HPV 16 and 18 are more commonly associated with lesions of great dysplasia which involves all layers of stratified epithelium, and has high chance of progression to metastasizing carcinoma & invasive cancer.

Persistent HPV infection is considered the main cause of cervical cancer, **HPV DNA** can be detected in most grades of premalignant lesions of the female and male genital tract.

- **> 90%** of positive Pap-smear is due to HPV infection.
- Pap-smear: is a screening test for detection abnormal epithelial cells of the cervix.

Diagnosis

- External genital warts can be easily diagnosed by medical examination.
- Internal genital warts can be visualized by colposcopy.

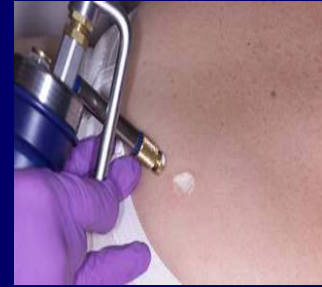Lab diagnosis:

- 1- **Polymerase chain reaction (PCR) is used to detect HPV DNA.**
- 2- Pap-smear test is used to identify abnormal epithelial cells of the cervix (cervical dysplasia).
- 3- In-situ DNA hybridization is used for HPV genotyping.

HPV treatment

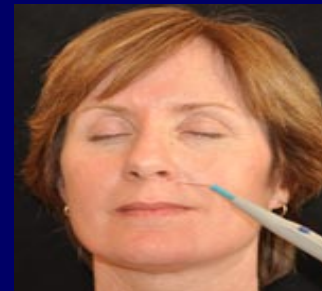1- Cryotherapy:

- freezing warts by liquid nitrogen
- suitable for small external warts



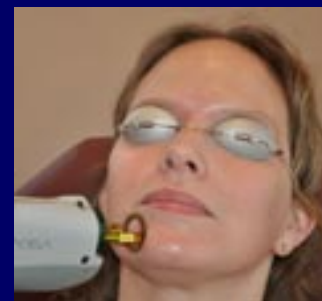2- Electrocautery treatment:

- destroying warts by an electric current
- suitable for small warts



3- Laser therapy:

- destroying warts by a focused light beam
- suitable for small and large warts



4- Surgical excision:

- removing warts by surgical tools
- suitable for all warts

Continued..

4- Topical treatment:

- Applied directly on external warts.
- Used for several weeks.
- Examples: Imiquimod, Podofilox.
- Podophyllin is applied by a doctor and contraindicated in pregnancy.
- Trichloroacetic acid (T.C.A) safe in pregnancy.

5- Injection:

- Interferon alpha, 5-fluorouracil epinephrine gel.
- Could be taken for several weeks (8-12).

HPV prevention

There are two vaccines available Gardasil and Cervarix and both are:

- Recombinant viral-like particles with no DNA.
- Given in 3 doses at 0, 2, 6 months.
- Recommended for young individuals ages 9-26 yrs old.
- Not given to pregnant women.
- **Gardasil**, a quadrivalent vaccine, provides protection against HPV genotypes 6,11,16,18 which causes genital warts.
- **Cervarix**, a divalent vaccine, provides protection against HPV genotypes 16, and 18 which causes cervical cancer.

Thank you for your attention !