

DISORDERS OF PREGNANCY AND PLACENTA

ECTOPIC PREGNANCY, SPONTANEOUS ABORTION AND GESTATIONAL TROPHOBLASTIC DISEASE.

SUFIA HUSAIN

Pathology

KSU, Riyadh

March 2018

Reference: Robbins & Cotran Pathology and Rubin's Pathology

Objectives

At the end of this lecture, the student should be able to:

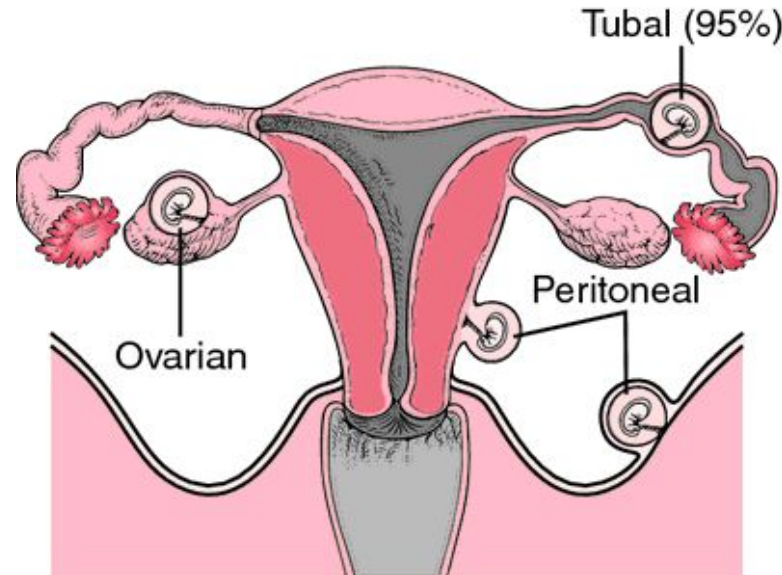
- A. Understand the pathology and predisposing factors of ectopic pregnancy and spontaneous abortion.
- B. Know the clinical presentation and pathology of hydatidiform mole and choriocarcinoma.

ECTOPIC PREGNANCY



Ectopic Pregnancy

- **Definition:** Ectopic pregnancy is defined as implantation of a fertilized ovum in any site other than the endometrium of the uterine cavity. About 1% of all pregnancies are ectopic.
- **Sites:**
 - Over 90% of ectopic pregnancies occur in the fallopian tubes (tubal pregnancy).
 - Other sites of ectopic pregnancy include the ovaries, abdominal cavity and uterine cervix.



Ectopic pregnancy. The fallopian tube is the most common site for ectopic pregnancies but they can also occur on the ovary or the peritoneal surface of the abdominal cavity. From Damjanov, 2000.

Ectopic Pregnancy

Clinical features

- A woman with an ectopic tubal pregnancy may present with pelvic pain or abnormal bleeding following a period of amenorrhea.
- Many present as an emergency with tubal rupture, severe acute abdominal pain and hemorrhagic shock.

Diagnosis

- Clinical:
 - abdominal/pelvic ultrasound → gestational sac within fallopian tube or other location
 - positive HCG levels
- Microscopic: placental tissue or fetal parts

Risk factors for ectopic pregnancy

Tubal ectopic pregnancy:

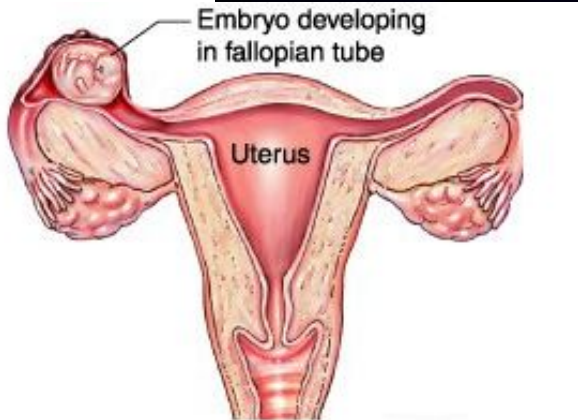
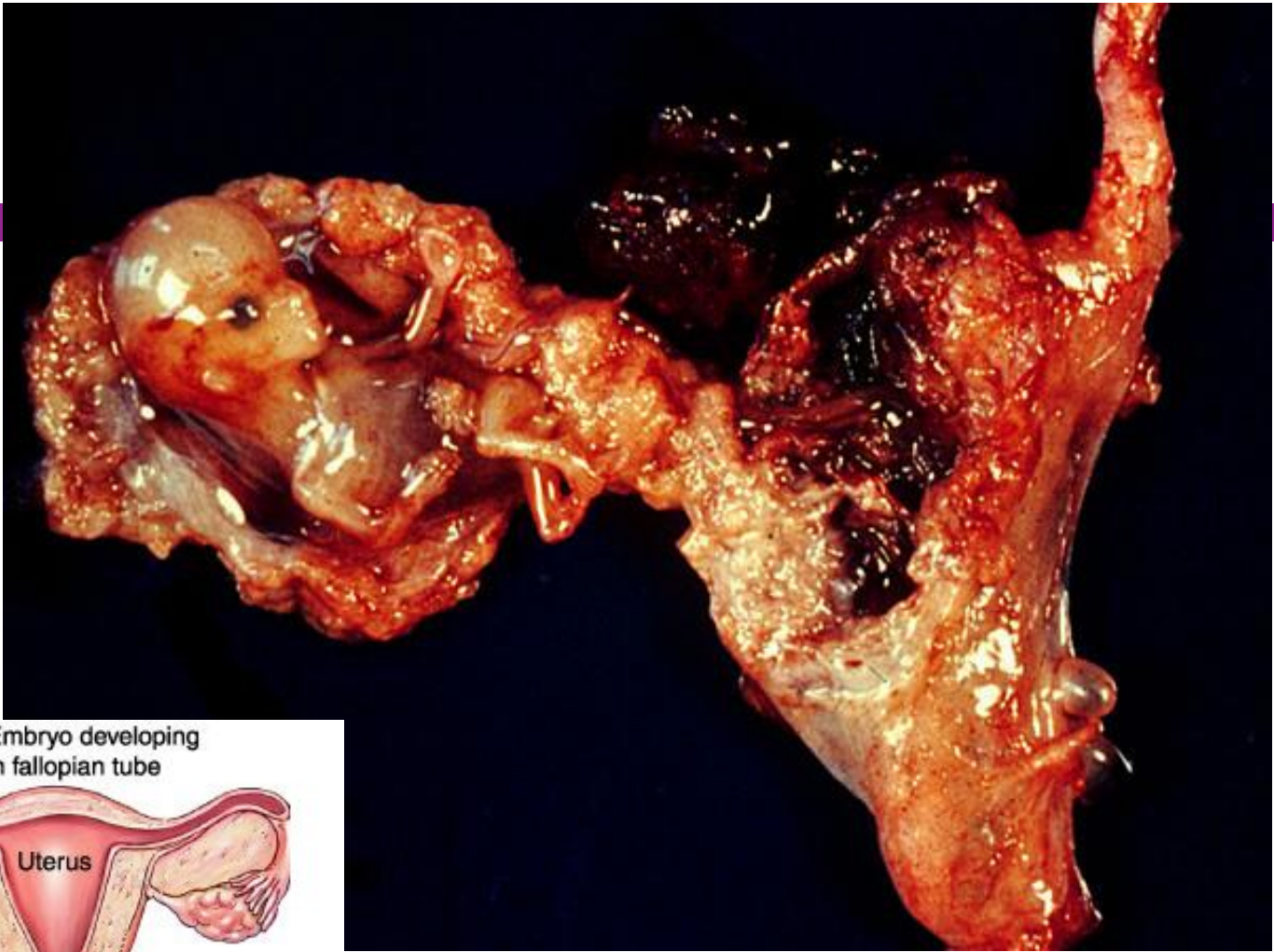
- Fallopian tubes are the most common location for ectopic pregnancies
- Any factor that retards passage of the ovum through the tubes predisposes to tubal ectopic pregnancy.
- In about half of the cases, it is due to chronic inflammation and scarring in the oviduct.
- The risk factors are as follows:
 1. Pelvic inflammatory disease/infections/salpingitis is the most common cause. The inflammation can damage ciliary activity, cause tubal obstruction, pelvic adhesions with scarring and distortion of the fallopian tubes. Women who have had pelvic infections have a five times greater risk of ectopic pregnancy (infection is usually by *Neisseria gonorrhoea* & *Chlamydia*).
 2. Abdominal/pelvic surgery or tubal ligation surgery.
 3. Intrauterine tumors and endometriosis.
 4. Smoking can → decreased tubal motility by damaging ciliated cells or it may predisposing them to pelvic inflammatory disease (due to the impaired immunity in smokers).
 5. Congenital anomaly of the tubes.
 6. In-utero diethylstilbestrol (DES) exposure increases the risk of ectopic pregnancy due to

Risk factors for ectopic pregnancy

7. History of previous ectopic pregnancy
8. History of multiple sexual partners → increase chance of pelvic inflammatory disease and therefore are high risk for ectopic pregnancy.
9. Intrauterine device users are at higher risk of having an ectopic pregnancy should pregnancy occurs.
10. History of infertility: there is higher risk of ectopic pregnancy in the infertile population. This may be due to the underlying infertility related issues or fertility drugs and treatments. In vitro fertilization has been associated with an increased risk of ectopic pregnancy including cervical pregnancies
 - NOTE: please note that in many tubal pregnancies, no anatomic cause is evident.

Ovarian pregnancies probably result from rare instances in which the ovum is fertilized just as the follicle ruptures.

Gestation within the abdominal cavity occurs when the fertilized egg drops out of the fimbriated end of the oviduct and implants on the peritoneum.



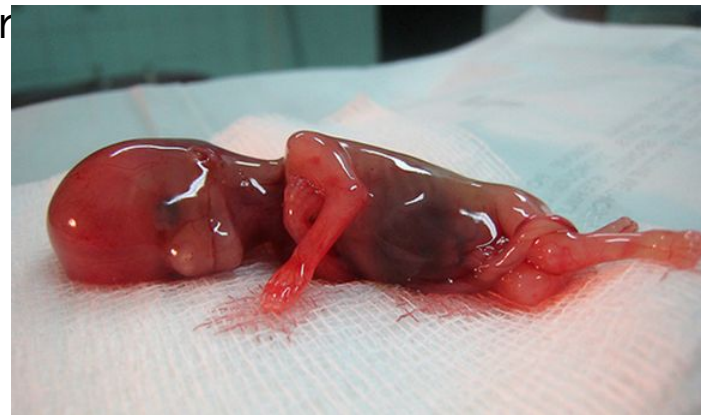http://4.bp.blogspot.com/-99ik_pMAEF4/USoTKSJB5fI/AAAAAAAAAD4/3w8mdgVxDSQ/s320/ectopic_pregnancy.jpg

SPONTANEOUS ABORTION



Spontaneous abortion (SAB)/ Miscarriage

- **Also known as miscarriage**
- It is the spontaneous end of a pregnancy at a stage where the embryo or fetus is incapable of surviving.
- Miscarriages that occur
 - before the 6th week of gestation are called *early pregnancy loss or chemical pregnancy*.
 - after the 6th week of gestation are called *clinical spontaneous abortion*.
- About 10-25% of all pregnancies end in miscarriage.
- Most miscarriages occur during the first



Causes of SAB/Miscarriage:

- Most miscarriages occur during the first trimester.
- The cause of a miscarriage cannot always be determined.
- Miscarriages can occur for many reasons. Chromosomal abnormalities of the fetus are the most common cause of early miscarriages. The causes are as follows

1. Chromosomal abnormalities:

- Half of the 1st trimester miscarriages have abnormal chromosomes.
- Chromosomal abnormalities also become more common with aging, and women over age 35 have a higher rate of miscarriage than younger women.
- A pregnancy with a genetic problem has a 95% probability of ending in miscarriage.

Causes of SAB/miscarriage

2. Hormonal problems: there is an increased risk of miscarriage with

- Cushing's Syndrome
- Thyroid disease
- Polycystic ovary syndrome (PCOS).
- Diabetes: good control of blood sugars during pregnancy is important. If the diabetes is not well controlled, there is increase risk of miscarriages and also of the baby to have birth defects.
- Inadequate function of the corpus luteum in the ovary (which produces progesterone necessary for maintenance of the very early stages of pregnancy) leads to progesterone deficiency which may lead to miscarriage.

3. Infections: by *Listeria monocytogenes*, *Toxoplasma gondii*, parvovirus B19, rubella, herpes simplex, cytomegalovirus and lymphocytic choriomeningitis virus etc are associated with an increased risk of pregnancy loss.

4. Maternal health problems can predispose to miscarriages e.g. systemic lupus erythematosus and antiphospholipid antibody syndrome

5. Lifestyle: smoking, drug use, malnutrition and exposure to radiation or toxic substances

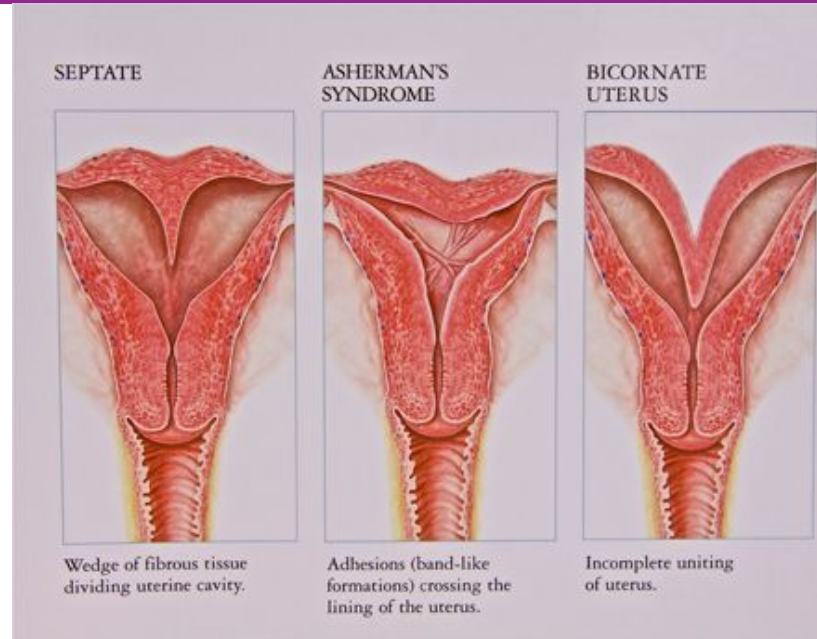
6. Maternal age: SABs increase after age 35 due to ovum abnormalities

7. Maternal trauma

Causes of SAB/miscarriage

8. Abnormal structural anatomy of the uterus can also cause miscarriages e.g. septate or bicornate uterus affect placental attachment and growth. Therefore, an embryo implanting on the septum would be at increased risk of miscarriage. Uncommonly uterine fibroids can interfere with the embryo implantation and blood supply, thereby causing miscarriage

9. Others: surgical procedures in the uterus during



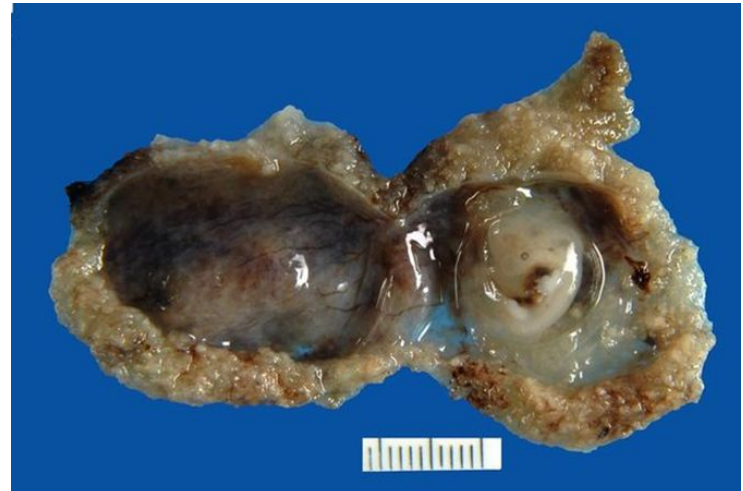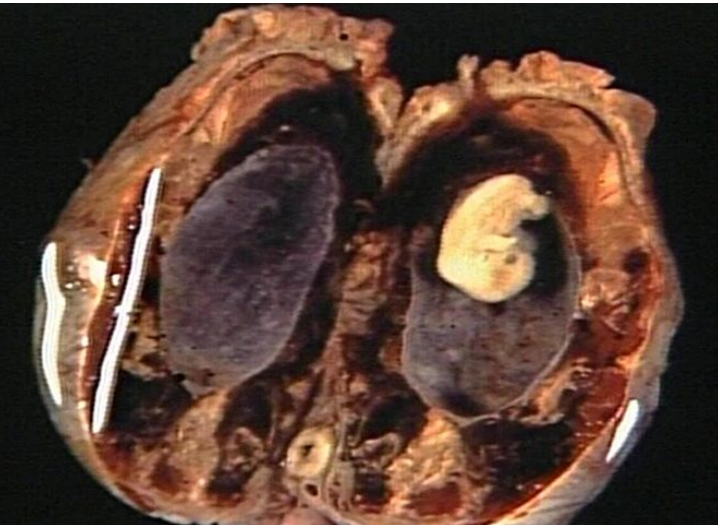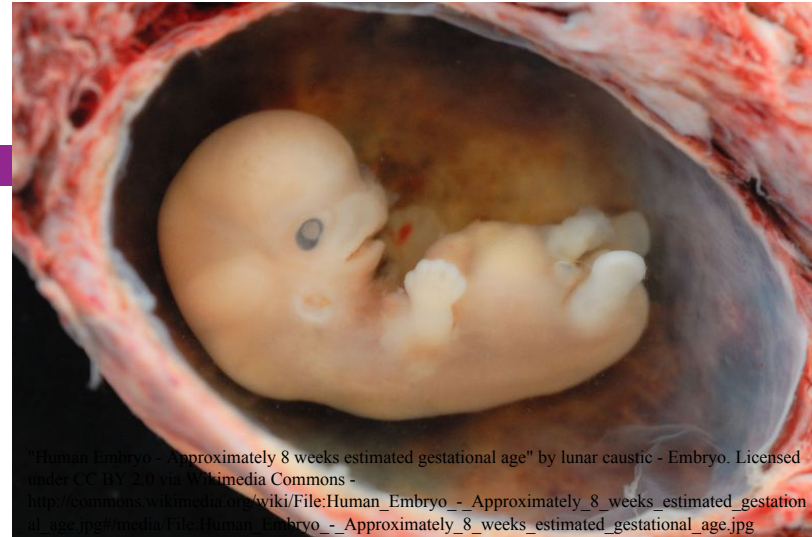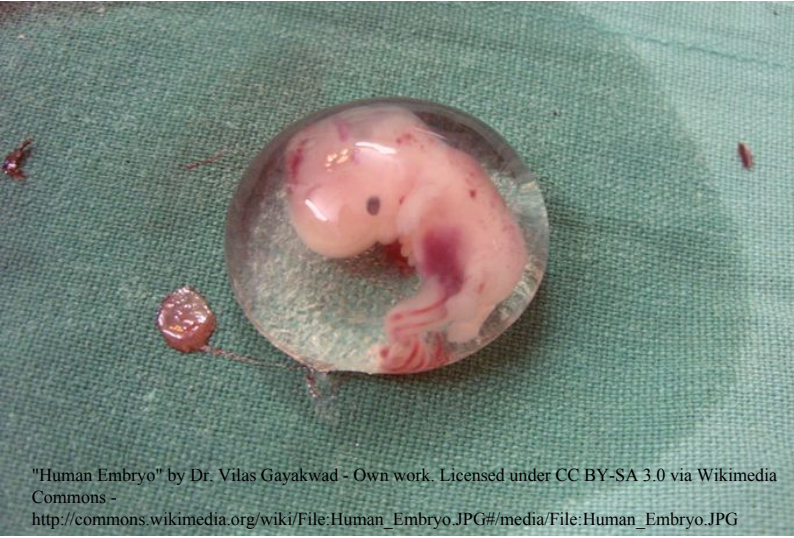http://www.acfs2000.com/assets/images/surgery_services/mullerian7.jpg

SAB/miscarriage

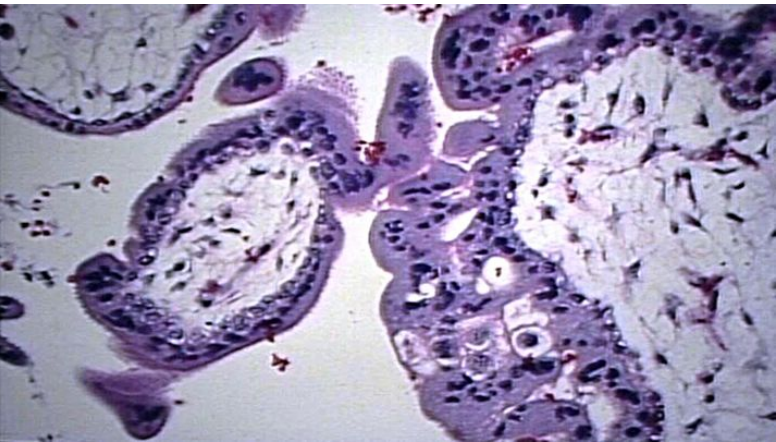
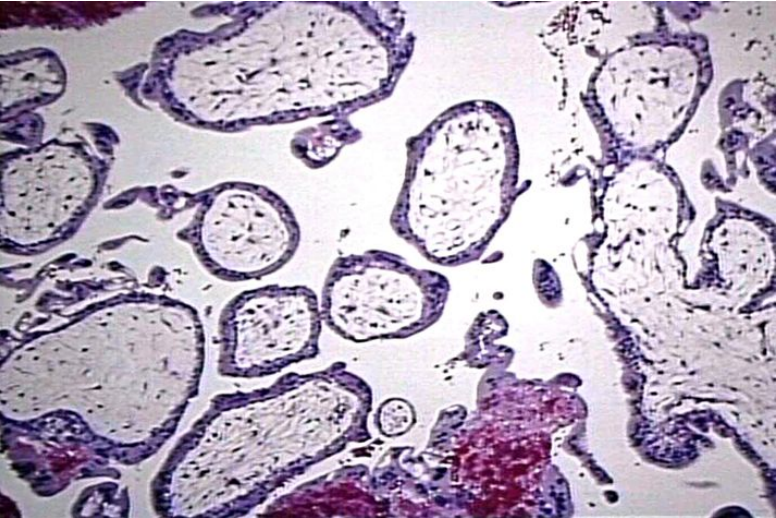
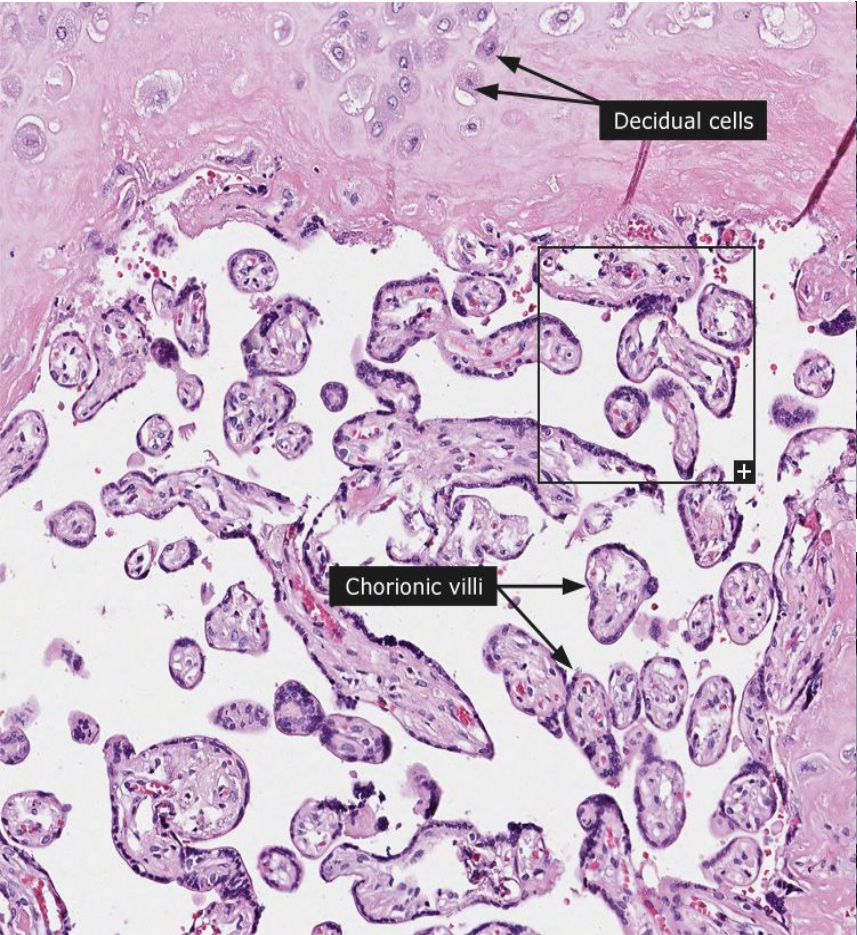
Diagnosis:

- A miscarriage can be confirmed
 - By ultrasound study
 - By the examination of the passed tissue microscopically for the products of conception. The products of conception include chorionic villi, trophoblasts, fetal parts and changes in the endometrium (hypersecretory).
- Genetic tests may also be performed to look for chromosomal anomalies.

Products of conception



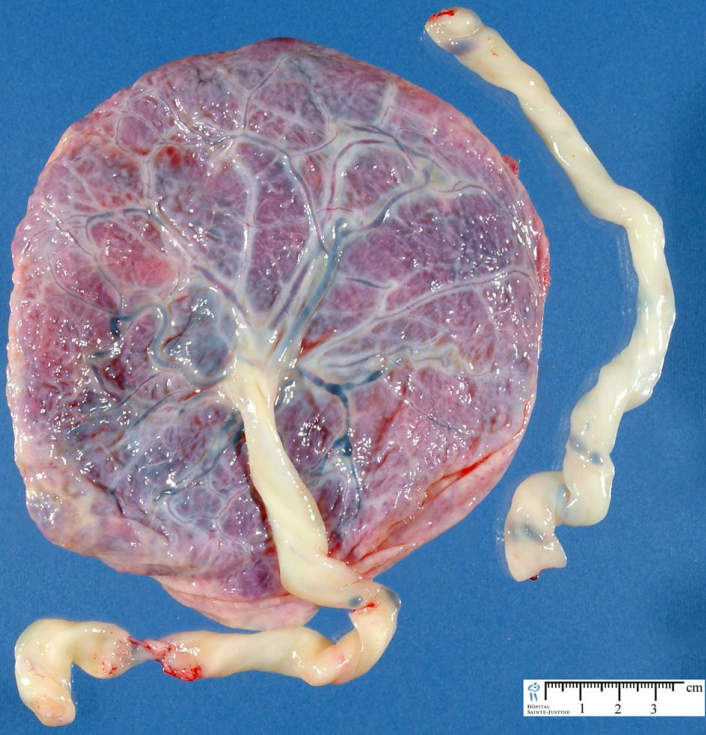
PRODUCTS OF CONCEPTION



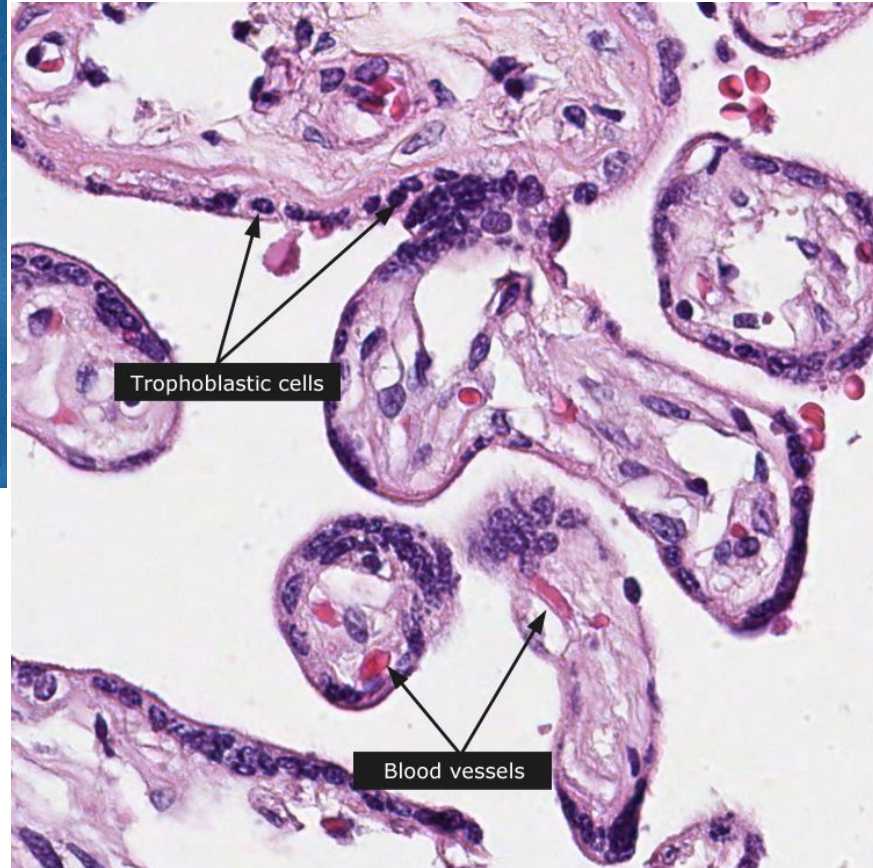
GESTATIONAL TROPHOBLASTIC DISEASE



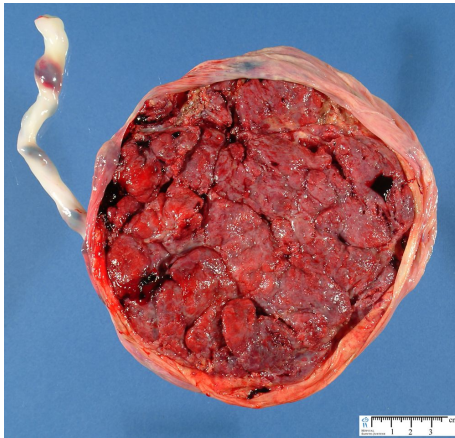
Normal placenta



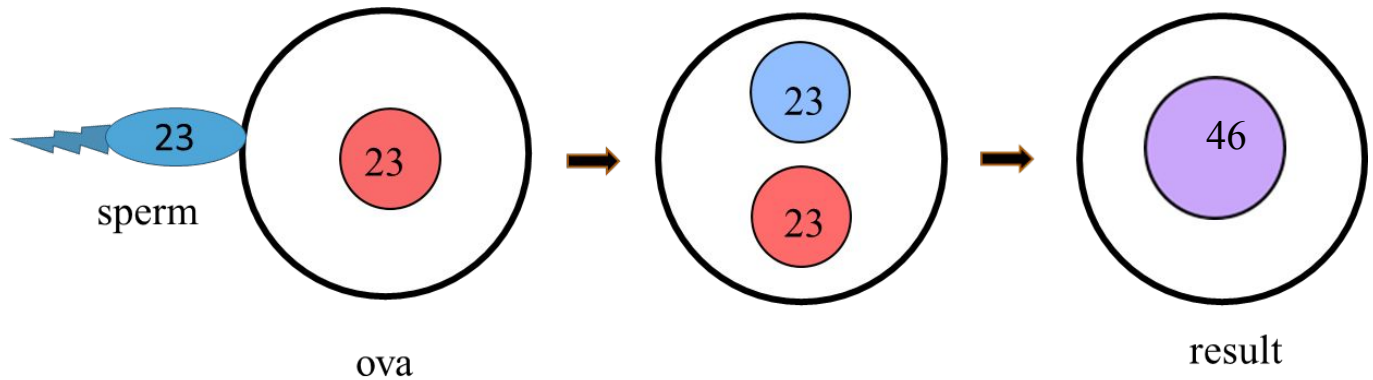
<http://www.humpath.com/IMG/jpg/placenta1>



http://www.proteinatlas.org/images_dictionary/placenta__1__example_1_1_100_1.jpg



Normal fertilization: a single sperm of 23 chromosomes fertilizes a normal egg of 23 chromosomes



Gestational Trophoblastic Disease (GTD)

- Gestational trophoblastic disease is a group of related disorders in which there is abnormal proliferation of placental trophoblasts.
- GTD are divided into
 1. benign non-neoplastic lesions
 2. hydatidiform moles
 3. neoplastic lesions
- The maternal age above 40 years has a 5 times more risk of trophoblastic disease compared to the mothers below 35 years.
- Most women who have had gestational trophoblastic disease can have normal pregnancies later.
- Most GTD produces the beta subunit of human chorionic gonadotropin (HCG).

NOTE:

- Serum HCG is also elevated in pregnancy (normal and ectopic) but in GTD it is markedly elevated.
- Also while in normal pregnancy the HCG levels drop after 14 weeks of gestation, in GTD the serum HCG levels continue to rise even after 14th weeks.

Types of GTD

The GTD have been divided and classified as follows:

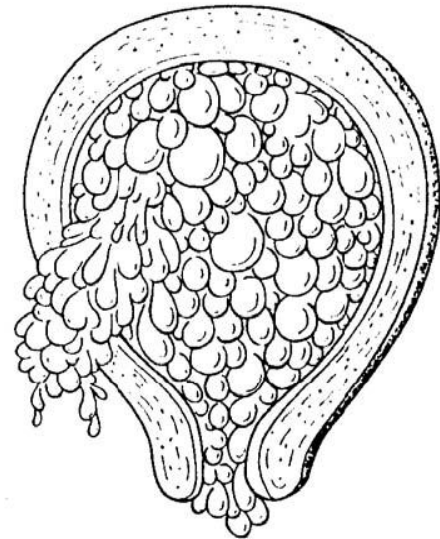
1. **Benign non-neoplastic trophoblastic lesions** — These are diagnosed as an incidental finding on an endometrial curettage or hysterectomy specimen. They are:
 - Exaggerated placental site
 - Placental site nodule
2. **Hydatidiform mole** — result from abnormalities in fertilization. They are essentially benign, but these patients carry an increased risk of subsequently developing choriocarcinoma. They are:
 - Complete hydatidiform mole
 - Partial hydatidiform mole
 - Invasive mole/chorioadenoma destruens
3. **Gestational trophoblastic neoplasia (GTN)** — are a group of tumors. They have potential for local invasion and metastases. They are:
 - Choriocarcinoma
 - Placental site trophoblastic tumor
 - Epithelioid trophoblastic tumor

Hydatidiform Mole

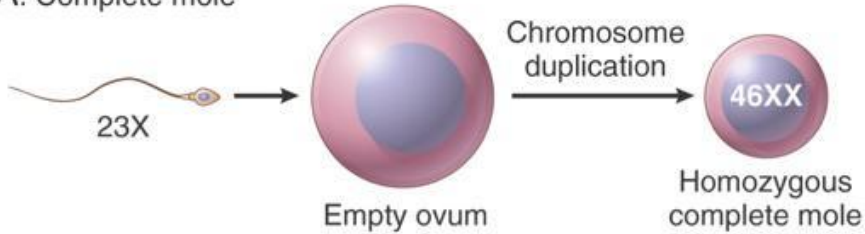
- It is an abnormal placenta due to excess of paternal (from father) genes.
- It is caused by abnormal gametogenesis and fertilization.
- It is the most common form of gestational trophoblastic disease; occurs in 1/1,000-2,000 pregnancies
- It results in the formation of enlarged and edematous placental villi, which fill the lumen of the uterus.
- Passage of tissue fragments, which appear as small grapelike masses, is common. The serum HCG concentration is markedly elevated, and are rapidly increasing.
- **Risk factors:**
 - maternal age: girls younger than 15 years of age and women over 40 are at higher risk.
 - Ethnic background: incidence higher in Asian women
 - Women with a prior hydatidiform mole have a 20-fold greater risk of a subsequent molar pregnancy than the general population.
- There are 2 types of hydatidiform mole (HM).
 - **Complete HM**
 - **Partial HM**

Complete HM

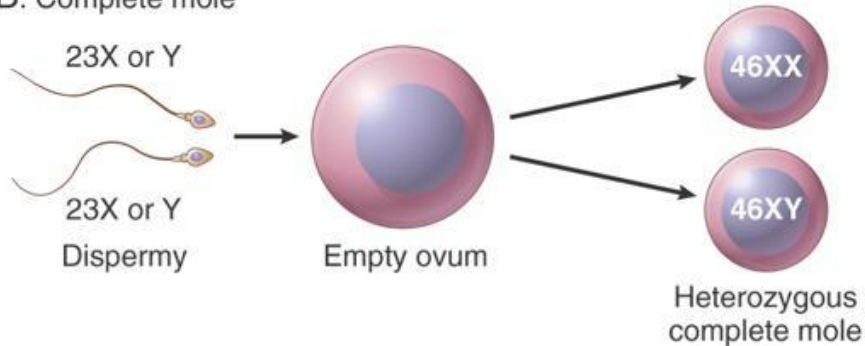
- ▶ Complete mole results from fertilization of an empty ovum that lacks maternal DNA → as a result all chromosomal material is derived from the sperm. There is complete lack of maternal chromosomes. All the chromosomes come from the male/paternal side i.e. it is an androgenetic pregnancy with no maternal DNA.
- ▶ 90% of complete moles are 46 XX, arising from duplication of the chromosomes of a haploid sperm after fertilization of an empty ovum
- ▶ It is a genetically abnormal placenta with hyperplastic trophoblasts, without fetus or embryo.
- ▶ Symptoms: fast rate of abdominal swelling (due to rapid increase in uterine size) mistaken for normal pregnancy but the uterus is disproportionately large for that stage of pregnancy. In addition patient has some vaginal bleeding, severe nausea and vomiting. HCG levels are elevated.
- ▶ Uterus is distended and filled with swollen/large villi with prominent trophoblastic cell proliferation. No embryo, or fetal tissue is present. Grossly it looks like a bunch of grapes.



A. Complete mole

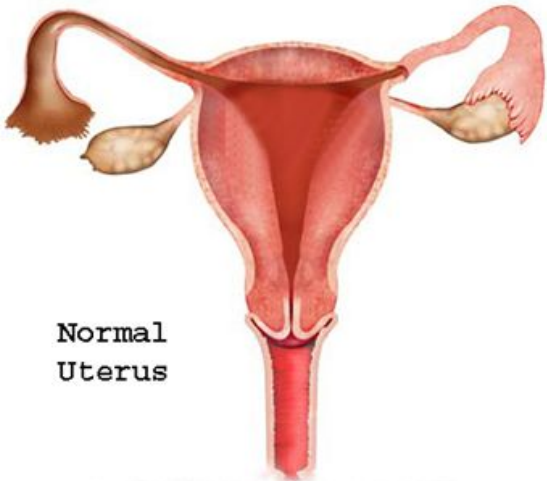


B. Complete mole

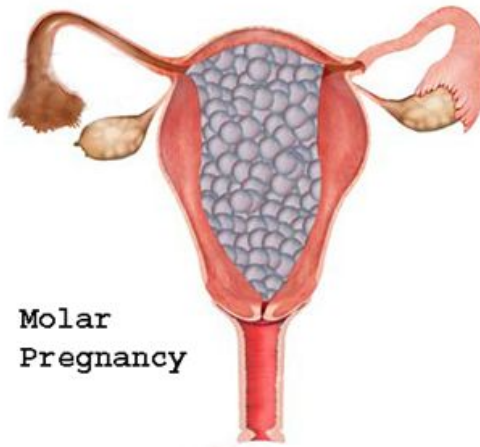

Complete mole fertilization:

- 90% of the time, a single sperm of 23 chromosomes fertilizes an egg that has lost its chromosomes. It then duplicates resulting in 46XX (all paternal)
- 10% of cases are 46 XY as a result of fertilization of an empty ovum by 2 sperm (dispermy)

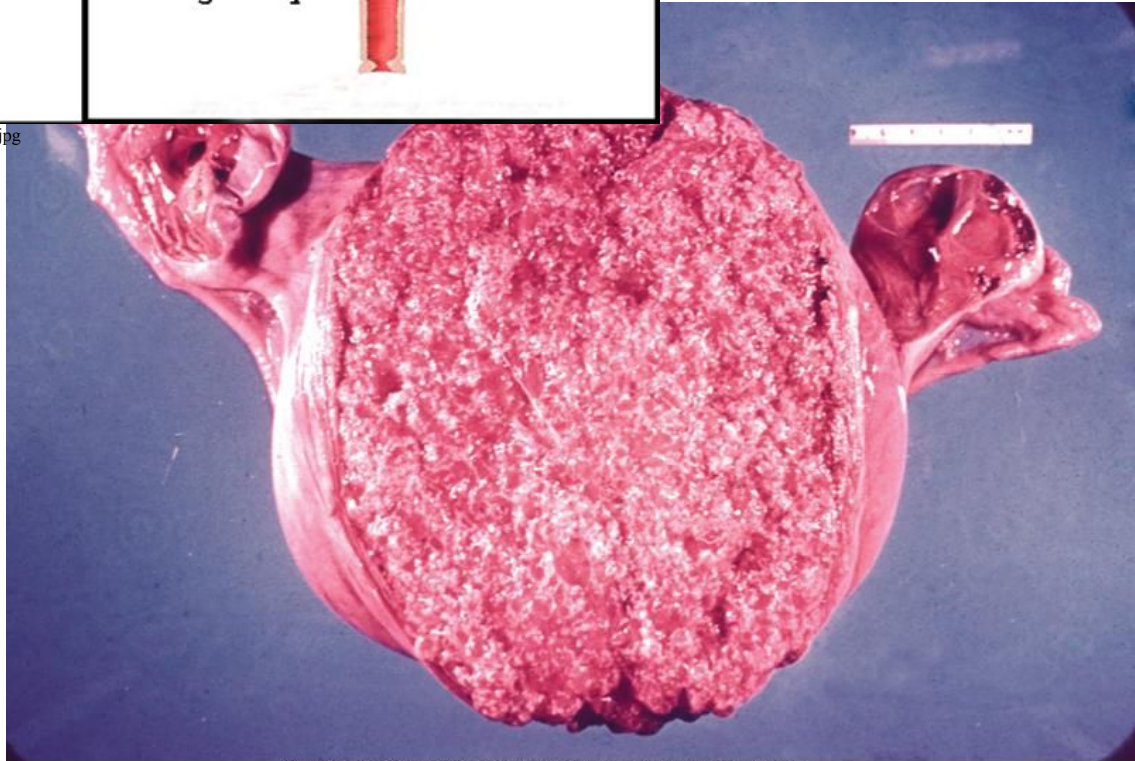


Normal
Uterus




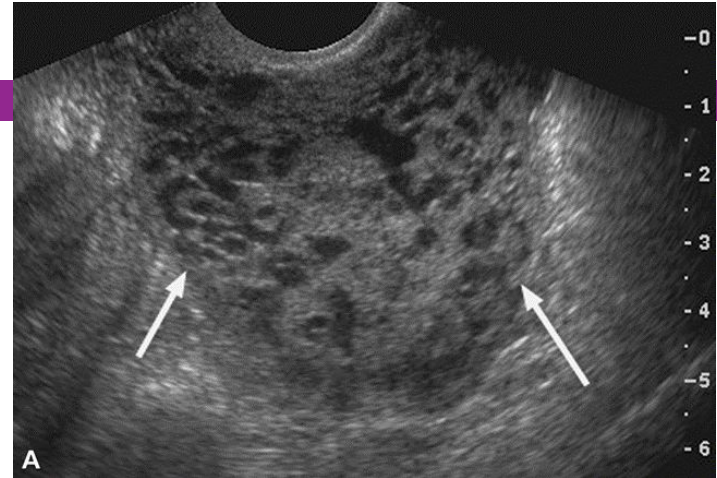
Molar
Pregnancy

<http://lakecharlesobgyn.com/Images/molar-pregnancy-1.jpg>



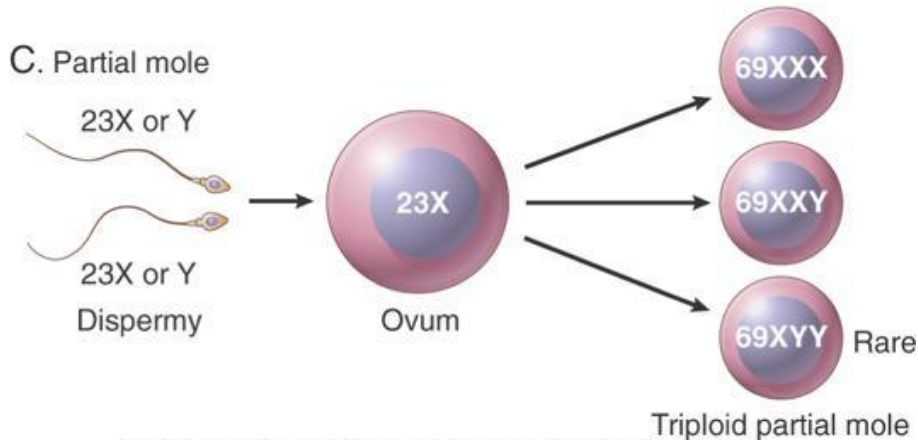
Complete HM.

- ▶ **Ultrasound:** will show a “cluster of grapes” appearance or a “snowstorm” appearance, signifying an abnormal placenta.
- ▶ **Treatment:** Evacuation of uterus by curettage and sometimes chemotherapy. With appropriate therapy cure rate is very high.
- ▶ **Complications:** uterine hemorrhage, uterine perforation, trophoblastic embolism, and infection. Few patients develop an invasive mole. The most important complication is the development of choriocarcinoma, which occurs in about 2% of patients after the mole has been evacuated.



Partial Mole (PM)

- Partial hydatidiform mole results from fertilization of a normal ovum (that has not lost its maternal chromosome) by 2 normal sperms. This results in a triploid cell having 69 chromosomes (triploidy gestation), of which one haploid set (23X) is maternal and two haploid ($23+23=46$) sets are paternal in origin.
- It is a genetically abnormal placenta with a resultant mixture of large and small villi with slight hyperplasia of the trophoblasts, filling the uterus. In contrast to a complete mole, embryo/fetal parts may be present. But the fetus associated with a partial mole usually dies after 10 weeks' gestation and the mole (~pregnancy) is aborted shortly thereafter.
- It almost never evolves into choriocarcinoma.
- Grossly the genetically abnormal placenta has a mixture of large chorionic villi and normal-appearing smaller villi.



Kumar et al: Robbins & Cotran Pathologic Basis of Disease, 8th Edition.
Copyright © 2009 by Saunders, an imprint of Elsevier, Inc. All rights reserved.

Partial mole fertilization:

- This results from fertilization of a normal single ovum/egg (23X) by two normal spermatozoa, each carrying 23 chromosomes, or by a single spermatozoon that has not undergone meiotic reduction and bears 46 chromosomes (the pregnancy has too much paternal DNA).
- 58% are 69XXY
- 40% are 69XXX
- 2% are 69XYY

Partial Mole (PM)

- It makes up 15–35% of all moles
- Uterine size usually small or appropriate for gestational age
- Serum HCG levels are high but not as high as complete mole.
- Chromosomal analysis of partial moles shows 69XXY in majority of cases (i.e. 3 haploid sets also called as triploidy).
- Treatment : Evacuation of uterus by curettage and sometimes chemotherapy.
- Prognosis: Risk for development of choriocarcinoma

FEATURE	CM	PM
Karyotype	Usually diploid 46XX	Usually triploidy 69XXY (most common)
Villi	All villi are hydropic; no normal villi seen	Normal villi may be present
Fetal tissue	Not present	Usually present
Trophoblasts	Marked proliferation	Mild proliferation
Serum HCG	Markedly elevated	Less elevated
Invasive mole	Occurs in about 15% of CMs	Very rare
Behavior	2% progress to choriocarcinoma	Very rarely progress to choriocarcinoma

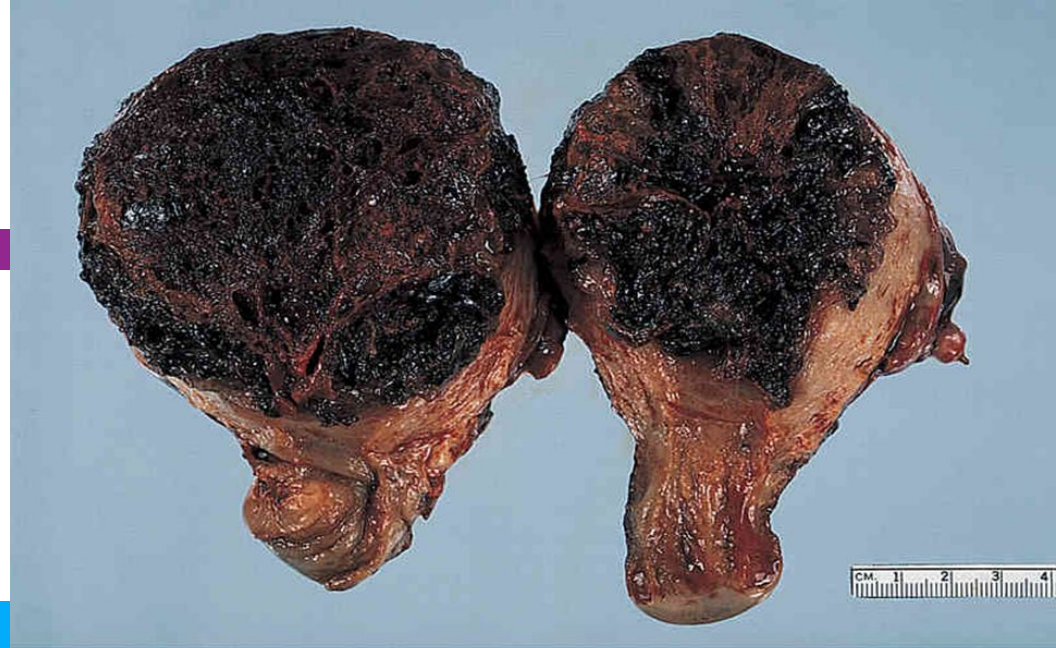2. Invasive Mole

- Invasive mole is when the villi of a hydatidiform mole extends/infiltrates into the myometrium of the uterus.
- The mole sometime enter into the veins in the myometrium, and a times spread via the vascular channels to distant sites, mostly the lungs (note: death from such spread is unusual).
- It occurs in about 15% of complete moles and rarely in partial mole.
- Can cause hemorrhage and uterine perforation.

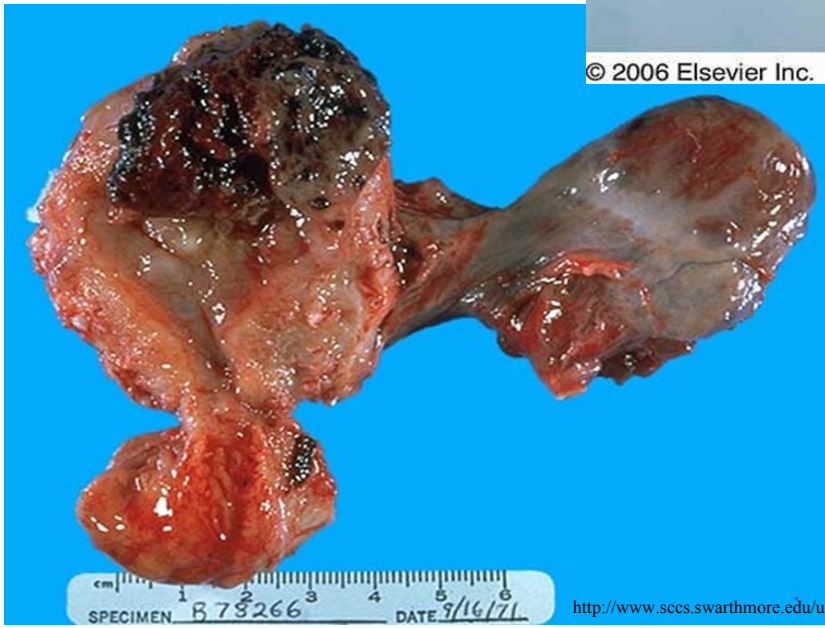
3. Choriocarcinoma

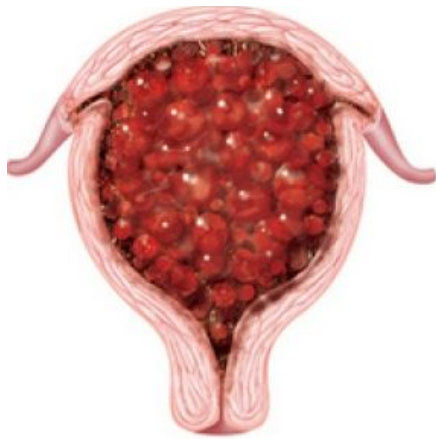- Definition: Malignant tumor of placental tissue, composed of a proliferation of malignant cytotrophoblast and syncytiotrophoblast, without villi formation.
- It is an aggressive malignant neoplasm.
- It is characterized by very high levels of serum HCG.
- Choriocarcinomas are aneuploidic.
- It spreads early via blood to the lungs and other organs.
- Responds to chemotherapy
- About half the choriocarcinoma are preceded by complete hydatidiform mole . Others can be preceded by partial mole (rare), abortion, ectopic pregnancy and occasionally normal term pregnancy.

CHORIOCARCINOMA

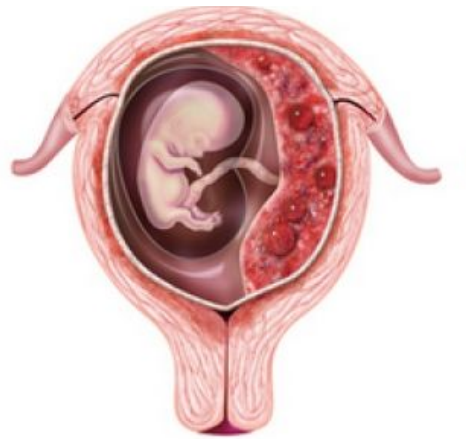

© 2006 Elsevier Inc.

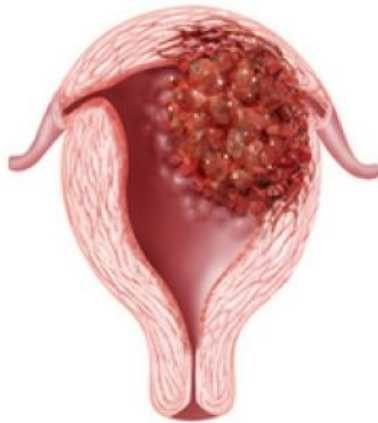



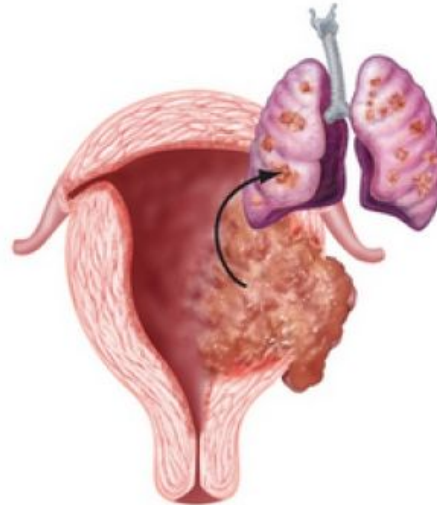
Complete hydatidiform mole



Partial hydatidiform mole



Invasive mole



Choriocarcinoma