

Congenital malformations and hydrocephalus

Pathology

Congenital malformations

- The incidence of CNS malformations, giving rise to mental retardation, cerebral palsy, or neural tube defects, is estimated at 1% to 2%
- Malformations of the brain are more common in the setting of **multiple** birth defects

Congenital malformations

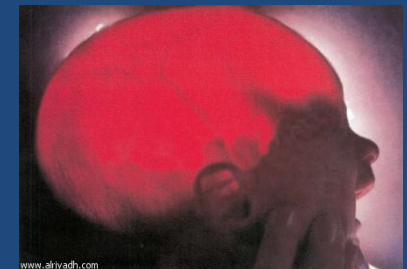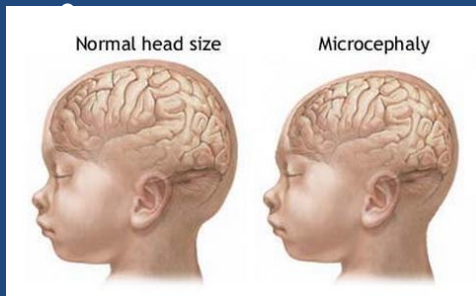
- Because different parts of the brain develop at different times during gestation (and afterwards), the timing of an injury will be reflected in the pattern of malformation
- Prenatal or perinatal insults may either cause:
 - failure of normal CNS development
 - tissue destruction

Congenital malformations

- Although the pathogenesis and etiology of many malformations remain unknown, both genetic and environmental factors are clearly at play:
 - **CNS malformation can be caused by Mutations** affecting molecules in pathways of neuronal and glial:
 - Development
 - Migration
 - connection
 - toxic compounds
 - infectious agents

Forebrain Malformations

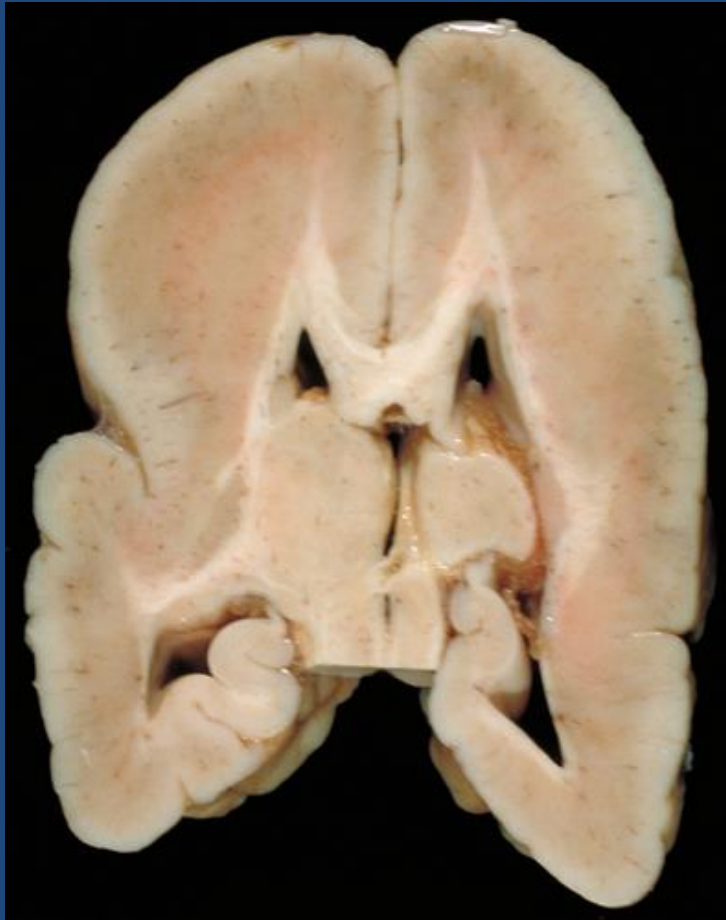- The volume of brain may be abnormally large (*megalencephaly*) or small (*microencephaly, more common*). Microencephaly, is usually associated with a small head as well
- They can occur in a wide range of clinical settings, including:
 - chromosome abnormalities
 - fetal alcohol syndrome
 - human immunodeficiency virus 1 (HIV-1) infection acquired in utero
- All causes are associated with a decreased number of neurons destined for the cerebral cortex. Disruption of normal neuronal migration and differentiation during development can lead to a disruption of the normal gyration and six-layered neocortical architecture



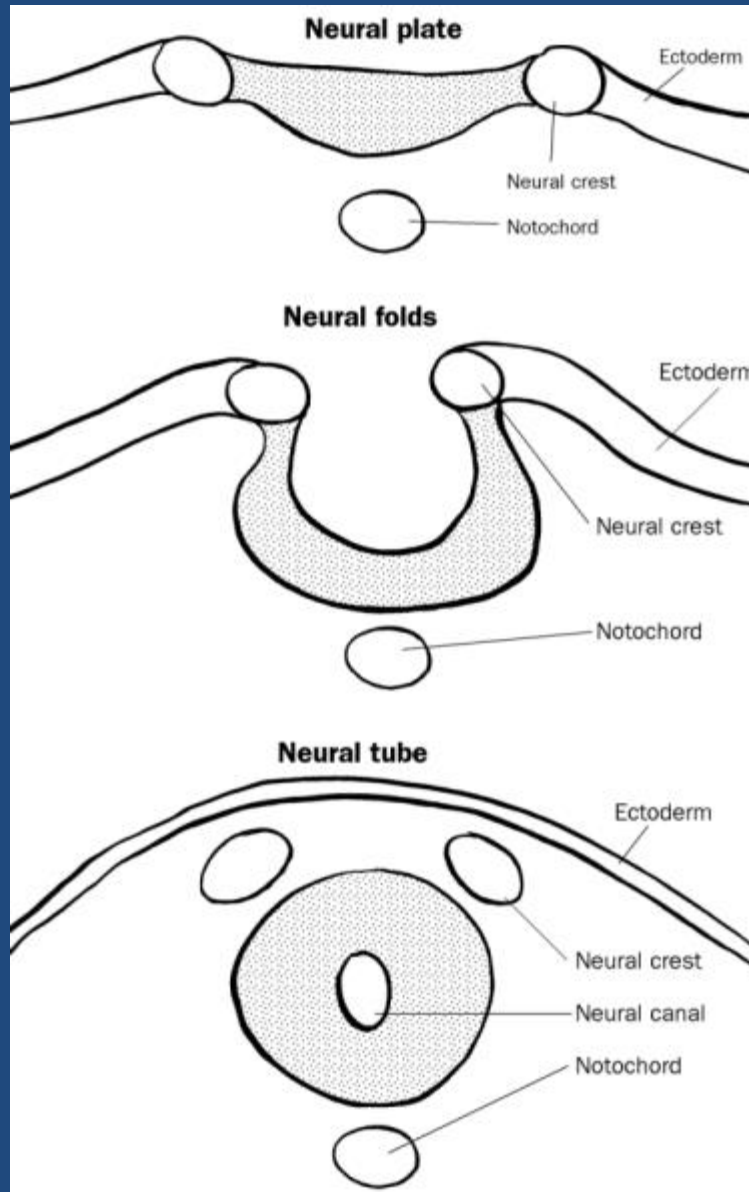
Forebrain Malformations

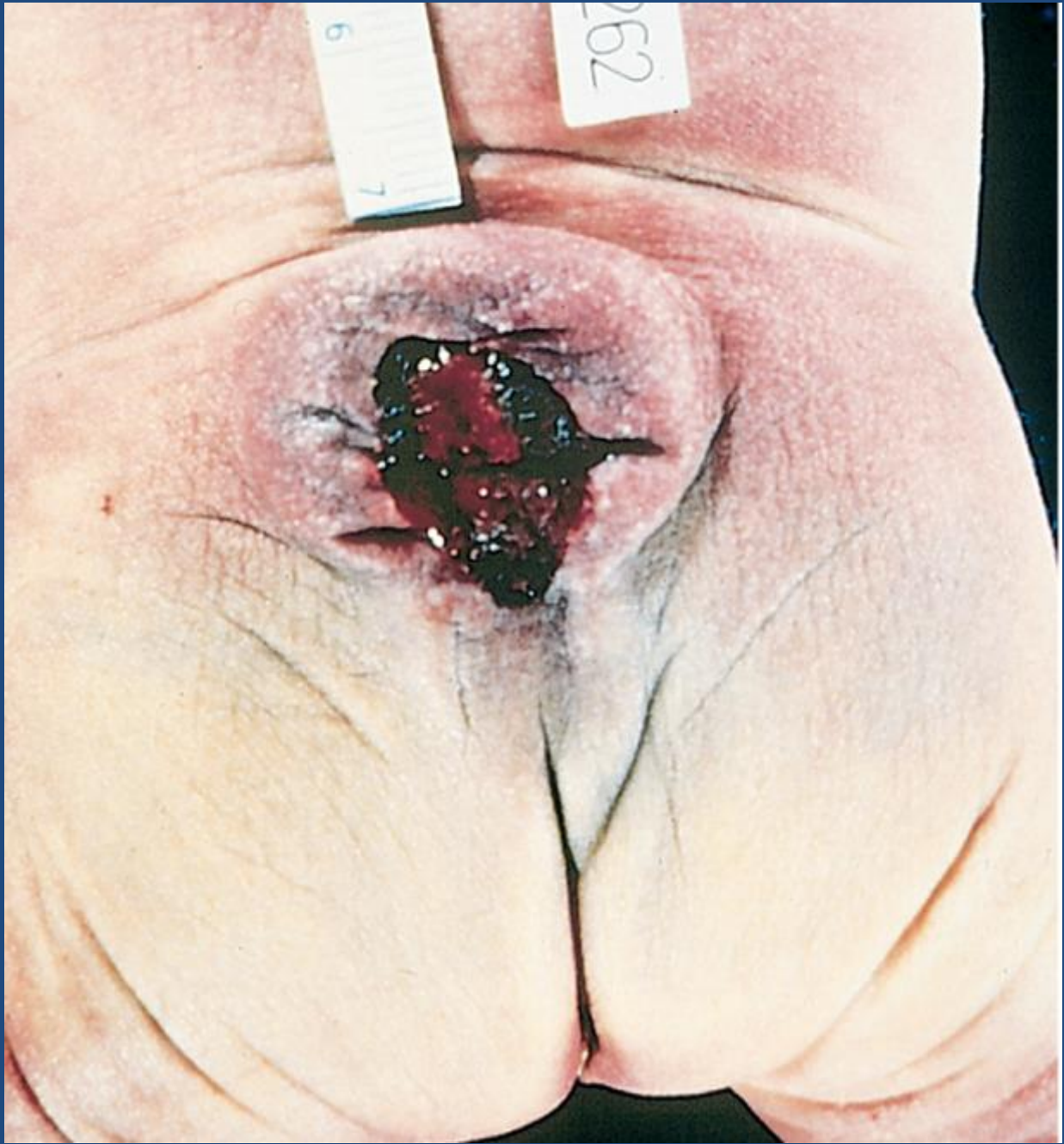- *Lissencephaly (agyria)* or, in case of more patchy involvement, *pachygyria* is characterized by an absence of normal gyration and a smooth-surfaced brain
 - The cortex is abnormally thickened and is usually only four-layered
 - Single-gene defects have been identified in some cases of lissencephaly.

Forebrain Malformations



- Cortical sulci are absent except, usually, for the Sylvian fissure
- The cortex is thick and consists of the molecular and three neuronal layers
- The deepest of these layers is also the thickest and most cellular, presumably comprised of neurons that migrated a certain distance from the ventricles but failed to reach their normal destinations
- There is a small amount of myelinated white matter between the abnormal cortex and the ventricles





Neural tube defect

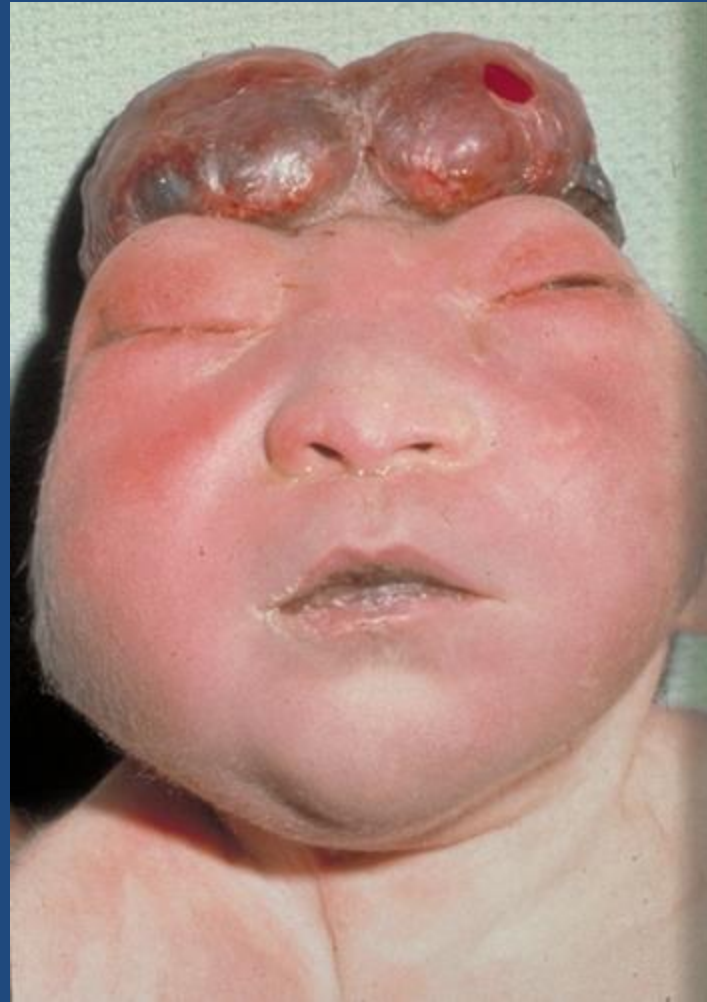- Among the earliest stages in brain development is the formation of the neural tube, the inside of which will become the ventricular system and the wall of which will become the brain and spinal cord
- Failure of a portion of the neural tube to close, or reopening after successful closure, may lead to one of several malformations. All are characterized by abnormalities involving some combination of neural tissue, meninges, and overlying bone or soft tissues
- Collectively, neural tube defects are the most frequent CNS malformations

Neural tube defect

- Folate deficiency during the initial weeks of gestation is a risk factor;
 - prenatal vitamins are aimed, in part, at reducing this risk
- The combination of ultrasound and maternal screening for elevated α -fetoprotein has increased the early detection of neural tube defects
- The overall recurrence risk in subsequent pregnancies is 4% to 5%

Neural tube defect

- *Myelomeningocele* is an extension of CNS tissue through a defect in the vertebral column
- They occur most commonly in the lumbosacral region
- patients have motor and sensory deficits in the lower extremities and problems with bowel and bladder control
- The symptoms derive from the abnormal spinal cord in this region, and are often compounded by infections extending from thin or ulcerated overlying skin

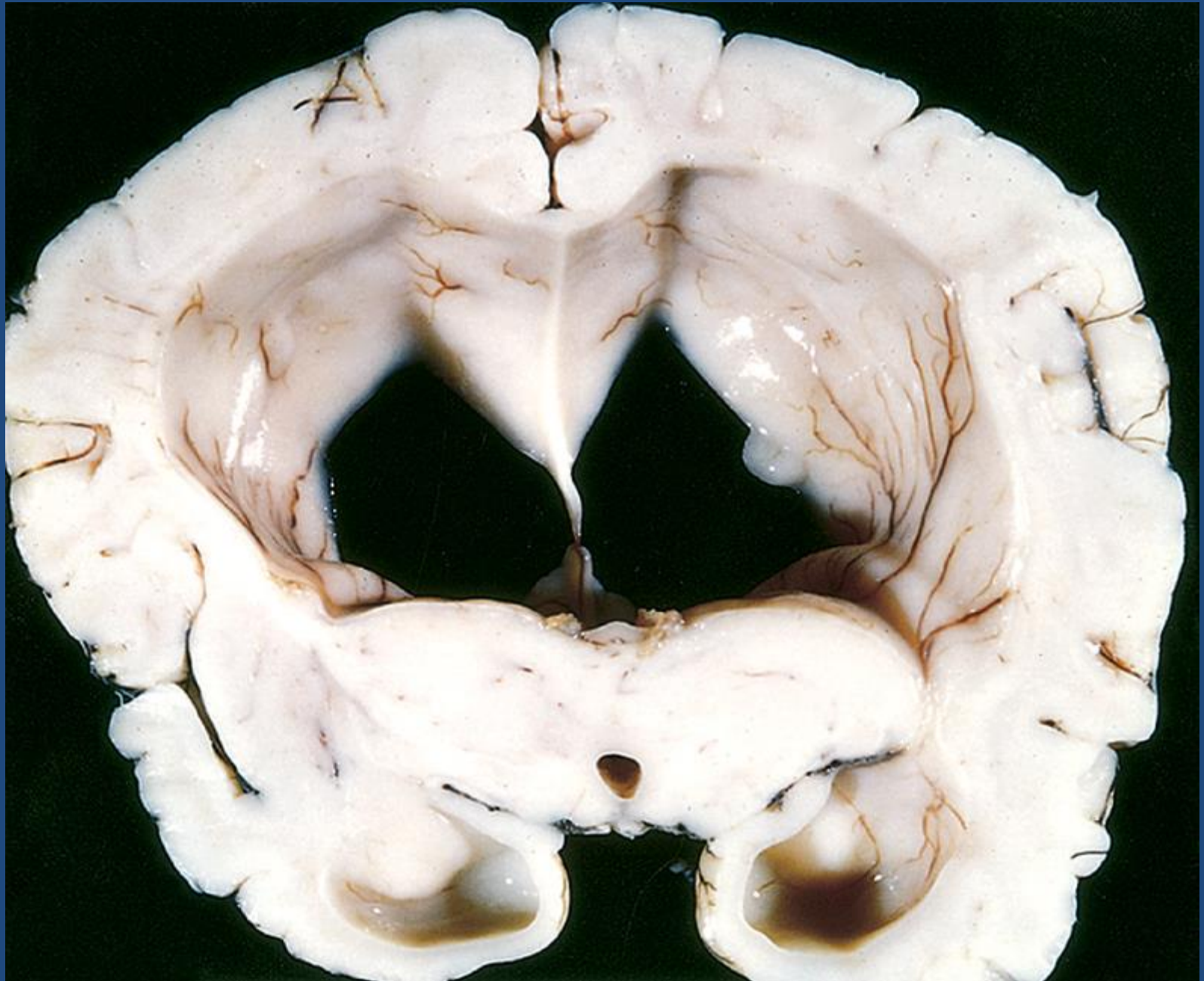


Neural tube defect

- At the other end of the developing brain, *anencephaly* is a malformation of the anterior end of the neural tube, with absence of the brain and top of skull
- An *encephalocele* is a diverticulum of malformed CNS tissue extending through a defect in the cranium
 - It most often involves the occipital region or the posterior fossa

Posterior Fossa Anomalies

- The most common malformations in this region of the brain result in either misplaced or absent cerebellum
- Typically, these are associated with hydrocephalus
- The *Arnold-Chiari malformation* (Chiari type II malformation) consists of:
 - a small posterior fossa
 - a misshapen midline cerebellum
 - downward extension of *vermis* through the foramen magnum
 - Hydrocephalus
 - a lumbar myelomeningocele



Hydrocephalus

- After being produced by the choroid plexus within the ventricles, cerebrospinal fluid (CSF) circulates through the ventricular system and exits through the foramina of Luschka and Magendie
- CSF fills the subarachnoid space around the brain and spinal cord, contributing to the cushioning of the nervous system within its bony confines
- The arachnoid granulations are responsible for the resorption of CSF
- The balance between CSF generation and resorption keeps the volume of this fluid stable

Hydrocephalus

- *Hydrocephalus* refers to the accumulation of excessive CSF within the ventricular system
- Most cases occur as a consequence of impaired flow or impaired resorption of CSF
- In rare instances (e.g., tumors of the choroid plexus), overproduction of CSF may be responsible

Hydrocephalus

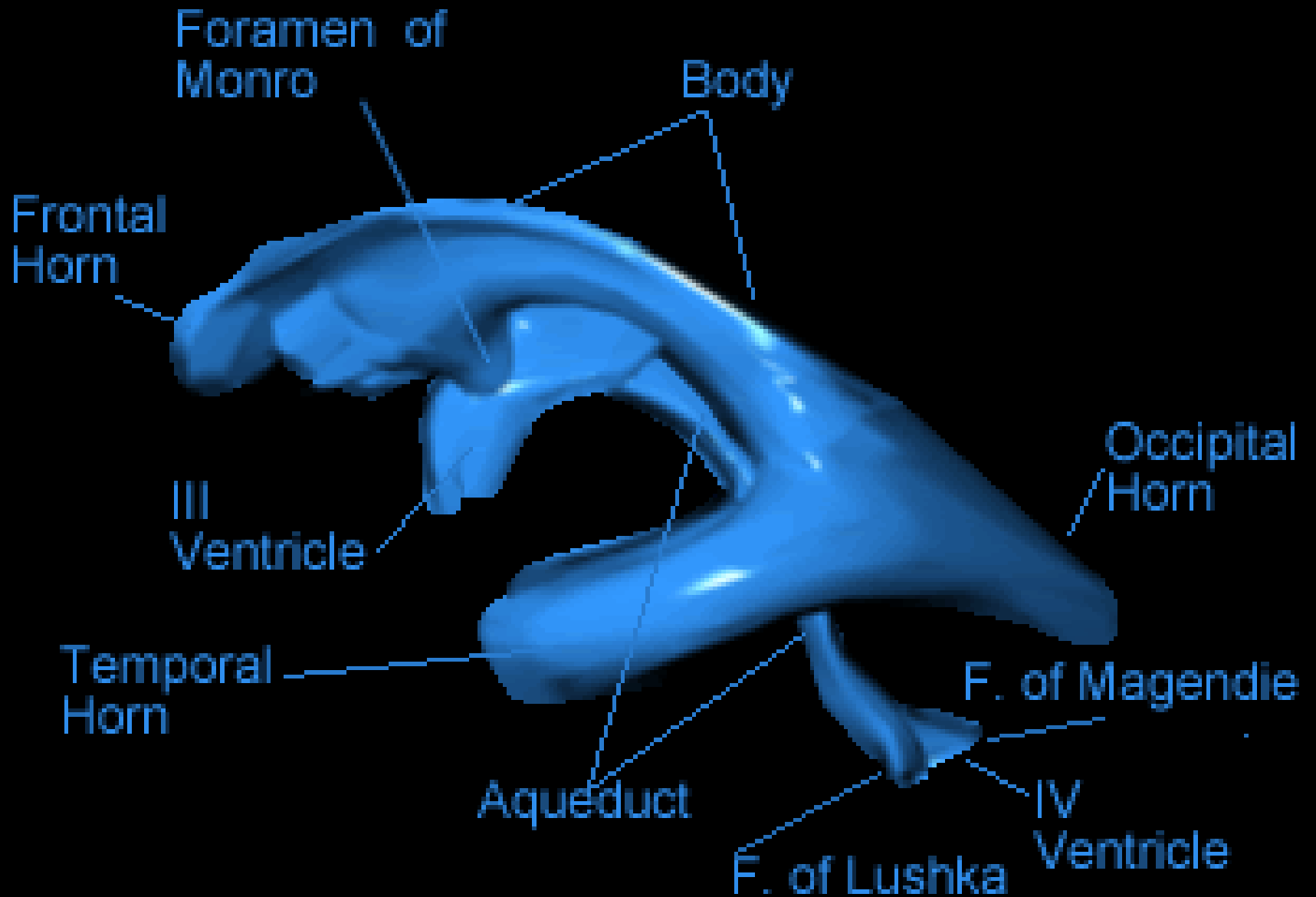
- When hydrocephalus develops in infancy before closure of the cranial sutures → enlargement of the head
- Hydrocephalus developing after fusion of the sutures → expansion of the ventricles and increased intracranial pressure, without a change in head circumference

Hydrocephalus

- If there is an obstacle to the flow of CSF within the ventricular system, then a portion of the ventricles enlarges while the remainder does not → *noncommunicating hydrocephalus*
 - most commonly seen with masses at the foramen of Monro or aqueduct of Sylvius
- In *communicating hydrocephalus* all of the ventricular system is enlarged; here the cause is most often reduced resorption of CSF

What can cause hydrocephalus?

- **Hypersecretion of CSF:** e.g. choroid plexus tumor
- **Obstructive hydrocephalus**
 - Obstruction of the foramina of Monro e.g. colloid cyst
 - Obstruction of the third ventricle e.g. pilocytic astrocytoma
 - Obstruction of the aqueduct e.g. aqueductal stenosis or atresia and posterior fossa tumors
 - Obstruction of the foramina of Luschka or impairment of flow from the fourth ventricle (Chiari malformation, meningitis, subarachnoid hemorrhage, posterior fossa tumors)
 - Fibrosis of the subarachnoid space e.g. meningitis, subarachnoid hemorrhage, meningeal dissemination of tumors
- **Defective filtration of CSF:** postulated for low-pressure hydrocephalus



HOMework

- Define: meningocele.
- Define: polymicrogyria.
- What is the difference between microcephaly and microencephaly?
- Define: hydrocephalus ex vacuo.

