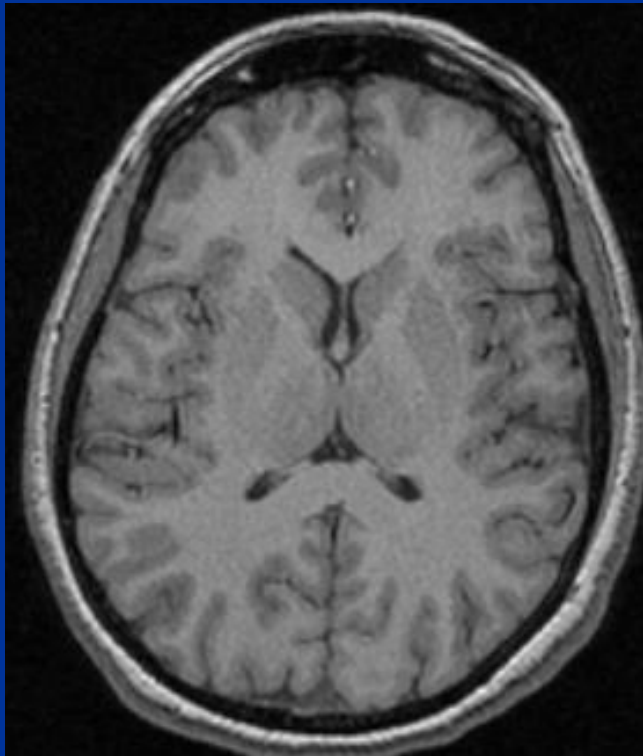


Radiology of cerebral hemispheres

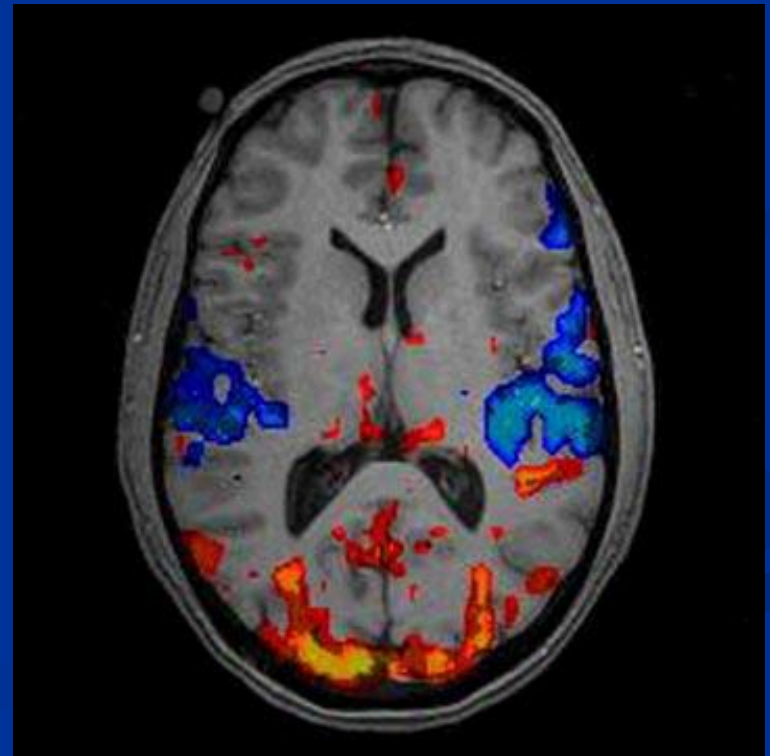
Radiology of cerebral hemispheres

- What we image?

Morphology



Function

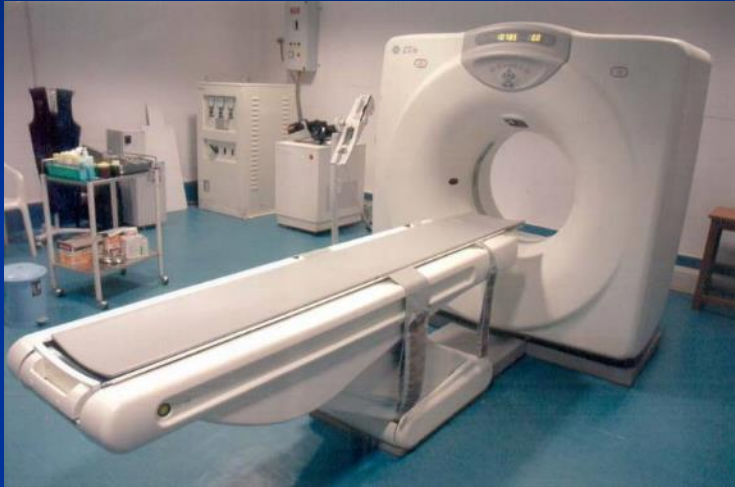

Radiology of cerebral hemispheres

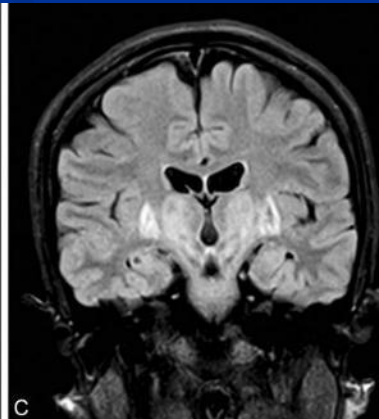
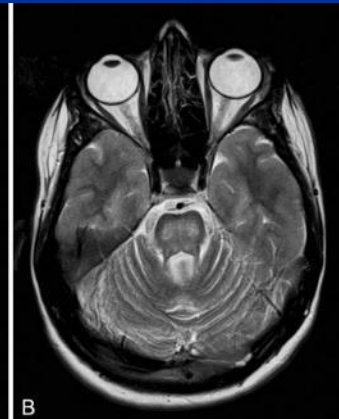
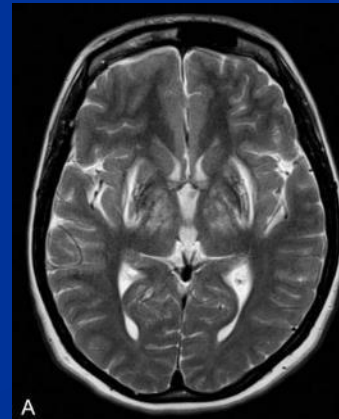
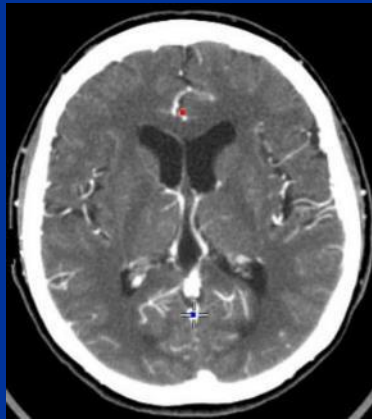
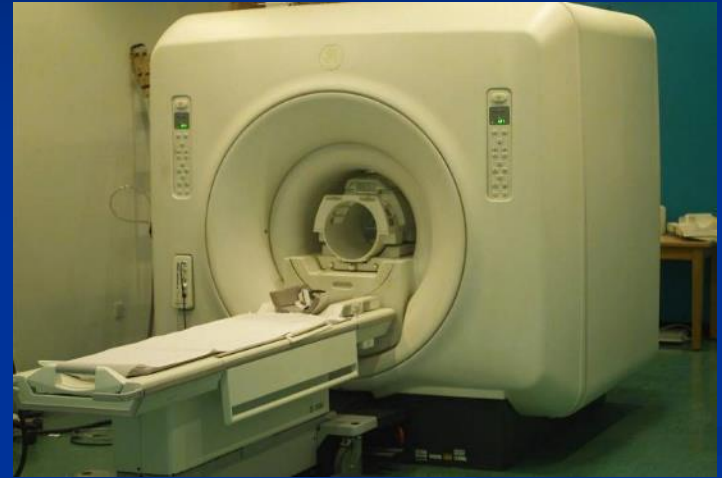Computed Tomography (CT)	Magnetic Resonance Imaging (MRI)
Ionizing Radiation	No ionizing radiation
Quick (2-3min)	Lengthy (15-20min)
Low resolution	High resolution
Single plane	Multiple planes

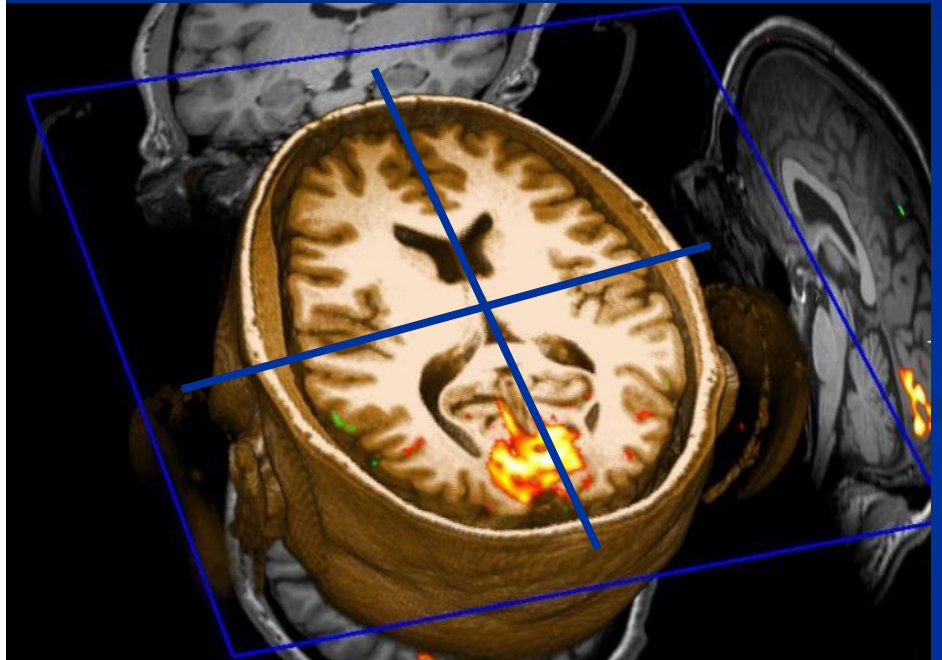
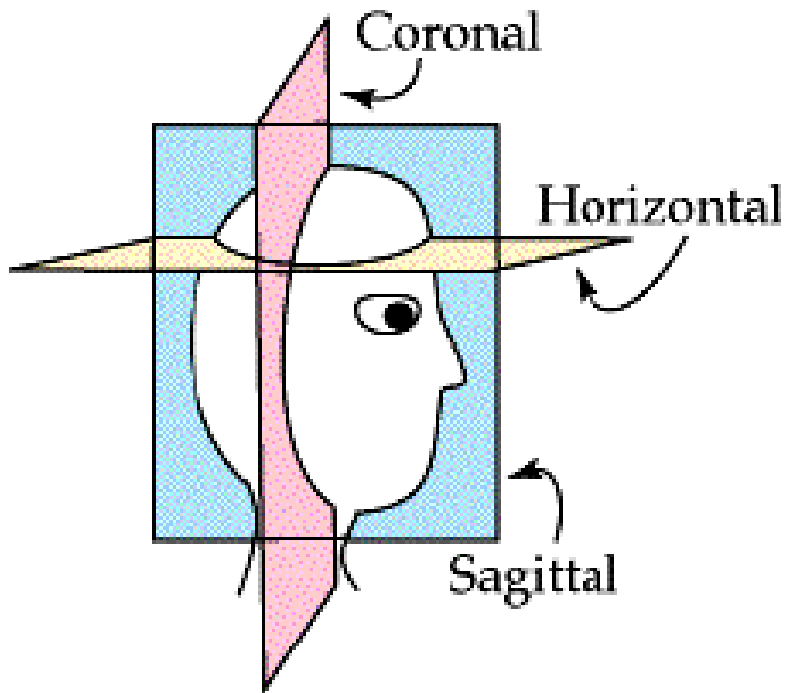
Radiology of cerebral hemispheres

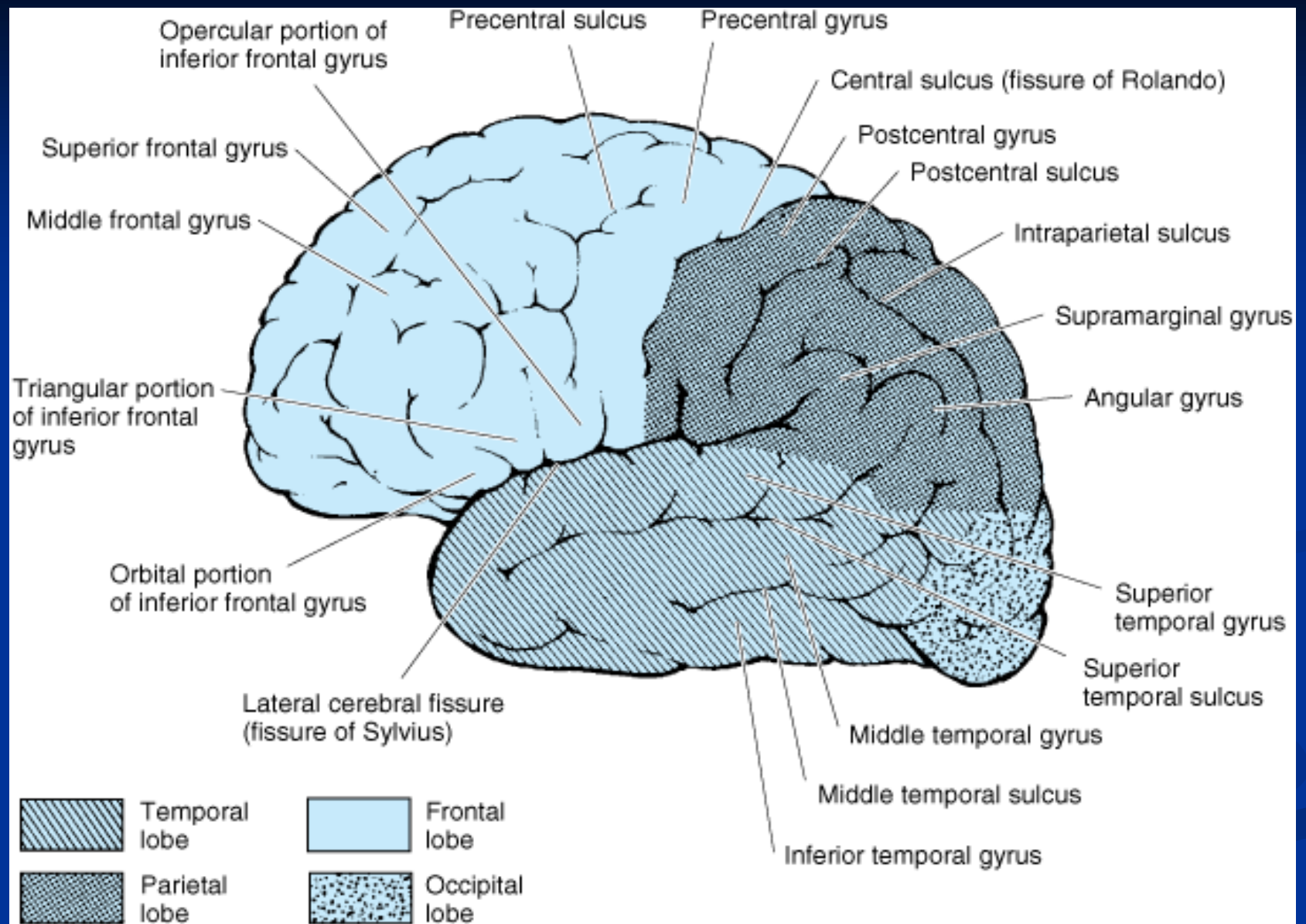
CT

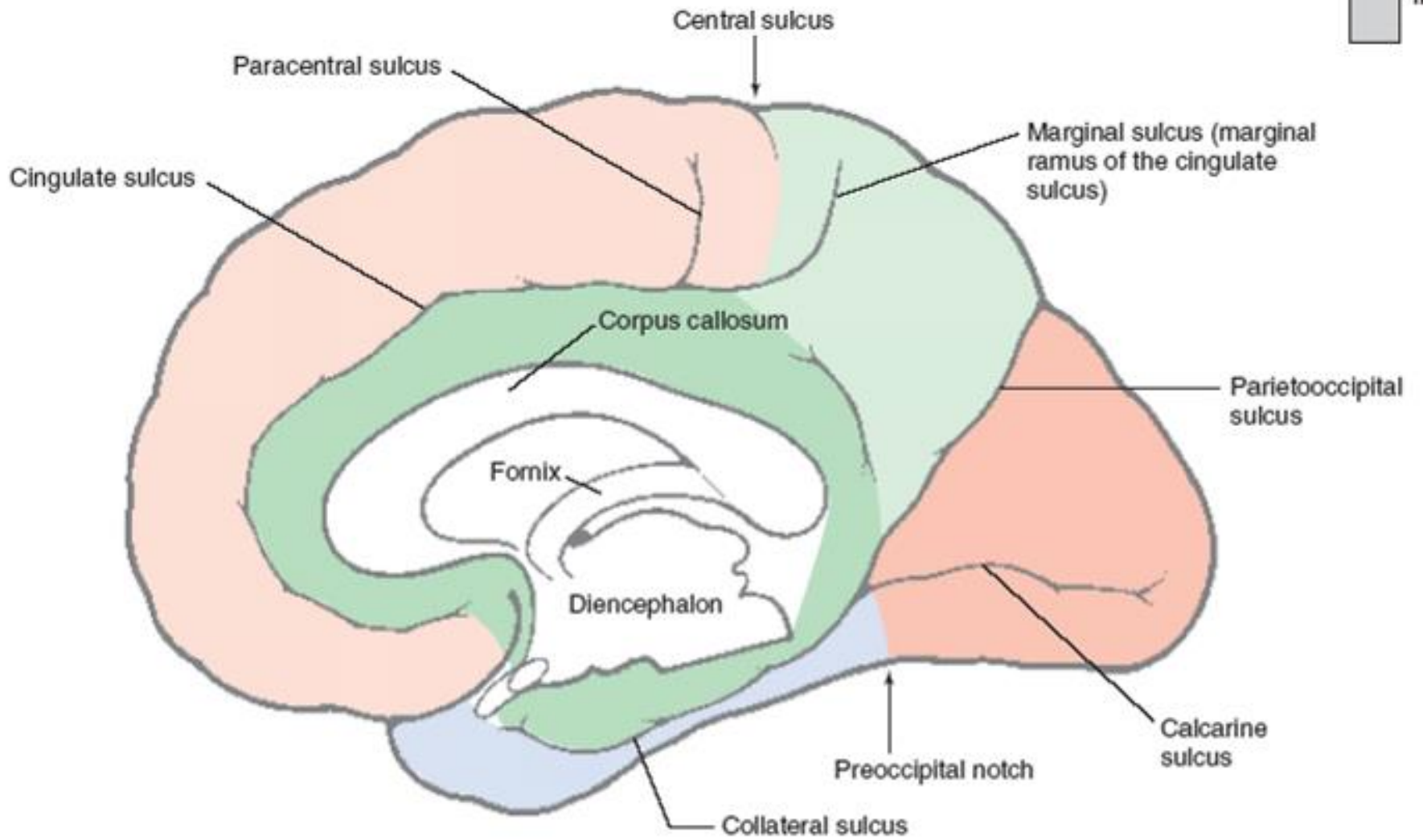


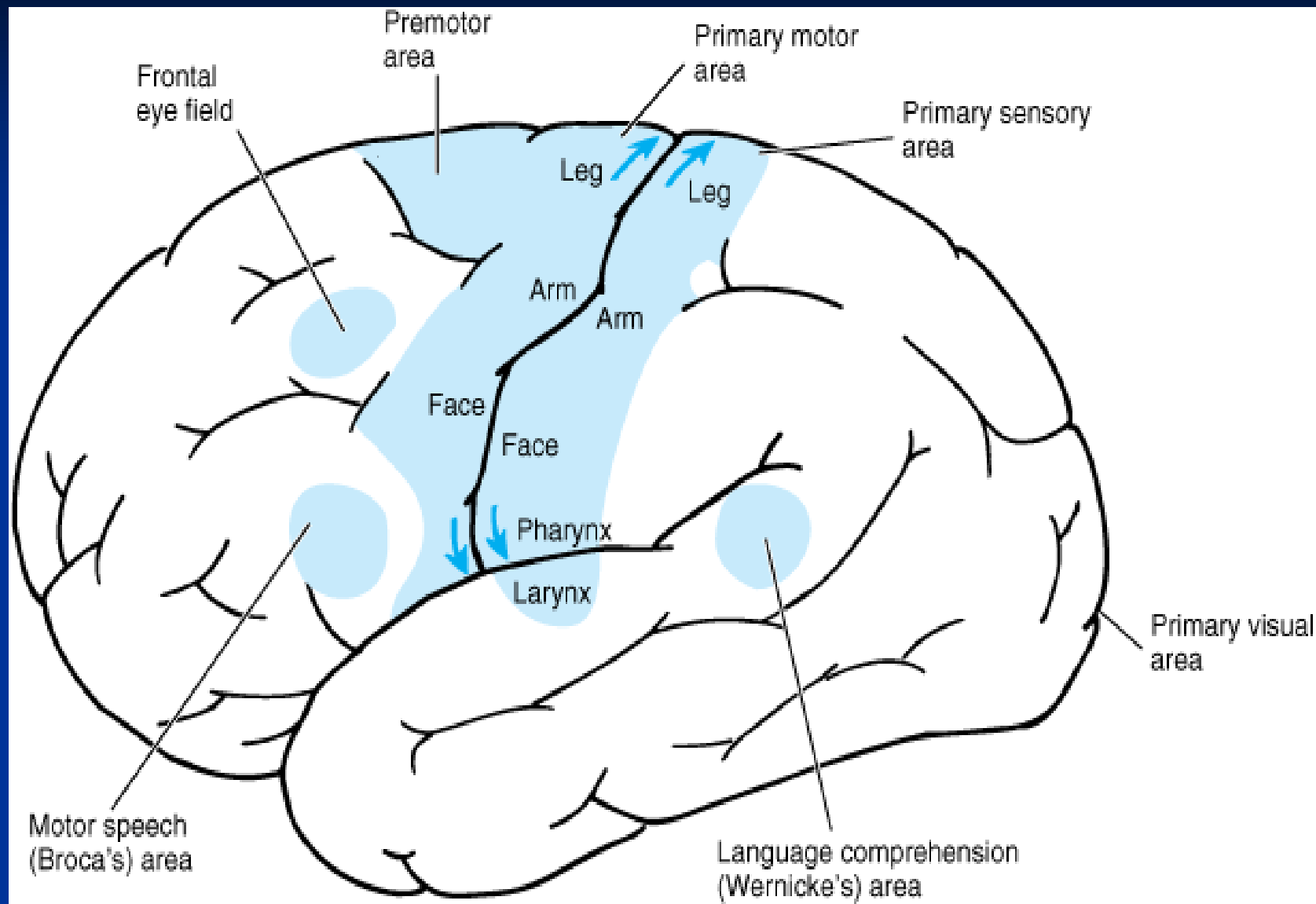
MRI

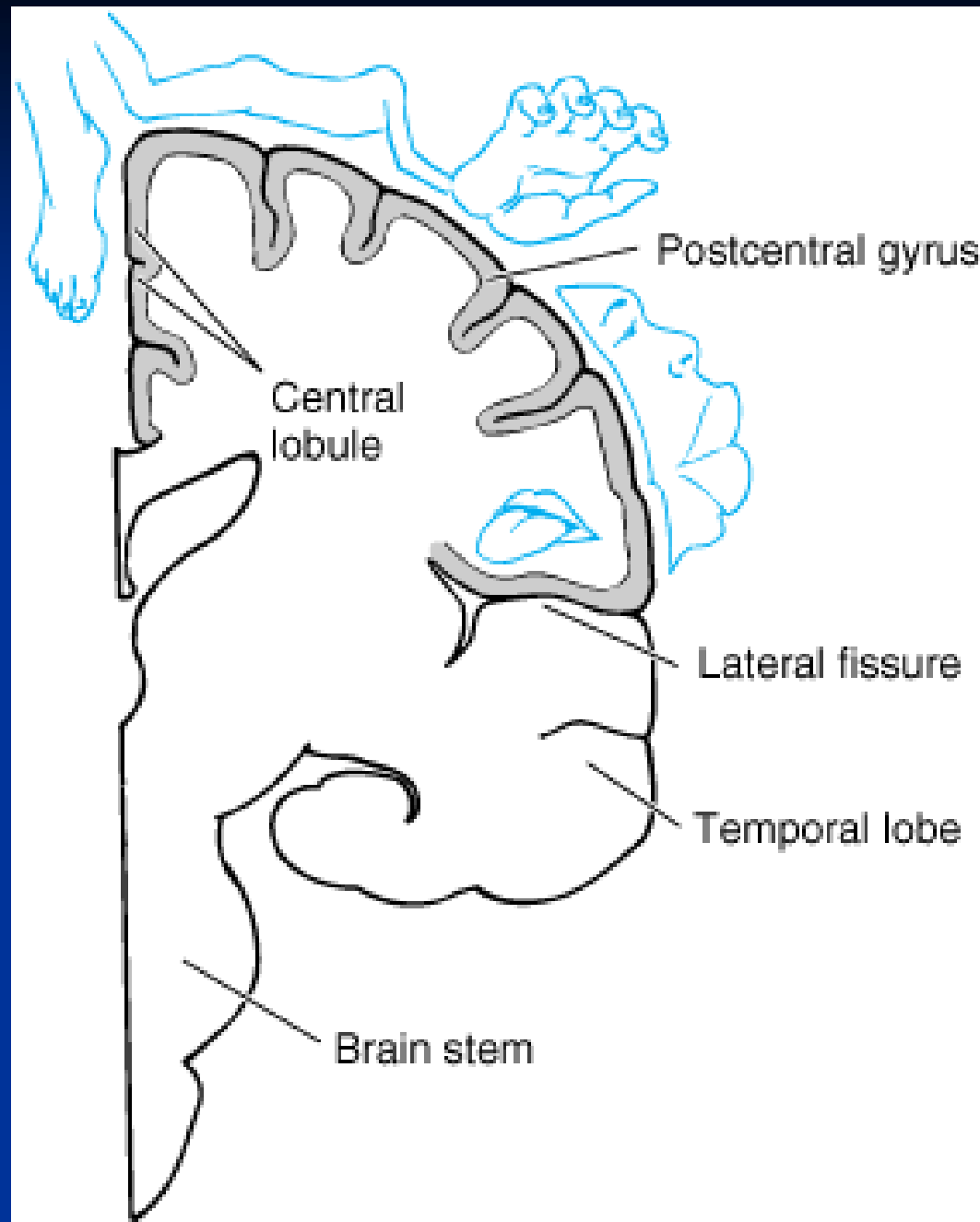






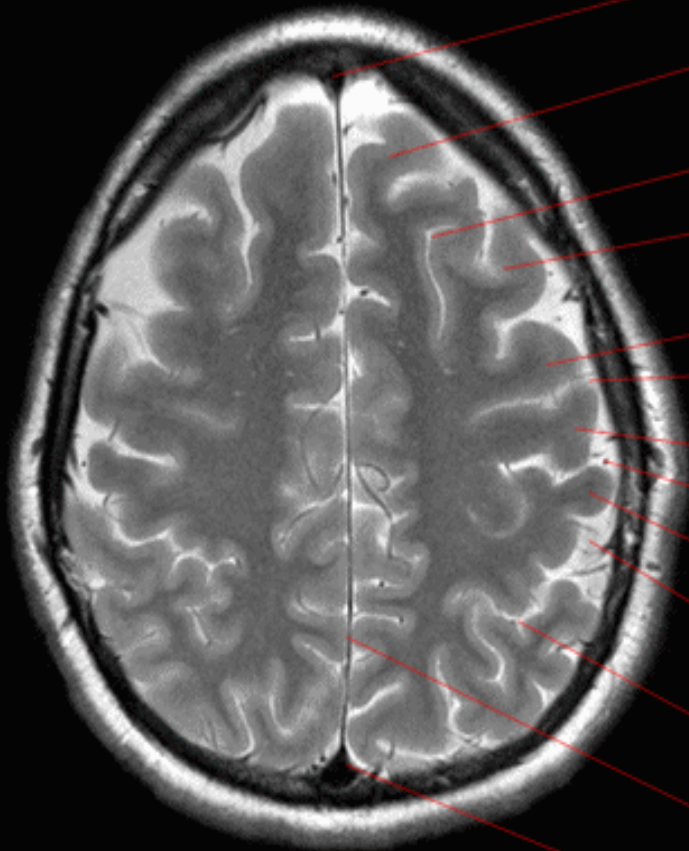




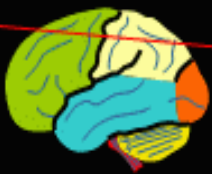


Brain

Axial T2

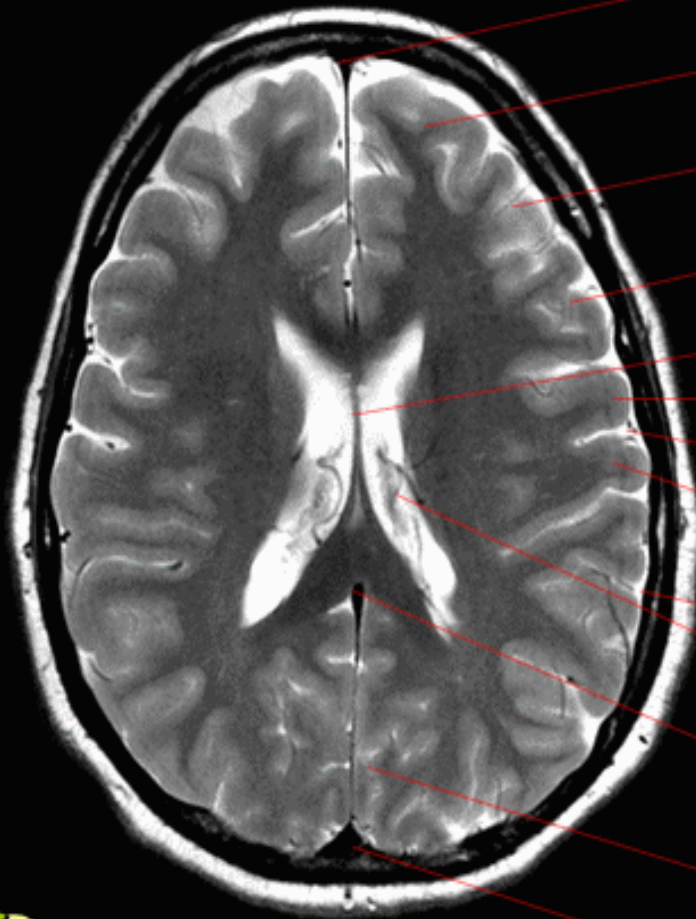


- Superior sagittal sinus
- Superior frontal gyrus
- Superior frontal sulcus
- Middle frontal gyrus
- Inferior frontal gyrus
- Precentral sulcus
- Precentral gyrus
- Central sulcus
- Postcentral gyrus
- Postcentral sulcus
- Intraparietal sulcus
- Interhemispheric fissure
- Superior sagittal sinus



Brain

Axial T2



Superior sagittal sinus

Superior frontal gyrus

Middle frontal gyrus

Inferior frontal gyrus

Septum pellucidum

Precentral gyrus

Central sulcus

Postcentral gyrus

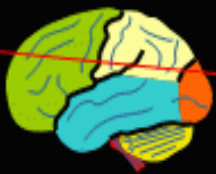
Lateral sulcus

Choroid plexus

Inferior sagittal sinus

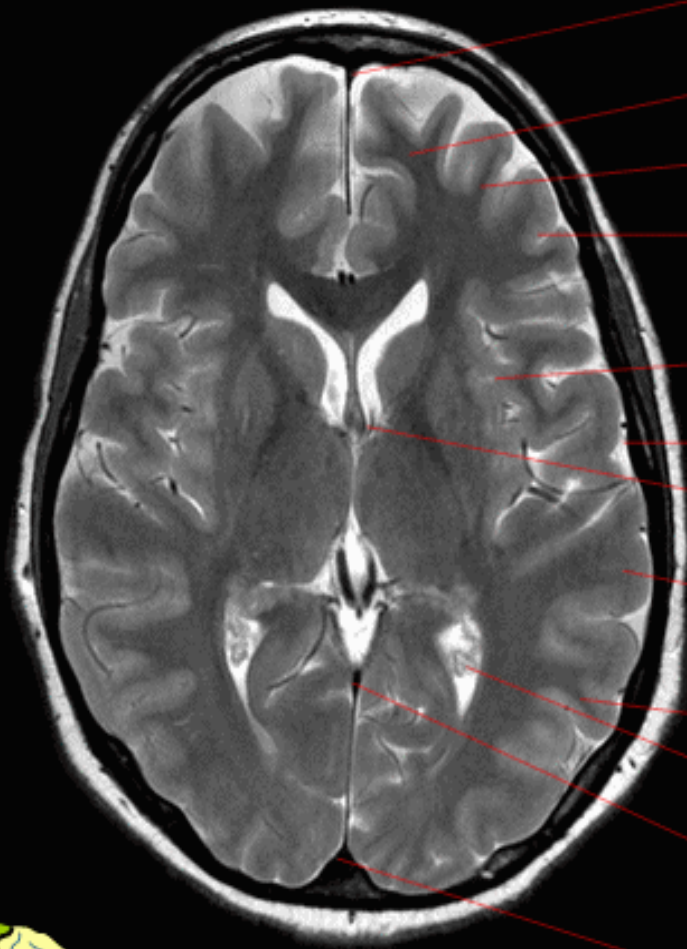
Parietooccipital sulcus

Superior sagittal sinus



Brain

Axial T2



Superior sagittal sinus

Superior frontal gyrus

Middle frontal gyrus

Inferior frontal gyrus

Insula

Lateral sulcus

Foramen of Monro

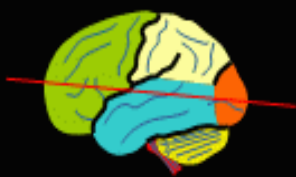
Superior temporal gyrus

Middle temporal gyrus

Choroid plexus

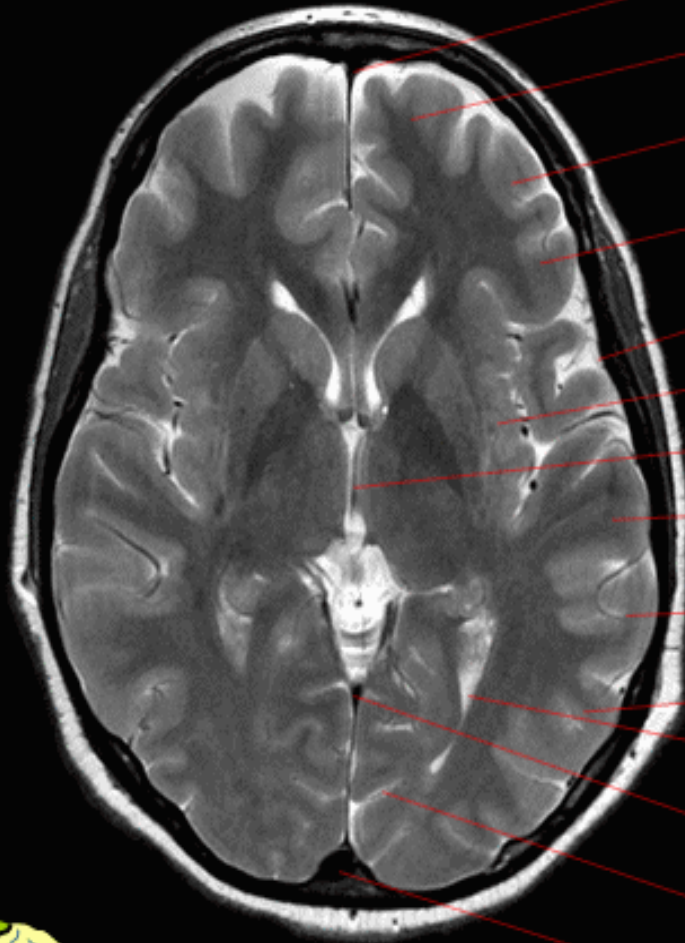
Straight sinus

Superior sagittal sinus

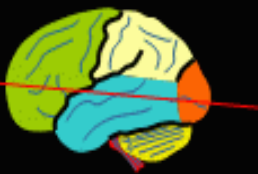


Brain

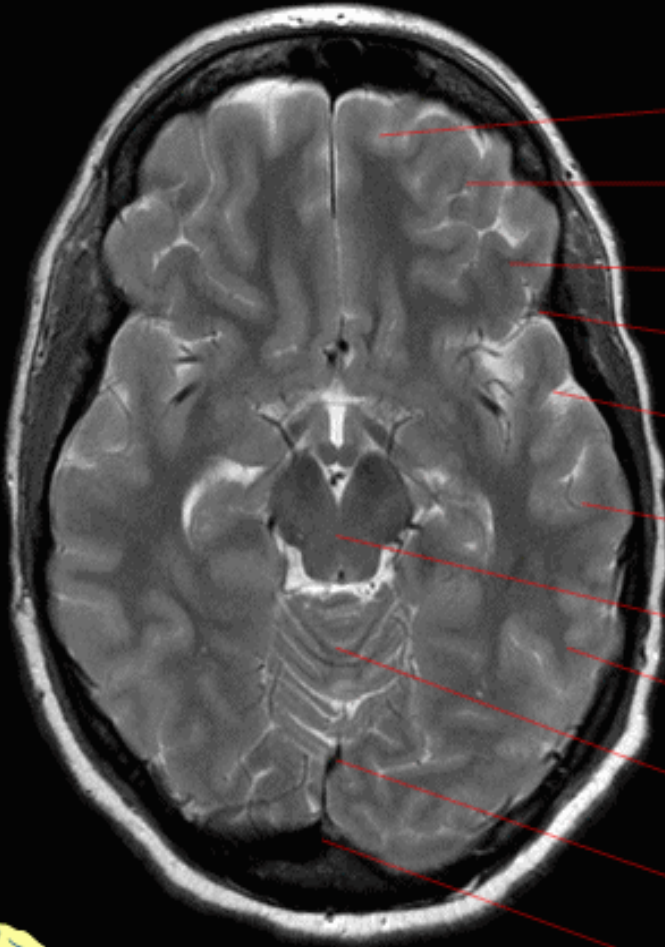
Axial T2



- Superior sagittal sinus
- Superior frontal gyrus
- Middle frontal gyrus
- Inferior frontal gyrus
- Lateral sulcus
- Insula
- Third ventricle
- Superior temporal gyrus
- Middle temporal gyrus
- Inferior temporal gyrus
- Occipital horn of lateral ventricle
- Straight sinus
- Calcarine sulcus
- Superior sagittal sinus



Brain Axial T2



Superior frontal gyrus

Middle frontal gyrus

Inferior frontal gyrus

Lateral sulcus

Superior temporal gyrus

Middle temporal gyrus

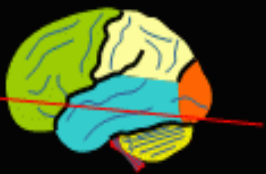
Midbrain

Inferior temporal gyrus

Vermis

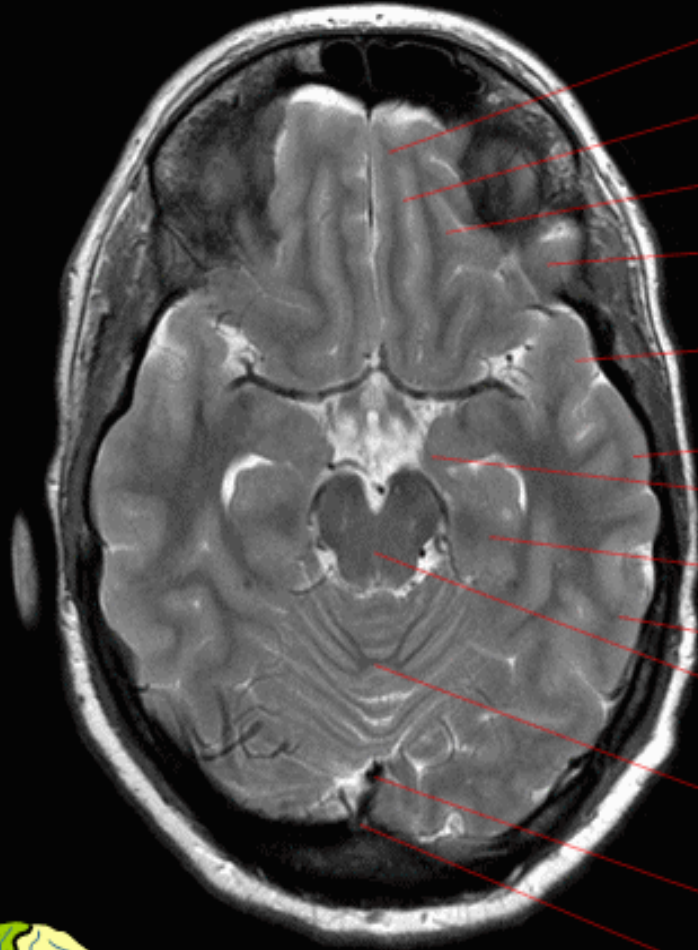
Straight sinus

Superior sagittal sinus



Brain

Axial T2



Gyrus rectus

Olfactory sulcus

Orbital gyrus

Inferior frontal gyrus

Superior temporal gyrus

Middle temporal gyrus

Uncus

Parahippocampal gyrus

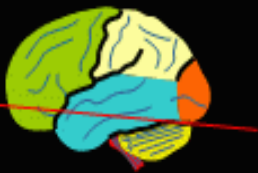
Inferior temporal gyrus

Midbrain

Vermis

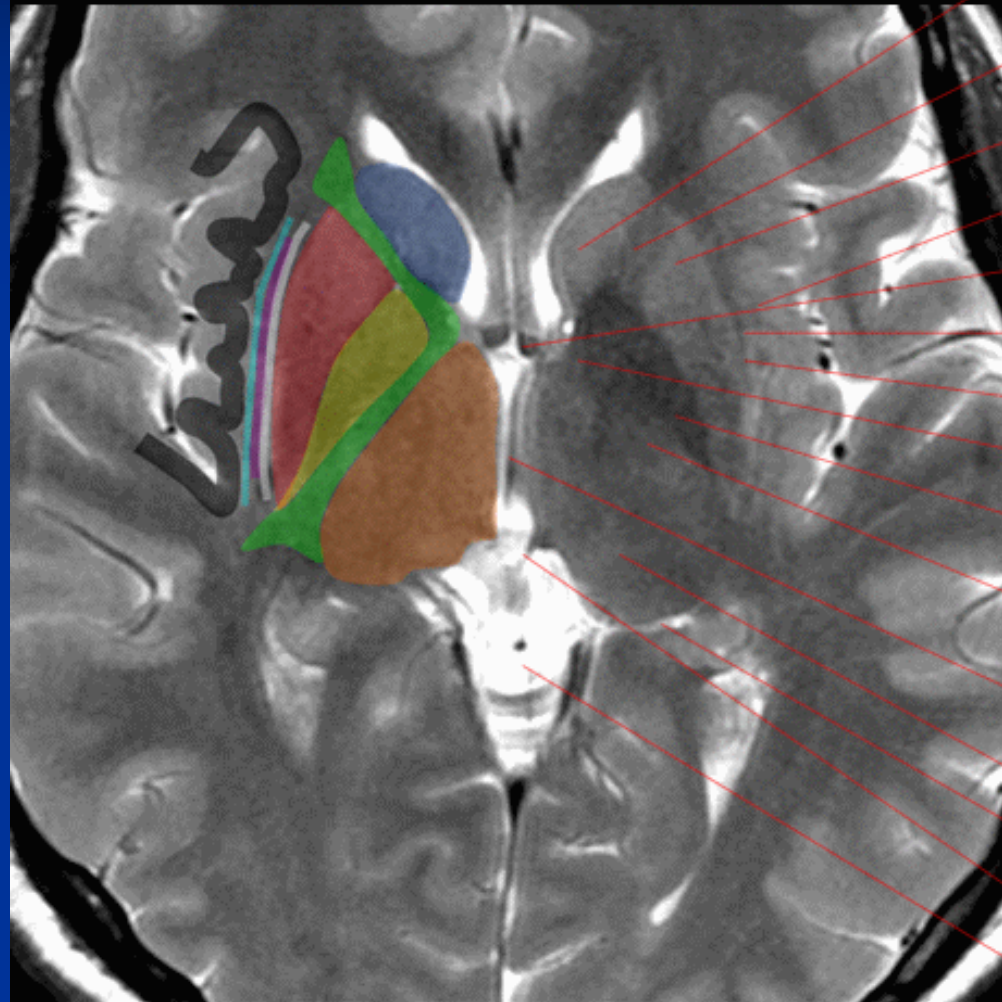
Straight sinus

Superior sagittal sinus

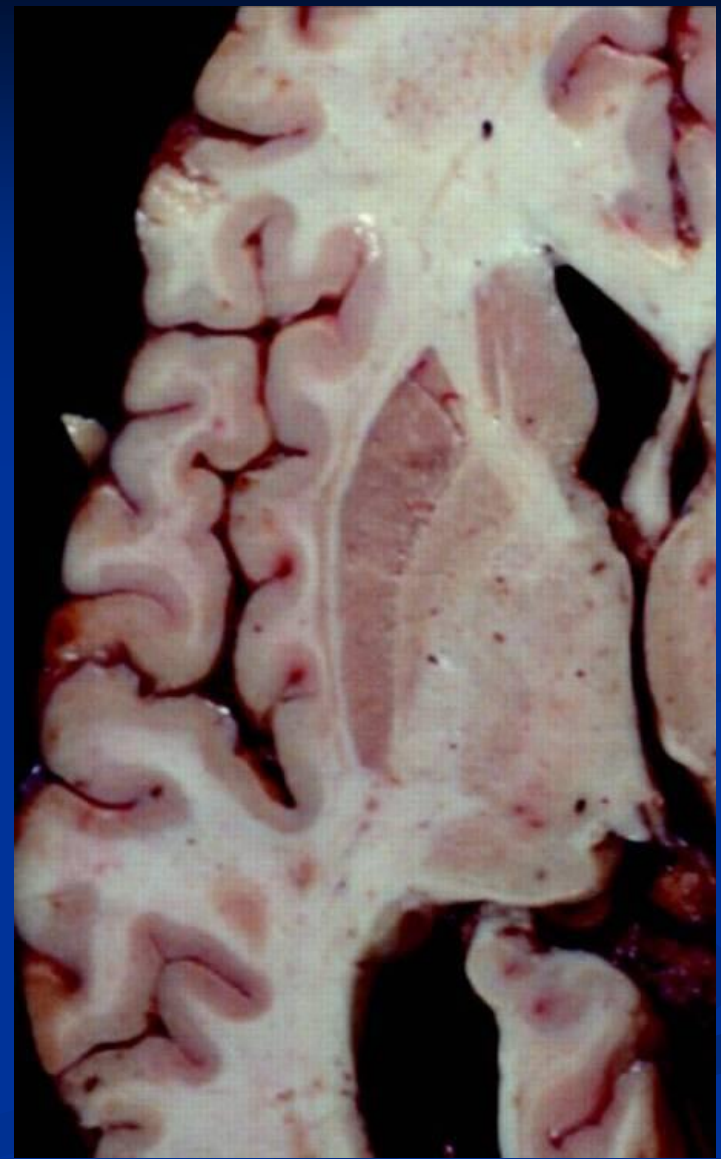
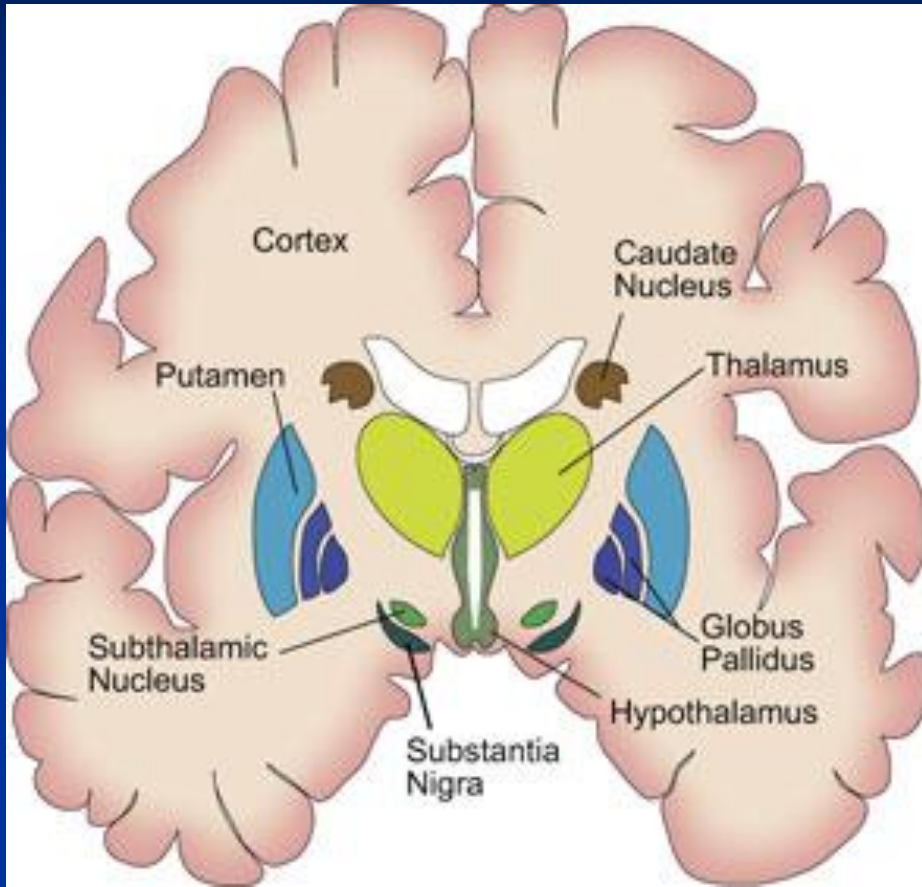


Brain

Axial T2

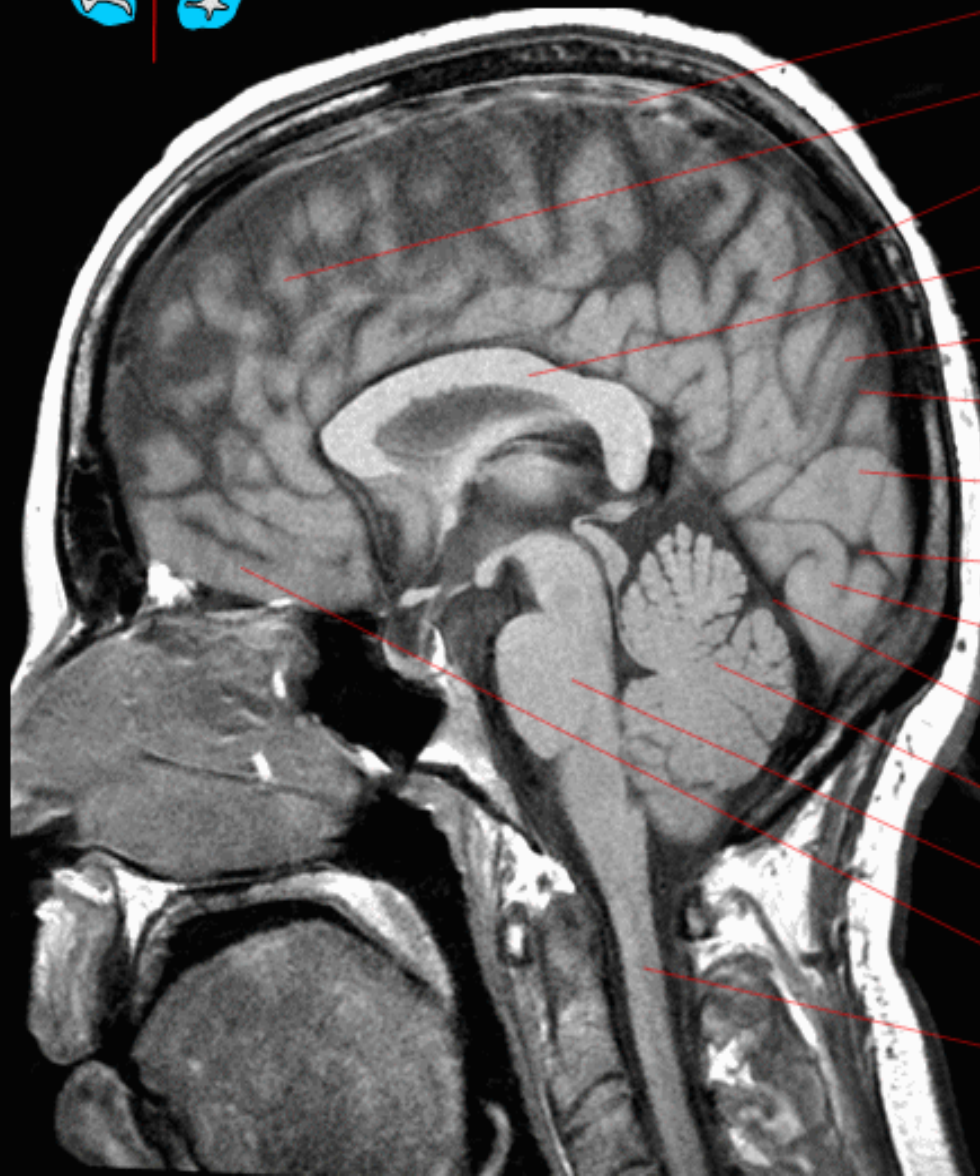
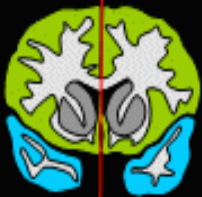
- Caudate nucleus
- Internal capsule (anterior limb)
- Putamen
- Extreme capsule
- Column of fornix
- Clastrum
- External capsule
- Internal capsule (genu)
- Globus pallidus
- Internal capsule (posterior limb)
- Third ventricle
- Thalamus
- Retropulvinar cistern
- Posterior commissure
- Quadrigeminal cistern



Brain

Sagittal T1



Superior sagittal sinus

Frontal lobe

Parietal lobe

Corpus callosum

Precuneus

Parieto-occipital fissure

Cuneus

Calcarine sulcus

Lingual gyrus

Straight sinus

Cerebellum

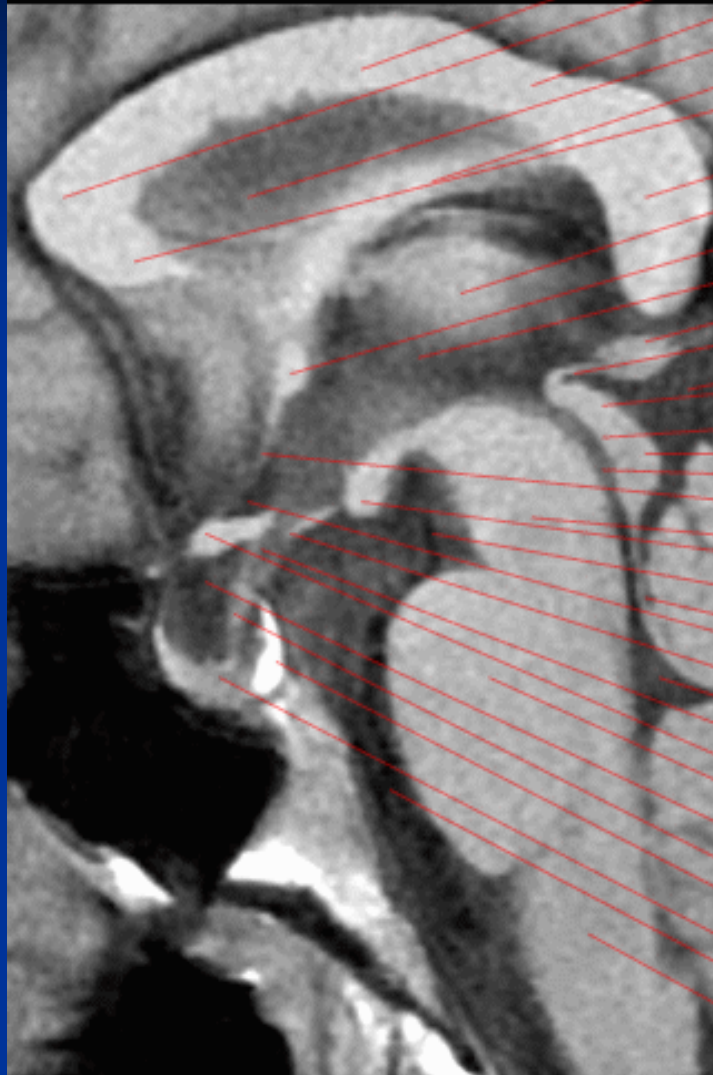
Brainstem

Straight gyrus

Spinal cord

Brain

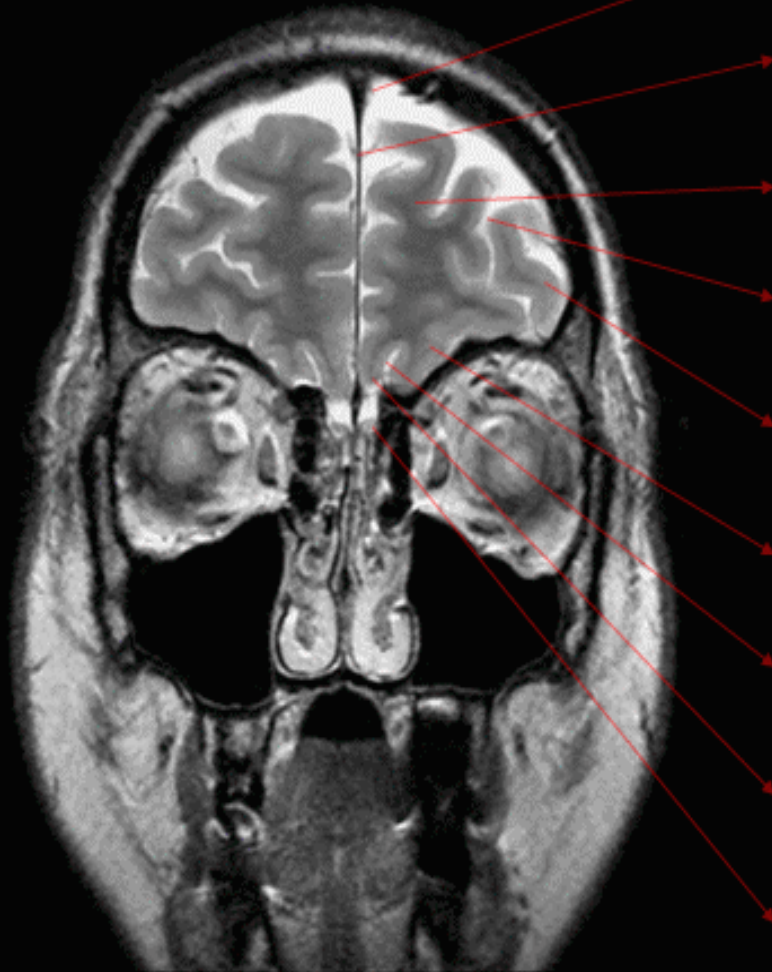
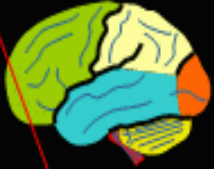
Sagittal T1



- Corpus callosum (body)
- Corpus callosum (genu)
- Corpus callosum (isthmus)
- Septum pellucidum
- Fornix
- Corpus callosum (rostrum)
- Corpus callosum (splenium)
- Thalamus
- Anterior commissure
- Third ventricle
- Pineal gland
- Posterior commissure
- Quadrigeminal cistern
- Superior colliculus
- Quadrigeminal plate
- Inferior colliculus
- Cerebral aqueduct
- Lamina terminalis
- Midbrain
- Mamillary body
- Interpeduncular cistern
- Superior medullary velum
- Supraoptic recess
- Tuber cinereum
- Fourth ventricle
- Infundibular recess
- Optic chiasm
- Pons
- Suprasellar cistern
- Infundibulum
- Neurohypophysis
- Adenohypophysis
- Prepontine cistern
- Medulla oblongata

Brain

Coronal T2



Superior sagittal sinus

Interhemispheric fissure

Superior frontal gyrus

Superior frontal sulcus

Middle frontal gyrus

Medial orbital gyrus

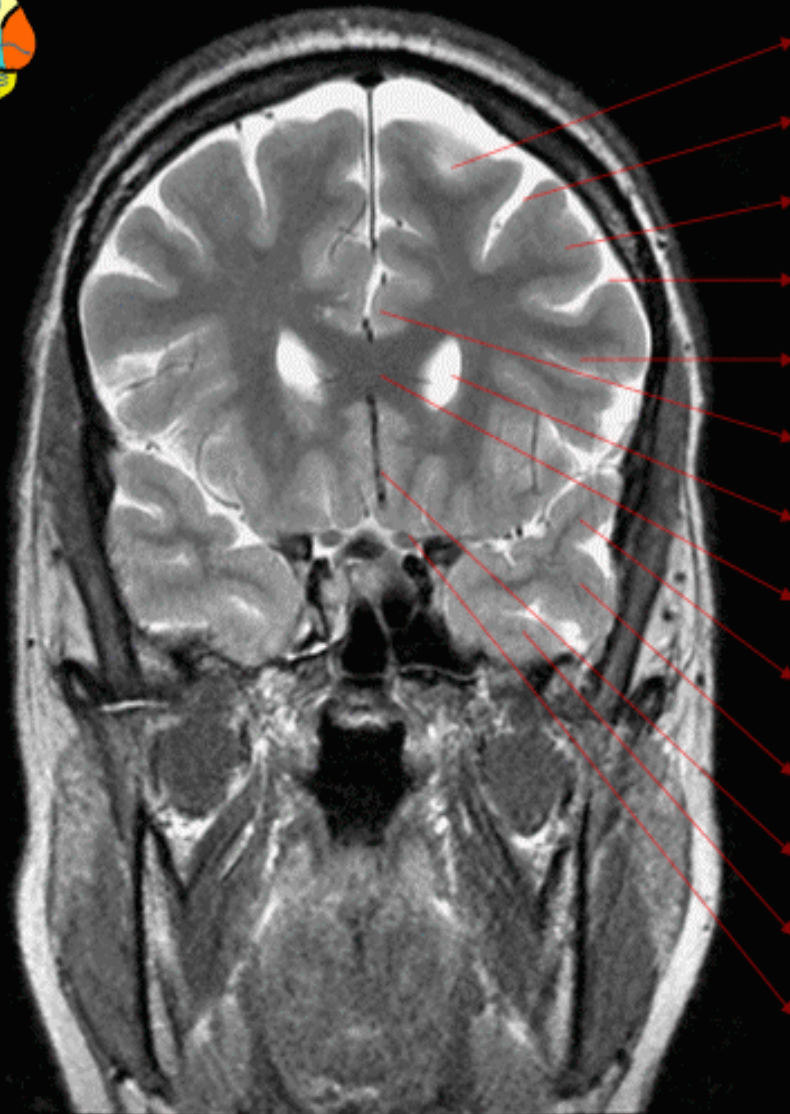
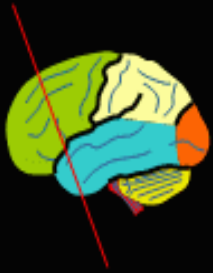
Olfactory sulcus

Gyrus rectus

Olfactory bulb

Brain

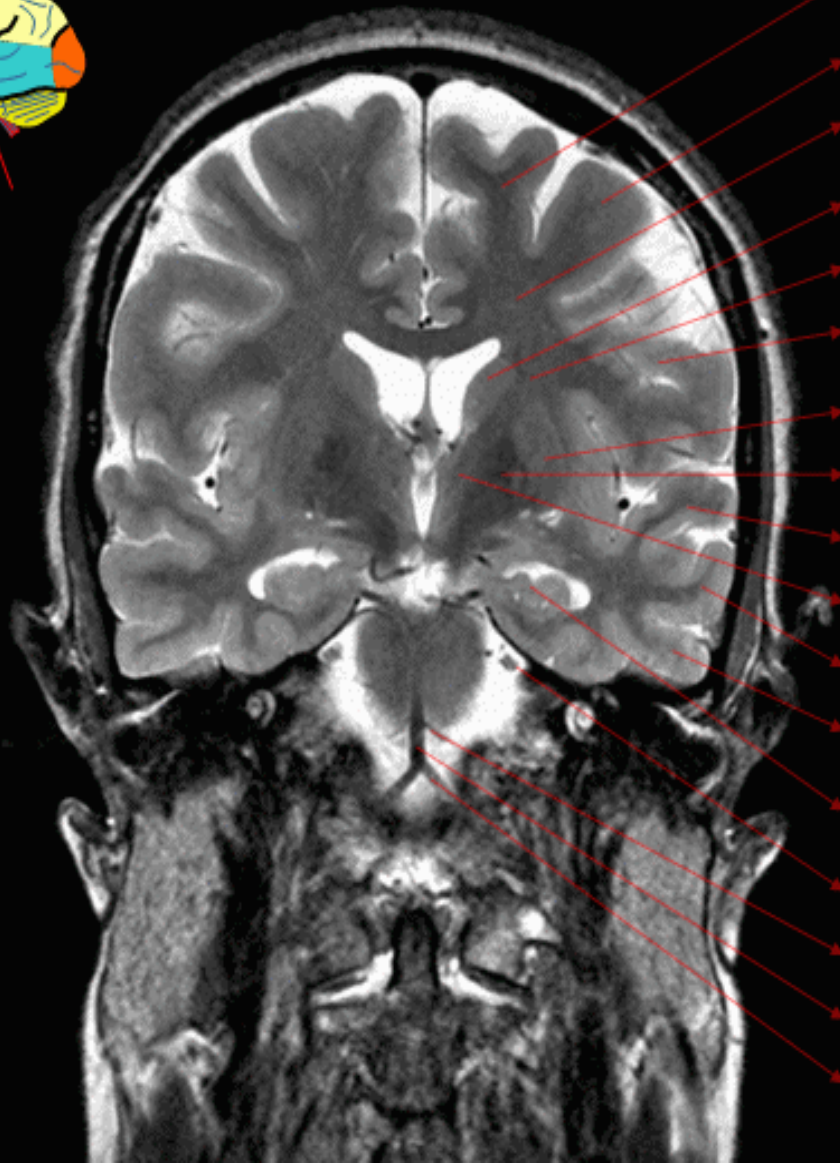
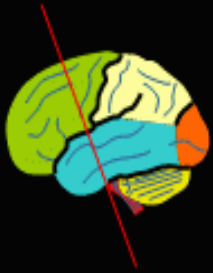
Coronal T2



- Superior frontal gyrus
- Superior frontal sulcus
- Middle frontal gyrus
- Inferior frontal sulcus
- Inferior frontal gyrus
- Cingulate gyrus
- Lateral ventricle (frontal horn)
- Corpus callosum (genu)
- Superior temporal gyrus
- Middle temporal gyrus
- Anterior cerebral artery
- Inferior temporal gyrus
- Pre-chiasmatic optic nerve

Brain

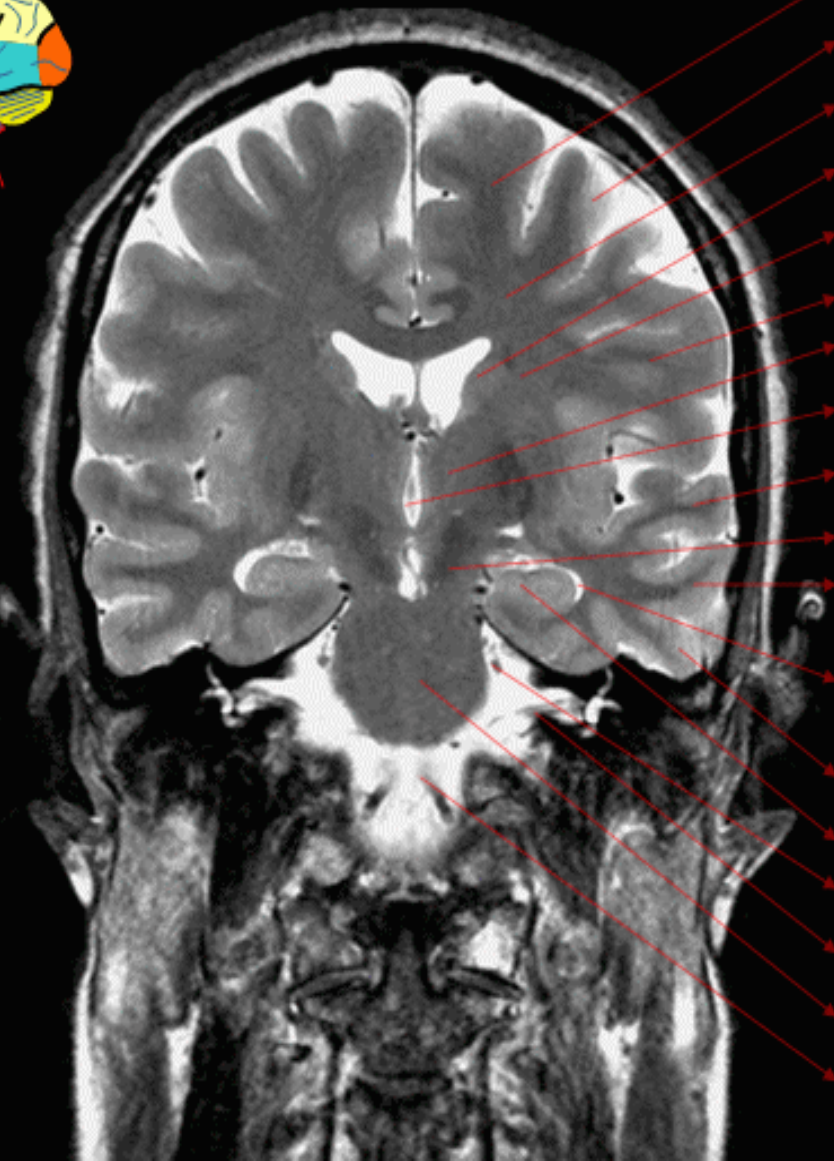
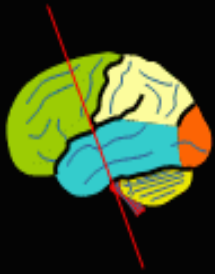
Coronal T2



- Superior frontal gyrus
- Middle frontal gyrus
- Centrum semiovale
- Caudate nucleus
- Corona radiata
- Inferior frontal gyrus
- Putamen
- Globus pallidus
- Superior temporal gyrus
- Internal capsule
- Middle temporal gyrus
- Inferior temporal gyrus
- Hippocampus
- Trigeminal nerve (V)
- Superior cerebellar artery
- Basilar artery
- Vertebral artery

Brain

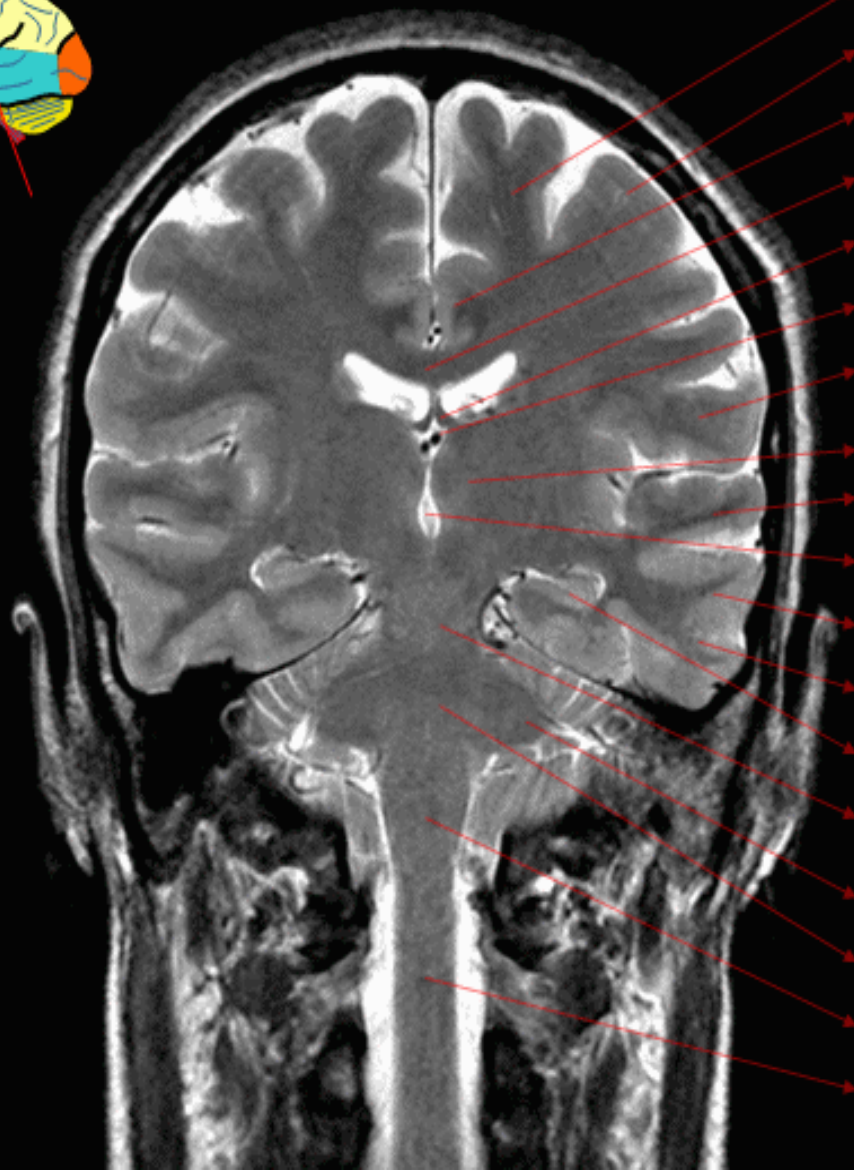
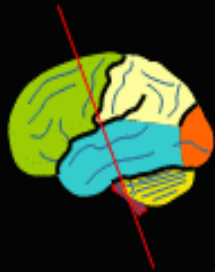
Coronal T2



- Superior frontal gyrus
- Middle frontal gyrus
- Centrum semiovale
- Caudate nucleus
- Corona radiata
- Inferior frontal gyrus
- Thalamus
- Third ventricle
- Superior temporal gyrus
- Mid brain
- Middle temporal gyrus
- Lateral ventricle
(temporal horn)
- Inferior temporal gyrus
- Hippocampus
- Trigeminal nerve (V)
- CN VII and VIII
- Pons
- Vertebral artery

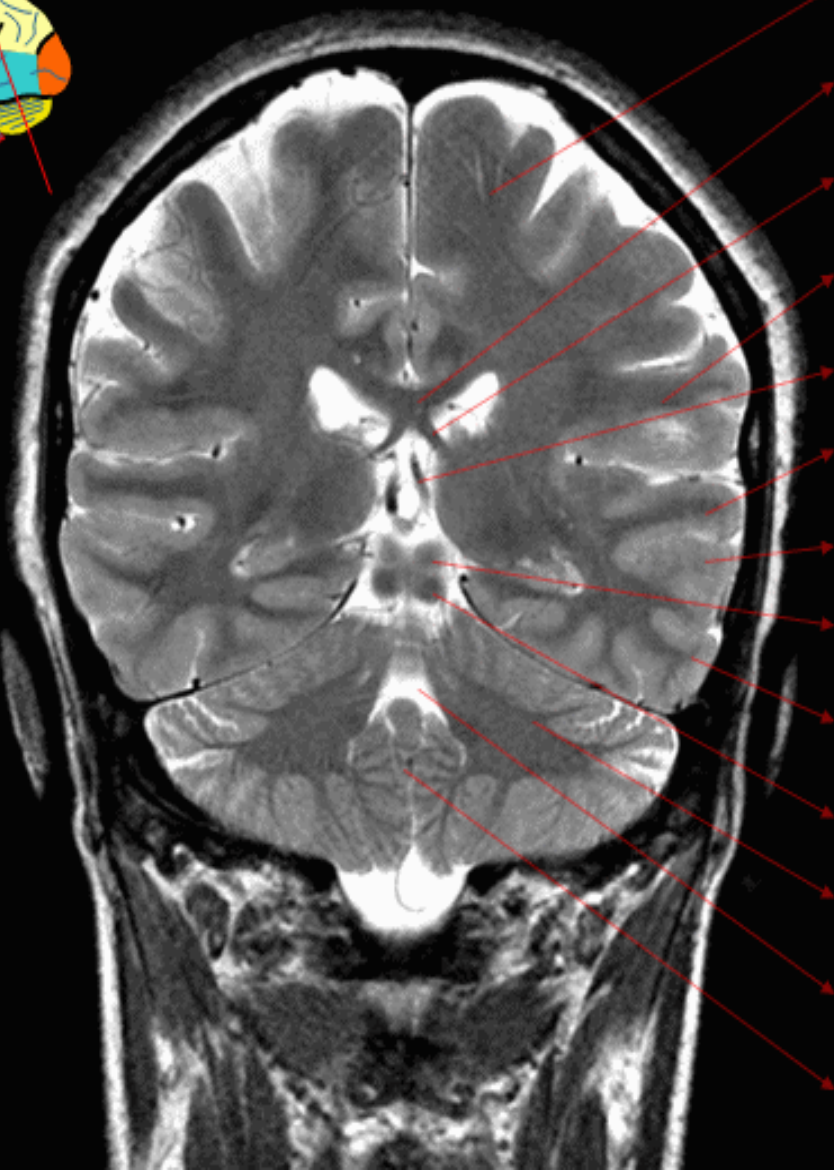
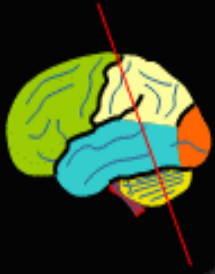
Brain

Coronal T2



- Superior frontal gyrus
- Middle frontal gyrus
- Cingulate gyrus
- Corpus callosum (body)
- Fornix
- Internal cerebral vein
- Precentral gyrus
- Thalamus
- Superior temporal gyrus
- Third ventricle
- Middle temporal gyrus
- Inferior temporal gyrus
- Hippocampus
- Mid brain
- Middle cerebellar peduncle
- Pons
- Medulla oblongata
- Spinal cord

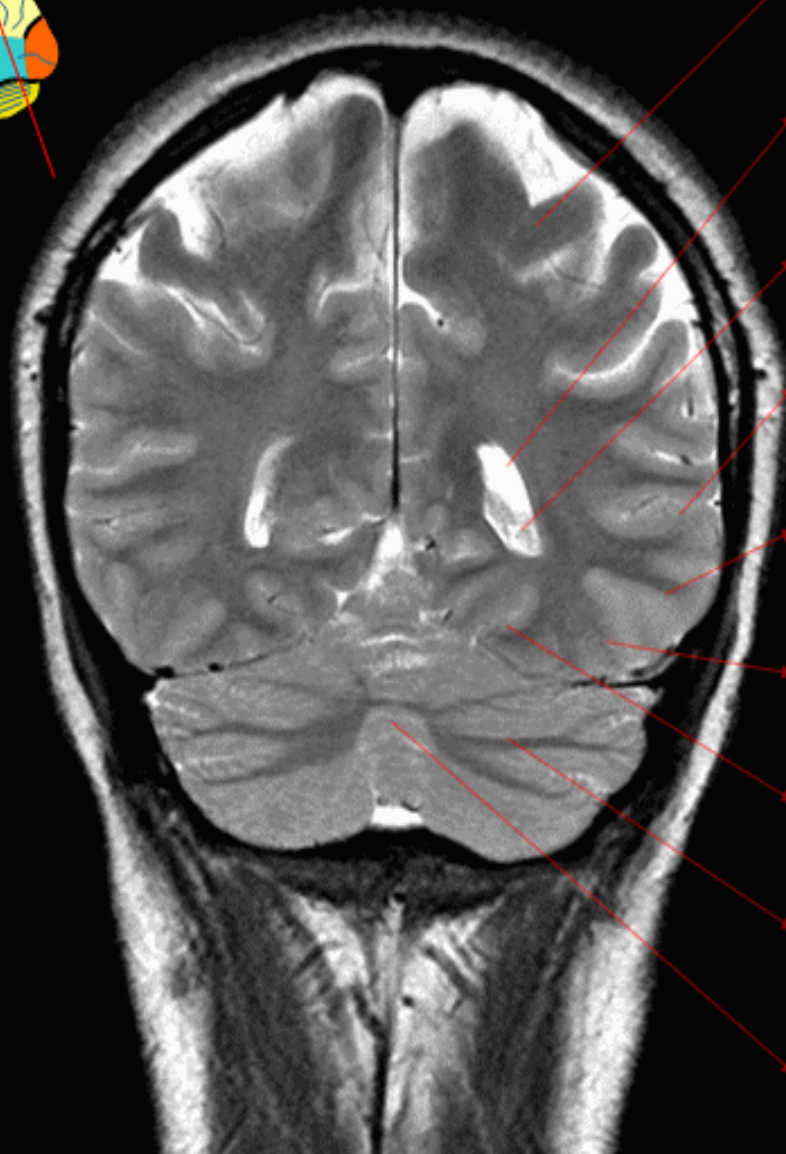
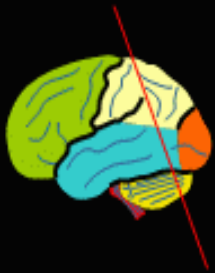Brain Coronal T2



- Postcentral gyrus
- Corpus callosum (body)
- Fornix
- Supramarginal gyrus
- Internal cerebral vein
- Superior temporal gyrus
- Middle temporal gyrus
- Superior colliculus
- Inferior temporal gyrus
- Inferior colliculus
- Cerebellum
- Fourth ventricle
- Vermis

Brain

Coronal T2



Supramarginal gyrus

Lateral ventricle (occipital horn)

Choroid plexus

Middle temporal gyrus

Inferior temporal gyrus

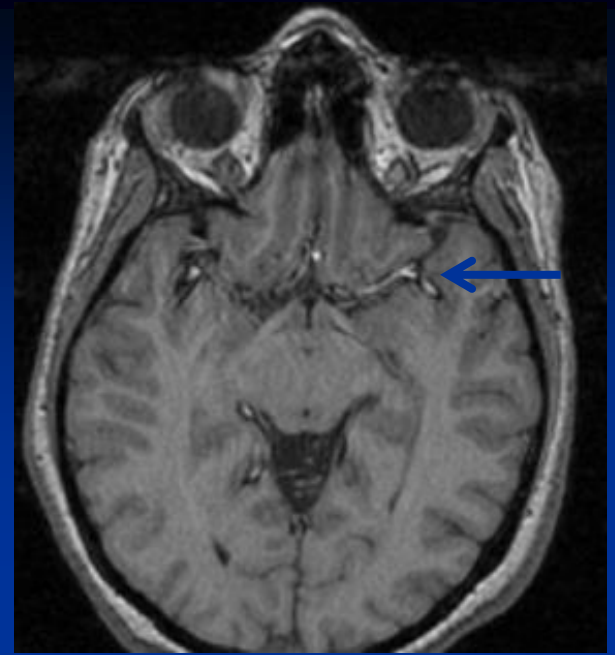
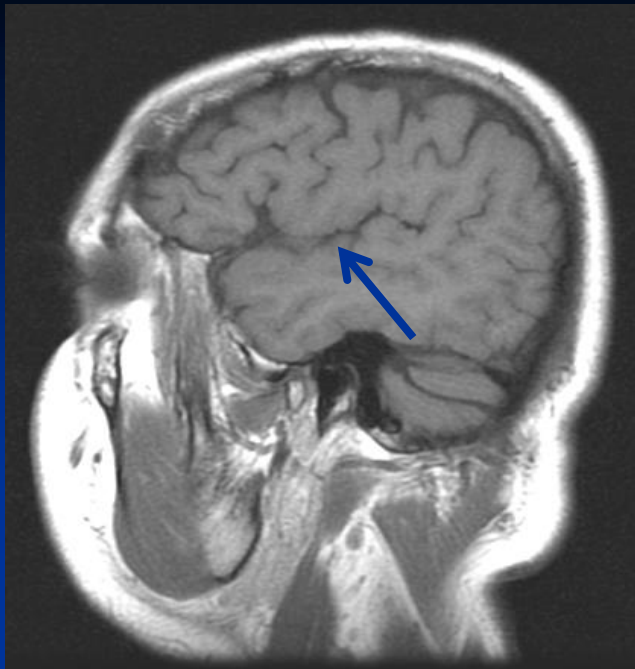
Fusiform gyrus

Lingual gyrus

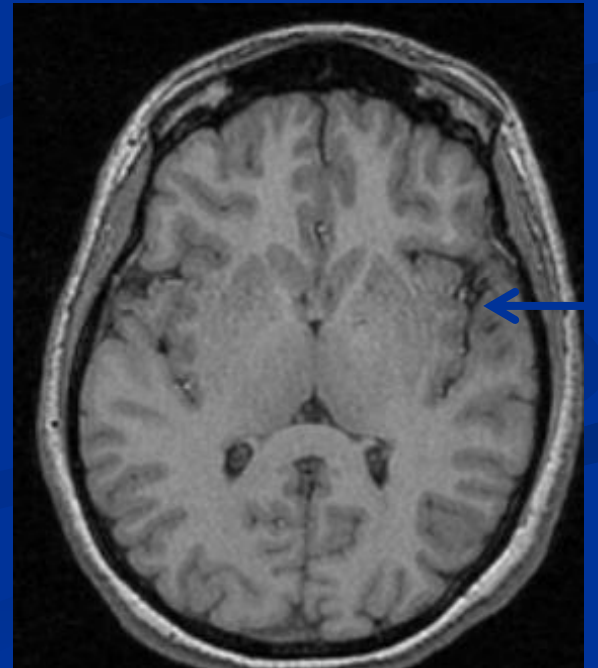
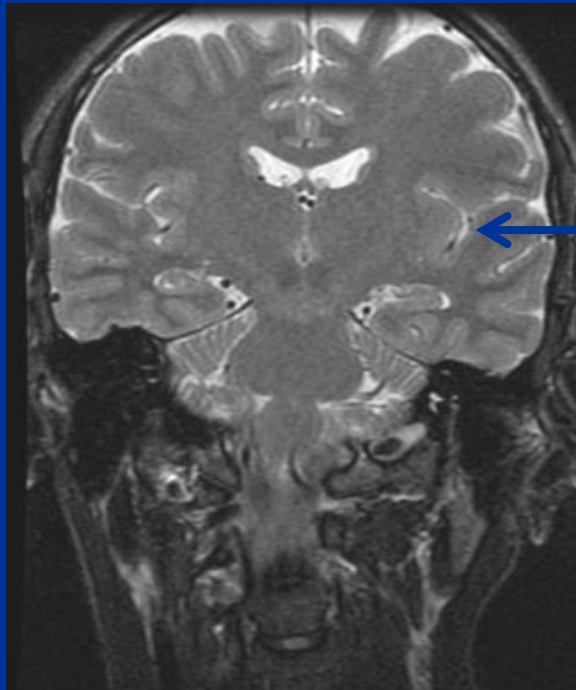
Cerebellum

Vermis

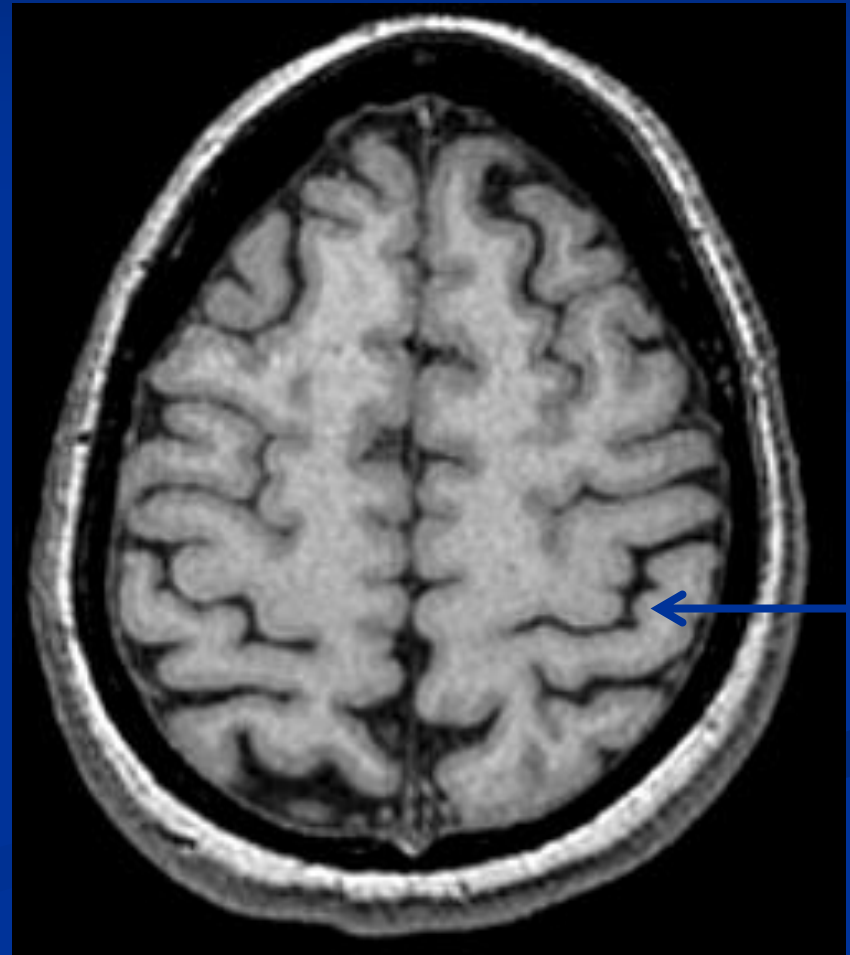
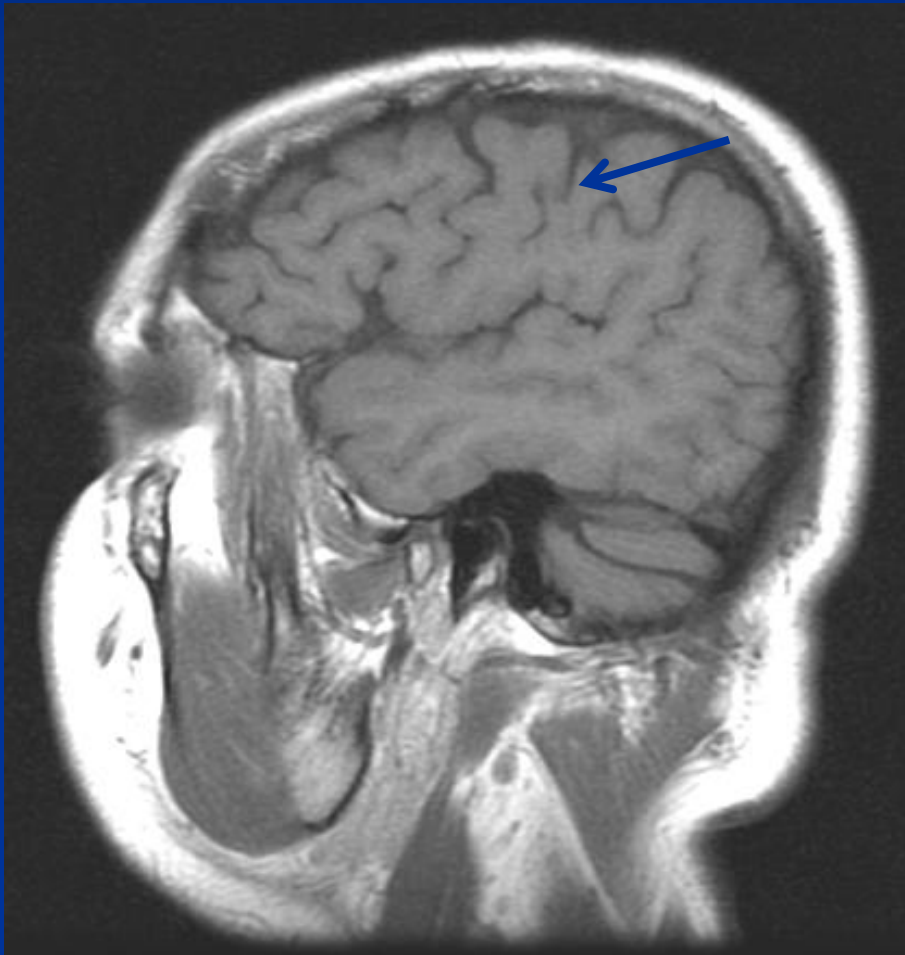
Multiplane correlation



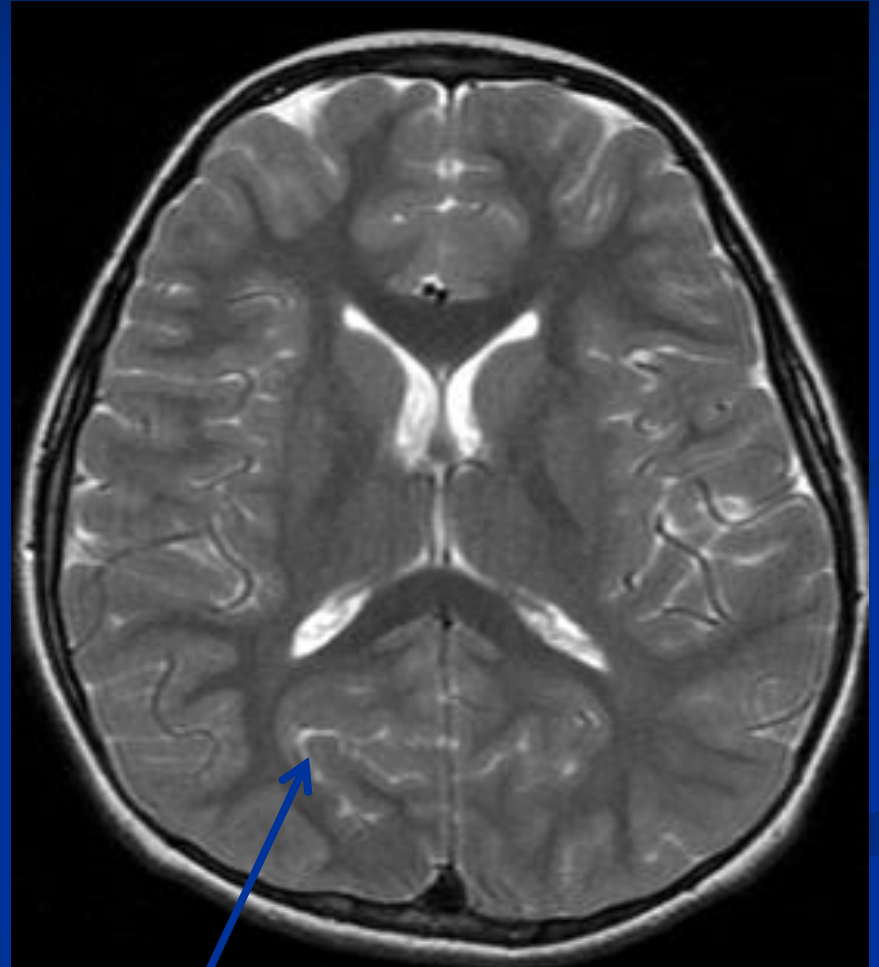
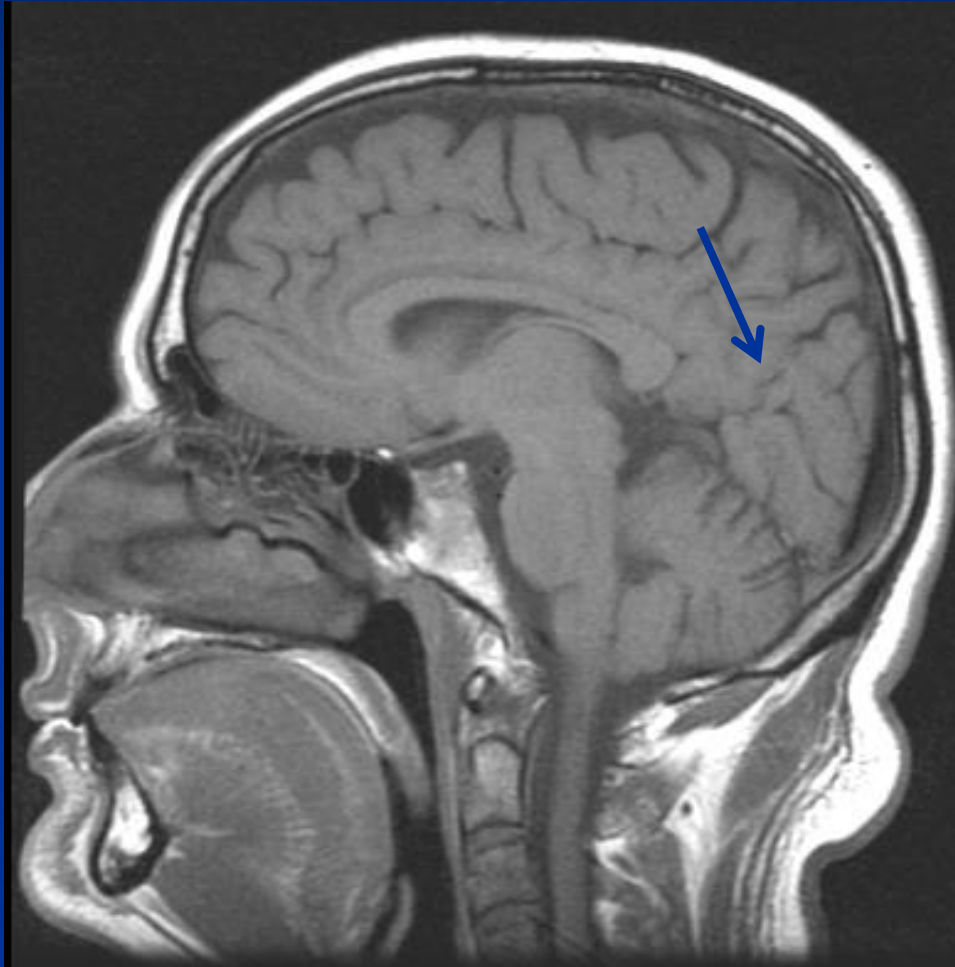
Sylvian fissure



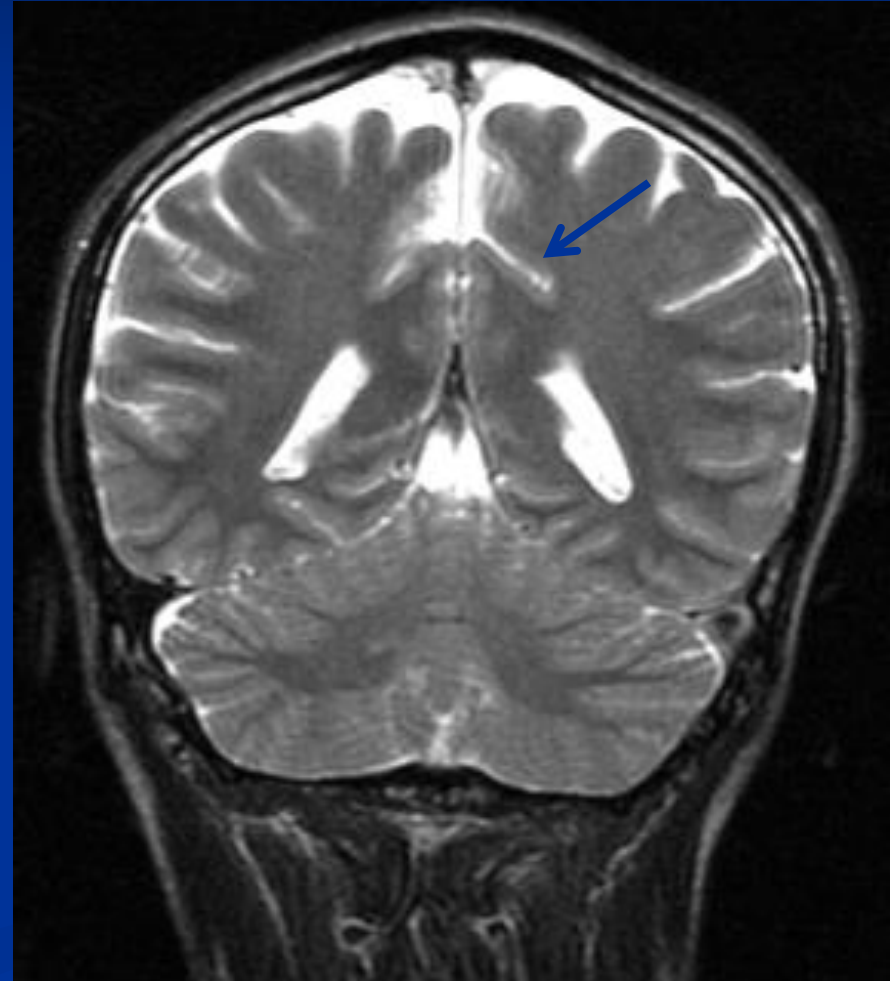
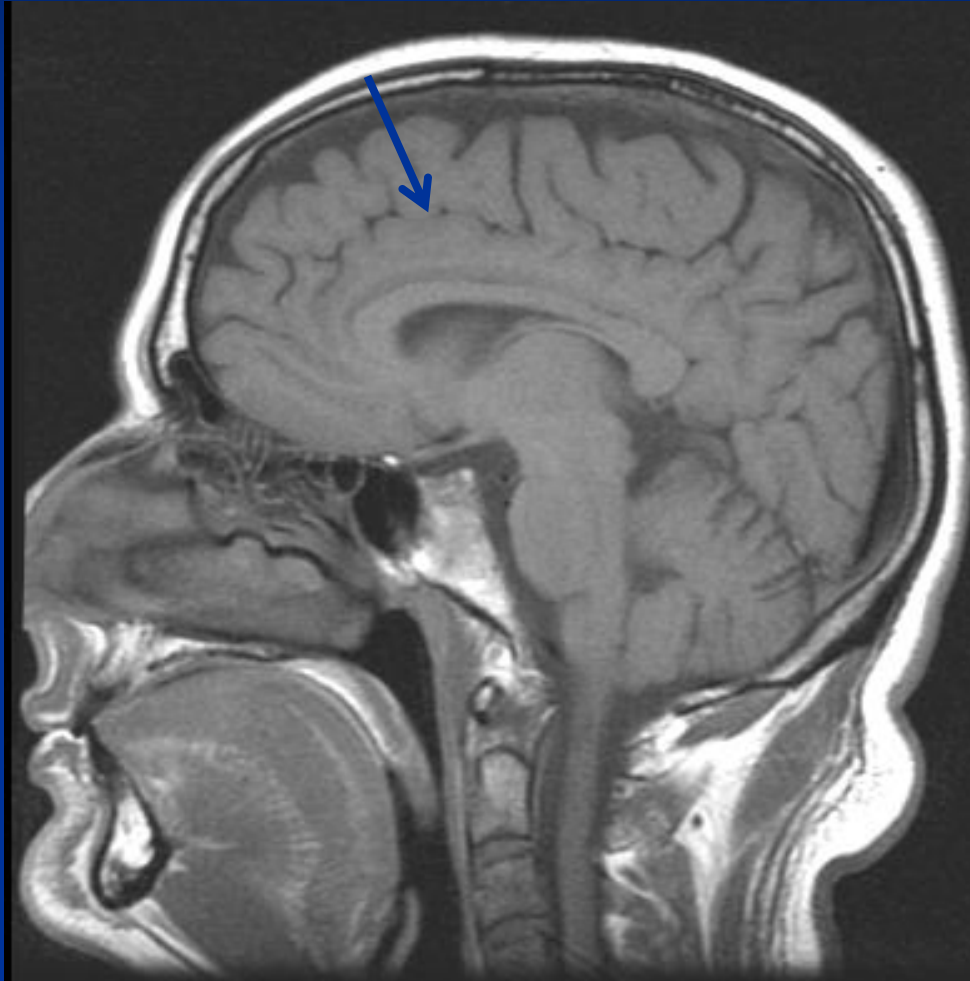Central (Rolandic) fissure



Parieto-occipital fissure

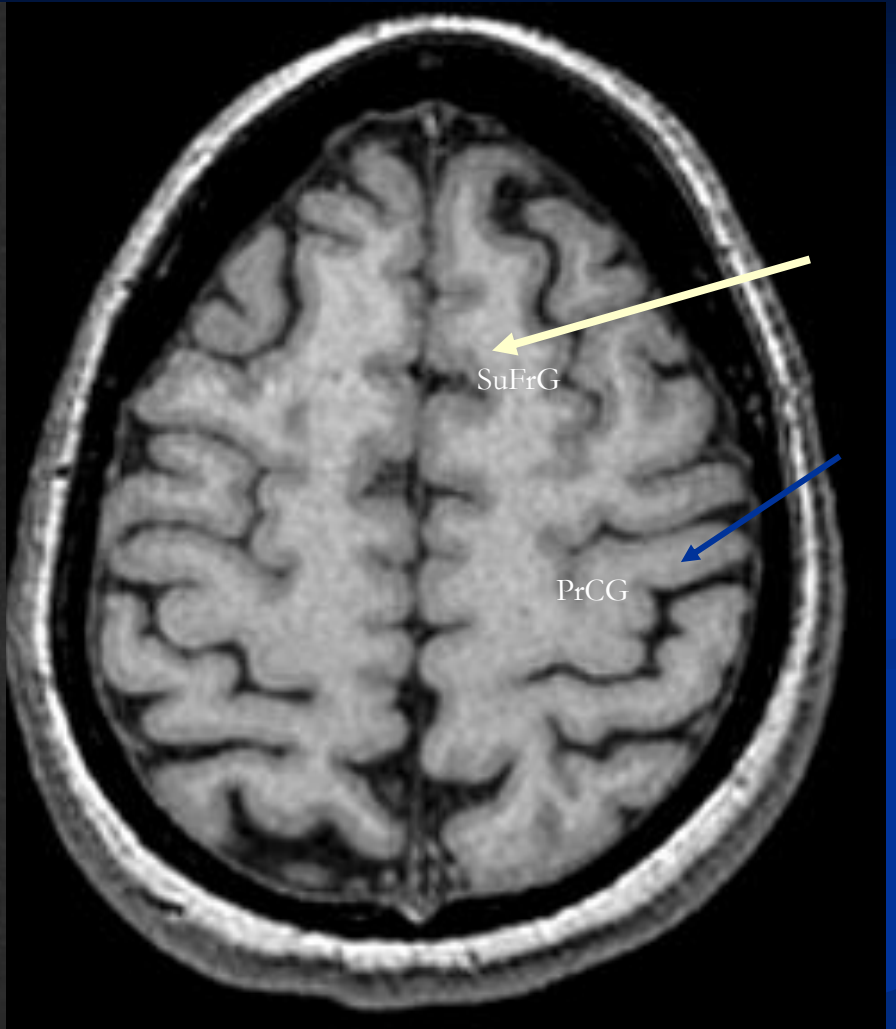
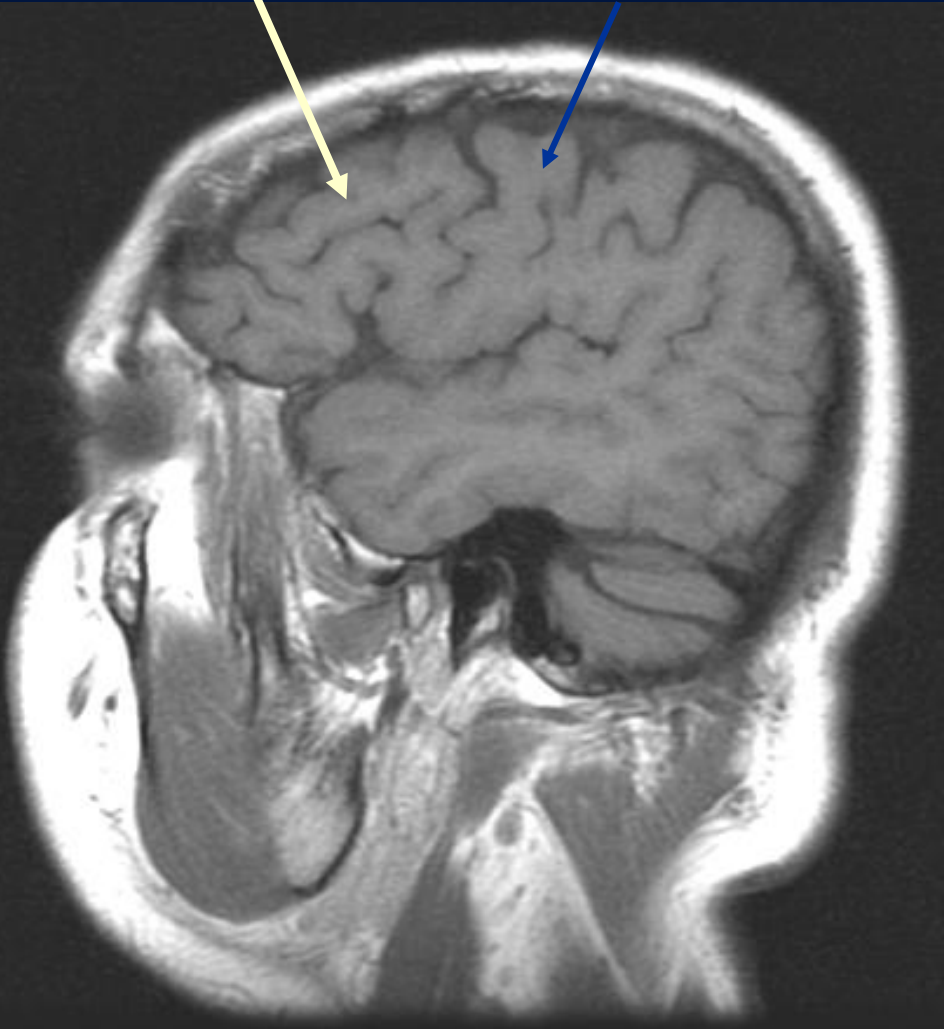


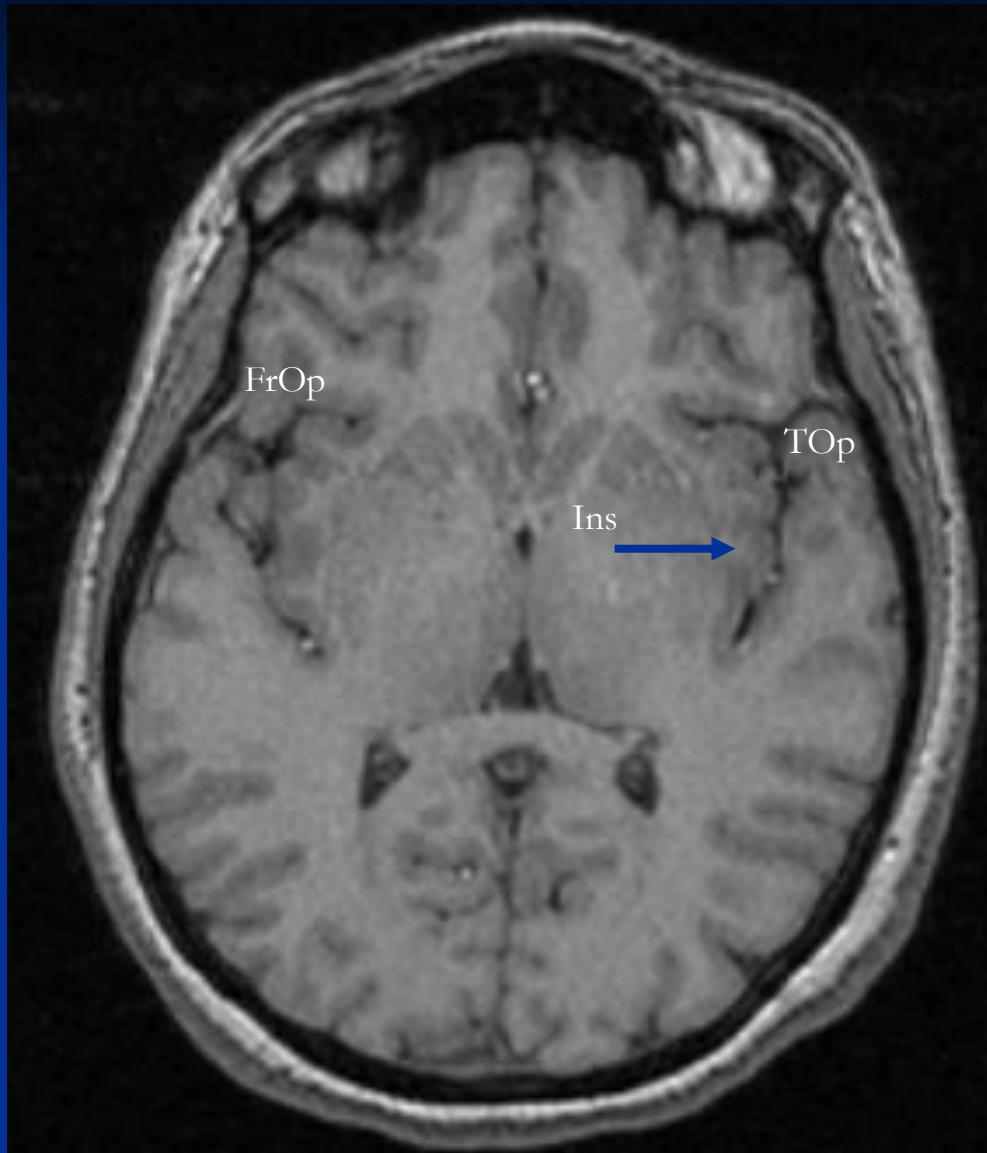
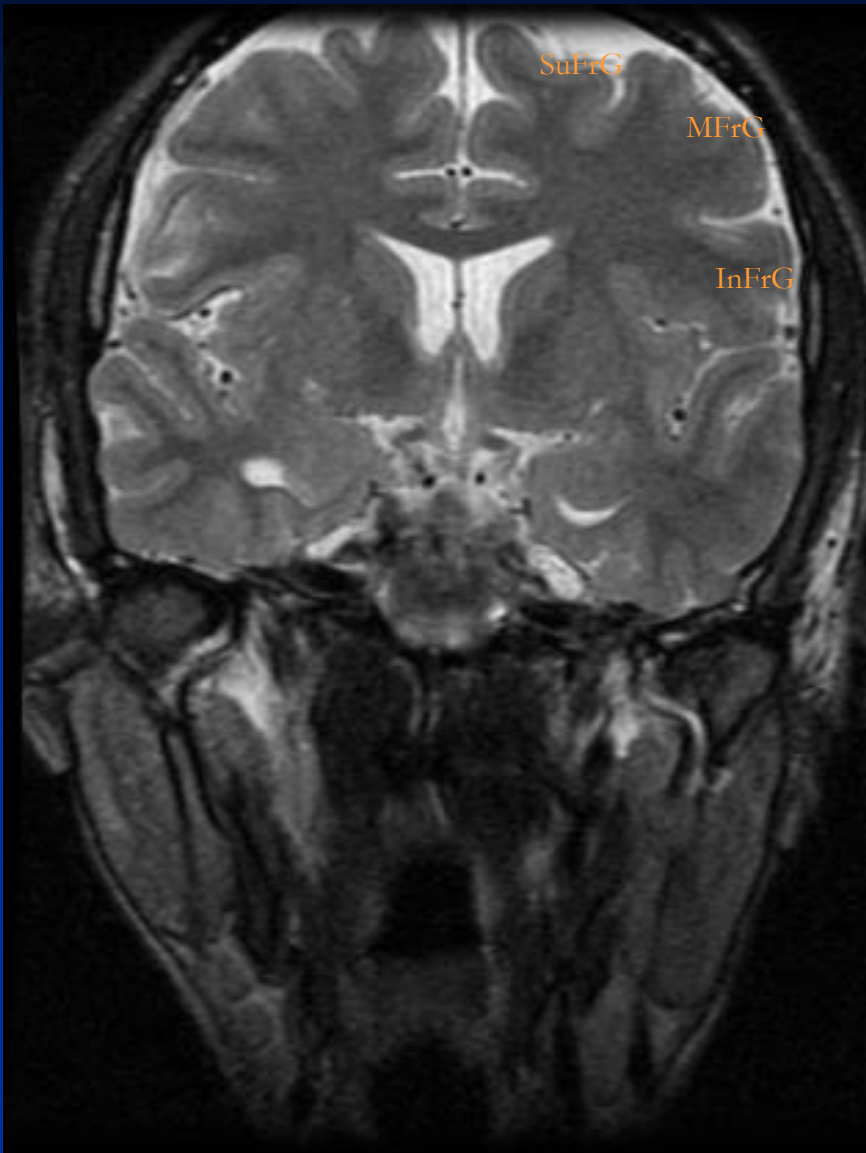
Cingulate Sulcus

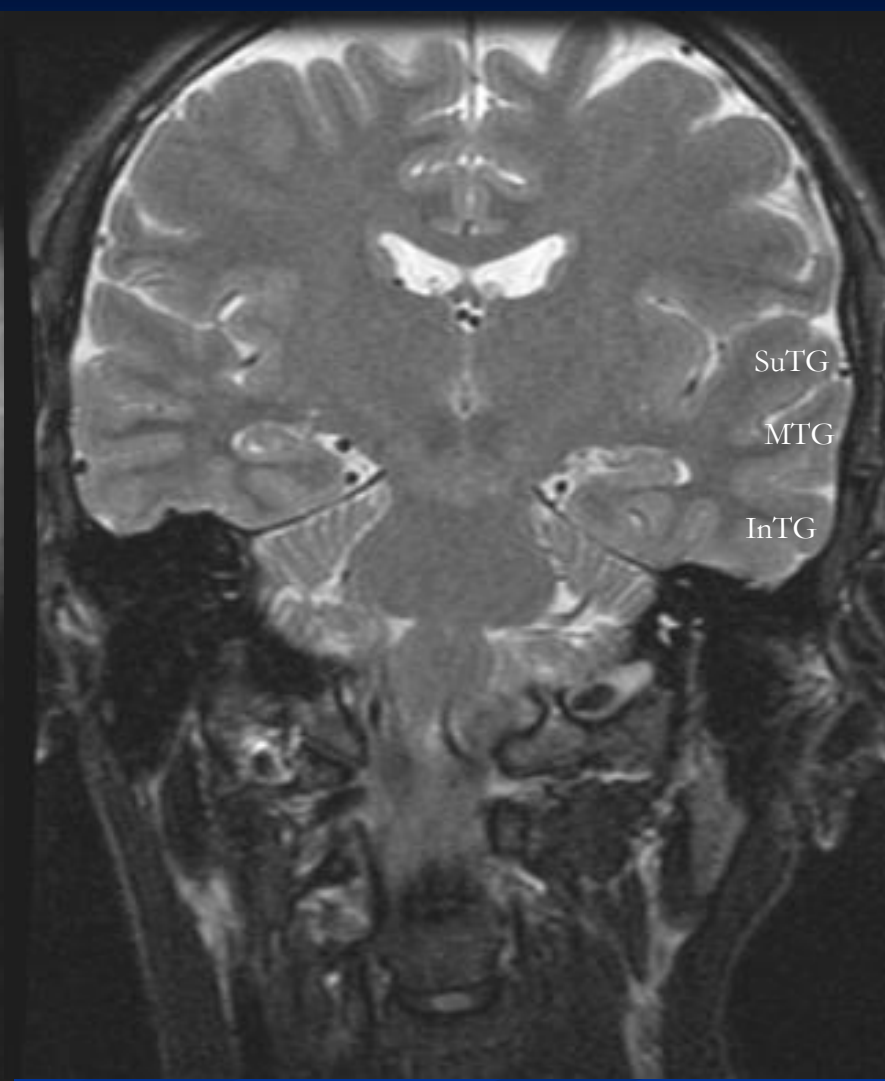
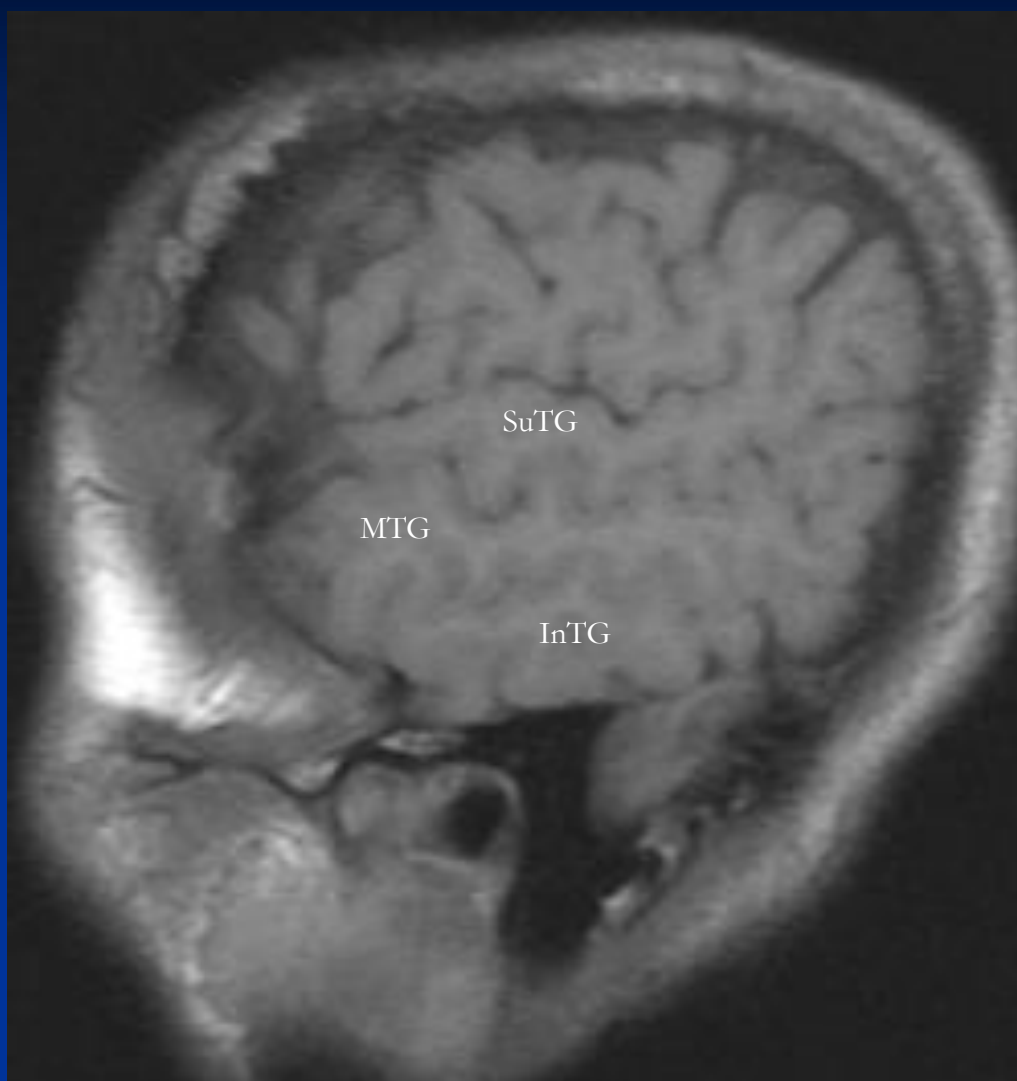


SuFrG

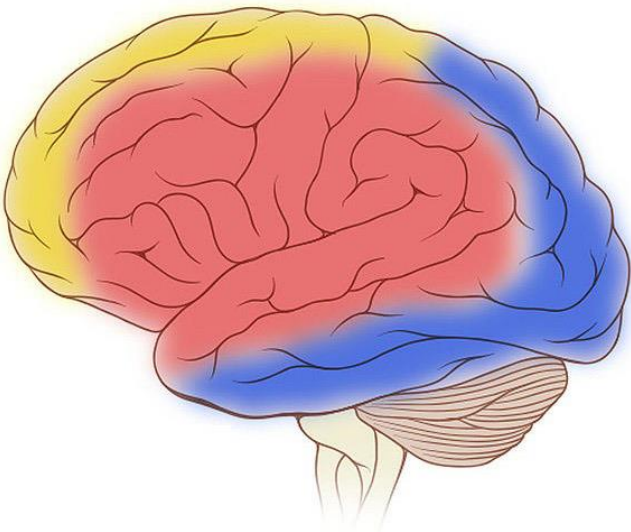
PrCG



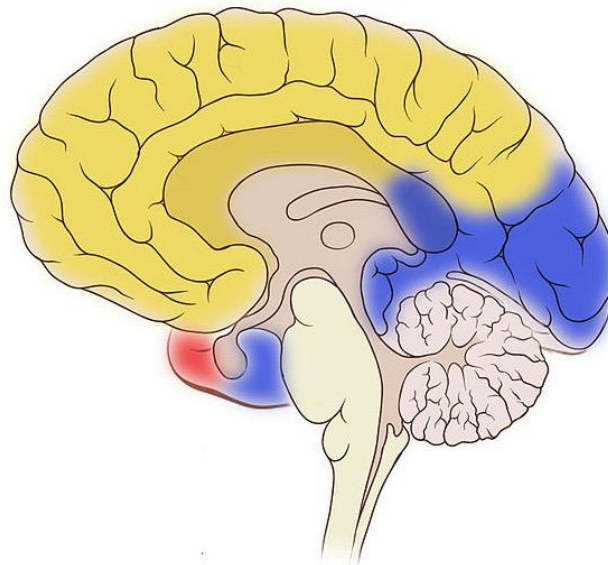







Lateral Brain



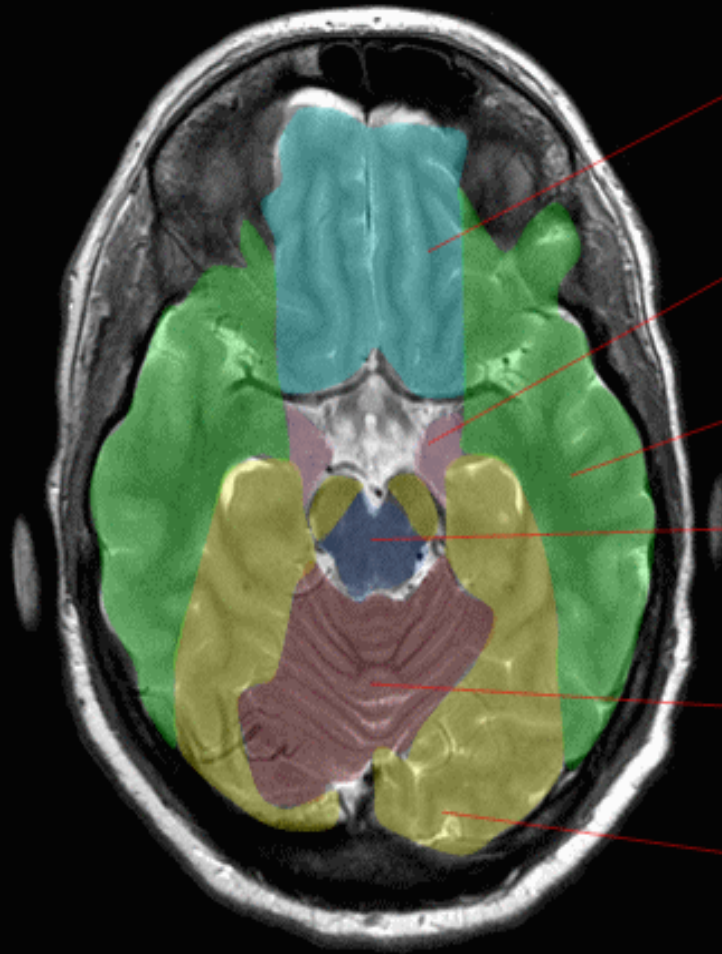
Medial Brain



-  Anterior Cerebral Artery
-  Middle Cerebral Artery
-  Posterior Cerebral Artery

Brain (Arterial territories)

Axial T2



Anterior cerebral artery

Anterior choroidal artery

Middle cerebral artery

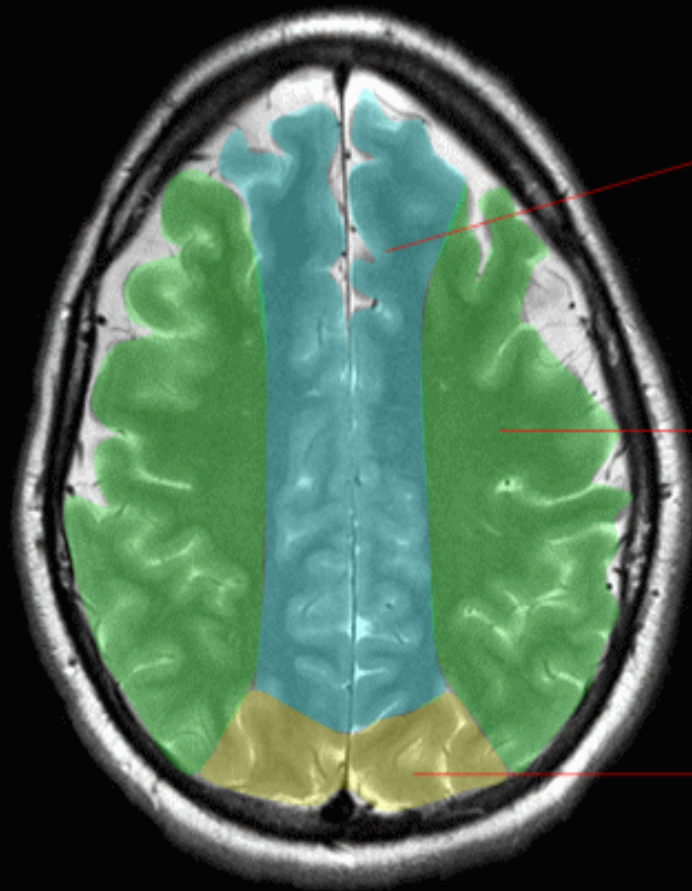
Basilar perforating arteries

Superior cerebellar artery

Posterior cerebral artery

Brain (Arterial territories)

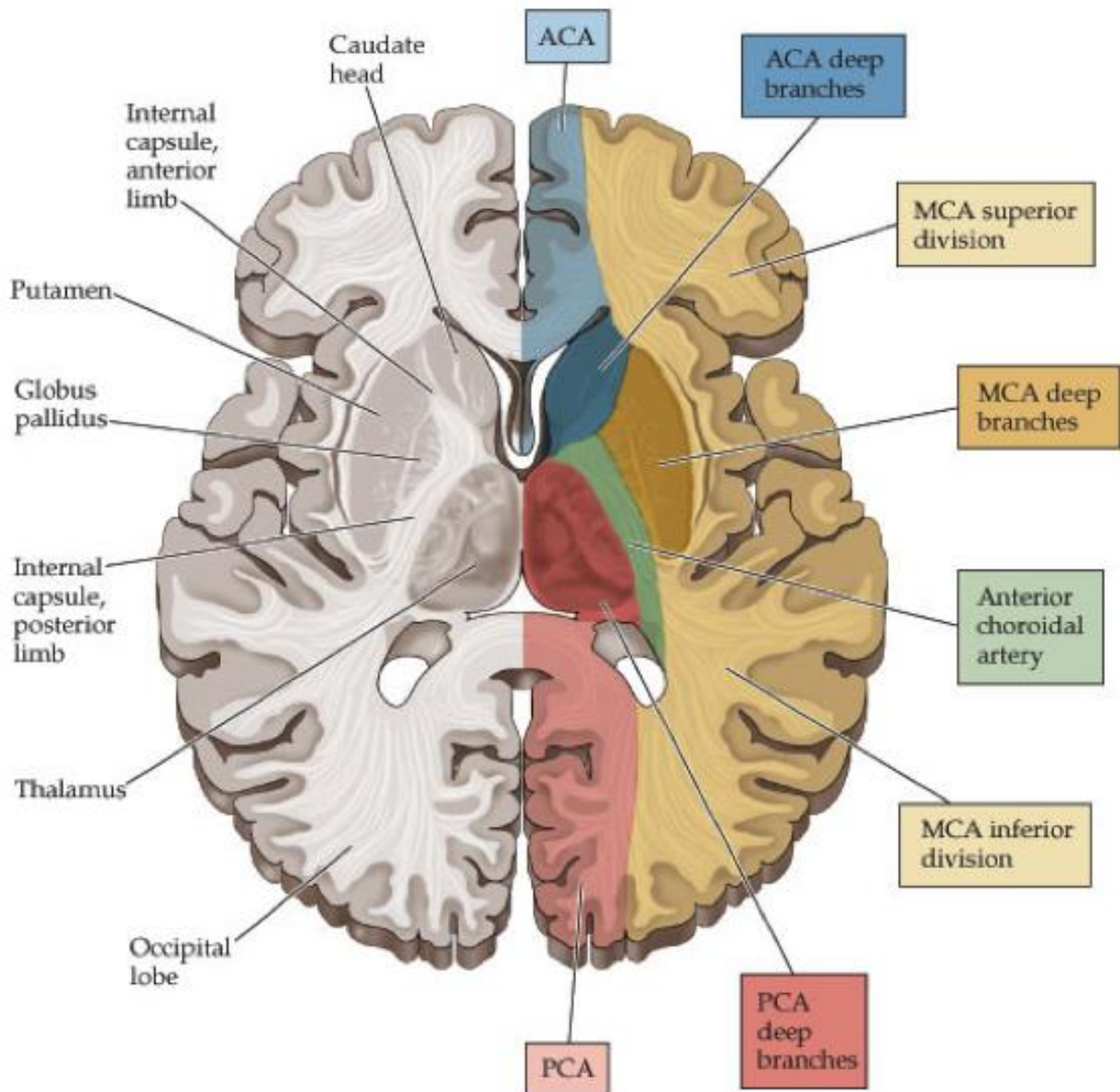
Axial T2



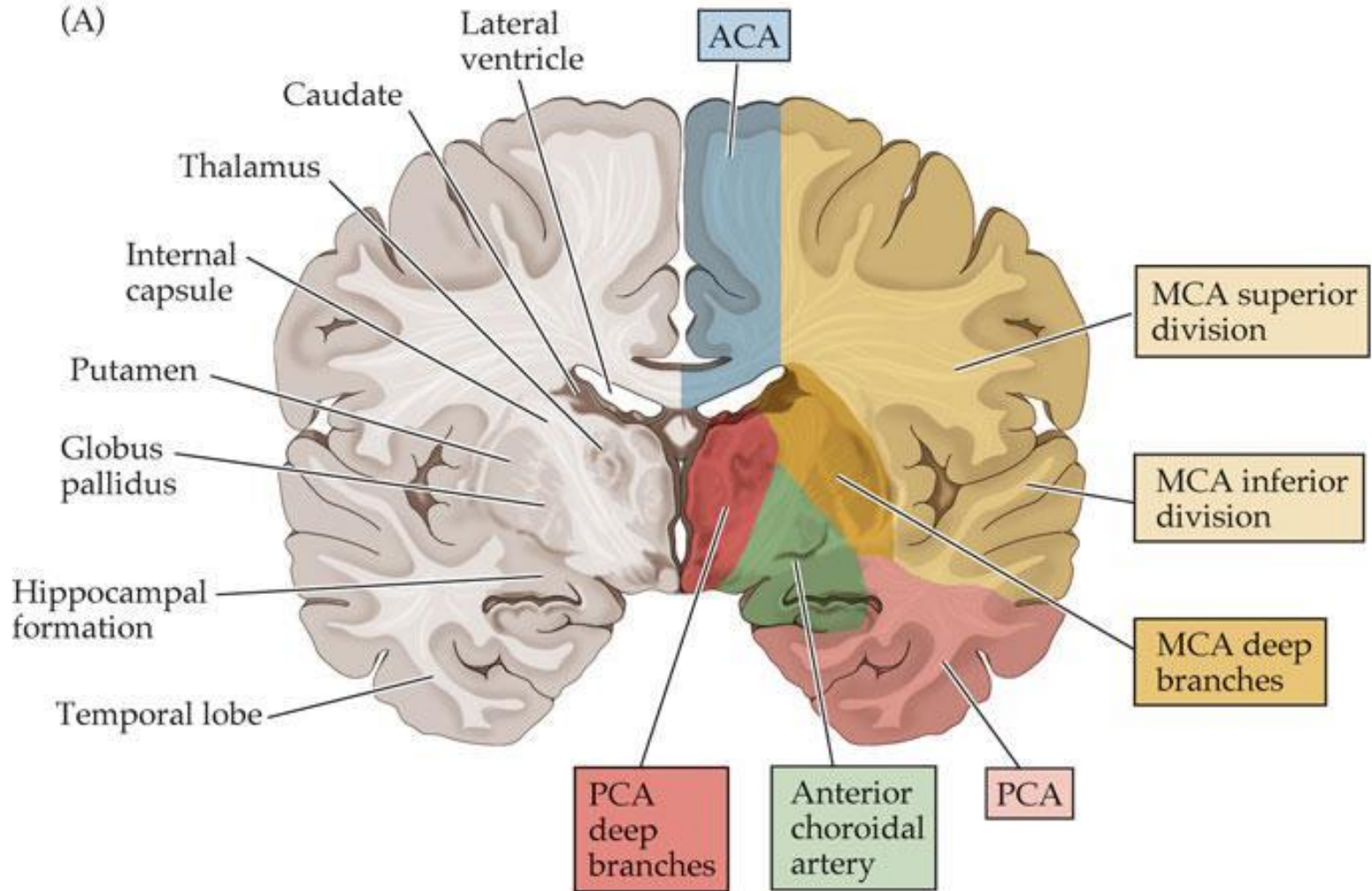
Anterior cerebral artery

Middle cerebral artery

Posterior cerebral artery



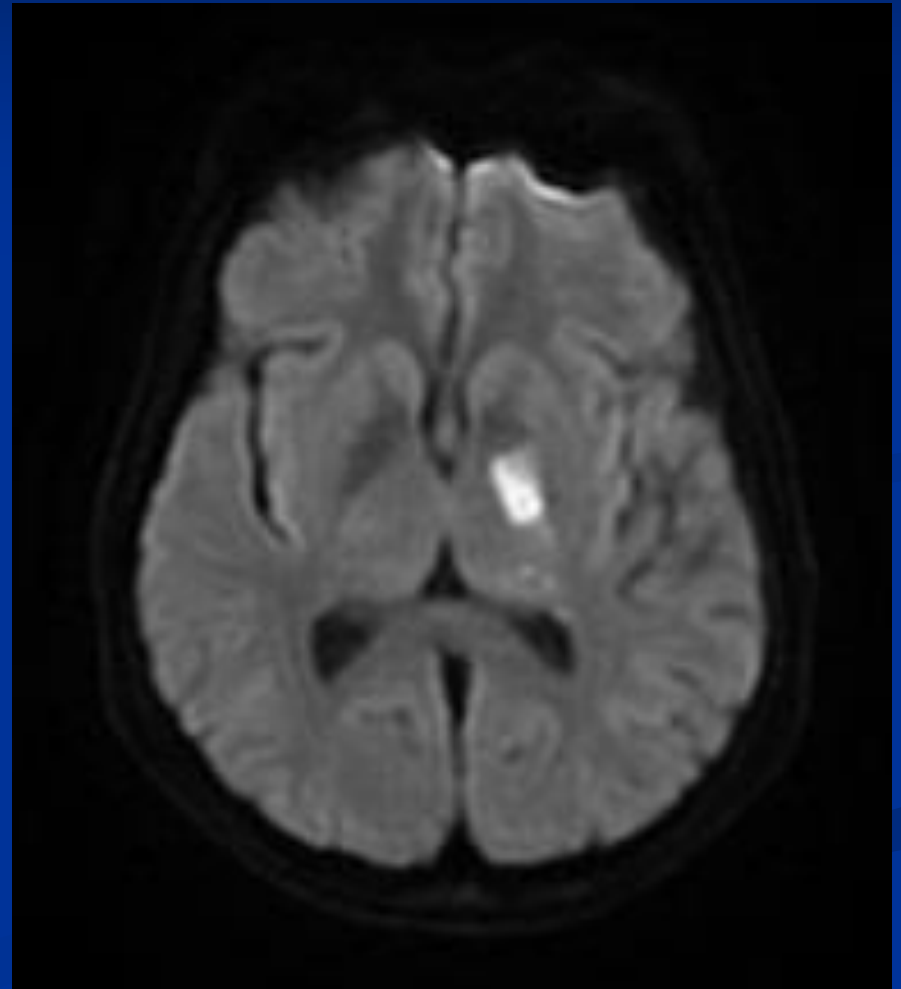
(A)



Quiz

This MR image shows acute infarction. What is the artery involved?

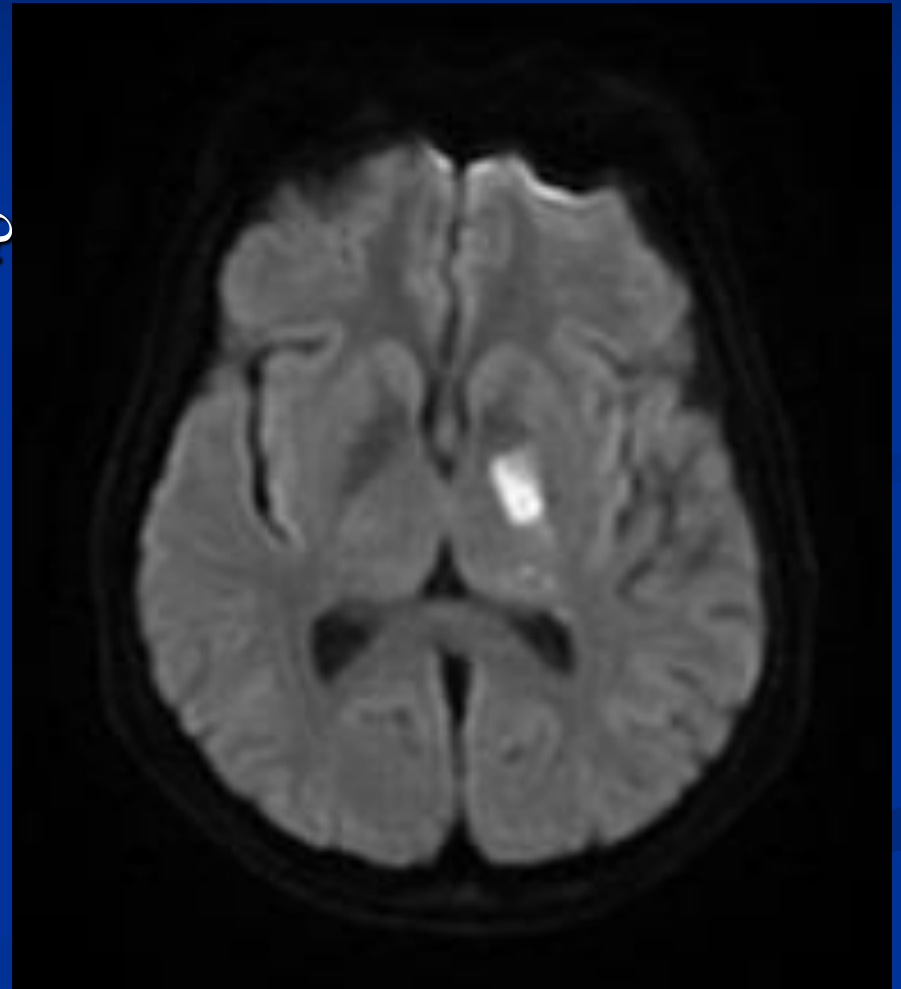
- A. Anterior cerebral
- B. Anterior choroidal
- C. Posterior cerebral
- D. Middle cerebral



Quiz

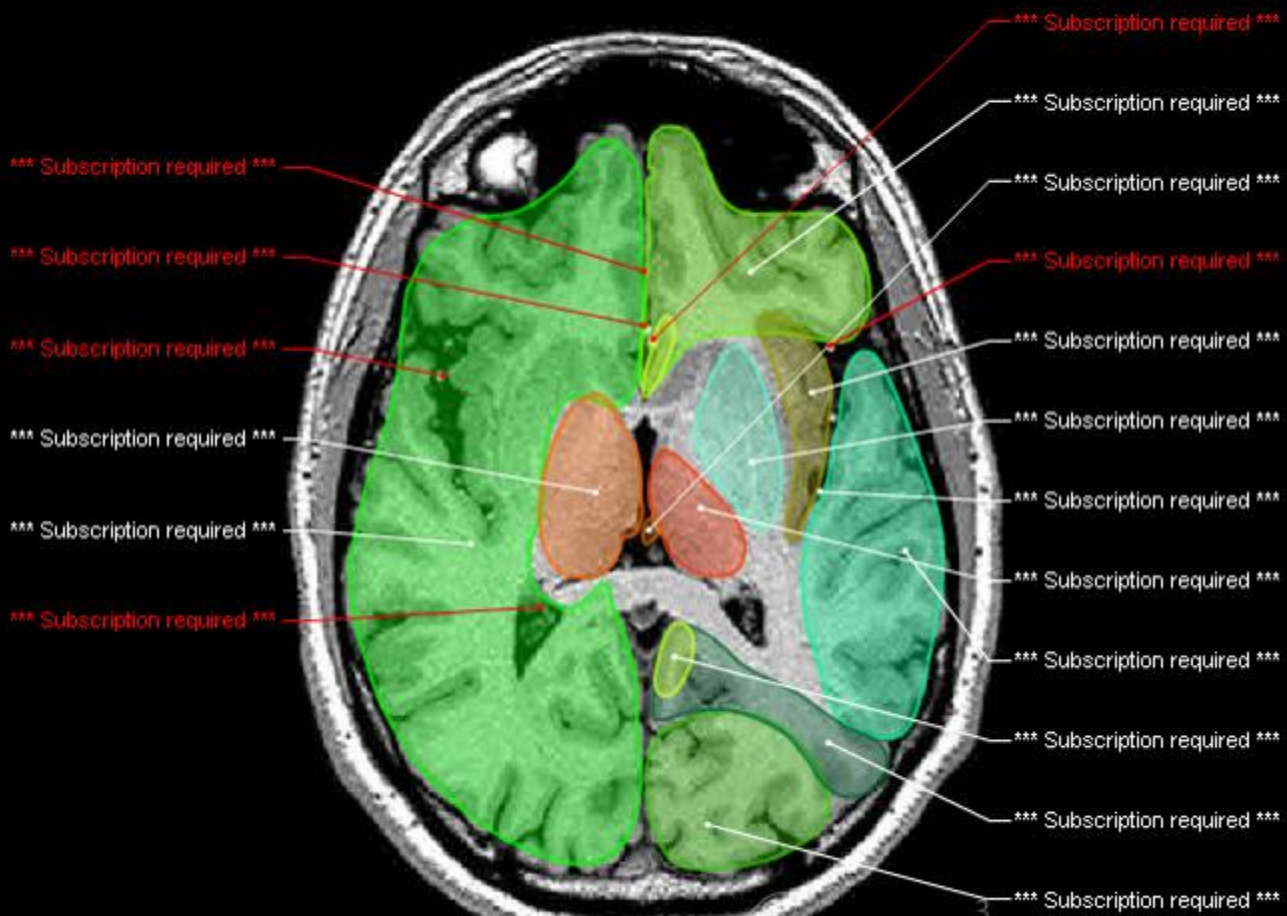
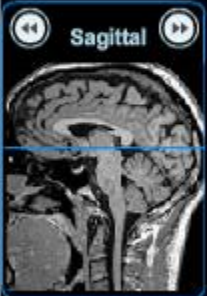
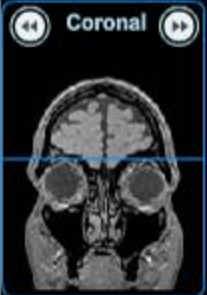
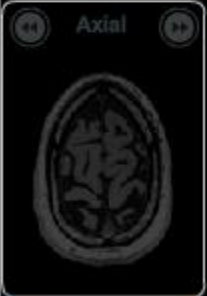This MR image shows acute infarction. What is the expected neurological deficit?

- A. Right leg weakness
- B. Right arm weakness
- C. Right body side weakness
- D. Left leg weakness



e-Resources

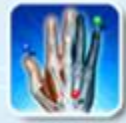- The whole brain atlas, Harvard University.
- Radiologic Anatomy, Wayne State University.
- E-anatomy, www.imaios.com
- Visible body, www.visiblebody.com
- Radiology assistant, www.radiologyassistant.nl



on iPhone

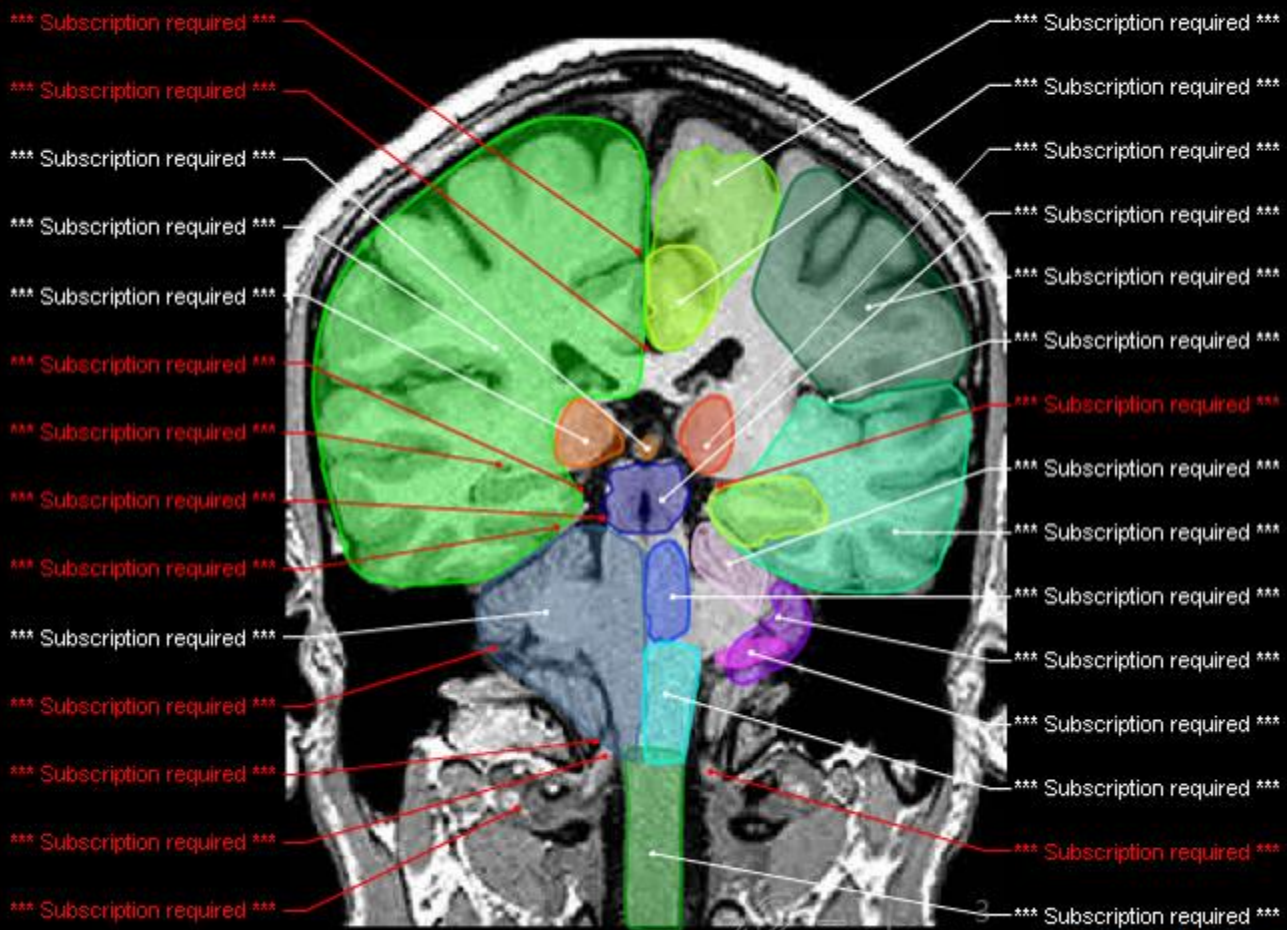
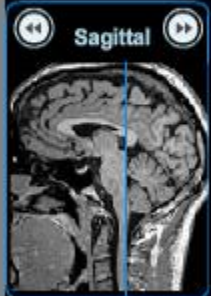
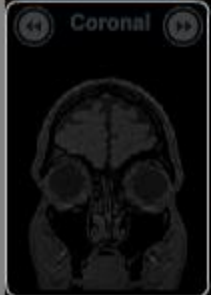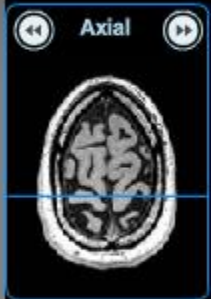IMAIOS Mobile

For all IMAIOS subscribed members e-Anatomy on your iPhone for \$29.99



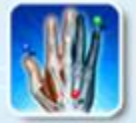IMAIOS Lite

Discover e-Anatomy 4 modules for only \$3.99



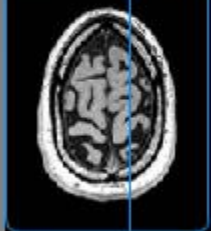on iPhone

IMAIOS Mobile
 For all IMAIOS subscribed members
 e-Anatomy on your iPhone
 for \$29.99

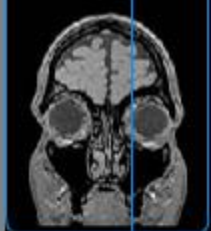


IMAIOS Lite
 Discover e-Anatomy
 4 modules for only \$3.99

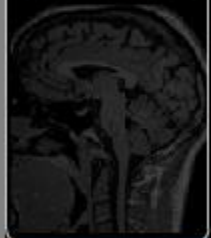
← Axial →



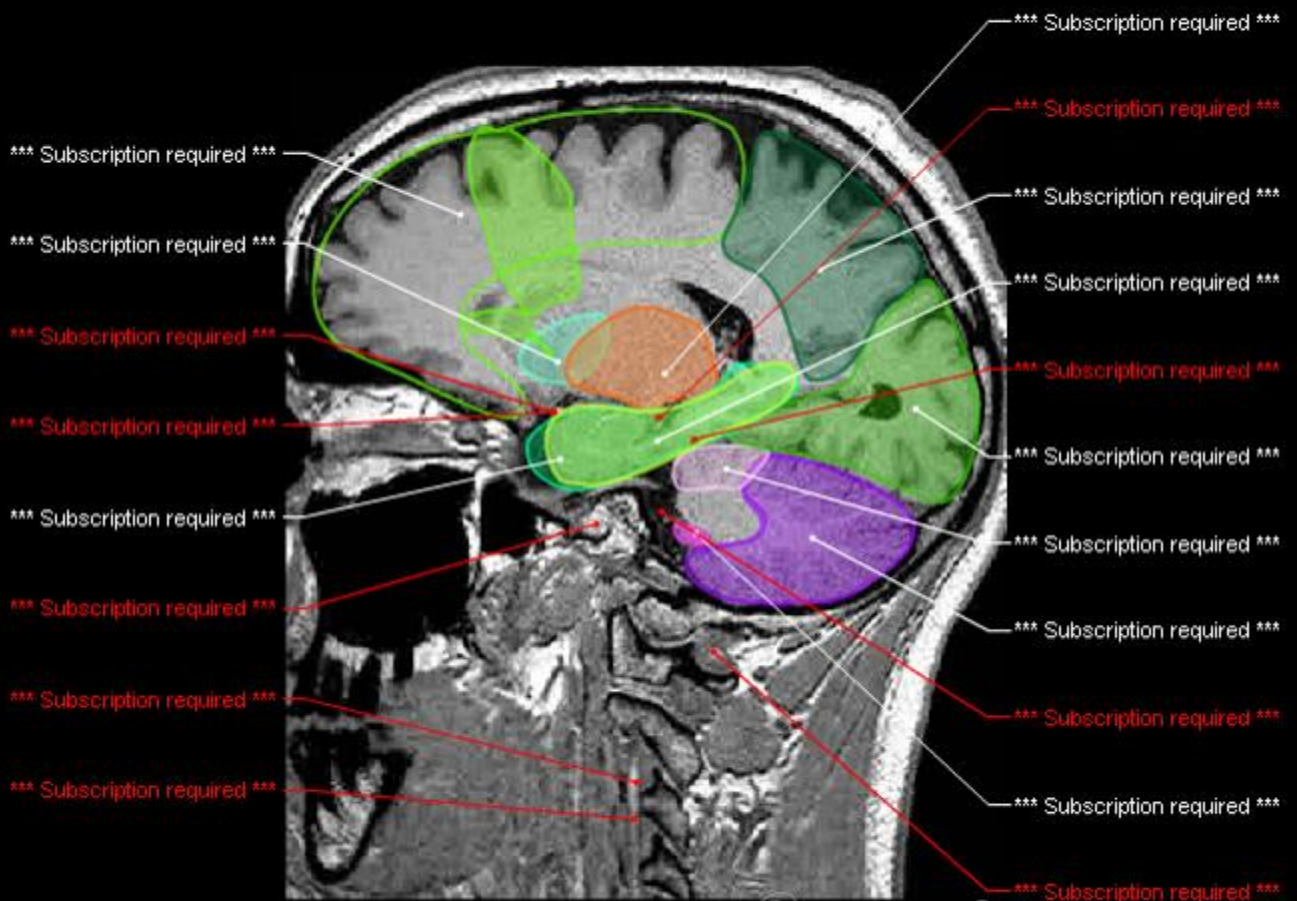
← Coronal →



← Sagittal →



3D



e-anatomy³

Copyright © IMAIOS 2010

on iPhone

IMAIOS Mobile

For all IMAIOS subscribed members
e-Anatomy on your iPhone
for \$29.99

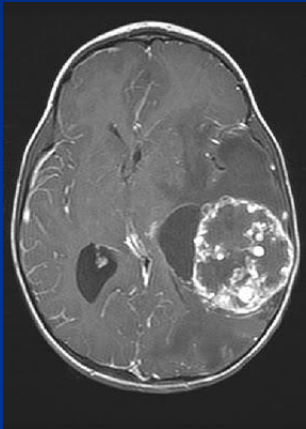


IMAIOS Lite

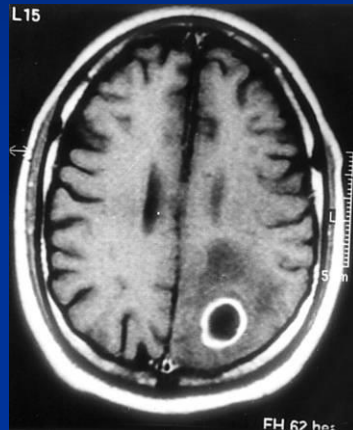
Discover e-Anatomy
4 modules for only \$3.99

Radiology of cerebral hemispheres

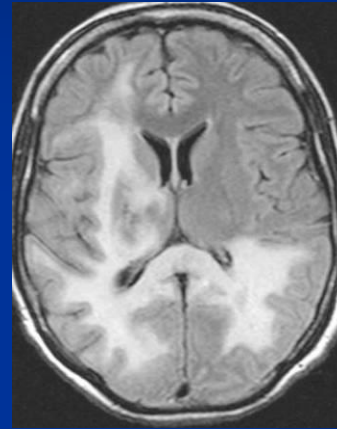
■ Beyond anatomy



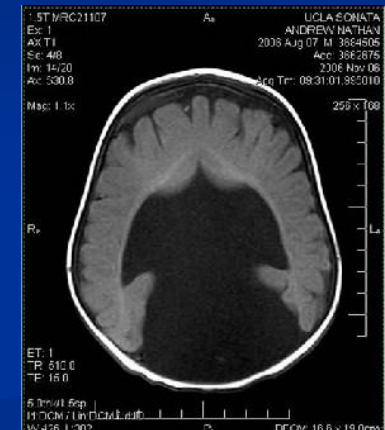
Tumor



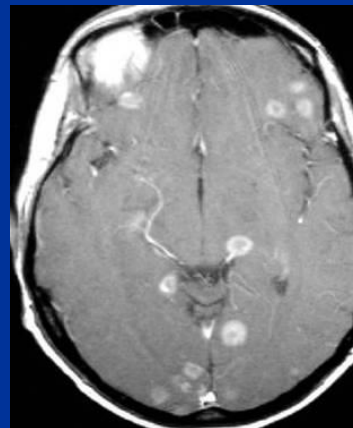
Abscess



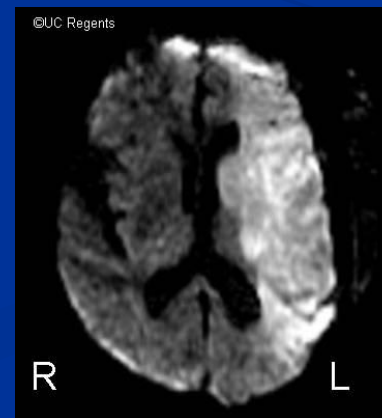
Infection



Malformation



Metastasis



Infarction

Thank you