



# ***Endocrine Block*** ***Pathology Practical***

Prepared by: 

- *Prof. Ammar Al Rikabi*
- *Dr. Sayed Al Esawy*

*Head of Pathology Department: Dr. Hisham Al Khalidi*

# Objectives:

**At the end of the practical sessions of the endocrine block, the students will be able to:**

- Identify the gross macroscopic picture of thyroid and suprarenal nodules.
- Describe the microscopic picture of thyroid adenomas and carcinomas.
- Recognize the histopathological changes found in thyroid and suprarenal tumors.

# **CONTENTS:**

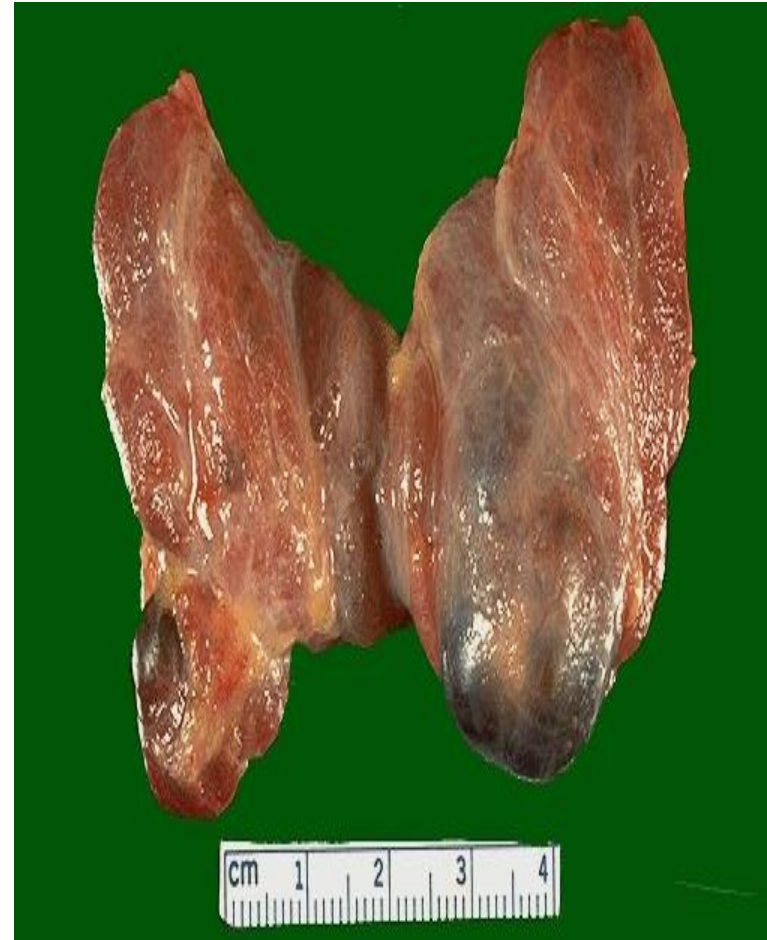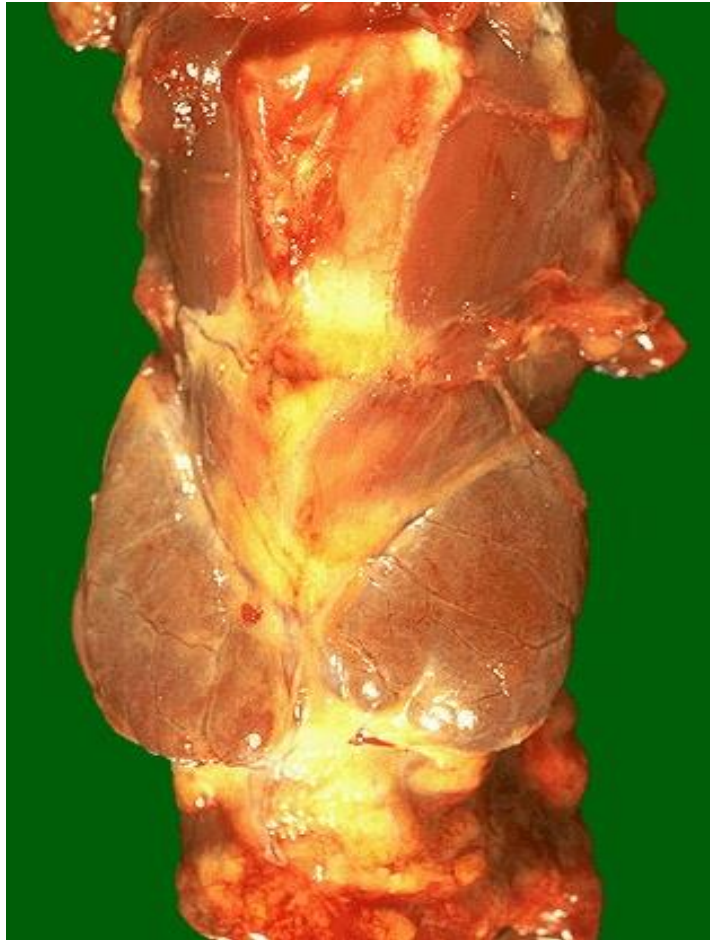**Gross pathology and histopathology section pictures of:**

- (1) Multinodular goiter.
- (2) Hashimoto's thyroiditis.
- (3) Papillary thyroid carcinoma.
- (4) Addison's disease.
- (5) Cushing syndrome.
- (6) Follicular adenoma.
- (7) Pheochromocytoma.



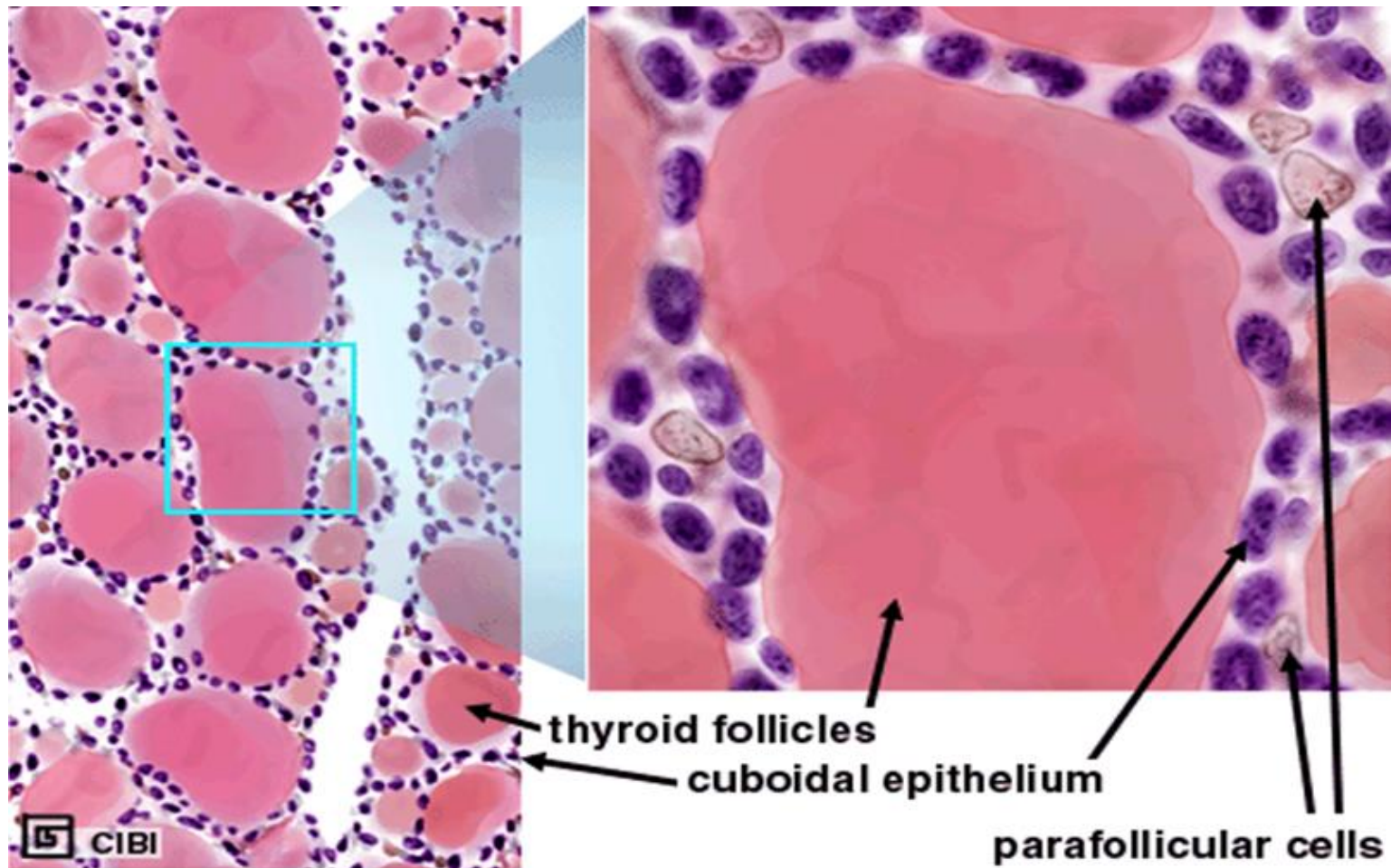
# ***Normal Anatomy & Histology***

# Normal anatomy of thyroid gland



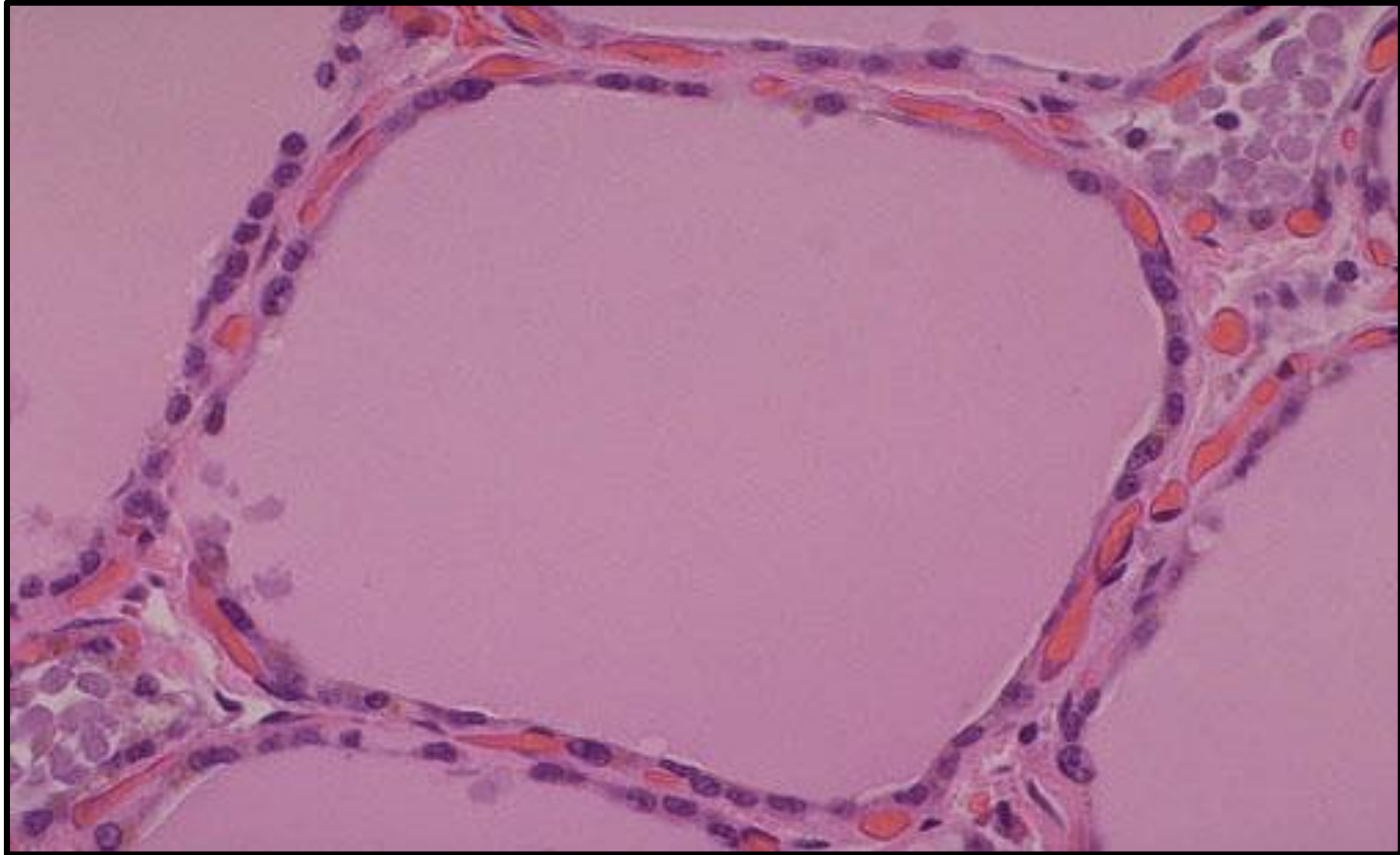
***The normal appearance of the thyroid gland (15-25 g) on the anterior trachea of the neck. The thyroid gland has a right lobe and a left lobe connected by a narrow isthmus. A normal thyroid cannot easily be palpated on physical examination***

## Normal Histology of Thyroid gland – LPF&HPF



*Normal thyroid seen microscopically consists of follicles lined by a cuboidal epithelium and filled with pink, homogenous colloid. The follicles vary somewhat in size. The interstitium, which may contain "C" cells, is not prominent.*

## Normal Histology of Thyroid gland - HPF



*This normal thyroid follicle is lined by a cuboidal follicular epithelium with cells that can add or subtract colloid depending upon the degree of stimulation from TSH (thyroid stimulating hormone) released by the pituitary gland. As in all endocrine glands, the interstitium has a rich vascular supply into which hormone is secreted.*



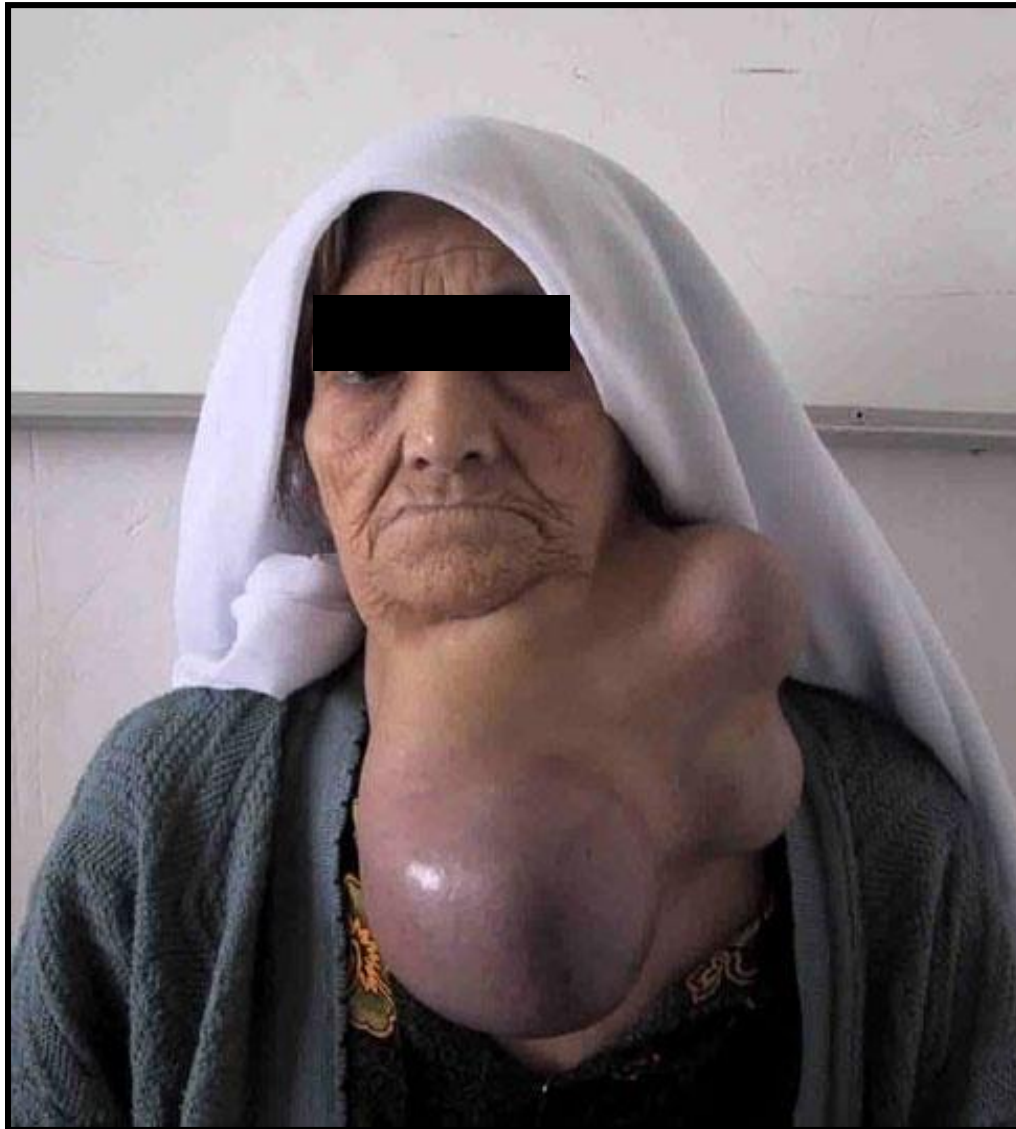# ***Gross and Histopathology***



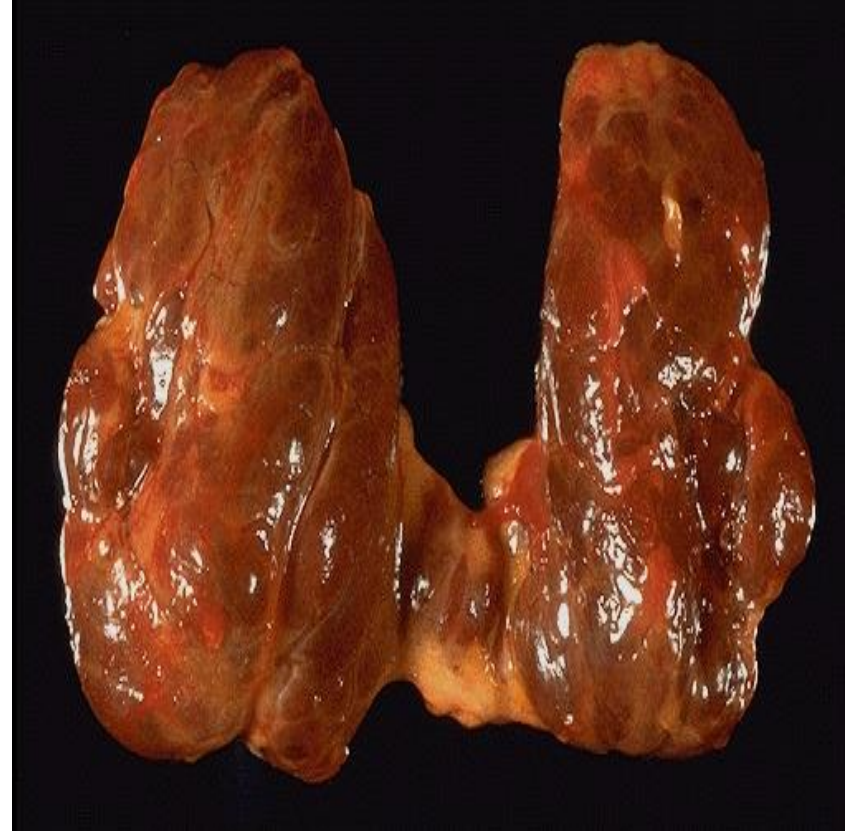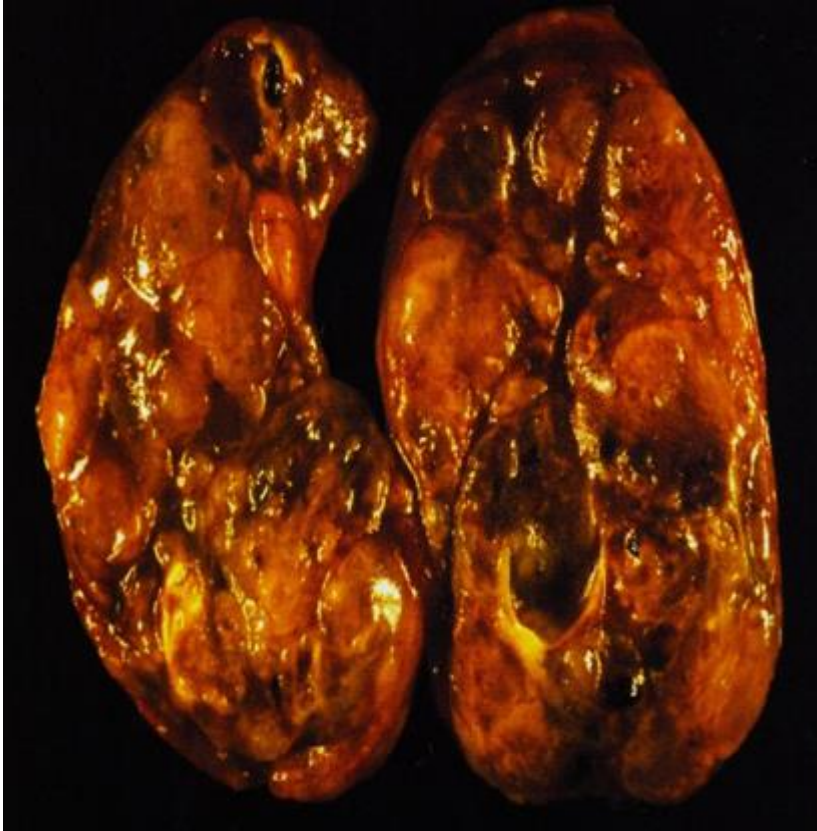


# ***1- Multinodular Goiter***

# *Multinodular Goiter – Clinical*

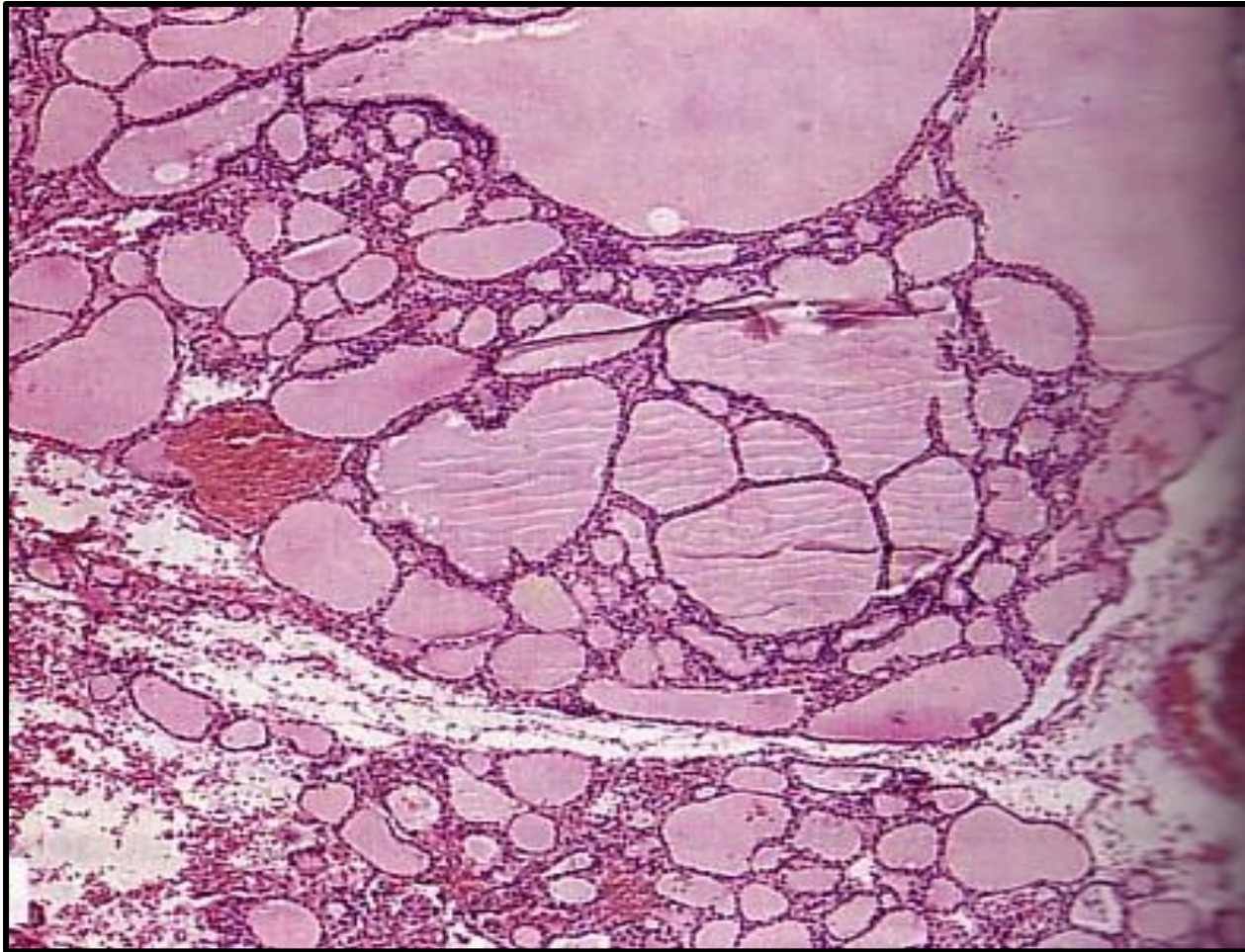

## ***Multinodular Goiter - Gross***



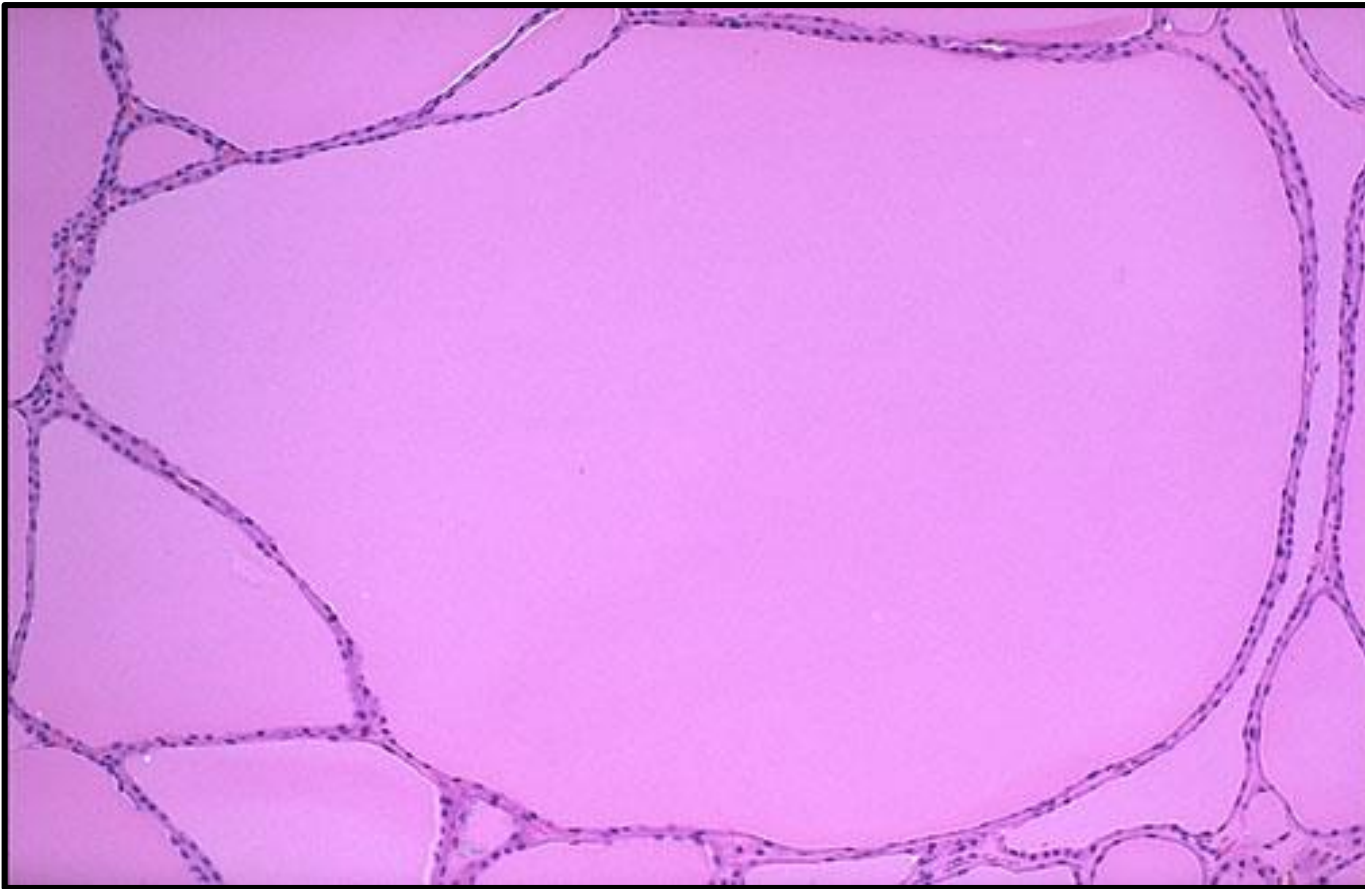
***This diffusely asymmetric enlarged thyroid gland is nodular with haemorrhage and cystic degeneration. This patient was euthyroid. This represents the most common cause for an enlarged thyroid gland and the most common disease of the thyroid***

## *Multinodular Goiter - LPF*



*Numerous follicles varying in size filled with colloid. We can also see : Recent haemorrhage , Haemosiderin , Calcification & Cystic degeneration*

## ***Multinodular Goiter - LPF***



***The follicles are irregularly enlarged, with flattened epithelium, consistent with inactivity, in this microscopic appearance at low power of a multinodular goiter.***



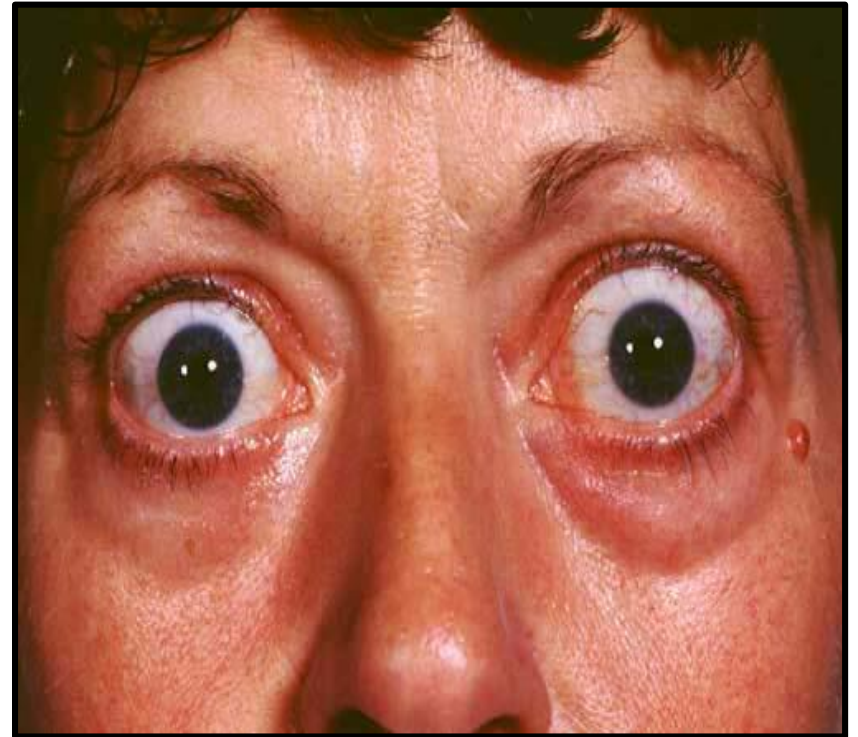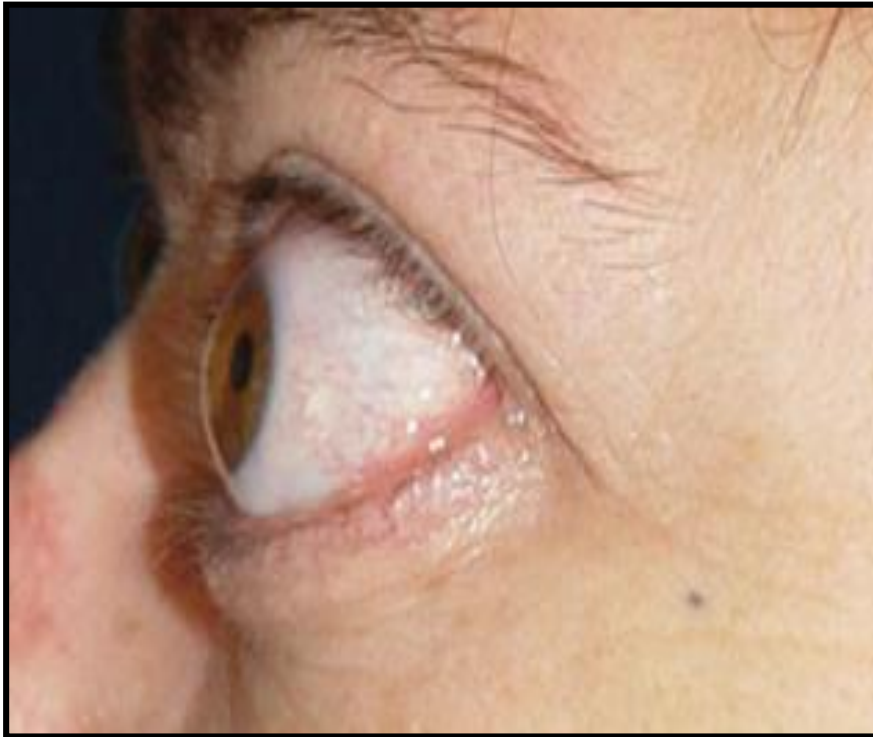
## ***2- Hyperthyroidism & Grave's Disease***

# ***HYPERTHYROIDISM***

## ***CLINICALLY:***

- ***Hypermetabolism***
- ***Tachycardia, palpitations***
- ***Increased T<sub>3</sub>, T<sub>4</sub>***
- ***Goiter***
- ***Exophthalmos***
- ***Tremor***
- ***GIT hypermotility***
- ***Thyroid "storm", life threatening***

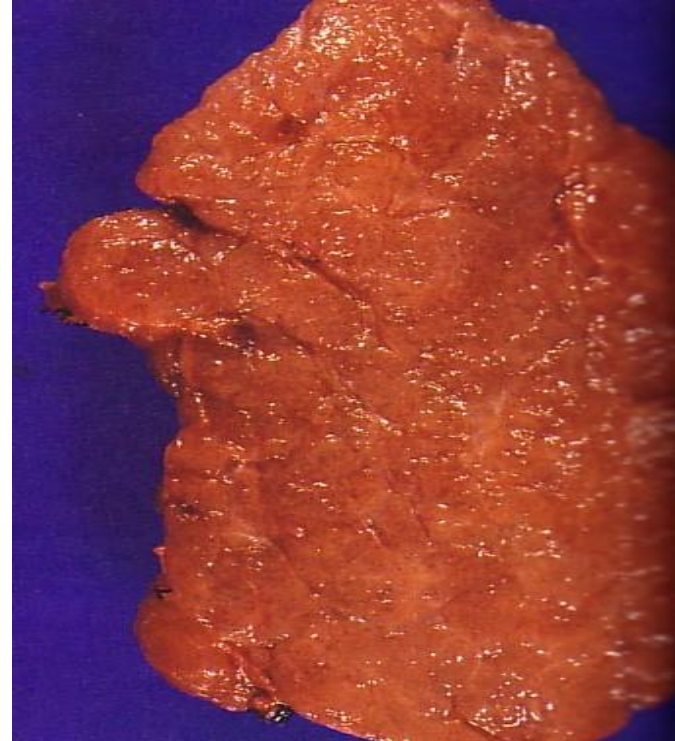
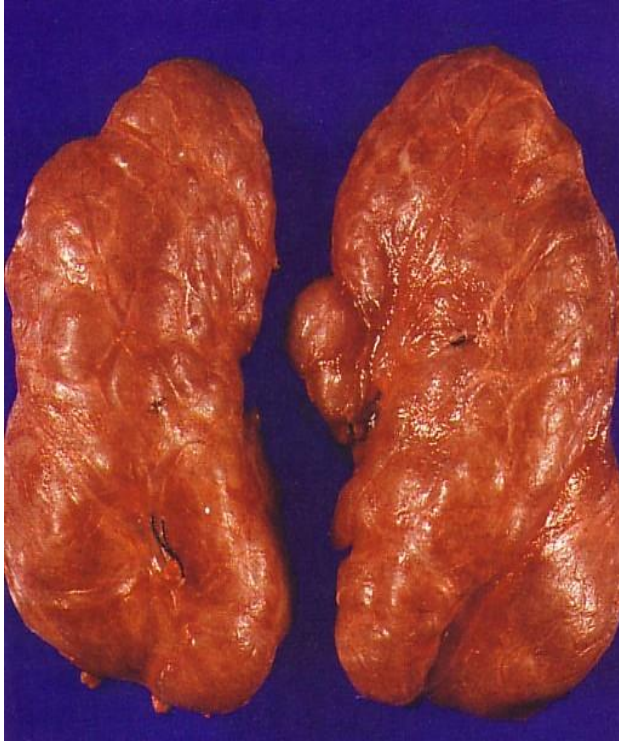## *Exophthalmos – Sign of Grave's Disease*



*Proptosis, Lid lag , Lid retraction , Peri-ocular fat deposition  
and Scleral rim above the iris*

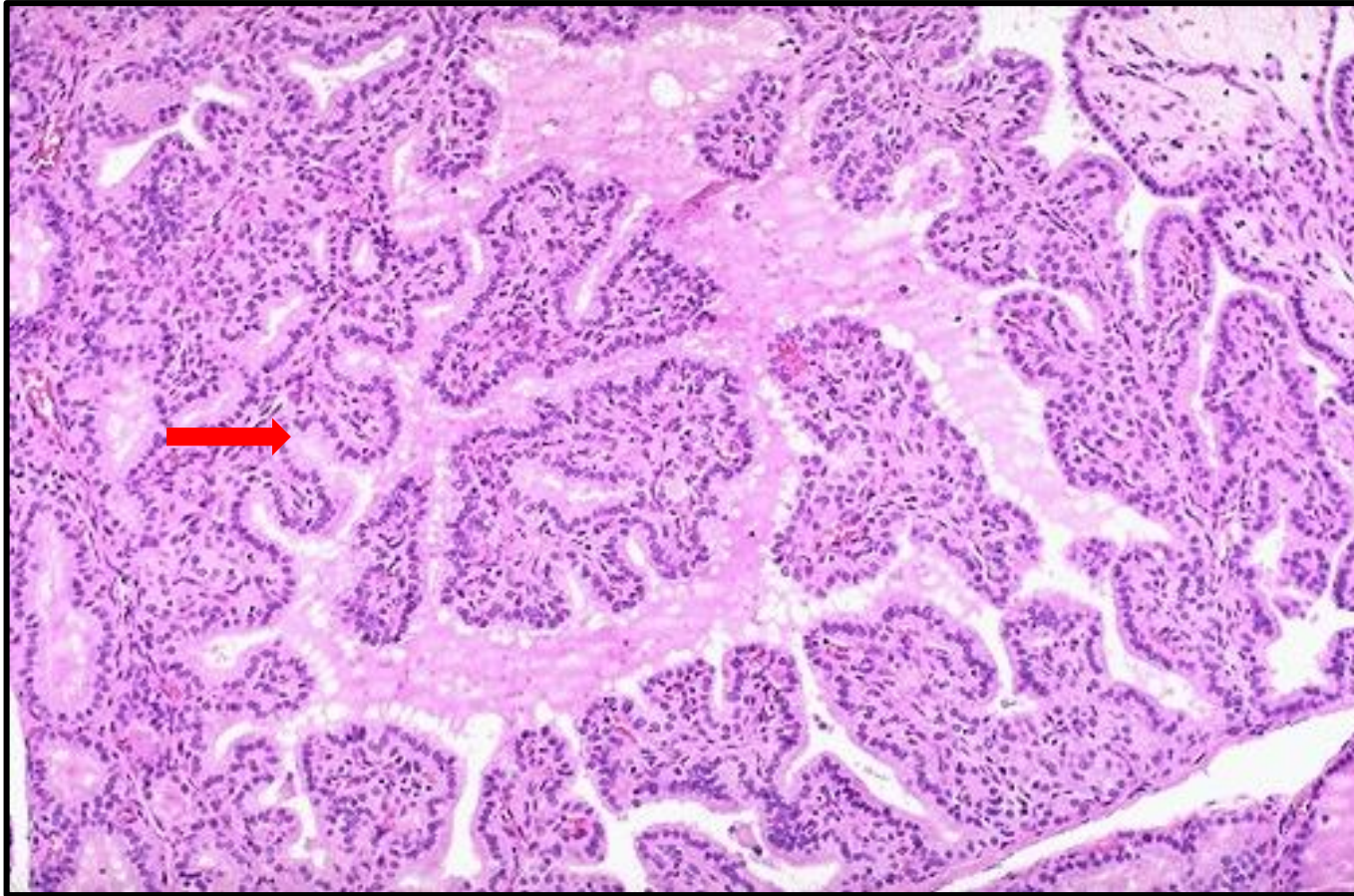


# *Grave's Disease - Gross*



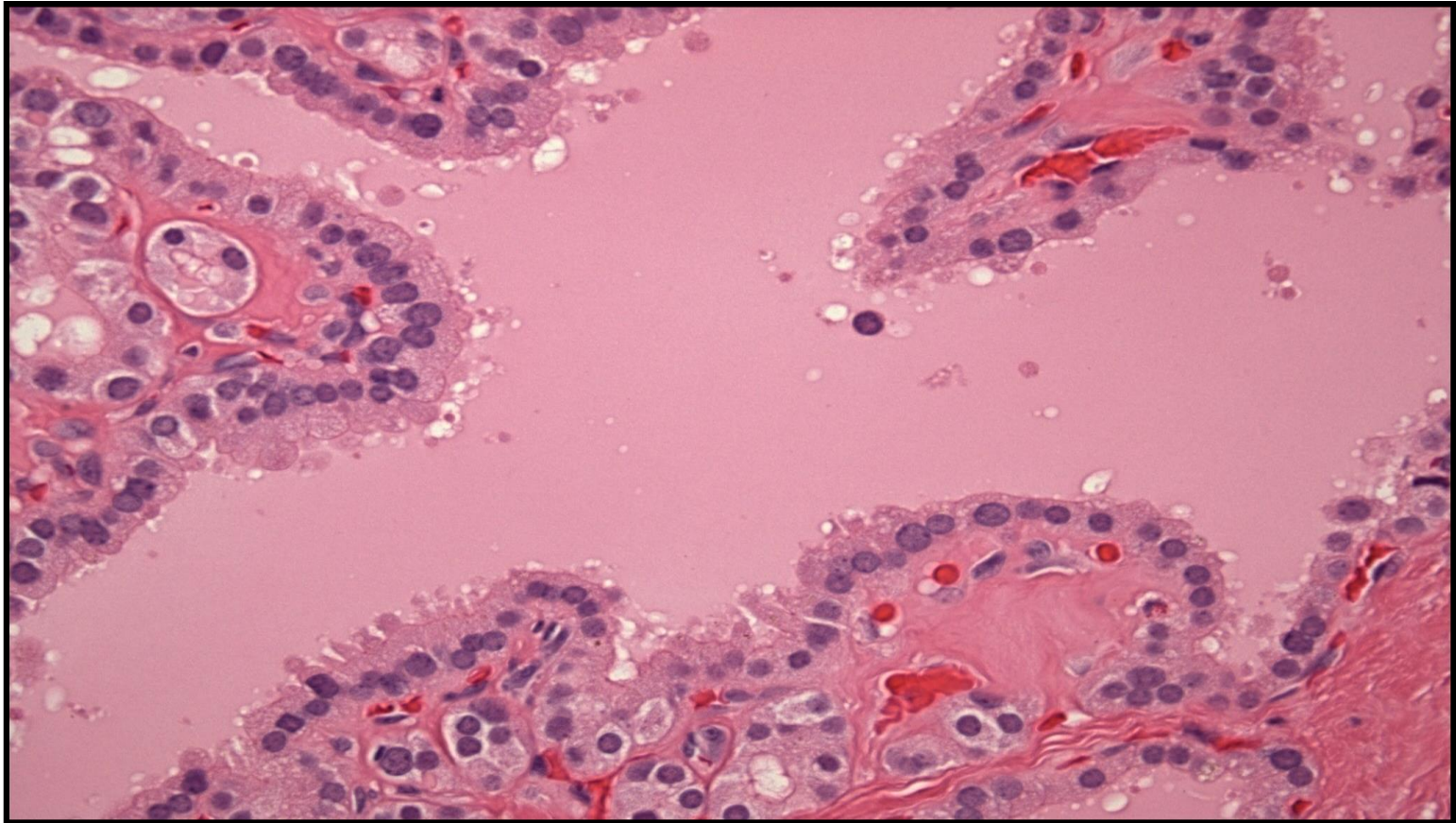
- *Symmetrical enlargement of thyroid gland*
- *Cut-surface is homogenous, soft and appear meaty*
- *Hyperplasia and hypertrophy of follicular cells*

## *Grave's Disease - LPF*



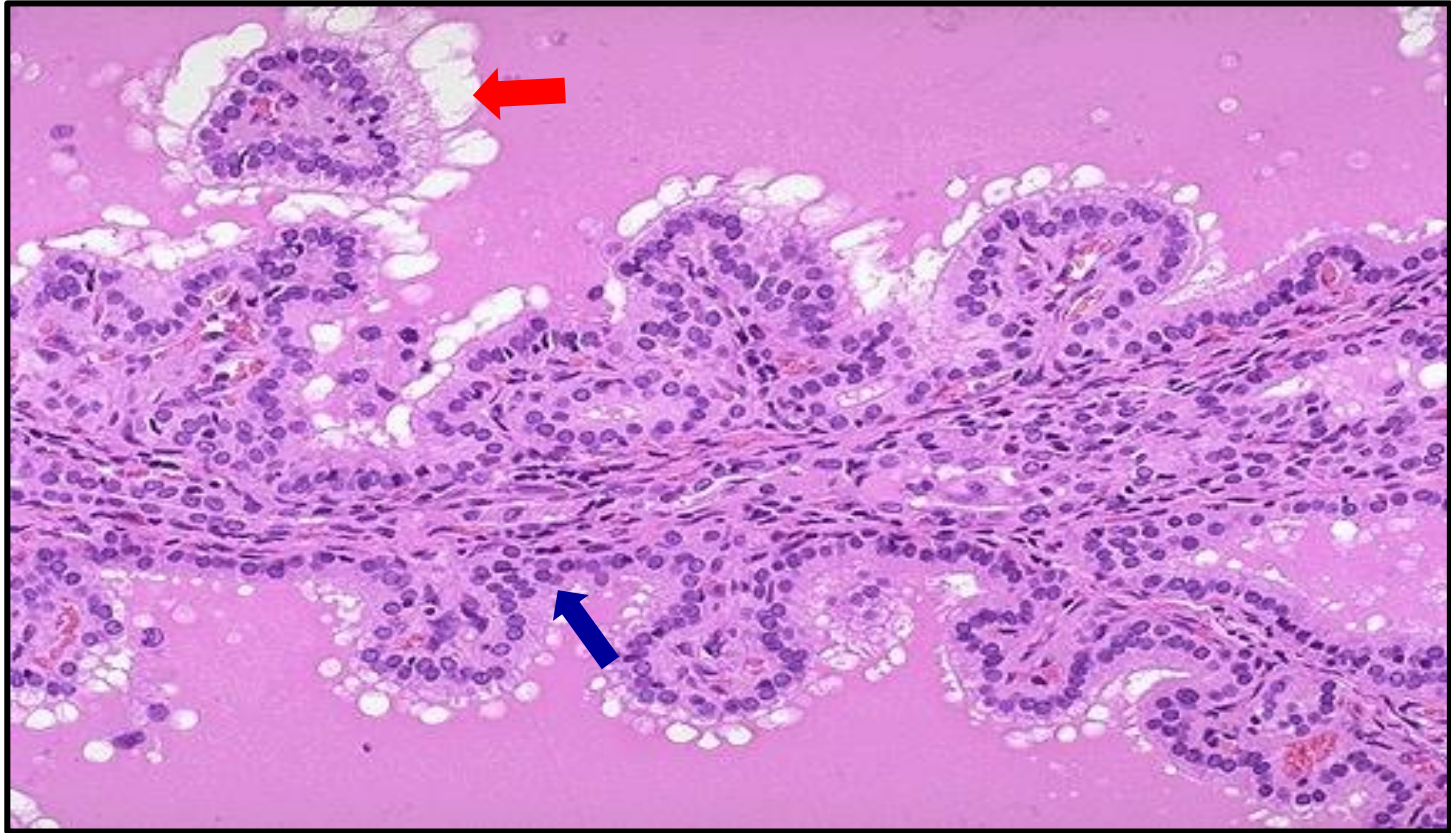
*A diffusely enlarged thyroid gland associated with hyperthyroidism is known as Graves disease. At LPF, note the prominent **infoldings** of the hyperplastic follicular epithelium*

# Grave's Disease - HPF



*Section shows thyroid follicles lined by columnar and high cuboidal cells with evidence of peripheral vacuoles within the intrafollicular colloid material . Note the presence of peripheral smaller thyroid follicles devoid of colloid but lined by similar cells*

# Grave's Disease - HPF

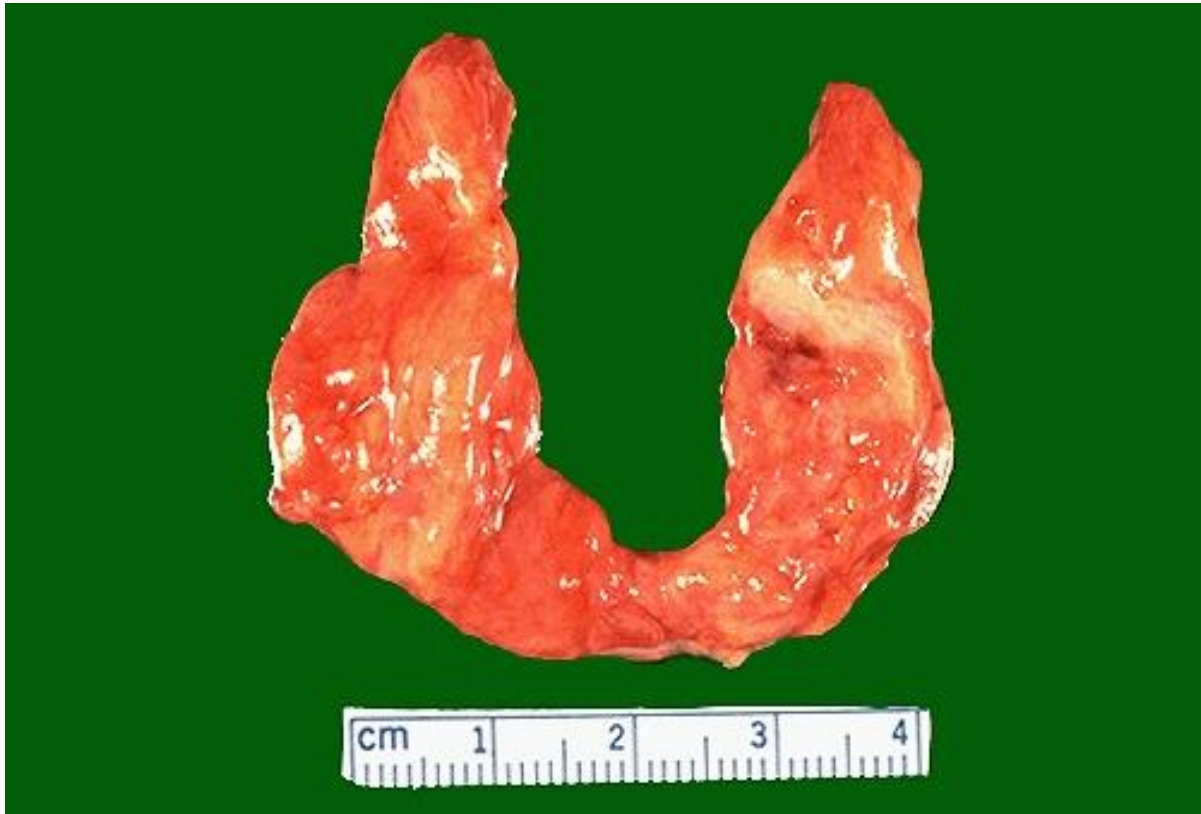

The tall columnar thyroid epithelium in Graves disease lines the **hyperplastic infoldings** into the colloid. Note the **clear vacuoles** in the colloid next to the epithelium where the increased activity of the epithelium to produce increased thyroid hormone has led to scalloping out of the colloid in the follicle.



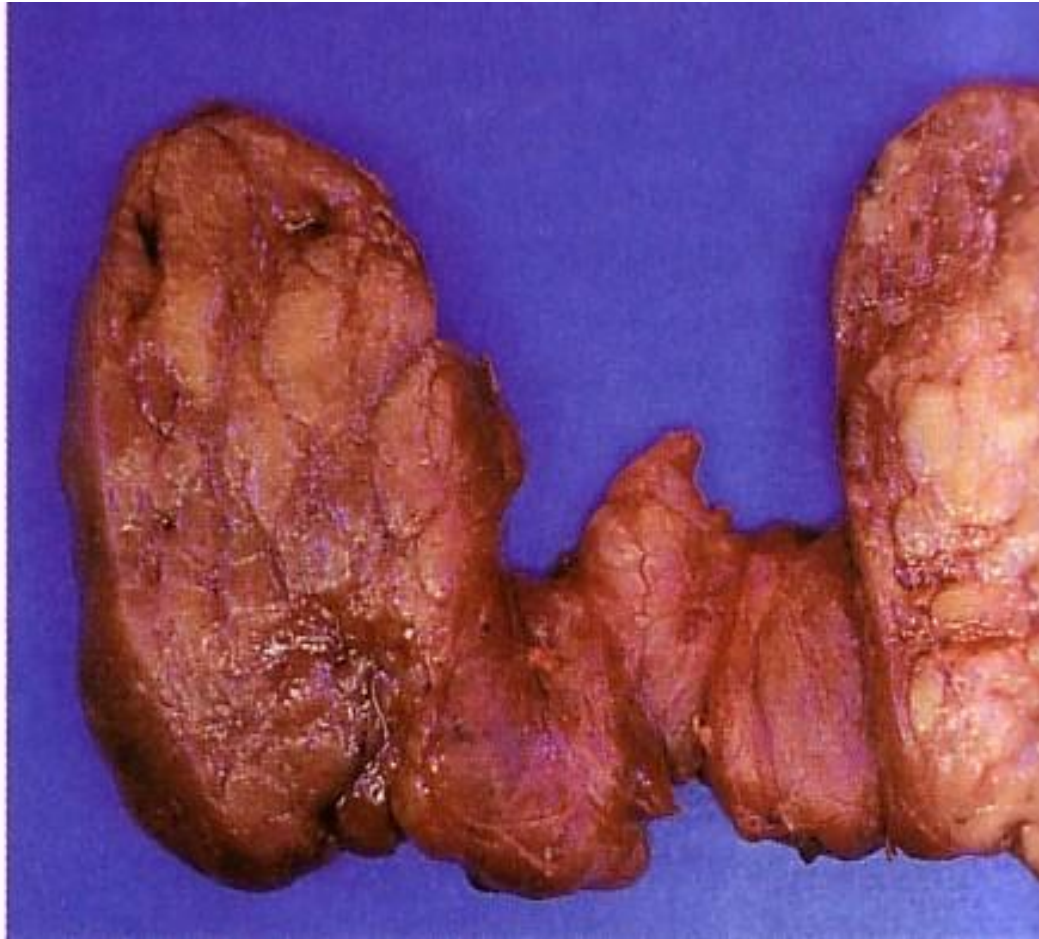
# ***3- Hashimoto's Thyroiditis***

## *Hashimoto's Thyroiditis, Gross*



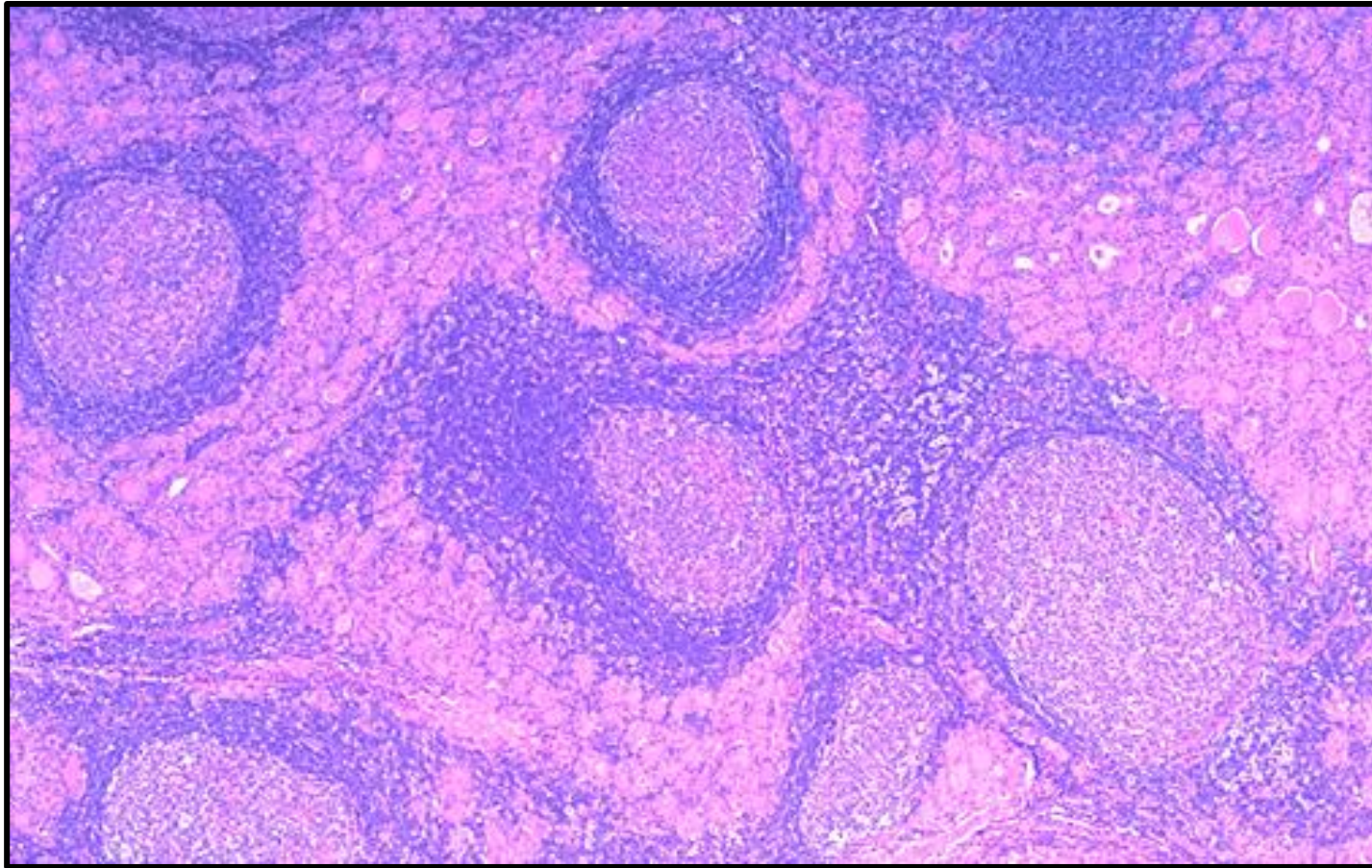
*This symmetrically small thyroid gland demonstrates atrophy. This patient was hypothyroid. This is the end result of Hashimoto's thyroiditis. Initially, the thyroid is enlarged and there may be transient hyperthyroidism, followed by a euthyroid state and then hypothyroidism with eventual atrophy years later.*

## *Hashimoto's Thyroiditis - Gross*



- *Diffuse enlargement.*
- *Firm or rubbery.*
- *Pale, yellow-tan, firm & somewhat nodular cut surface*

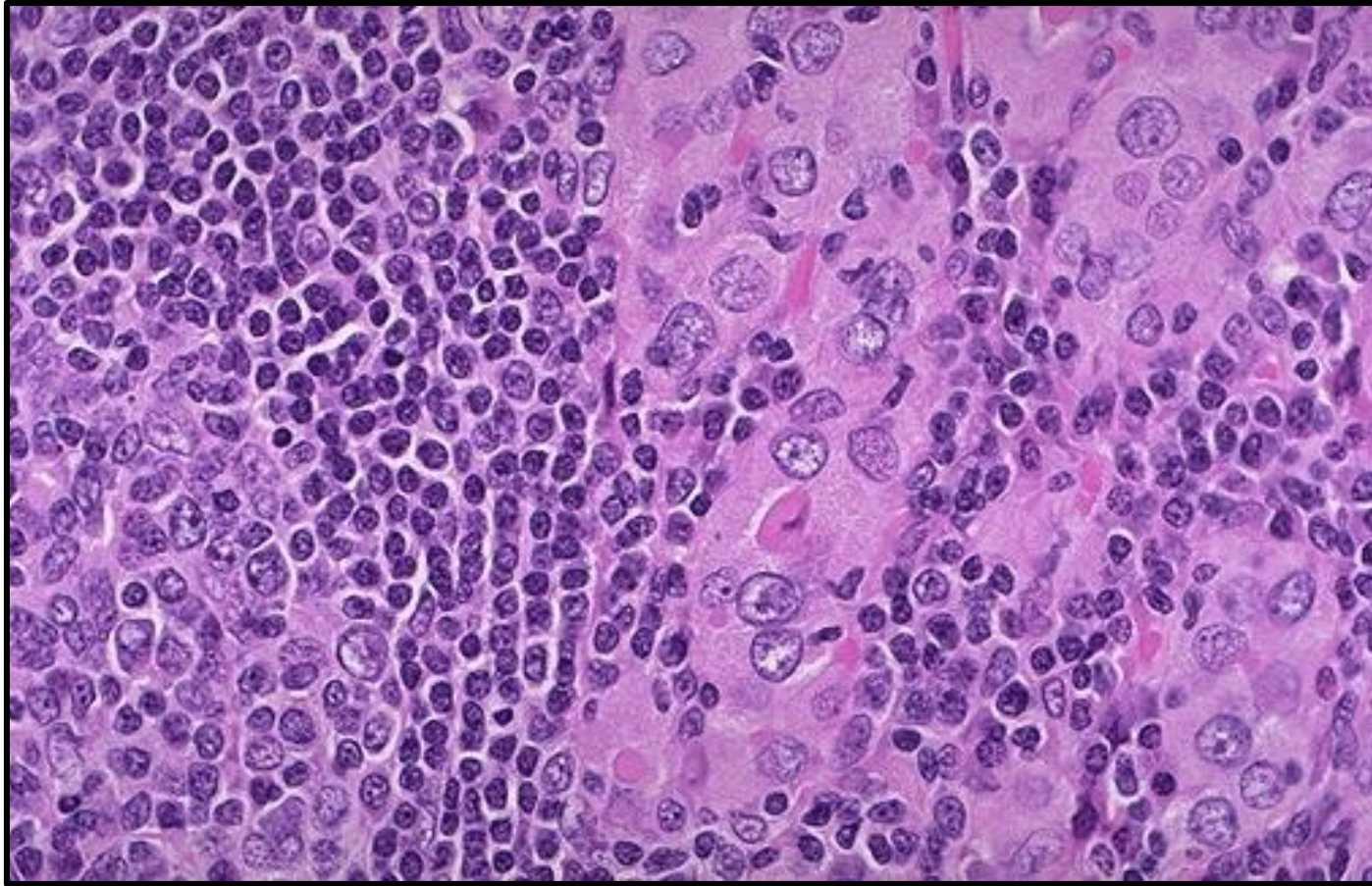
## *Hashimoto's Thyroiditis - LPF*



*This view shows an early stage of Hashimoto thyroiditis with prominent lymphoid follicles containing large, active germinal centers. In this autoimmune disease, antithyroglobulin and antimicrosomal (thyroid peroxidase) autoantibodies can often be detected in serum.*



## *Hashimoto's Thyroiditis - HPF*

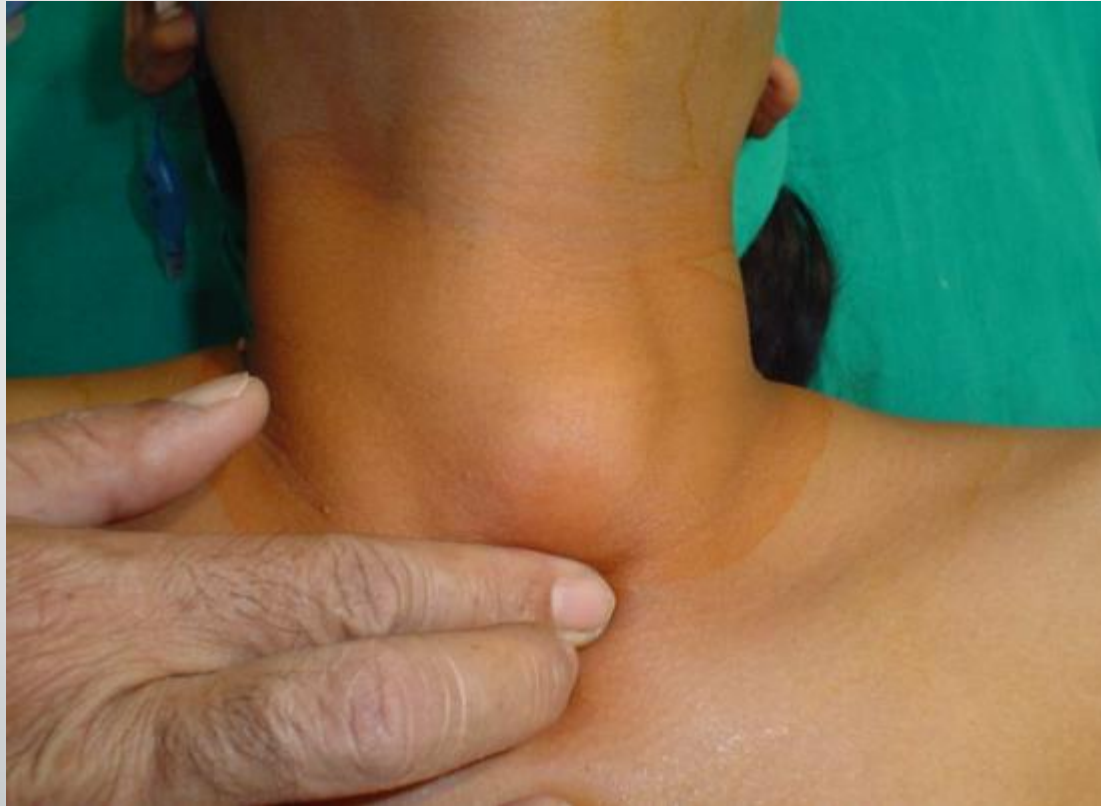

*This HPF view demonstrates the pink Hürthle cells at the center and right. The lymphoid follicle is at the left. Increased interstitial connective tissue. Hashimoto's thyroiditis initially leads to painless enlargement of the thyroid, followed by atrophy years later.*

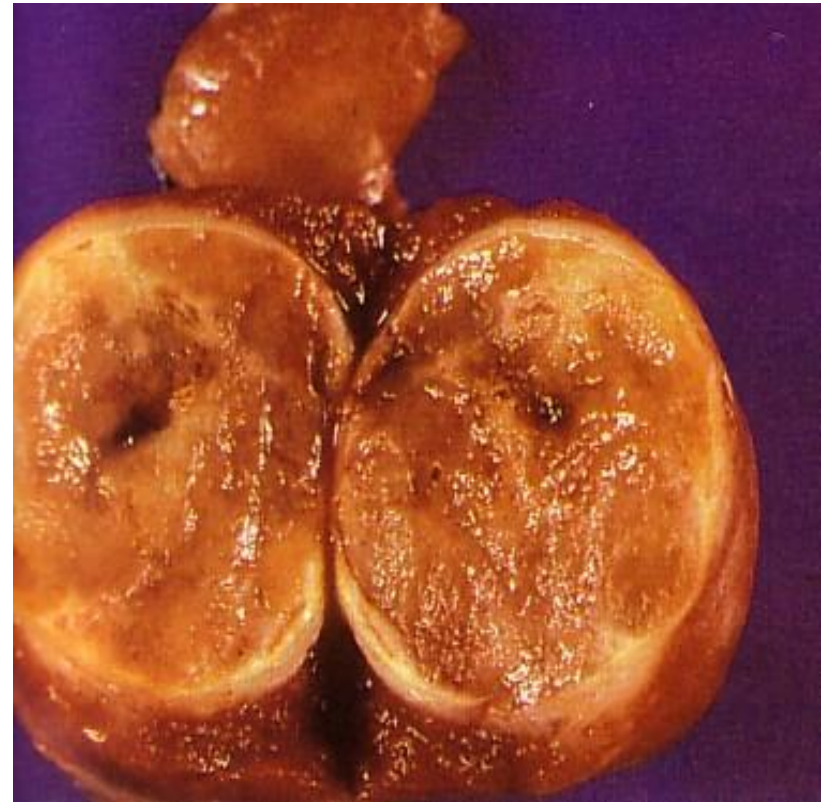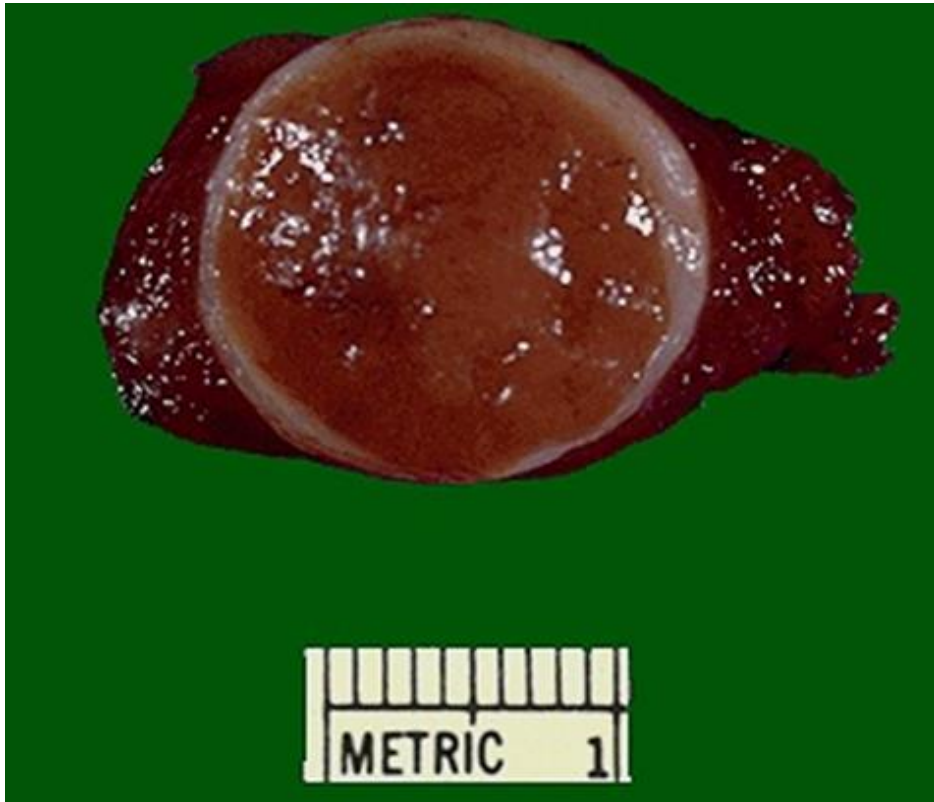


# ***4- Follicular Adenoma***

# *Solitary Thyroid nodule*

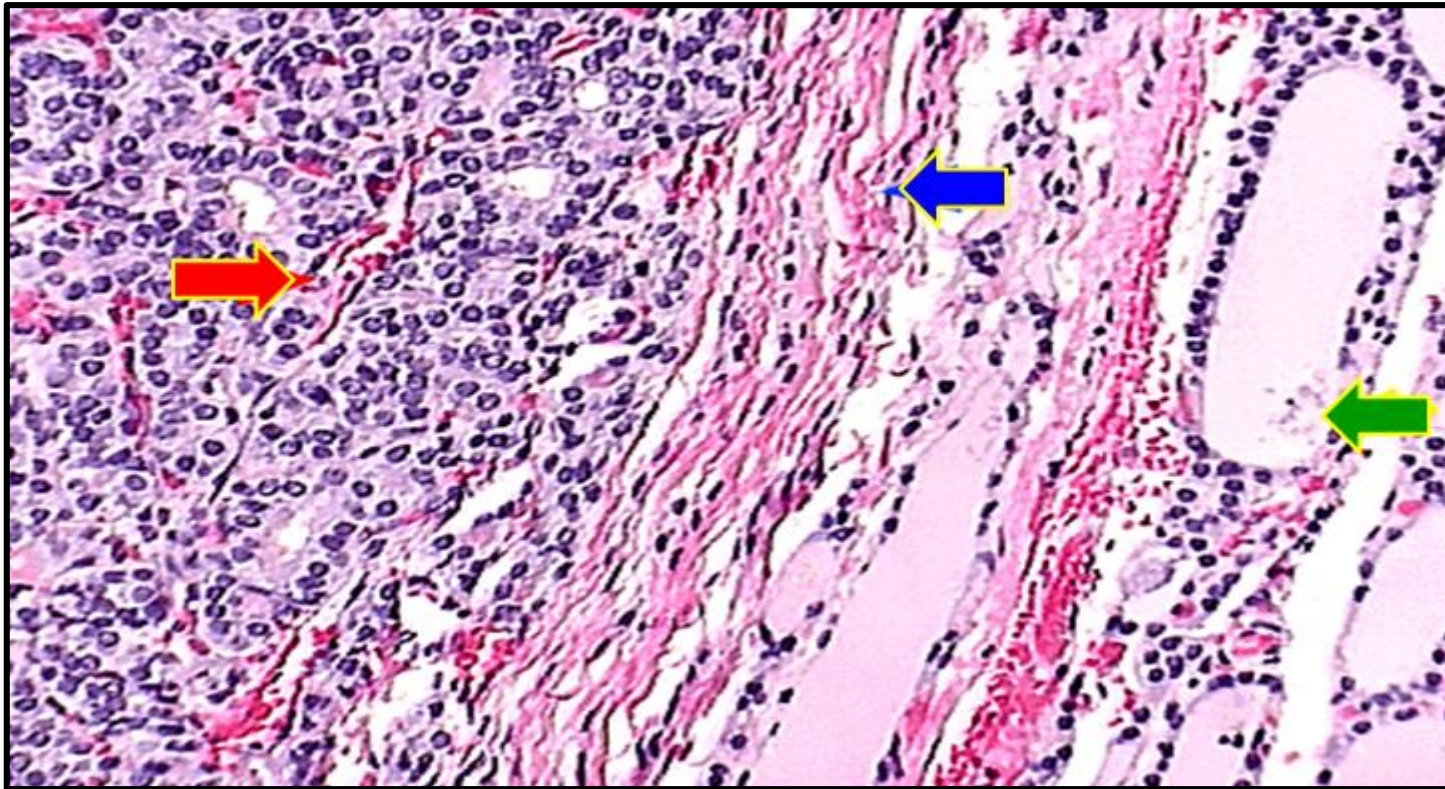


## *Follicular Adenoma – Gross cut section*



*A well circumscribed light brown and circular tumor nodule which is surrounded by a thick and whitish capsule  
The surrounding thyroid tissue is unremarkable .  
The features are consistent with a follicular adenoma of thyroid gland .*

## Follicular Adenoma – LPF

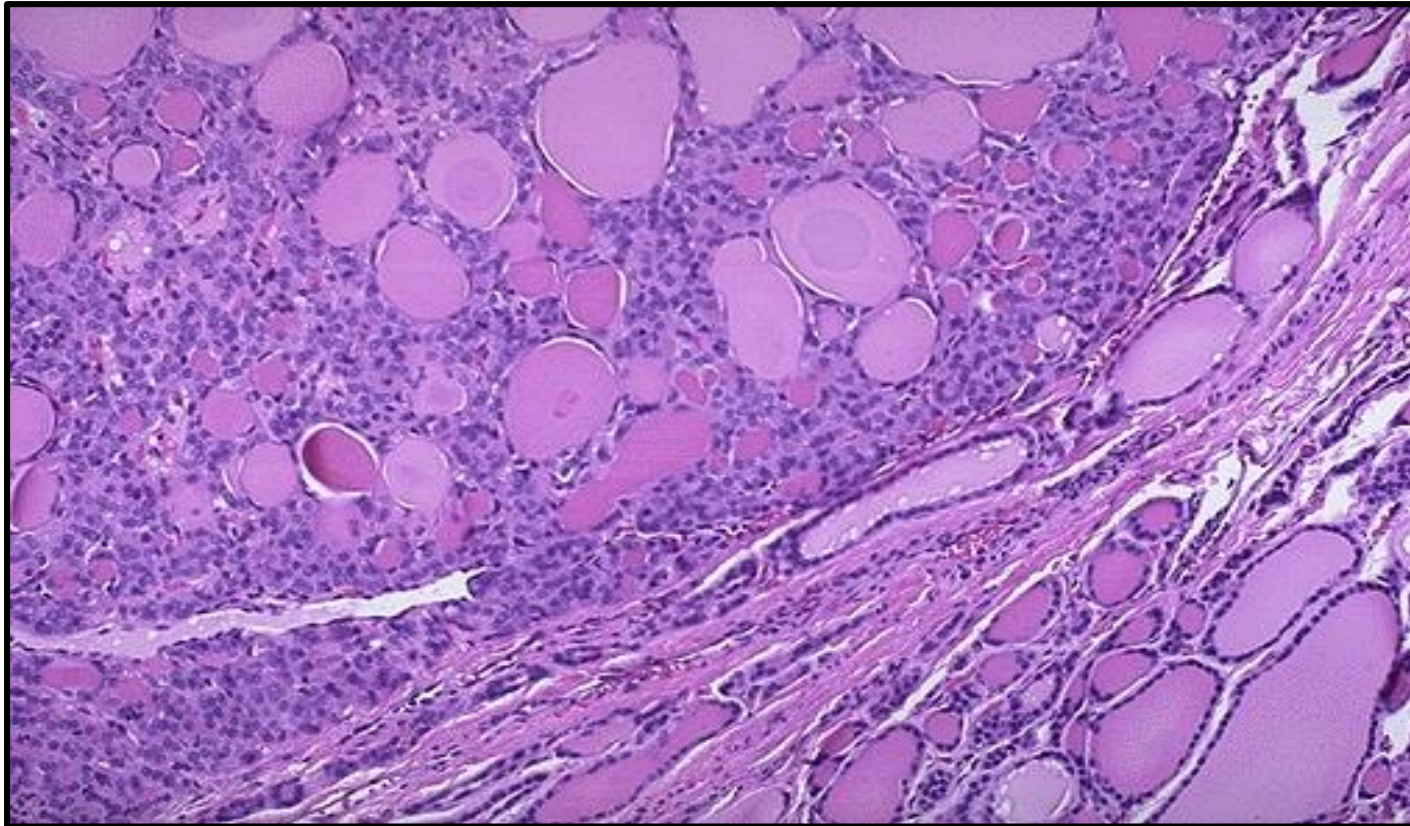


The **Red arrow** is located within the adenoma. Although composed of follicular cells, little colloid is seen.


The **Blue arrow** points to the capsule of the adenoma, a few strands of connective tissue.

The **Green arrow** points to colloid within a large normal follicle.

## ***Follicular Adenoma – HPF***

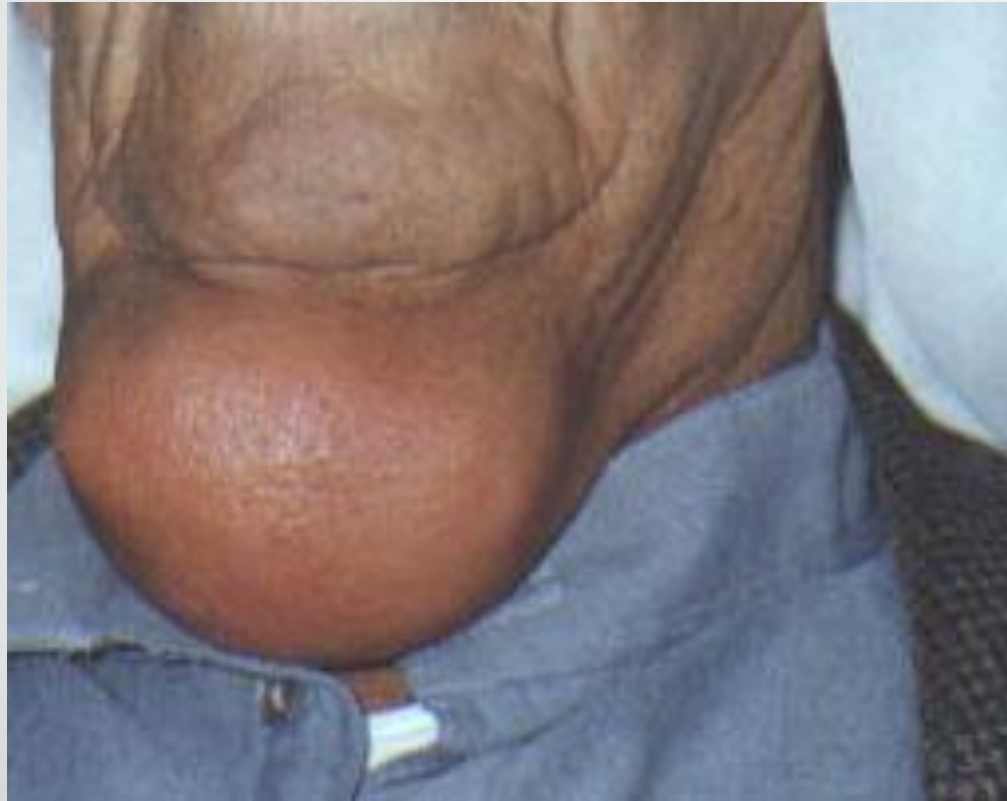

***Normal thyroid follicles appear at the lower right. The follicular adenoma is at the center to upper left. This adenoma is a well- differentiated neoplasm because it closely resemble normal tissue. The follicles of the adenoma contain colloid, but there is greater variability in size than normal.***



# ***5- Papillary Thyroid Carcinoma***

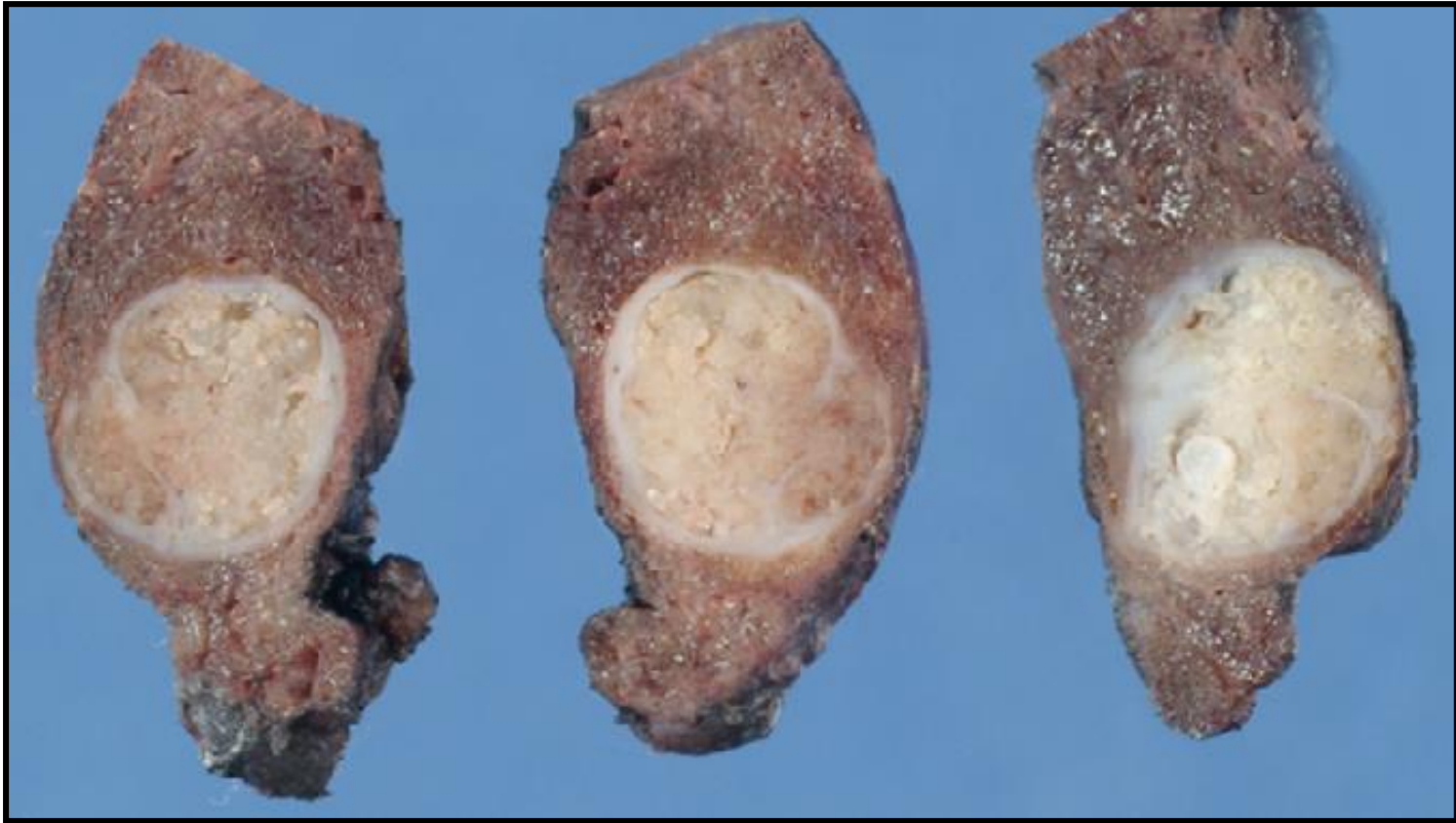
# *Papillary Thyroid Carcinoma*



*Huge thyroid swelling due to papillary thyroid carcinoma*

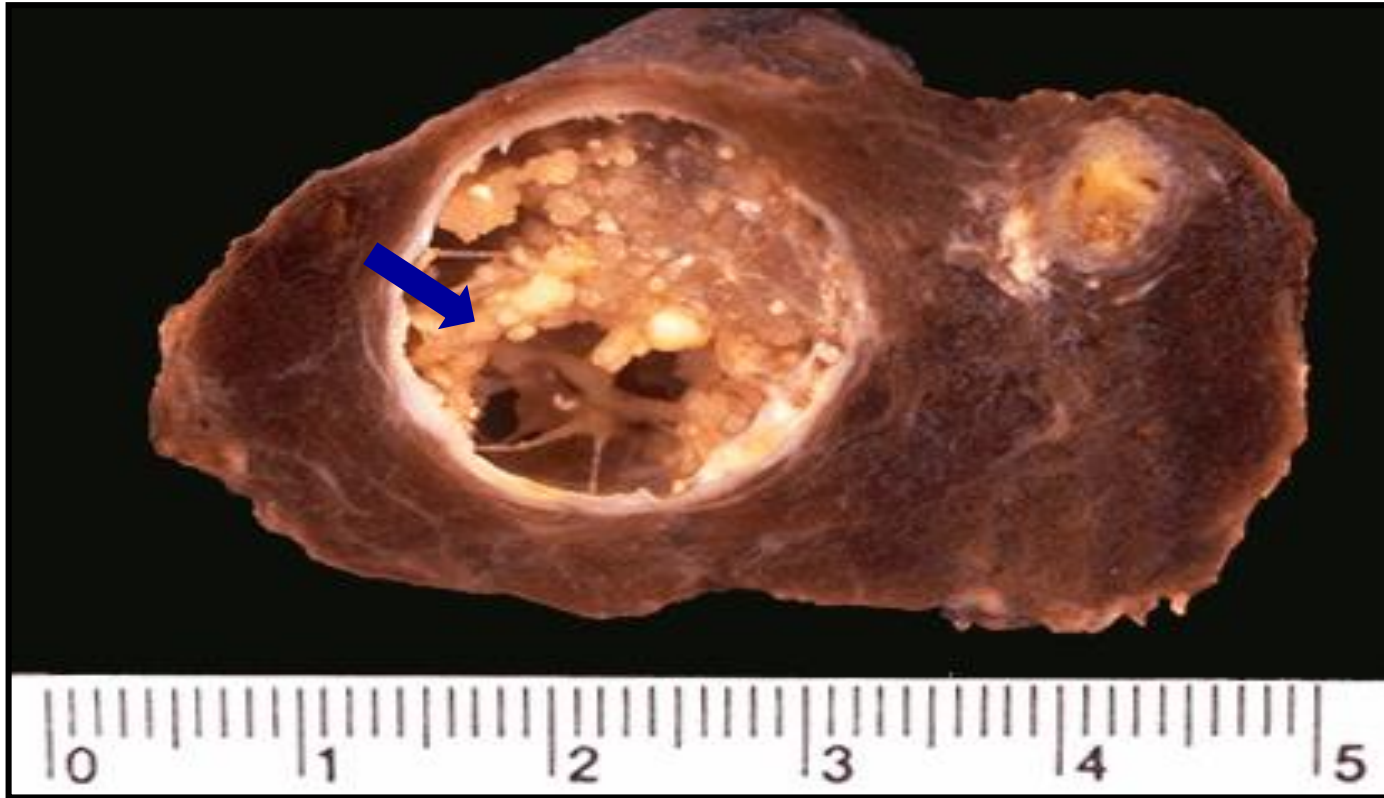

## *Papillary Thyroid Carcinoma– Gross*



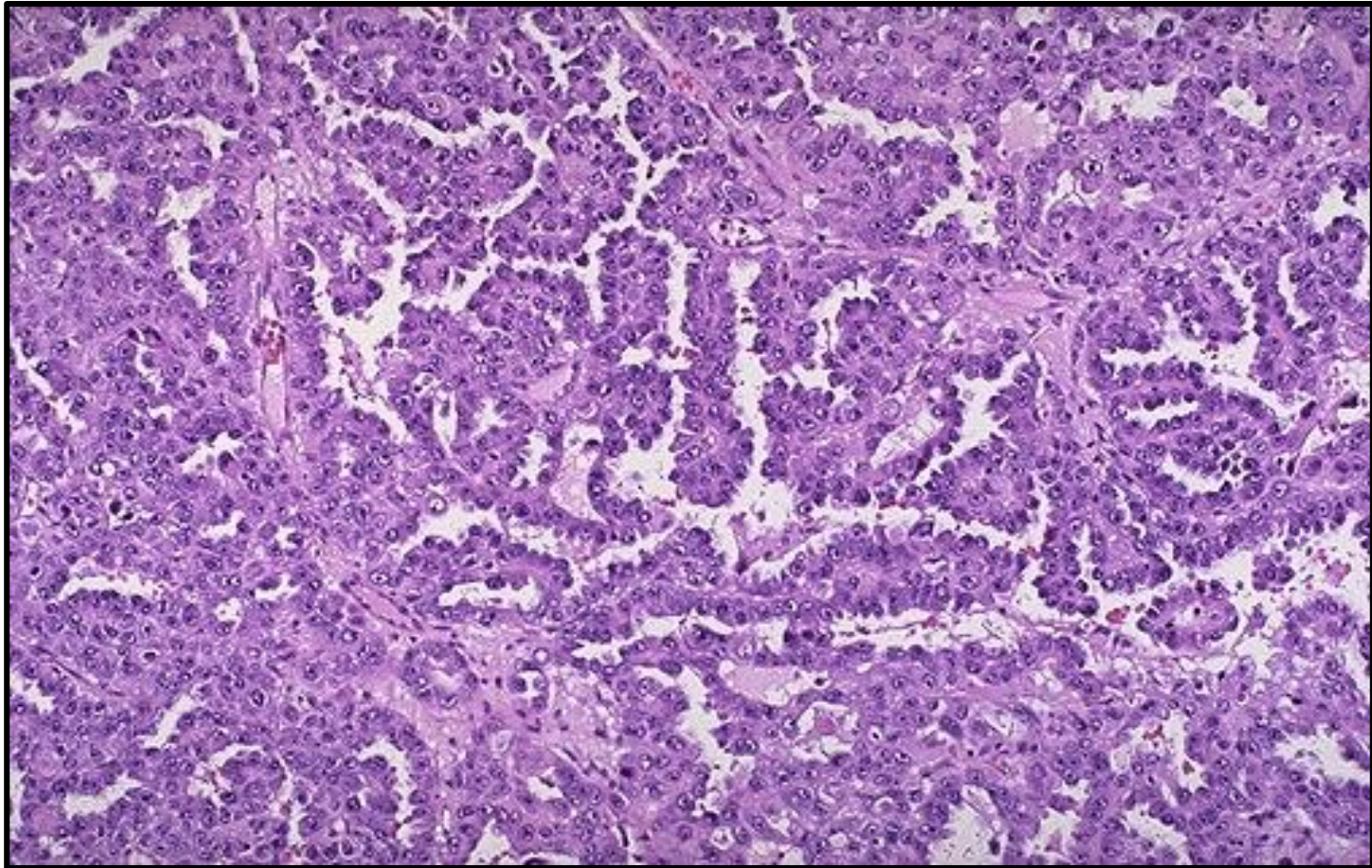
*A relatively well circumscribed pale and firm nodule showing a whitish cut surface with vague scattered papillary areas .*

# *Multifocal Papillary Thyroid Carcinoma– Gross cut section*



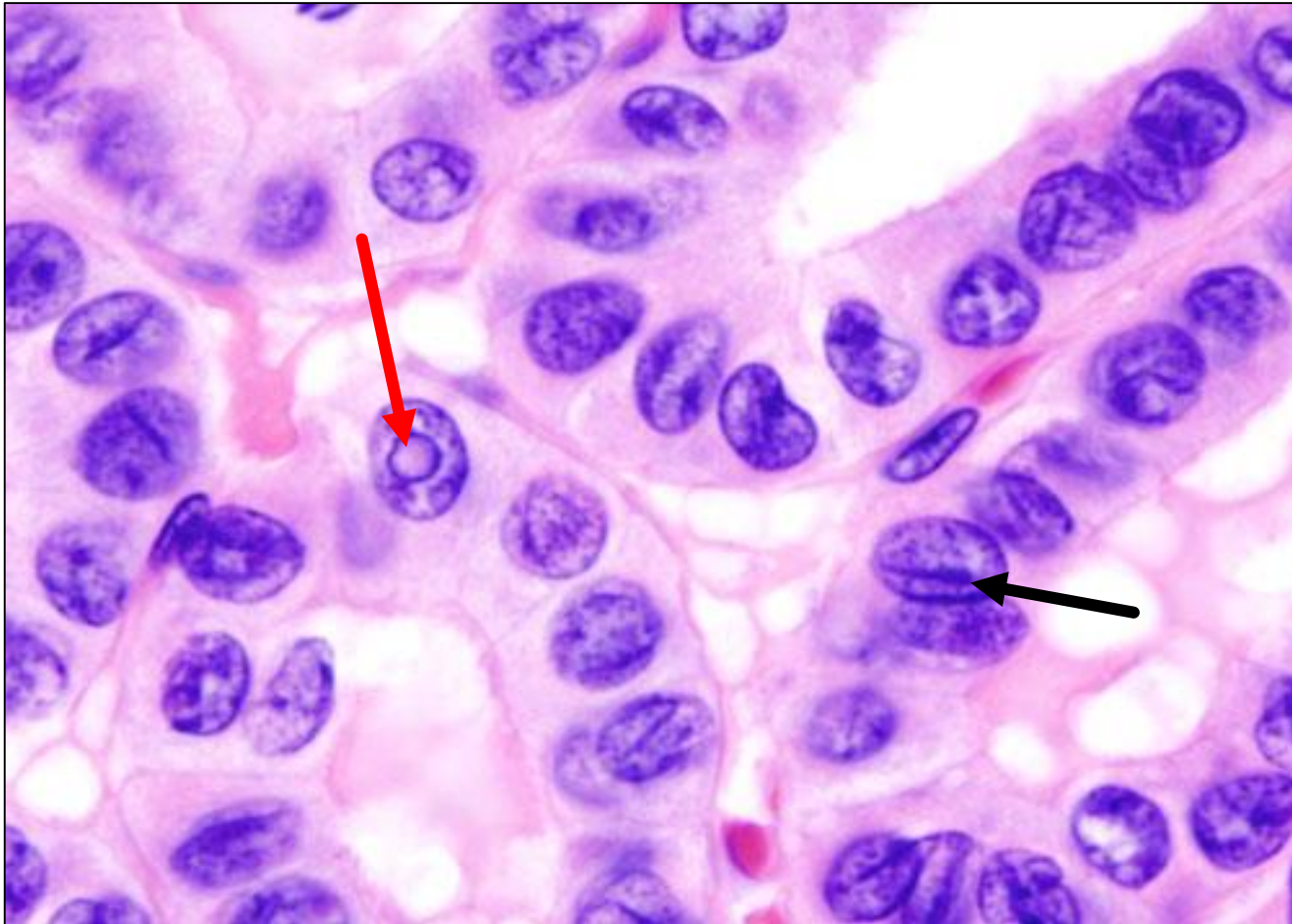
*Sectioning through a lobe of excised thyroid gland reveals a papillary carcinoma. This neoplasm can be multifocal, as seen here, because of the propensity of this neoplasm to invade lymphatics within thyroid, and lymph node metastases are also common. The larger mass shown here is cystic and contains **papillary excrescences***

## *Papillary Thyroid Carcinoma– LPF*



*Sections show a papillary neoplasm consisting of papillary fronds lined by overlapping clear nuclei (Orphan Annie nuclei).  
Calcified Psammoma bodies are also seen*

## *Papillary Thyroid Carcinoma– HPF*



*High power microscopic field showing a classical papillary carcinoma of the thyroid gland. Note the presence of intranuclear inclusion (red arrow) and coffee bean nucleus with prominent nuclear groove (black arrow)*

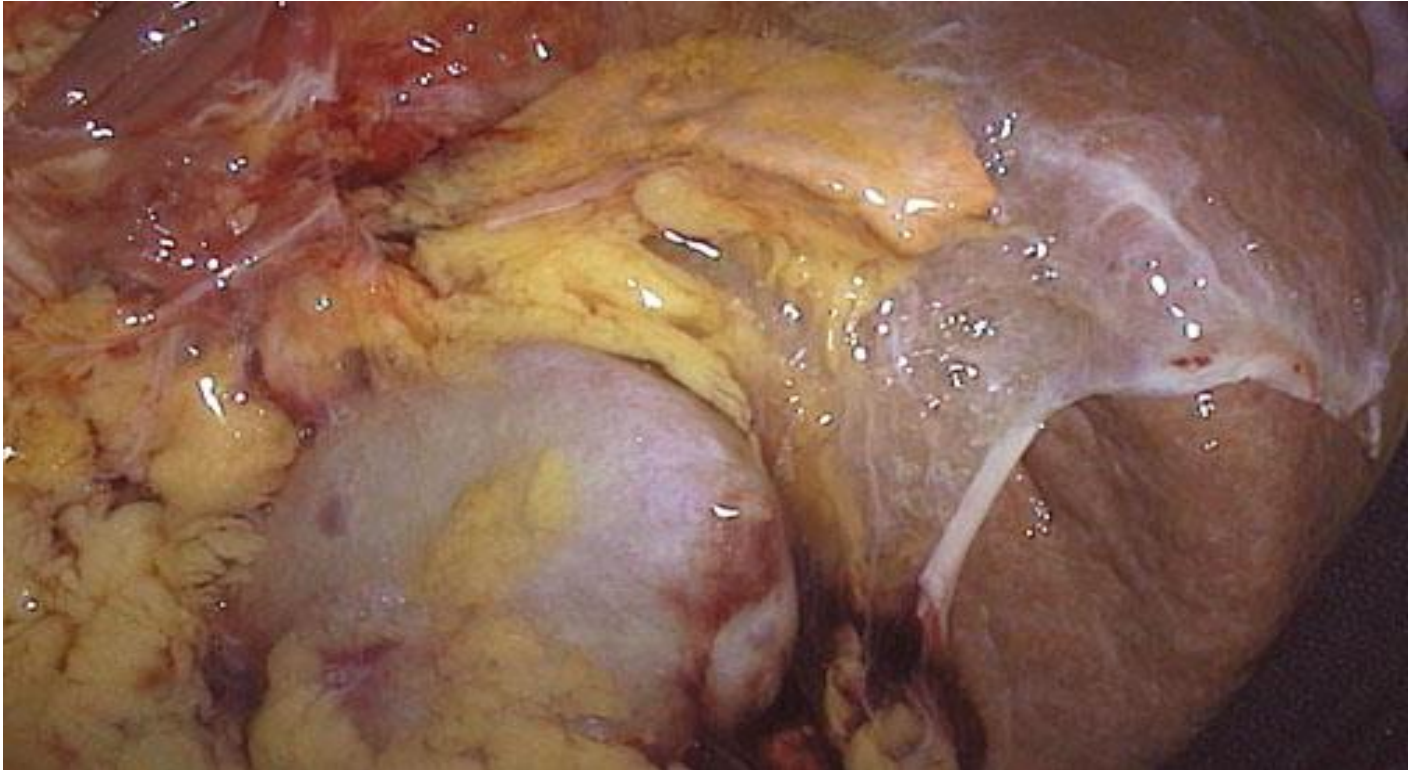


# ***ADRENAL GLAND***



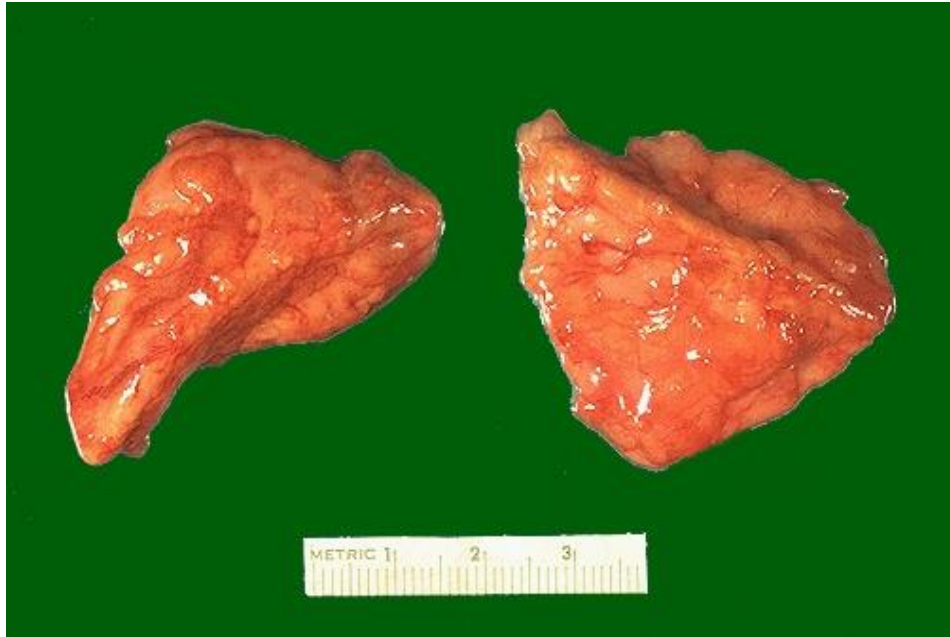# ***Pheochromocytoma***

## Adrenal Gland – In situ

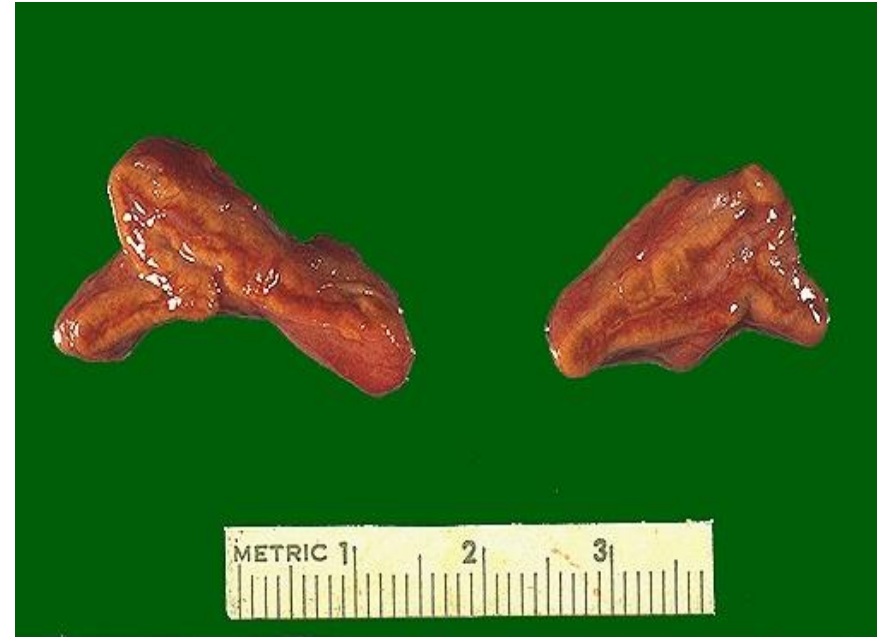

*A normal right adrenal gland is shown here positioned between the liver and the kidney in the retroperitoneum. Note the amount of adipose tissue, some of which has been reflected to reveal the upper pole of the kidney and the adrenal.*

# Adrenal Gland – Normal Gross & Cross section



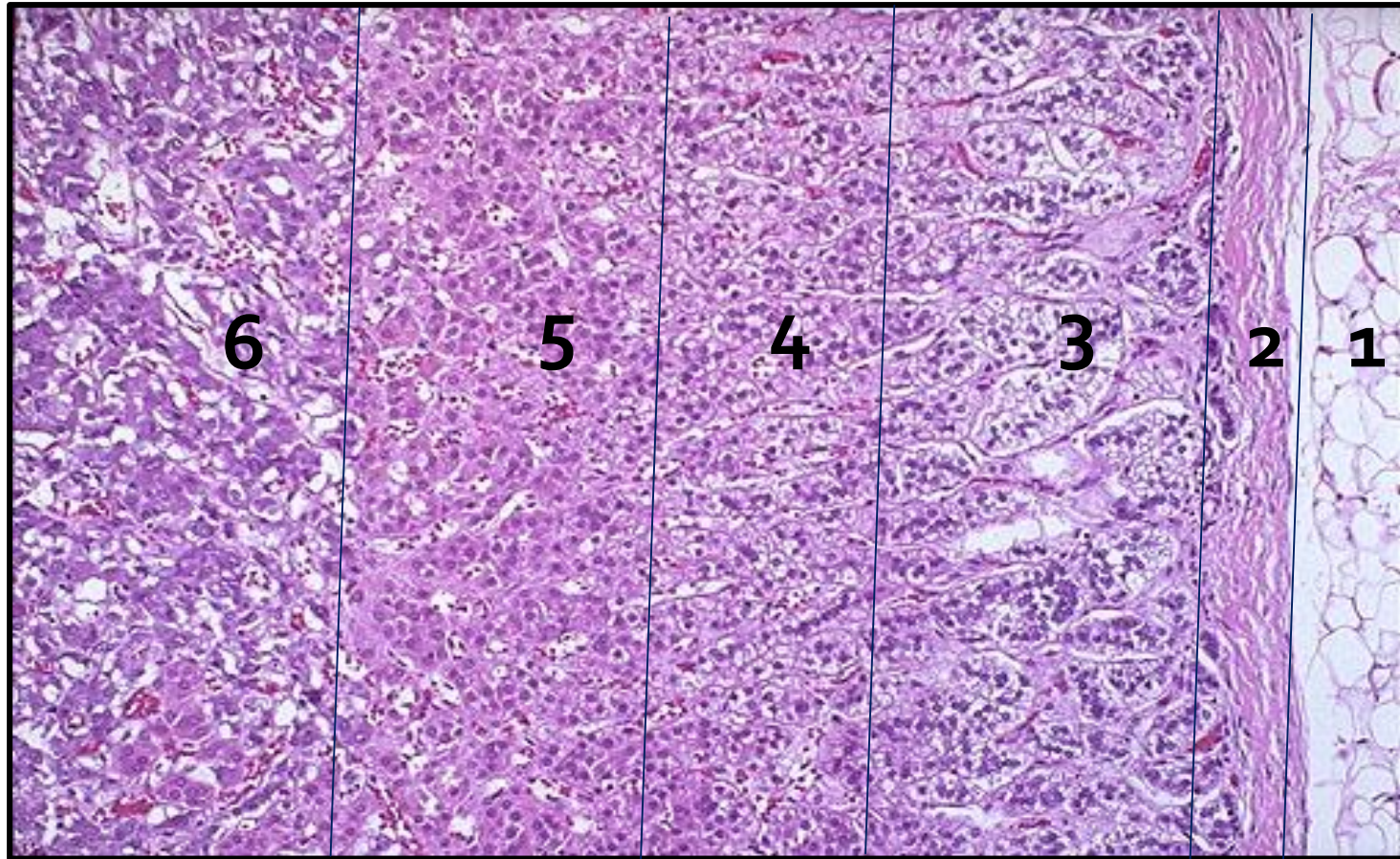
*Here are normal adrenal glands.  
Each adult adrenal gland  
weighs from 4 to 6 grams.*



*Sectioning across the adrenals  
reveals a golden yellow outer  
cortex and an inner red to grey  
medulla.*



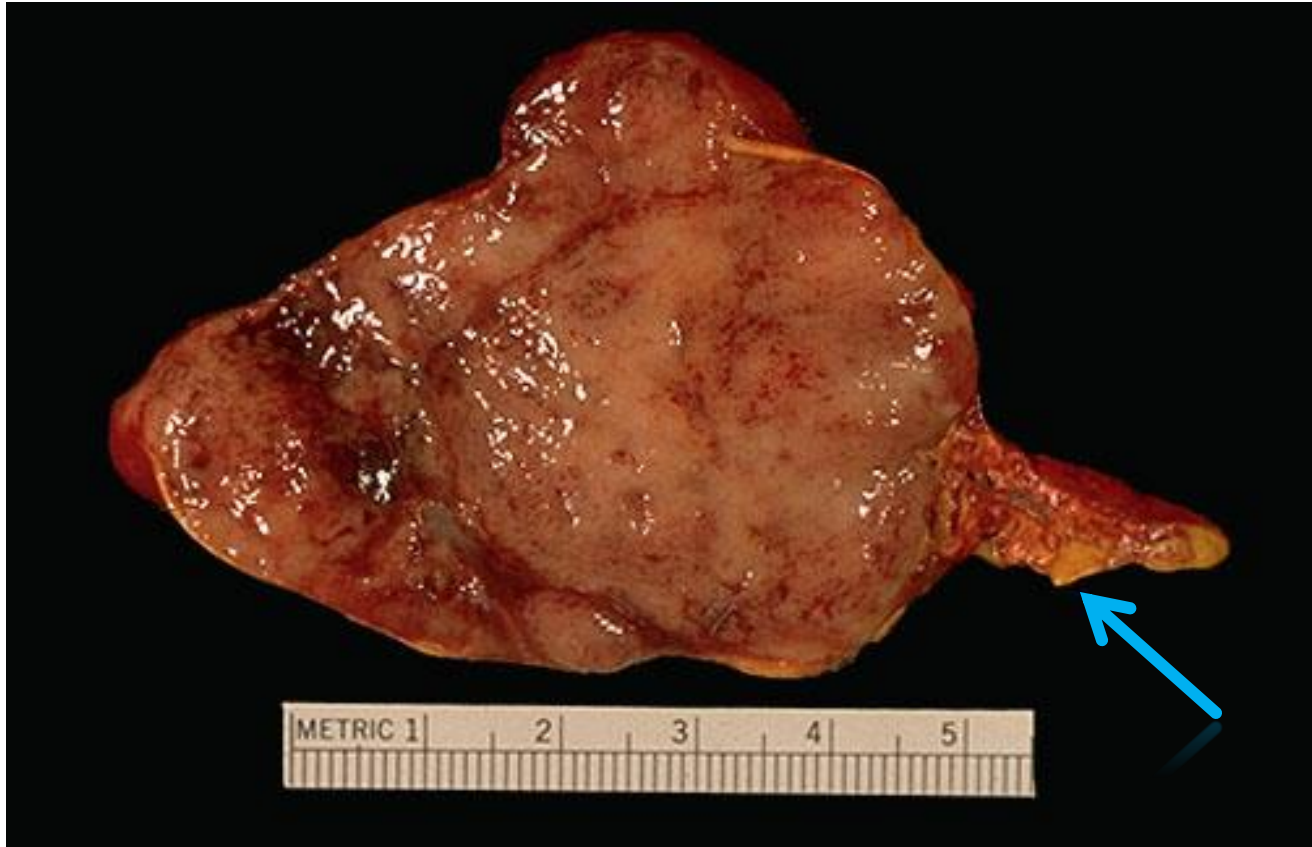# Normal Adrenal Gland Histology



**1 – Periadrenal fat**  
**3- Zona Glomerulosa**  
**5- Zona Reticularis**

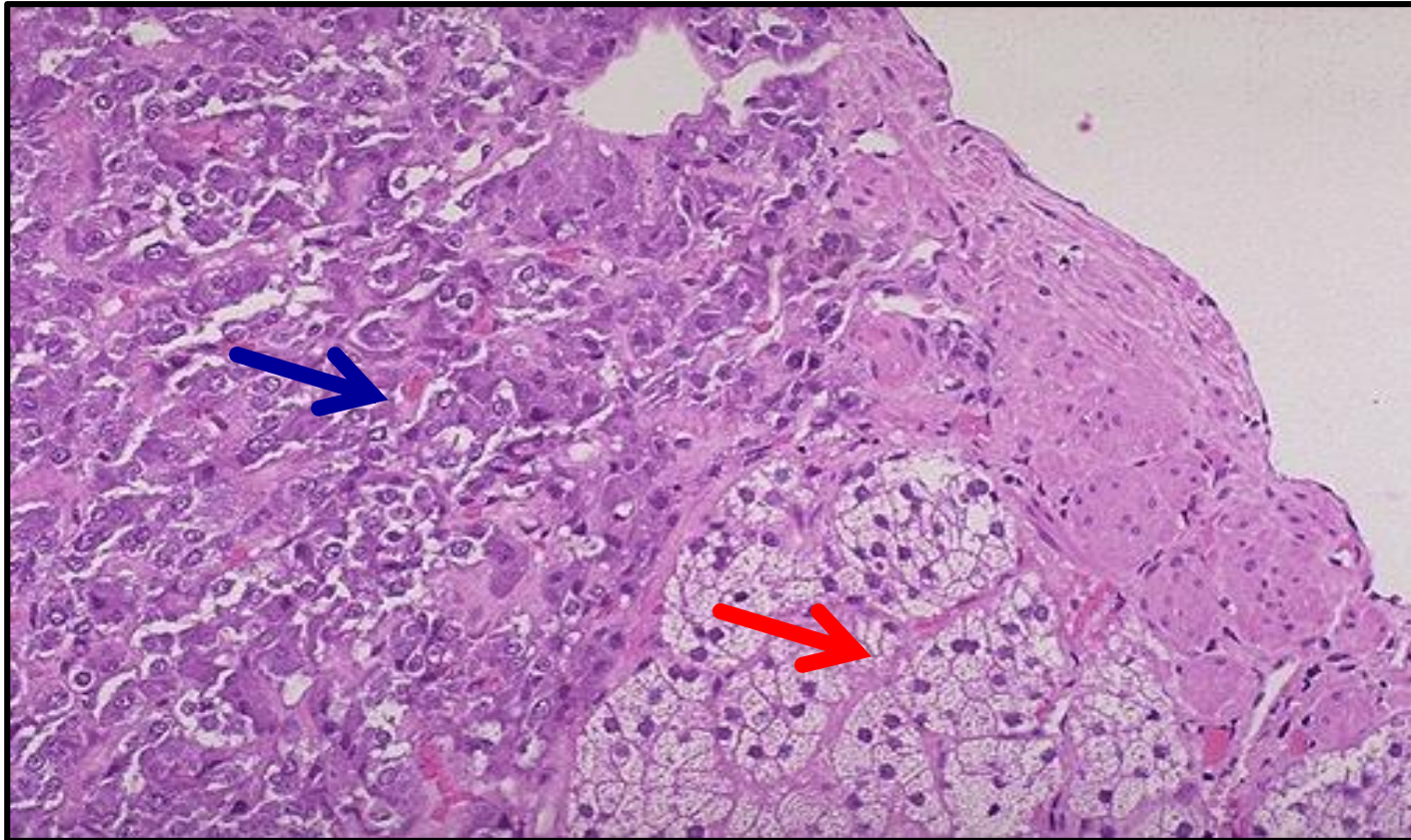
**2- Adrenal Capsule**  
**4- Zona Fasciculata**  
**6- adrenal Medulla**

## *Pheochromocytoma – Gross cut section*



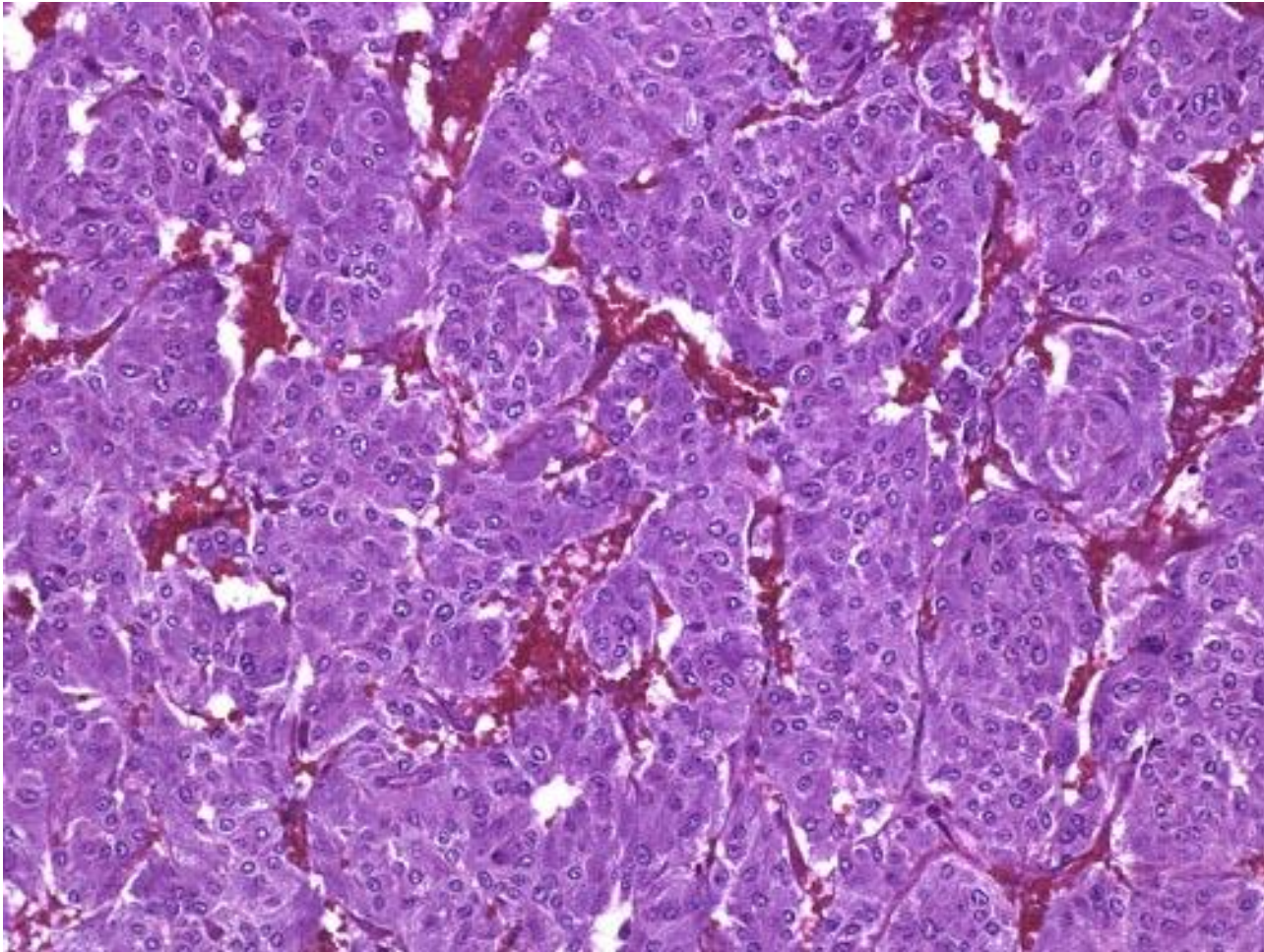
*A single partly pale and partly hemorrhagic adrenal medullary mass . Note the grey-tan color of the tumor compared to the yellow cortex stretched around it and a small remnant of remaining adrenal at the lower right ( [arrow](#) )*

## Pheochromocytoma – LPF



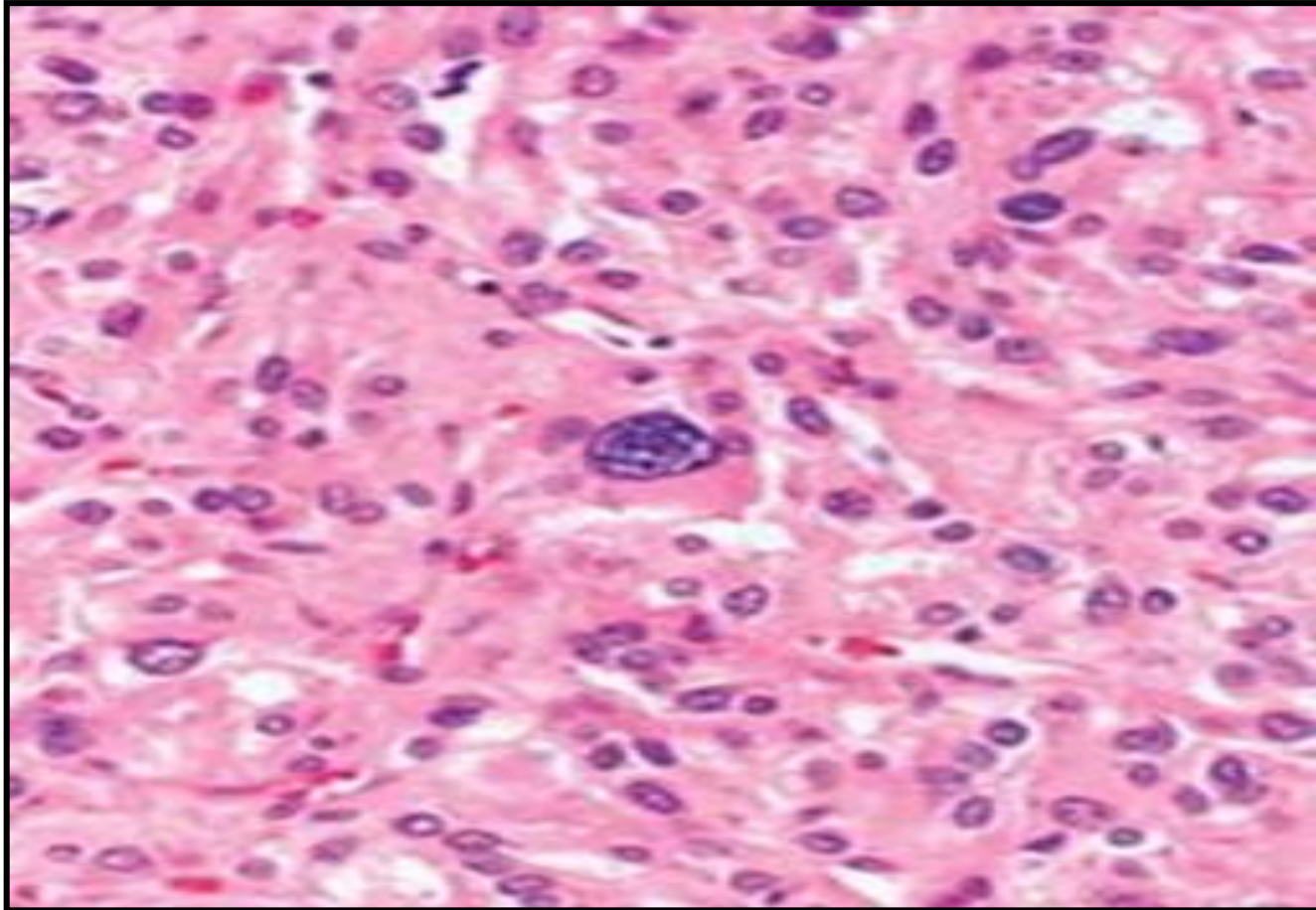
There is some **residual adrenal cortical tissue** at the lower center right, with the darker cells of the **pheochromocytoma** seen above and to the left.

## *Pheochromocytoma – LPF*



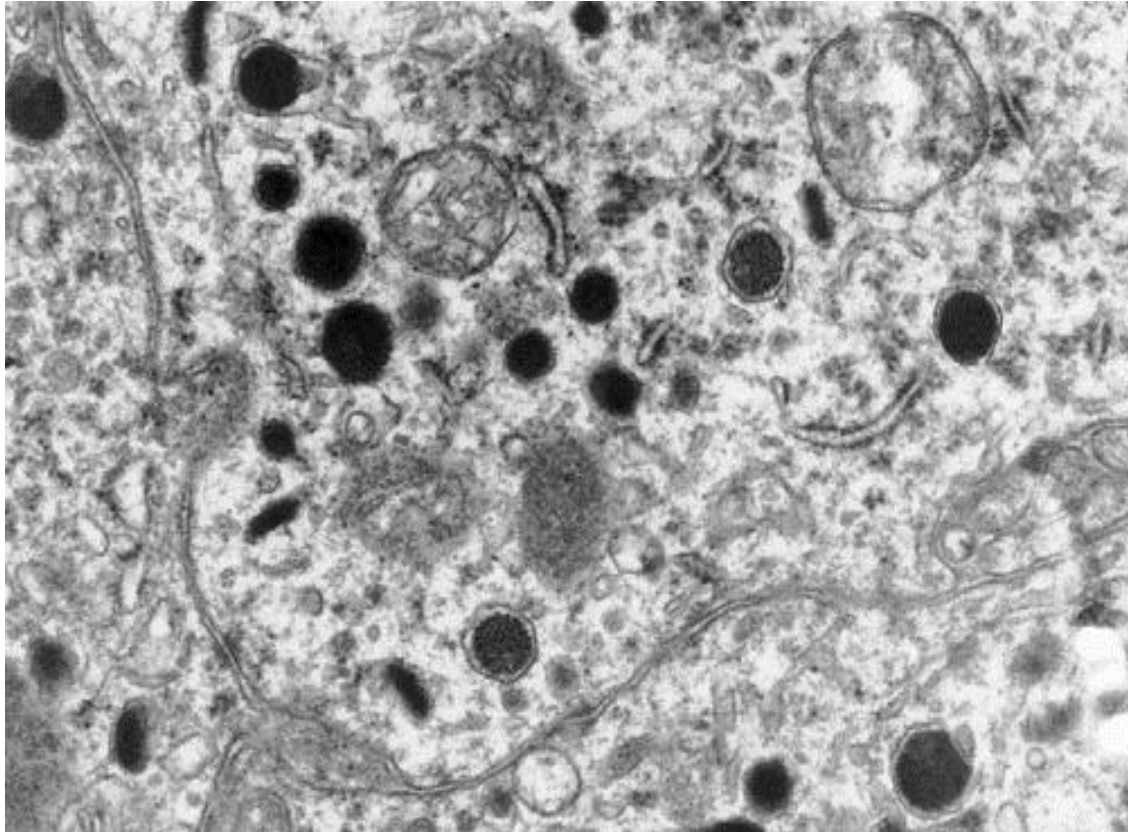
*Microscopic view of pheochromocytoma consisting of circular balls of cells with trabecular areas. Note the presence of numerous blood vessels between the tumor cells*

## *Pheochromocytoma – HPF*



*High power view of pheochromocytoma consisting of cells with granular nuclear chromatin . Note the presence of **a large polymorphic cell** near the center of the picture .*

## *Pheochromocytoma – Electron Microscopy view*



*By electron microscopy, the neoplastic cells of the pheochromocytoma contain variable numbers of membrane-bound, electron-dense neurosecretory granules . It is these granules that contain the catecholamines. The granules seen here appear as small black round objects in the cytoplasm of the cell. The cell nucleus is at the upper left.*

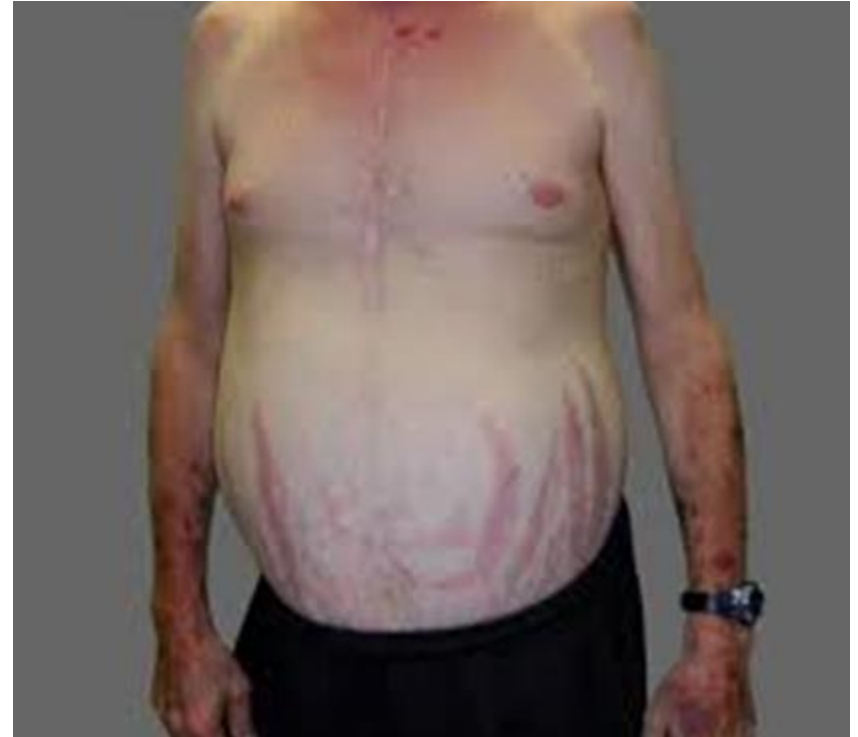

# ***Cushing Syndrome***

## ***Cushing Syndrome – Clinical Case***



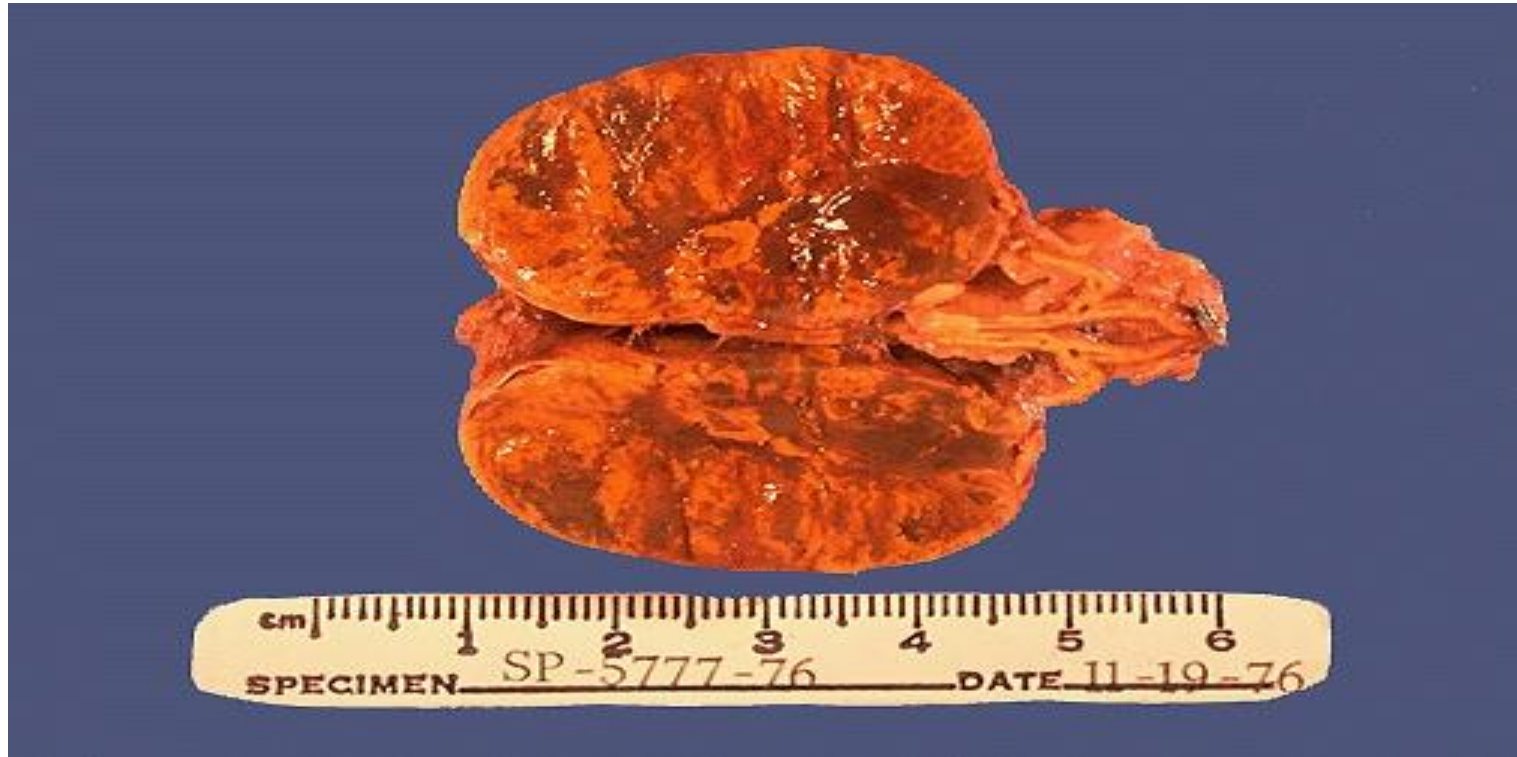***A child with Cushing syndrome as a result of Long-term corticosteroids treatment. Note the classical Moon face appearance***



***A patient with Cushing syndrome. Note the truncal obesity and purple striae.***

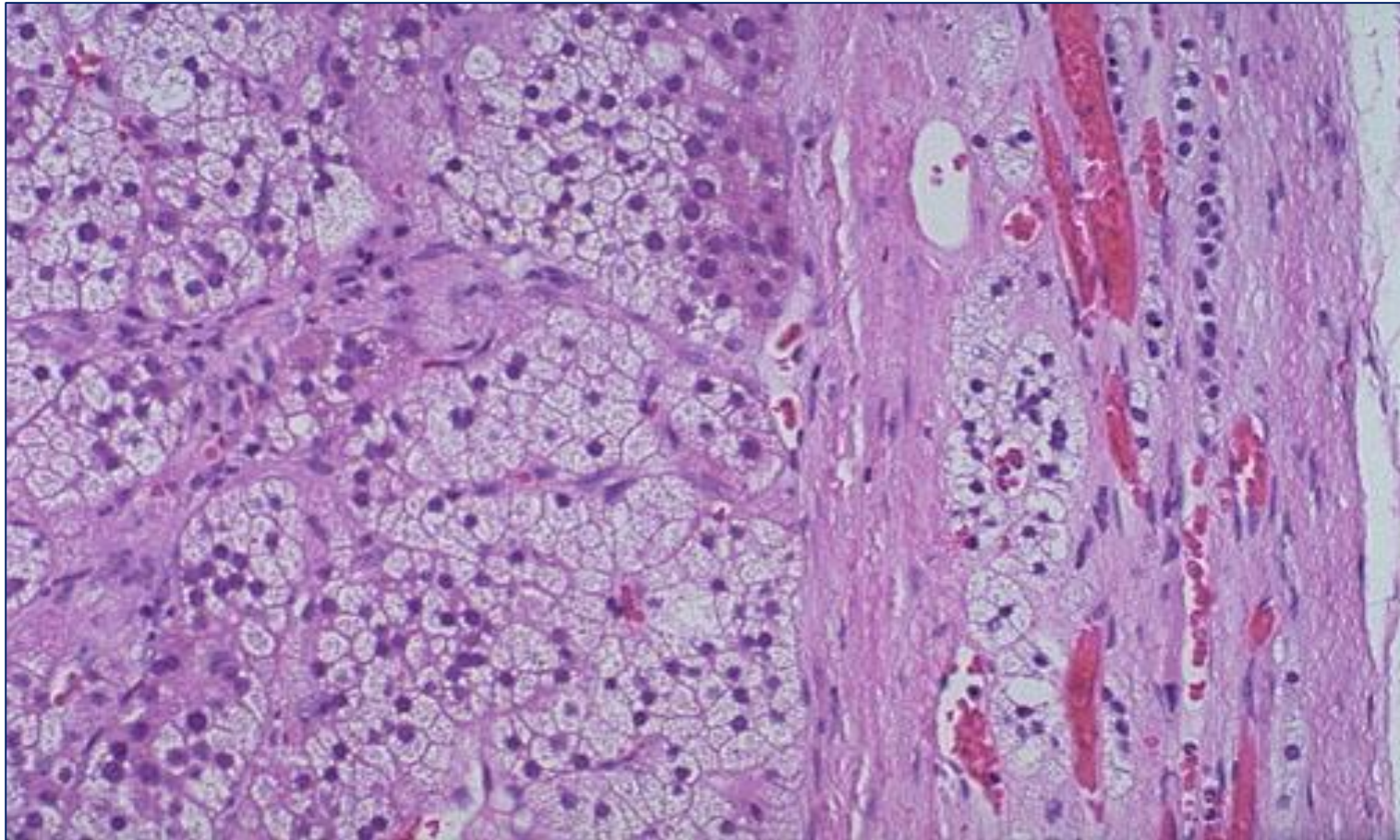


## Cushing syndrome with Cortical Adenoma - Gross



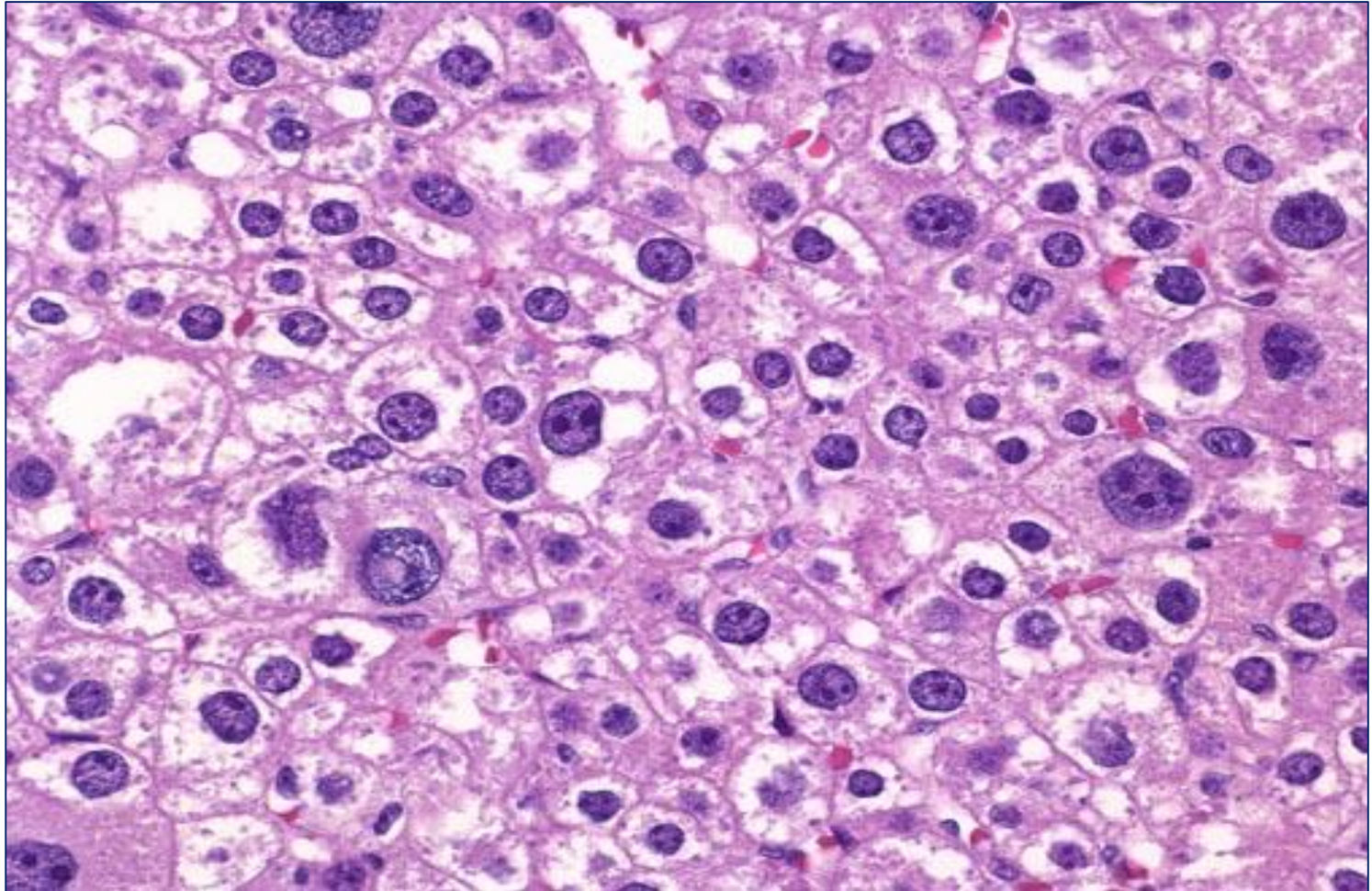
*This adrenal gland, removed surgically from a patient with Cushing syndrome, has been sectioned in half to reveal a **cortical adenoma**. Some remaining **atrophic adrenal** is seen at the right. The adenoma is composed of yellow firm tissue, just like adrenal cortex. This neoplasm is well-circumscribed. Histologically, it is composed of well-differentiated cells resembling the normal cortical fasciculata zone. It is benign.*

## Cortical Adenoma - MPF



*Microscopically, the adrenal cortical adenoma at the left resembles normal adrenal zona fasciculata. The **capsule** of this benign neoplasm is at the right. There may be minimal cellular pleomorphism within adenomas.*

## ***Adrenal Gland – Cortical Adenoma - HPF***



***There were occasional enlarged hyperchromatic nuclei with one or more prominent nucleoli.***

***GOOD LUCK***

