



POSTURE & EQUILIBRIUM

Q-What is posture?

It is maintenance of upright position against gravity (center of body is needed to be between the legs) it needs **antigravity muscles**

1-**Up-right posture** need postural reflexes

2- posture depends on muscle tone (**stretch reflex**) (basic postural reflex)

3-The main pathways concerned with posture are:-

A- medial tracts control proximal limbs & axial muscles for posture & gross movements

4- **lateral pathways as corticospinal –rubrospinal**) control distal limbs.



postural reflex depends on the following receptors:-

1- Vestibular apparatus receptors as •

Maculae (utricle & saccule) & SCC crista. •

- Maculae for linear acceleration & orientation of head in space •
- SCC crista for angular acceleration •

2- Visual (vision) & auditory (hearing) receptors:- •

Vision can compensate for loss of auditory, vestibular & proprioception

-(Tabes dorsalis +ve Rombergism) •

-If Pt with sensory ataxia stands with eyes closed ,he falls down) •

3-Proprioceptors of muscles , tendons , ligaments & joints:- •

a- Neck Proprioceptors:- •

detect head position in relation to trunk •

b- Body Proprioceptors proprioceptors of •
anti-gravity muscles

c- pressure receptors as in sole of feet •
initiate positive supporting reaction (
magnet reflex)

•

- Stretch reflexes & postural reflexes can be modified by coordinated activity ;-

-Spinal cord

-Medulla

-Midbrain

-Cerebral cortex

-Cerebellum

postural reflexes are:-

a-static reflexes(at rest)

b-phasic reflexes (with
motion)

A-Static R (statotonic): maintain posture at rest

A- spinal

B-medullary reflexes

C-Righting reflexes (midbrain)

A-Spinal reflexes:- (Center in S.C)

1- local static reflexes:

Positive supporting reaction (magnet reflex)

(receptors are proprioceptors of flexors(contraction of both flexors & extensors)

-protective reflex

2 -Stretch reflex

3- Segmental static reflexes:-

Mediated by one segment of the spinal cord as :-

a- **Crossed extensor reflex**

b- **Negative supporting R** (which release +ve supporting reaction

- -(receptors are proprioceptors of extensors of the released limb)

N.B spinal R can be studied in **spinal animal** with cut at neck b/w the S.C& brain stem so all S.C is intact.

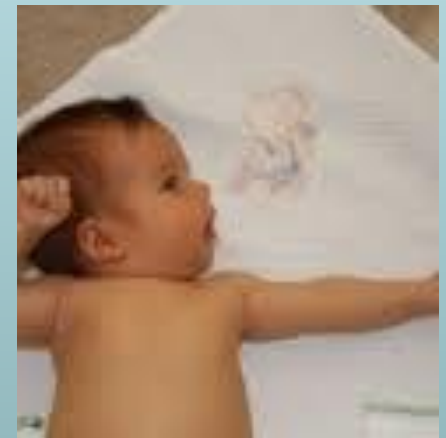B- Medullary static Reflexes

(Center=medulla oblongata) are:-

Include (Neck & labyrinthine reflexes)

1- Neck static reflexes (studied in a decerebrated animal cut above medulla + labyrinth destroyed)

-Stimulus is :-changing head position that (+) neck proprioceptors



1- Ventroflexion of head

-Arms flexion+ extend hindlimb
(as in decortication).



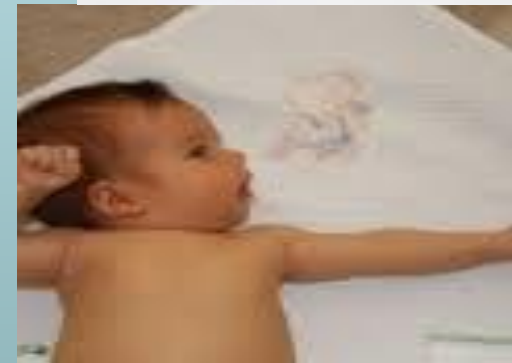2-Dorsiflexion of head /

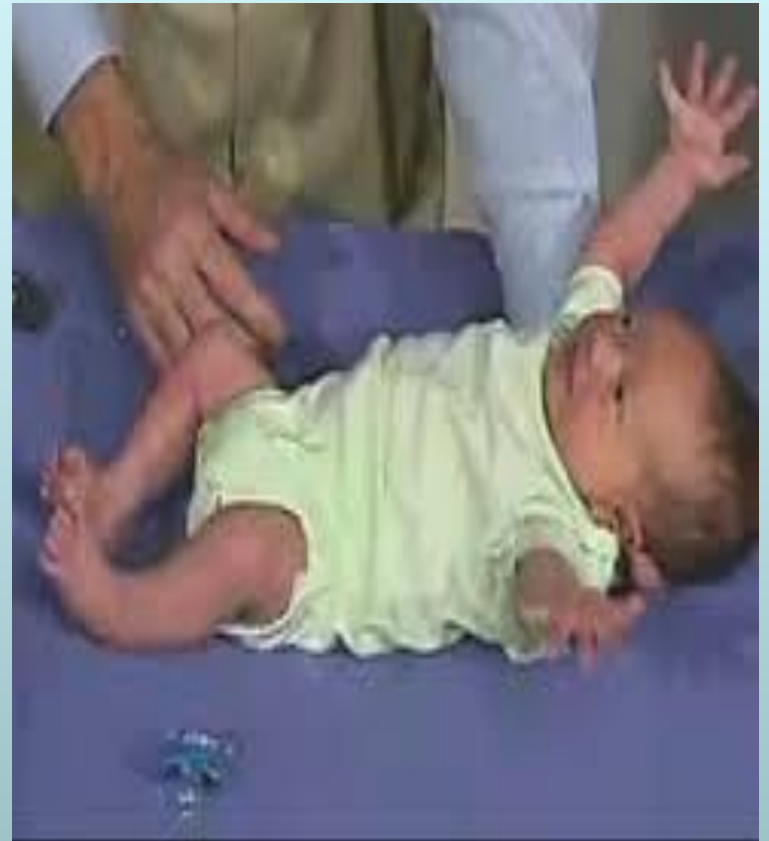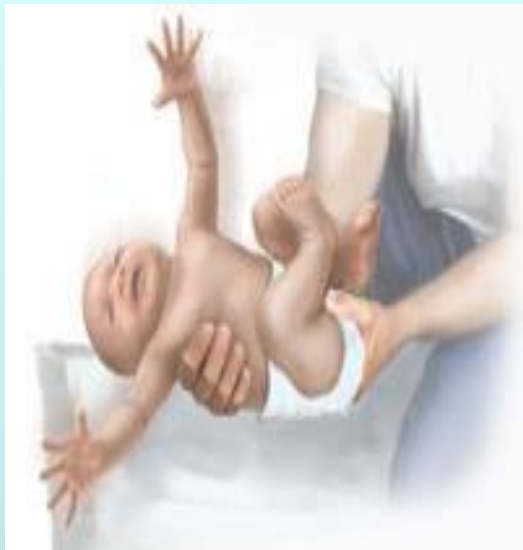-Arms extended + flex hindlimb.



3-Turning head to one side

Extention of limbs on that side +
flexion of other side.
(as in decortication)





Moro Startle Reflex

2- labyrinthine static reflex:-

(in decerebrated animal) + elimination of neck proprioceptors)(labyrinth intact)

- Receptors are otolith organs (maculae)

-Stimulus is gravity

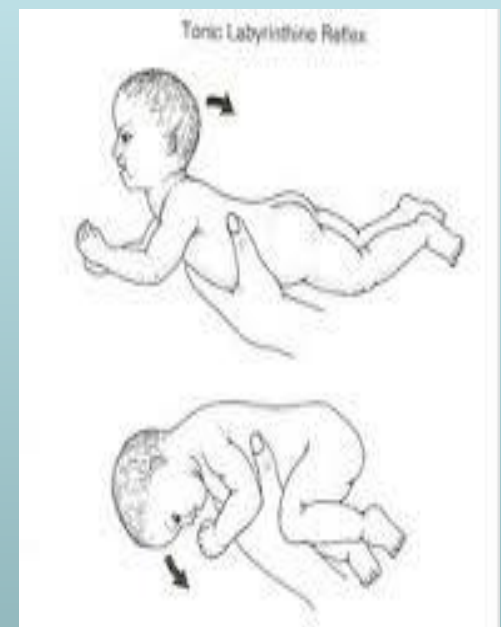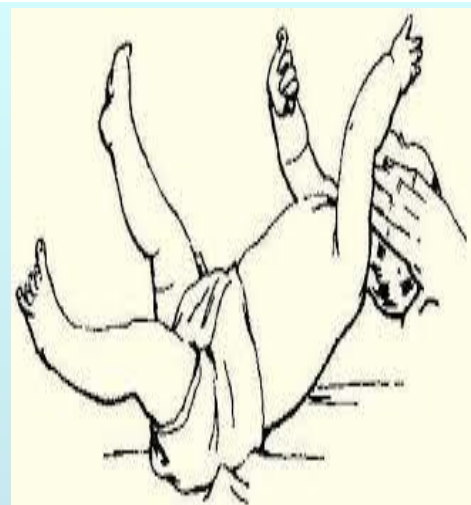
1- Ventroflexion of head (or prone position)

>>>>> 4 limbs flexion

2- Dorsiflexion of head (or supine position)

>>>>>4 limbs extended

(as in decerebration)



C- Righting reflexes:-

(Center is midbrain except the visual in C.C):-

when upright posture is disturbed as in falling down>>>>>Righting R

studied in a decerebrated animal -

(cut above midbrain = upper decerebration) -

a- Visual righting reflexes(cortical):-

- Visual image can correct position of head & body if position is disturbed

- Center is c.c -

- Stim: visual stimuli

- Receptors; eye receptors



b- labyrinthine righting reflexes
(midbrain):-

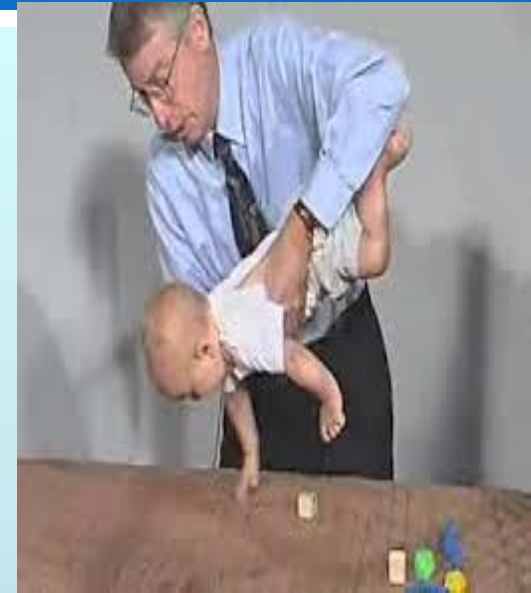(covered eyes) & animal held in air from pelvis)

- The body is not in the proper position

As in tilting the head & head is not in proper site >>>>stimulates the otolith organs >>>> stimulate neck muscles to correct the head level

Receptors; otolith organs

Response; righting of head

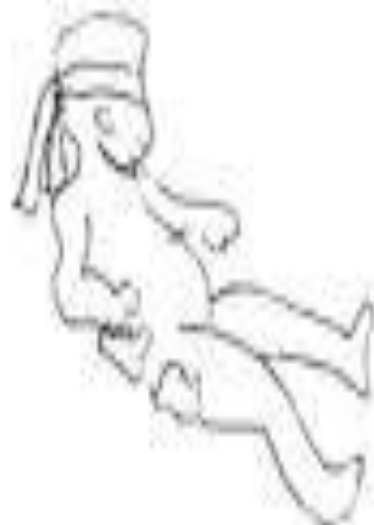



held vertically



prone head moves upright



supine head moves upright



lateral tilt head moves upright

All static labyrinthine reflexes have macula as receptors •
but in statokinetic reflexes during motion SCC receptors. •
(macula act in linear & SCC receptors act in angular •
acceleration)

c- Body on head righting reflexes (midbrain):- :-

Stim: pressure on side of body & head is free

Receptors; trunk proprioceptors

Response/ reflex correction of head .

d- Body on body (midbrain):-

Pressure on side of the body and head is fixed

Receptors/ trunk proprioceptors

response /reflex correction of body

e- Neck righting reflexes (midbrain) :-

Stim: Stretch of neck muscles

(As if head is corrected & body still tilted

Receptors; Muscle spindles of neck muscles

Response; - Righting of shoulders & then righting of body.

B- Phasic reflexes (statokinetic reflexes) (center in C.C):- •

-maintain posture during motion

a- Hopping reaction:- •

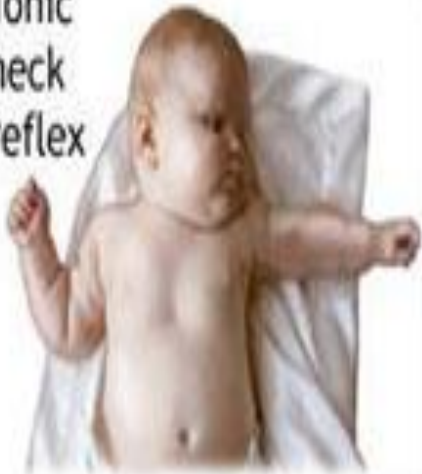- When animal is pushed laterally } } } } } } reflex hopping to keep limbs in position to support body. •

The receptors are in muscle spindles. •

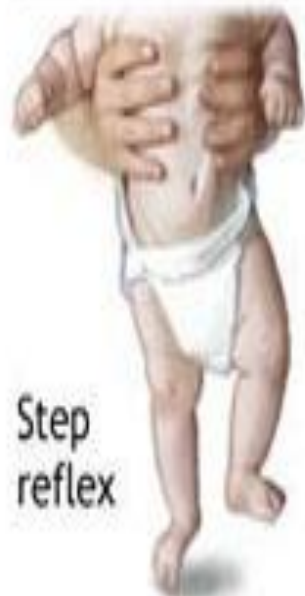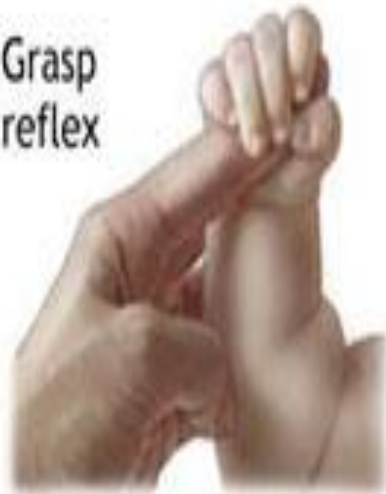b- Placing reaction :- •

- blind folded animal suspended in air & moved towards a supporting surface, the feet will be placed firmly on the supporting surface (receptors are touch receptors & proprioceptors in soles of feet)

Tonic neck reflex

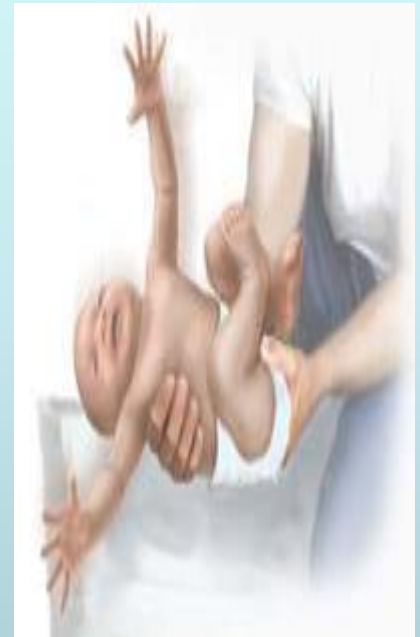
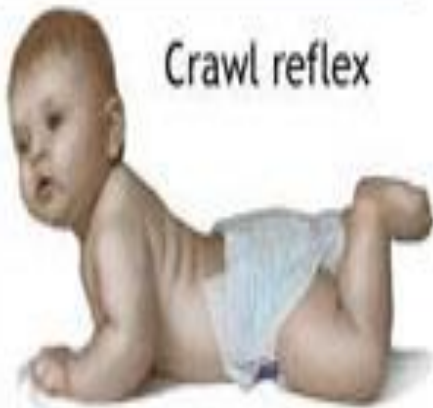
Grasp reflex

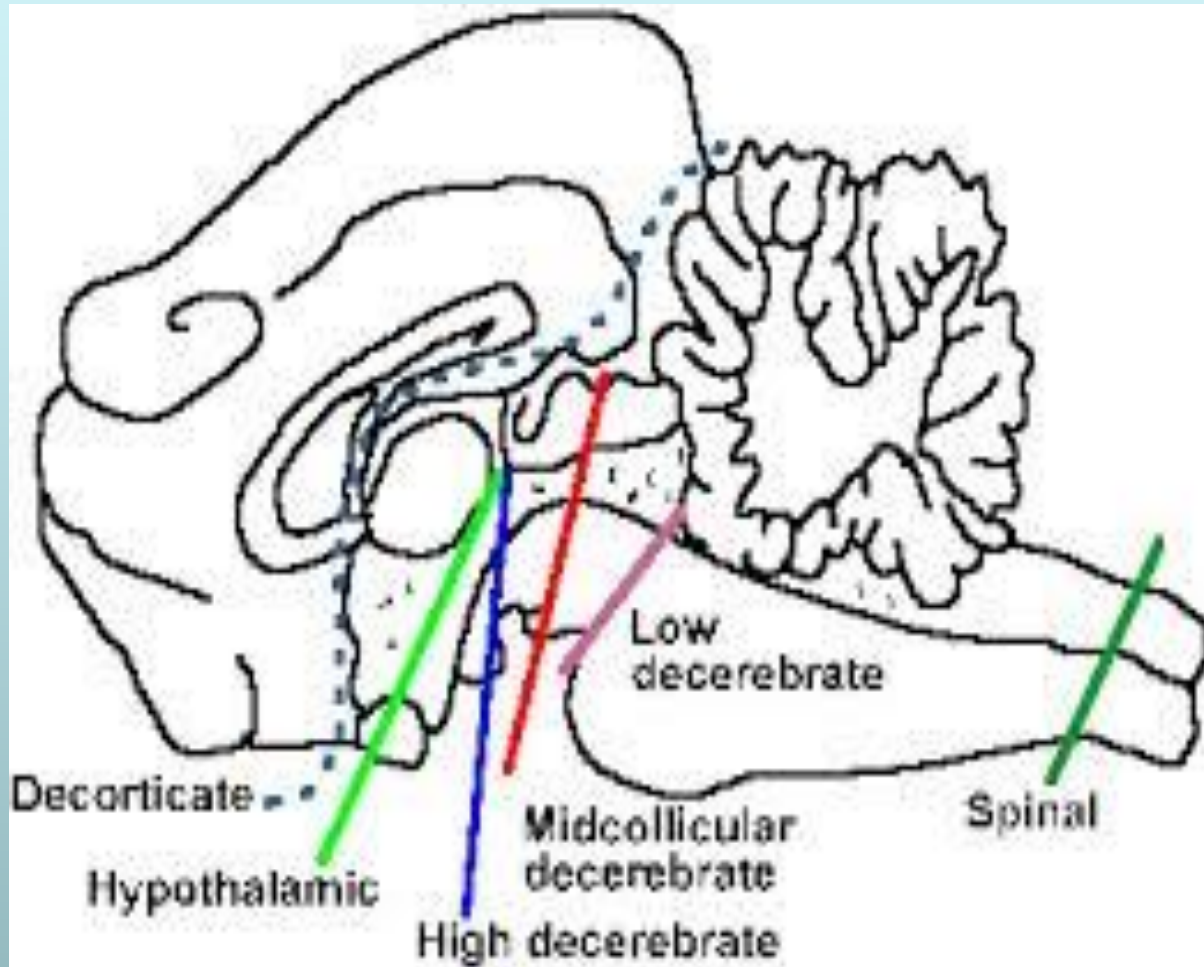


Step reflex

Crawl reflex



Decerebrate rigidity & Decorticate rigidity



Decerebrate rigidity :-

- In section between superior & inferior colliculi of midbrain (mid-collicular lesion) (below the level of the red nucleus >>>> block inhibitory signals from brain & red nucleus to tonically active pontile reticular formation & Vestibular N

>>>>causing:

1- Maintained tonic static postural reflexes that support animal against gravity :-

a-Medullary tonic neck R

b-Medullary labyrinthine R.

2- Absent midbrain righting R

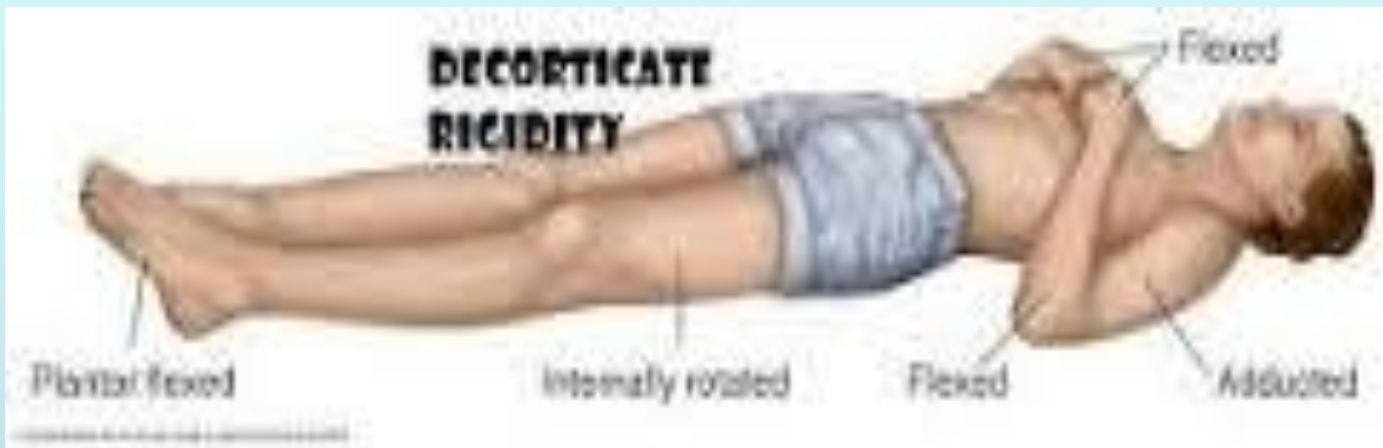3- Extension of head & 4 limbs extensors (as in labyrinthine static R)

-The jaw may be clenched with the neck hyperextended due to increased extensor tone from vestibulospinal & reticulospinal tracts to extensor motor neurons

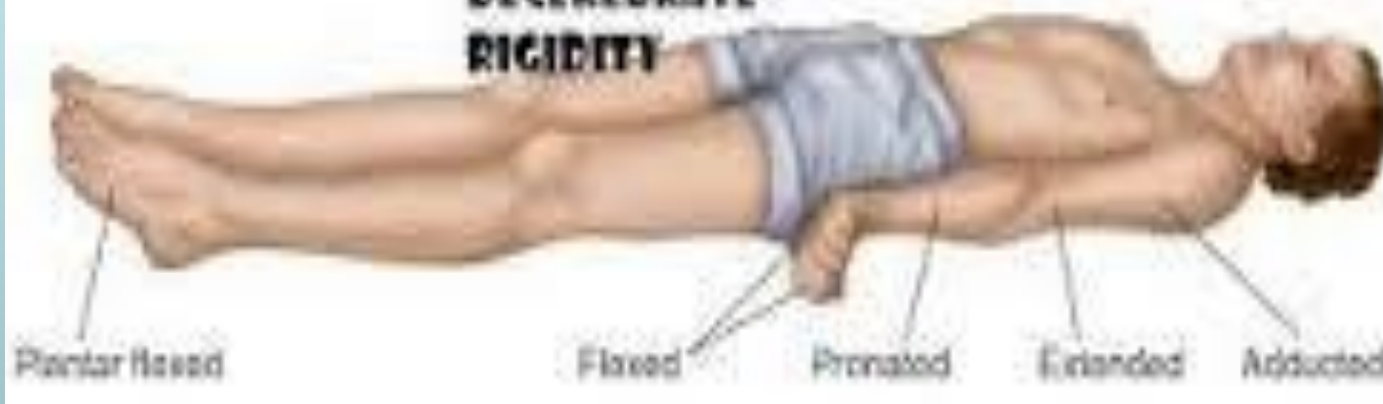4- spasticity & rigidity & extension in antigravity muscles

-In human by vascular lesion of brain stem between red N & vestibular nucleus

**DECORTICATE
RIGIDITY**



**DECEREbrate
RIGIDITY**



Decorticate rigidity more common in human than decerebrate rigidity:-

1- lesion in cerebral cortex but brain stem is intact as what seen in hemiplegic patients after Hemorrhage of internal capsule

2-Medullary tonic neck & tonic labyrinthine reflexes present

3-Righting midbrain reflexes present

4-Visual righting, placing & hopping reflexes lost

5- it causes extensor rigidity in legs & moderate flexion of arms if head unturned , as supine position (tonic neck reflexes)

- the hands are clenched into fists, and the legs extended and feet turned inward

2- Turning the head to one side initiates tonic neck reflexes e.g turning head to the left >>>>>>extension of limbs on left side & flexion of right side

Cause :-

are intact 1-lesions above the red nucleus so rubrospinal ,pontine reticulospinal & vestibulospinal are intact this leads to the characteristic flexion posturing of the upper extremities and extensor posturing of the lower extremities.

2-Corticospinal tract is interrupted, so the pontine reticulospinal and the vestibulospinal extend L.L

3-normally suppressor area 4 strip in the anterior edge of precentral gyrus inhibit red nucleus , if this inhibition is lost by decortication >>>>>>disinhibition of the **red nucleus** , so facilitate the **rubrospinal tract** to flex U.L

4- Also/ there is loss of inhibitory signals from suppressor area 4 to gamma motor neurons via reticulospinal

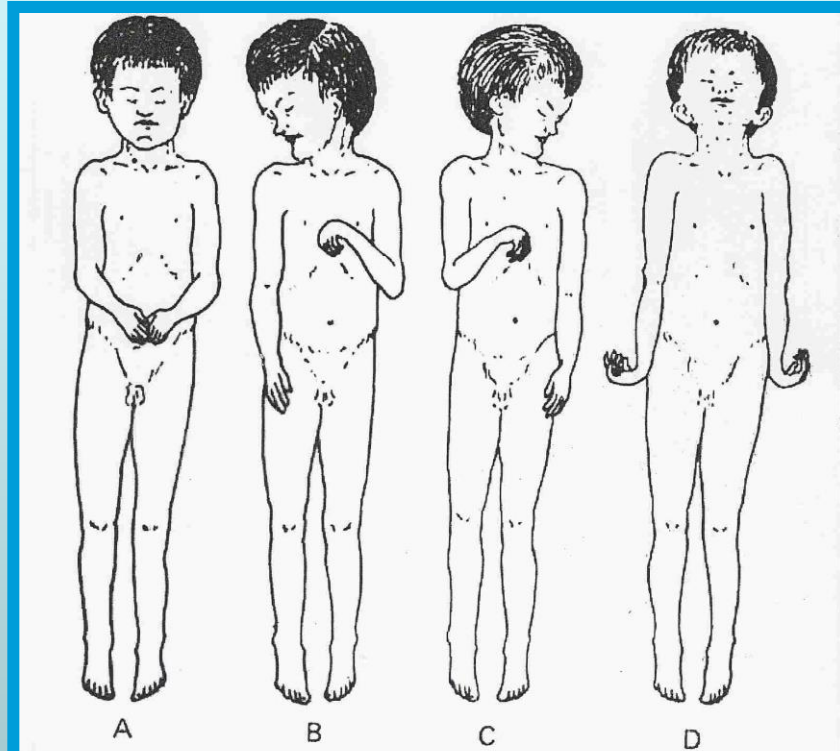
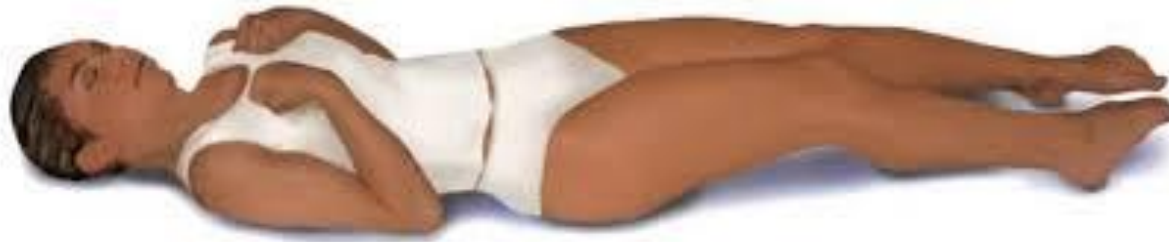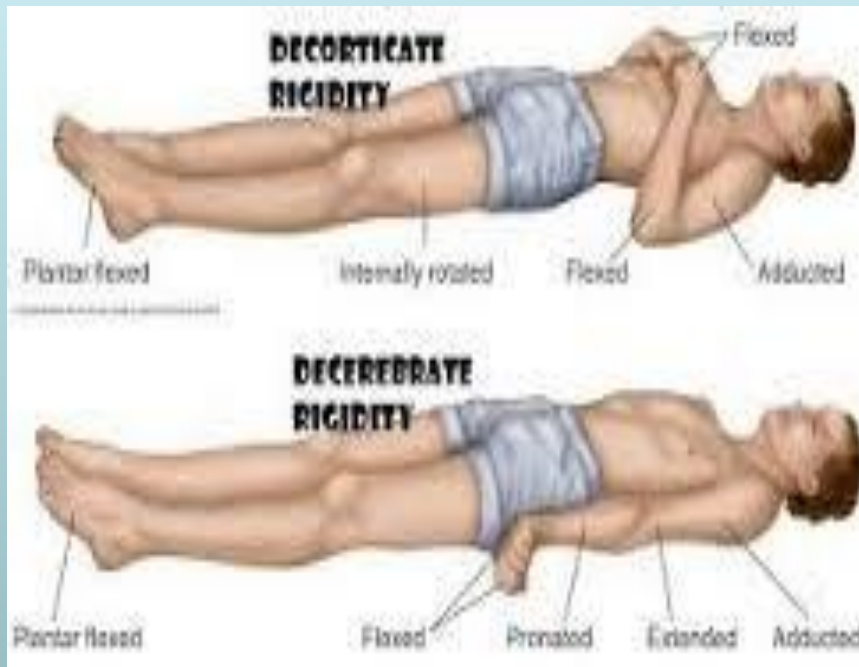


Figure 12-7. Human decorticate rigidity (**A–C**) and true decerebrate rigidity (**D**). In **A** the patient is lying supine with the head unturned. In **B** and **C**, the tonic neck reflex patterns produced by turning of the head to the right or left are shown. (Reproduced, with permission, from Fulton JF [editor]: *Textbook of Physiology*, 17th ed. Saunders, 1955.)



Copyright Pat Thomas, 2005.



POSTURING

DECORTICATE
(Flexor)

Arms are like **C**
Moves in toward the "Cord"

Problems With Cervical Spinal Tract or Cerebral Hemisphere.

DECEREBRATE
(Extensor)

Arms are like **e**
S

Problems Within Midbrain or Pons.

© 2007 Learning Education Concepts, Inc.

Table 12–2. Principal postural reflexes.

Reflex	Stimulus	Response	Receptor	Integrated In
Stretch reflexes	Stretch	Contraction of muscle	Muscle spindles	Spinal cord, medulla
Positive supporting (magnet) reaction	Contact with sole or palm	Foot extended to support body	Proprioceptors in distal flexors	Spinal cord
Negative supporting reaction	Stretch	Release of positive supporting reaction	Proprioceptors in extensors	Spinal cord
Tonic labyrinthine reflexes	Gravity	Contraction of limb extensor muscles	Otolithic organs	Medulla
Tonic neck reflexes	Head turned: (1) To side (2) Up (3) Down	Change in pattern of extensor contraction (1) Extension of limbs on side to which head is turned (2) Hind legs flex (3) Forelegs flex	Neck proprioceptors	Medulla
Labyrinthine righting reflexes	Gravity	Head kept level	Otolithic organs	Midbrain
Neck righting reflexes	Stretch of neck muscles	Righting of thorax and shoulders, then pelvis	Muscle spindles	Midbrain
Body on head righting reflexes	Pressure on side of body	Righting of head	Exteroceptors	Midbrain
Body on body righting reflexes	Pressure on side of body	Righting of body even when head held sideways	Exteroceptors	Midbrain
Optical righting reflexes	Visual cues	Righting of head	Eyes	Cerebral cortex
Placing reactions	Various visual, exteroceptive, and proprioceptive cues	Foot placed on supporting surface in position to support body	Various	Cerebral cortex
Hopping reactions	Lateral displacement while standing	Hops, maintaining limbs in position to support body	Muscle spindles	Cerebral cortex

Thank you for
listening



Visit www.bubblegumonline.com
© 1999 AGC, Inc.