

بِسْمِ اللَّهِ الرَّحْمَنِ الرَّحِيمِ



السَّلَامُ عَلَيْكُمْ وَرَحْمَةُ اللَّهِ وَبَرَكَاتُهُ



*PHYSIOLOGY OF  
BRAIN STEM*

*Dr. Hayam Gad  
Associate Professor of Physiology,  
College of Medicine, KSU*

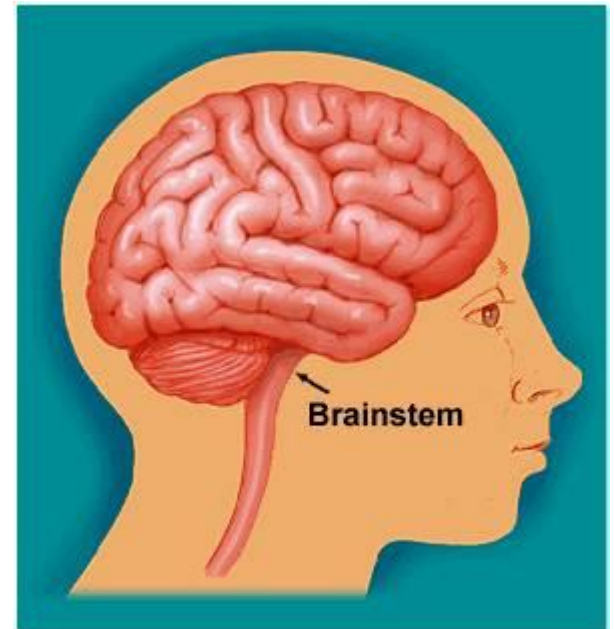
# Learning Objectives



- ✓ Components of Brain Stem
- ✓ Important structures in Brain Stem
- ✓ Functions of the Brain Stem
- ✓ Signs & Symptoms of Brain Stem Lesion
- ✓ Brain Stem Function Tests

# *THE BRAIN STEM*

- The brain stem is the lower part of the brain.
- It is adjoining and structurally continuous with the spinal cord.



# Components of Brain stem

1

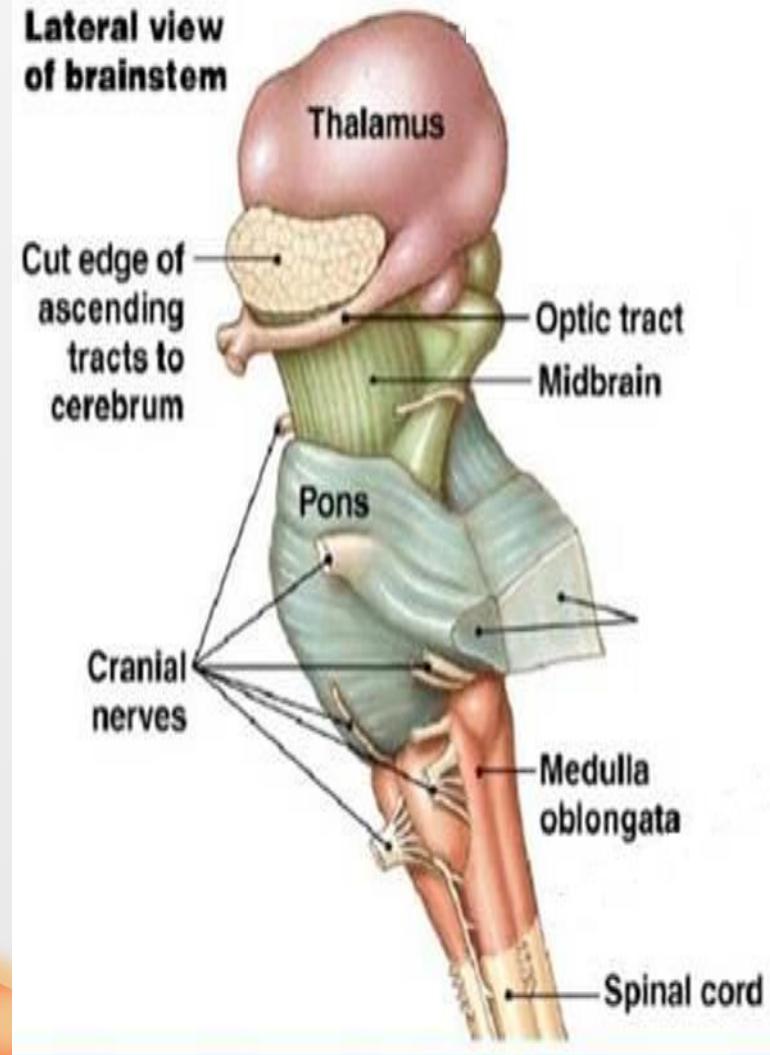
Mid Brain

2

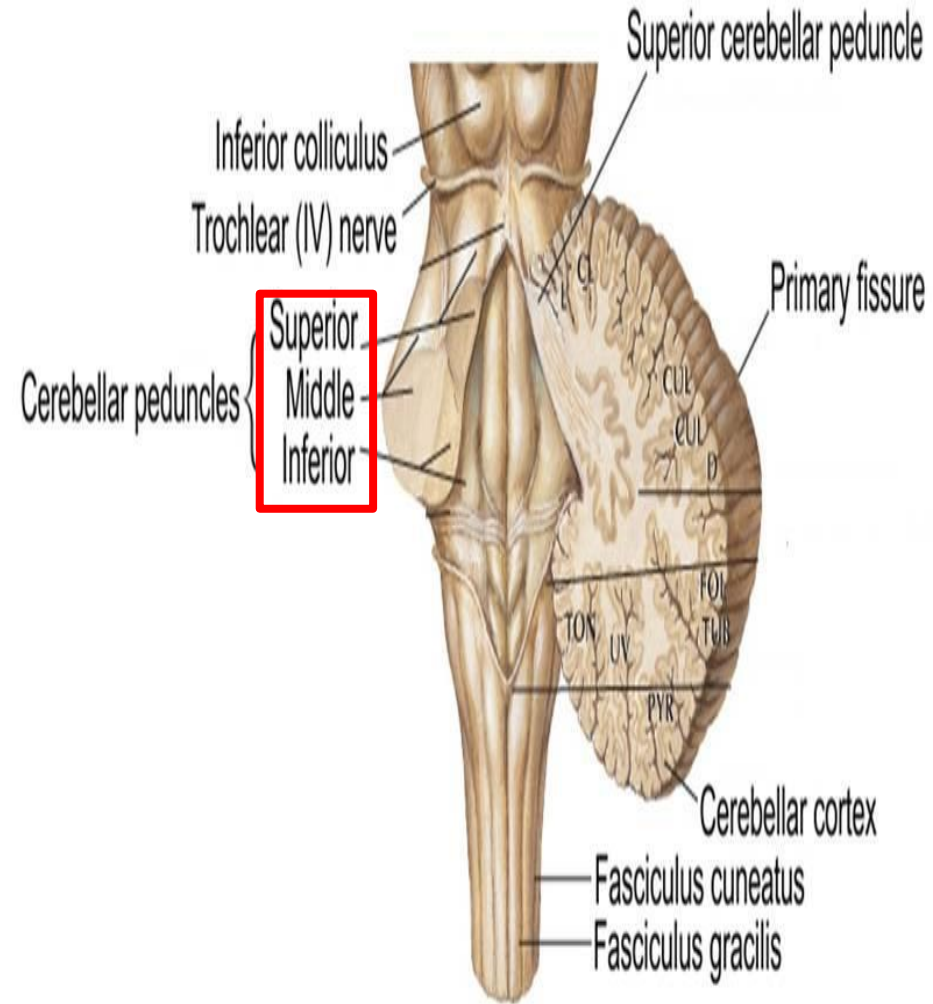
Pons

3

Medulla Oblongata



- The midbrain, pons and medulla connect to the cerebellum via the superior, middle and inferior peduncles respectively.



# The Midbrain

The midbrain is divided into three parts:

1

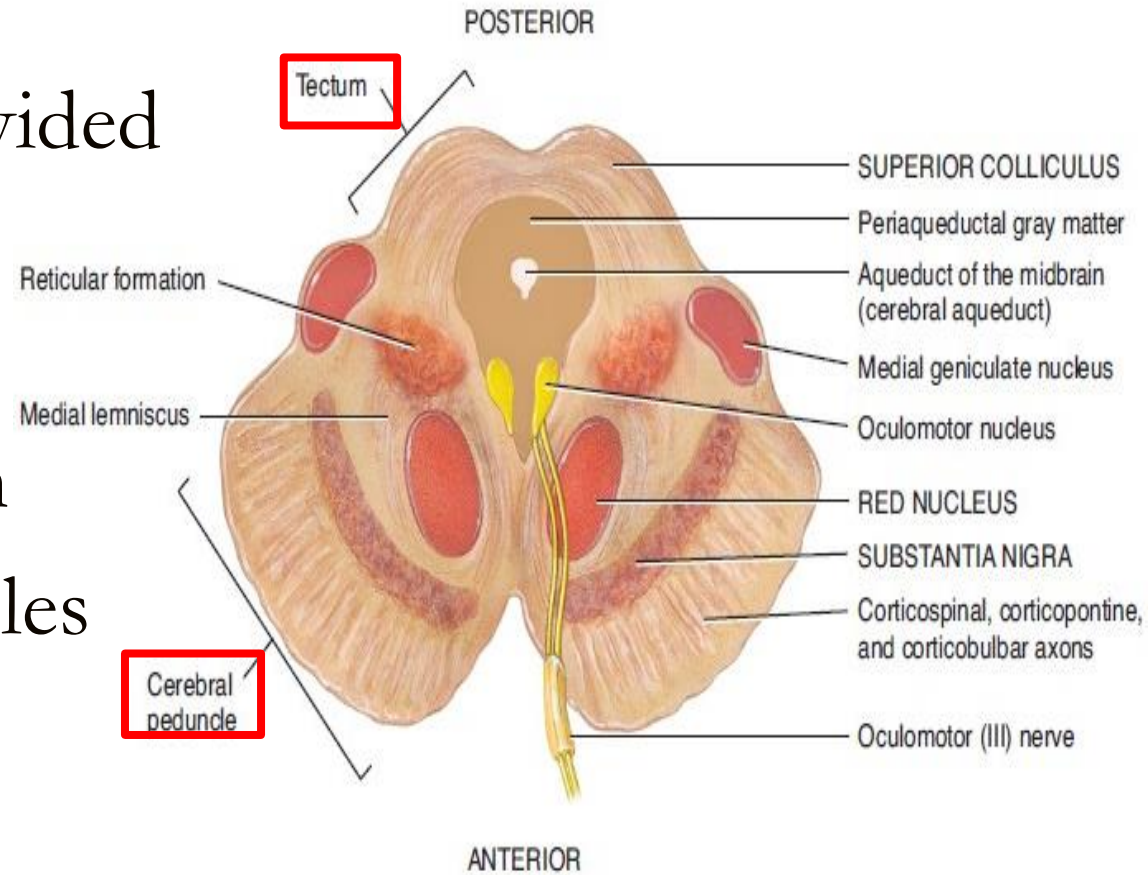
The Tectum

2

The Tegmentum

3

Cerebral Peduncles

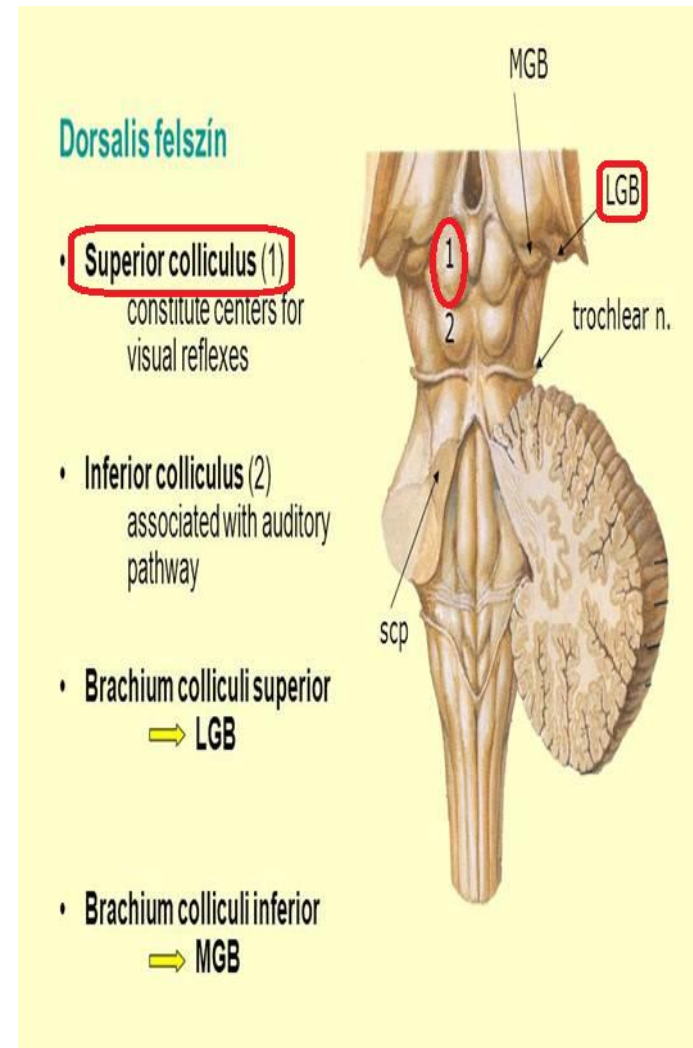


(b) Transverse section of midbrain

# 1- The Tectum ("roof" in latin) includes:

## a) The superior colliculus

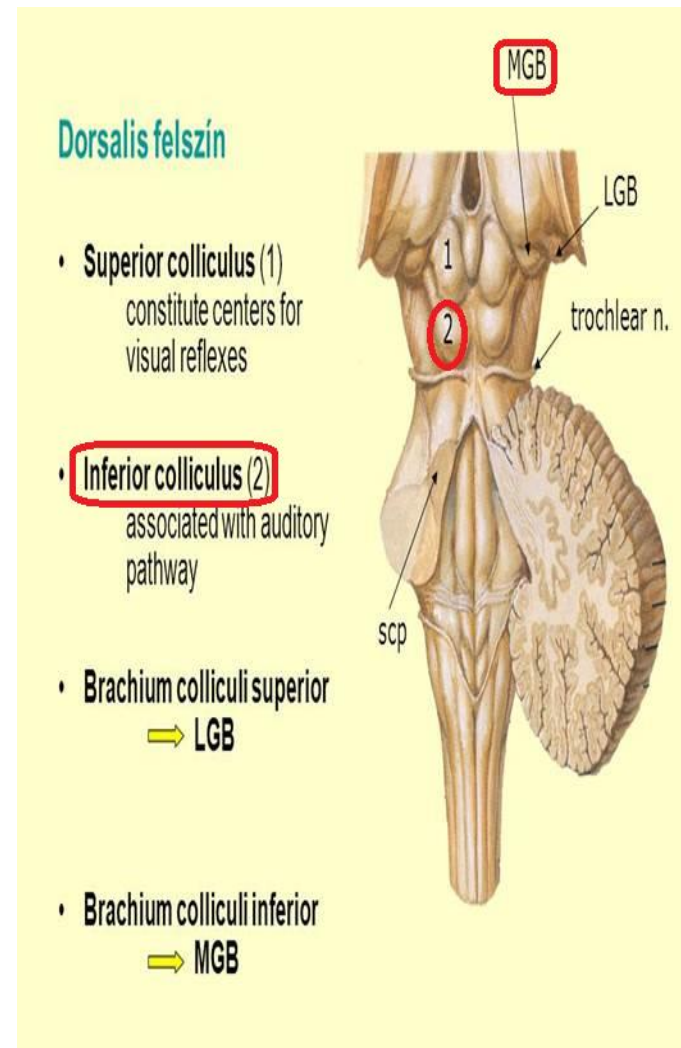
- It constitutes center for visual reflexes
- It sends its superior brachium to the **lateral geniculate body** of the thalamus.





## b) The inferior colliculus

- It is associated with auditory pathway
- It sends its inferior brachium to the **medial geniculate body** of the thalamus.
- The cerebral aqueduct runs through the midbrain, beneath the colliculi.

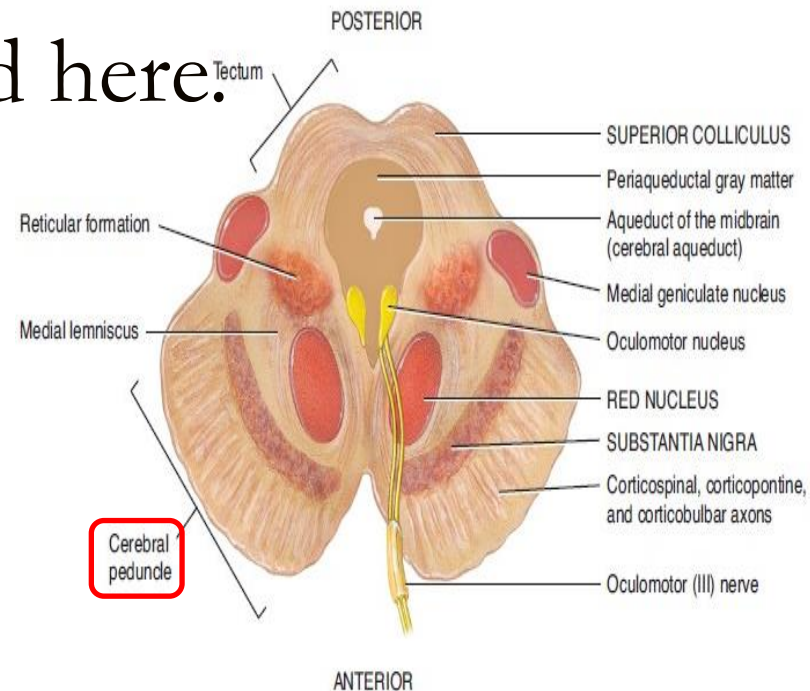


## 2- The Tegmentum

- Ventral to the cerebral aqueduct.
- Several nuclei, tracts and the reticular formation is contained here.

3- The ventral side is comprised of paired Cerebral Peduncles.

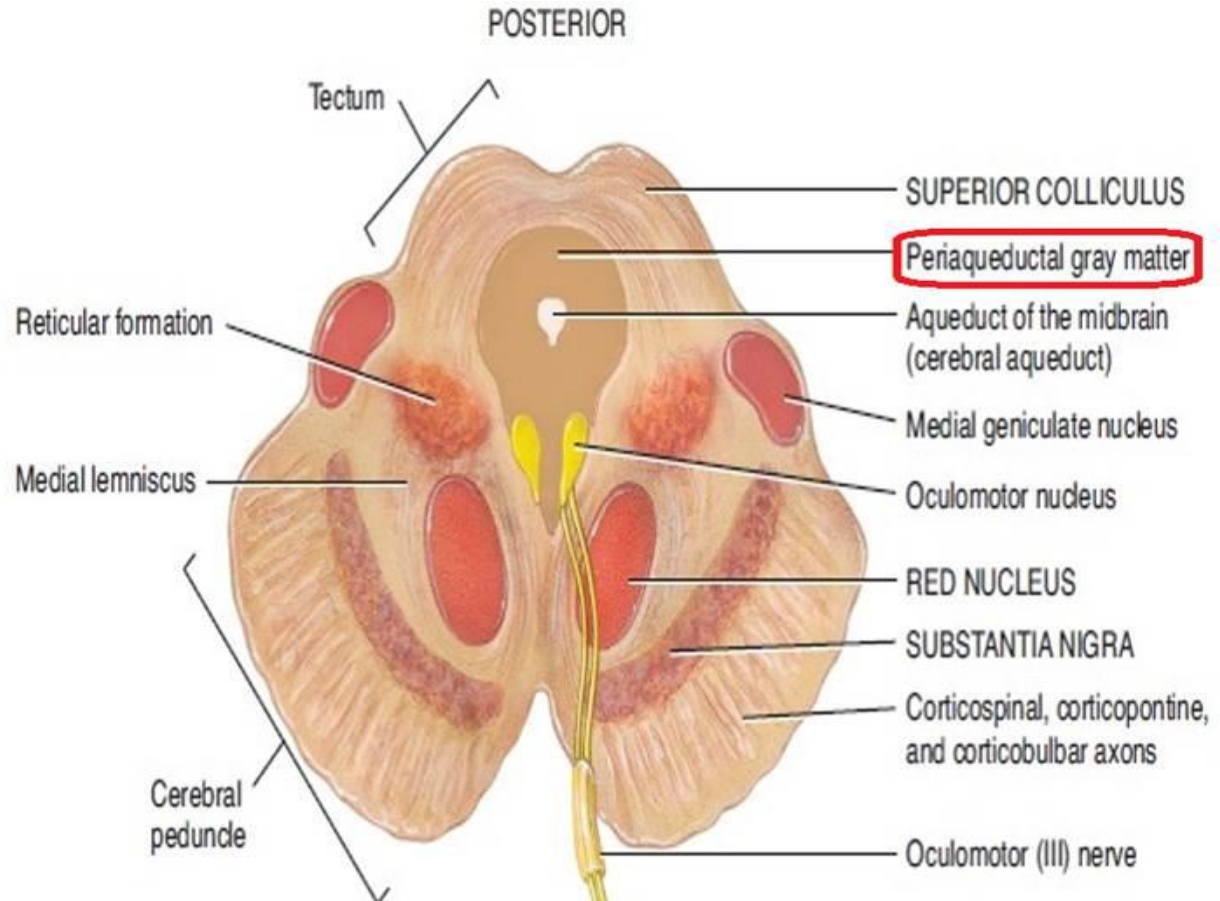
These transmit axons of UMN.

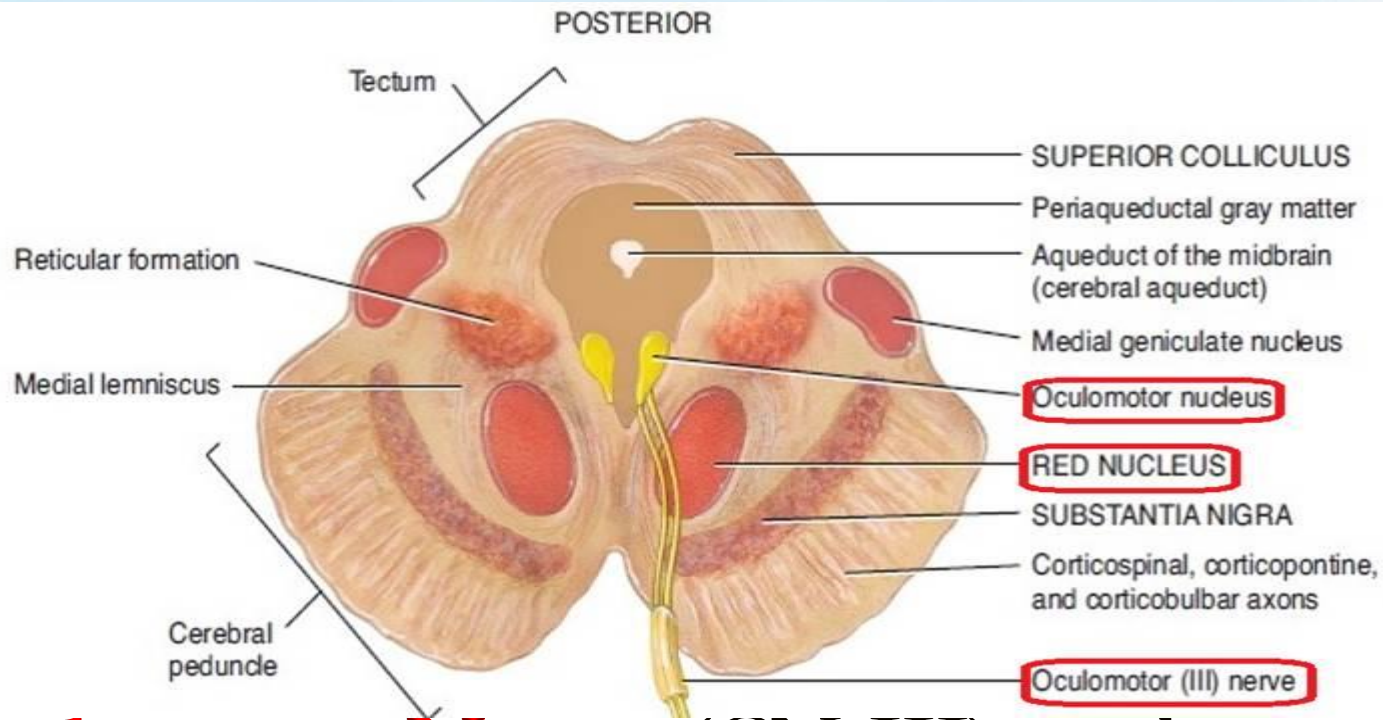


(b) Transverse section of midbrain

# Midbrain internal structures

∞ **Periaqueductal Gray:** Around the cerebral aqueduct, contains neurons involved in the **pain desensitization** pathway





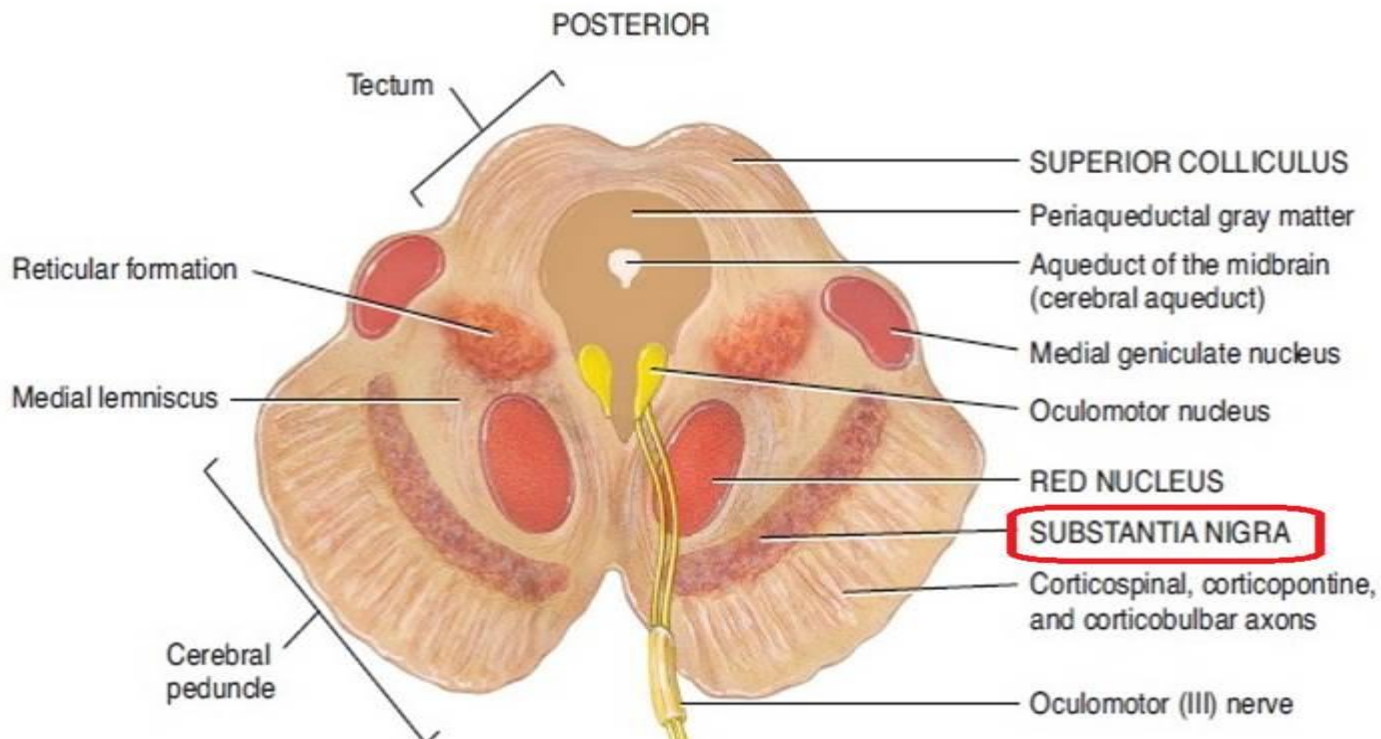
❧ **Oculomotor Nerve (CN III) nucleus.**

❧ **Trochlear Nerve (CN IV) nucleus.**

❧ **Red Nucleus:** This is a motor nucleus that sends a **descending tract** to the lower motor neurons.

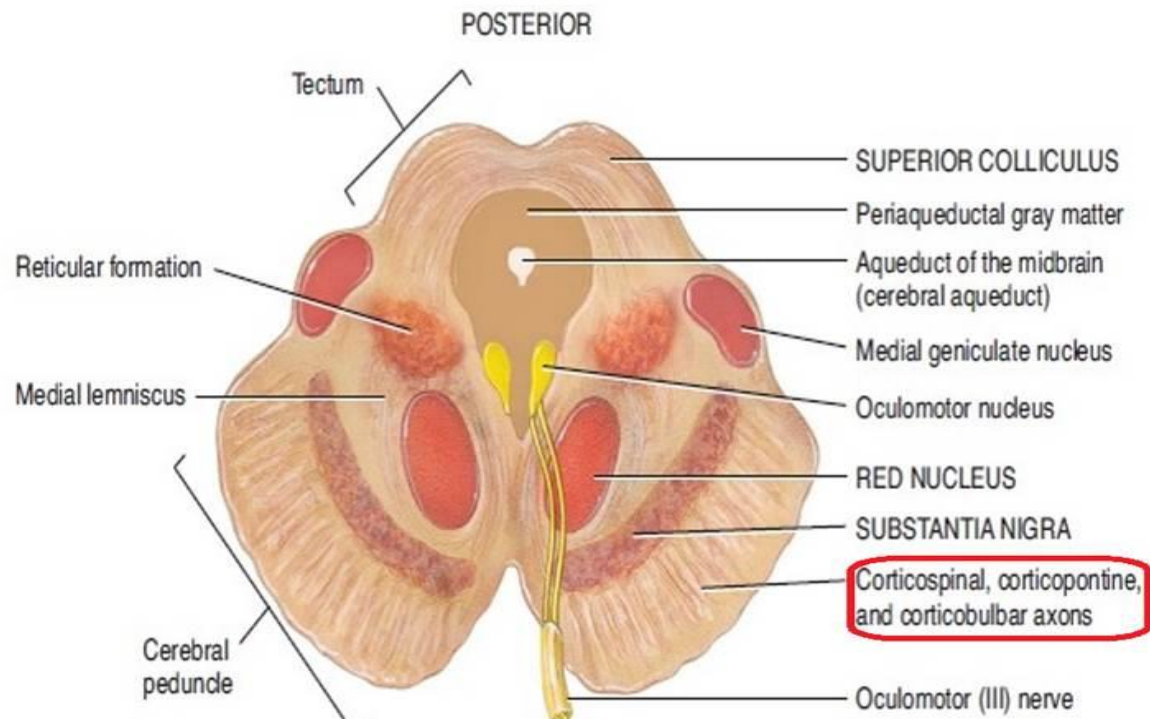
## ❧ Substantia Nigra:

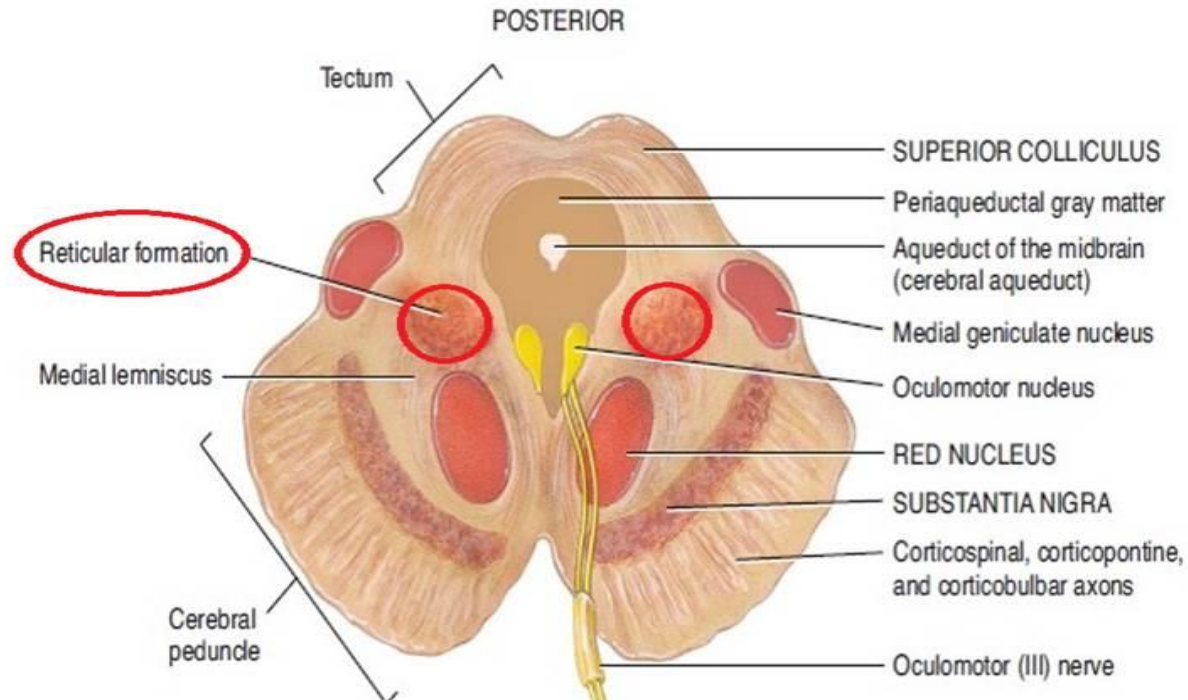
- ❧ A concentration of neurons in the ventral portion of midbrain
- ❧ It is involved in **motor function**.



## ∞ Central Tegmental Tract:

- ∞ Directly anterior to the floor of the 4th ventricle.
- ∞ It is a pathway by which many tracts project up to the cortex and down to the spinal cord.



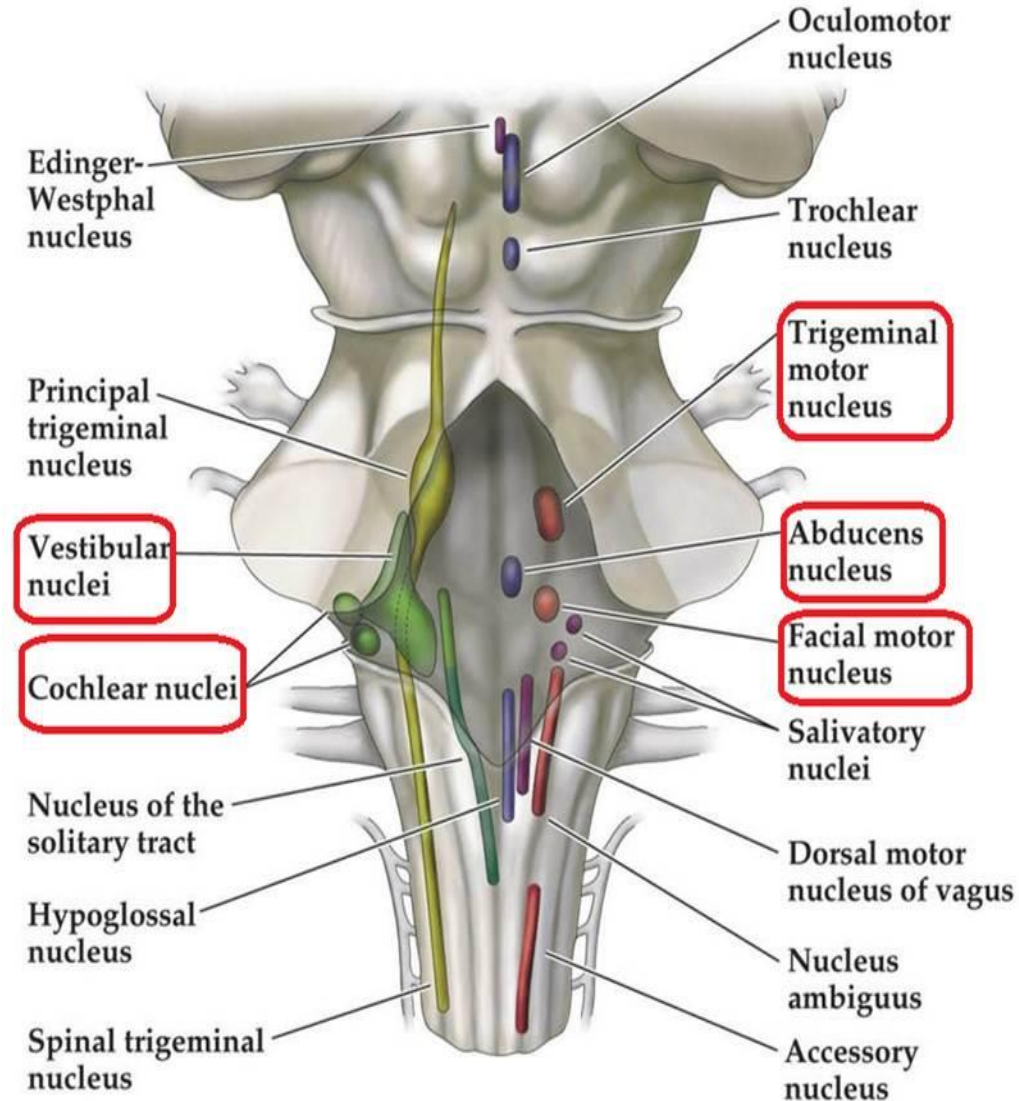


∞ **Reticular Formation:** A large area that is involved in various important functions of the midbrain:

- ☑ It contains LMN
- ☑ It is involved in the pain desensitization pathway
- ☑ It is involved in the arousal and consciousness systems
- ☑ It contains the locus coeruleus, which is involved in intensive alertness modulation and in autonomic reflexes.

# The Pons

- At the level of the midpons, trigeminal nerve (CN V) emerges.
- Between the basal pons, cranial nerve 6 (abducens), 7 (facial) & 8 (vestibulo-cochlear) emerge (medial to lateral).

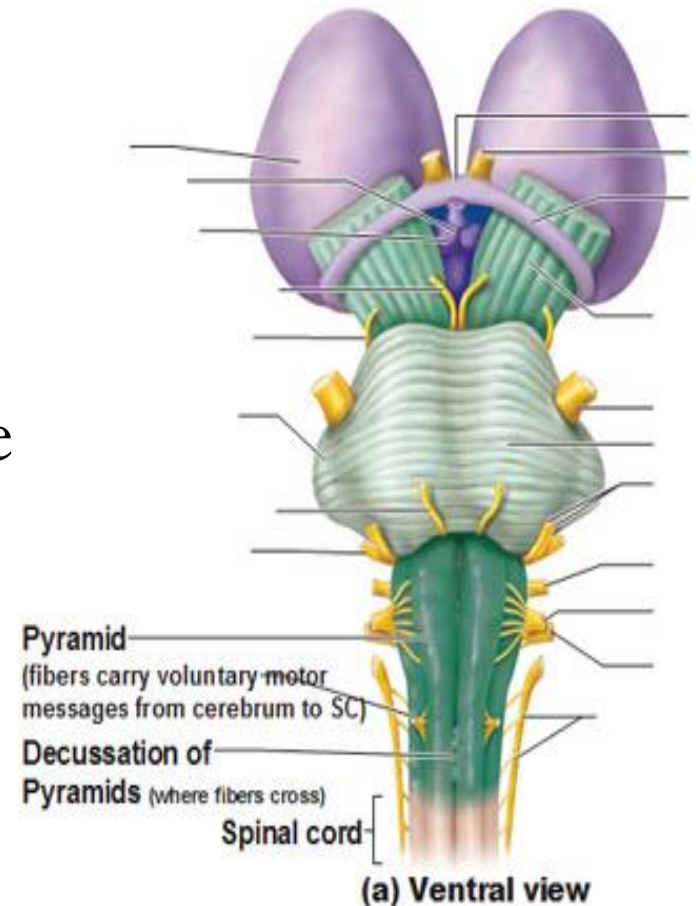




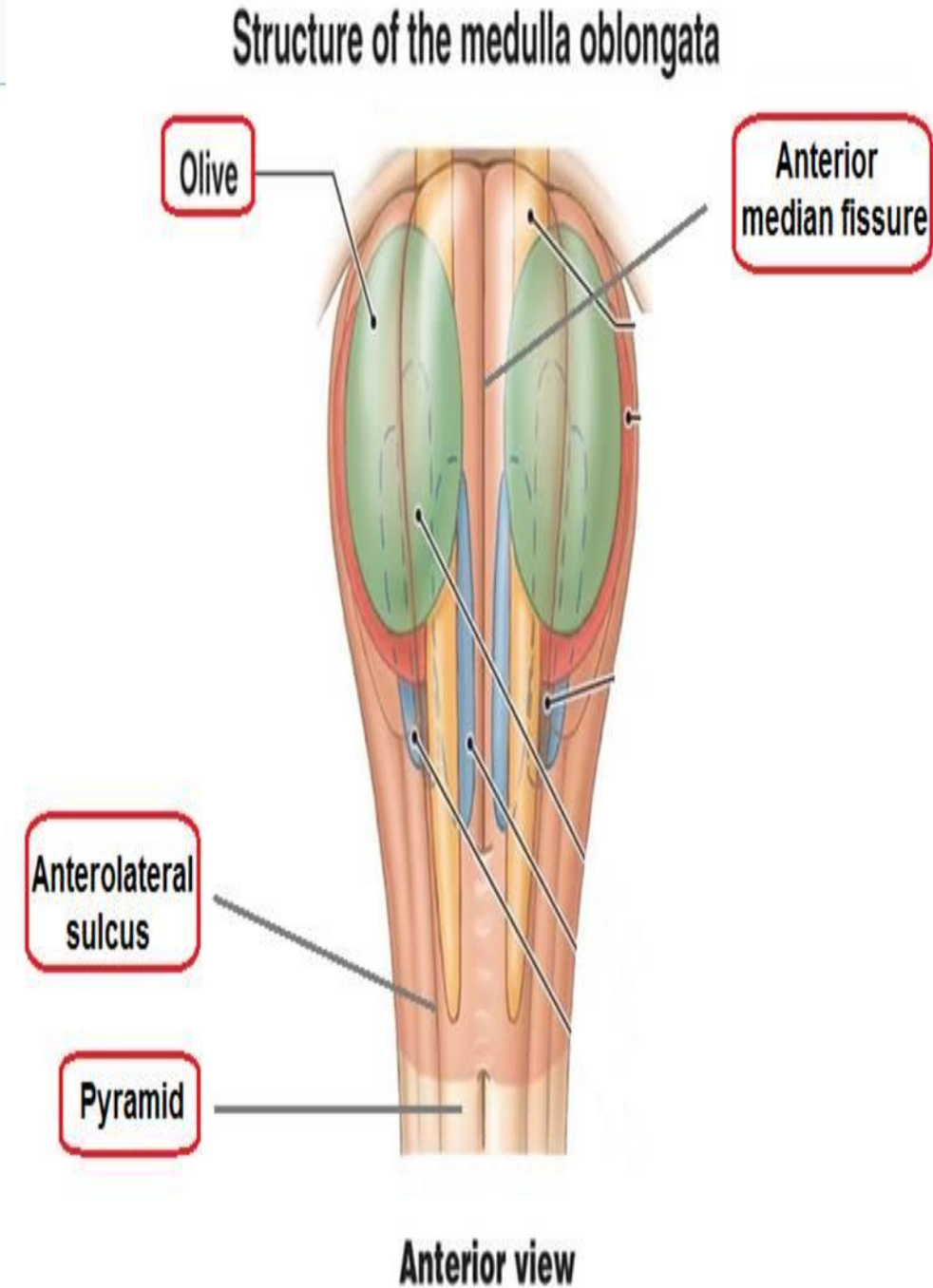
# The Medulla

## Ventral view

- The most medial part of the medulla is the anterior median fissure.
- Moving laterally on each side are the pyramids. They contain the fibers of the **corticospinal (pyramidal) tract** as they head inferiorly to synapse on lower motor neuronal cell bodies within the ventral horn of the spinal cord.

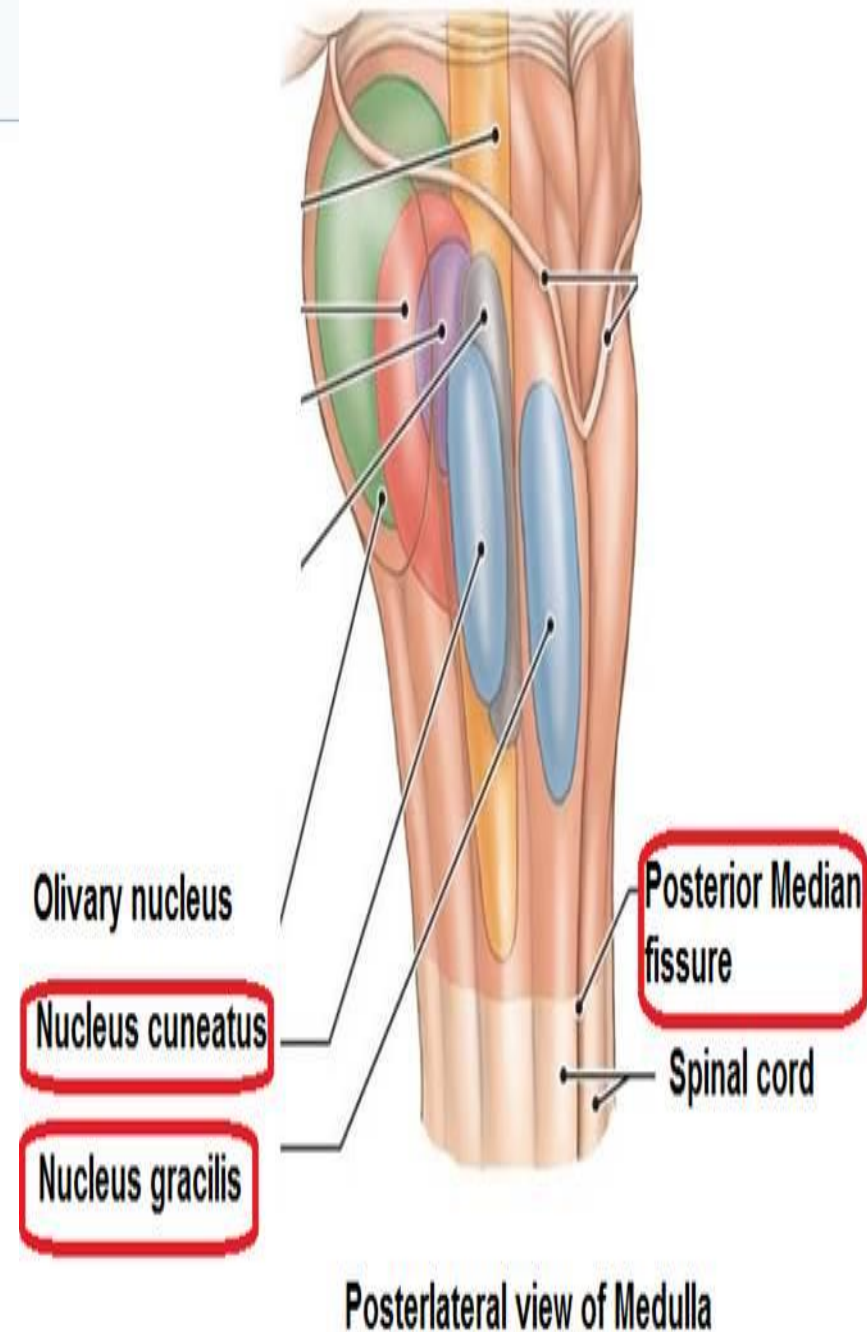


- The anterolateral sulcus is lateral to the pyramids.
- Emerging from the anterolateral sulci are the **hypoglossal nerve** (CN XII) rootlets.
- Lateral to the anterolateral sulci are the **olives** containing underlying inferior olivary nuclei and afferent fibers).
- Lateral (and dorsal) to the olives are the rootlets for **glossopharyngeal** (IX) & **vagus** (X) cranial nerves.

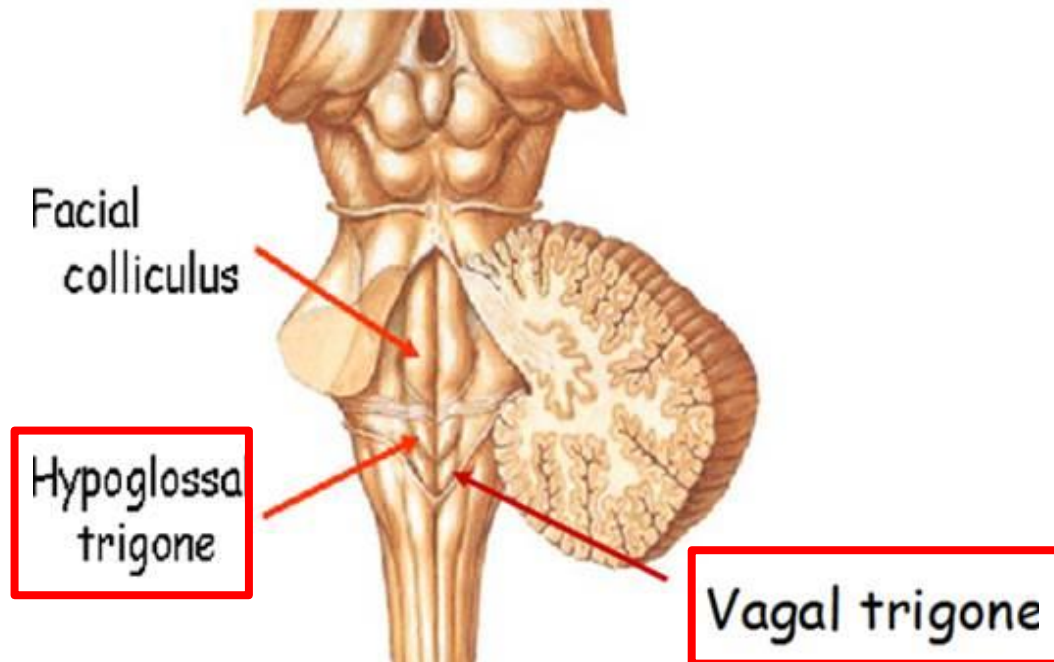


## Dorsal view

- ❖ The most medial part of the medulla is the **posterior median fissure**.
- ❖ Moving laterally on each side is **the fasciculus gracilis**.
- ❖ Lateral to that is the **fasciculus cuneatus**.
- ❖ Superior to each of these, are the **gracile and cuneate tubercles**, respectively. Underlying these are their respective nuclei.



- ❖ In the midline is **the vagal trigone** and superior to that is **the hypoglossal trigone**. Underlying each of these are motor nuclei for the respective cranial nerves.



# Functions of the Brain Stem

1. Conduct functions (way station).

2. Provides the origin of the cranial nerves (CN III-XII).

3. Conjugate eye movement.

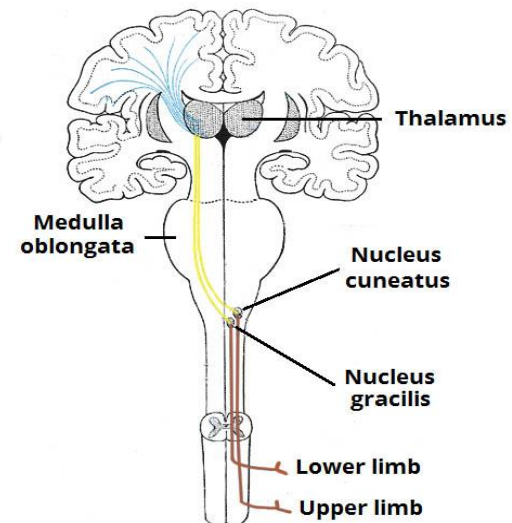
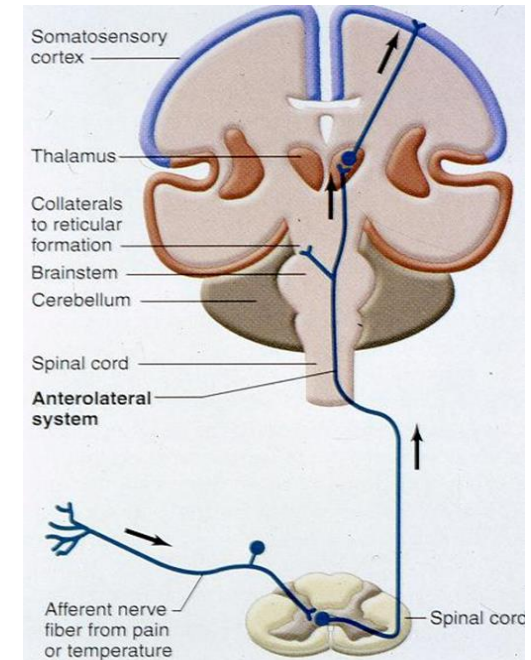
4. Integrative functions.

## 1. Conduct functions

All information related from the body to the cerebrum and cerebellum and vice versa, must traverse the brain stem.

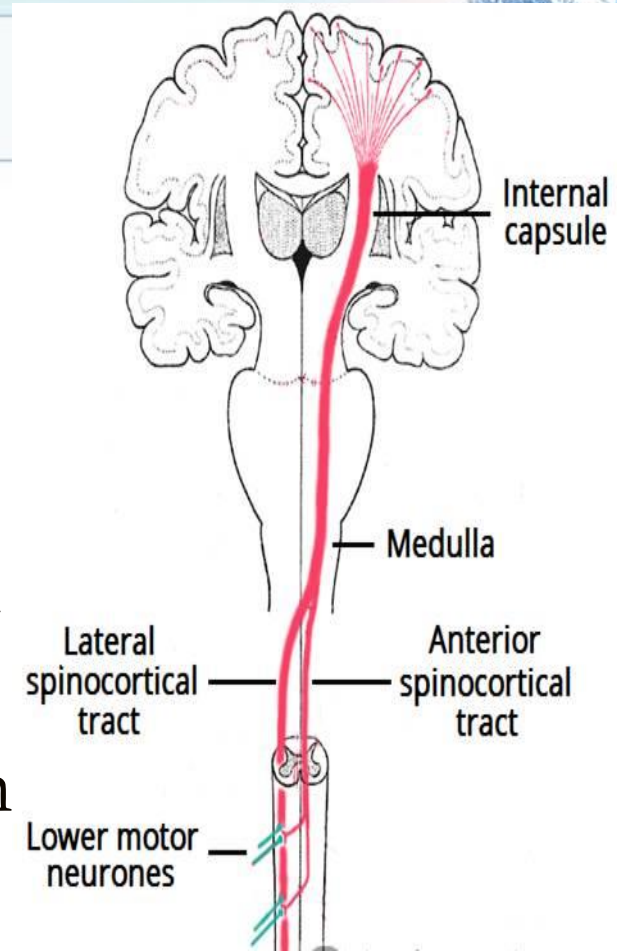
a) The ascending sensory pathways coming from the body to the brain includes:

- The spinothalamic tract for pain and temperature sensation.
- The dorsal column, fasciculus gracilis, and cuneatus for touch, proprioceptive and pressure sensation.



## b) Descending tracts

- Corticospinal tract (UMN): runs through crus cerebri (the anterior portion of the cerebral peduncle), basal part of pons and medullary pyramids; 70-90 % of fibers cross in pyramidal decussation to form the lateral corticospinal tract, synapse on LMN in ventral horn of spinal cord.



- Upper motor neurons that originate in brain stem's vestibular, red, and reticular nuclei, which also descend and synapse in the spinal cord.



**2. The brain stem provides the main motor and sensory innervation to the face and neck via the cranial nerves (CN III-XII).**

The fibers of cranial nerve nuclei except for **olfactory & optic nerve** either originating from, or terminating in the cranial nerve nuclei in brain stem.

# Origin & functions of the cranial nerves

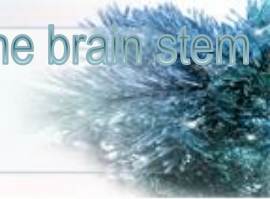## From midbrain

- CN III (oculomotor)
- CN IV (trochlear)

Both moves eyes; CN III constricts the pupils, accommodates.

## From pons

- CN V (trigeminal): Chews and feels front of the head.
- CN VI (abducens): Moves eyes.
- CN VII (facial): Moves the face, tastes, salivates, cries.
- CN VIII (acoustic): Hears, regulates balance.



## From medulla

- CN IX (glossopharyngeal): Tastes, salivates, swallows, monitors carotid body and sinus.
- CN X (vagus): Tastes, swallows, lifts palate, talks, communication to and from thoraco-abdominal viscera.
- CN XI (accessory): Turns head, lifts shoulder.
- CN XII (hypoglossal): Moves tongue.

# Classification of the cranial nerves according to functions

## SENSORY

CN I

CN II

CN VIII



## MOTOR

CN III

CN IV

CN VI

CN XI

CN XII



## MIXED

CN V

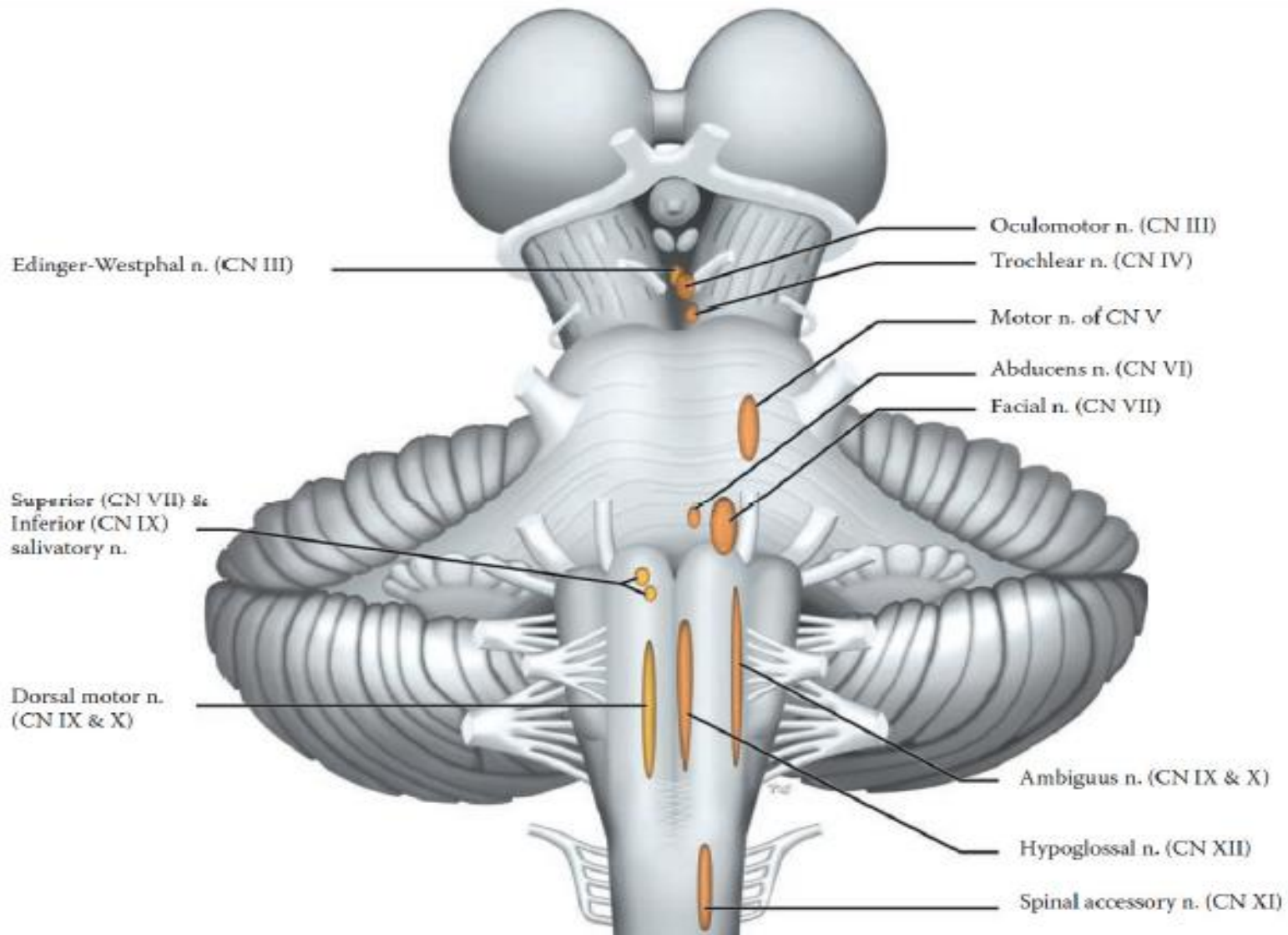
CN VII

CN IX

CN X

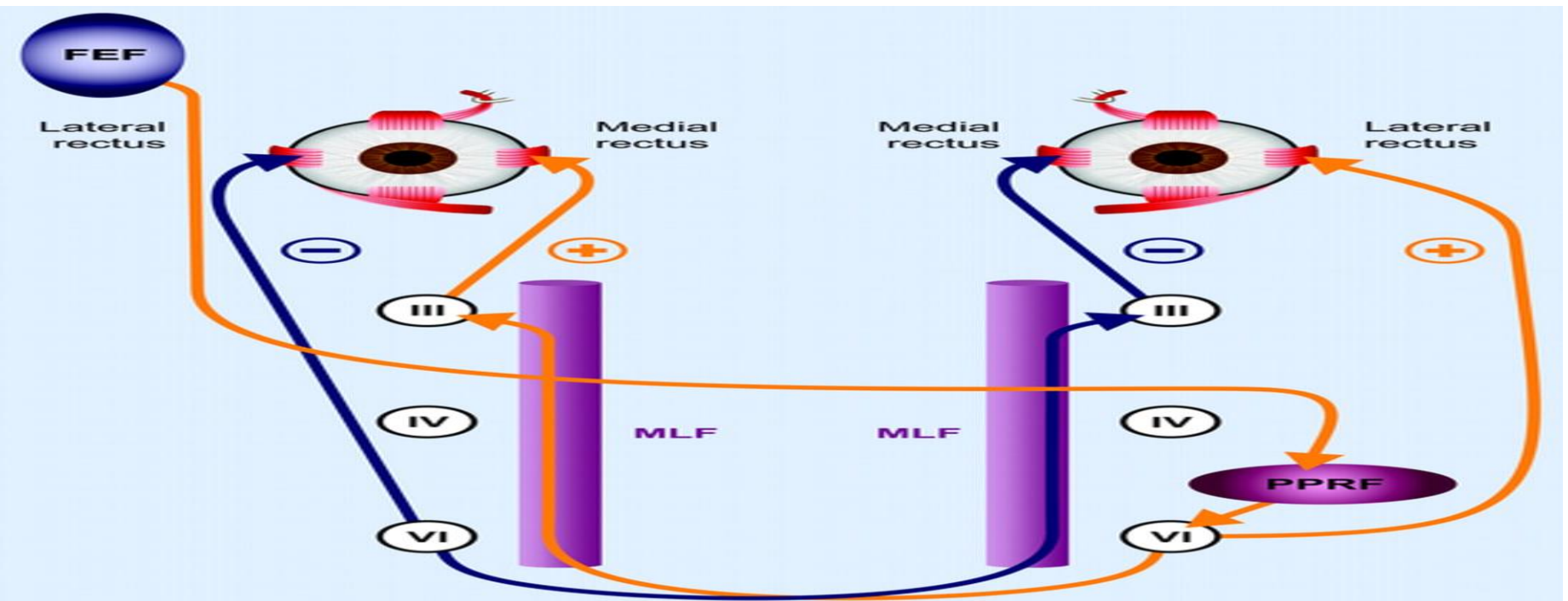


# Cranial Nerves (Motor) Nuclei



# 3. Conjugate eye movement.

It refers to motor coordination of the eyes that allows for bilateral fixation on a single object



The frontal eye field (FEF) projects to the opposite side at the midbrain-pontine junction, and then innervates the paramedian pontine reticular formation (PPRF).

From there, projections directly innervate the lateral rectus (contralateral to FEF) and the medial rectus muscle (ipsilateral to FEF).

The left FEF command to trigger conjugate eye movements to the right.

## 4. Integrative functions

- It controls consciousness & sleep cycle (alertness and arousal) through reticular formation.
- It has got center for cardiovascular, respiratory & autonomic nervous system.
- It has centers for cough, gag, swallow, and vomit.
- Sense of body balance (Vestibular functions)



## 4. Integrative functions...Cont.

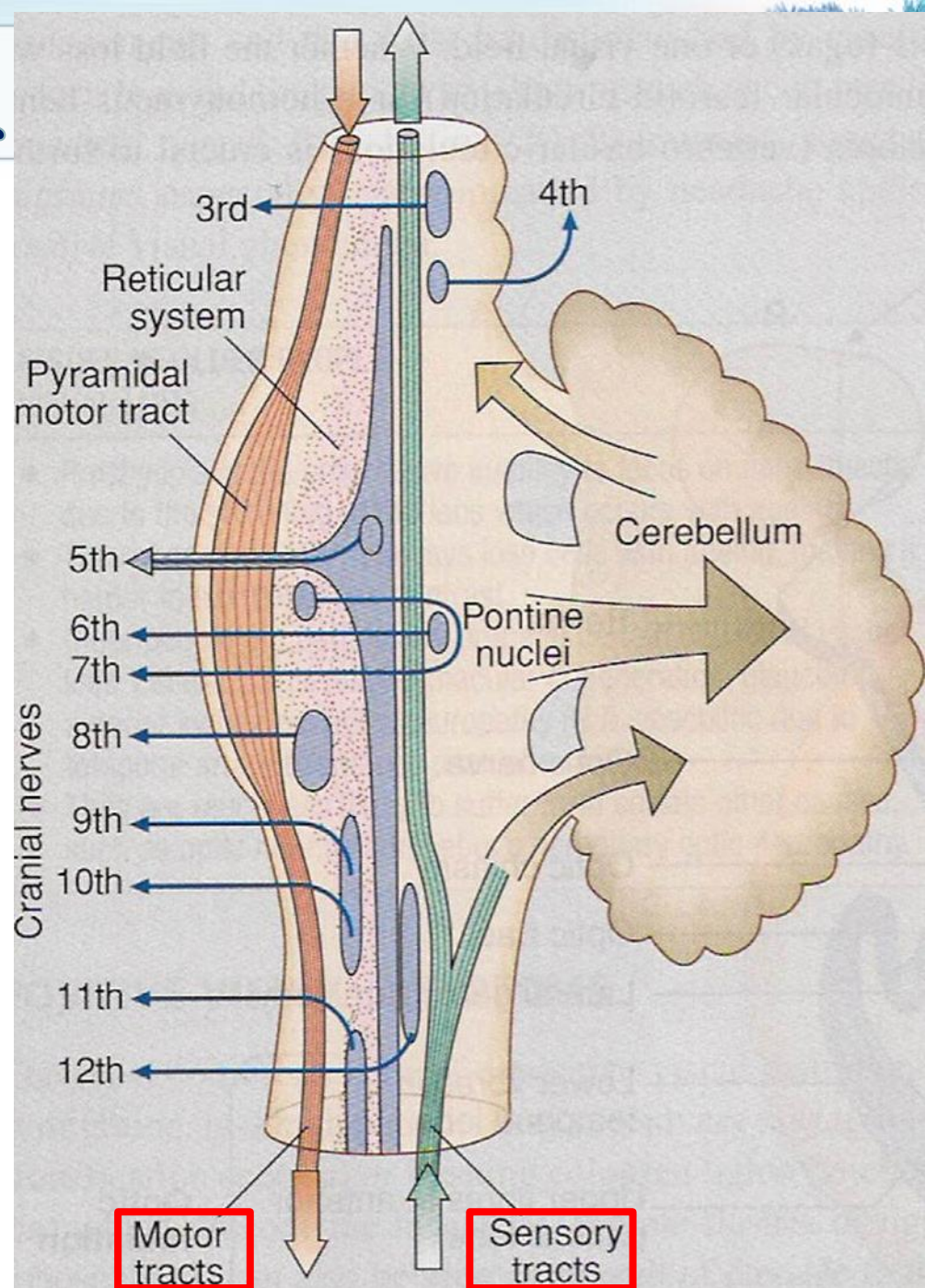
- **Substantia** which is a part of the basal ganglia is present in midbrain and is involved in control of movement.
- Midbrain also contain **red nucleus** which regulate the motor activity through cerebellum.

## 4. Integrative functions...Cont.

- Inferior and superior colliculi are situated on the dorsal surface of the midbrain and is involved in auditory & visual processing required for head movements.
- Pain sensitivity control: **Periaqueductal grey matter** of mesencephalon is an area which is rich in endogenous opioid and is important in modulation of painful stimuli.

# Functional organization of the Brain Stem

- Ventral layer of brainstem is **motor** in function.
- Middle layer is **sensory** in function & contains medial lemniscus which conveys sensory information from dorsal column.



# Function of Midbrain

Nerve pathway  
to cerebral  
hemispheres

CN III -  
Oculomotor  
[motor].  
(Related to eye  
movement)



CN IV - Trochlear  
[motor]. (Superior  
oblique muscle of  
the eye which  
rotates the eye down  
and out)

Auditory and  
Visual reflex  
centers



# Symptoms and signs of midbrain lesion

**Pupils: Midposition to dilated.**

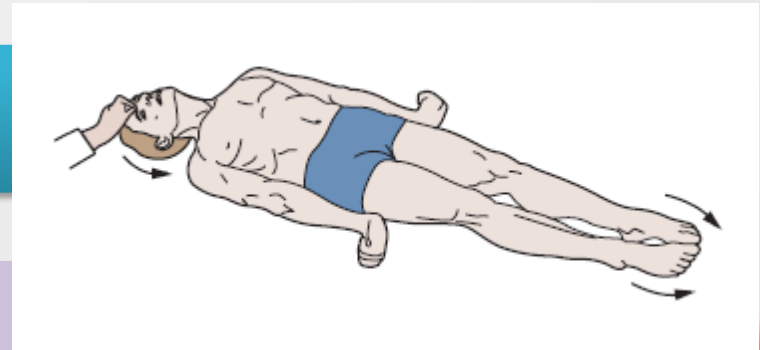
**Reactivity is sluggish to fixed.**

**Posture: Abnormal extensor response.**

**Cranial Nerve (CN) deficits: Ipsilateral CN III, CN IV palsy and ptosis (drooping of eye lids).**

**Respiratory: Hyperventilating.**

**Level of consciousness (LOC): Varies**



# Function of Pons

**CN V -  
Trigeminal  
[motor and  
sensory]. (Skin  
of face, tongue,  
teeth; muscle of  
mastication)**

**CN VIII -  
Acoustic  
[sensory].  
(Hearing)**

**Respiratory  
Center**



**CN VI -  
Abducens  
[motor]. (Lateral  
rectus muscle of  
eye which  
rotates eye  
outward)**

**CN VII -  
Facial [motor  
and sensory].  
(Muscles of  
facial  
expression).**

# Symptoms and signs of lesion in pons

**Pupils size: Pinpoint**

**Posture: Abnormal extensor response**

**CN Deficits: CN V, CN VI, CN VII, CN VIII**

**Respiratory:**

- Apneustic (Abnormal respiration marked by sustained inhalation).
- Hyperventilation.


**LOC: Semi-coma**

# Function of Medulla Oblongata

**Crossing of  
motor tracts.**

**Cardiac Center**

**Vasomotor  
Center**



**Respiratory  
Center**

**Centers for  
cough, gag,  
swallow, and  
vomit.**






# Function of Medulla Oblongata (Cont.)

**CN IX - Glossopharyngeal ) [mixed].  
(Muscles & mucous membranes of  
pharynx, the constricted openings  
from the mouth & the oral pharynx  
and the posterior third of tongue).**

**CN X - Vagus  
[mixed]. (Pharynx,  
larynx, heart,  
lungs, stomach)**



**CN XI - Accessory  
[motor]. (Rotation  
of the head and  
shoulder)**

**CN XII -  
Hypoglossal [motor].  
(Intrinsic muscles of  
the tongue)**



# Symptoms and signs of lesion in Medulla

**Pupils: Dilated.**

**Reactivity is Fixed.**

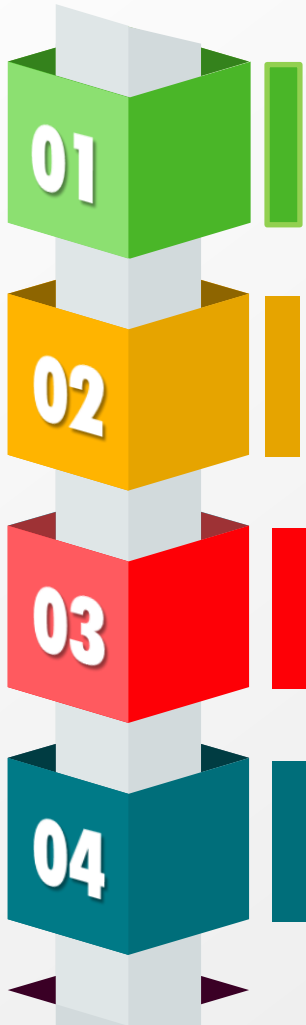
**Movement: Ipsilateral paralysis.**

**CN Palsies: Inability to control movement. Absent cough, gag.**

**Respiratory: Abnormal breathing patterns**

**LOC: Comatose.**

# Brain Stem Function Tests



☞ **To test reticular formation**

Alertness, Consciousness & Sleep.

☞ **Corticospinal tract**

Motor power, reflexes


☞ **Pain response**

Facial grimacing on firm pressure over the supra orbital ridge.

☞ **To test respiratory center**

look for the normal pattern of respiration

# Brain Stem Function Tests



☞ **To test cardiovascular center**  
Look for normal circulatory function

☞ **To test brainstem reflexes:**

- Pupillary and corneal reflexes.
- Vestibulo-ocular reflex: Injection of iced water into the ear will produce eyes movement.
- Oculo-cephalic reflex: Eyes will be fixed when head is moved in one or another directions.
- Gag reflex.
- Cough reflex

# The rule of 4 of the brain stem

## ☞ 4 structures in 'midline' and begin with 'M'

- Motor pathway (Contralateral weakness)
- Medial lemniscus (Contralateral proprioception/vibration loss)
- Medial longitudinal fasciculus (Ipsilateral internuclear ophthalmoplegia)
- Motor nucleus and nerve (Ipsilateral CN function loss).

## ☞ 4 motor nuclei in midline and are those that are divisors of 12 (3,4,6,12)

- Nuclei of CN 3, 4, 6, 12 are midline
- Nuclei of CN 5, 7, 9, 11 are lateral

## ☞ 4 structures to the 'side' (lateral) and begin with 'S'

- Spinocerebellar pathway (Ipsilateral ataxia)
  - Spinothalamic pathway (Contralateral pain/temp sensory loss)
  - Sensory nucleus of CN5 (Ipsilateral pain/temp loss in face)
  - Sympathetic pathway (Ipsilateral Horner's Syndrome)
- 

# The rule of 4 of the brain stem...Cont.

☞ **4 CN in medulla (9,10,11,12), 4 in pons (5,6,7,8) and 4 above pons (1,2,3,4)**


## ☞ Medulla

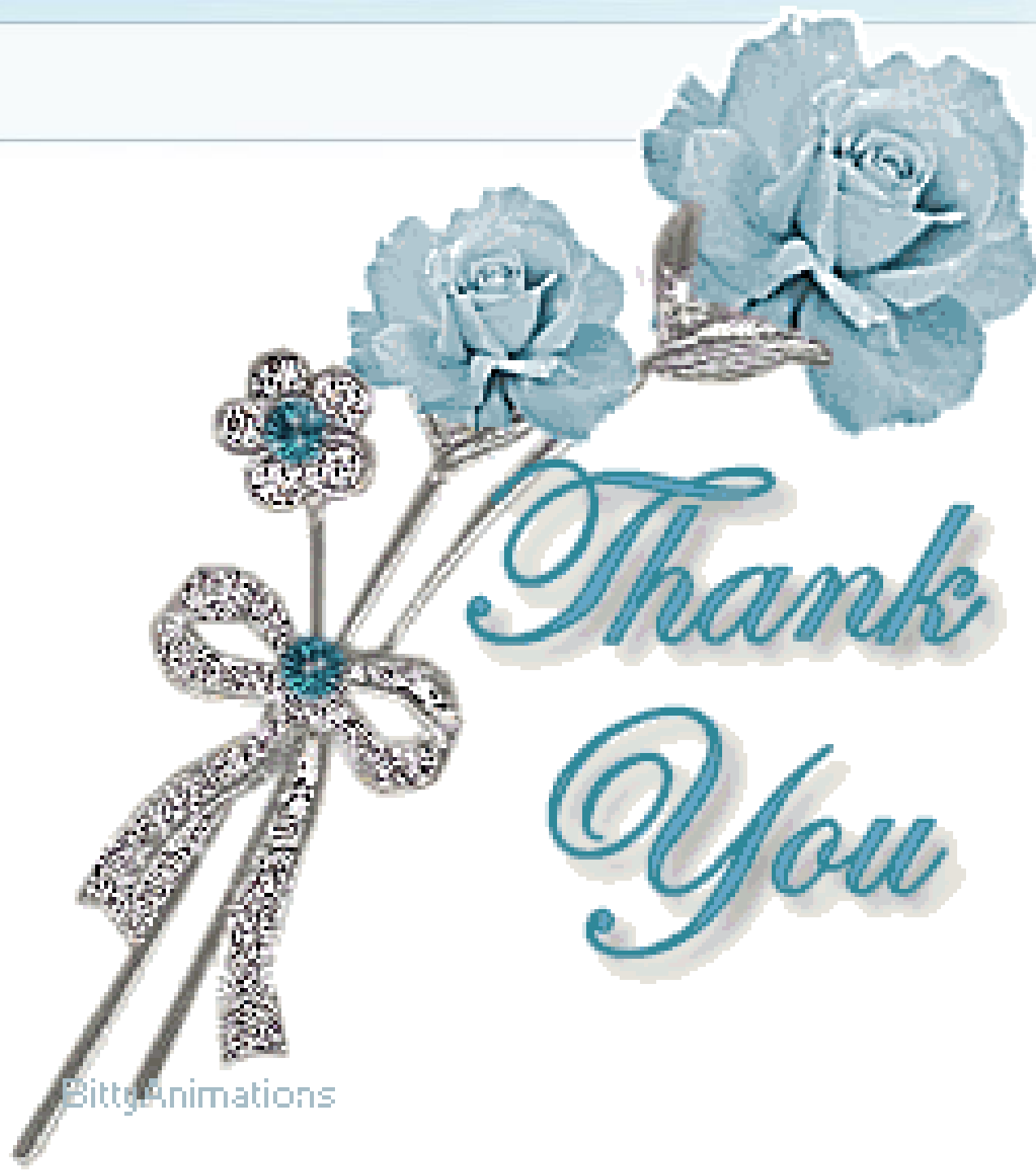- Glossopharyngeal CN9 (Ipsilateral pharyngeal loss)
- Vagus CN10 (Ipsilateral palatal weakness)
- Spinal accessory CN11 (Ipsilateral shoulder weakness)
- Hypoglossal CN12 (Ipsilateral weakness of tongue)

## ☞ Pons

- Trigeminal CN5 (Ipsilateral facial sensory loss)
- Abducent CN6 (Ipsilateral eye abduction weakness)
- Facial CN7 (Ipsilateral facial weakness)
- Auditory CN8 (Ipsilateral deafness)

## ☞ Above the pons

- Olfactory CN1 (not in the midbrain)
  - Optic (not in the midbrain)
  - Oculomotor CN3 (eye turned out and down)
  - Trochlear CN4 (eye unable to look down when looking towards nose)
- 



Thank  
You